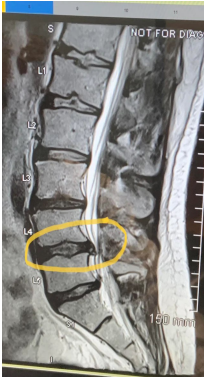

Neurosurgery

Q1



السؤال كان فيه صورتين صورة ال spine وصورة لل dermatomes وكان به نحدد ايش ال dermatomes اللي متضرر حسب صورة ال spine ما قدرت احط صورة لل dermatomes لانه اجابة الدكتور مش منطقية مع الصورة

A) which one of these dermatomes will be affected ?

B) which of the following will be affected by this compression ?

- hip flexion
- Hip extension
- Dorsiflexion
- Knee extension

Ans : dorsiflexion

C) which of the following isn't a red flag

- urinary inconstistence
- Bowel dysfunction
- knee paresthesia
- Urinary retention

D) neurogenic claudication is :

- relieved by rest
- Downhill claudication

السؤال كامل ارشيف

Brain tumour

1) Meningioma true??

Slow growing

2) What to see?

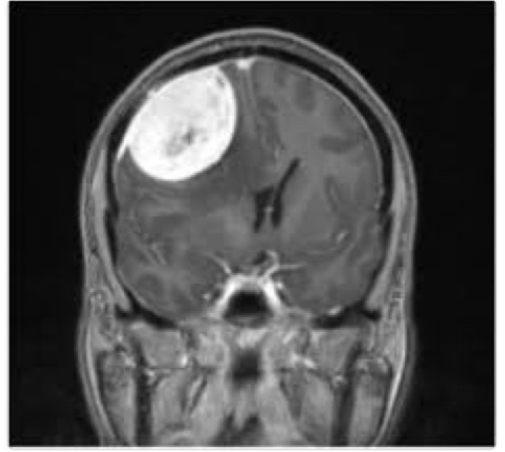
Dural tail sign

3) Best for grading??

Histopathology

4) On Histo??

Psoomma bodies



Subarachnoid haemorrhage

A) don't occur before 3 days

Vasospasm

B) which of the followings consider as subarachnoid test

- hunt and hess
- WFNS
- other test
- A+B

Ans:A+B

C) why we use CCB

- vasodilation
- Neuroprotective
- Prevent vasospasm

D) factor that favour clipping

- elderly patients
- Comorbidity
- Poor clinical grade
- Good neurological exam

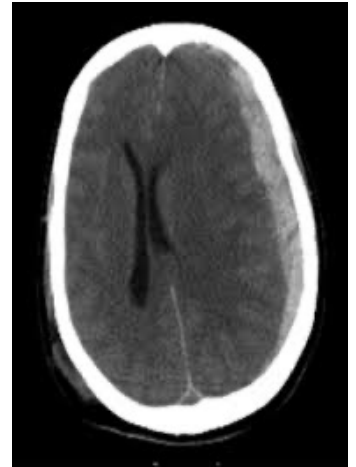Subdural haemorrhage

A) not true

Don't cross suture

B) acute feature

- crescent shape
- Hypo-dense
- Hyper-dense



Ans : hyper dense

C) management

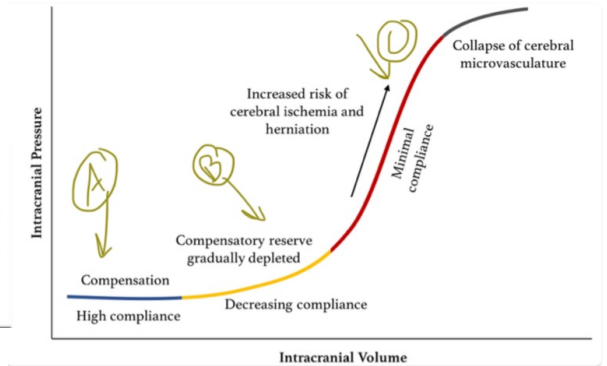
Evacuation

D) GCS

Open eye to painful stimuli display flexion to pain incomprehensible sound?

- 6
- 7
- 8
- 9

ICP



A) point C
Herniated

B) point A
Auto-regulation

C) management
ICU + ventilation+ emergency surgery

Which side of hemisphere is affected?
Right hemisphere