



# Forensic Archive (C)



1-What is the legal definition of abortion:

- A)expulsion of an embryo, viable, of 28 weeks of pregnancy
- B)expulsion of an embryo, before 24 weeks of pregnancy
- C)expulsion of an embryo, dead, of 28 weeks of pregnancy
- D)expulsion of an embryo, viable or dead, of 28 weeks of pregnancy

Answer: C

2- An old man had **primitcarb** poisoning (which is a carbamate), he suffered from **dyspnea** and other symptoms less than 24h which one of these statements is true:

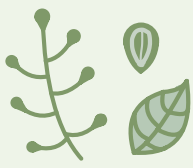- a) give him oximes as soon as possible
- b) don't give oximes
- c)give oximes only when the condition is severe

Answer: B

3-a Palestine viper has bitten Ali, and Noah tried to suck the venom through the bite mark, 3 hours later symptoms appeared on Ali so Noah took him to the ER, the physician gave both Ali and Noah antivenom as he believed it's a prophylactic measure:

- a)Physician is right
- b)Physician is wrong, he shouldn't have given Noah as the antivenom has no effect nor Ali as he only has local effect
- c)Physician is wrong, he shouldn't have given Noah as the antivenom has no effect on him but giving to Ali is right
- d)Physician is wrong as Noah is asymptomatic

Answer: C



#### 4-What's false concerning wounds:

Blackening around the wound isn't related to the **distance** of firearm.

#### 5-What's the correct answer about target site for corrosive damage : (السؤال)

(محدد انه المدة كانت قصيرة)

We can see esophagus and stomach by hot **endoscopy**

#### 6-Baby came to ER, what should you do:

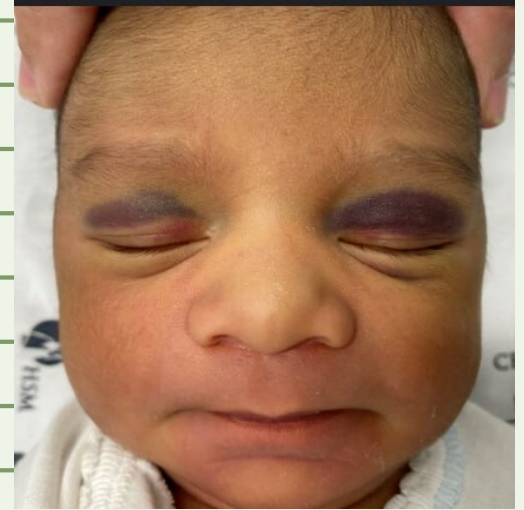
A)Nothing, the baby is well

B)Monitor the baby

C)You should take CT images for the skull

D)Caused only by direct blow to his eye

Answer:C

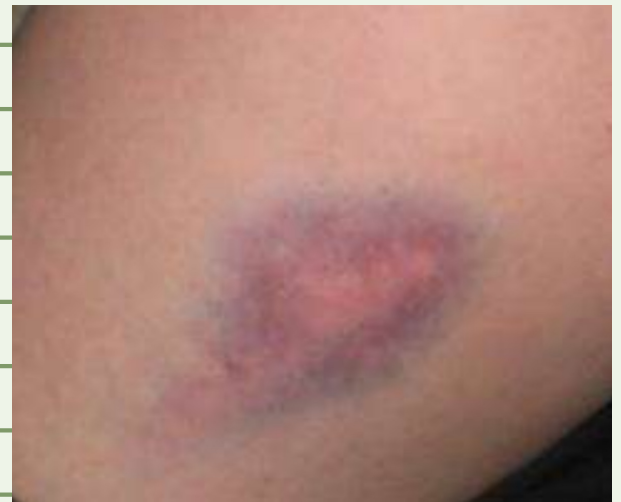

#### 7-What's true about this bruise in a dead patient:

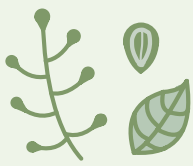A)the colour of bruise determines the accurate time of death

B)Bruise indicates undergoing physical pressure and we have to transfer him to the forensic medicine

Answer:B



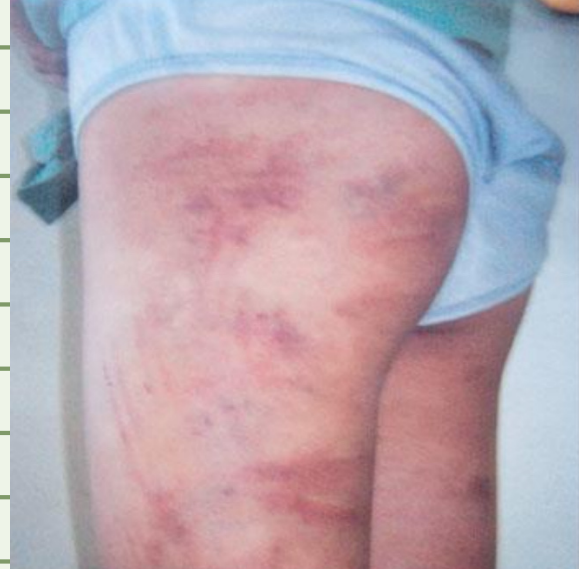(صورة تقريبية لأكثر من كدمة)



**8-Picture shows a child, who misses his classes and has erratic behavior:**

- A) physical abuse, should do more investigation about the family home condition
- B) his abuse is more of physical more than sexual
- C) accidental injury
- D) his abuse is more of psychological than physical
- E) his abuse is more of emotional than physical

Answer: A



(صورة تقریبه)

**9-A man was found dead near the fireplace in his farm what's the wrong assumption:**

It's definitely suicide (it could be accidental)

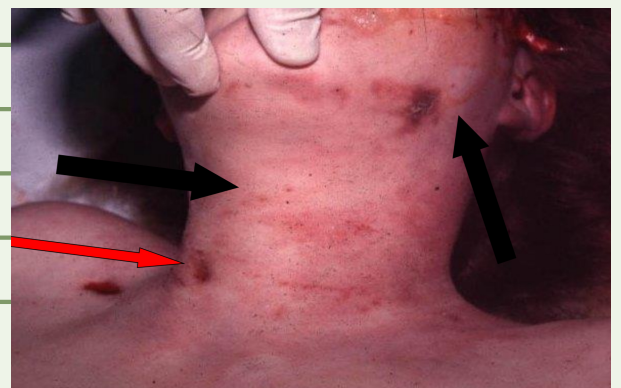
**10-a man took a long shower, and the water heater was on and he was later found dead in the shower, what's the correct answer:**

- A) Suicide
- B) Cyanide poisoning case
- C) O<sub>2</sub> dissociation curve shifted to the left

Answer: C

**11-Choose the correct answer :**

Hyoid bone fracture is most likely involved





**12- When to stop giving atropine to a person who has been poisoned:**

A) When **respiratory** secretions are cleared

B) When all manifestations stop

C) Change in pin point pupil size

Answer: A

**13- Pic of dead man whose neck and upper half of his back was tensed & his head was elevated:**

A) cadaveric spasm

B) rigor mortis

C) flaccidity

Answer: B

**14- As shown in this picture, choose the case that doesn't cause it:**

Throttling, CO poisoning, haemorrhage, hanging

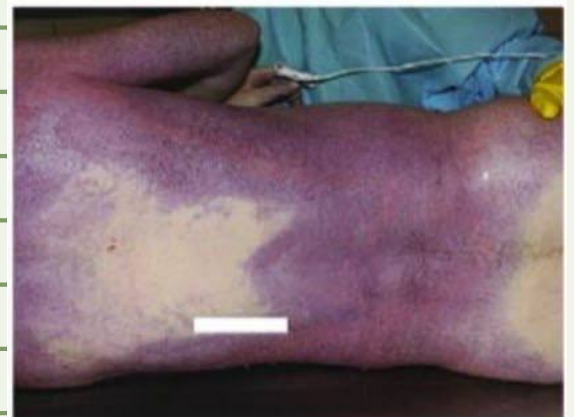A) all except CO poisoning

B) all except hanging

C) All

D) all except haemorrhage

Answer:





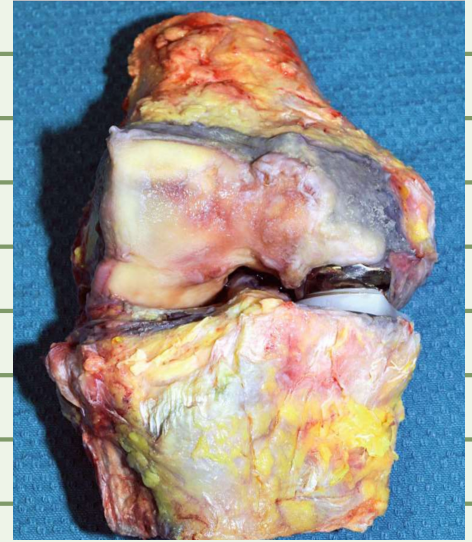15- This person could be identified by:

A) DNA

B) X-ray

C) Medical record

Answer: C



16- choose the right answer

A) closed mass disaster

B) open mass disaster

C) closed open mass disaster

Answer: A



17- A 20 years old male with rheumatic fever was admitted to hospital with severe dyspnea and palpitation, he had generalized edema and marked cyanosis. Echo was done revealing aortic stenosis. Treatment started but he died. Write death certificate:

السبب المباشر للوفاة : هبوط حاد بالدورة الدموية

المرض الاصلى: حمى روماتيزمية

الحاله المرضية: ضيق في الصمام الاورطي



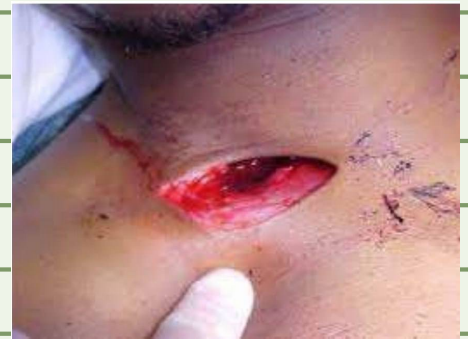18- A man came to ER poisoned by ethanol after 1 hour, what is the correct measure:

- A) IV fluid
- B) gastric lavage
- C) emesis

Answer: A

19- Picture shows:

Stab wound



20- man came with chronic constipation what's the poisonous material that he was exposed to?

- A) chronic lead toxicity
- B) Paracetamol toxicity
- C) Arsenic toxicity

Answer: A

21- Pic of yellow eyes (jaundice), a man ingested a large amount of paracetamol, what should you do:

Give antidote and treat the liver injury

22- A case of acute ethanol poisoning, what is the correct answer:

Give Naloxone



23-Presentation that is correct concerning methanol:

Snow storm appearance

24-A clean stab wound in chest, that is 5cm wide, 2cm deep, directed downwards, the victim was unable to struggle. Choose the correct answer  
(الضحية ما كان عنده مجال للمقاومة)

A)homicidal

B)accidental

C)suicide

Answer:

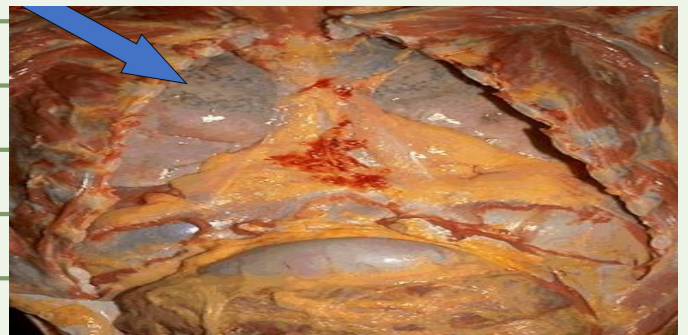
25-Pic shows emphysema aquosum,  
choose the wrong answer:

A)Shows rib markings

B)Lots of froth

C)Has certain odor

Answer: C



26-Regarding acidification of urine for amphetamine, choose the wrong answer:

A)complicated by metabolic acidosis

B)not used nowadays

C)significantly enhances toxin removal

D)done on weak bases

Answer: C