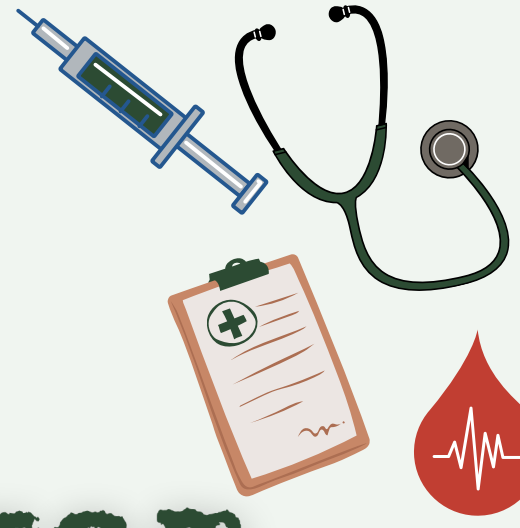



# CNS Final Exam

2024 - 2025

Done by:

Khalid Bayaydah

Designed by:

Razan fawwaz

Lateral part of frontal lobe blood supply >> middle cerebral

1. Tela chorioidae situated :

A. Body of the central canal.

B. Roof of the inferior horn of the lateral ventricle.

3. superior surface of the thalamus and the body fornix.\* علاغلب

4. Which of the following is true about C. Neoformans:

1. ingestion of its spores cause systemic manifestation.

2. Produce mucoid colonies by culturing on Sabouraud dextrose agar \*

5. which of the following drugs contraindicated with stroke case:

1. ketamine\*

2. halothane

3. desflurane

6. If you have a bout of diarrhea on your way to work; The recommended drug to buy from a drugstore?

1. loperamide\*

7. One of the following not a histological feature of oligodendroglioma:

1. nuclear pseudoinclusion\*

2. clear cytoplasm.

3. fried egg appearance

4. thin walled blood vessels

8. A patient who bought street drug yesterday comes to you and he is showing signs of diarrhea, dilated pupils and he is agitated, These symptoms may have appeared due to which of the following :

A. Cocaine overdose

B. Opioids overdose

C. Withdrawal symptoms due to Opioids abstinence \*

10. which of the following have no relation to the thalamus:

A. Posterior limb of internal capsule

B. Lentiform nucleus

C. Body of corpus callosum\*

11. not a boundary of the 3rd ventricle:

A. Optic tract\*

B. mamillary body

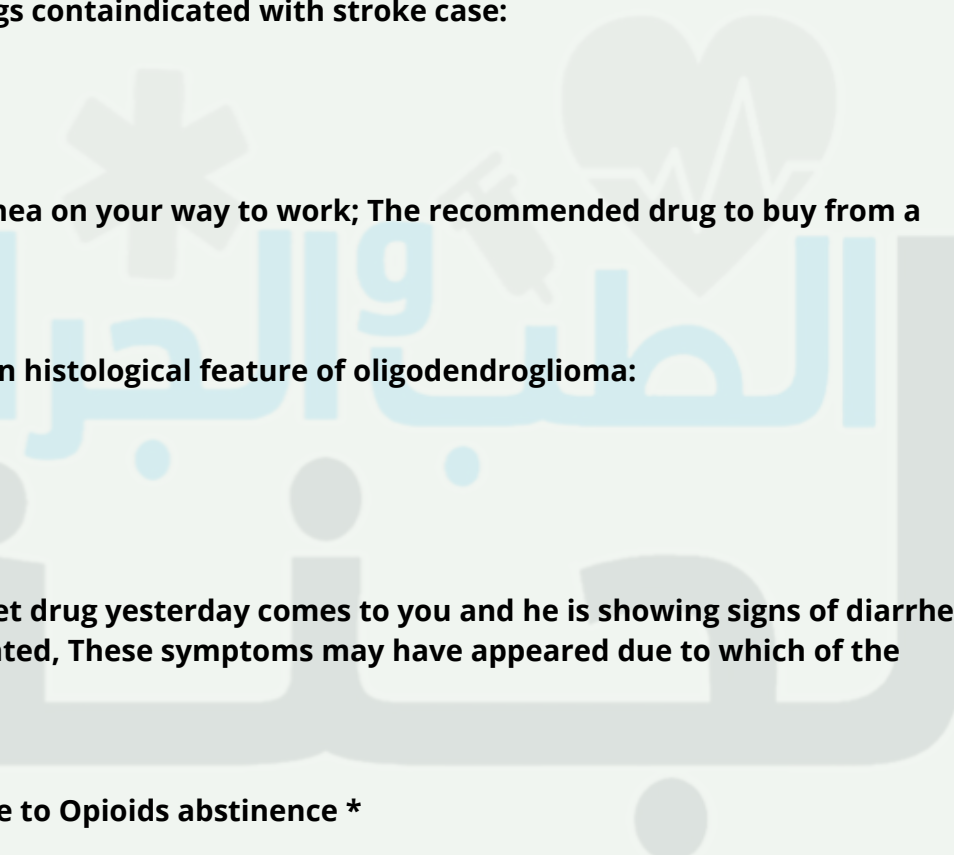
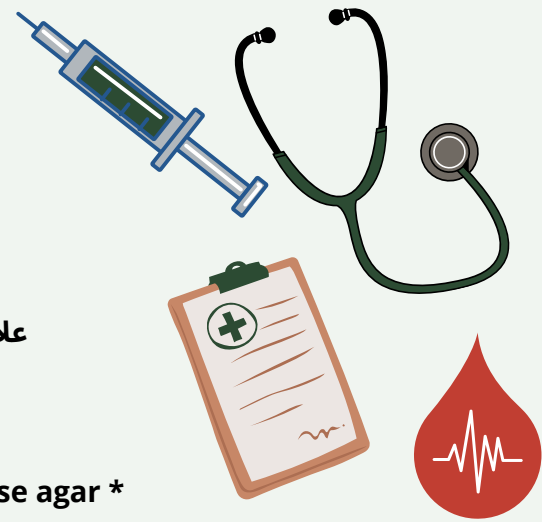
3. Tegmentum of the midbrain

12. Outer band of ballilarger:

Internal granular\*

13. Best definition of sulci:

Depths in the cerebral cortex for increasing surface area\*



14. 3rd layer of the midbrain at the superior colliculus:  
Stratum opticum\*

15. Meningitis in infants is commonly due?  
Streptococcus agalctiae \*

16. facial colliculus found at:  
Lower level of pons\*

17. A doctor suspects that a patient is with subarachnoid hemorrhage even though the CT scan is normal, the best next step is:

- A. MRI
- B. Lumbar puncture and CSF analysis\*
- C. Cranial doppler ultrasound

18. one of the following not supplied by the anterior cerebral artery:

- A. Lateral part of frontal lobe\*
- B. Medial part of frontal
- C. Medial part of parietal

20. The mother of a child suffering from absence seizures came to a doctor clinic اشفي مثل هيك the recommended drug to prescribe:  
A. ethosuximide

- Which of the following is correct about metabotropic receptors? Answer: Comprise a single protein subunit, winding cell membrane seven times (transmembrane domains)
- Pellicle formation: TB

Not found in cerebral tissue?

- 1) HMG-CO synthase\*
- 2) glucose
- 3) SCOT
- 4) lactate

GABA main function?

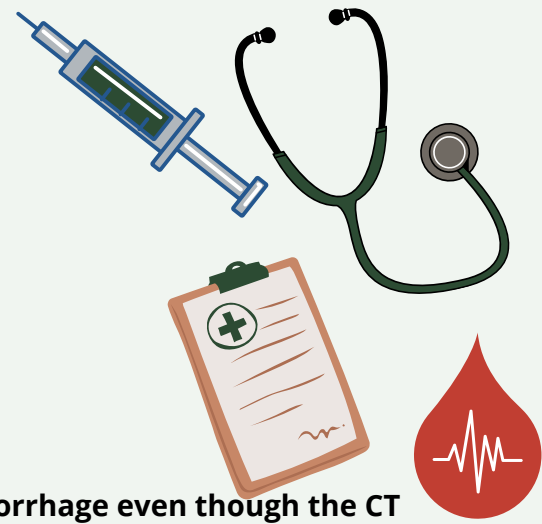- 1) main inhibitory\*
- 2) main excitatory

Supplying muscle of mastication?

- 1) ant cerebral artery
- 2) middle cerebral artery\*
- 3) posterior cerebral artery

Which of the following white matter is not related to the thalamus

- A. Body of corpus callosum\*
- B. Hypothalamus
- C. Stria habenularis
- D. External medullary lamina
- E. Stratum zonale



Lesion in middle cerebral artery produce damage to?

- 1) motor coordination and balance
- 2) production and comprehension of language\*
- 3) visual damage

The nerve supply of nuclear bag of muscle spindles is:

- A. A-alpha
- B. A-beta
- C. A-delta
- \*D. 1-a
- E. 2

Postnatal development of BBB?

- 1) astrocyte
- 2) pericyte
- 3) astrocyte + pericyte\*
- 4) microglial

palisading necrosis

ناسيه صيغة السؤال

GBM \*

Meningioma

cryptococcal neoformans

gram neg

csf culture on sabouraud dex agar show mucoid colonies\*

urease neg

csf examination by using india ink , treat by antibiotic

(في ingestion spores)

limbic system جزء مو من ال

cerebellum

drug of choice to treat absence seizures

ethosuximide

All the following are true except

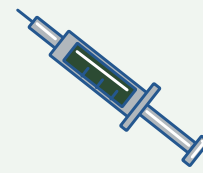
- A- csf produced from 3rd , 4th ventricle and subarchinoid space \*
- B- csf go to blood through villi

All the following related 3rd ventricle except

- A- tegmentum \*
- B- posterior commissure

All the following are true about hypothalamus except:

- A- have vertical part
- B- its horizontal part form the floor of the lateral ventricle
- C- subthalamus sulcus between it and thalamus\*



الطبيب والجراحة

White matter that connects uncus with anterior perforated substance

- A- corpus callosum
- B- anterior perforated substance
- C- cingulum \*
- D- uncinat fasciculus

Cortex of vermis influence on

- A- coordination of movement of upper limbs
- B- coordination of movement of long axis \*
- C- concus assessment of movement error
- D- planning sequential movement

Third layer of superior colliculus:

- A) stratum zonale
  - B) stratum griseum superficial
  - C) stratum opticum\*
  - D) stratum griseum mediate
- About holocencephaly

A- failure of forbrain to devided to 2 cerebral hemisphere

One of following present ni the anterior horn of thoracic segment:

- A) central group
- B) anterior medial group\*
- C) antero-latera
- D) postero-lateral

Axons of the largest pyramidal cells supplying the digits arise from:

- A) betz cells\*

One of the following true about lumber segment:

- A) central canal anterior
- posterior horn thin and divarging
- C) gray matter abundant compared to white matter \*
- D) don't have lateral horn

Patient with schz take clozipan what the adverse effect should be in caution

- A- agranulocytosis \*
- B- extrapyremidal symptoms

One of these drug is MAOB inhibitors

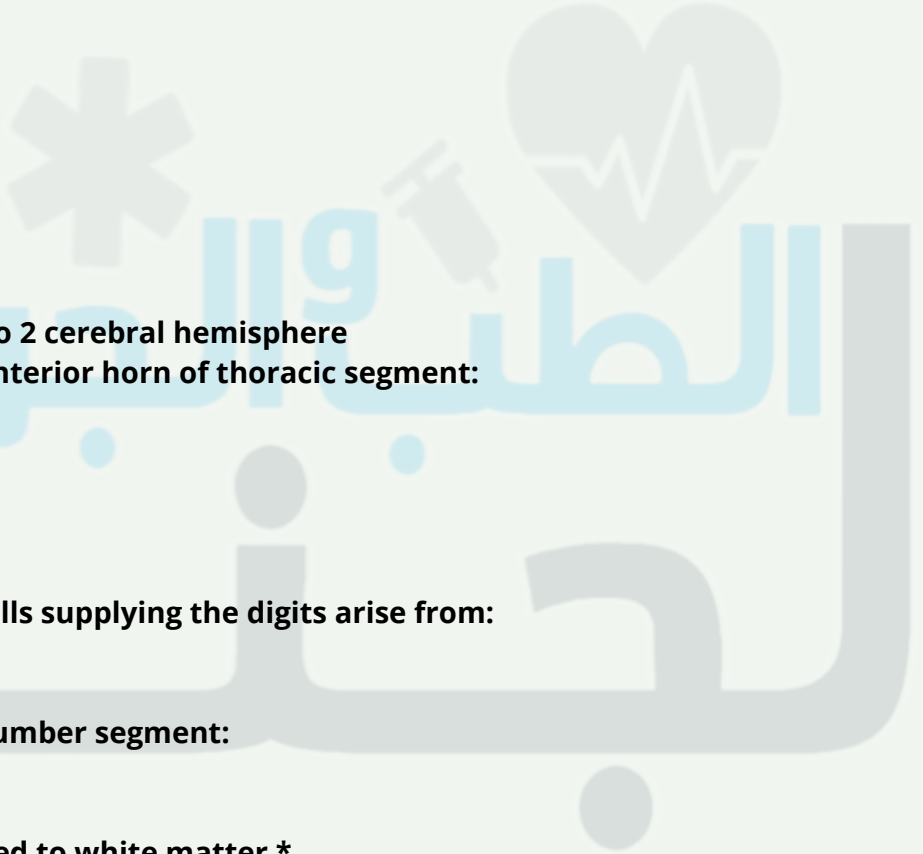
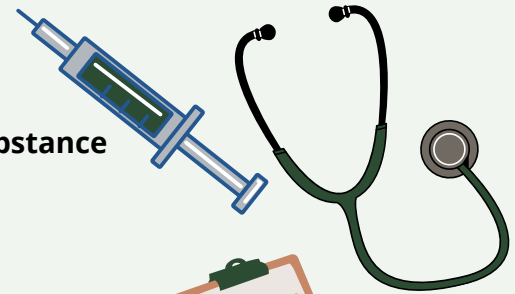
- A- selligline \*
- B- L-dopa

One of the following is false

- A- amantidine increases release of dopamine and reabtake \*

Choose the uncorect answer:

- A- beneserizide cross BBB \*



One of the following cells present in a purkinje layer:

- A) Candelabrum cells\*
- B) Unipolar Brush cells
- C) Stellate cells

One of the following is not generated from neural crest ?

- a) aorticopulmonary septum
- B)otic ganglia
- c) Odontoblasts
- d) dura matter\*

What is CORRECT related to Martinotti Cell?

- a) They have very short many dendrites
- b) large spindle neurons present mainly in deepest layers
- c) their axons extend towards the surface and bifurcate to forming synapse with pyramidal\*
- d) they send excitatory signals

(Case) patient fall and suffer from lower back pain ,in examination revealed that L3 nerve is damaged when exits from ?

- a) Pedicles between L3 -L4 vertebrae \*
- b) laminae between L2 -L3 vertebrae
- c) Pedicles between L2 -L3 vertebrae
- d) laminae between L3 -L4 vertebrae

One of the following is SNRI drug?

- a) Sertraline
- b) Paroxetine
- c) venlafaxine\*
- d) Citalopram
- e) imipramine

Which of the following drugs is Monoamine Oxidase Inhibitors?

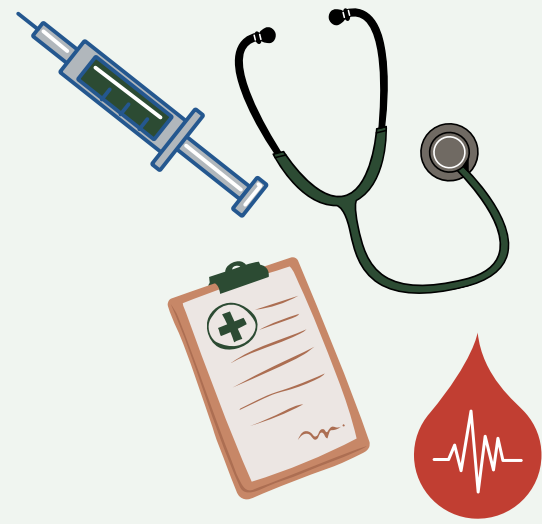- a) Citalopram
- b)selegiline\*
- c) Amitriptyline
- d) Doxepin

Which artery run in callosal sulcus?

- a)ACA \*
- b)MCA
- c) PCA
- d) Internal Cerebral Artery

One of the following dose not share in circle of Willis ?

- a) Posterior cerebral Artery
- b) middle cerebral artery \*
- c) Anterior communicating Artery
- d) Anterior cerebral Artery
- e) internal carotid artery



الطبيب والخبيرة  
بجنتة

Tumor in Vestibulooclear nerve which cranial nerve of the following will be affected ?

- a) Hypoglossal
- b) Vagus
- c) Abducens
- d) facial\*
- e) Occulo-motor

7 years old child has ADHD which of the following is the drug of choice ?

- a) Morphine
- b) Amphetamine
- c) Atomoxetine
- d) Methylphenidate\*

Patient is examined by CT which reveals no Subarachnoid hemorrhage what the next test should be done to confirm the diagnosis?

- a) MRI
- b) lumbar puncture to test CSF\*
- c) PCR
- d) biopsy

One of the following is norepinephrine & serotonin reuptake inhibitors

- A- citalopram
- B- venlafaxin \*
- C- fluvoxamine
- D- sertraline

Epidural hemorrhage appear in MRI as

- A- semilunar hypercondense
- B- semilunar hypocondense
- C- biconcave hypercondense
- D- biconvex hypocondense\*

You had an exam and had diarrhea go to pharmacy and ask for opioid overcounter what is it

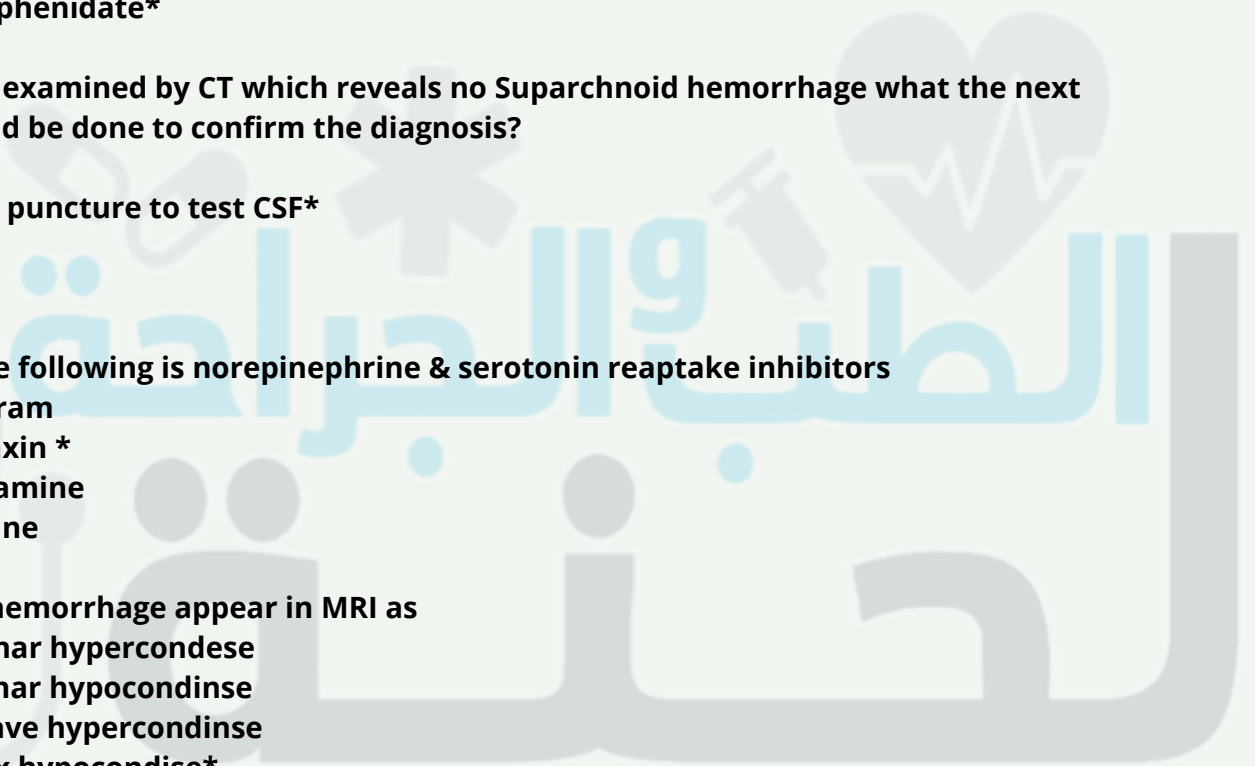
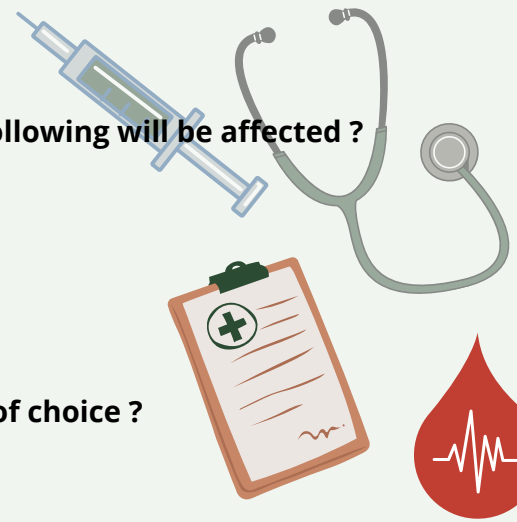
- A- loperamide \*
- B- alvimopan

All the following results from lesion in Kluver-Bucy syndrome except

- A- nystagmus \*
- B- tameness
- C- loss of fear reaction
- D- tendency to examine everything orally
- E- placidity

The pia mater separated from the neural tissue by:

- A) astrocytic processes\*



One of the following is true

- A- catecholamine drug increase RAS activity \*
- B- corticofugal decrease RAS activity
- C- sensory signal decrease RAS activity
- D- stimulation of sleep center increase RAS activity

True about fine touch

- A- stereognosis by giving familiar object \*
- B- tactile localization by 2 touch applied simultaneously

One of the following true regarding neurotransmitters

- A- gaba is inhibitory \*

The most sensitive neuron to transient global ischemia

- A- cerebellar pyrkinji cell

Watershed infarct result from

- A- hypertension
- B- hypotensive episode \*

Woman with headache, a mass beneath dura matter you take sample from meninges, what you will found?

- A- psammoma body

Wrong about ataxia:

- A) Dysmetria
- B ) Dys-diadokokinesia
- C) Nystagmus
- D) static tremor\*
- E) Zigzag gait

All of the following found in premotor area 6 ,except:

- A) Broca's area
- B ) Head rotation area
- C) Hand skilled area
- D) Exner's area 45
- E) Area 8 (frontal eye field)\*

Which nucleus of the following responsible for proprioceptive sensation in the head?

- a) mesencephalic nucleus\*
- b) Vegus nucleus
- c) vestibular nucleus
- d) spinal nucleus of Trigeminal
- e) solitary nucleus

واكيد كانت بدھا الصح theories of sleep السؤال بس كان عن ال

- A) Active theory seems to be the real mechanism of sleep.\*
- B) Passive theory seems to be the real mechanism of sleep
- C) metabolic theory nhibition of the RAS by fatigue
- D)passive theory means inhibition of the RAS by signals discharged from certain centers.







اللهم اهدنا فيمن هديت، وعافنا فيمن عافيت، وتولنا فيمن توليت، وبارك لنا فيما أعطيت، وقنا واصرف عنا برحمتك شر ما قضيت، إنك تقضي ولا يقضى عليك، إنه لا يذلُّ من واليت، ولا يعزُّ من عاديت، تباركت ربنا وتعاليت، لك الحمد على ما قضيت، ولك الشكر على ما أعطيت، نستغفرك اللهم من جميع الذنوب والخطايا ونتوب إليك، لا ملجأ ولا منجى منك إلا إليك.

**وتظل تسعى جاهداً في همةٍ  
والله يعطي من يشاء إذا شكر**