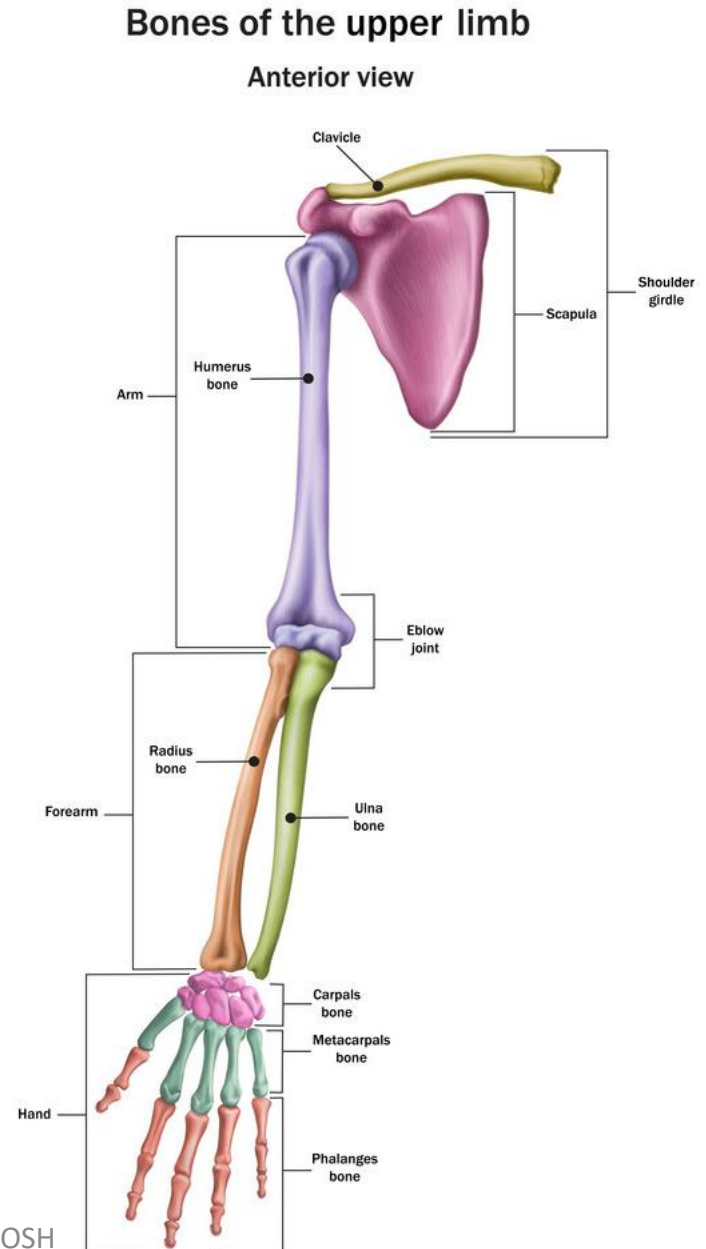


# Upper limb Lecture one

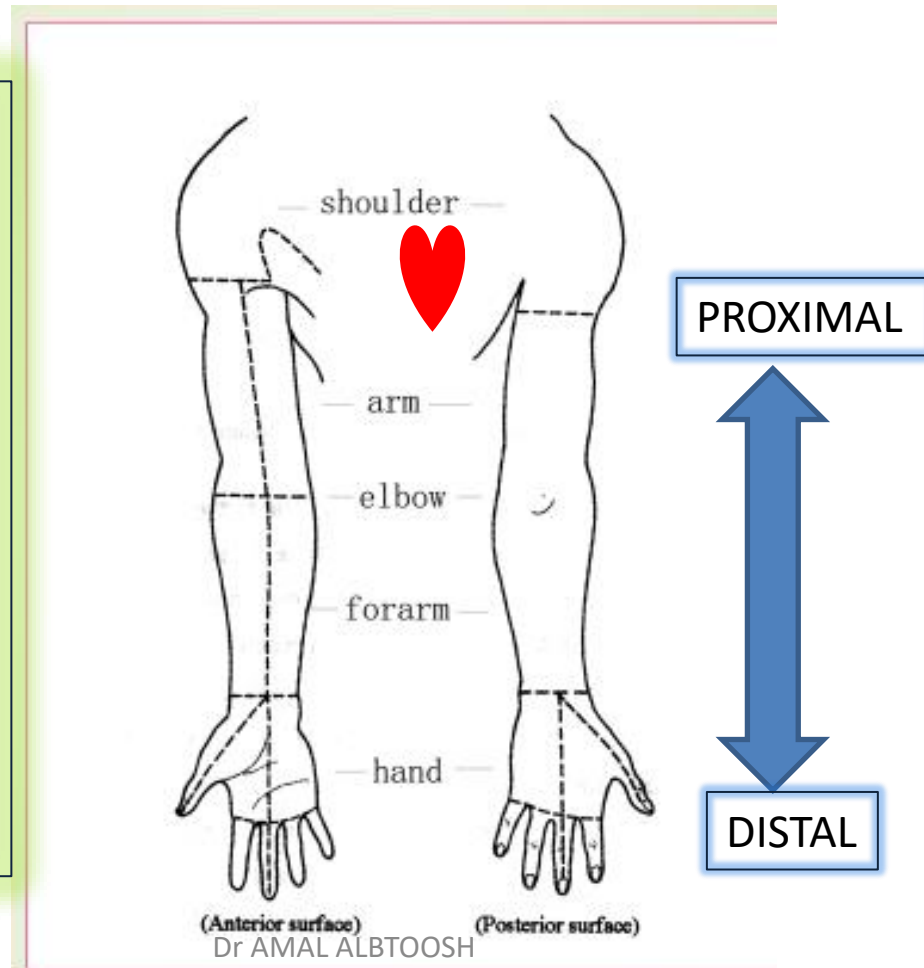
Dr Amal  
Albtoosh



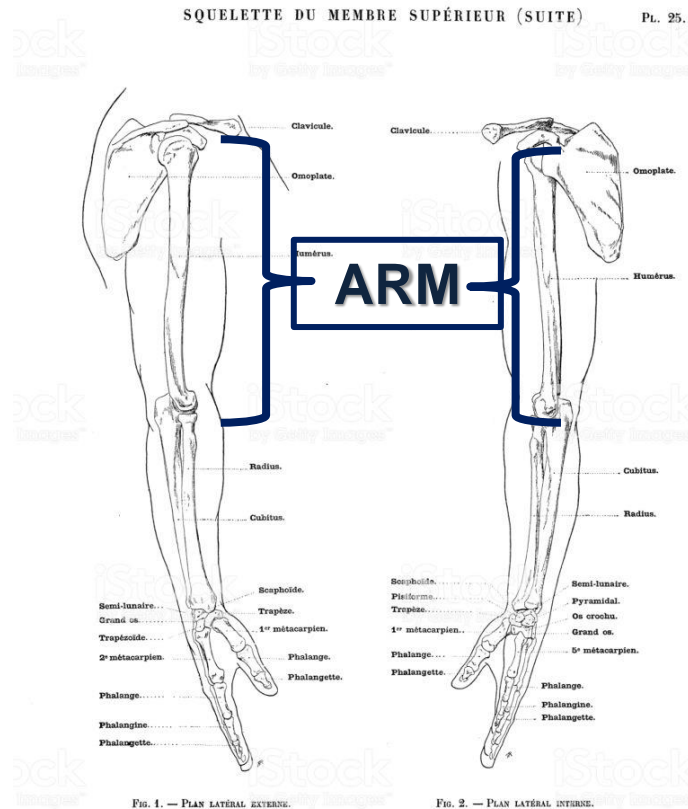
# What is the limb?

- Limb: a leg or arm of a human being

The upper limb is a multijointed lever that is freely movable on the trunk at the shoulder joint. At the distal end of the upper limb is the important organ, the hand.



# WHAT IS ARM?



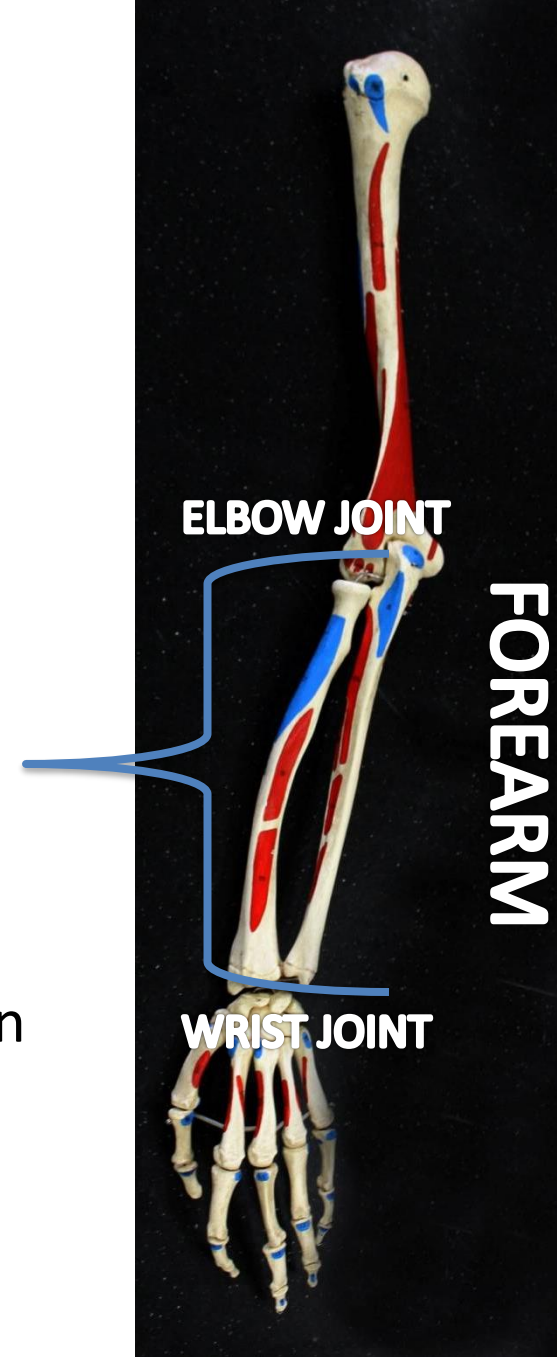
The word “**ARM**” in anatomy is restricted to the area between the shoulder and elbow joints.

The **ARM (BRACHIUM)** consists of the humerus, which articulates distally with the **FOREARM (ANTEBRACHIUM)** through the elbow complex.

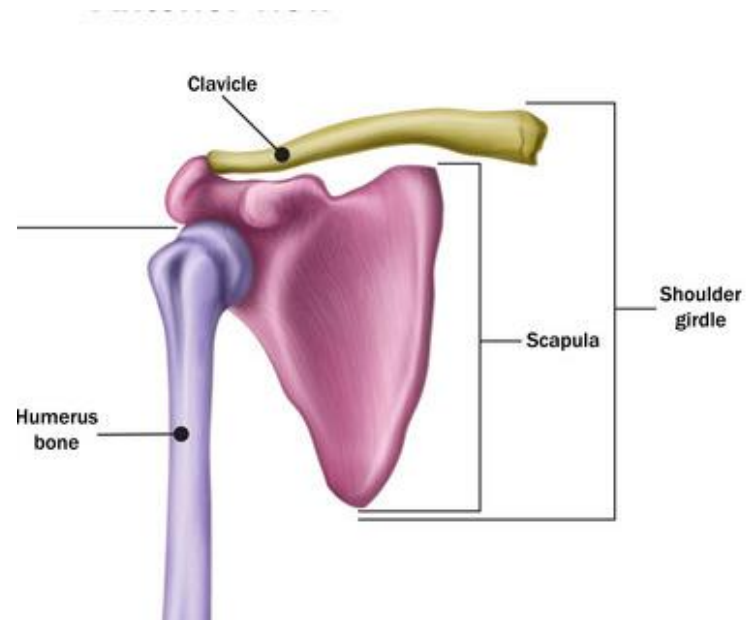
# THE FOREARM

## The forearm (antebrachium) :

- ❖ consists of TWO BONES: the radius and ulna.
- ❖ **Proximally**, the forearm articulates with the humerus through the **elbow complex** (humeroulnar and humeroradial joints).
- ❖ **Distally**, the forearm articulates with the carpal bones through **the wrist complex**, enabling a wide array of actions.
- ❖ The muscles of the forearm that act upon the elbow, wrist complex, and the digital joints

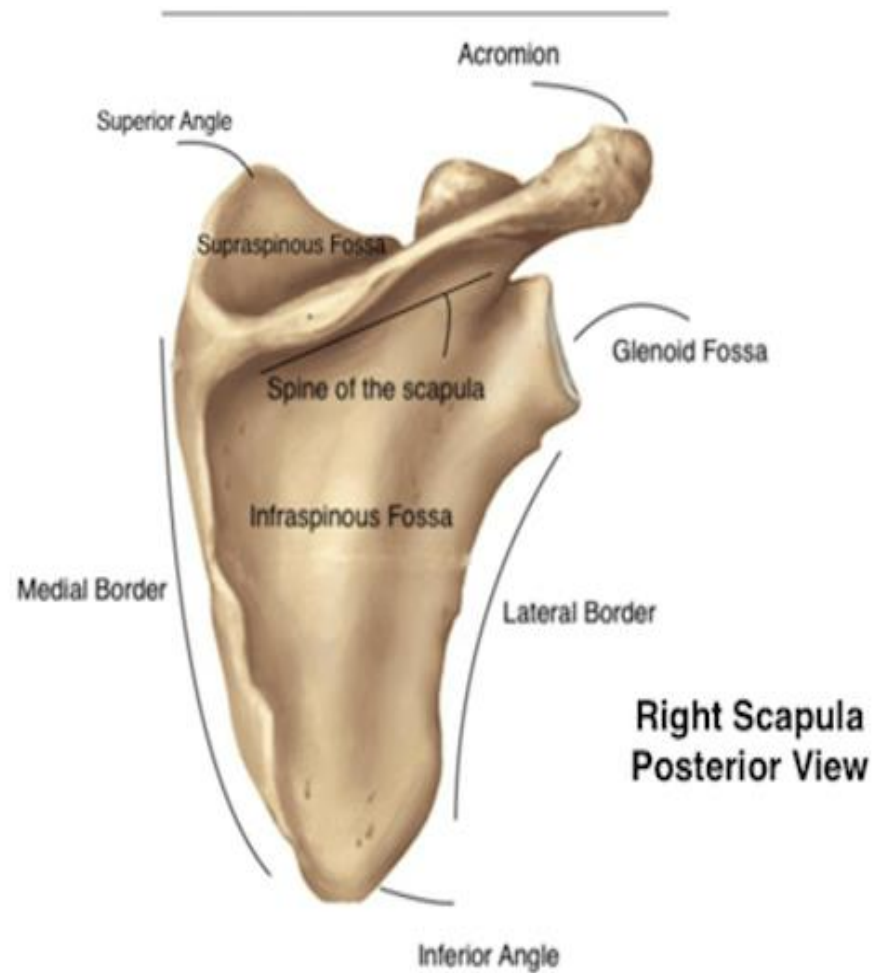


# SHOULDER GIRDLE bones



## Scapula:

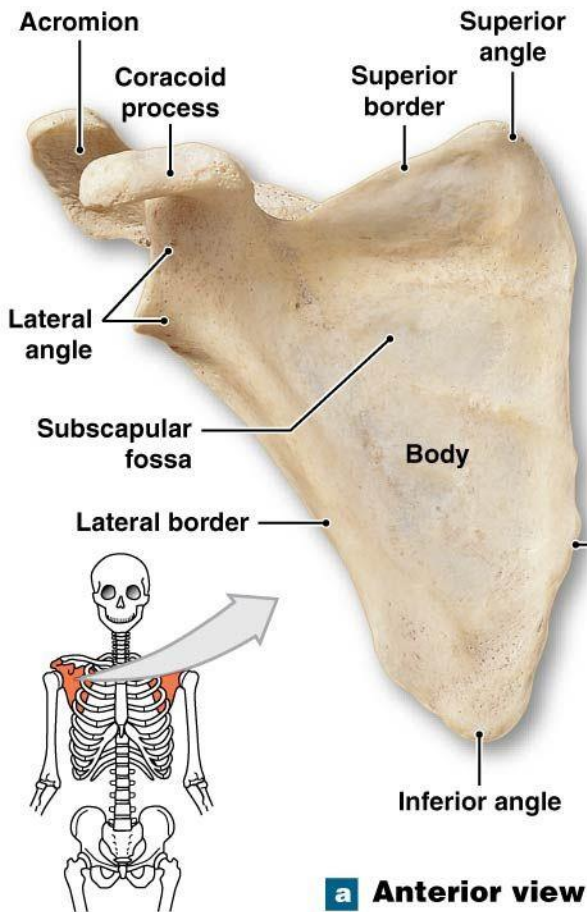
- flat bone
- inverted triangle
- 3 borders
  - ✓ Superior border
  - ✓ medial border
  - ✓ lateral border



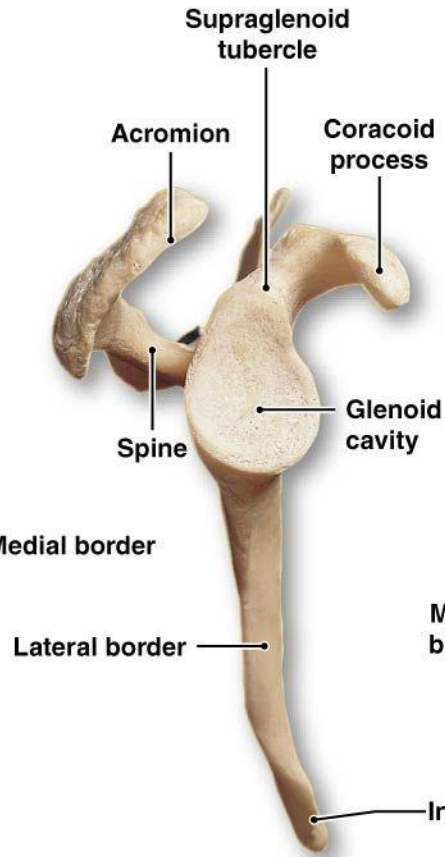
□ 2 surfaces

✓ anterior

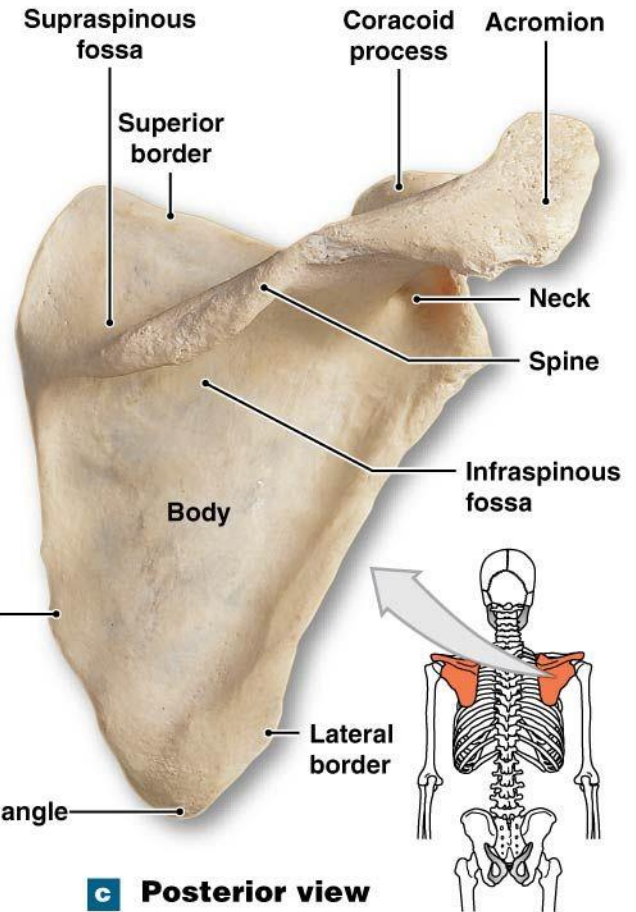
✓ posterior



**a Anterior view**

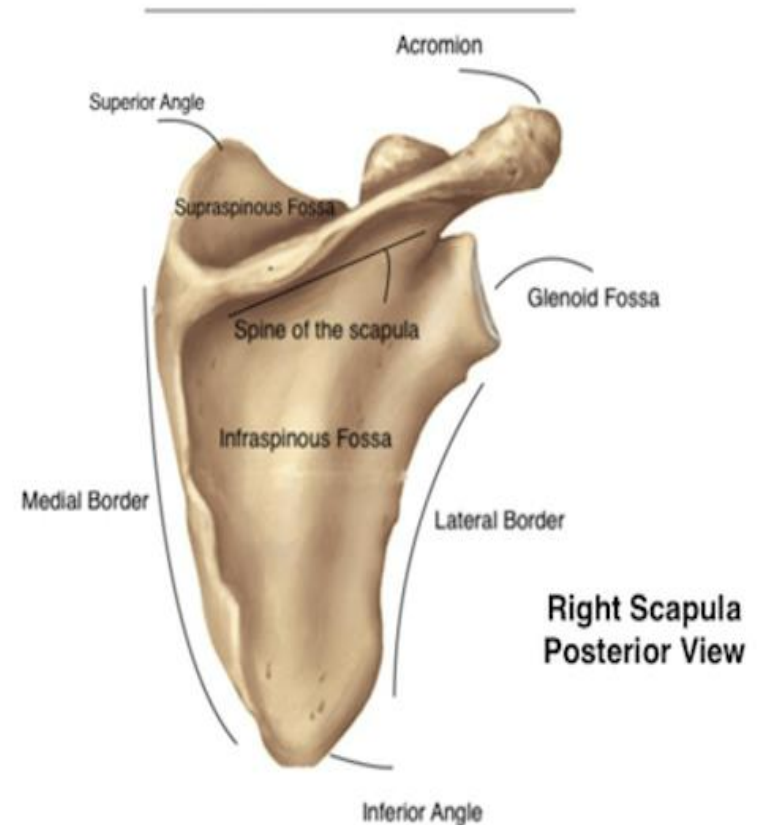


**b Lateral view**



**c Posterior view**

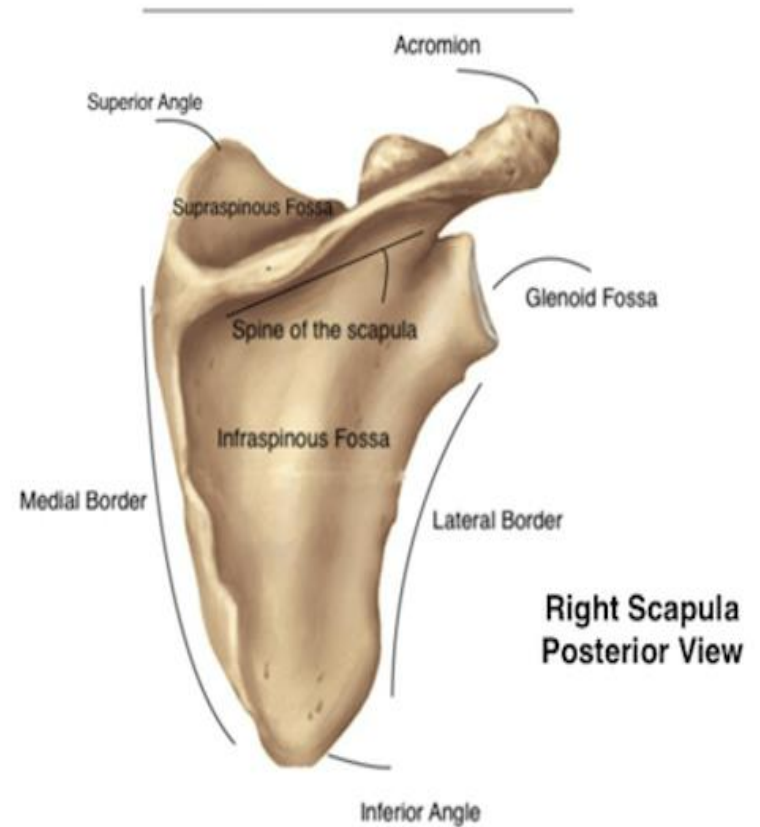
- 3 angles
- ✓ Superiomedial angle
- ✓ Superiolateral angle
- ✓ Inferior angle



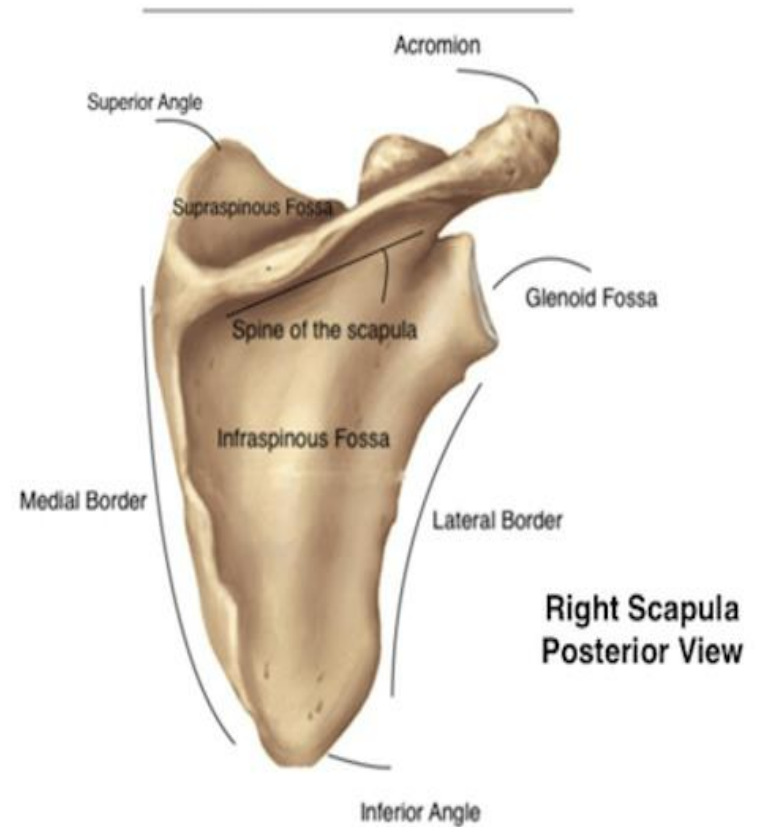


☐ 3 Fossae

- ✓ supraspinous fossa
- ✓ infraspinous fossa
- ✓ Subscapular fossa



- ☐ 3 processes
- ✓ spine
- ✓ Acromion
- ✓ coracoid



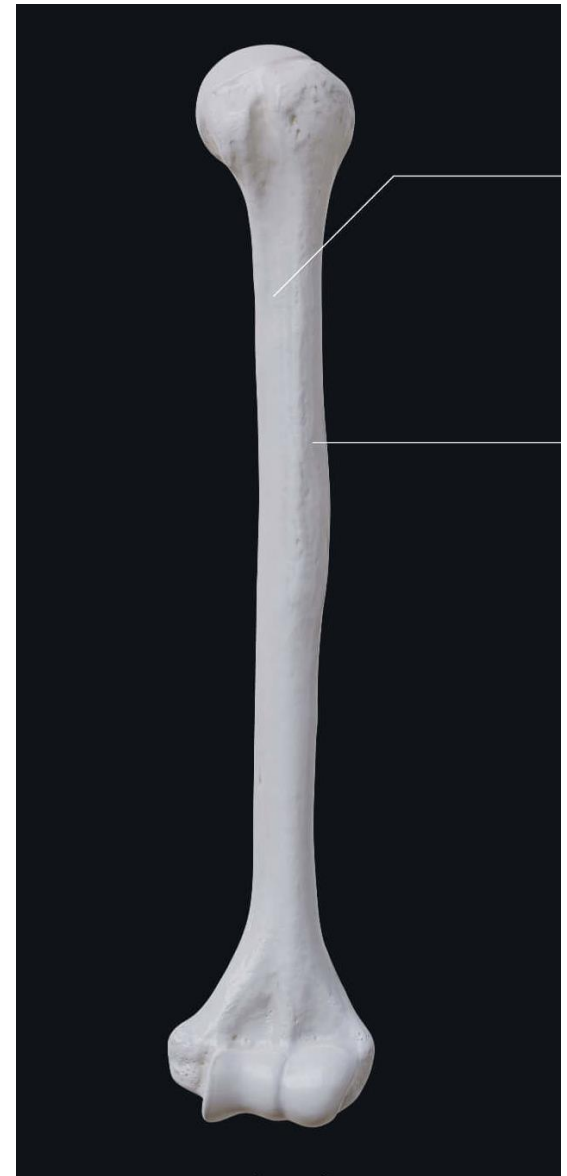# Clavicle

- ❑ The clavicle is the only long bone that lies in a horizontal position in the body
- ❑ The clavicle has three regions:
  - ✓ The medial end: **sternal end of the clavicle**
  - ✓ The lateral end: **acromial end of the clavicle**
  - ✓ The shaft: acts as a point of attachment for several muscles



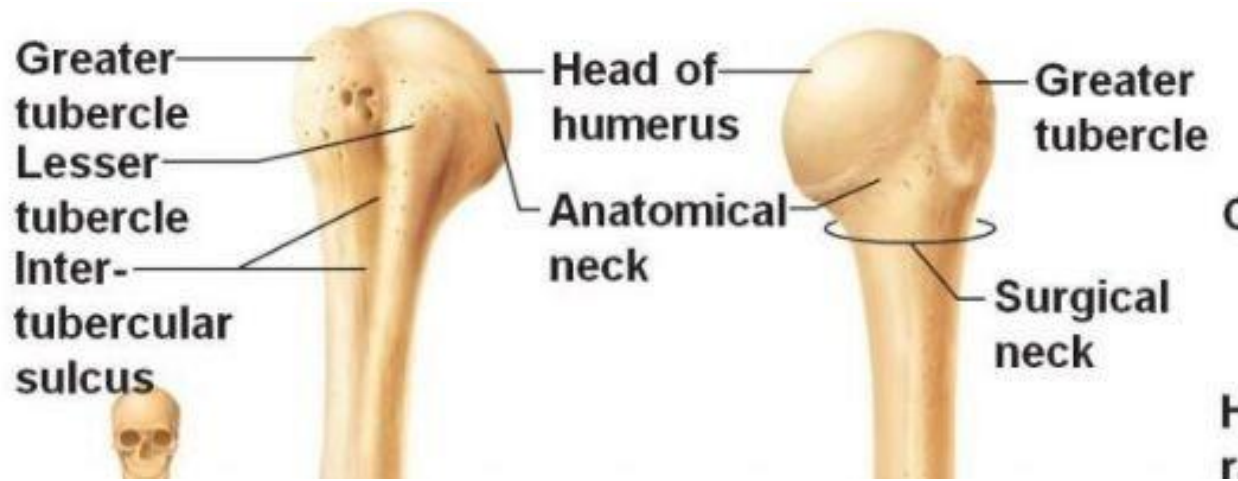
Clavicle

The **humerus** is the longest bone of the arm and is characterized by many distinct features that help to allow the upper extremity to move through a significant range of motion



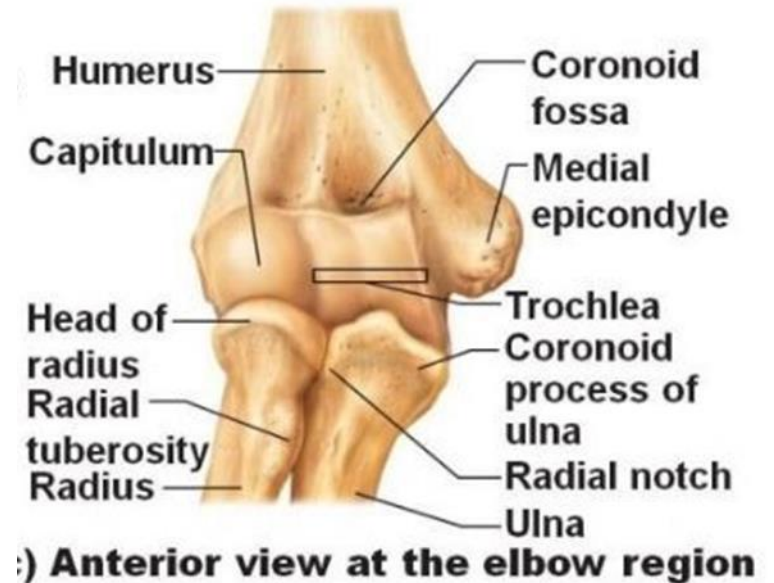- ❖ The following **landmarks** are found on the humerus:
- ❖ **Head.** A ball-shaped structure that articulates with the glenoid cavity.
- **Anatomical neck.** Formed by a narrow constriction immediately distal to the head of the humerus.
- **Surgical neck.** Lies distal to the anatomical neck and tubercles of the humerus.

The axillary nerve and the posterior humeral circumflex artery course into the posterior compartment of the arm, deep to the surgical neck.



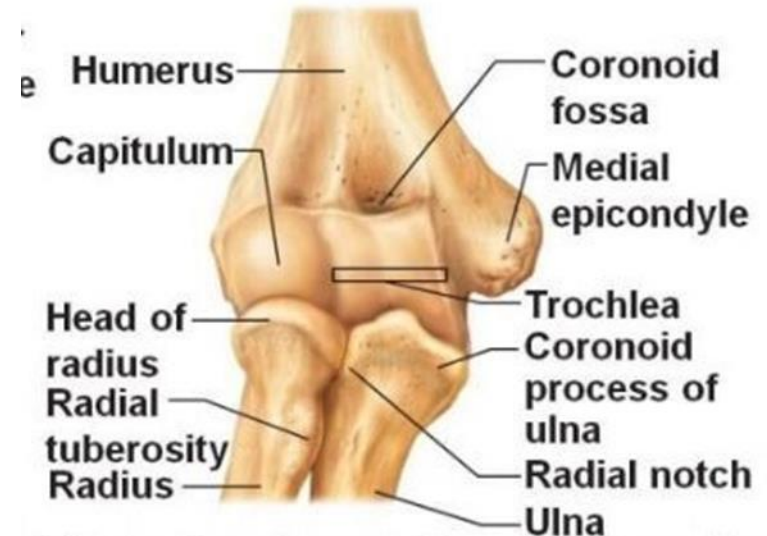
# HUMERUS

- **Medial epicondyle.** Located on the distal medial end of the humerus and provides an attachment surface for the anterior forearm muscles (flexors).
- **Trochlea.** Characterized by a pulley shape; it helps to guide the hinge joint. The trochlea of the humerus articulates with the trochlear notch of the ulna.

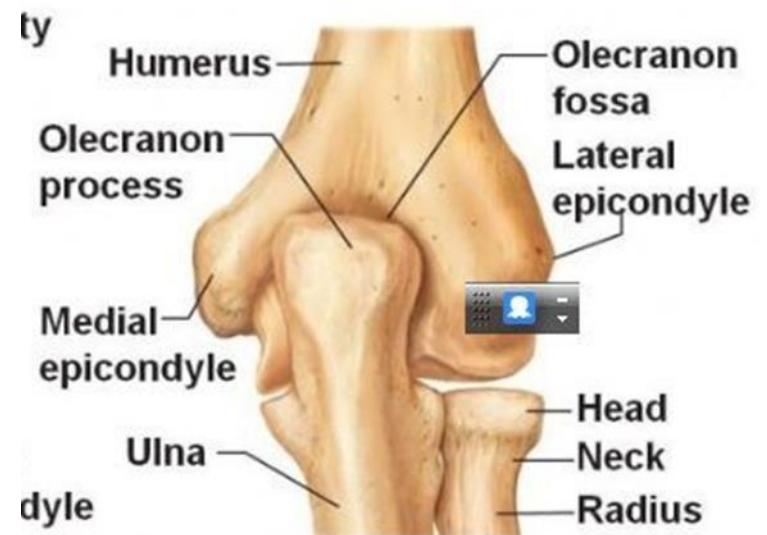

# HUMERUS

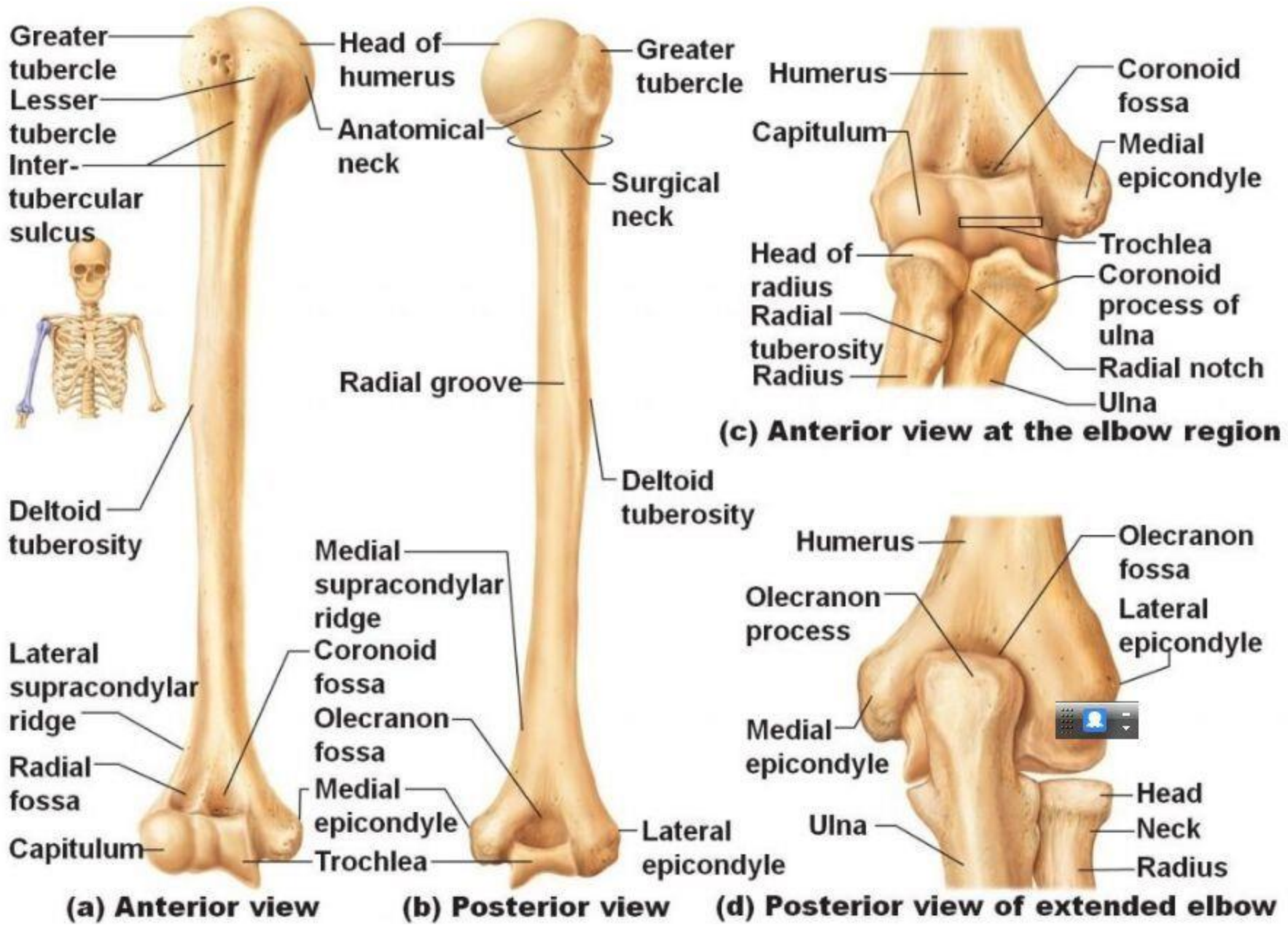
- Capitulum. Characterized by its oval, convex shape for articulation with the radial head.
- Coronoid fossa. Located on the distal anterior surface of the humerus, where the coronoid process of the ulna articulates.
- Olecranon fossa. Located on the distal posterior surface of the humerus, where the olecranon process of the ulna articulates.



**c) Anterior view at the elbow region**



**d) Posterior view of extended elbow**



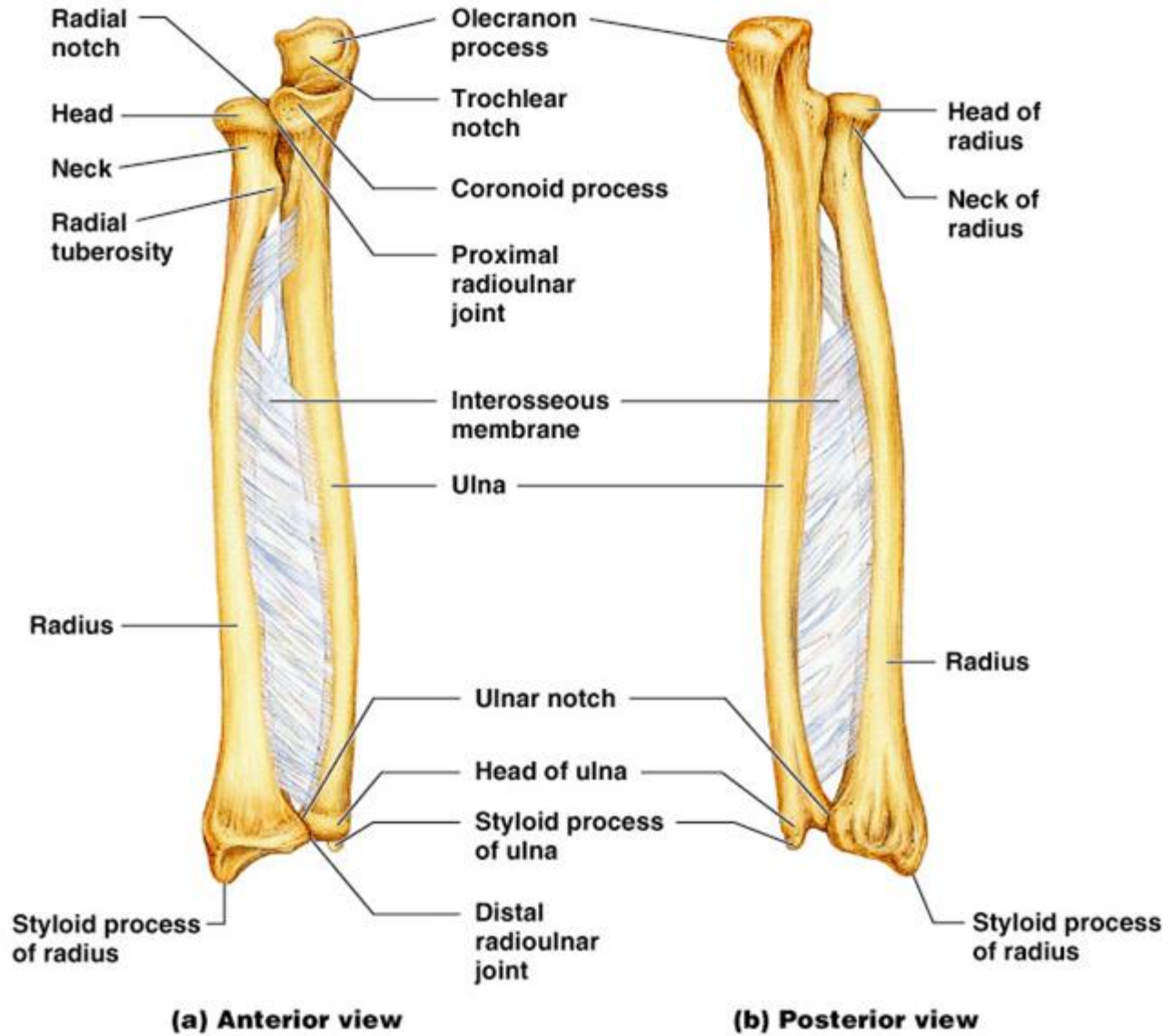
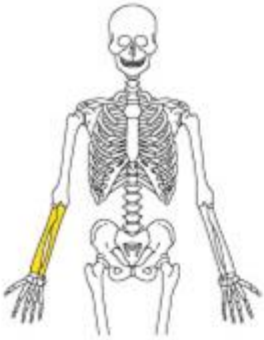
**(a) Anterior view**

**(b) Posterior view**

**(c) Anterior view at the elbow region**

**(d) Posterior view of extended elbow**



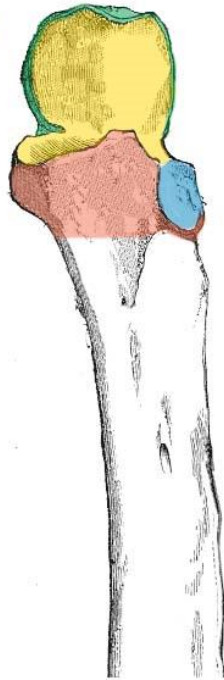


Copyright © 2004 Pearson Education, Inc., publishing as Benjamin Cummings.

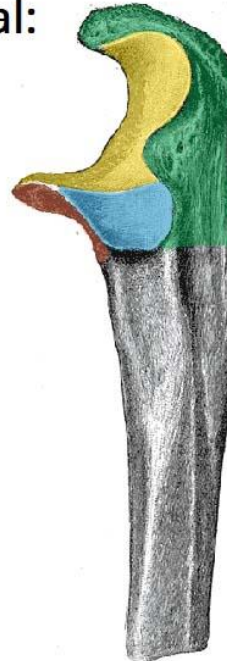# ULNA FEATURES

- ❖ Long Bone
- ❖ looks like a wrench مفتاح انجليزي
- ❖ It lies medially and **parallel** to the radius
- ❖ **The proximal end**
  - ✓ Olecranon
  - ✓ Coronoid process
  - ✓ Trochlear notch
  - ✓ Radial notch Tuberosity of ulna

Anterior:



Lateral:



- Olecranon
- Coronoid Process
- Trochlear Notch
- Radial Notch



## Shaft of the Ulna

❖ As it moves distally, it decreases in width.

❖ HAS THREE SURFACES:

**Anterior**

**Posterior**

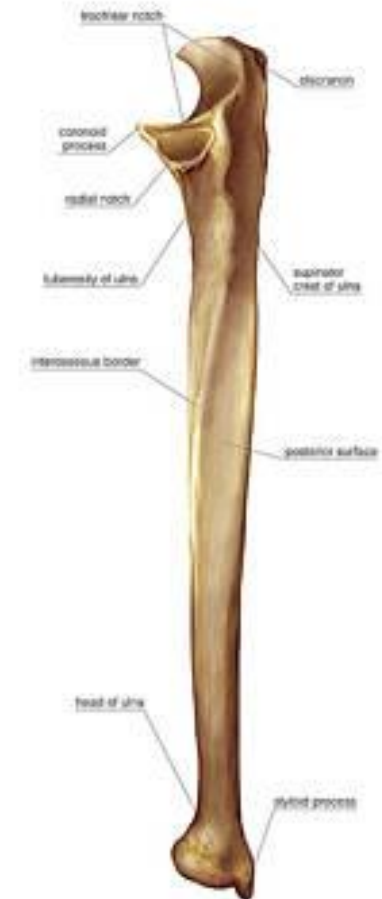
**Medial**

❖ HAS THREE BORDERS:

**Posterior** – palpable along the entire length of the forearm posteriorly

**Interosseous**

**Anterior**



## Distal end

❖ The distal end of the ulna is much smaller in diameter than the proximal end.

❖ It is mostly unremarkable, terminating in

✓ rounded **HEAD**,

✓ the ulnar **styloid process**.

## The radius

- ❖ Long bone
- ❖ It lies laterally and parallel to ulna.

### Proximal end of the Radius

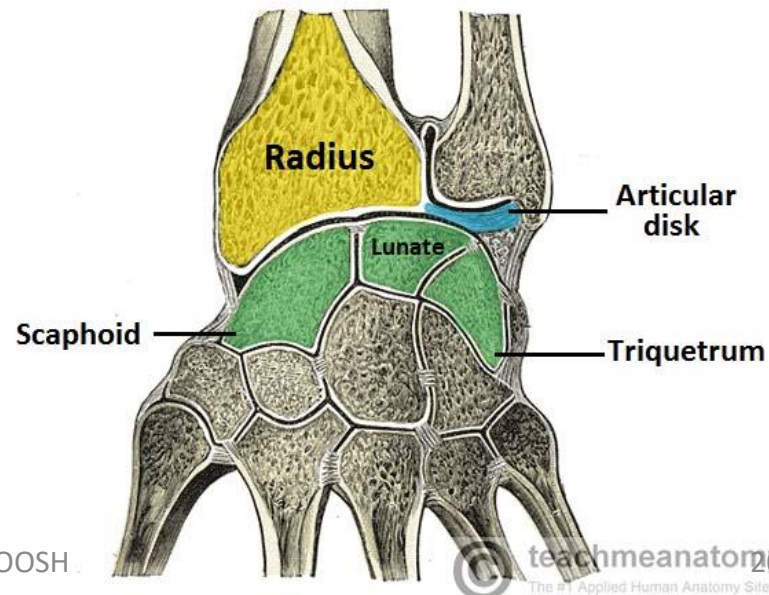
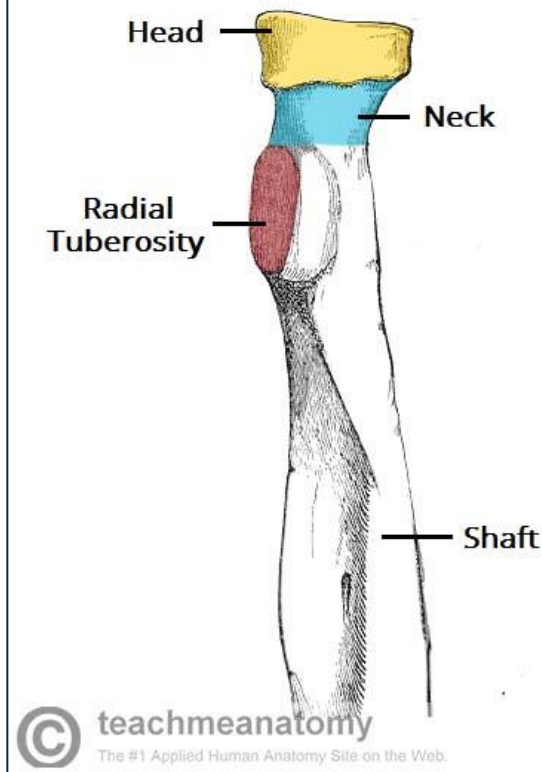
- ✓ head,
- ✓ neck
- ✓ **radial tuberosity** (bicipital tuberosity)

### Shaft of the Radius

- ❖ The radial shaft **EXPANDS** in diameter as it moves distally.
- ❖ Much like the ulna, it has three borders and three surfaces.

### The Distal End

- ❖ The lateral side projects distally as the **styloid process**.
- ❖ **ulnar notch**
- ❖ The distal surface of the radius has two facets, for articulation with the **scaphoid** and **lunate** carpal bones. This makes up the **wrist joint**.



# The Bony Structure of The Hand

## ❖ 8 carpal bones

*Proximal row:*

Scaphoid

Lunate

Triquetrum

Pisiform

*Distal row:*

Trapezium

Trapezoid

Capitate

Hamate

## ❖ 5 Metacarpals

## ❖ 14 phalanges

