

Cartilage

Quit

Cartilage

- A **strong firm** and **pliable** CT composed of cells that called **chondrocytes** and highly specialized **extracellular matrix** (ECM)
- An **Avascular** tissue → Cartilage is a tissue of very **low metabolic activity** and **cell turnover**
- Cartilage receives its nutrients from blood vessels from a surrounding dense connective tissue, the **perichondrium**
- Nerves are **not** present in cartilage, but nerves and nerve ending are present in the **perichondrium**
- Contain large amount of **glycosaminoglycans** and water to permit **diffusion** of substances
- About **70% wt water** for diffusion, binding and resilience

- There are 3 types:
 - **Hyaline cartilage**
 - **Elastic cartilage**
 - **Fibrocartilage**

The difference between the different cartilage types depend on the different properties of the **extracellular matrix**, and in particular on the amount and type of the **fibres** embedded in the matrix



Main menu

Slide menu



Quit

Hyaline cartilage

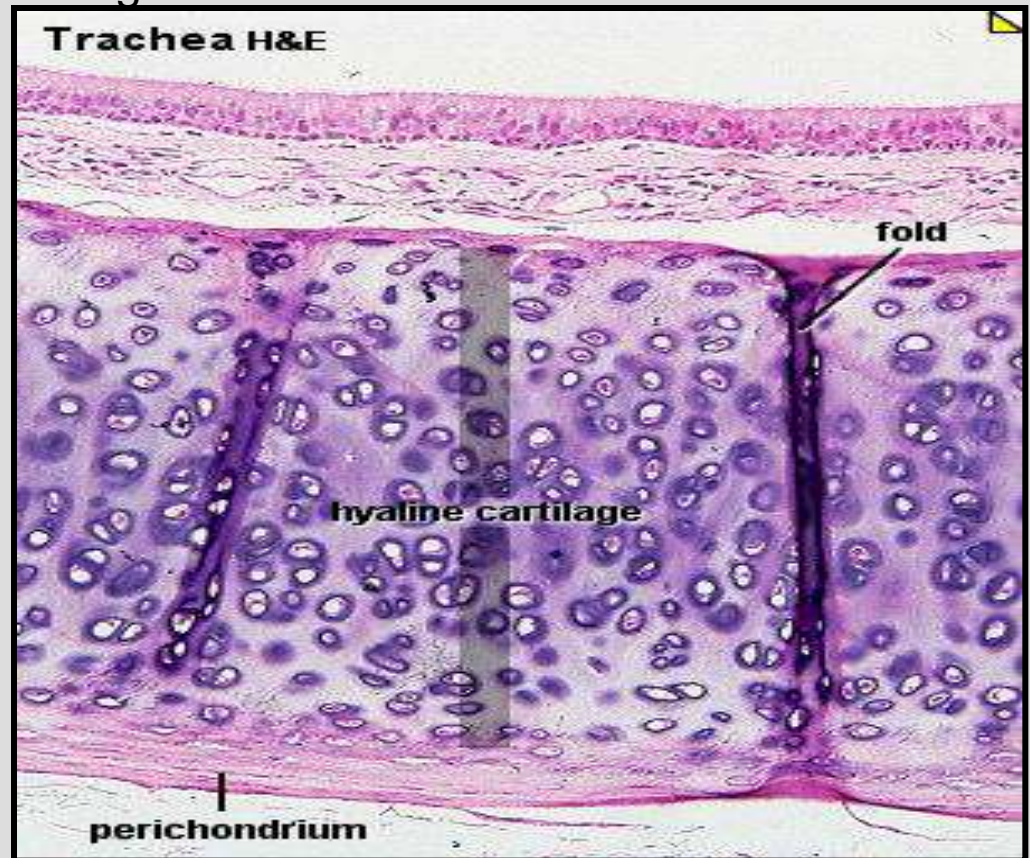
- From Greek *hyalos* means glassy, semi-transparent (**translucent**), that is both **flexible** and **resilient** to mechanical forces
- Homogeneous amorphous matrix
- Bluish-white and translucent
- The most widely distributed type of cartilage

Found:

- Rib cartilage (costal cartilage)
- articulating surfaces
- nose
- larynx
- Trachea, bronchi
- embryonic skeleton

The cartilage consists of

1. **Cells**
2. **ECM**
 - a. fibres
 - b. ground substance



1. Cells

Chondrogenic cells

- # small spindle-shaped cells derived from mesenchymal cells
- # present in the inner cellular layer of the perichondrium
- # undergo division and differentiation to form chondroblasts and in some occasions to osteoprogenitor cells

Chondroblasts

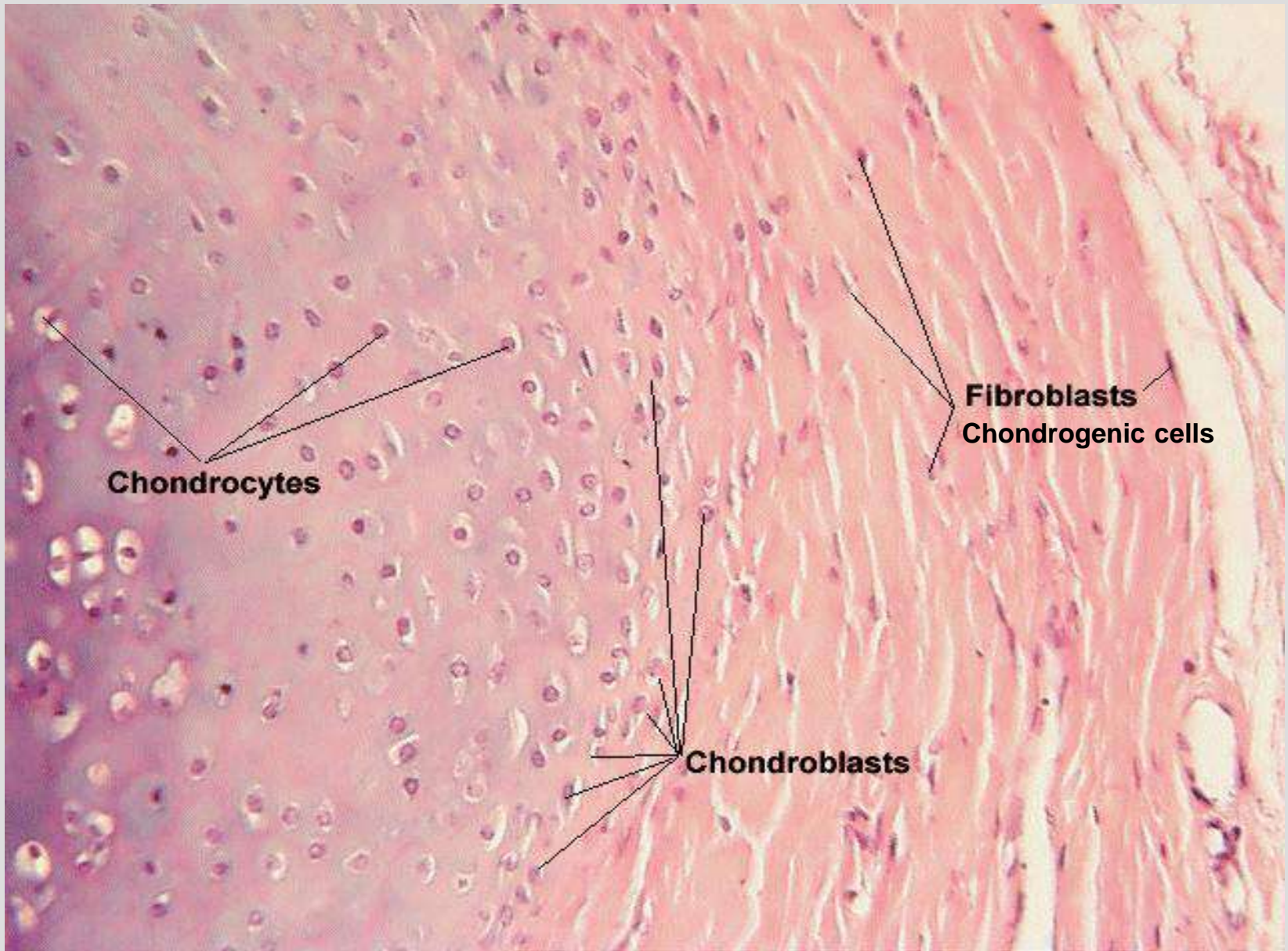
- # differentiated from the chondrogenic cell of the perichondrium
- # Oval or spindle in shape with basophilic cytoplasm (protein synthesis)
- # High rER, Golgi apparatus and mitochondria
- # provide collagen and proteins
- # change to chondrocytes

Chondrocytes

- # surrounded by lacuna (small chambers) within the matrix, usually 1-3 sometimes more
- # round in shape with basophilic cytoplasm
- # young chondrocytes are active in protein synthesis but older chondrocytes become less active
- # numerous rER, large Golgi and secretory granules

2. Fibres

- **Collagen** fibres mainly **type II**
- Elastic fibres



Chondrocytes

Chondroblasts

Fibroblasts
Chondrogenic cells

3. Matrix

The main components of hyaline cartilage (wet weight) are approximately:

1- Water 70-75%

2- Fibres **Collagen (type II) 16%**

3- Ground substance **10% -Proteoglycans
-glycosaminoglycans**

4- Other glycoproteins 1.6%

5- Minerals 0.5%

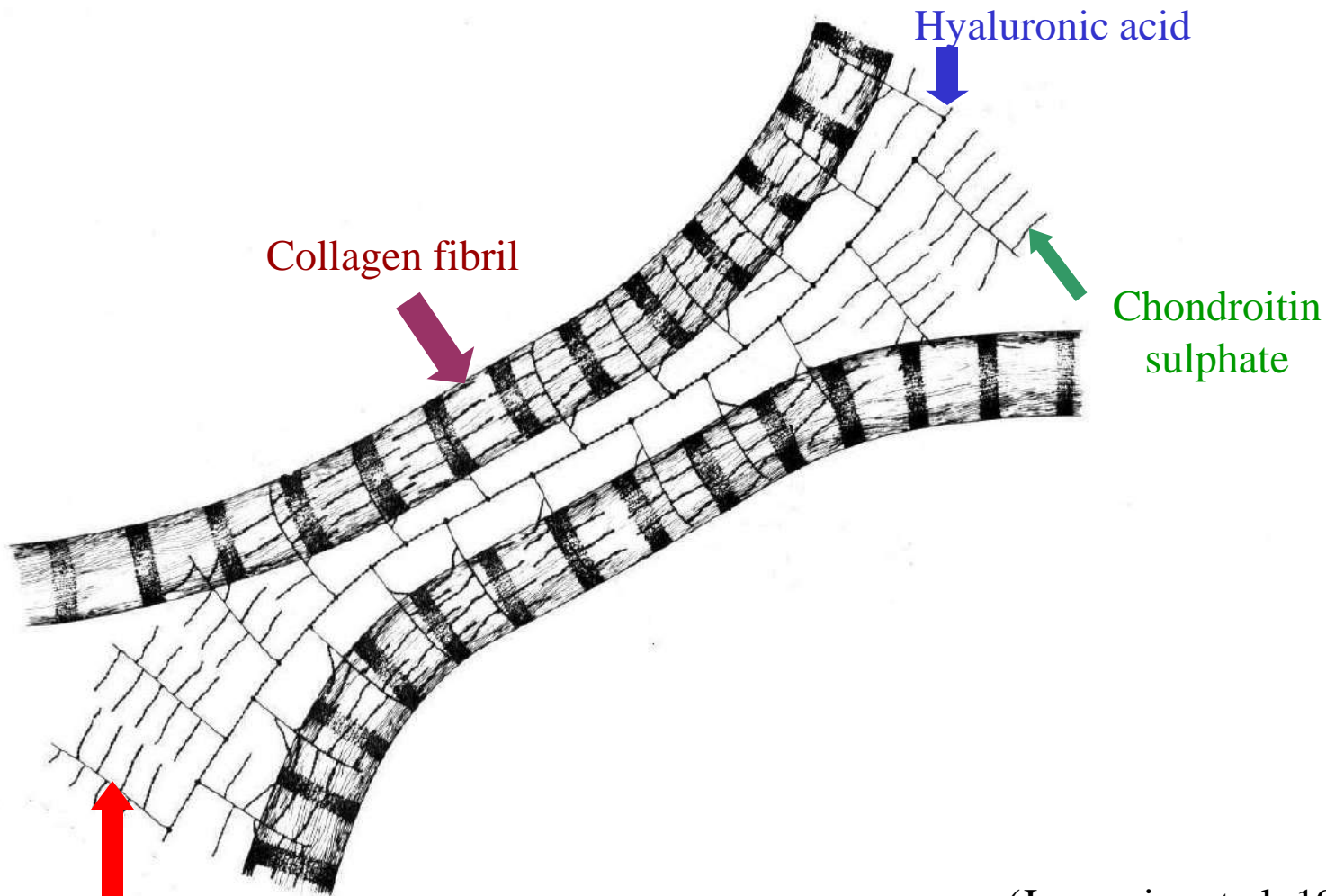
Proteoglycans Aggr

Sulphated glycosaminoglycans (composed of **chondroitin sulphate** and **keratan sulphate**)

Non-sulphated glycosaminoglycans (**Hyaluronic acid**)

In cartilage the protein core of the proteoglycan molecule binds through a linking protein to hyaluronic acid to form a proteoglycan aggregate which binds to the fibres by electrostatic inter action to resist compression


- The highest concentration of proteoglycan around the chondrocyte lacunae (intense stain) called **territorial matrix**
- Low concentration far from cells **interterritorial matrix**



(Junqueira et al, 1986).

Protein core (**Proteoglycans**)

In this drawing one can see 2 collagen fibrils (↓) that are linked by thread like structures in the matrix of the cartilage. In the center between the 2 collagen fibrils runs a hyaluronic acid (↓) chain. Perpendicular from this chain, proteoglycans (↑) stretch towards the fibrils. Chondroitin sulphate (↑) side chains stretch out perpendicular from the proteoglycans and bind to the collagen fibrils.




Main menu

Slide menu



Quit

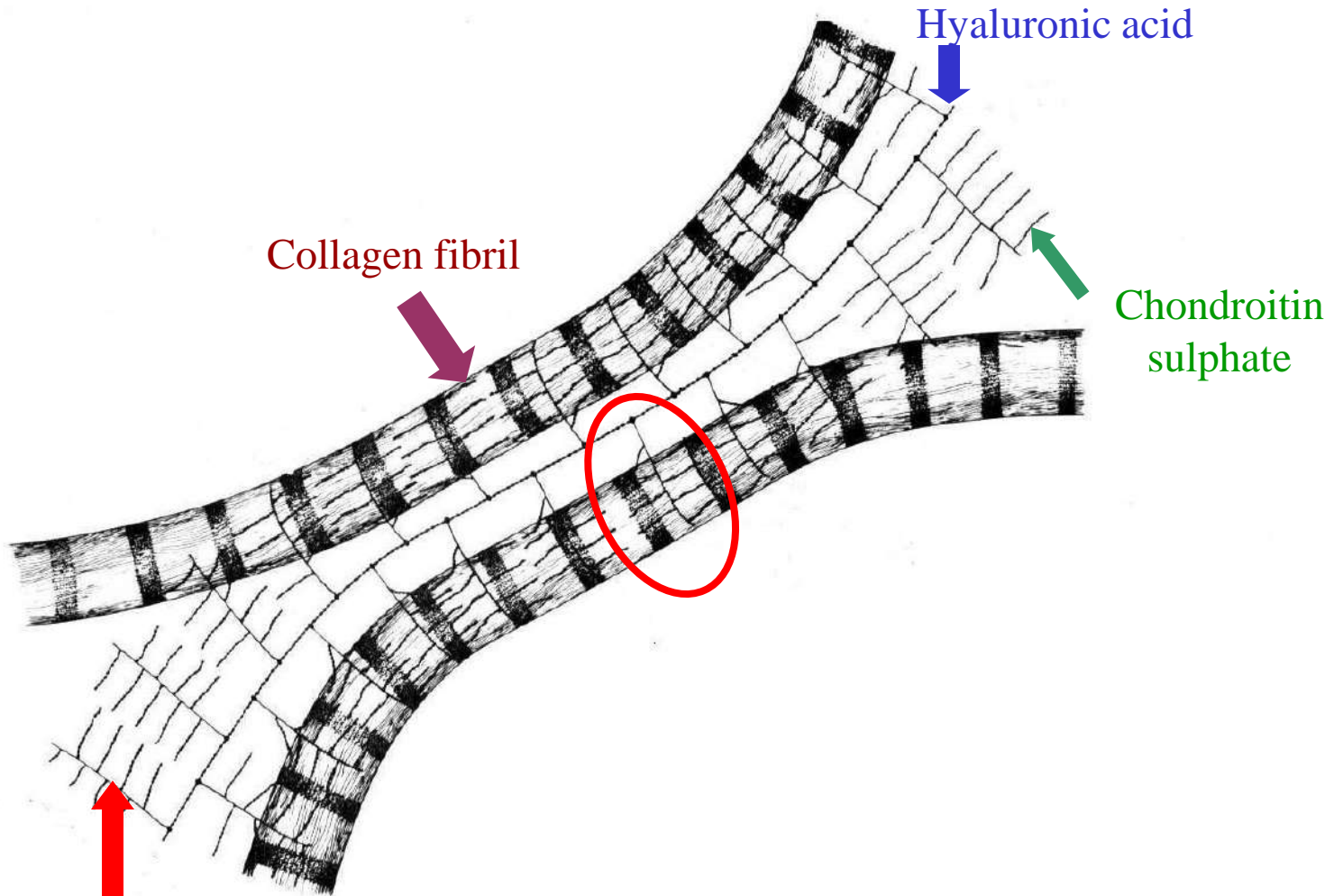


Main menu

Slide menu

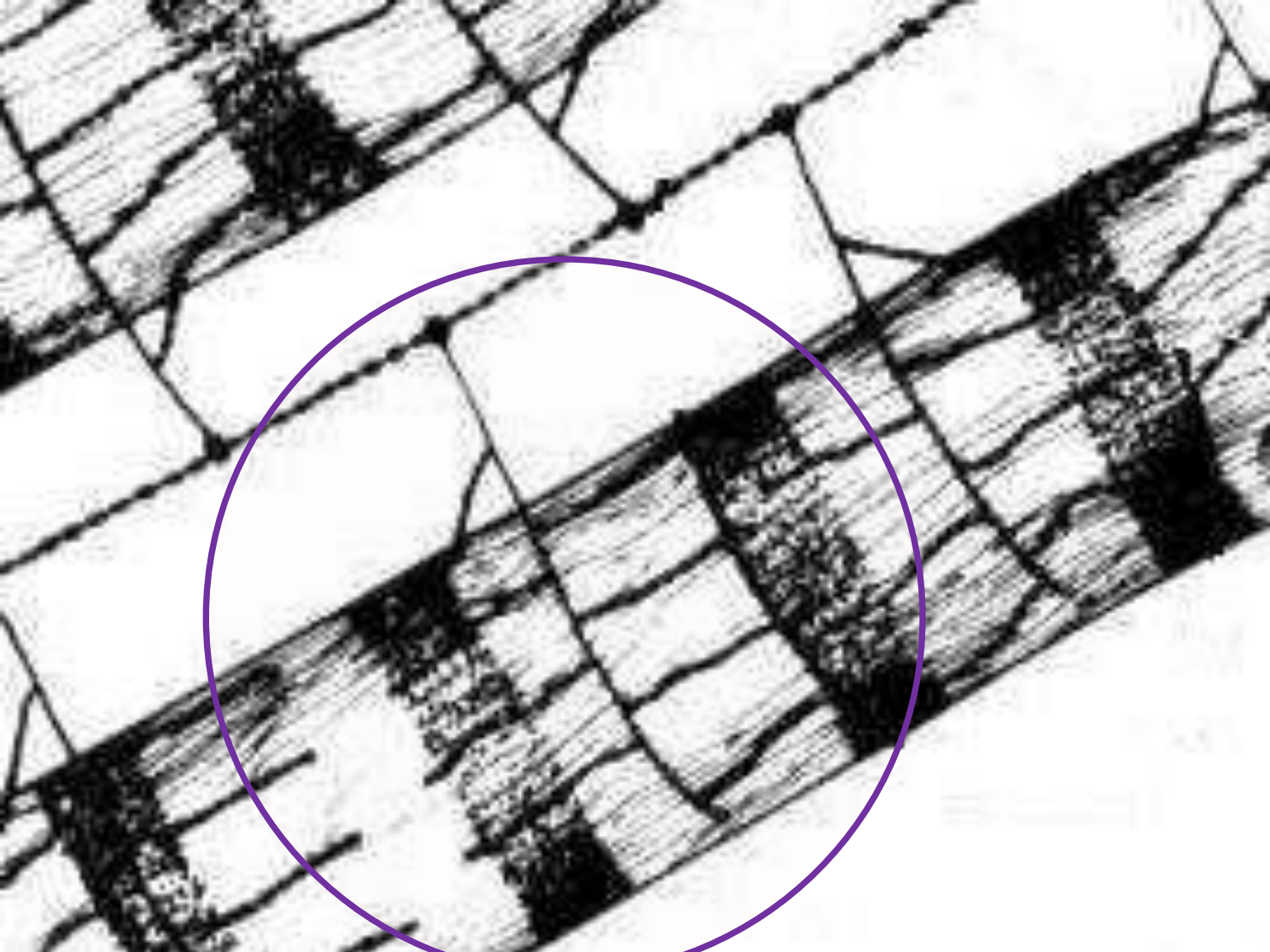


Quit




(Junqueira et al, 1986).

Let us take a closer look at how the collagen fibrils are bound together in the area marked by the red circle.



Slide 4



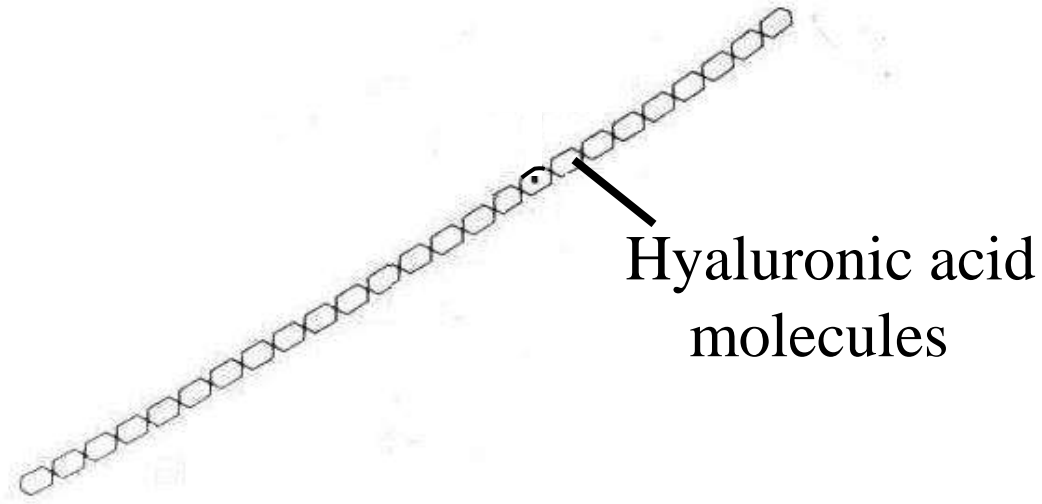
Main menu

Slide menu



Quit


The hyaluronic acid chain lies between two collagen fibrils. From this chain proteoglycans stretch towards the collagen fibrils. On the collagen fibrils chondroitin sulfates link perpendicular to the proteoglycans. Lets take another look at how the linking system between the collagen fibrils is build up.



Hyaluronic acid
molecules

(Junqueira et al, 1986).

Hyaluronic acid molecules form a chain.


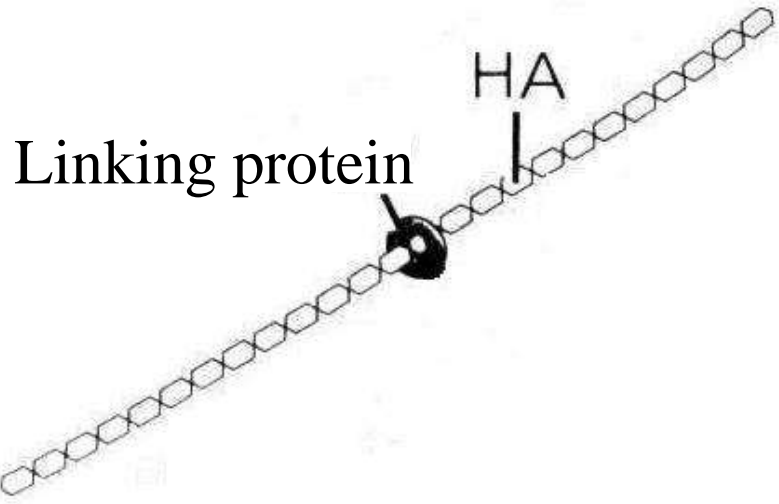


Main menu

Slide menu



Quit



Main menu

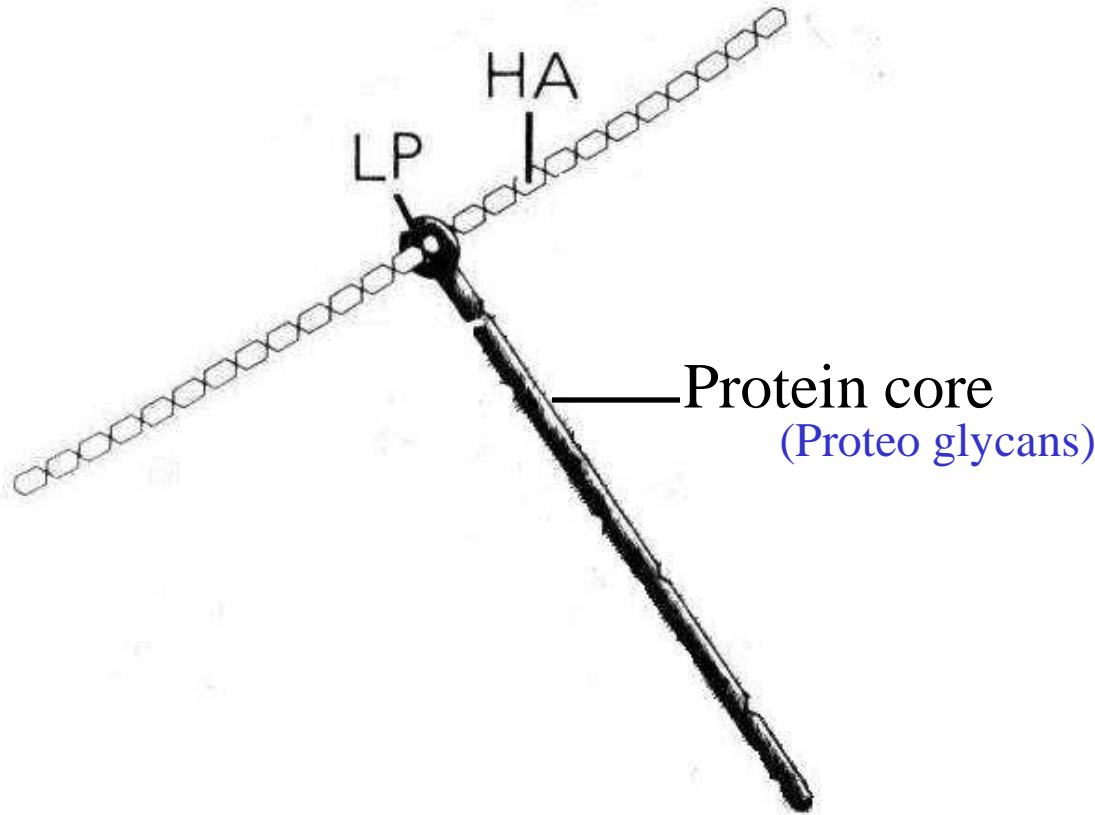
Slide menu



(Junqueira et al, 1986).


A linking protein then attaches to this chain.

Quit



(Junqueira et al, 1986).

A protein core made up by proteoglycans then attaches to the protein link.

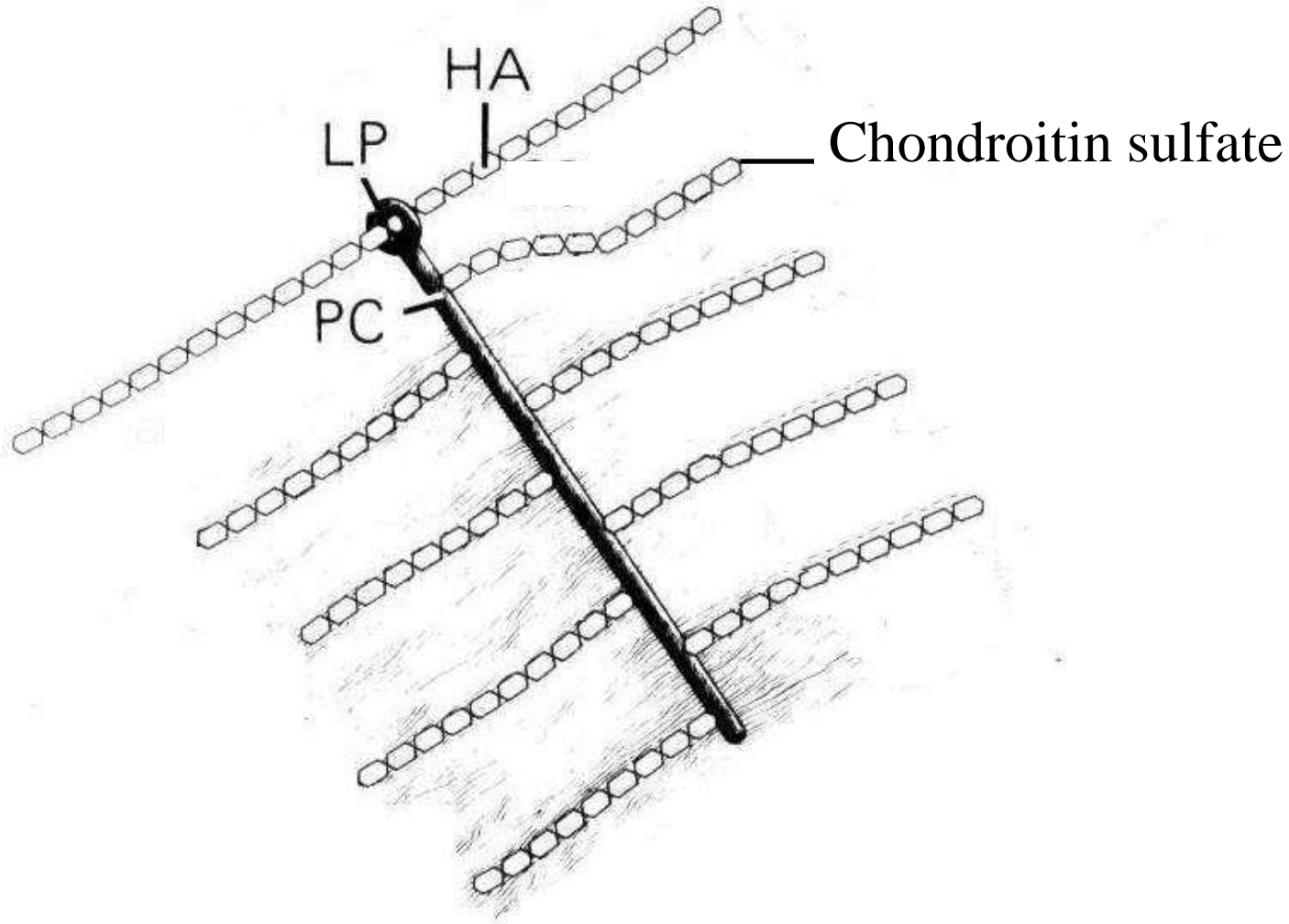


Main menu

Slide menu




Quit



(Junqueira et al, 1986).

From the protein core (PC) – chondroitin sulphate side chains stretch perpendicular.

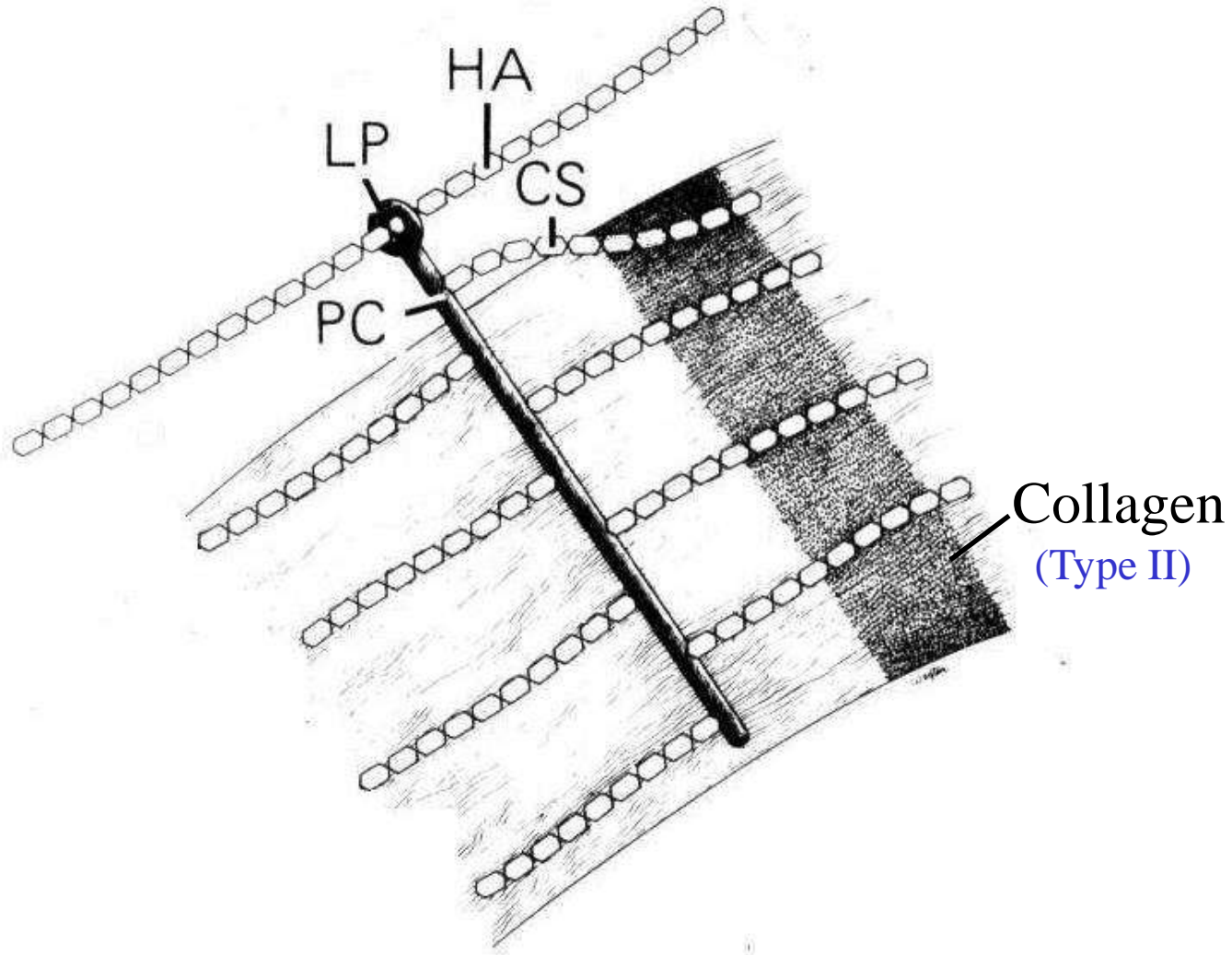


Main menu

Slide menu




Quit



(Junqueira et al, 1986).

The chondroitin side chains (CS) bind electrostatically to the collagen fibrils.

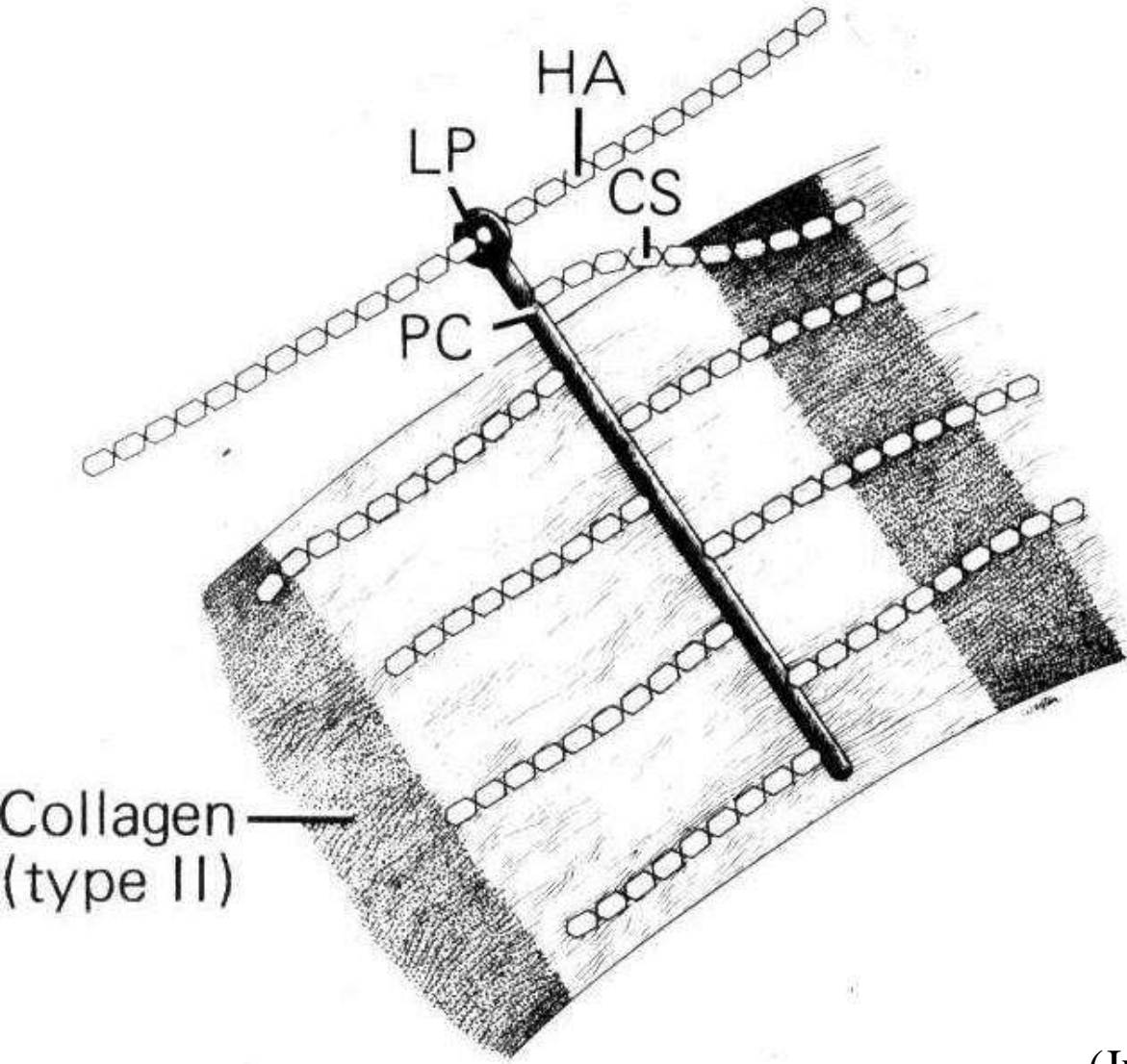


Main menu

Slide menu




Quit



(Junqueira et al, 1986).

Let us now take a closer look at the chondroitin side chains (CS).



Main menu

Slide menu



Quit

Perichondrium

- Dense CT firmly surround the cartilage resembling capsules that surround glands and many organs responsible for growth and maintenance
- Two layers (actively growing perichondrium)
 - outer fibrous** rich in blood vessels and nerves
 - inner cellular** (chondrogenic cells) differentiate to form chondroblasts

Chondrogenesis

- Like all connective tissue, cartilage is derived in the embryo from **mesenchyme**. Mesenchyme cells grow and differentiate into young cartilage cells or **chondroblasts** that are very active in secreting the surrounding matrix. The chondroblasts grow and develop in lacunae. These chondroblasts further differentiate into mature cartilage cells or **chondrocytes**.

******* The ability of cartilage to repair itself is **limited** particularly in adults.
Mainly due to the activity of the perichondrium during the period of growth in young individuals
Cardiothoracic surgery // costal cartilage cut



Main menu

Slide menu



Quit

Two different types of chondrogenesis

• ***Appositional growth*** takes place in **the perichondrium** the fibroblasts (**chondrogenic cells**) of the perichondrium change to **chondroblasts** which later change to round **chondrocytes** (addition from **outside**)

• ***Interstitial growth*** (addition from **inside**) takes place around the **lacunae** providing new cells for growth (enlarging the cartilage), and in areas where **perichondrium** is **absent** like


- articular surfaces in joints
- or in areas with direct contact with bone e.g. nasal and costal cartilages
- in forming bones and epiphyseal plate

As a consequence of this mitotic activity, lacunae may possess two, four, eight daughter chondrocytes. These are known as **isogenous** or **nest cells**

Functions of hyaline cartilage

- bone formation in fetal skeleton
- epiphyseal bone growth
- provide smooth articulation for joints

Slide 13

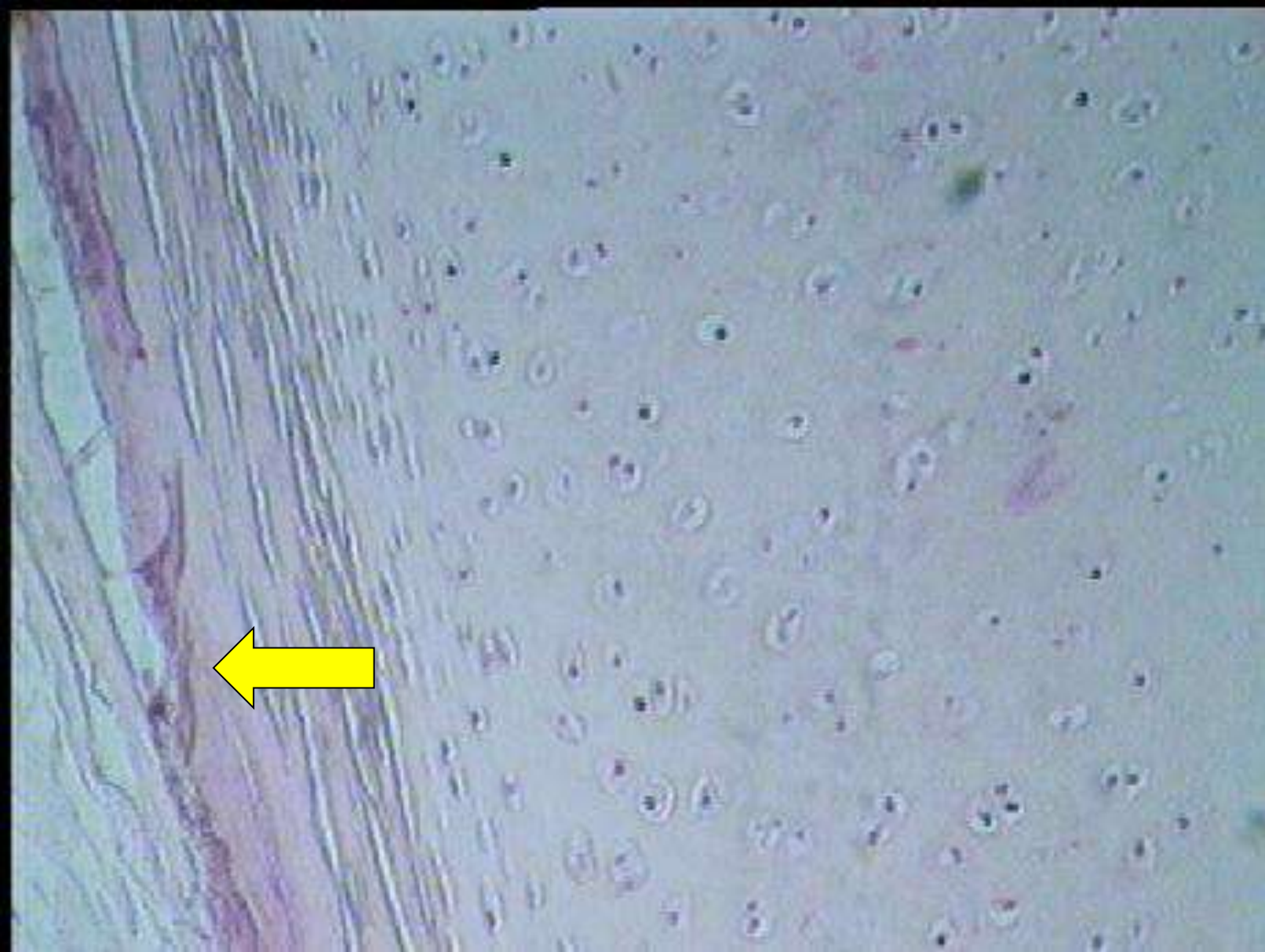

Main menu


Slide menu



Quit



This is hyaline cartilage. The ← indicates the perichondrium. In the perichondrium there are oval chondroblasts that will change to round chondrocytes because of appositional growth that takes place.

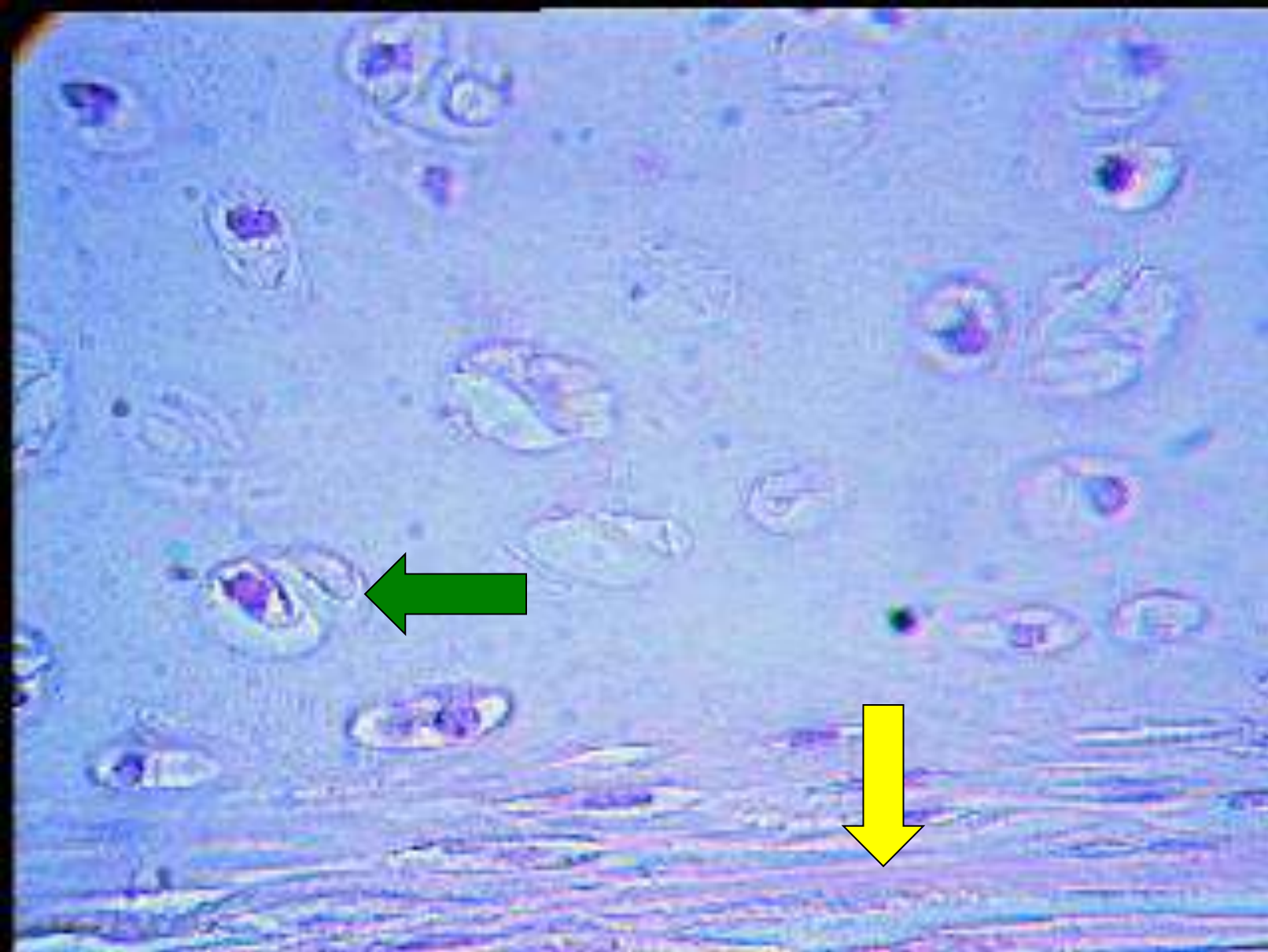

Main menu


Slide menu



Quit



This is hyaline cartilage the ← indicates a lacuna with 2 chondrocytes in it. The ↓ indicates the perichondrium.

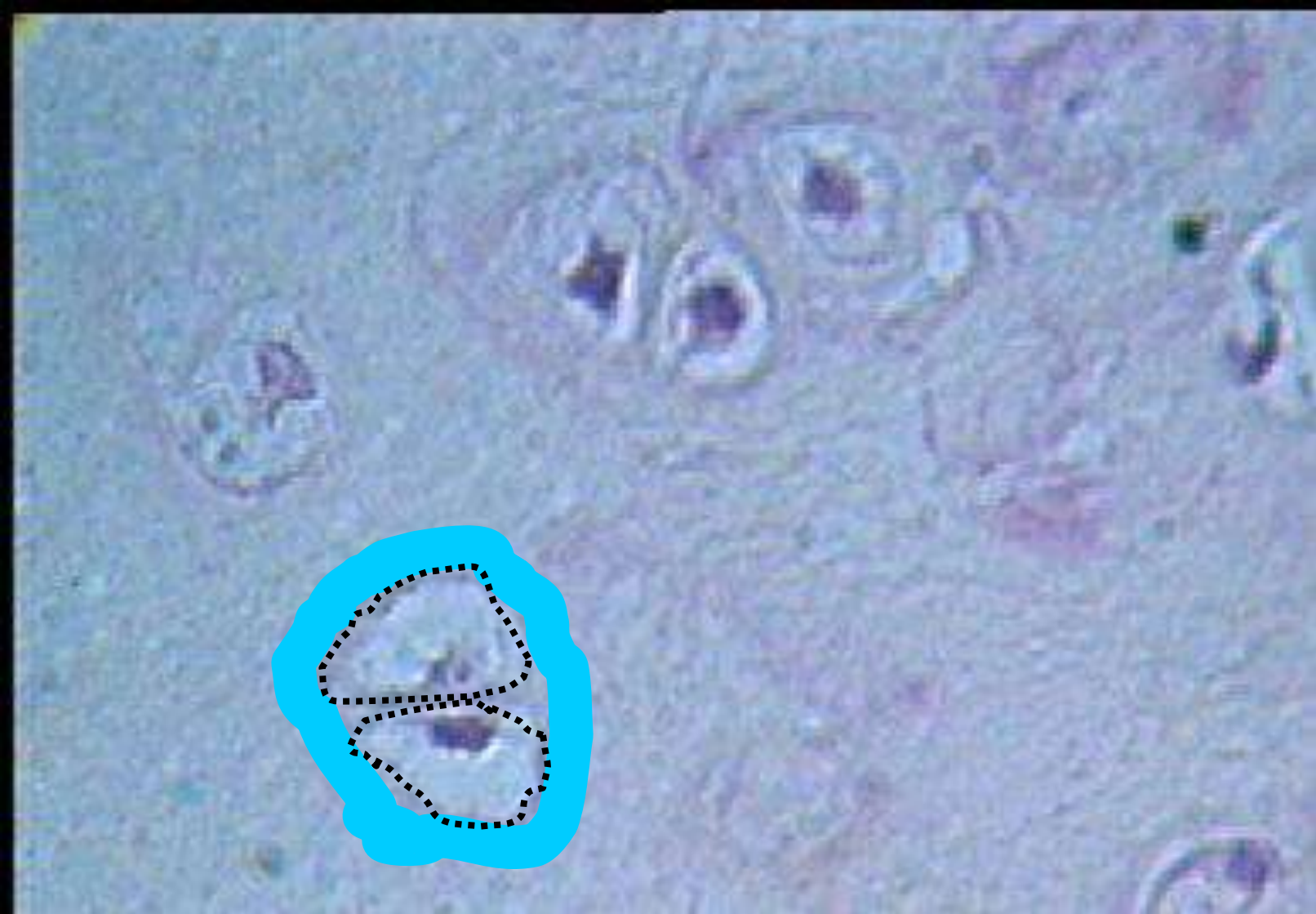

Main menu

Slide menu



Quit



This is a high magnification of hyaline cartilage. The **blue** area around the lacuna is the **territorial matrix**. The indicates two chondrocytes that lie together in one lacuna.

Articular Cartilage

is a specialized form of **hyaline cartilage**. transforms the articulating ends of the bones into **lubricated, wear-proof, slightly compressible surfaces, no perichondrium** and is **partly vascularized**.
divided into several zones:

1. *Tangential layer* (Superficial)

small and flattened chondrocytes parallel to the surface with very fine collagen fibres

2. *Transitional zone* (intermediate)

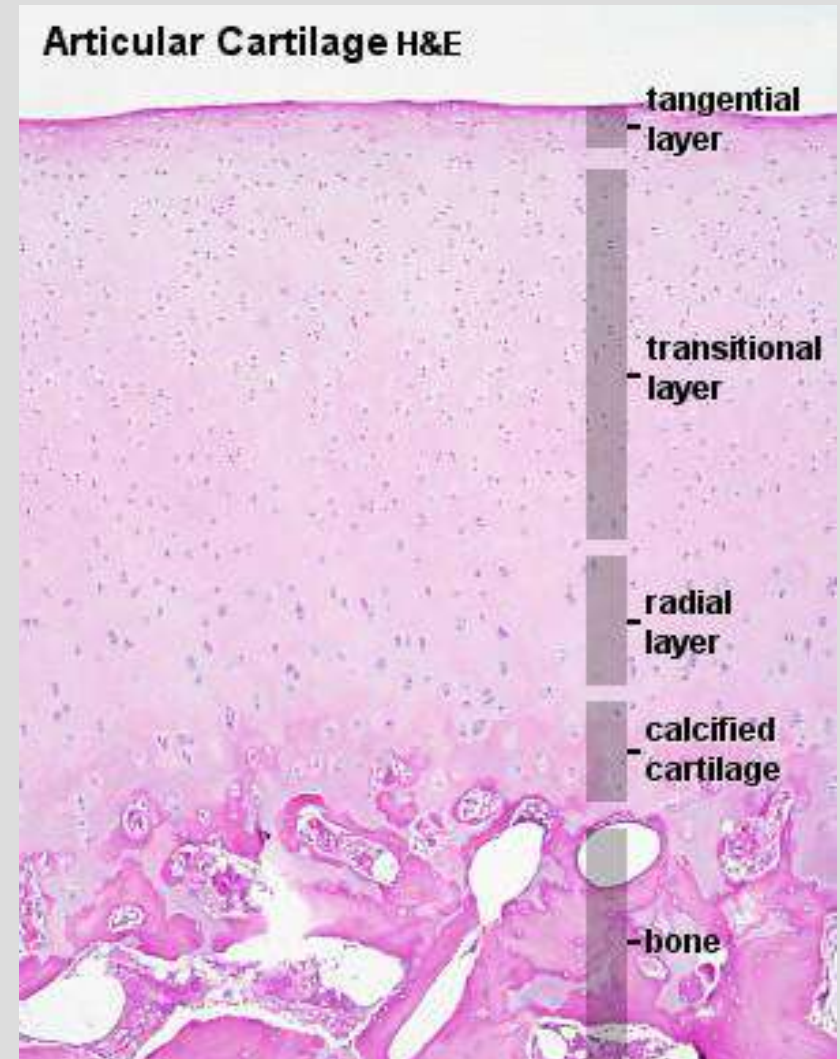
The chondrocytes are slightly larger and round and with oblique collagen fibres

3. *Radial zone* (deep)

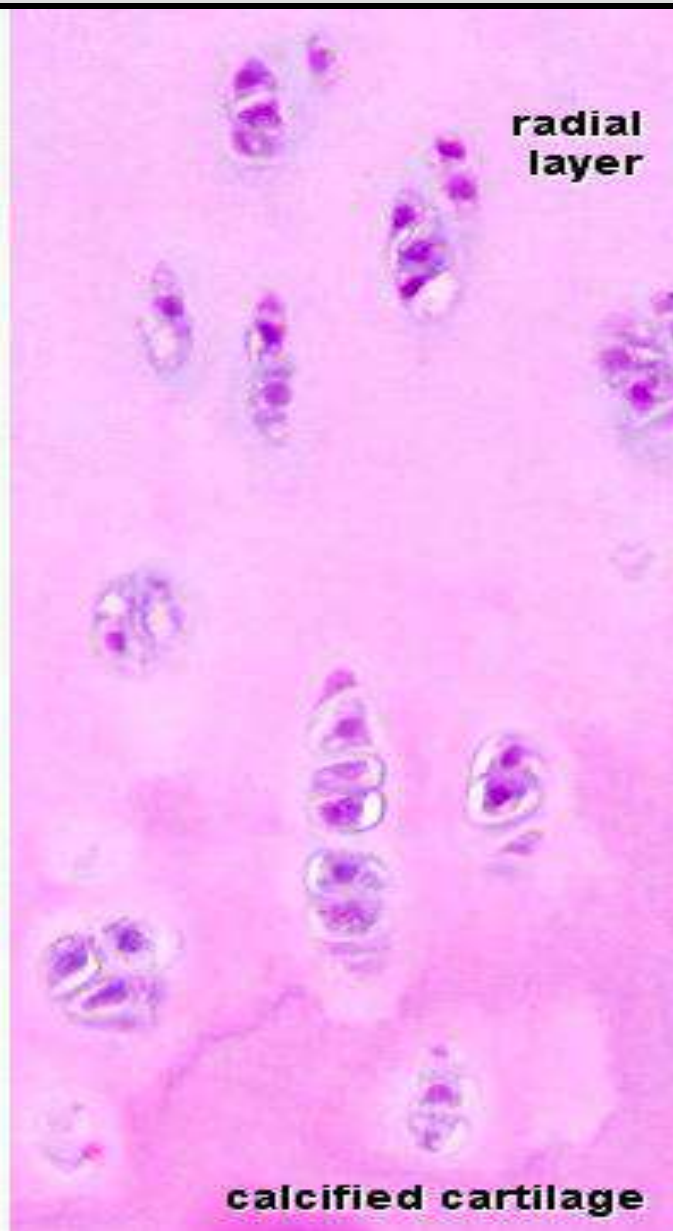
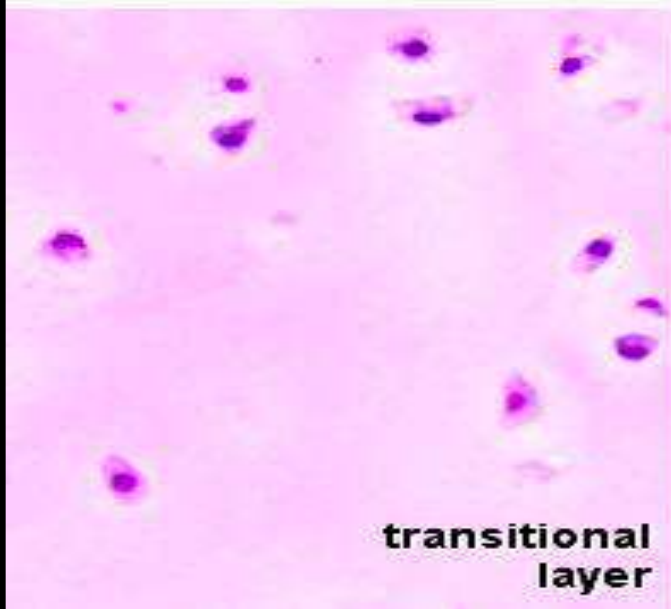
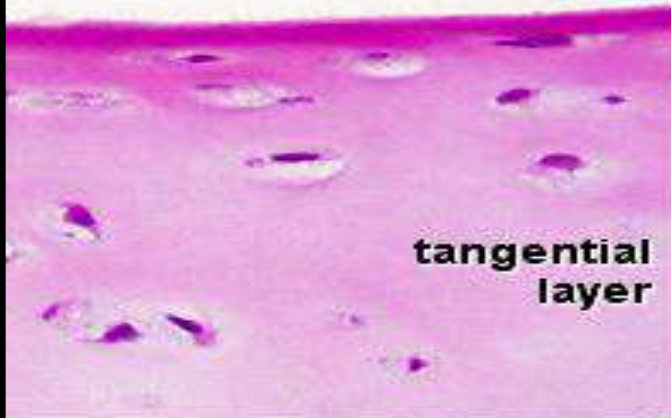
Fairly large chondrocytes, in columns, and parallel to it collagen fibres

4. *Calcified cartilage layer* (mineralized)

It rests on the underlying bone and attached to the subchondral bone.



Articular Cartilage H&E





Elastic cartilage

- Similar to hyaline except that it contains many **elastic fibres** to provide **elasticity** and **resiliency**
- Yellow** in colour (in fresh state due to elastin)
- Unlike hyaline cartilage its matrix usually **does not calcify**
- All location** are surrounded by **perichondrium**

Found:


- external ear (pinna of ear or auricle)
- external auditory canal
- epiglottis
- Eustachian tube
- Larynx (corniculate and cuneiform cartilage)

Main menu

Slide menu



Quit

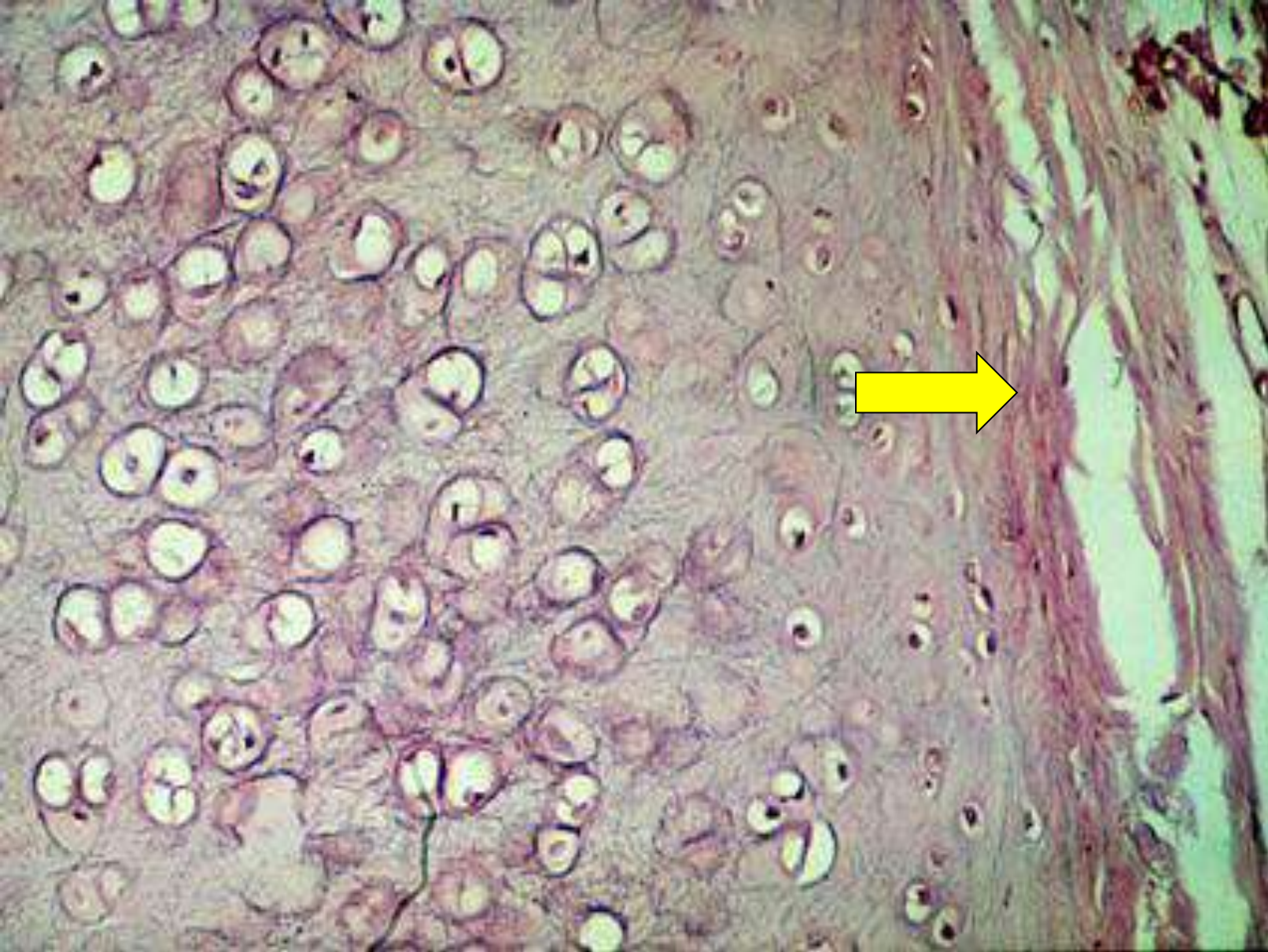


Main menu

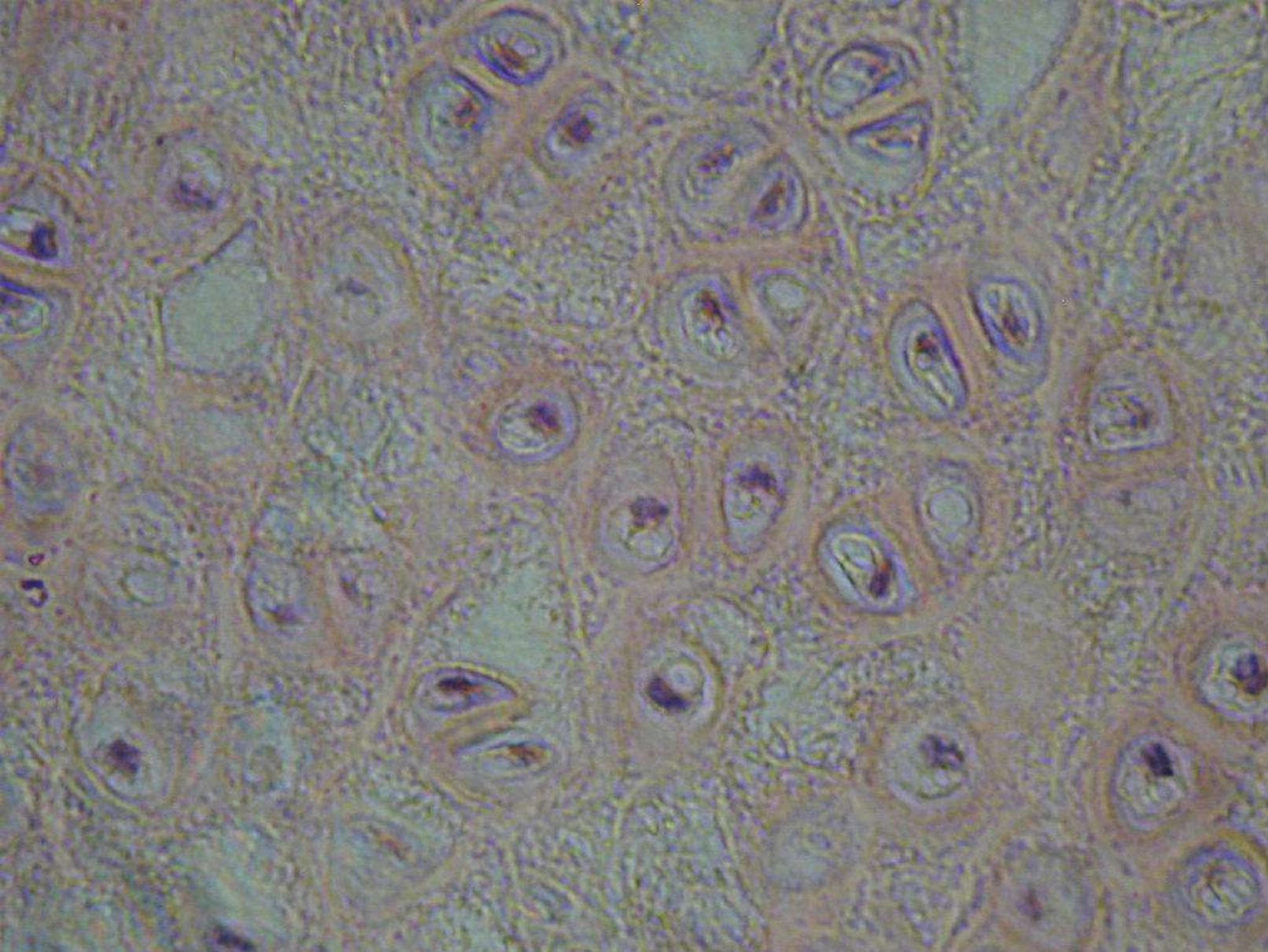
Slide menu




Quit



This is elastic cartilage. Like hyaline it has a → perichondrium on the outside. The matrix of elastic cartilage contains a lot of visible elastic fibers. This cartilage also has lacunae with chondrocytes and territorial matrix.



Slide 18



Main menu

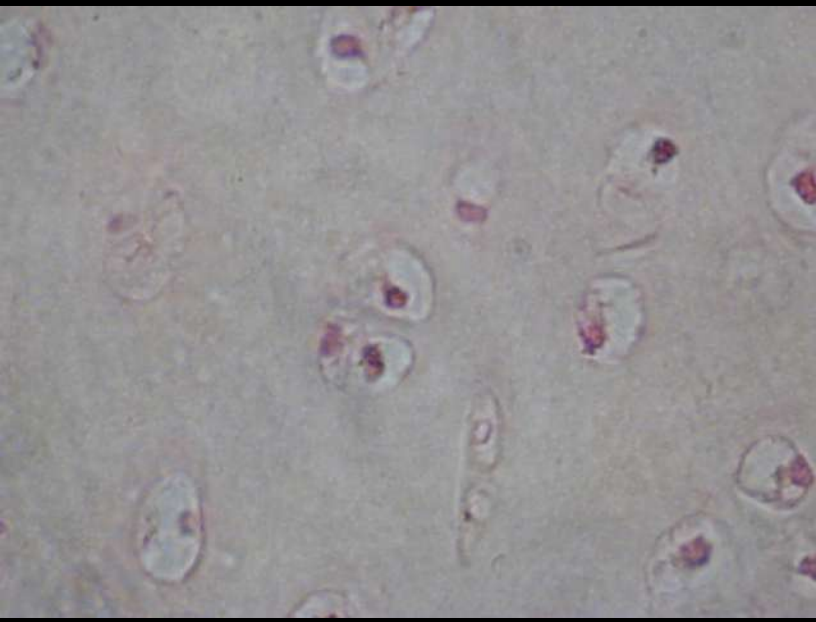
Slide menu



Quit

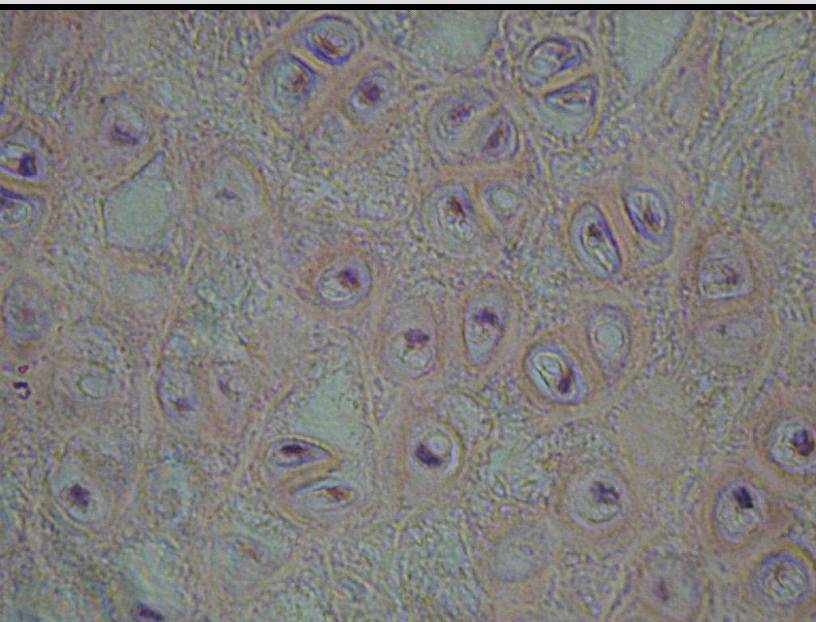
This is a high magnification of elastic cartilage. Notice the matrix containing fibers.

Two slides taken at the same magnification



Hyaline cartilage

\pm 14 chondrocytes are visible in this slide.




Elastic cartilage

\pm 38 chondrocytes are visible in this slide.

In elastic cartilage the concentration of lacunae with chondrocytes is much higher than in hyaline cartilage.

Slide 19



Main menu

Slide menu



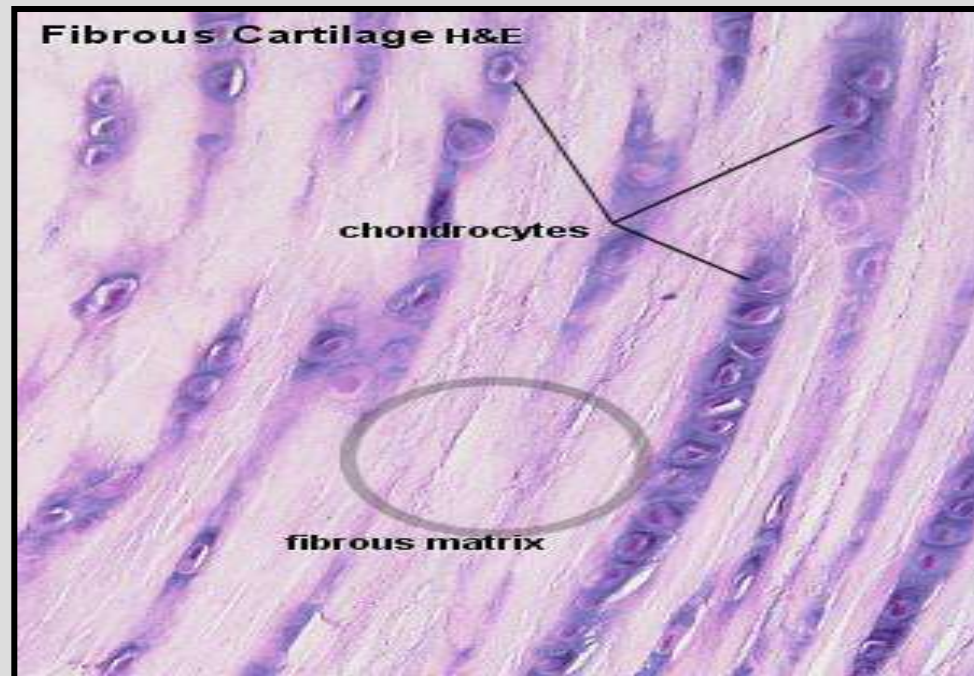
Quit

Fibrocartilage

- Always associated with **dense CT**
- Many **collagen** fibres in the matrix with relatively **little** amorphous matrix (In contrast to other cartilage types, **collagen type I is dominant in fibrous cartilage.**)
- **No perichondrium**
- Chondrocytes tend to lie in **rows**
- Can withstand **strong forces**, resist compression and shear forces

Found:

- Intervertebral disk
- symphysis pubis
- articular disc of sternoclavicular and temporomandibular joints




Main menu

Slide menu



Quit




Main menu


Slide menu



Quit



This is fibrocartilage. The matrix contains a lot of collagen fibers. The lacunae with chondrocytes are few and tend to lie in rows. The indicates a row of chondrocytes.

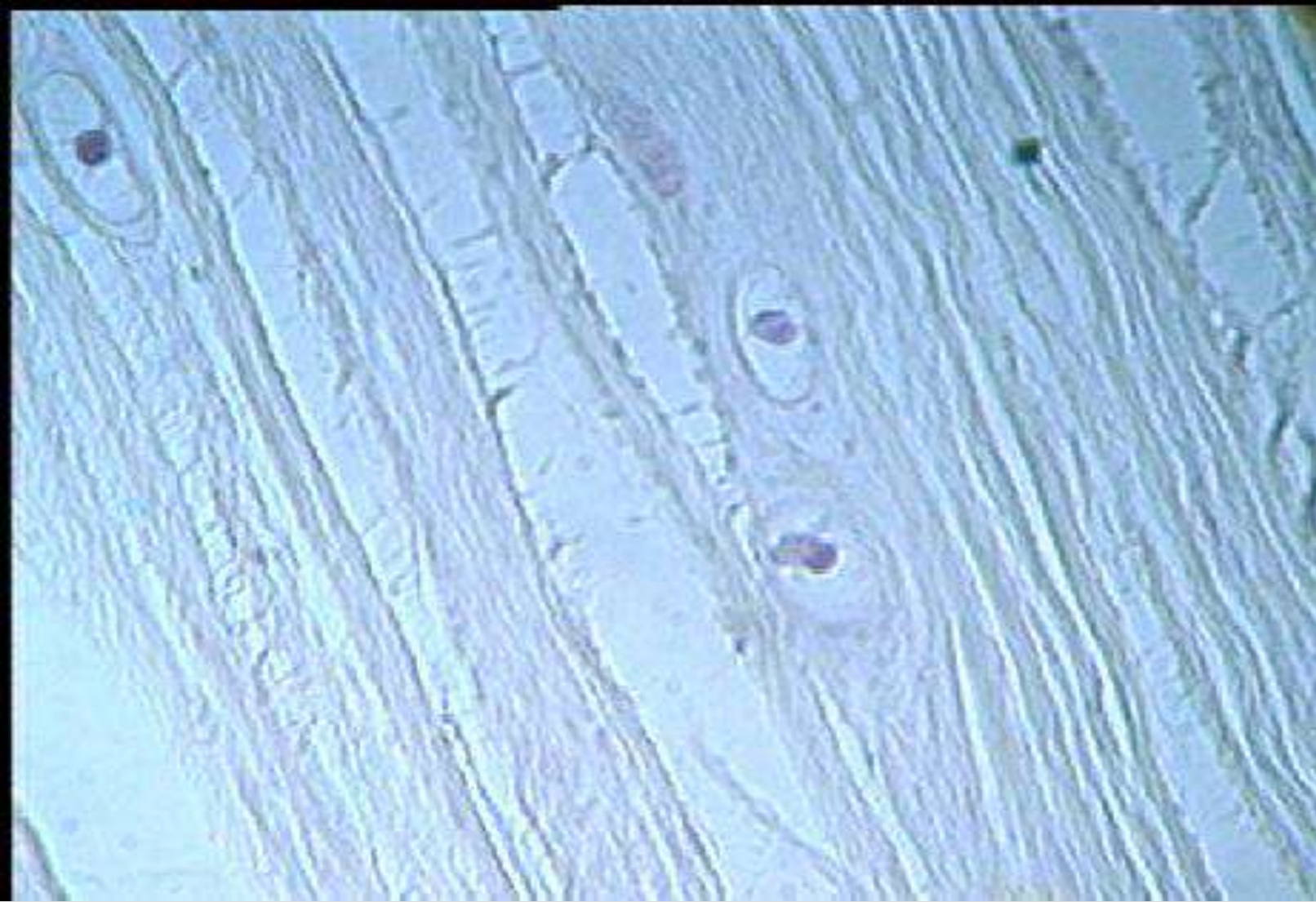

Main menu

Slide menu



Quit



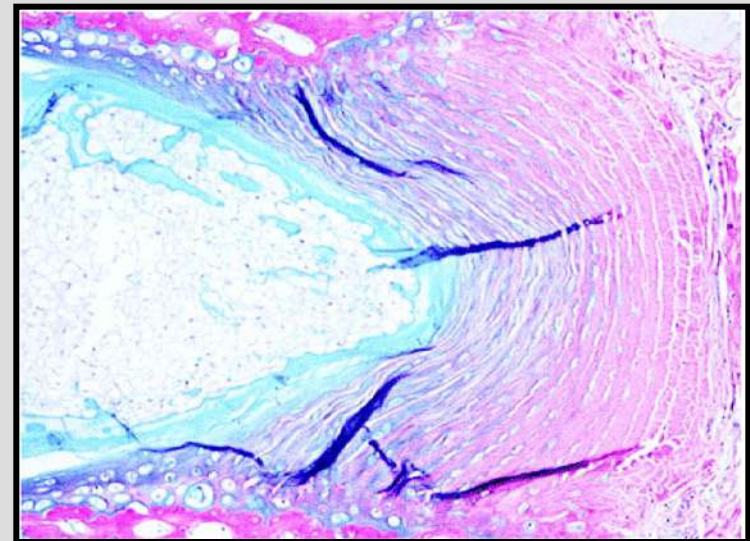
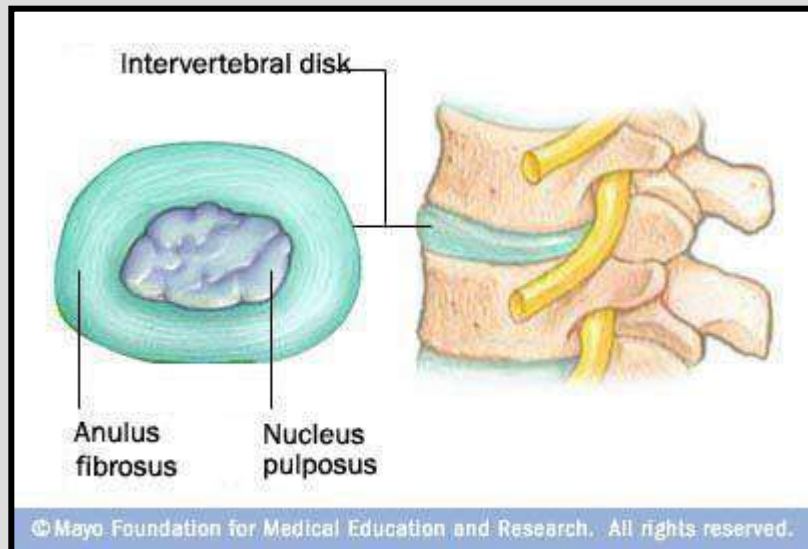
This is a high magnification of fibro cartilage. This type of cartilage does'n have a perichondrium. The matrix is highly packed with collagen fibers for strength.

Intervertebral disks

consist of fibrocartilage plates between the vertebrae and act as mechanical shock absorbers. In sections they are seen to be formed of two components:

- annulus fibrosus**, which is the outer region consisting of orderly concentric arrangements of cells and matrix dominated by **collagen type I** and **chondrocytes**

- nucleus pulposus** (large vacuolated cells, that are vestiges of the embryonic notochord).



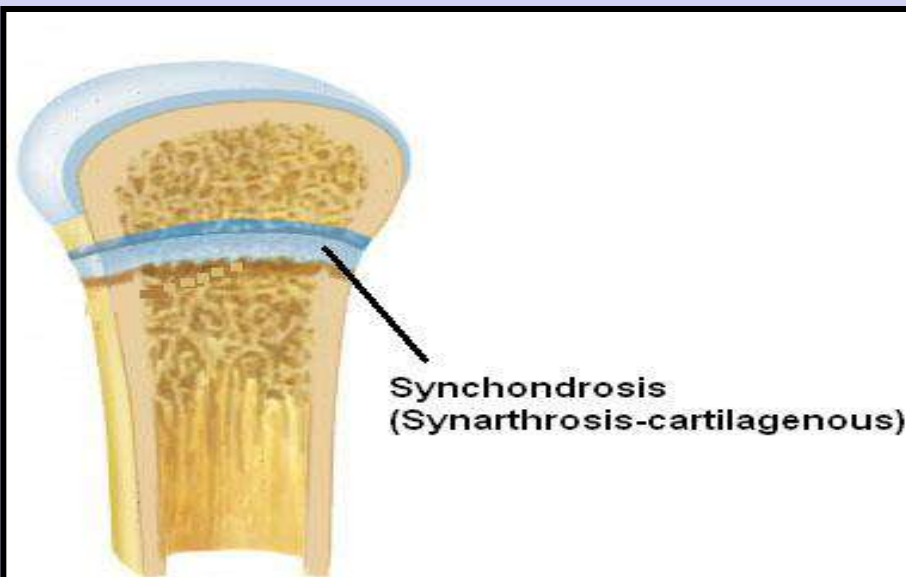
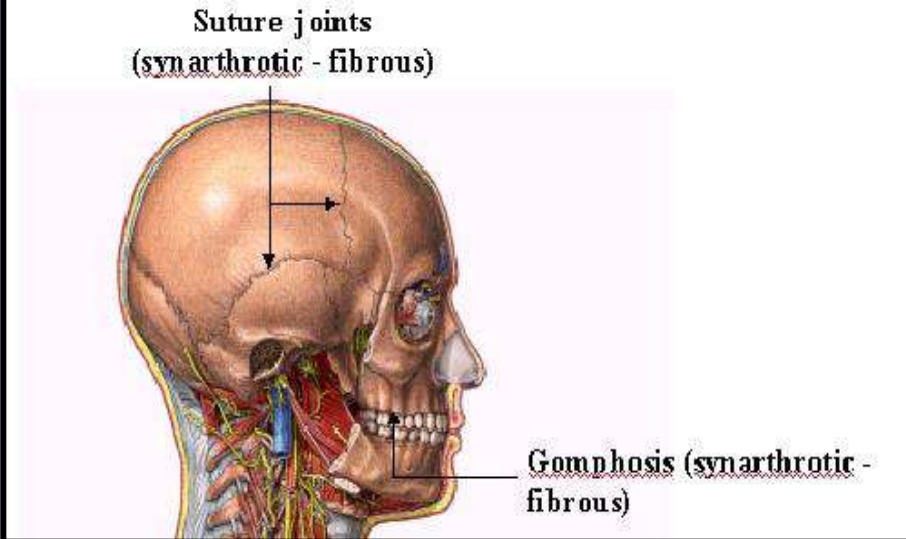
Articulations

A. **Synarthrosis** – an **immovable** joint.

1. **Fibrous** – bones are held together by dense fibrous connective tissue e.g. **Sutures** and **Gomphosis** – a joint between the teeth and the bony sockets the **periodontal ligament**.

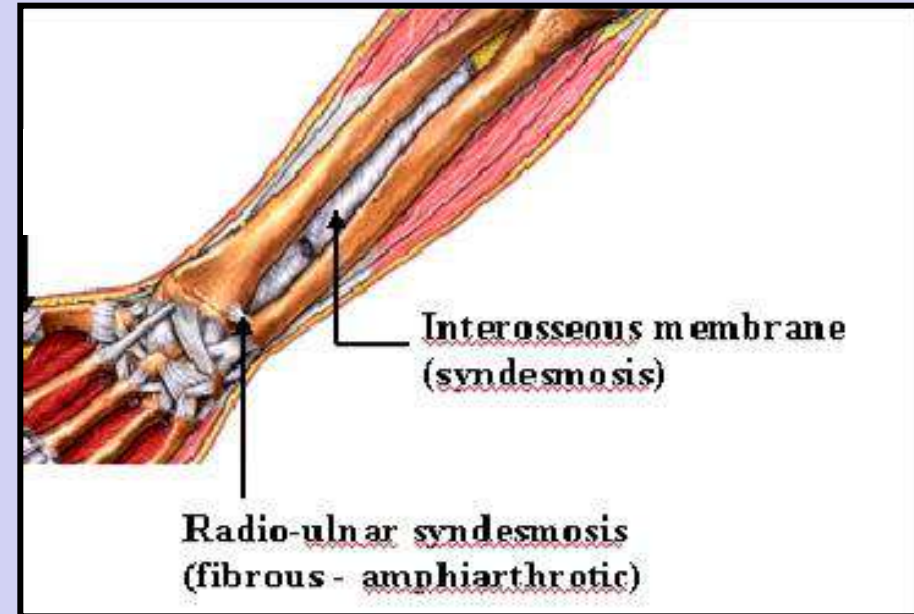
2. **Cartilagenous (synchondrosis)** – bones are held together immovably with cartilage, e.g. **epiphyseal growth plate**.

SYNARTHROTIC ARTICULATIONS OF THE SKULL

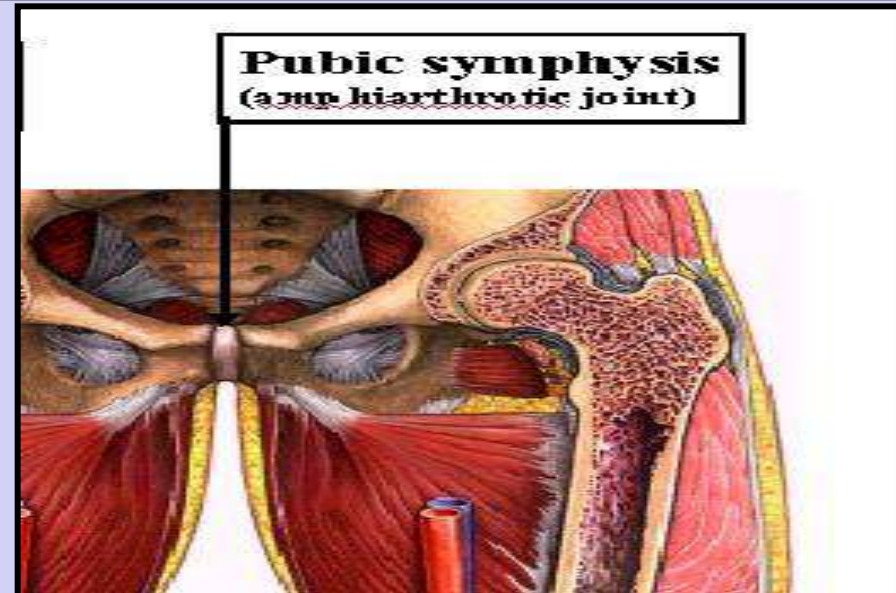


B. Amphiarthrosis – a slightly moveable joint.

1. **Fibrous (syndesmosis)** – bones are held together by a fibrous ligament or sheet e.g. distal ends of the **tibia and fibula** together, **interosseous membrane**, holds the tibia and fibula, as well as, the **radius and ulna** together.



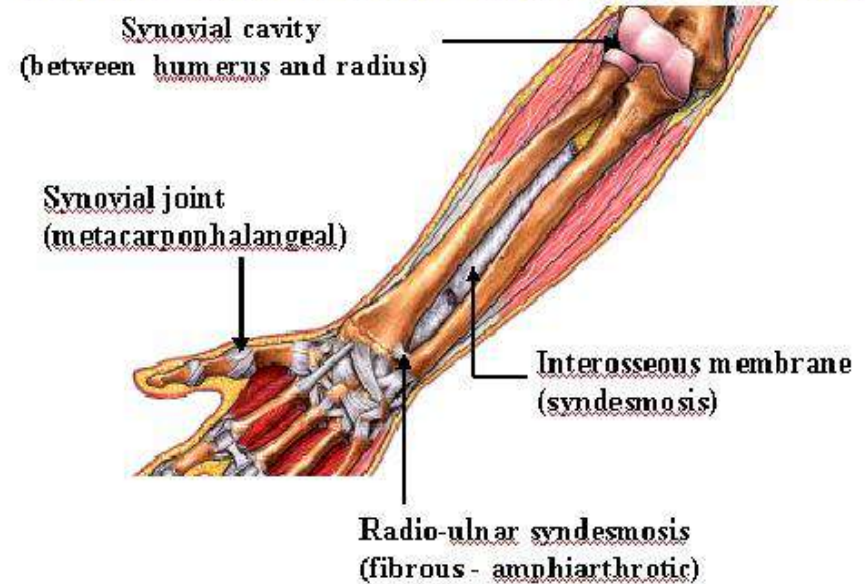
2. **Cartilagenous** – articulating bones are held together by a pad of fibrocartilage e.g. the **symphysis** and the **intervertebral disks**.



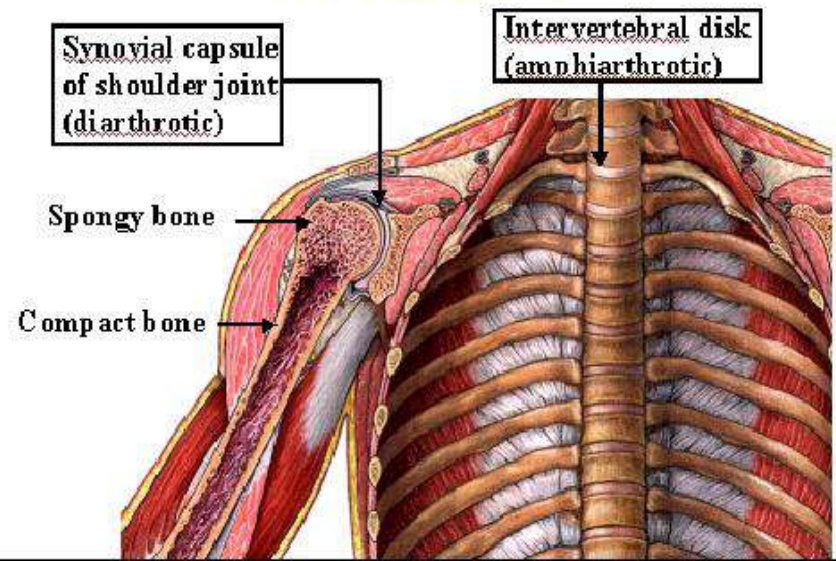
C. **Diarthrosis** – a freely moveable joint always showing a joint capsule lined with a synovial membrane. The **synovial joints** are further subdivided by the type of movement they allow:

1. **Monaxial** – movement in **one** plane (knee and elbow).
2. **Biaxial** – movement in **two** planes (wrist)
3. **Triaxial** – movement in **three** planes (shoulder and hip)

ARTICULATIONS OF ANTEBRACHIUM, WRIST AND HAND - ANTERIOR VIEW



ARTICULATIONS OF THE UPPER TORSO



Thank you

Prof Aiman I Al-Qtaitat