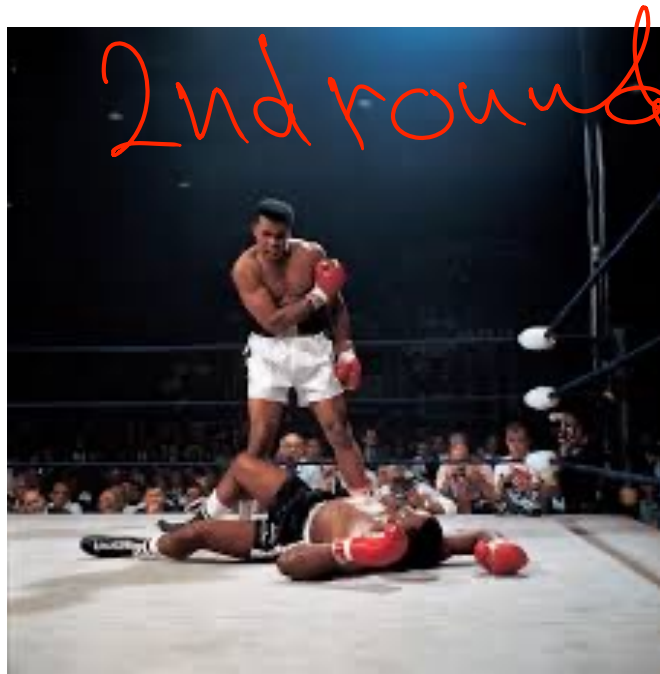


relations to
the Lateral
pterygoid Muscle.



deep relations:-

Mohammed Ali clay in the past is the MR of boxing in 2nd round

1-M → Medial pterygoid Muscle
2-M → Mandibular. N

ALI
↓

3-A → Auriculo-temporal. N

4-L → Lingual. N

5-I → Inferior alveolar. N

6-Clay → Gland of tympani

7-past → ^{visu} → old → otic ganglion

8-M → Middle meningeal. A

9-2nd = 2nd part of maxillary. A

Maxillary artery →

1- قار → 2- قار → 3- قار
1st infundibulation 2nd deepulation between neck

Buccal. N
→ Between head