

وسهلا



أهلا

يُمنع أخذ السلايدات بدون
إذن المحرر واي اجراء
يخالف ذلك يقع تحت طائلة
المسؤولية القانونية
جميع المعلومات للاستخدام
التعليمي فقط

الأستاذ الدكتور يوسف حسين

كلية الطب - جامعة مؤتة - الأردن

دكتورة من جامعة كولونيا المانيا

Prof. Dr. Youssef Hussein Anatomy - YouTube

الواتس (أي استفسار)
00201224904207

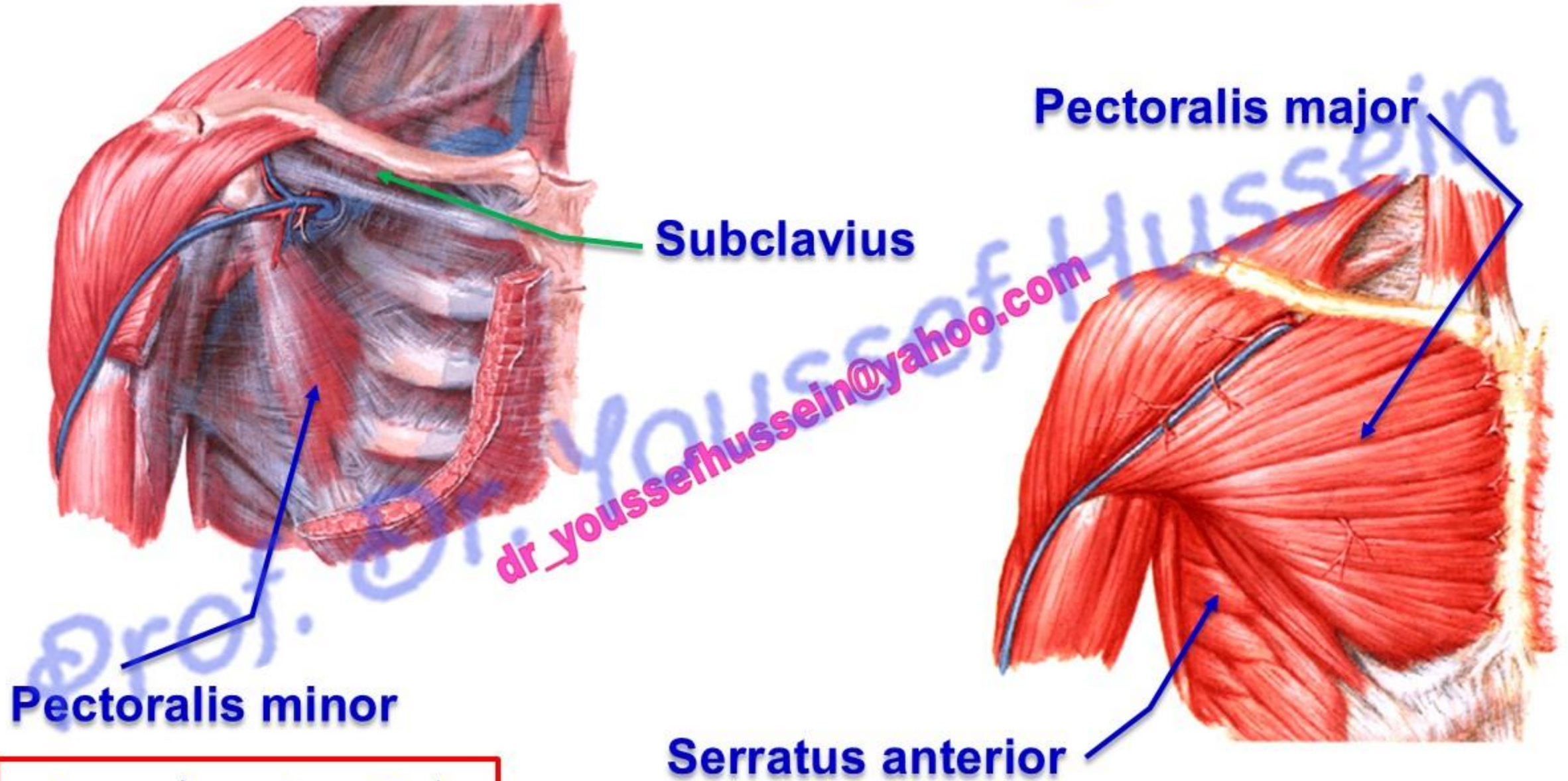
MUSCLES OF THE PECTORAL REGION

اليوثيوب د. يوسف حسين

- **Pectoral region** is the region in front of the upper part of the chest, its **Muscles** connecting the chest wall to the arm.

[Prof. Dr. Youssef Hussein Anatomy - YouTube](#)

Muscles of the Pectoral region



Subclavius

Pectoralis major

Pectoralis minor

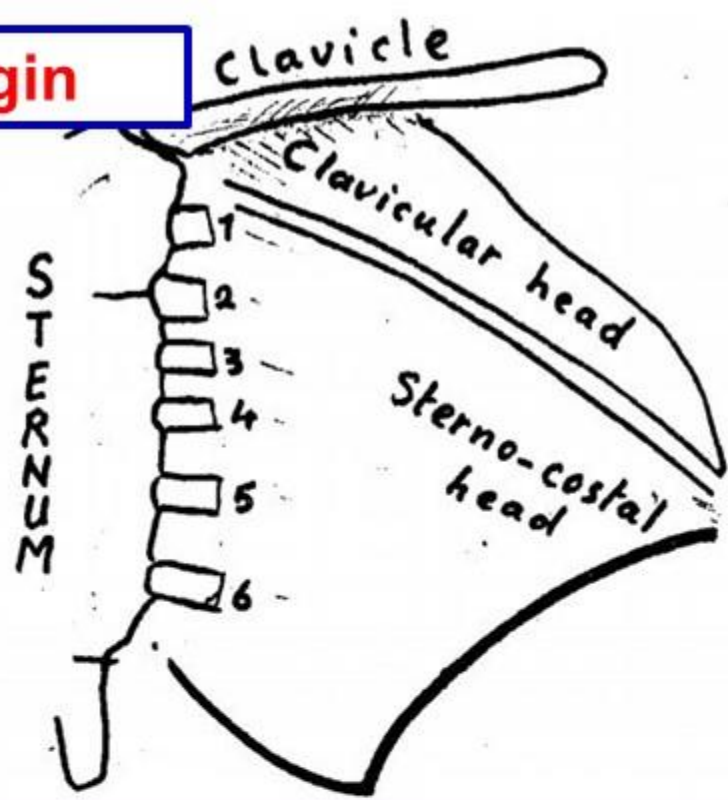
Serratus anterior

اليوتيوب د. يوسف حسين

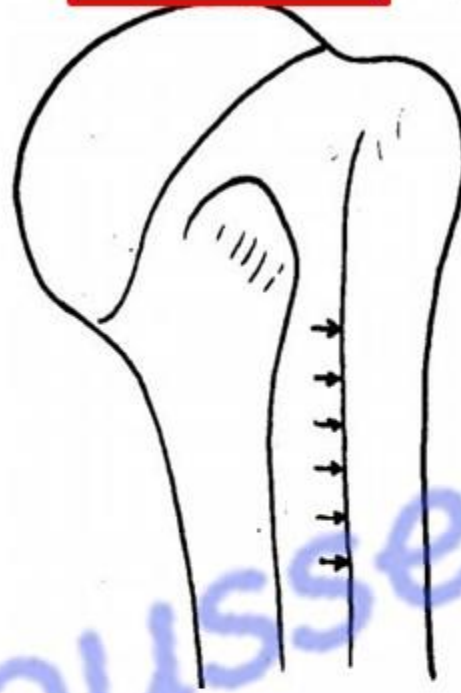
Pectoralis Major muscle

اليو تيوب د. يوسف حسين

Origin

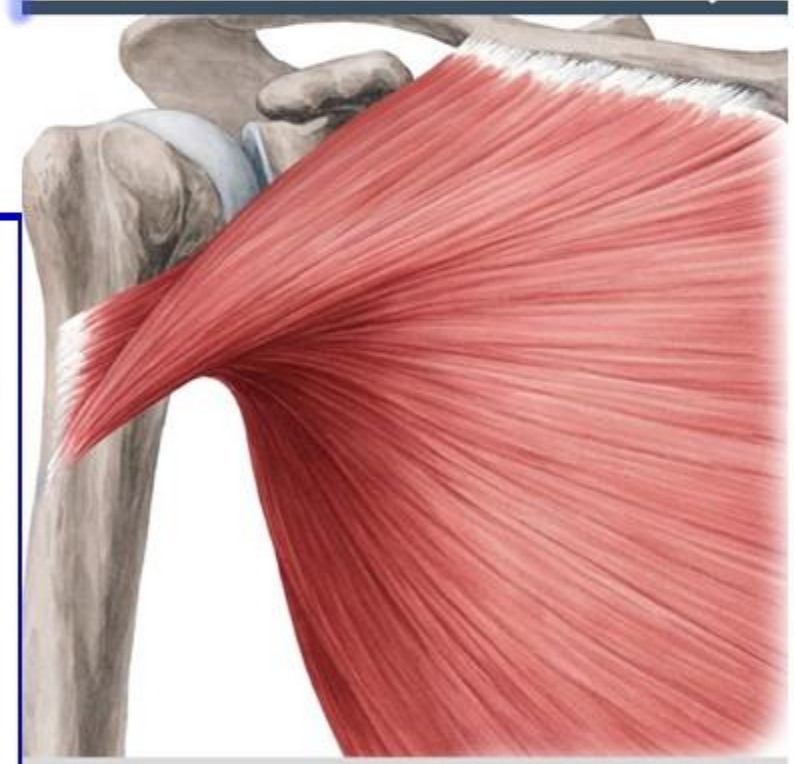

Insertion



dr_youssefhussein@yahoo.com

Lateral lip of the bicipital groove



* **Origin: by two heads:**

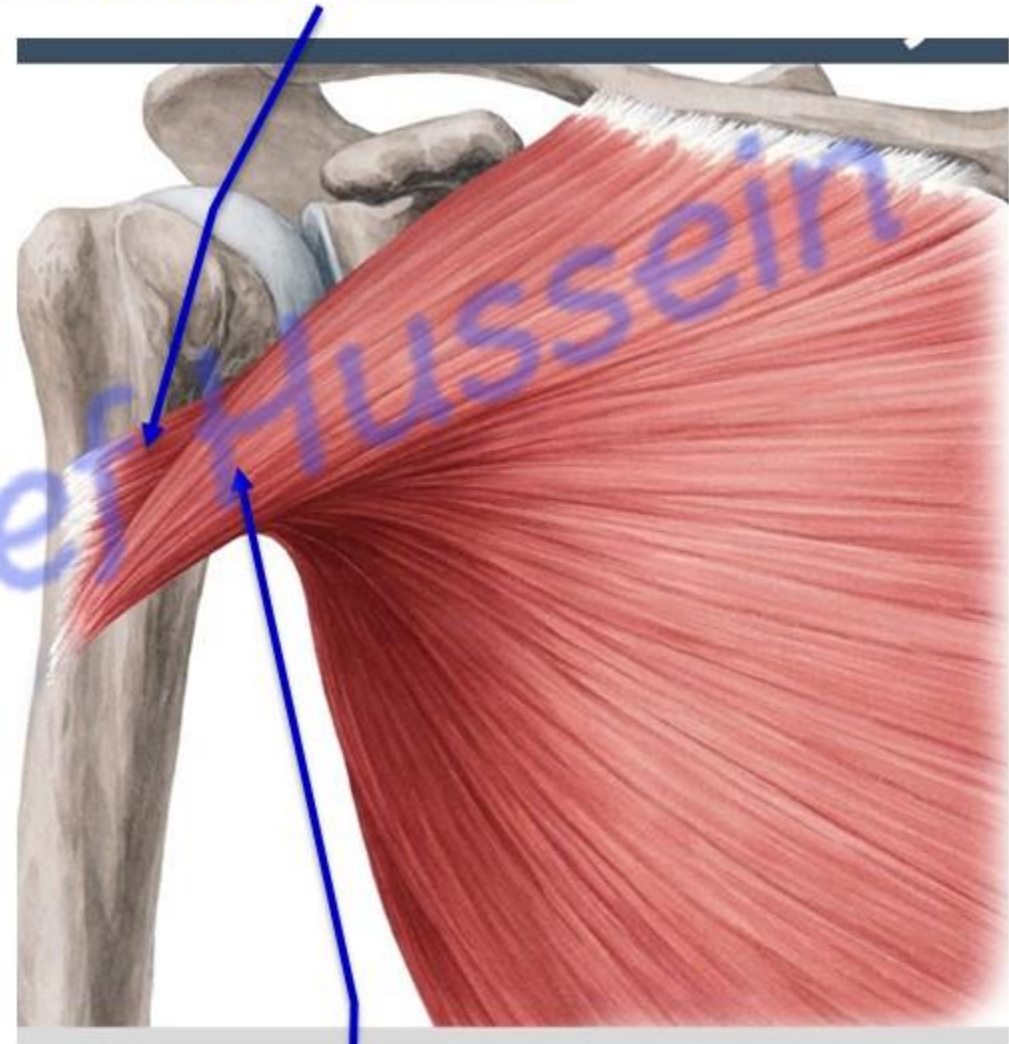
A) Clavicular head: from anterior surface of the medial 1/2 of the clavicle.

B) Sternocostal head: 1) anterior surface of the sternum.
2) Upper 6 costal cartilages.
3) External abdominal oblique aponeurosis.

Pectoralis major muscle

- 1- The **upper fibers** are **twisted** and inserted **downward** forming the anterior lamina.
 - 2- The **lower fibers** are **twisted** and inserted **upward** forming the posterior lamina.
- **SO** the anterior fold of the axilla is **higher than** the posterior fold

Posterior lamina

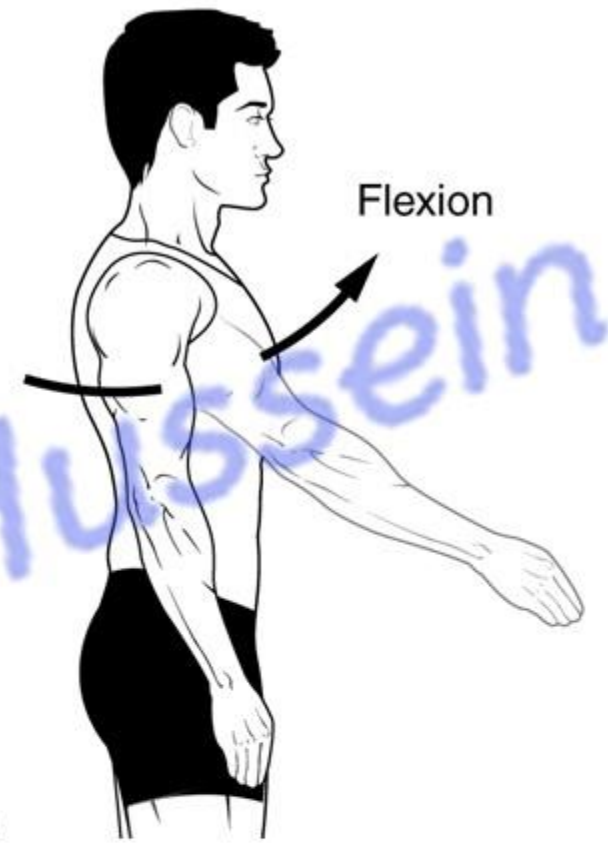


Anterior lamina

- **Nerve supply (double):** Lateral pectoral nerve (C5,6,7) and medial pectoral nerve (C8,T1).
- It is the **only muscle** of the upper limb supplied by 5 segments from brachial plexus.

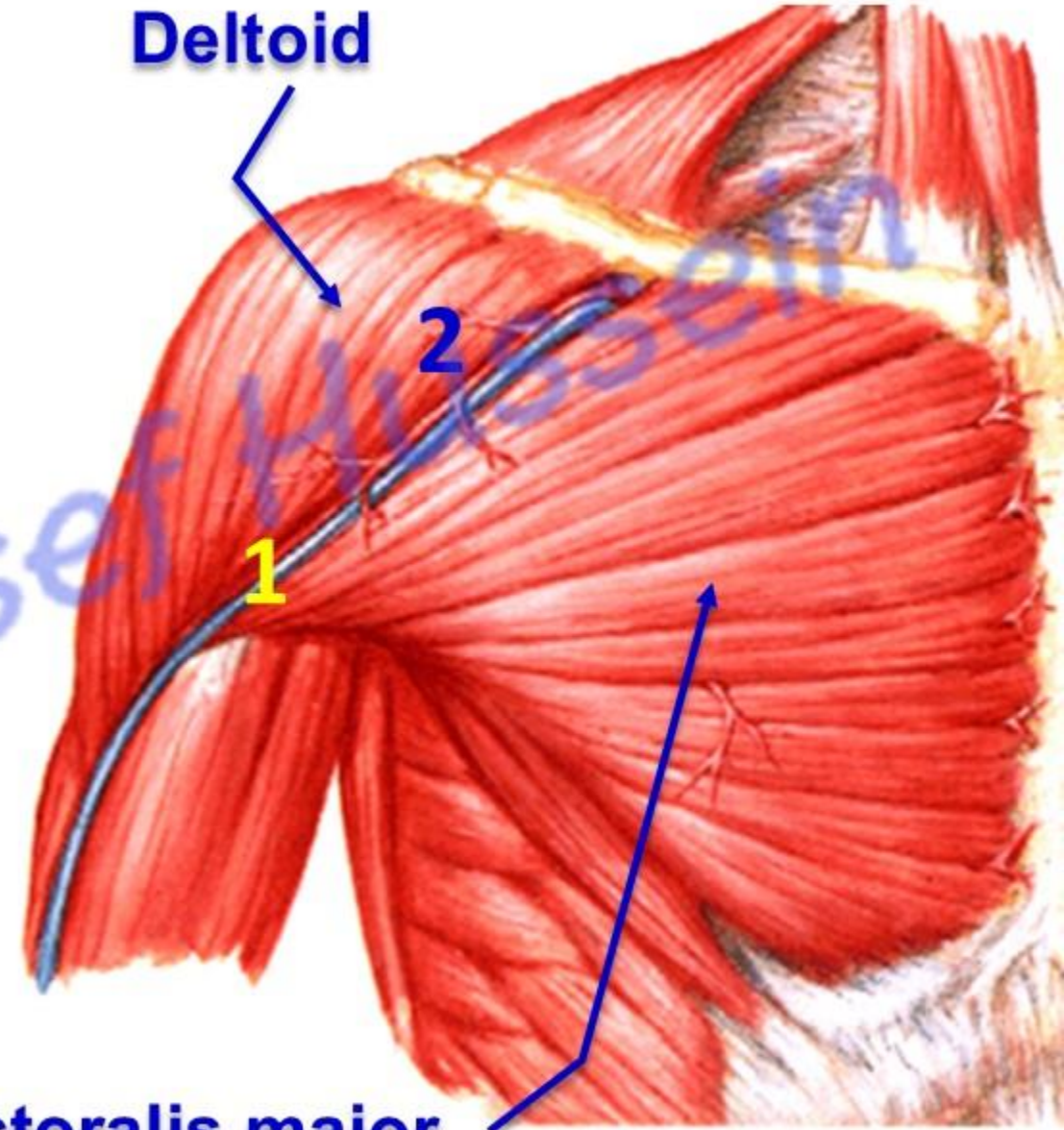
* **Actions:**

- 1- Adduction and medial rotation of the arm.
- 2- Flexion of the arm by **clavicular head**.
- 3- Elevates the ribs during deep inspiration.
- 4- **Sternocostal part** acts together with latissimus dorsi, teres major and deltoid: **draw the trunk up during climbing and gymnastic.**



اليوتيوب د. يوسف حسين

- **Deltopectoral groove** between deltoid and pectoralis major containing:
 - 1- Cephalic **Vein**.
 - 2- Deltoid branch of thoracoacromial **Artery**.



Pectoralis major

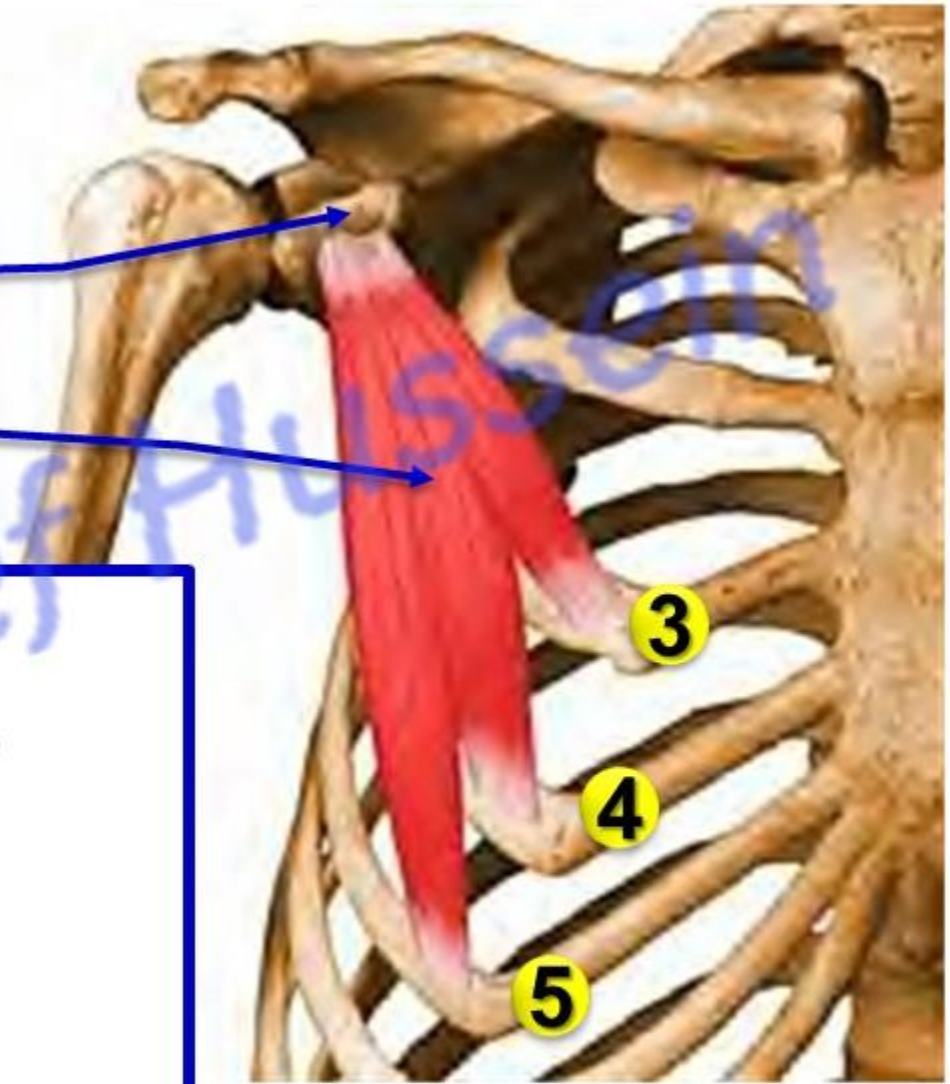
اليو تيوب د. يوسف حسين

Pectoralis minor

Coracoid process

Pectoralis minor muscle

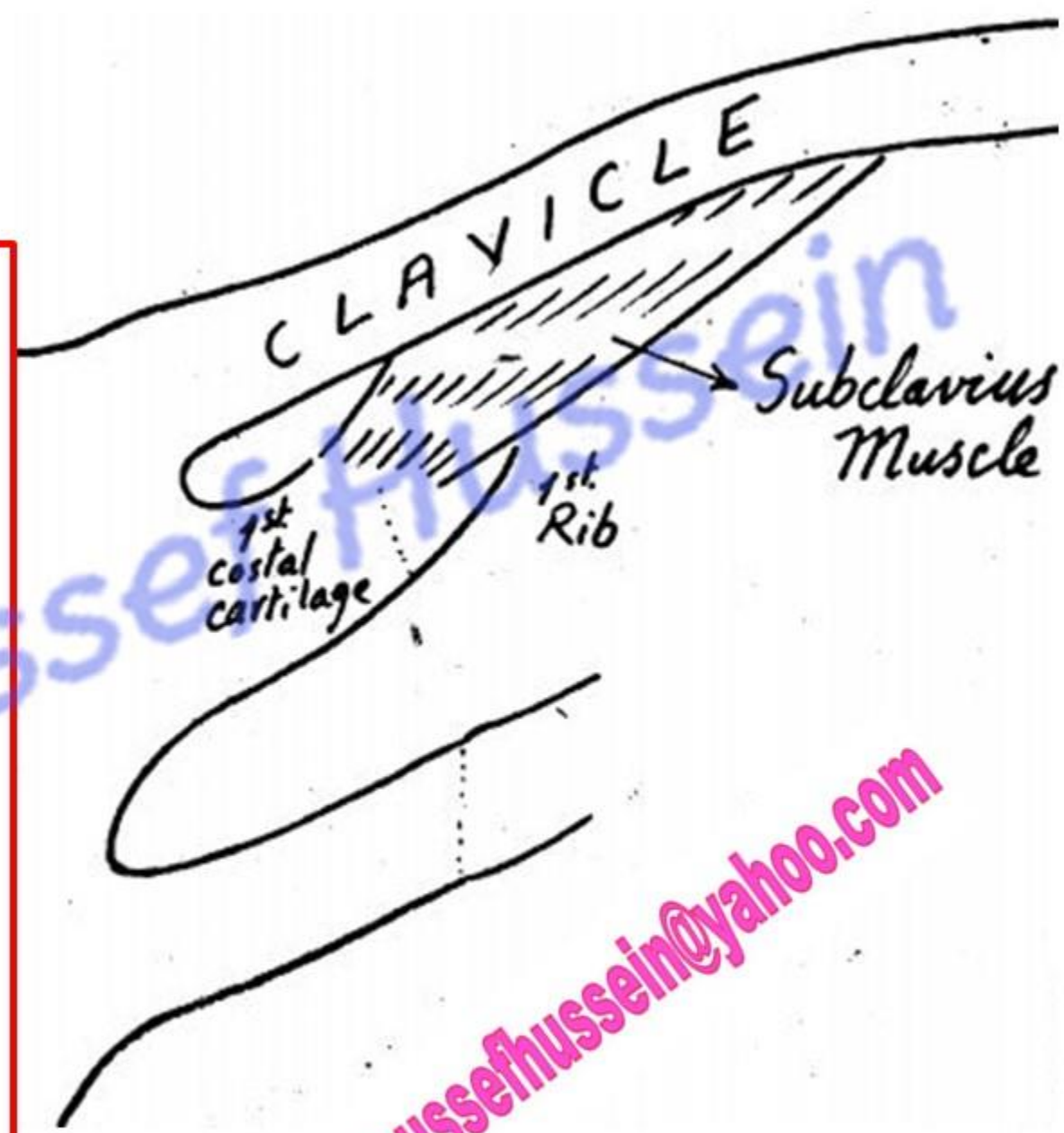
- * **Origin:** from the 3rd, 4th and 5th ribs.
- * **Insertion:** superior surface of the coracoid process.
- * **Nerve supply:** medial pectoral nerve.
- **Actions:**
 - 1) Protraction the scapula (forward movement).
 - 2) Depression the shoulder.
 - 3) Elevates the ribs during deep inspiration.



Subclavius

- * **Origin:** from the upper surface of **first rib** and **first costal cartilage**.
- * **Insertion:** into subclavian groove on the lower surface of the clavicle.
- * **Nerve supply:** Nerve to subclavius from upper trunk of brachial plexus (C 5 & 6) .
- * **Action:** Fixation of the clavicle during movements of the shoulder girdle.

اليوثيوب د. يوسف حسين



Clavipectoral fascia

اليوثيوب د. يوسف حسين

Clavipectoral fascia

Clavicle

Thoracoacromial artery

Cephalic vein

Pectoralis minor muscle

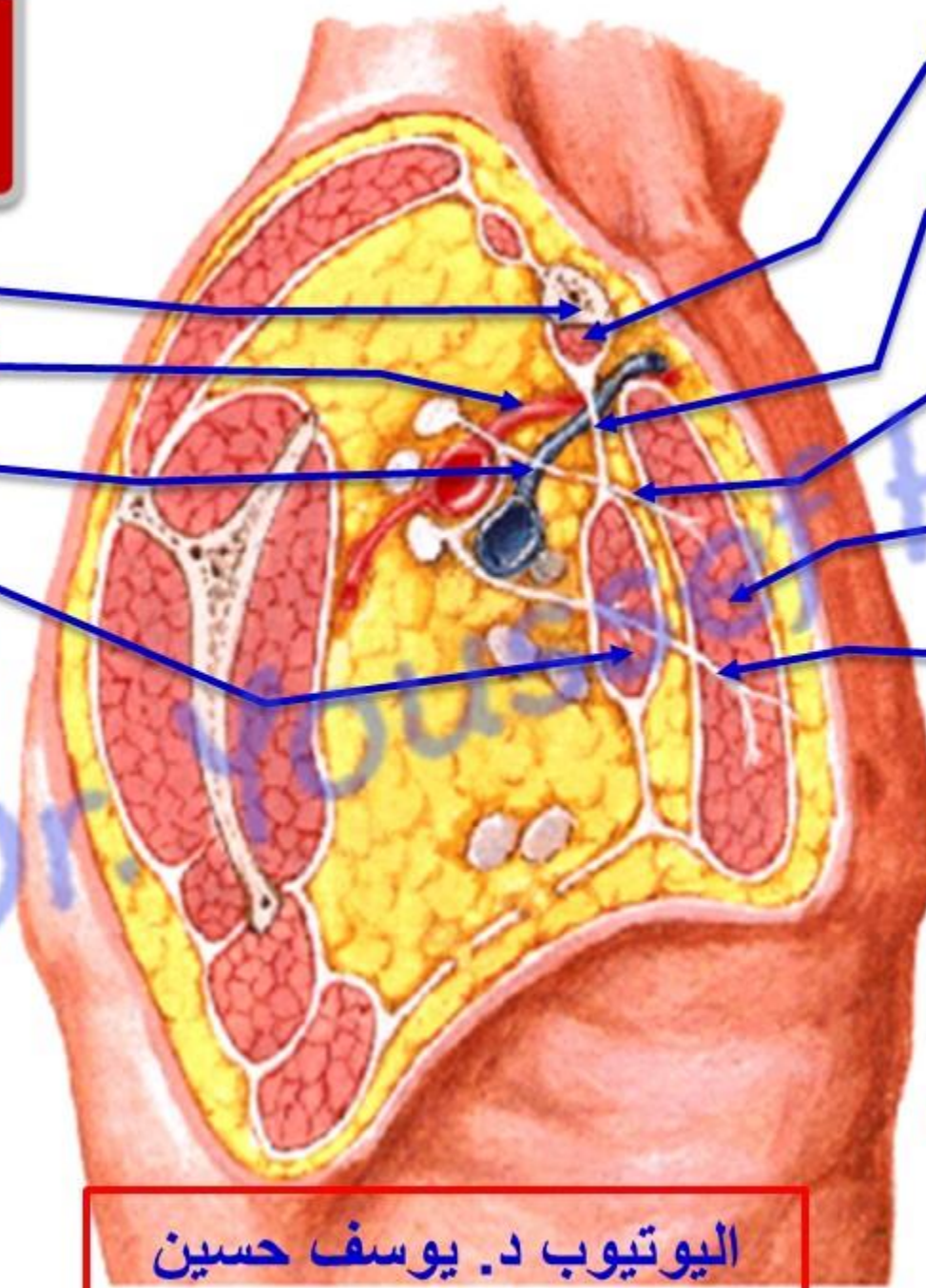
Subclavius muscle

Clavipectoral fascia

Lateral pectoral nerve

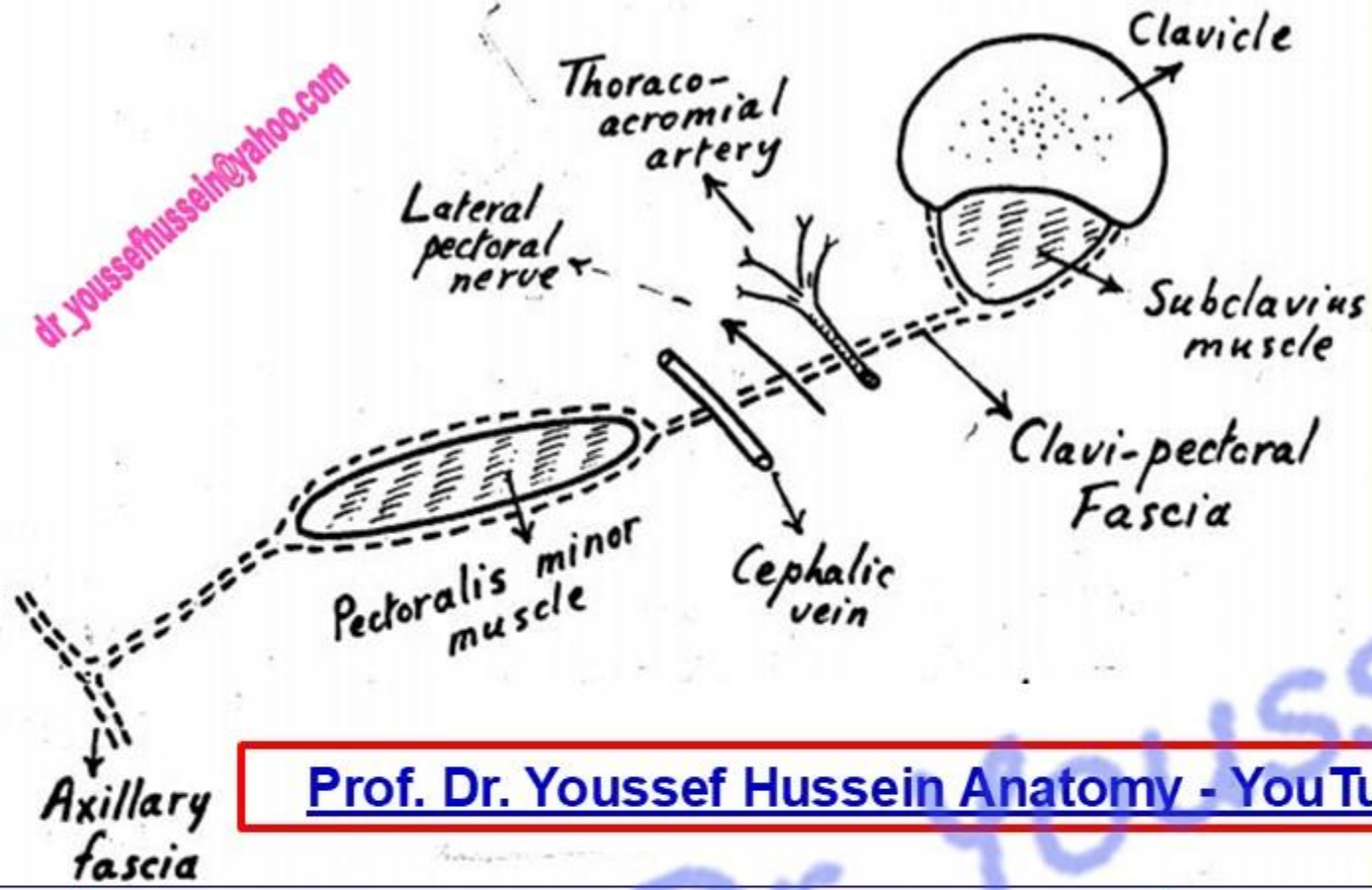
Pectoralis major

Medial pectoral nerve

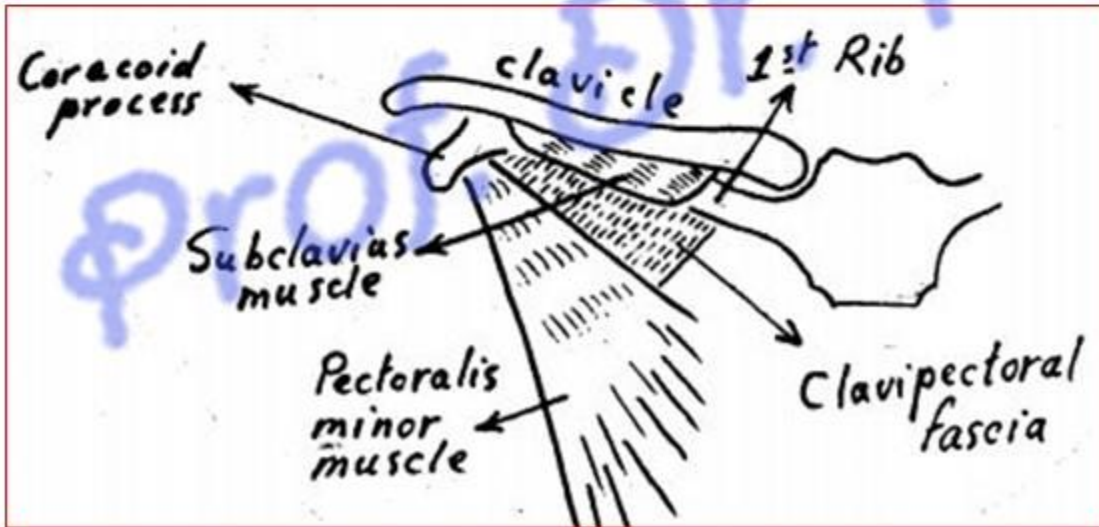


dr_youssefhusein@yahoo.com

اليوثيوب د. يوسف حسين



Prof. Dr. Youssef Hussein Anatomy - YouTube



• Clavipectoral Fascia

* Attachments:

1- Superiorly, it splits into two laminae which enclose subclavius and attached to the margins of subclavian groove.

2- Inferiorly, it splits to enclose pectoralis minor, then fuse together to form **suspensory ligament of the axilla**. It attaches to the axillary fascia.

3- Medially, the first rib.

4- Laterally, the coracoid process.

• The structures pierced the fascia

a) Cephalic Vein.

b) Thoraco-acromial Artery.

c) Lateral pectoral Nerve.

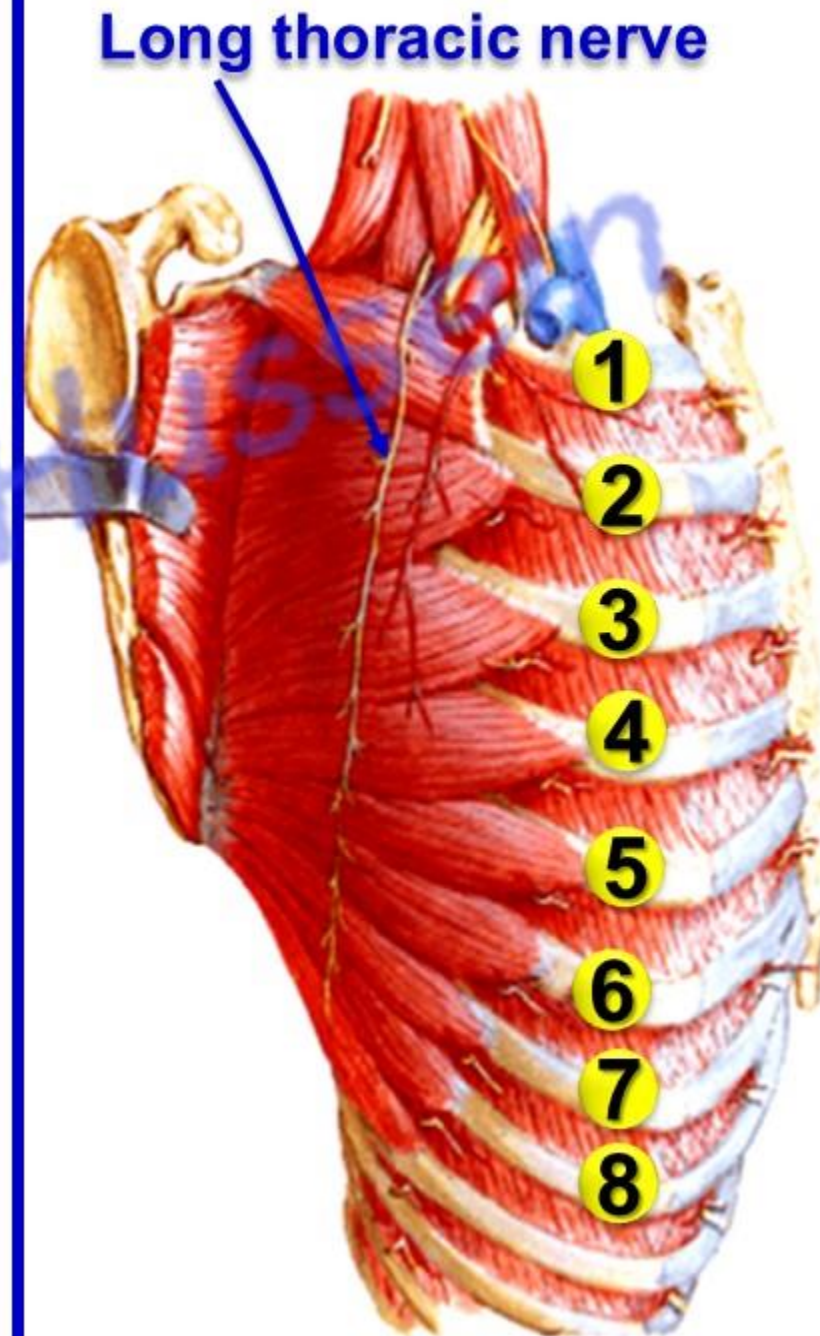
d) Lymphatics vessels.

Serratus anterior

اليوطيوب د. يوسف حسين

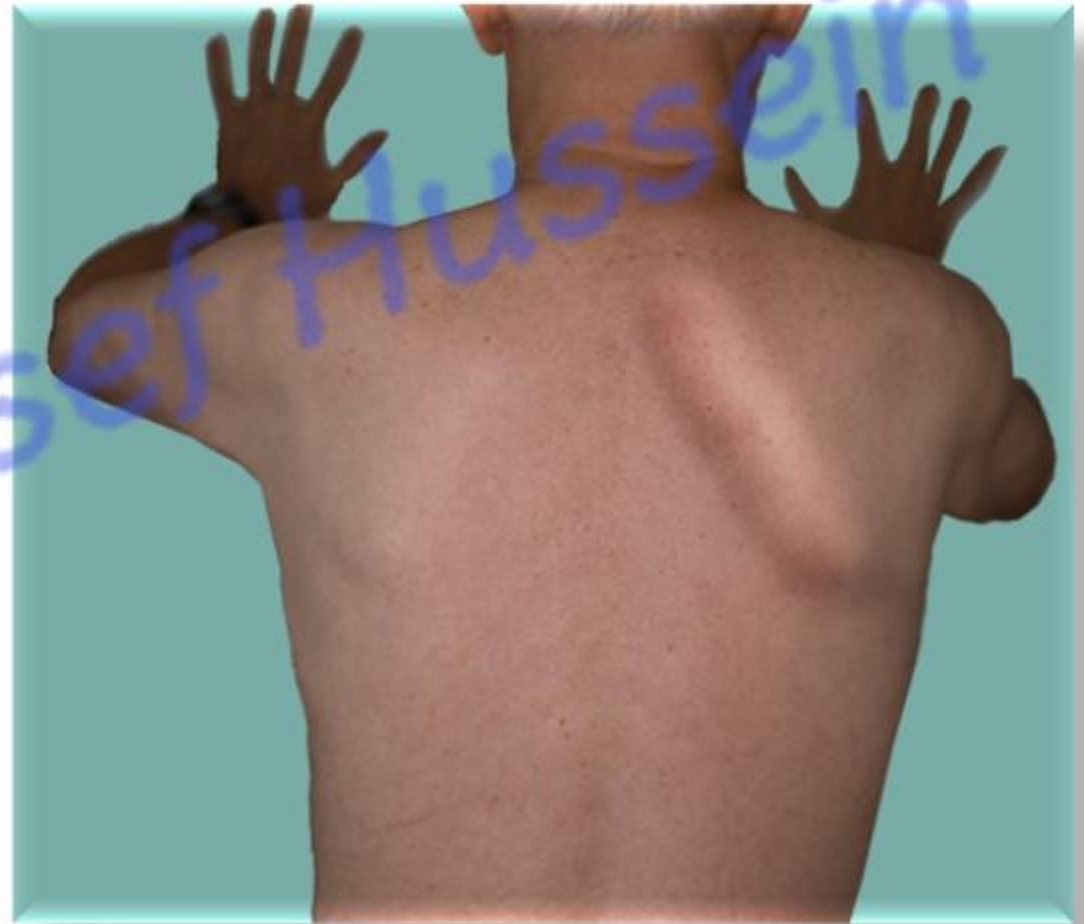• Serratus Anterior Muscle

- * **Origin;** by fleshy digitations from the **upper** eight ribs.
 - The first digitation takes origin from the 1st and 2nd ribs.
- * **Insertion:** anterior surface of the medial border of the scapula.
 - The first digitation:** anterior surface of the superior angle.
 - The 2nd and 3rd digitations:** anterior surface of medial border.
 - The lower five digitations:** anterior surface of inferior angle.
- * **Nerve supply:** long thoracic nerve (**nerve of Bill C5, 6, &7**) passes superficial to the muscle.
- * **Actions:** [Prof. Dr. Youssef Hussein Anatomy - YouTube](#)
 - 1- Protraction of the scapula** (pulls the scapula forward with pectoralis minor).
 - 2- Lower 5 digitations, **Abduction of the arm above 90 degree**, acting with the trapezius muscle.
 - 3- Fixation of the scapula** during movement of the upper limb.



*“ Injury of the long thoracic nerve


- It descends in the midaxillary line **on the superficial surface** of the muscle.
- **Winging of the scapula”** due to paralysis of the muscle
- A protrusion of the medial border of the scapula away from the posterior chest wall.
- **Test of the muscle**; ask the patient to push the wall with the outstretched hand. If the muscle is affected the winging is increased.



https://www.youtube.com/channel/UCVSNqbibj9UWYaJdd_cn0PQ

يُمنع أخذ السلايدات بدون
إذن المحرر واي اجراء
يخالف ذلك يقع تحت
طائلة المسؤولية القانونية

اليوتيوب د. يوسف حسين



Questions

<https://www.youtube.com/@ProfDrYoussefHusseinAnatomy/playlists>