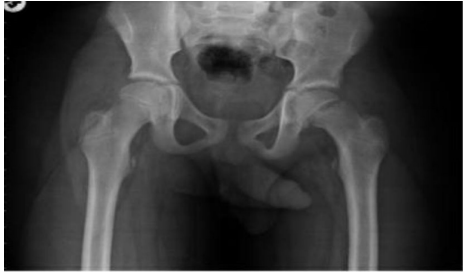

Diagnosis ?

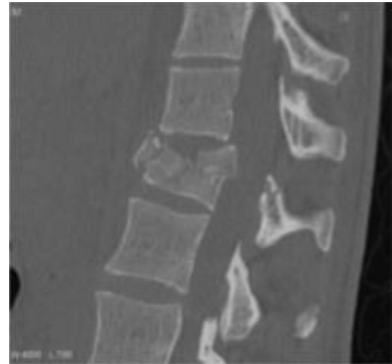
A. SCFE

B. Perthes



2- diagnosis ?

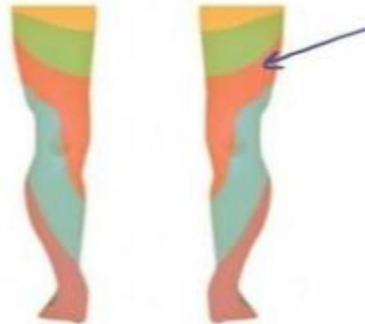
Burst fracture



3- One of the following jerks is related to an injury of the dermatome indicated by the arrow?

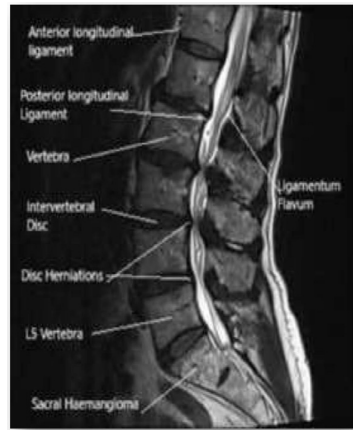A- knee jerk

B- ankle jerk



4- A case of patient had lumbar canal stenosis (this information was not written in the question), according to difference between vascular and neurological claudication choose the true answer

a. Downhill more painful ✓

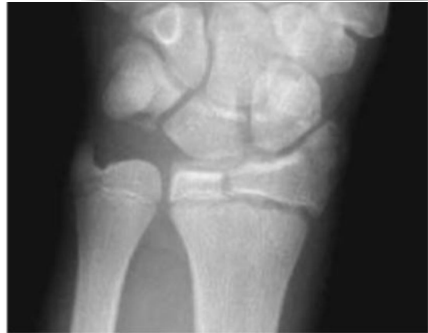

5- Salter harris
Classification:

A. Type 1

B. Type 2

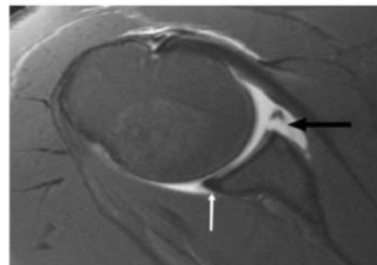
C. Type 3 ✓



6-

A. anterior inferior glenoid labrum injury , Bankart leasion

✓

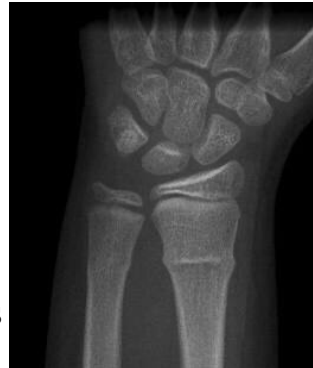

7- what is the treatment ?

A- cast below the elbow ✓

B- cast above the elbow

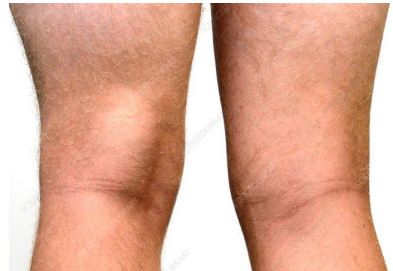C- reduction



8- All of the following can cause this except :

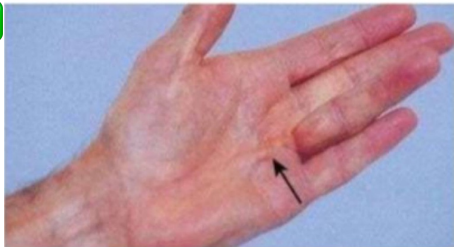
a. - clergyman bursa ✓

B- baker cyst



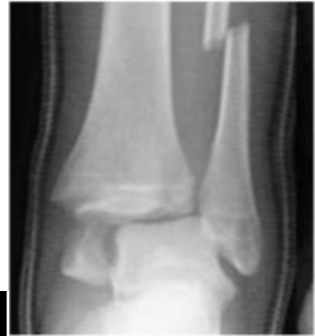9- your diagnosis?

Dupuytren's contracture ✓



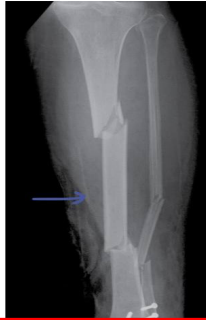10- Cause of this fracture , and what is the type ?

- A- eversion , Weber classification
- B- inversion , Weber classification



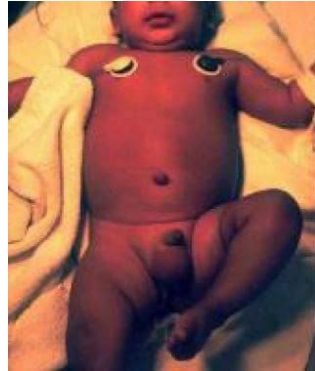11- dx ?

Segmental fracture



12- Child came to the ER with his parents complaining of hip pain since 24 hours, he is stable , he has slightly high temperature, wbc:120000,ESR:80 , what is the first thing you will do?

- a-NSAIDs
- b- antibiotic
- c-admission and observation
- d- arthrotomy and wash out
- e-analgesia



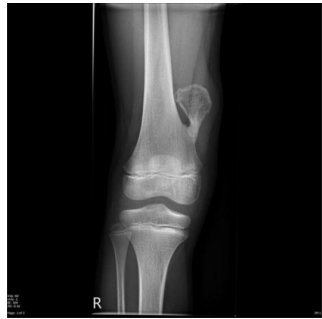13- All these muscles contributes to foot dorsiflexion except:

- a. peroneus tertus
- b. Tibialis anterior
- c. plantaris ✓
- d. extensor hallucis
- e. extensor digitorum profundus



14- Dx ?

Osteochondroma ✓

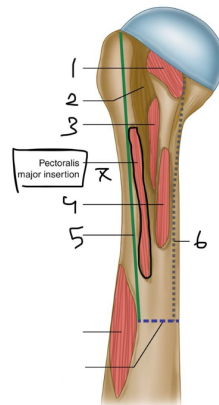


15- name the muscle insertion in 7 ?

A- Deltoid

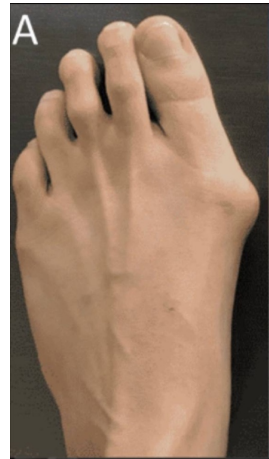
B- pectoralis major ✓

C- lattismus Dorsi



16- all true except ?

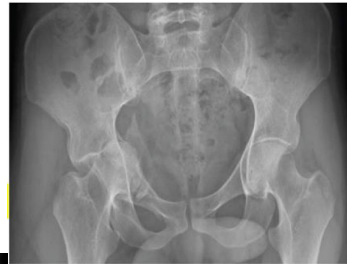1st metatarsal is in valgus position ✓



17- All of these are late complications except

a. sciatic nerve injury ✓

b. Necrosis



18- Which of these symptoms won't be associated with this picture ?

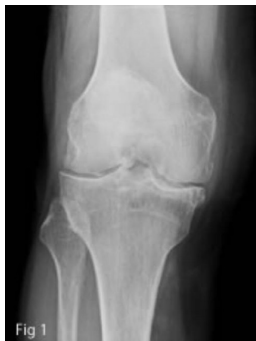A- Genu valgus



B- crepitation

C- knee swelling


D- pain



19- what is the cause of this positive test ?

A- injury in medial side of forearm

B- flexor tendon injury



20- Which of the following is false ?

A- Its insert to medial cuneiform and second metatarsal bone 2

B- cause foot dorsiflexion

C- supplied by deep fibular nerve

D- originate from Lateral tibial condyle , Superior two thirds of the lateral surface of tibia , Anterior surface of interosseous membrane , Deep surface of deep fascia of the leg , Anterior intermuscular septum.

