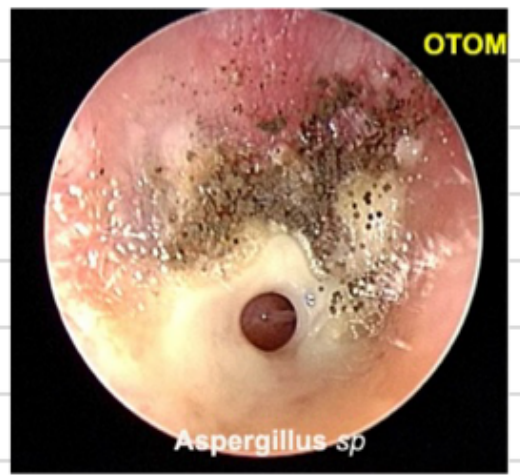

ear fungal infection.

- Diagnosis: ↗

→ Treatment: suction + topical anti fungal

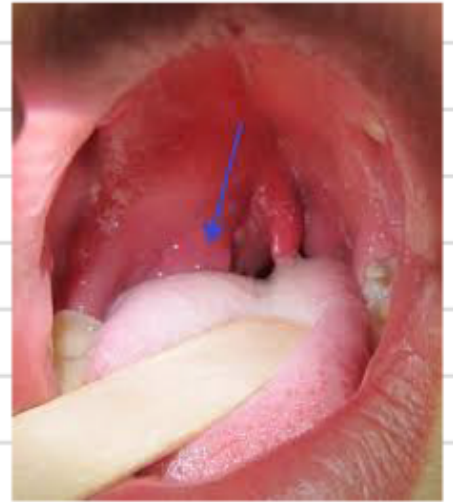

Dx: Quinsy ↗

* if patient presented with trismus, Tx:

Incision w/ drainage orally.

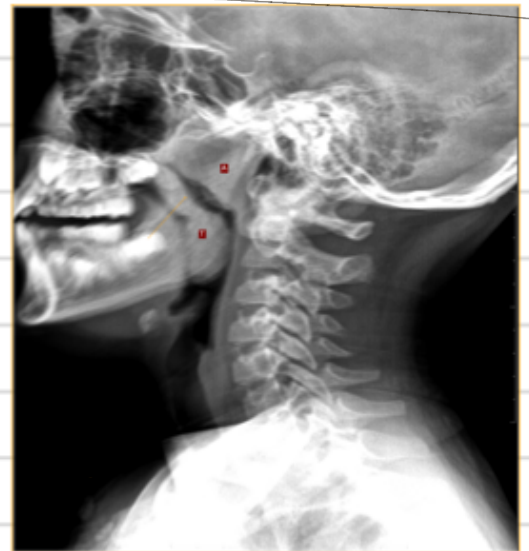age not mentioned.



* Dx: Adenoid hypertrophy.

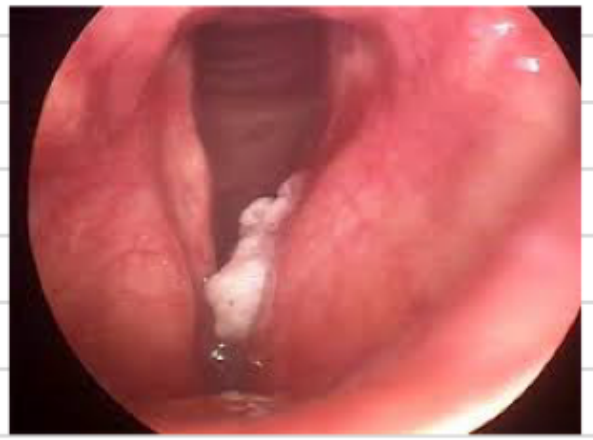* Tx: Adenoidectomy.

* Contraindication for surgery: Down syndrome.



* Staging if the tumor is deemed fixation?

T₃



* Next step: Direct laryngoscopy.

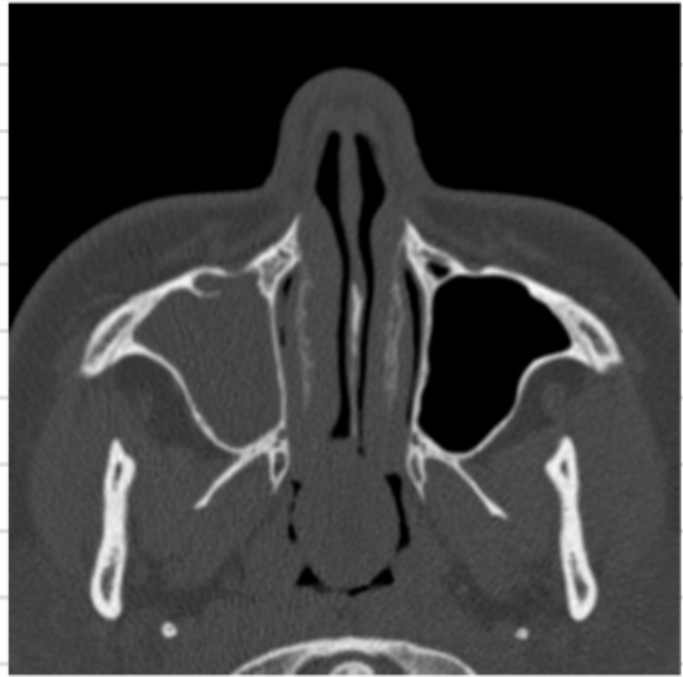1) which wrong about it?

- left maxillary and ethmoid

sinuses are not affected.

- straight nasal septum.

من قنطرة باق كيارات.



2) treatment?

FESS w/ polypectomy.

3)

1) Dx:

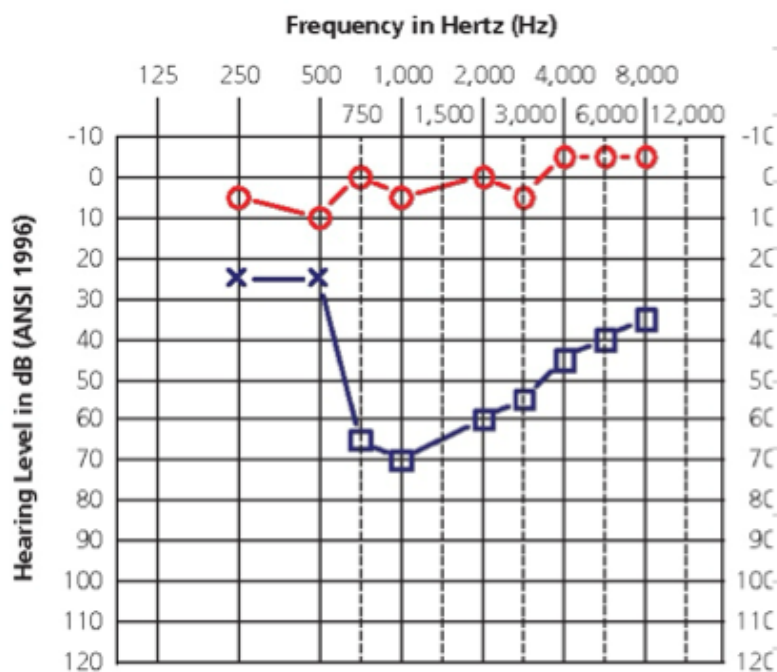
* left SNHL

2) on tympanometry?:

Right is A.

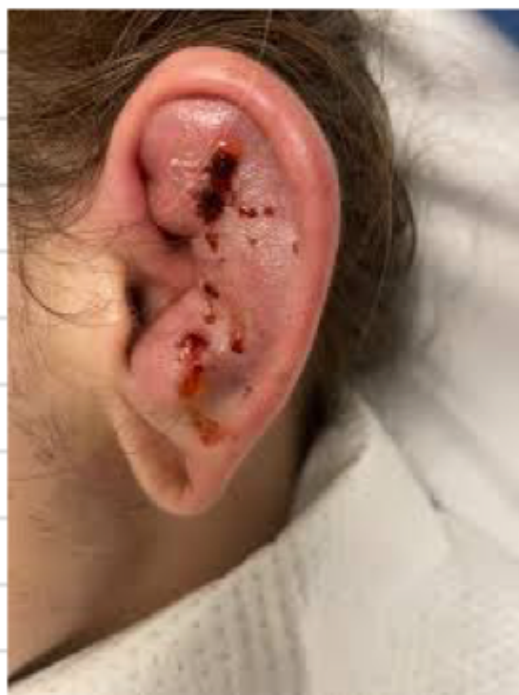3) one statement is right?

* MRI for CPA is mandatory.



* not DDx: Otitis Media.

* treatment: incision and compression.



* Next step?

Biopsy.

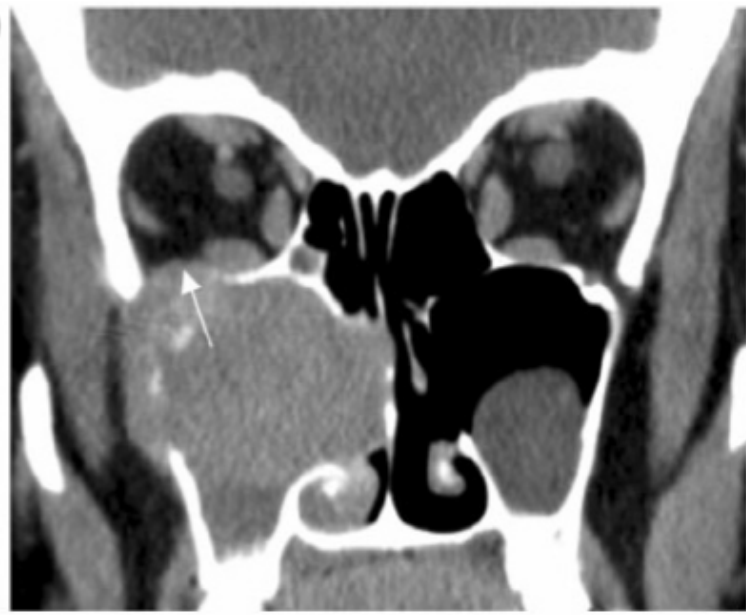* all of the following are
evidence except:

- Bone erosion

- soft tissues are reliable in this modality.

- The lesion could bleed if touched with
endoscope.

(a)



* one of the following is not related
to central vertigo:

- Bidirectional nystagmus.

- horizontal and rotational nystagmus after
the head is held down for 30 seconds.

- immediate nystagmus when the head is pulled down.

- nystagmus with same amplitude every time the maneuver is done.

- Nausea and vomiting.

