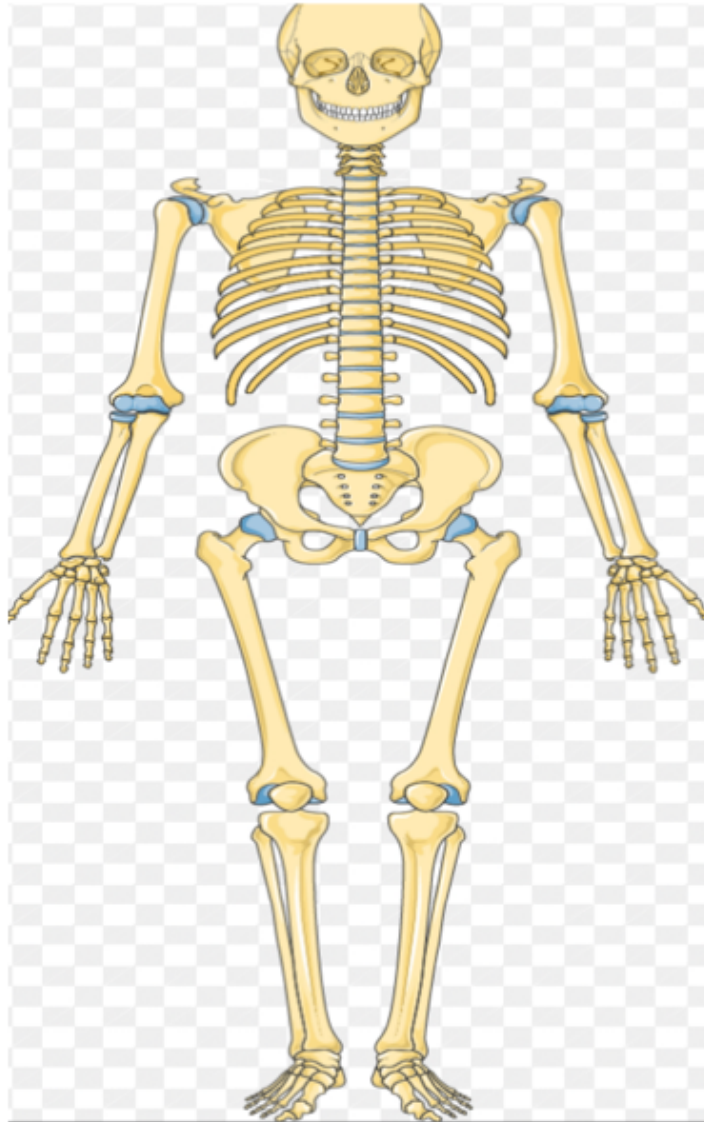


# Worksheet in Anatomy



Faculty of dentistry

Mutah University

Prepared by: Mohammad Alsardi & Mohammad Ramadan

1-Bones are classified into long bones if they are present

*a- proximal end*

*b-distal end*

*c-Shaft*

*d- All of these*

2-The metacarpals and phalanges are classified into:

a-long bones

b-short bones

c-irregular bones

d-flat bones

3-The largest sesamoid bone is :

a-pisiform

b-ribs

c-patella

d- sternum

4-how many bones in the one upper limb

A- 31

B-32

C- 30

D- 33

5– the bone that lies between shoulder joint and elbow joint is:

A– femur

B– humerus

C– tibia

D. – radius

6– how many bones in the arm?

A– one

B – two

C – three

D – four

7 – what's the part that lies between Elbow joint and wrist joint

A – arm

B – forearm

C – scapula

D – hand

8-what's the part in the scapula that separates supraspinous fossa from infraspinous fossa ?

A – spine

B – coracoid

C. – acromion

D. – subscapular fossa

9– the subscapular fossa lies in?

A – interior surface

B – posterior surface

10 – the longest bone in the body is

A – humerus

B. – femur

C– ulna

D – radius

11– the part that lies in the lateral of scapular and articulate with head of humerus is?

A– wrist joint

B. – supraspinous fossa

C – glenoid cavity

D. – elbow joint

12 – the surgical neck contains nerves and arteries

A– True

B – false

Answers :

1-D.                    8-a

2-a.                    9-a

3-c.                    10-b

4-b.                    11. C

5-b.                    12-true

6-a

7-b

### Worksheet (anatomy)

- 1) Which of the following bones belongs to the appendicular skeleton?
  - a) Sternum
  - b) Vertebrae
  - c) Scapula
  - d) Skull
- 2) The insertion of the Brachioradialis is located in the ?
  - a) Sternum
  - b) Mastoid
  - c) Radius
  - d) Clavicle
- 3) Skeletal muscle are supplied by the ?
  - a) Autonomic nervous system
  - b) Somatic nervous systems
- 4) Which of the following has one tendon ,with fibrous coming from one direction ?
  - a) Fusiform
  - b) Unipennate
  - c) Bipennate
  - d) Multipeannate
- 5) Pollicis represent the ?
  - a) Palm
  - b) Wrist
  - c) Thumb
  - d) Forarm

### Answers :-

1)c

2)c

3)b

4)b

5)c