

TRIANGLES OF THE NECK
{Anterior triangle of the neck}

Dr. Aiman Qais Afar
Surgical Anatomist

College of Medicine / University of Mutah
2nd Year (MSS)
2nd Semester 2024 - 2025

Sunday 9 March 2025

Muscles of the Neck

Dr. Aiman Al Maathidy
Sunday 9 March 2025

2

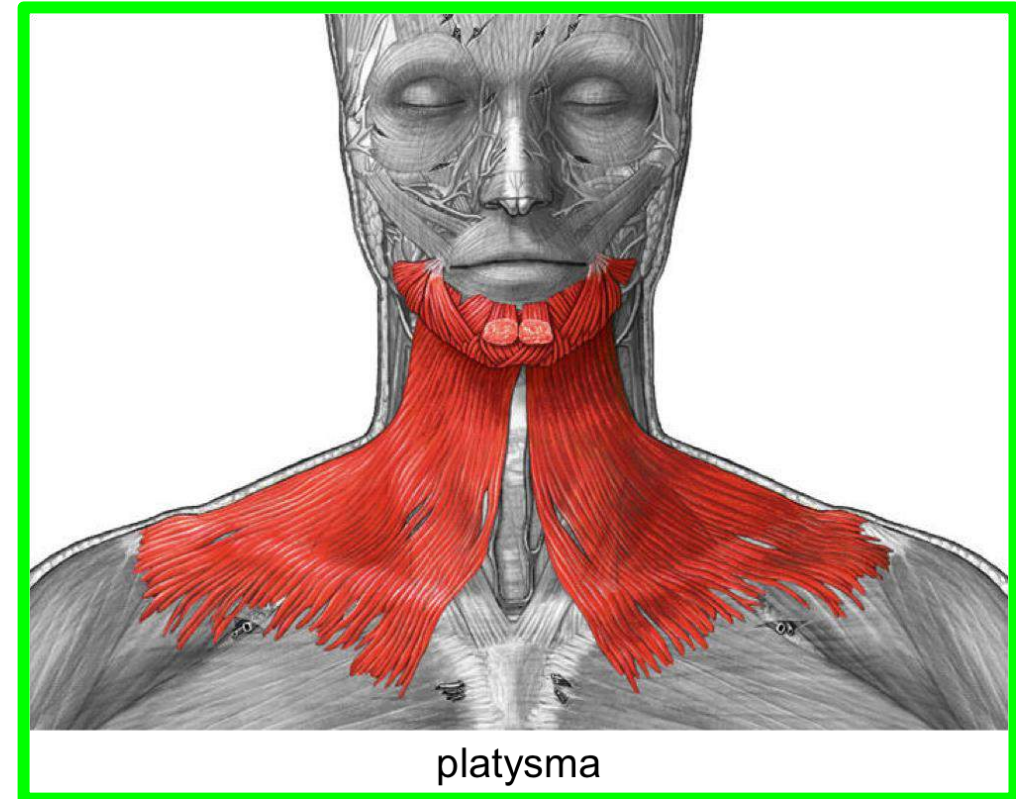
Muscle: Platysma

Origin: Deep fascia over pectoralis major and deltoid

Insertion: Body of mandible and angle of mouth

N. Supply: Facial nerve; cervical branch

Action: Depresses mandible and angle of mouth



Muscles of the Neck

Dr. Aiman Al Maathidy
Sunday 9 March 2025

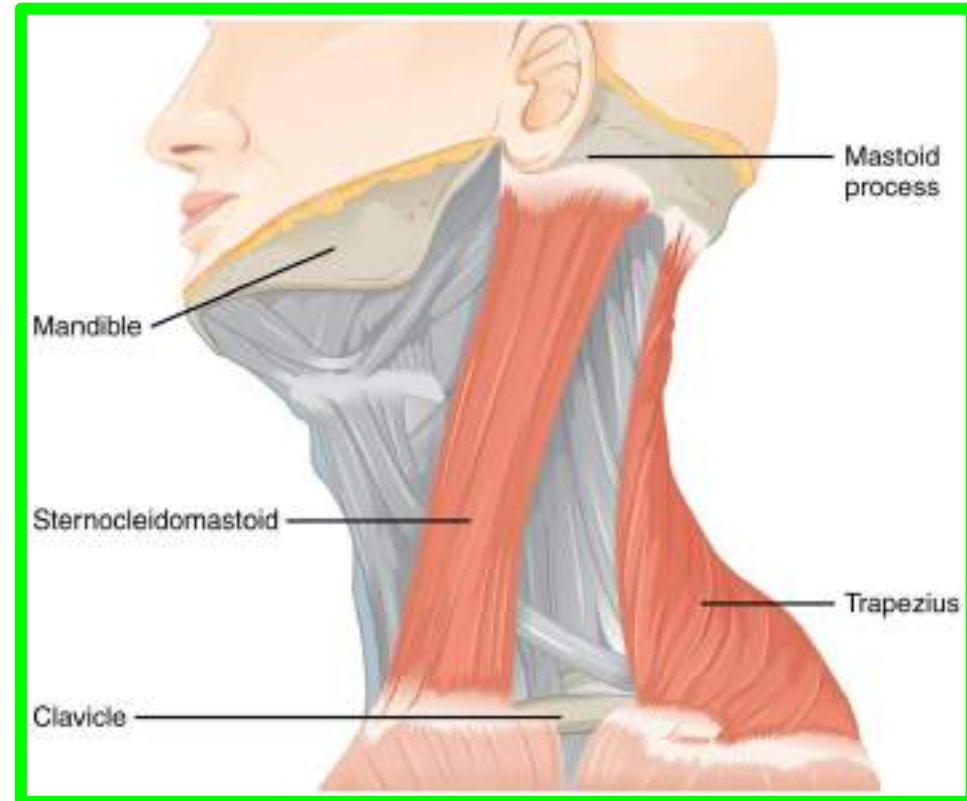
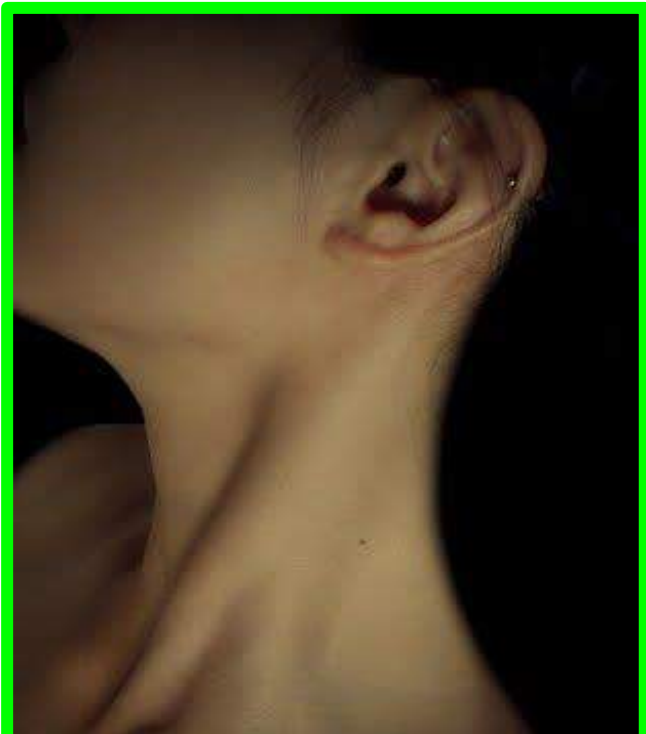Muscle: Sternocleidomastoid

Origin: Manubrium sterni and medial third of clavicle

Insertion: Mastoid process of temporal bone and occipital bone

N. Supply: Spinal part of **accessory nerve** and **C2 and 3**

Action: Two muscles acting together **extend head and flex neck**; one muscle **rotates head to opposite side.**



Suprahyoid Muscles

Muscle: Digastric

Posterior belly

Origin: Mastoid process of temporal bone

Insertion: Intermediate tendon is held to hyoid by fascial sling

N. Supply: Facial nerve

Action: Depresses mandible or elevates hyoid bone

Anterior belly

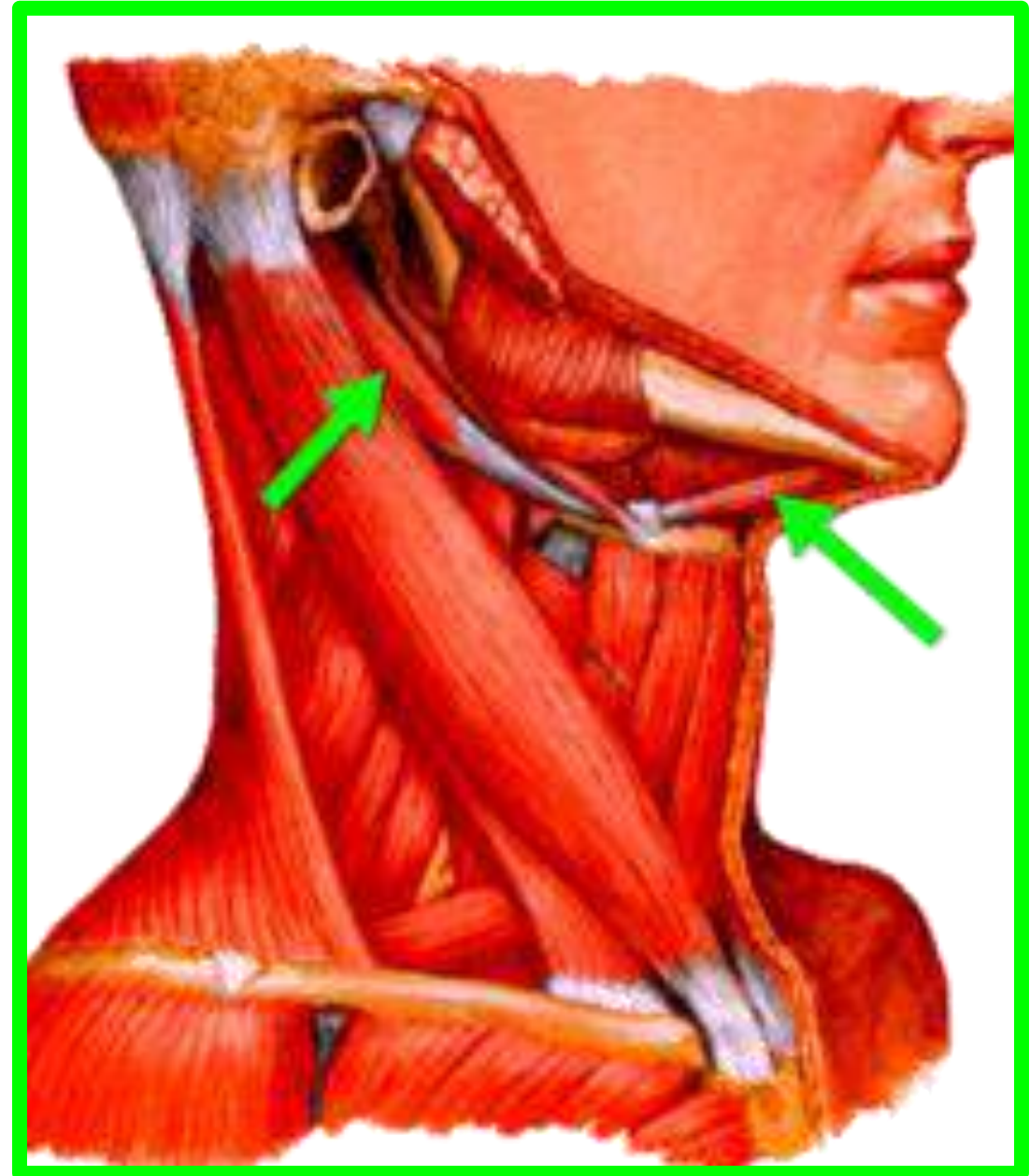
Origin: Body of mandible

N. Supply: Nerve to mylohyoid

Sunday 9 March 2025

Dr. Aiman Al Maathidy

4



Suprahyoid Muscles

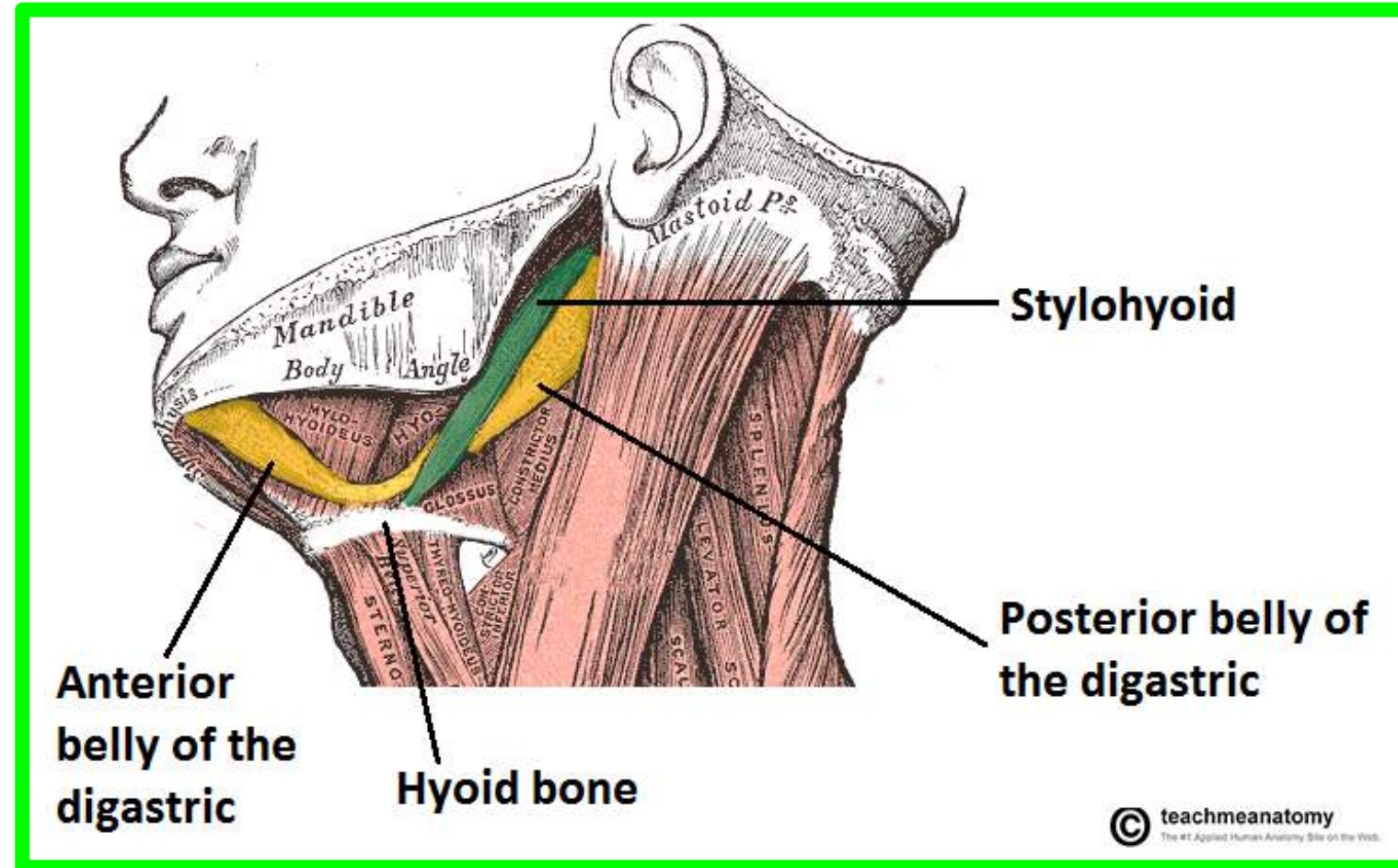
Muscle: Stylohyoid

Origin: Styloid process

Insertion: Body of hyoid bone

N. Supply: Facial nerve

Action: Elevates hyoid bone



Suprahyoid Muscles

Dr. Aiman Al Maathidy
Sunday 9 March 2025

6

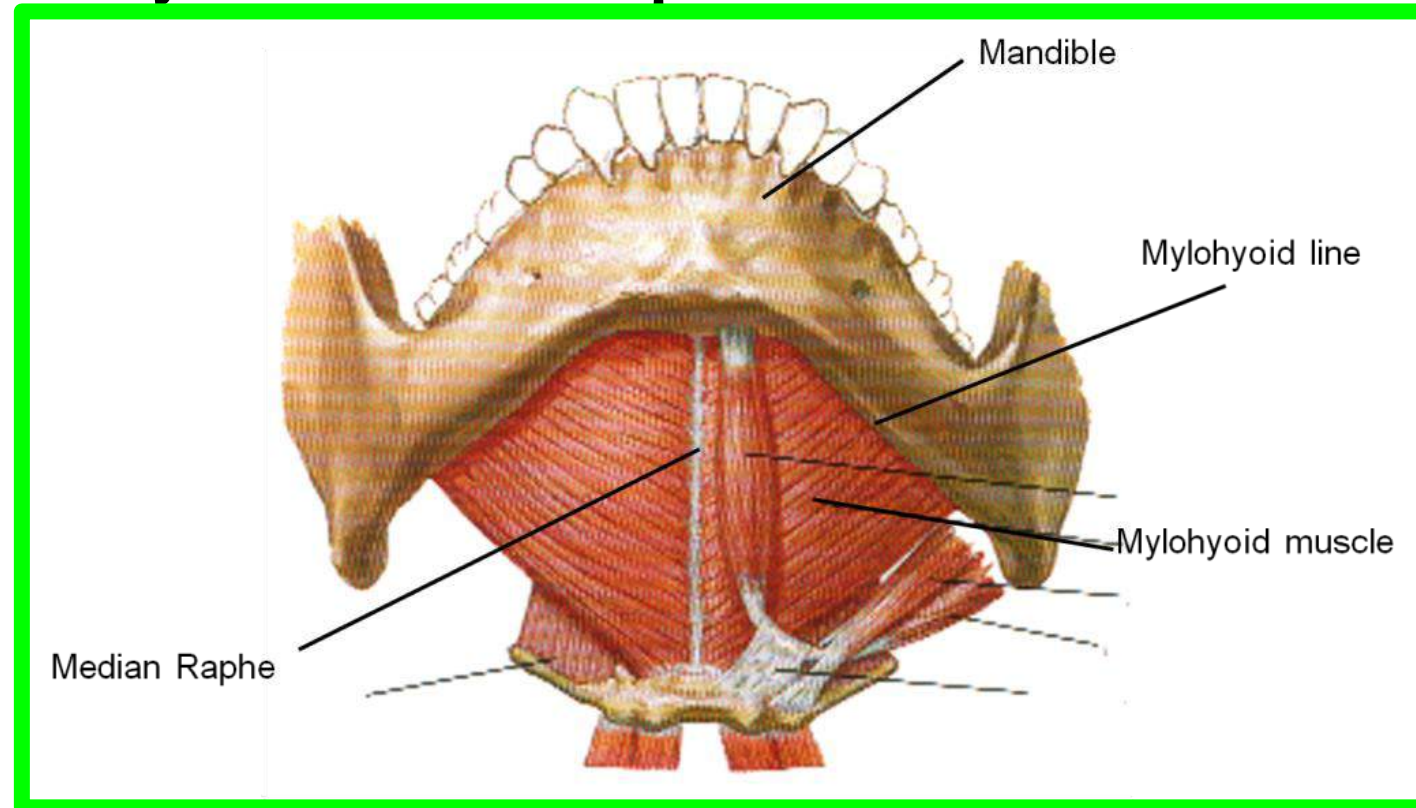
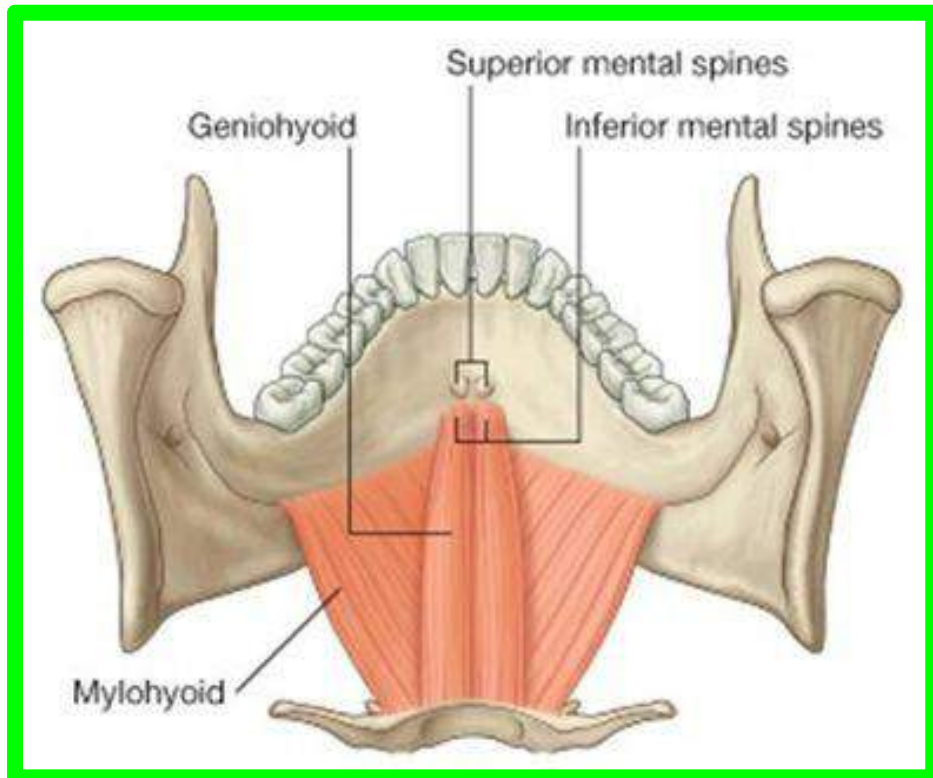
Muscle: Mylohyoid

Origin: Mylohyoid line of body of mandible

Insertion: Body of hyoid bone and fibrous raphe

N. Supply: Inferior alveolar nerve (Nerve to mylohyoid)

Action: Elevates floor of mouth and hyoid bone or depresses mandible



Suprahyoid Muscles

7

Dr. Aiman Al Maathidy
Sunday 9 March 2025

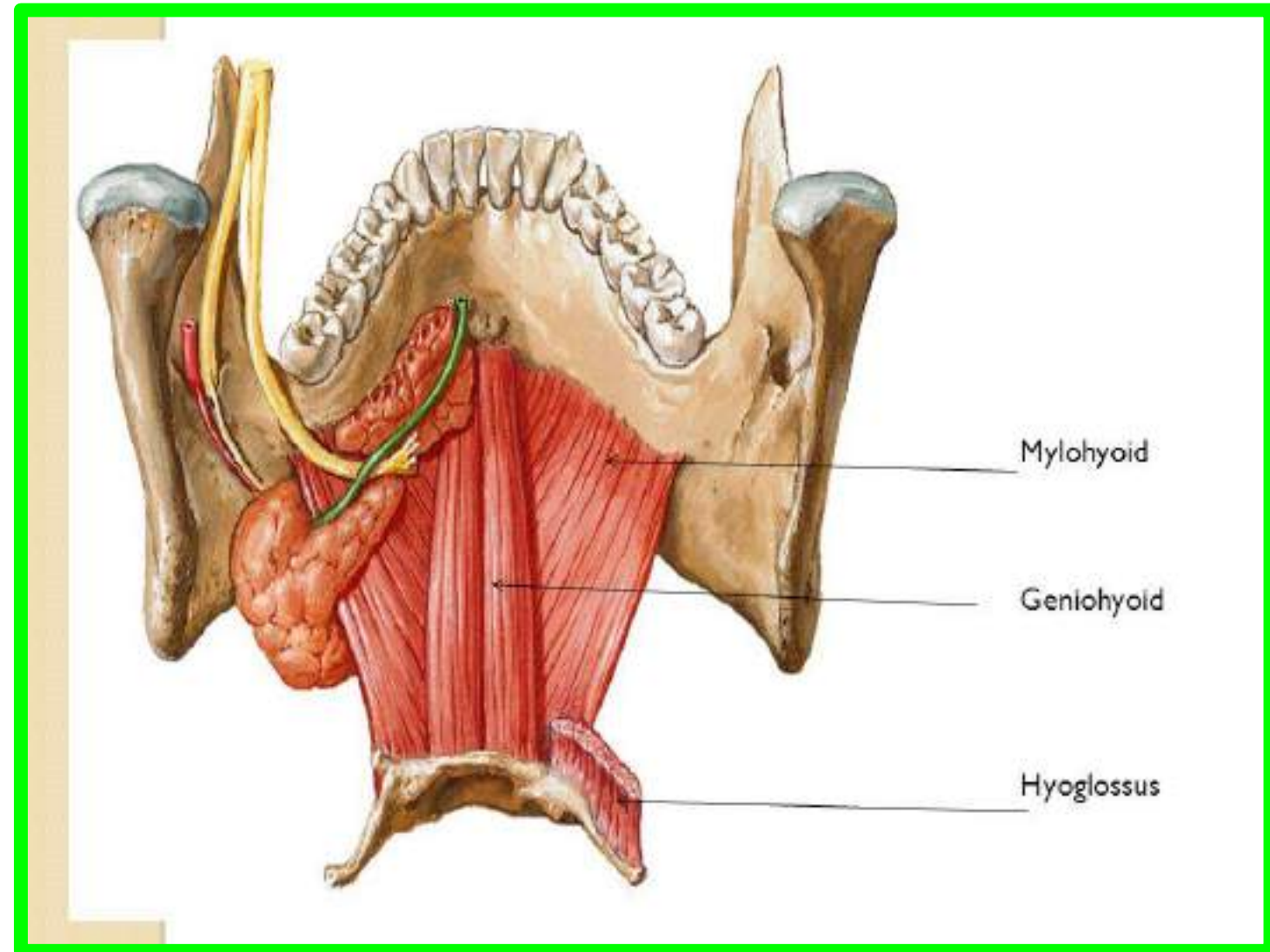
Muscle: Geniohyoid

Origin: Inferior mental spine
of mandible

Insertion: Body of hyoid bone

N. Supply: 1st cervical nerve

Action: Elevates hyoid bone
or depresses mandible



Infrahyoid Muscles

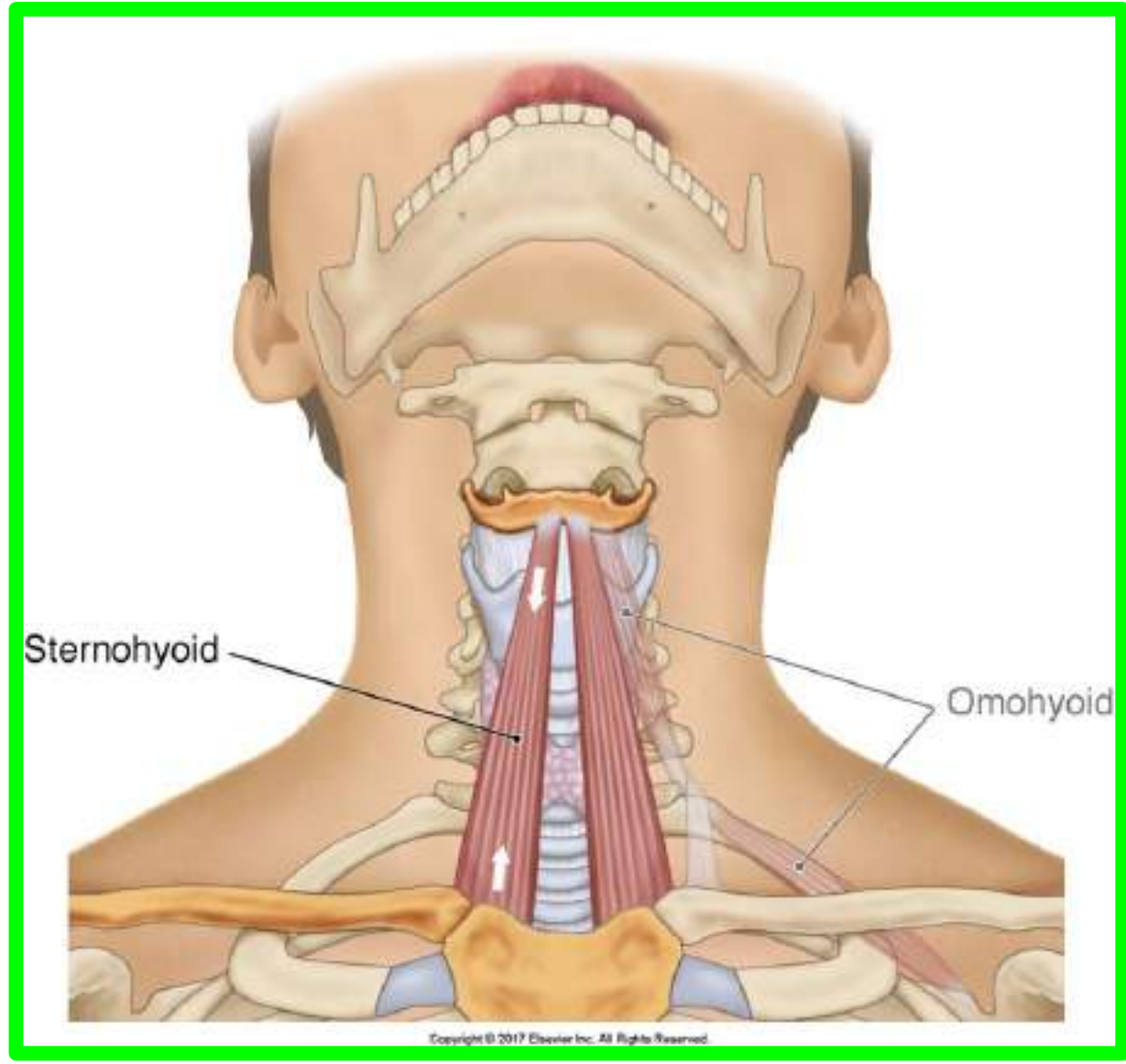
Muscle: Sternohyoid

Origin: Manubrium sterni and clavicle

Insertion: Body of hyoid bone

N. Supply: Ansa cervicalis; C1, 2, and 3

Action: Depresses hyoid bone



Infrahyoid Muscles

Muscle: Sternothyroid

Origin: Manubrium sterni

Insertion: Oblique line on lamina of thyroid cartilage

N. Supply: Ansa cervicalis; C1, 2, and 3

Action: Depresses larynx

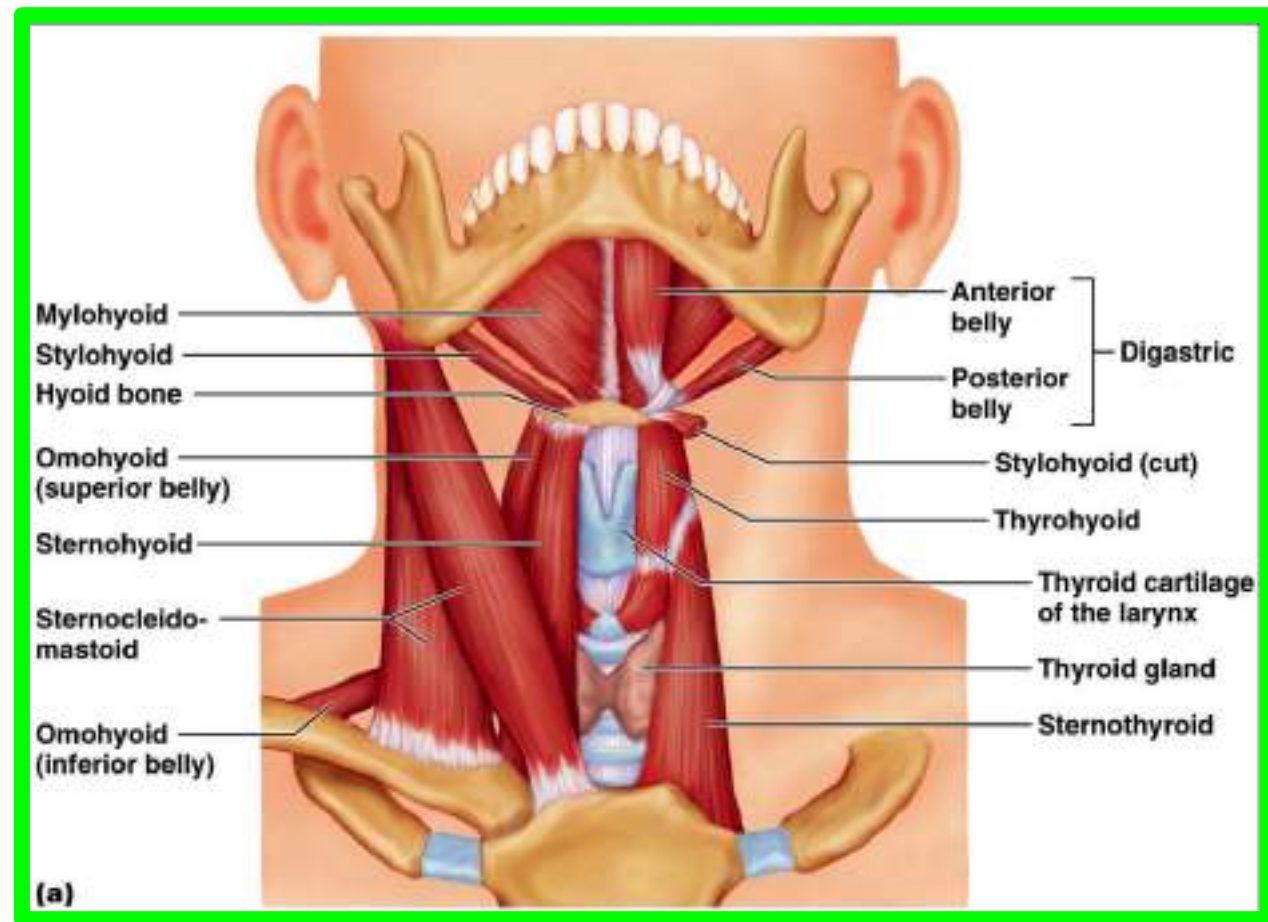
Muscle: Thyrohyoid

Origin: Oblique line on lamina of thyroid cartilage

Insertion: Lower border of body of hyoid bone

N. Supply: 1st cervical nerve

Action: Depresses hyoid bone or elevates larynx



Infrahyoid Muscles

Dr. Aiman Al Maathidy
Sunday 9 March 2025

Muscle: Omohyoid **Inferior belly**

Origin: Upper margin of scapula and suprascapular ligament

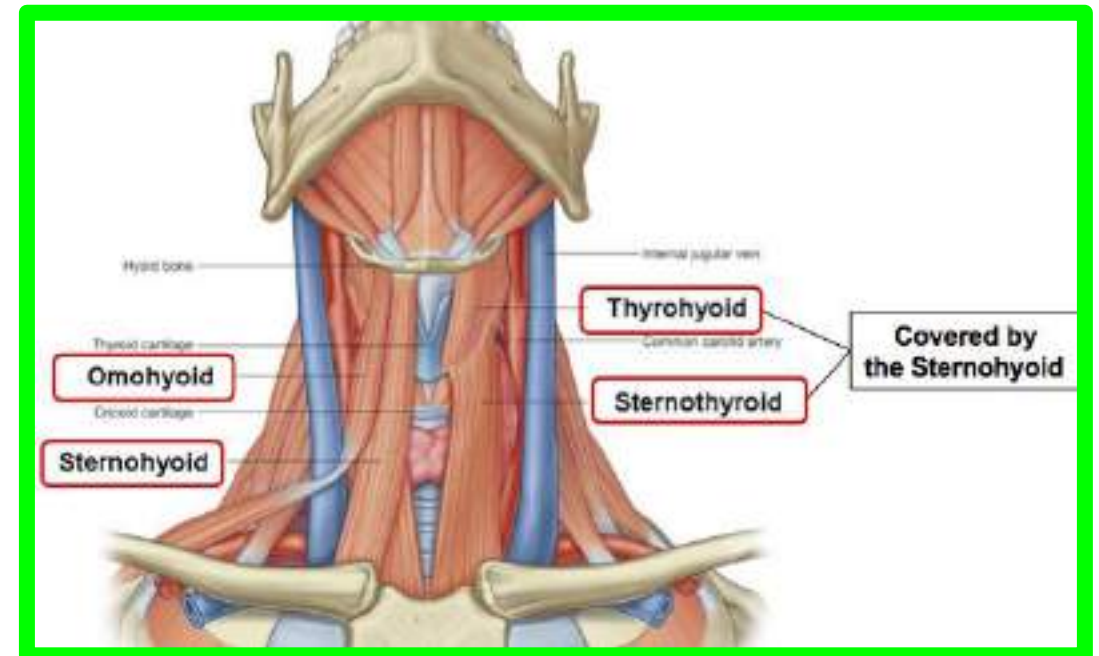
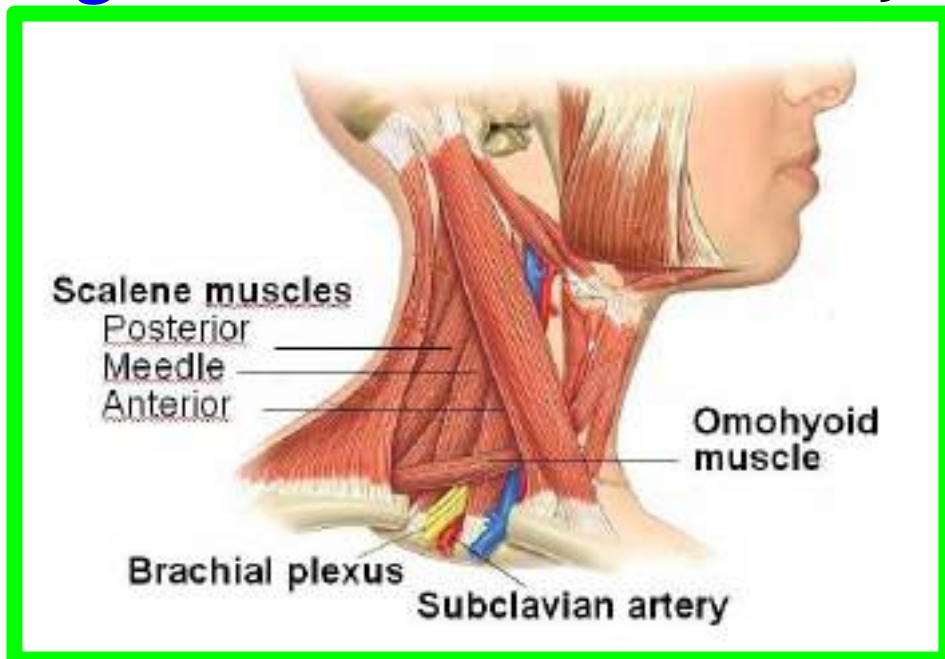
Insertion: Intermediate tendon is held to clavicle and first rib by fascial sling

N. Supply: **Ansa cervicalis; C1, 2, and 3**

Action: Depresses hyoid bone

Superior belly

Origin: Lower border of body of hyoid bone

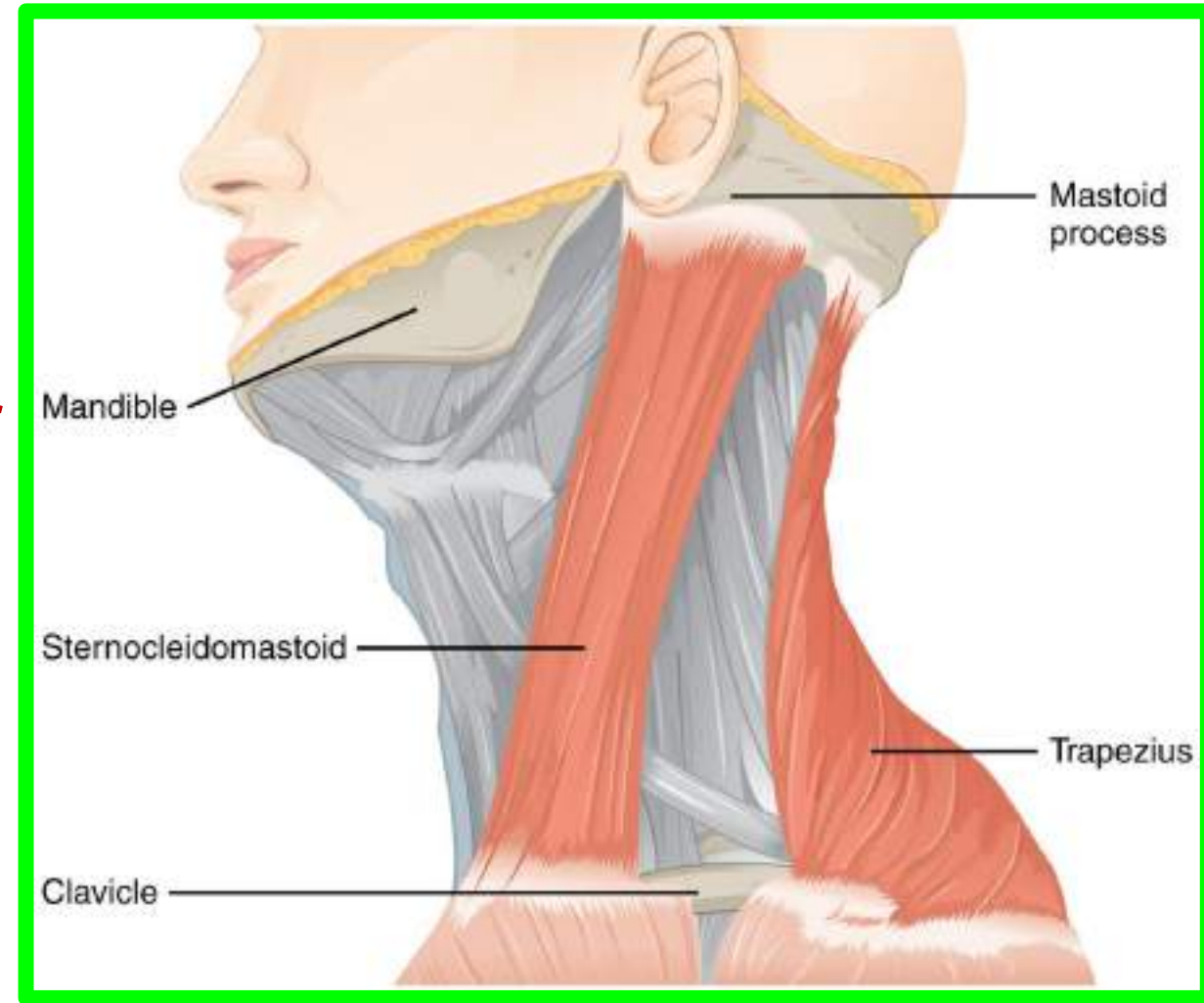


Sternocleidomastoid Region

✓ The sternocleidomastoid is a key muscular landmark in the neck because it visibly divides each side of the neck into the anterior and lateral cervical regions (**anterior and posterior triangles of the neck**)

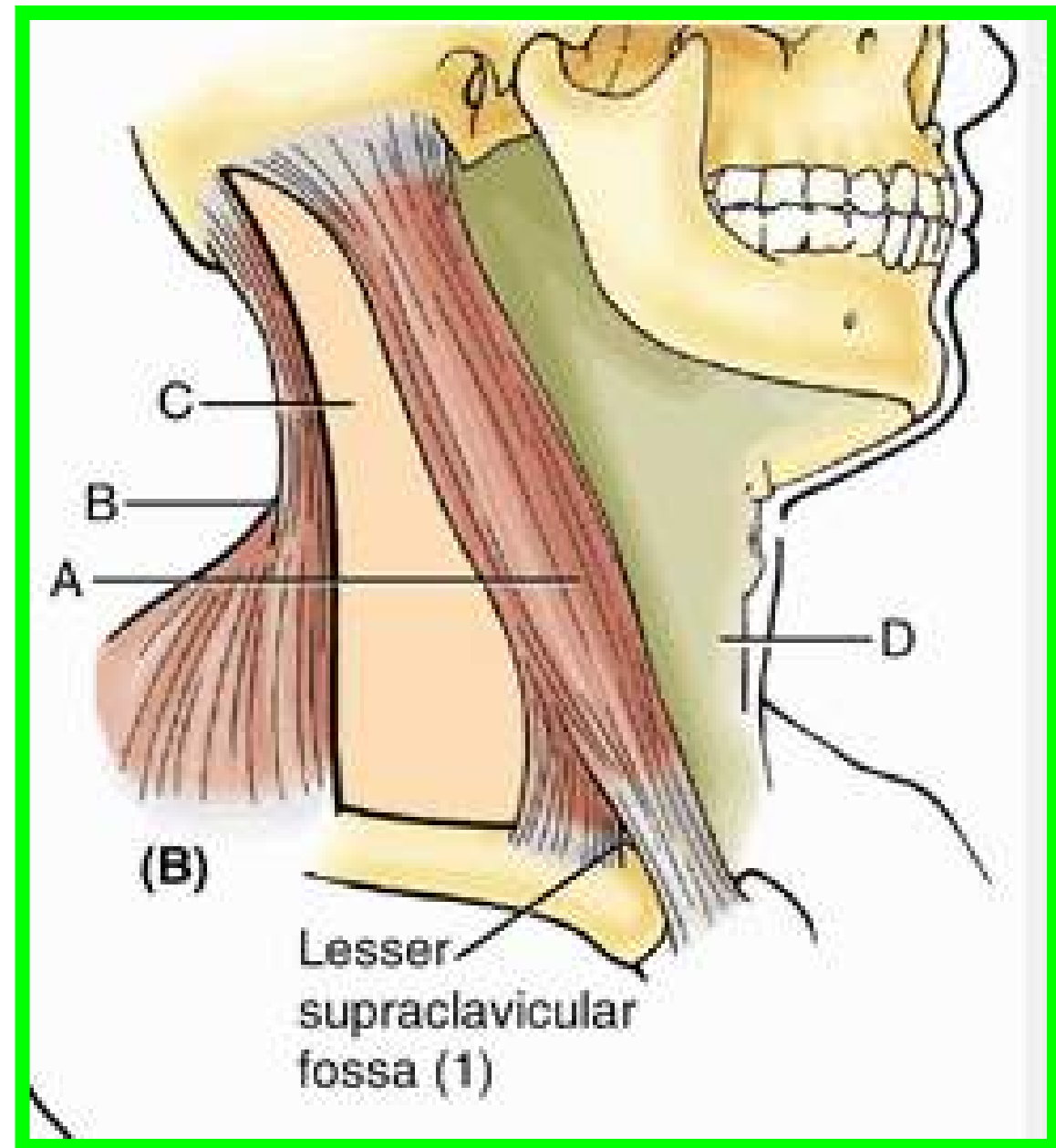
✓ The region between these triangular regions, corresponding to the area of this broad, strap-like muscle, is the **sternocleidomastoid region** of the neck.

✓ **The SCM** has two heads: the rounded tendon of the sternal head attaches to the manubrium, and the thick fleshy clavicular head attaches to the superior surface of the medial third of the clavicle



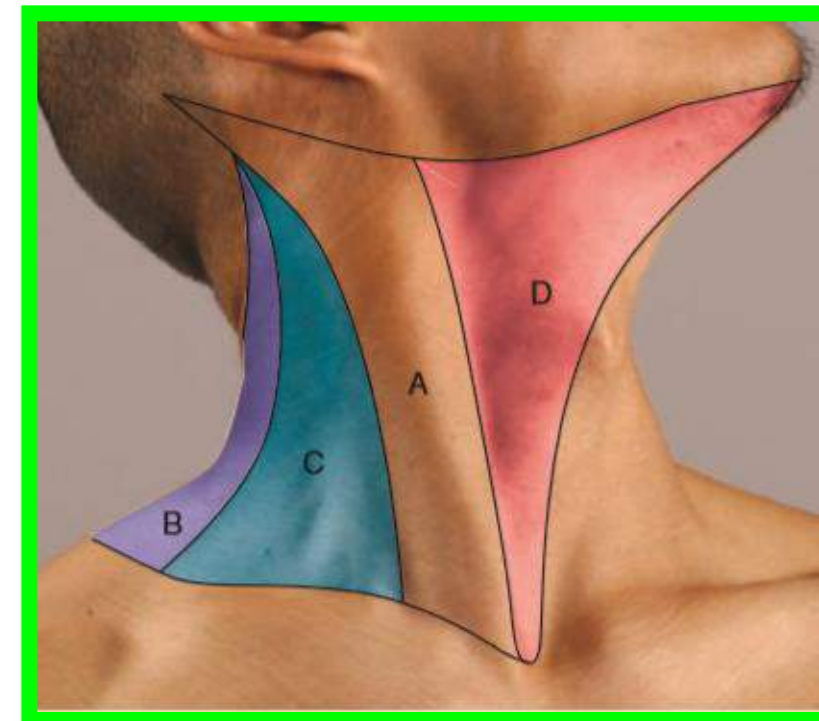
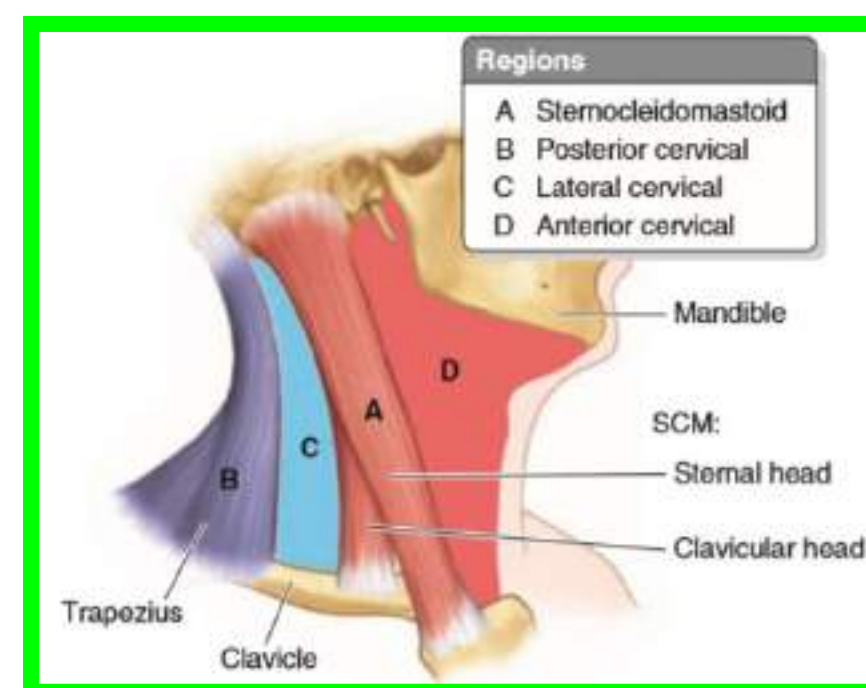
Sternocleidomastoid Region

- ✓ The two heads are separated inferiorly by a space, visible superficially as a small triangular depression, **the lesser supraclavicular fossa**.
- ✓ The heads join superiorly as they pass obliquely upward toward the cranium.
- ✓ The superior attachment of the SCM is **the mastoid process** of the temporal bone and **the superior nuchal line** of the occipital bone.
- ✓ The investing layer of deep cervical fascia splits to form a sheath for the SCM



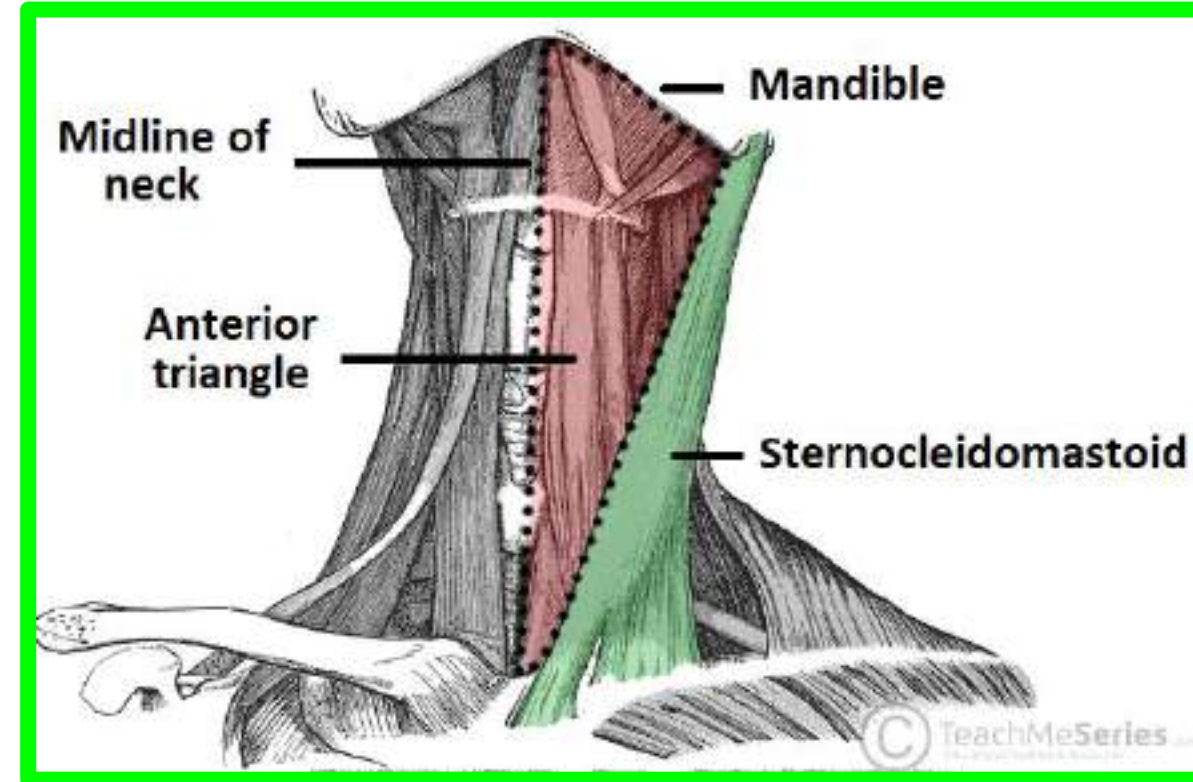
Posterior Cervical Region

- ✓ The region posterior to the anterior borders of the trapezius is the posterior cervical region
- ✓ The suboccipital region is deep to the superior part of this region
- ✓ The trapezius is a large, flat triangular muscle that covers the posterolateral aspect of the neck and thorax.
- ✓ The trapezius attaches the pectoral girdle to the cranium and the vertebral column and assists in suspending it.



Anterior triangle of the neck (Anterior Cervical Region)

- ❖ **An anterior boundary:** formed by the median line of the neck.
- ❖ **A posterior boundary:** formed by the anterior border of the SCM.
- ❖ **A superior boundary:** formed by the inferior border of the mandible.
- ❖ **An apex:** located at the jugular notch in the manubrium.

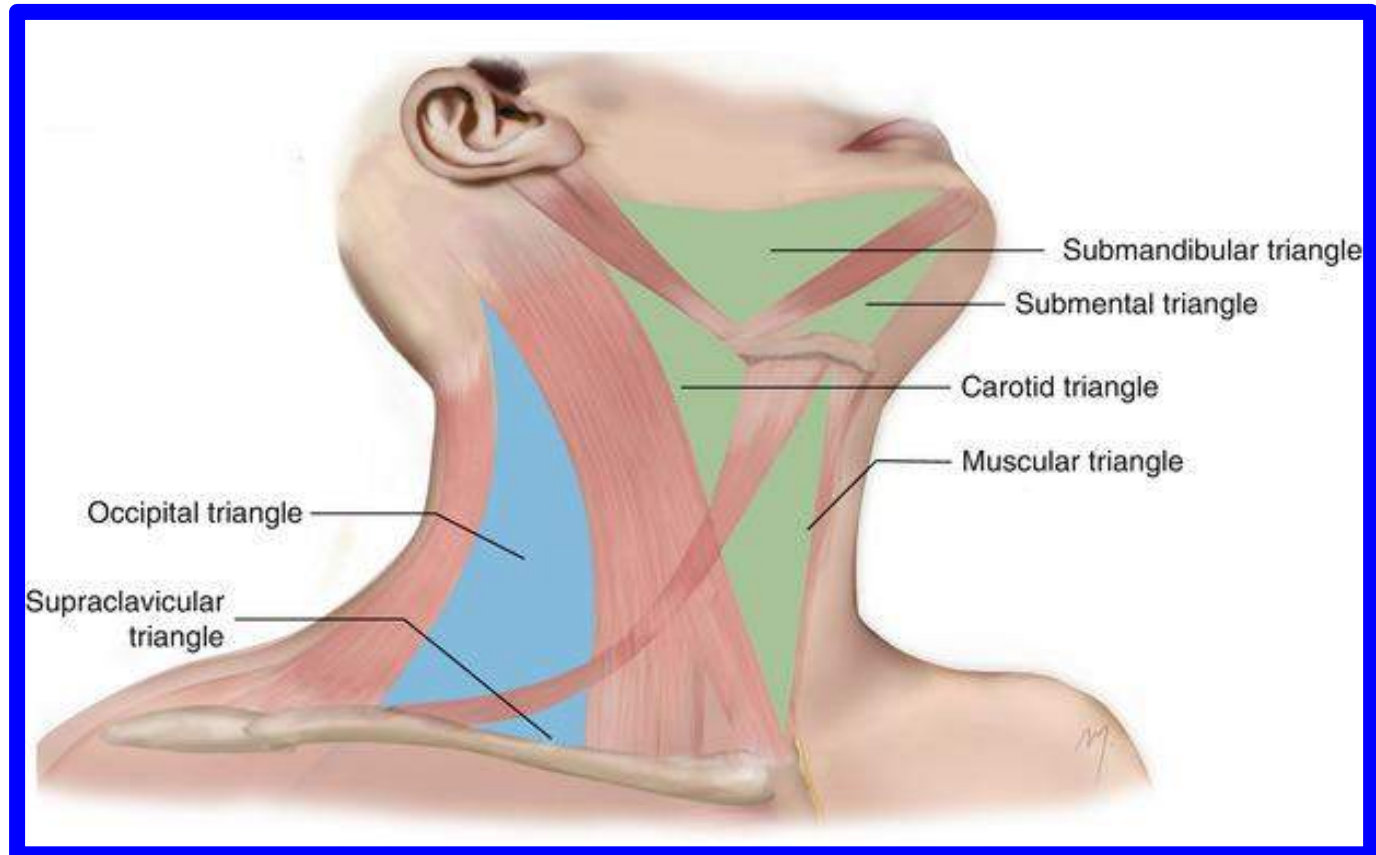


Dr. Aiman Al Maathidy
Sunday 9 March 2025

- ❖ **A roof:** formed by subcutaneous tissue containing the platysma.
- ❖ **A floor:** formed by the pharynx, larynx, and thyroid gland.

Anterior triangle of the neck (Anterior Cervical Region)

For more precise localization of structures, the anterior cervical region is subdivided into **four smaller triangles** (the unpaired submental triangle and **three small paired triangles**: submandibular, carotid, and muscular) by the digastric and omohyoid muscles



Dr. Aiman Al Maathidy
Sunday 9 March 2025

Anterior triangle of the neck (Anterior Cervical Region)

The submental triangle,

✓ inferior to the chin, is an unpaired suprahyoid area bounded:

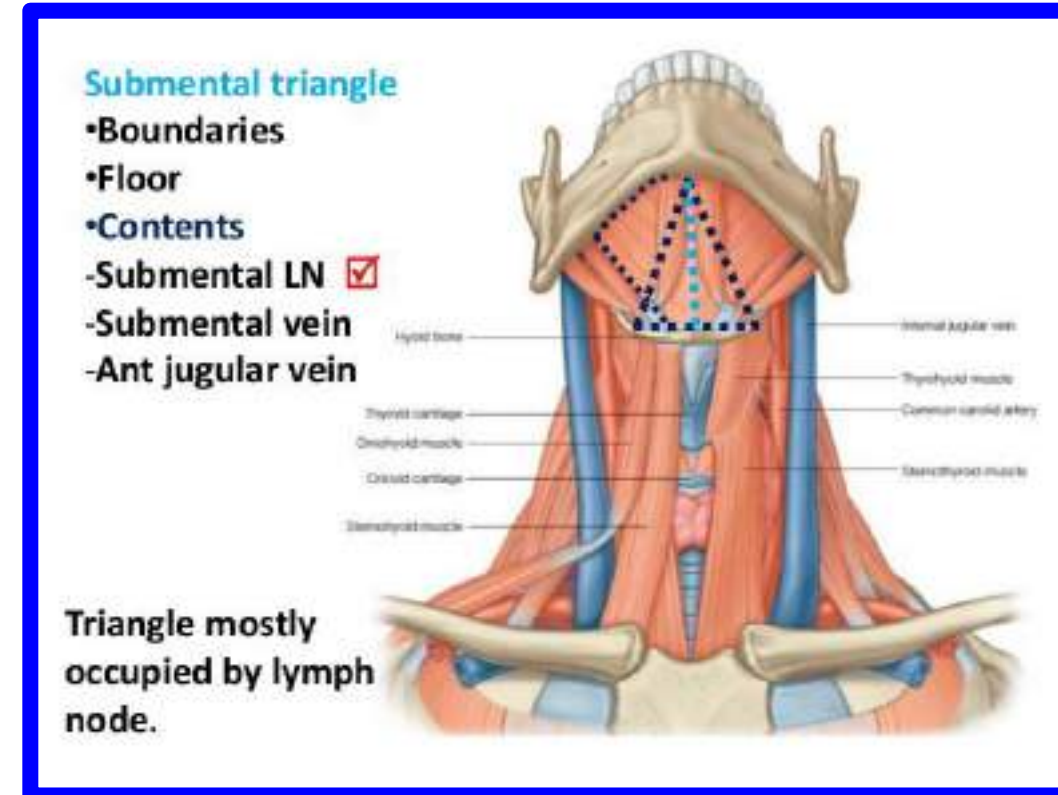
✓ inferiorly by the body of the hyoid and
✓ laterally by the right and left anterior bellies of the digastric muscles.

✓ The floor is formed by the two mylohyoid muscles, which meet in a median fibrous raphe

✓ The apex is at the mandibular symphysis, the site of union of the halves of the mandible during infancy.

✓ Its base is formed by the hyoid

□ This triangle contains several small submental lymph nodes and small veins that unite to form the anterior jugular vein



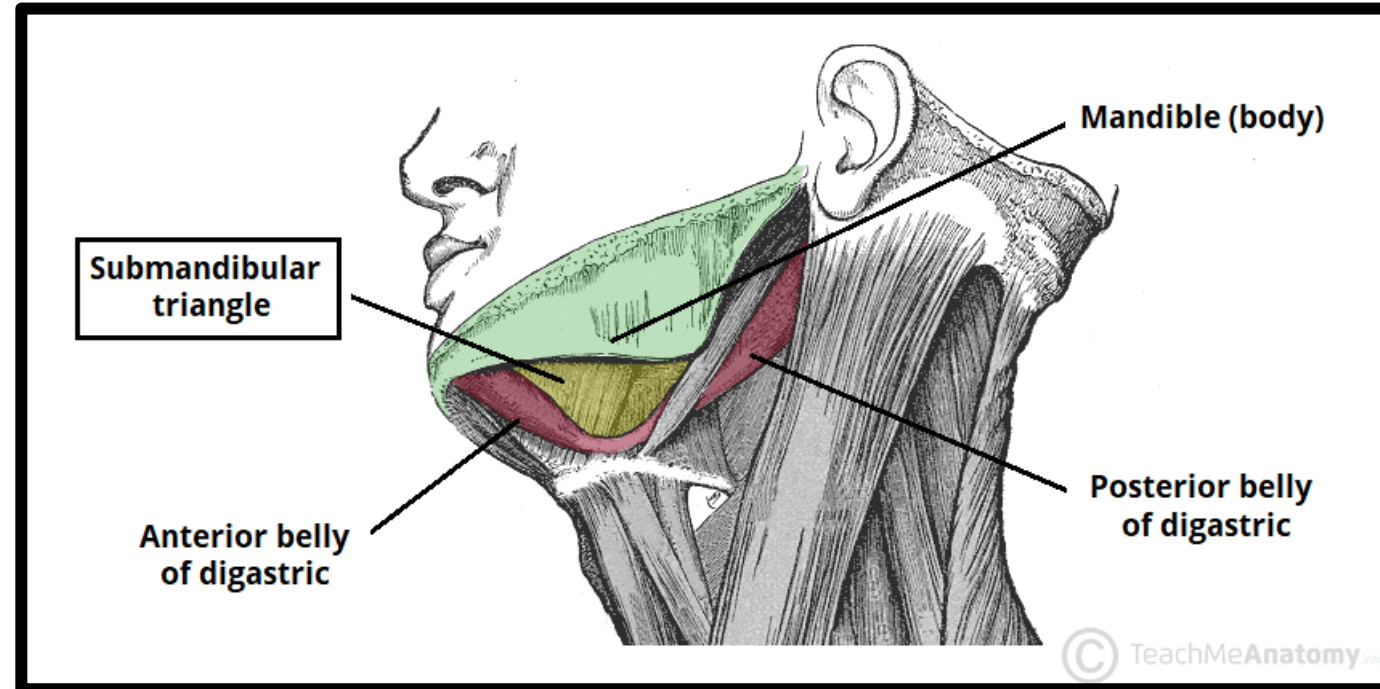
Anterior triangle of the neck (Anterior Cervical Region)

The submandibular triangle

✓ is a glandular area between the inferior border of the mandible and the anterior and posterior bellies of the digastric muscle.

✓ The floor is formed by the mylohyoid and hyoglossus muscles and the middle constrictor muscle of the pharynx.

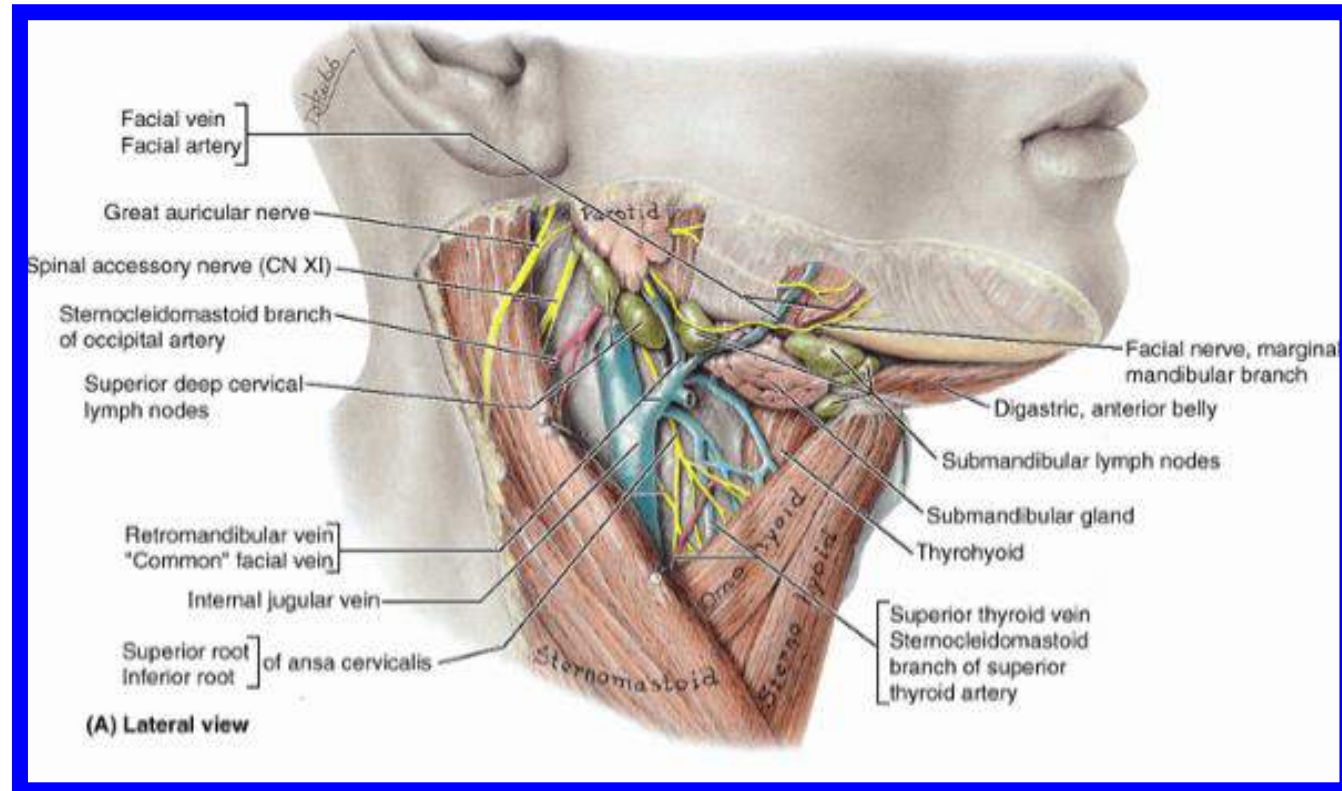
✓ The submandibular gland nearly fills this triangle.



✓ Submandibular lymph nodes lie on each side of the submandibular gland and along the inferior border of the mandible

Anterior triangle of the neck (Anterior Cervical Region)

- ✓ The hypoglossal nerve (CN XII)
- ✓ The mylohyoid muscle Nerve (a branch of CN V₃, which also supplies the anterior belly of the digastric),
- ✓ Parts of the facial artery and vein,
- ✓ The submental artery (a branch of the facial artery)



Dr. Aiman Al Maathidy

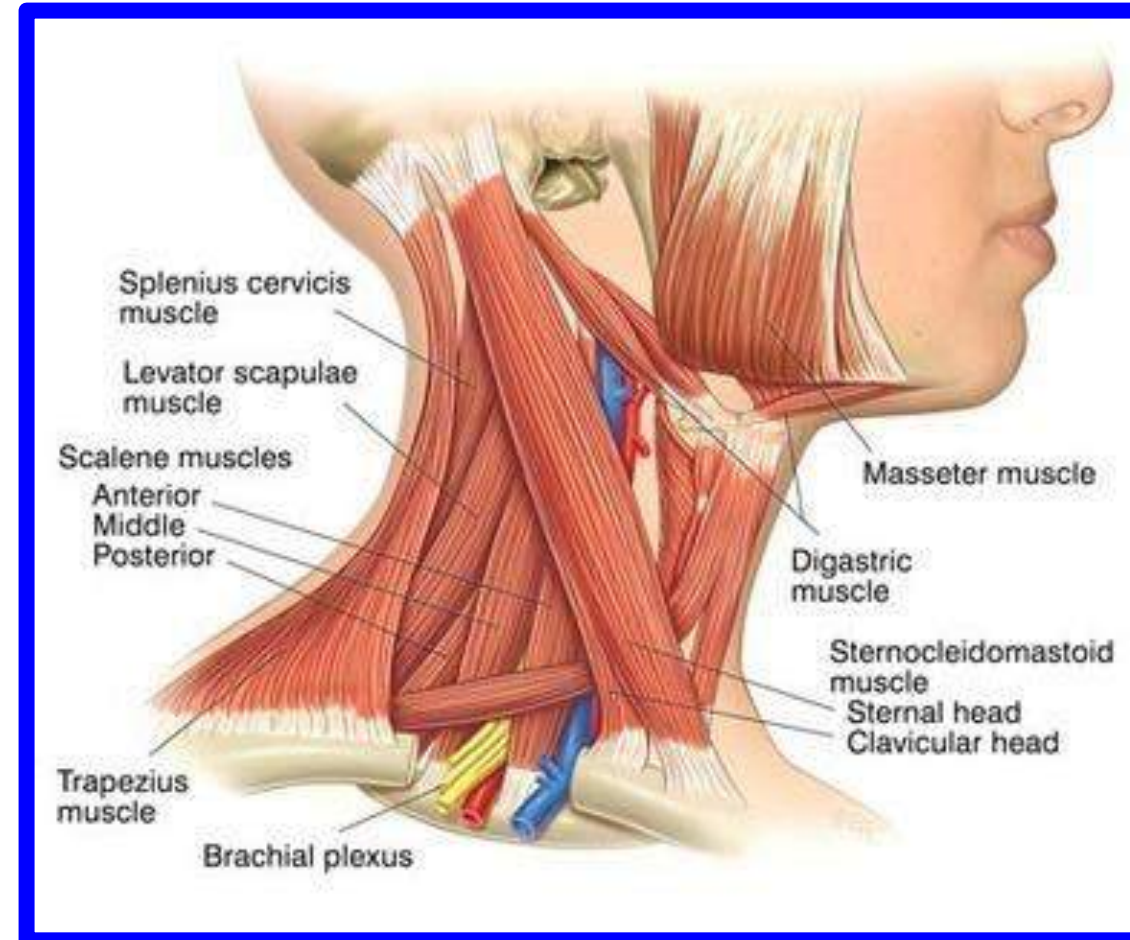
Sunday 9 March 2025

Anterior triangle of the neck (Anterior Cervical Region)

The carotid triangle

Sunday 9 March 2025

- ✓ is a vascular area bounded by the superior belly of the omohyoid, the posterior belly of the digastric, and the anterior border of the SCM
- ✓ This triangle is important because the **common carotid artery** ascends into it.
- ✓ Its pulse can be auscultated or palpated by compressing it lightly against the transverse processes of the cervical vertebrae.



Anterior triangle of the neck (Anterior Cervical Region)

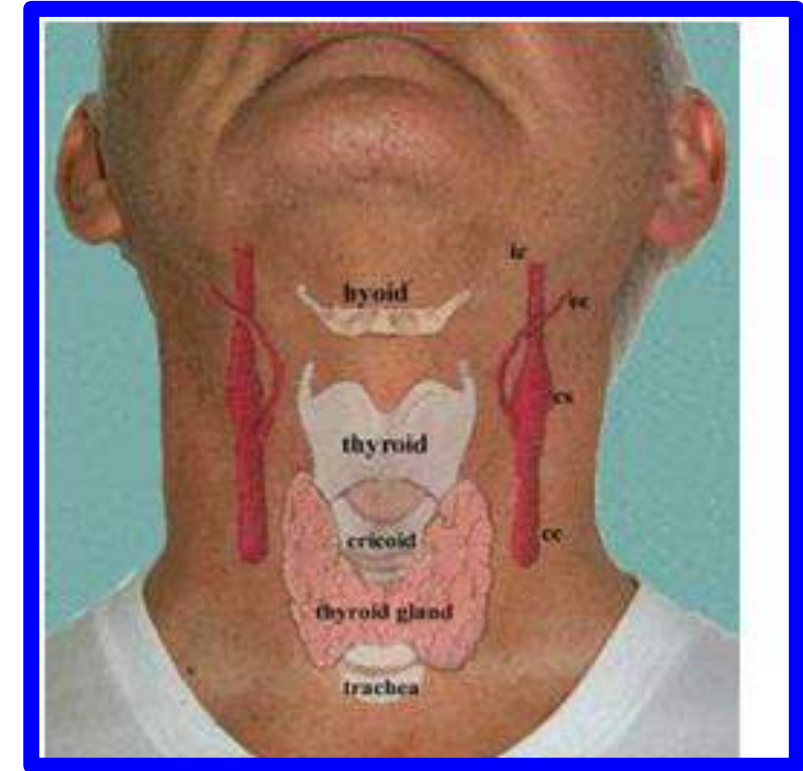
The carotid triangle

✓ At the level of the superior border of the thyroid cartilage, **the common carotid artery** divides into **the internal** and **external carotid arteries**.

✓ Located within the carotid triangle are the following:

❑ **Carotid sinus**: a slight dilation of the proximal part of **the internal carotid artery**, which may involve **the common carotid artery**

❑ Innervated principally by the **glossopharyngeal nerve (CN IX)** through **the carotid sinus nerve**, as well as by **the vagus nerve (CN X)**, it is a baroreceptor (**pressoreceptor**) that reacts to changes in arterial blood pressure.



Anterior triangle of the neck (Anterior Cervical Region)

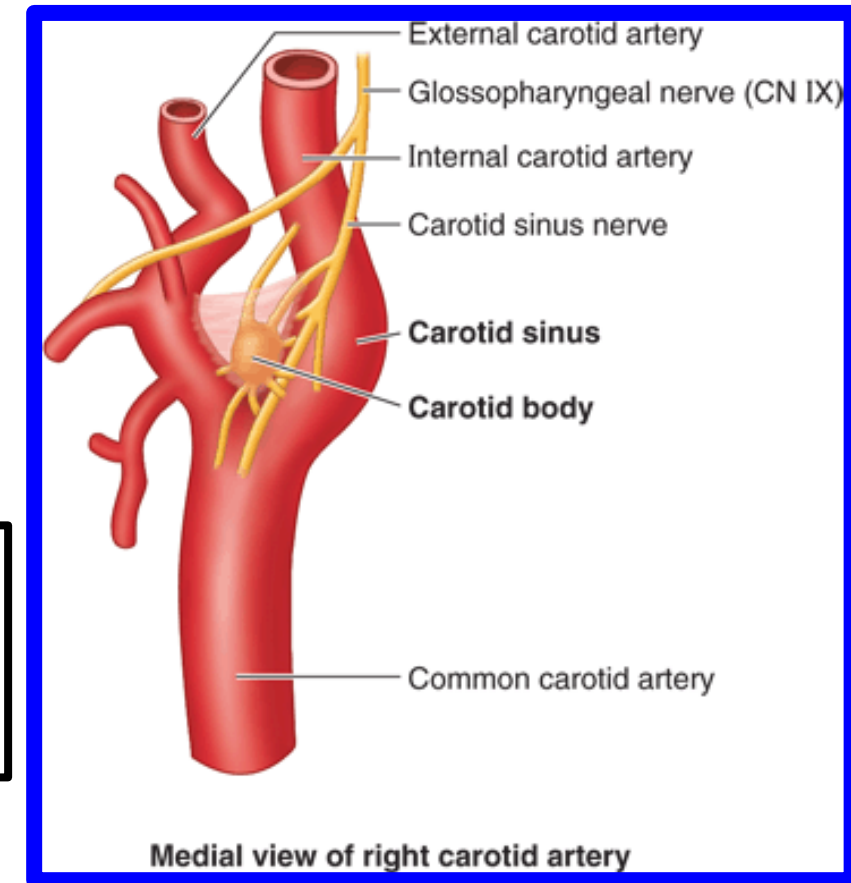
The carotid triangle

Carotid body: a small, reddish brown ovoid mass of tissue in life that lies on the medial (deep) side of the **bifurcation of the common carotid artery** in close relation to **the carotid sinus**

Supplied mainly by **the carotid sinus nerve**

Carotid sheath containing common carotid artery and its branches; internal jugular vein and its tributaries; vagus nerve;

external carotid artery and some of its branches;
hypoglossal nerve and **superior root of ansa cervicalis; spinal accessory nerve (CN XI)^b;**
thyroid gland, larynx, and pharynx; **deep cervical lymph nodes; branches of cervical plexus**



Anterior triangle of the neck (Anterior Cervical Region)

The muscular triangle

- ✓ is bounded by the superior belly of the omohyoid muscle, the anterior border of the SCM, and the median plane of the neck.
- ✓ This triangle contains **the infrahyoid muscles and viscera** (e.g., the thyroid and parathyroid glands).

the Muscular triangle

is bounded

in front, by the median line of the neck from the hyoid bone to the sternum;

behind, by the anterior margin of the sternocleidomastoid;

above, by the superior belly of the omohyoid

Contents

A-infrahyoid muscles

They consist of 4 muscles arranged into 2 layers :

1- superficial layer :

– sternohyoid

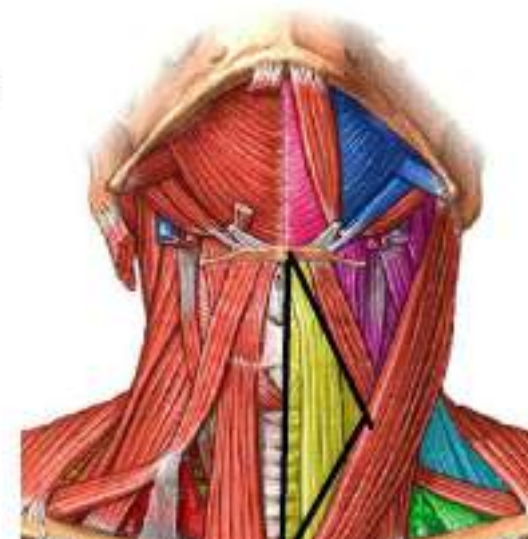
– omohyoid

2- deep layer:

– sternothyroid

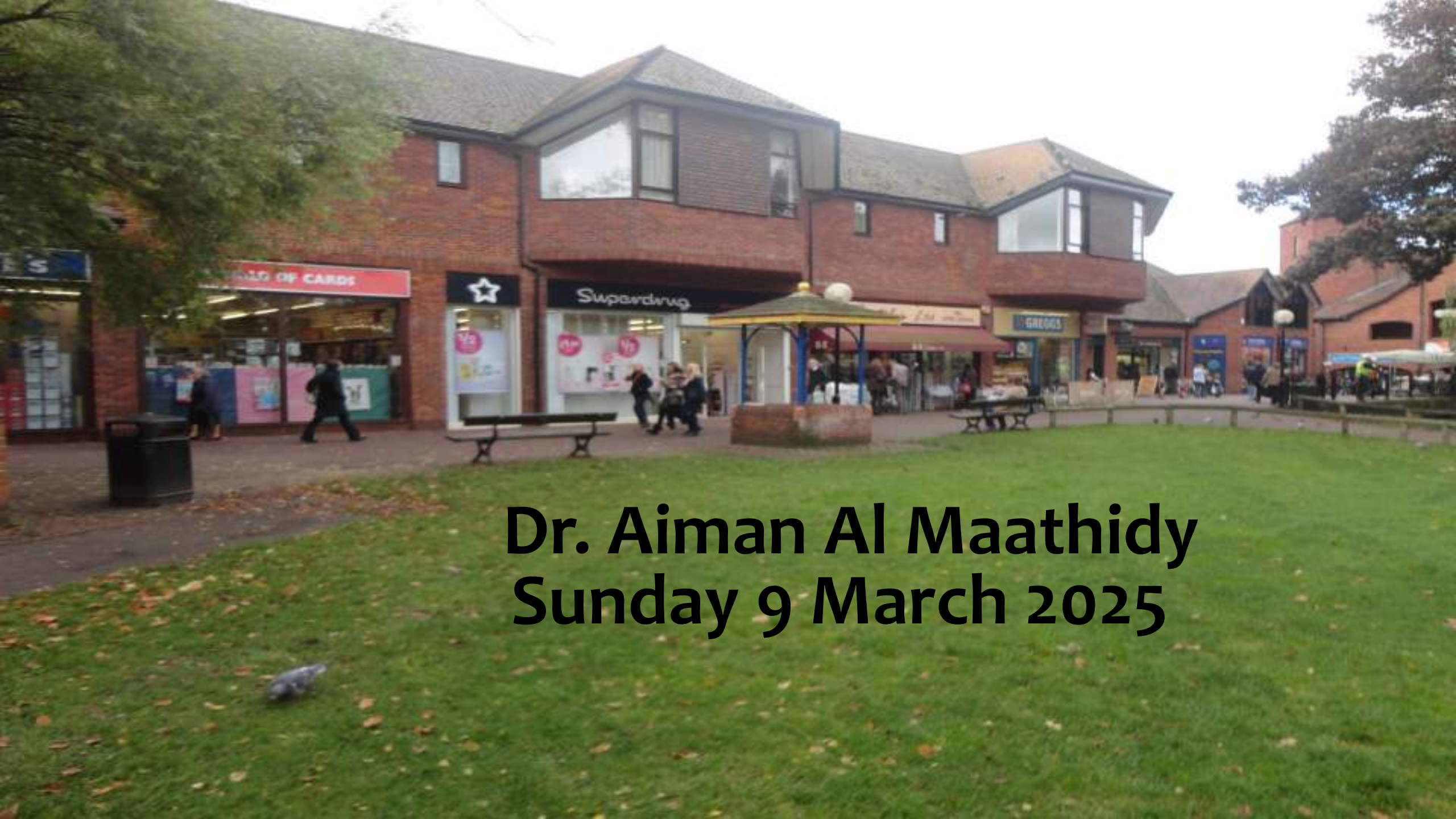
– thyrohyoid

B-lat. Lobe of thyroid gl. lying deep to sternohyoid & sternothyroid



Dr. Aiman Al Maathidy

Sunday 9 March 2025



Dr. Aiman Al Maathidy
Sunday 9 March 2025