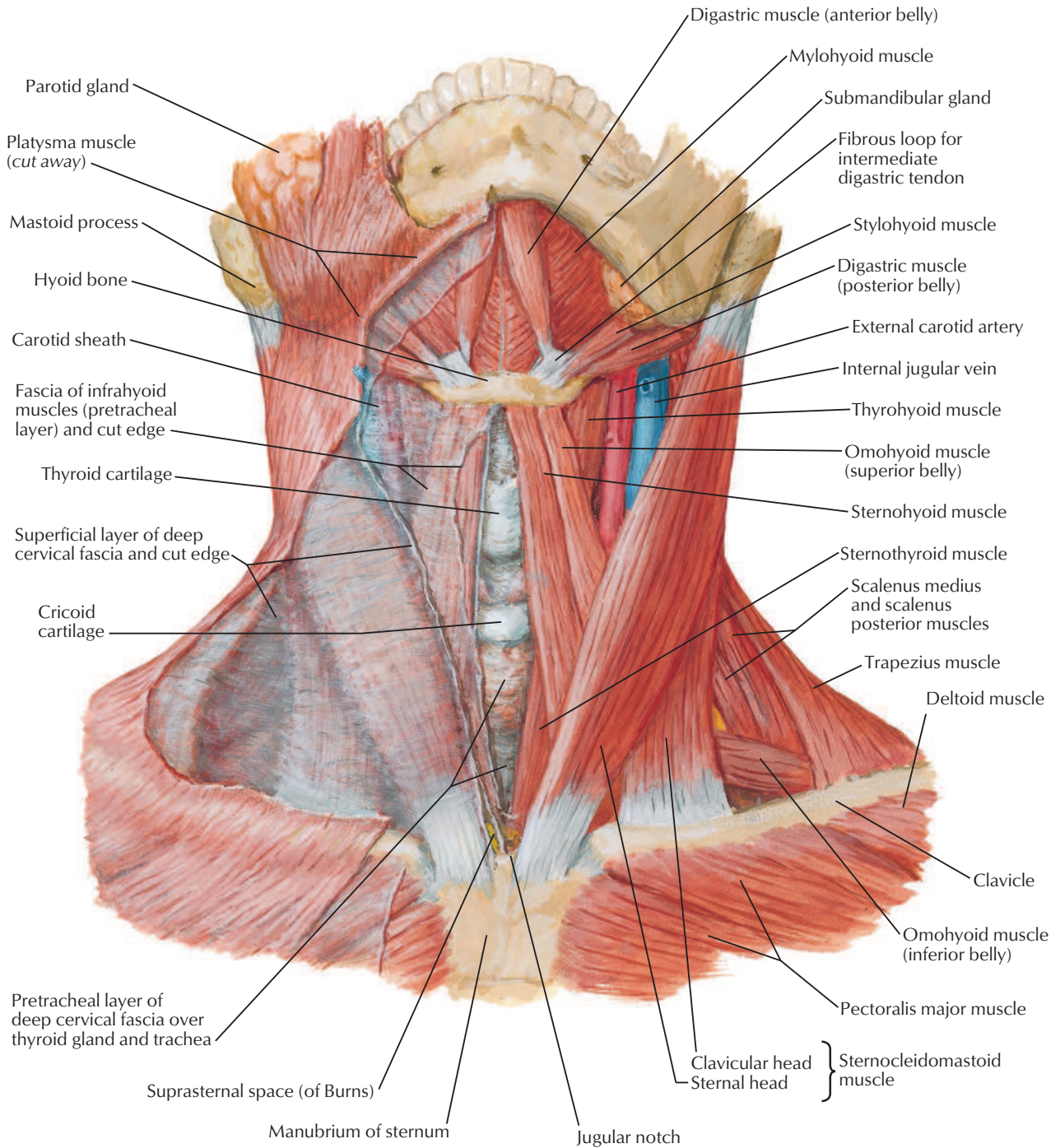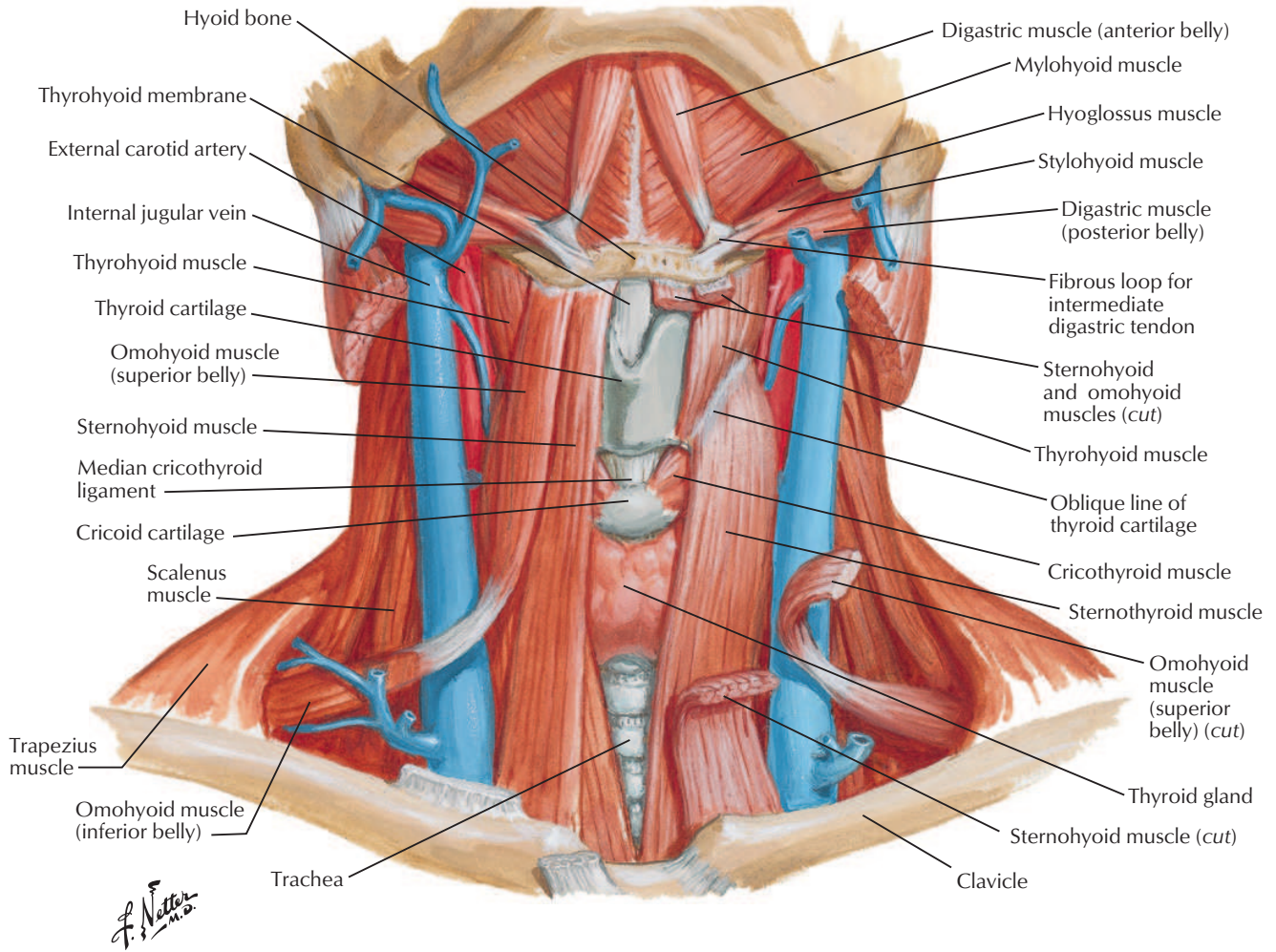
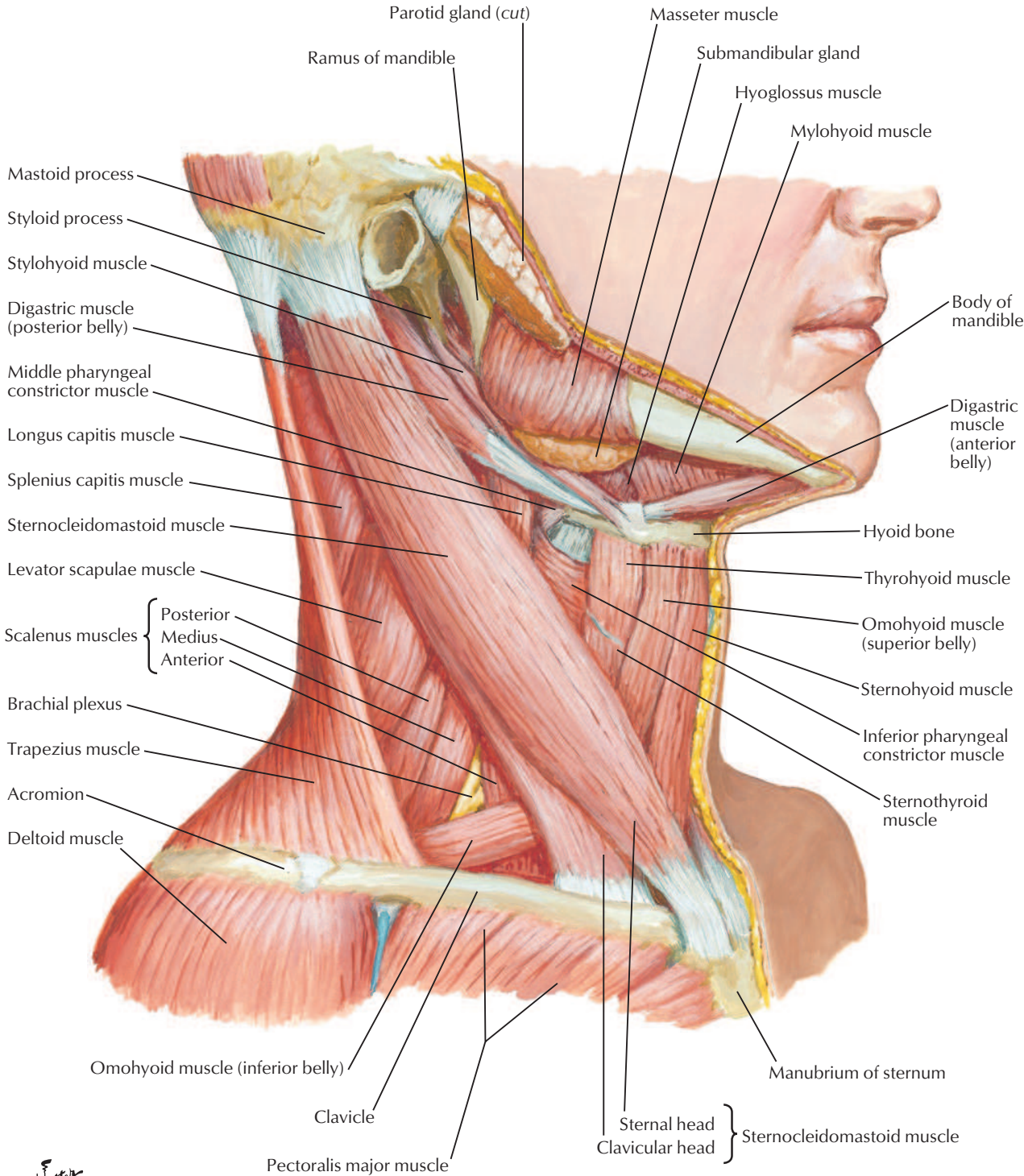


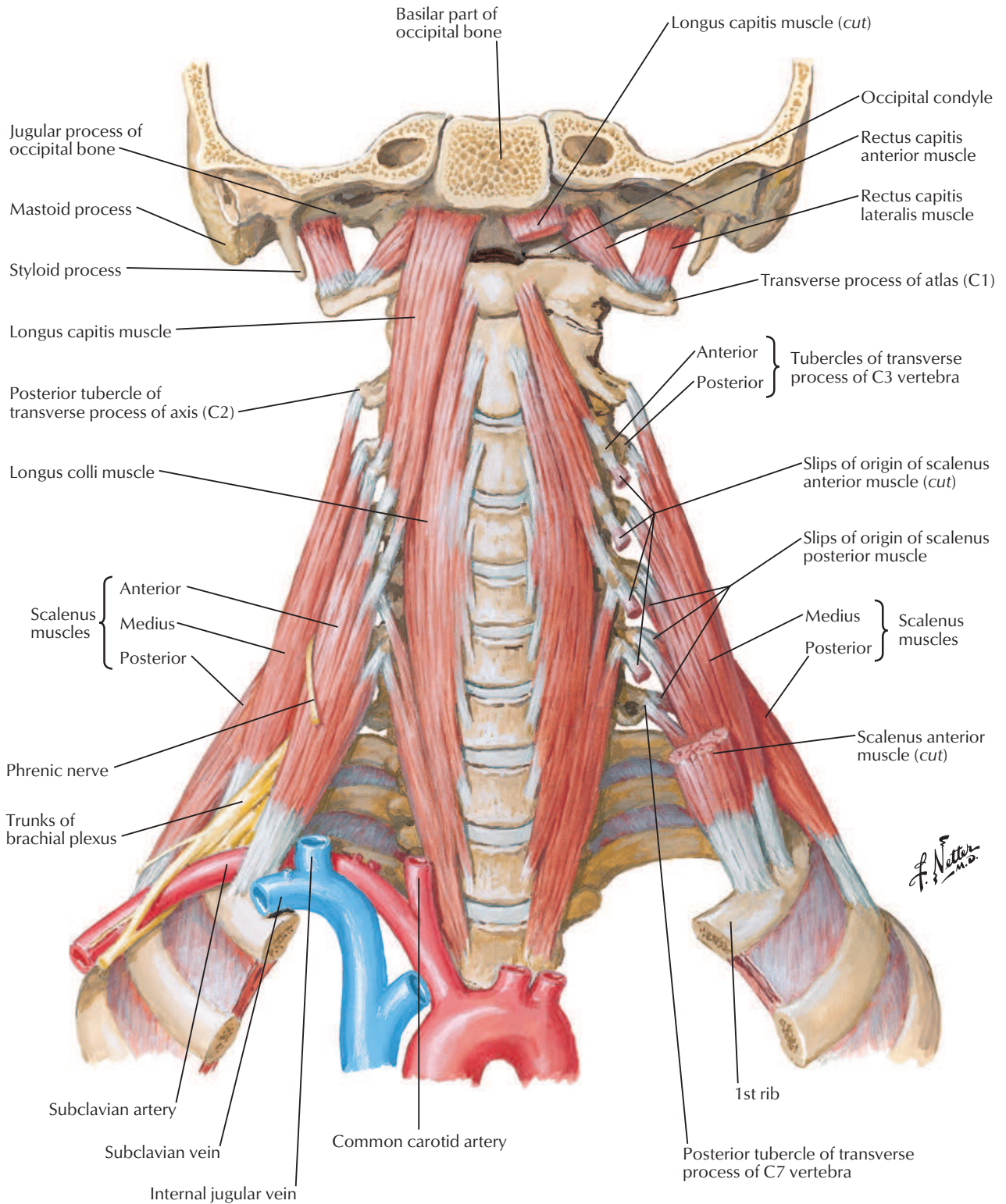
*F. Netter M.D.*





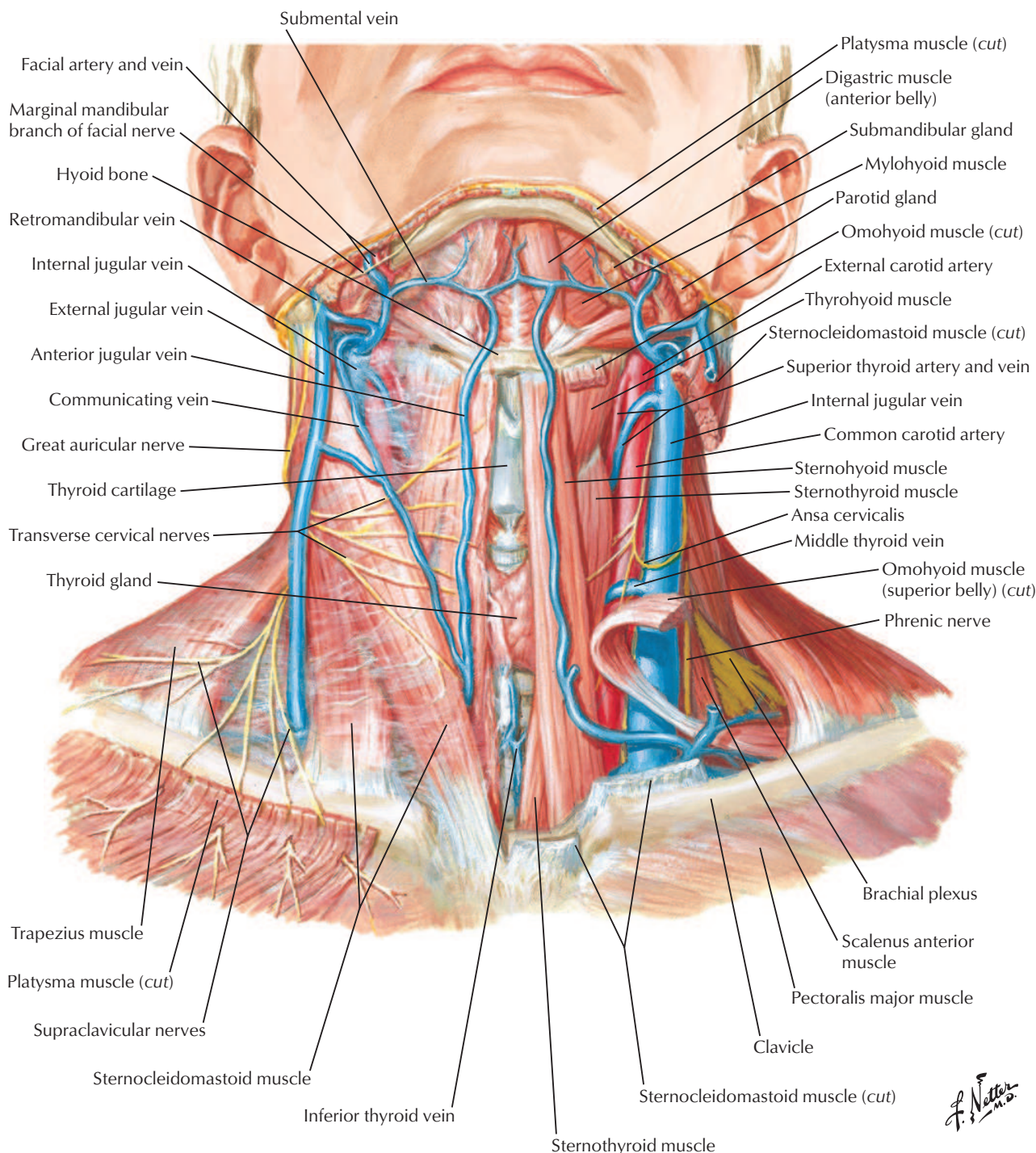
See also Plates 32, 35, 38

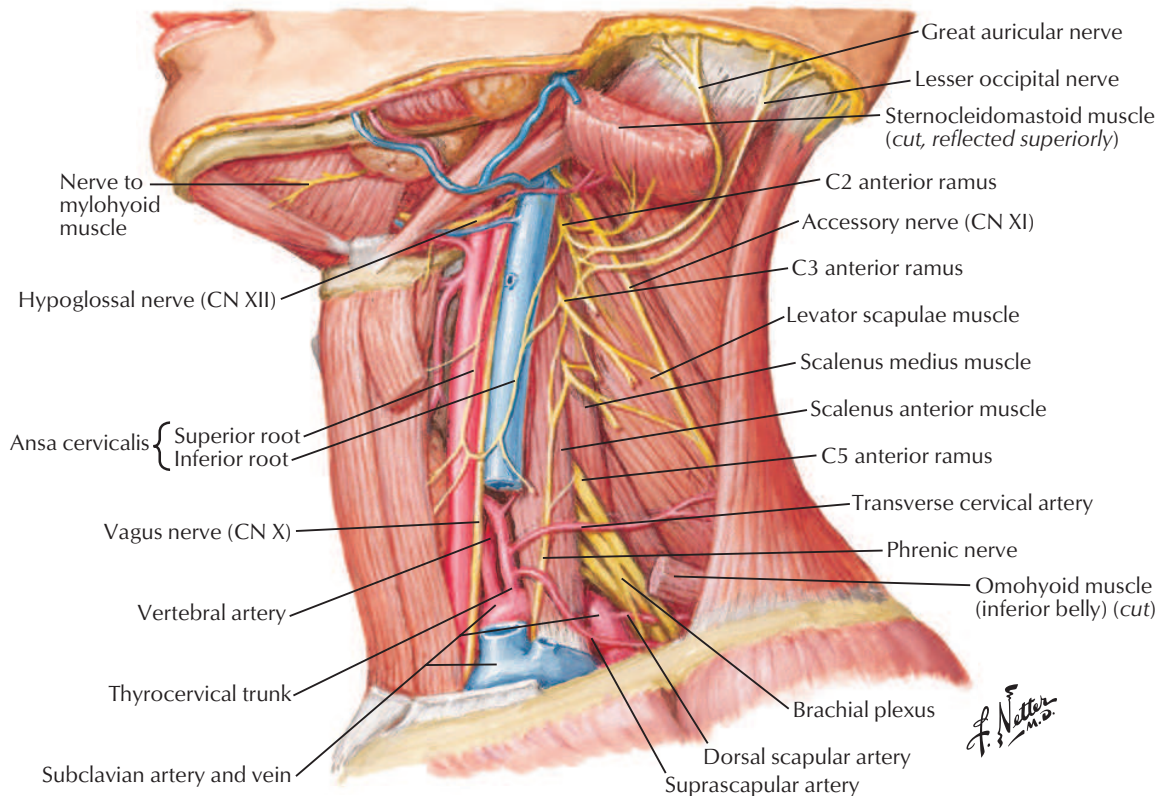
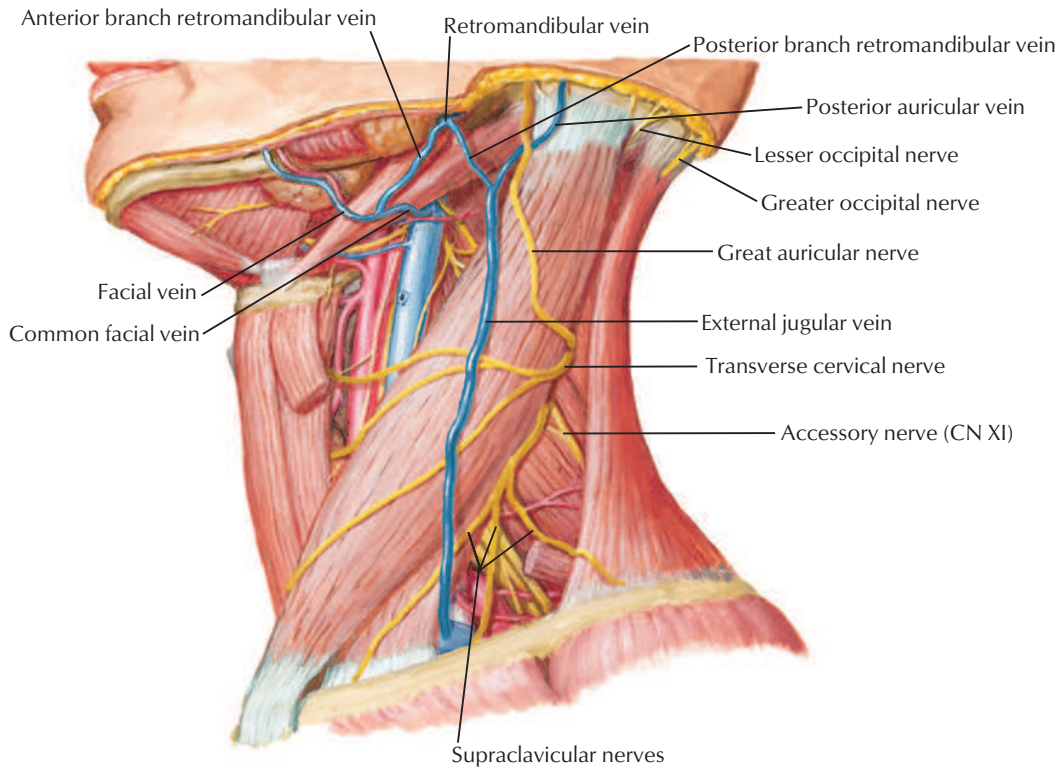






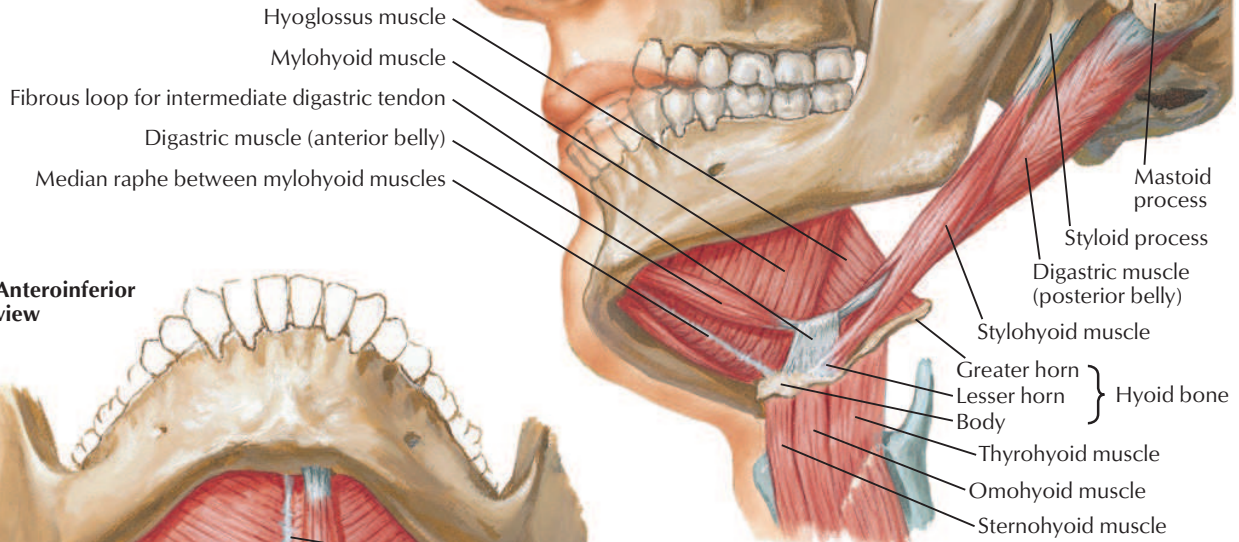
For deep veins of neck see [Plate 84](#)



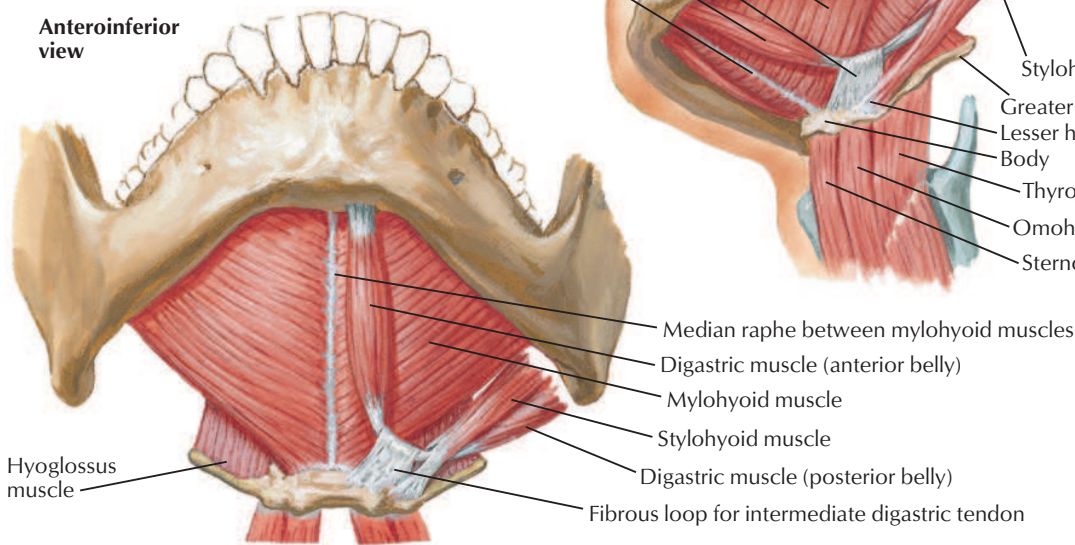




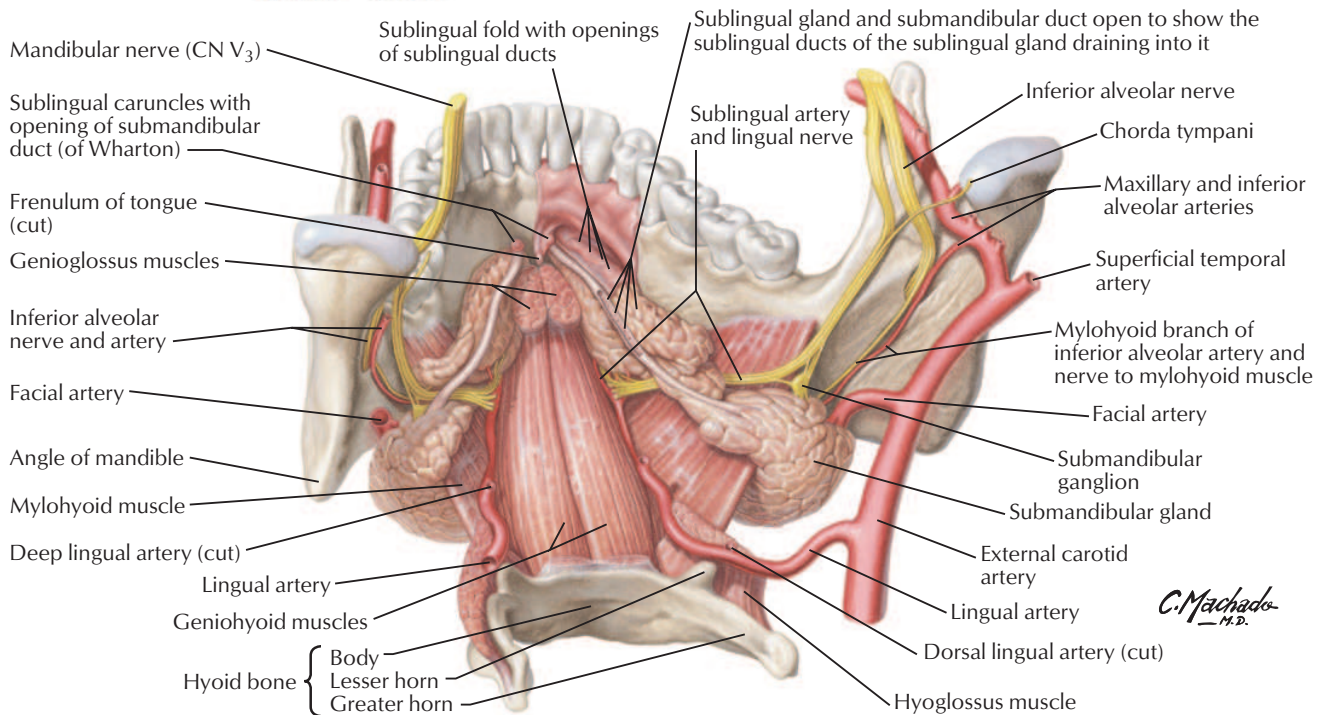
## Lateral, slightly inferior view



## Anteroinferior view



*F. Netter M.D.*



*C. Machado M.D.*