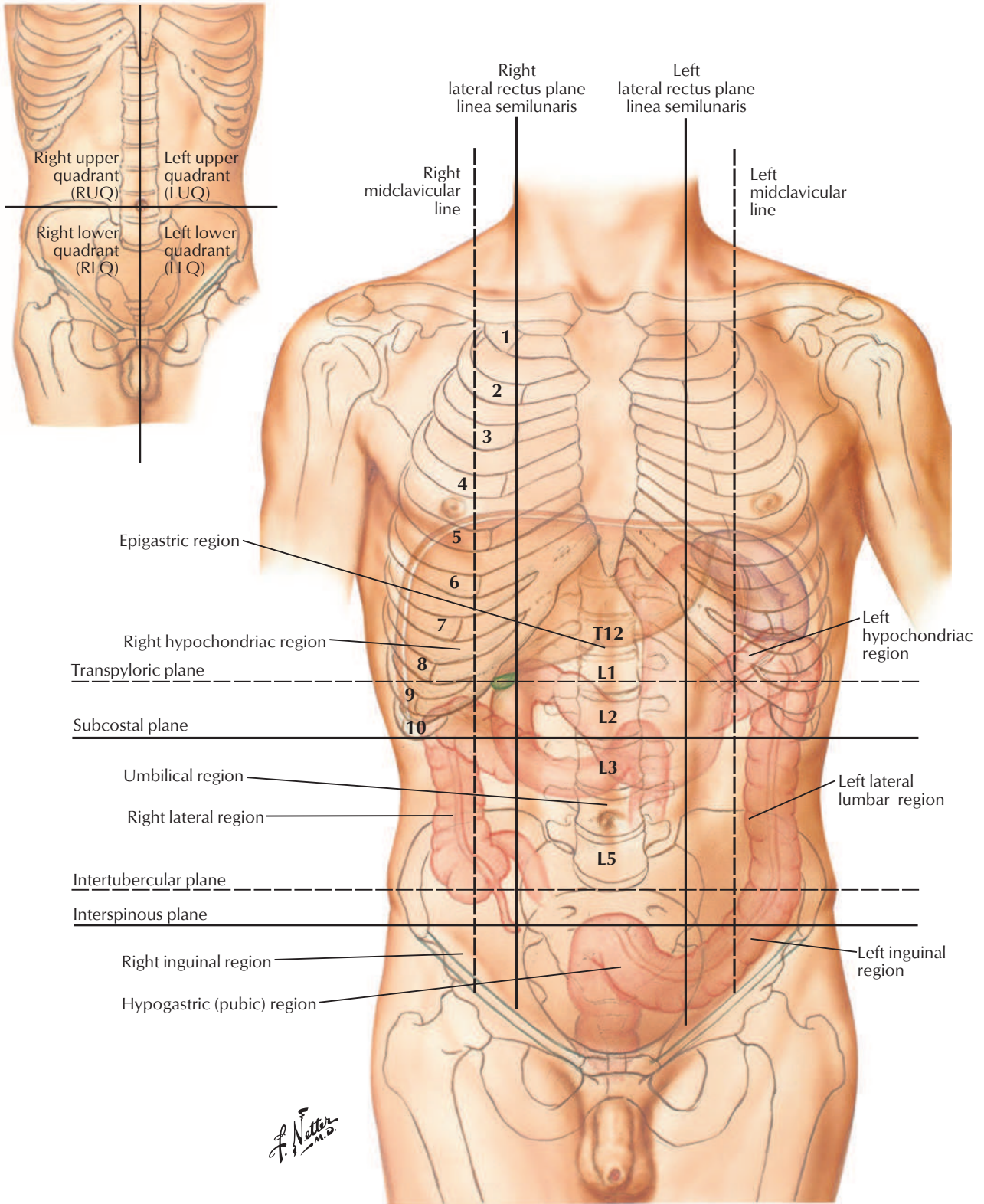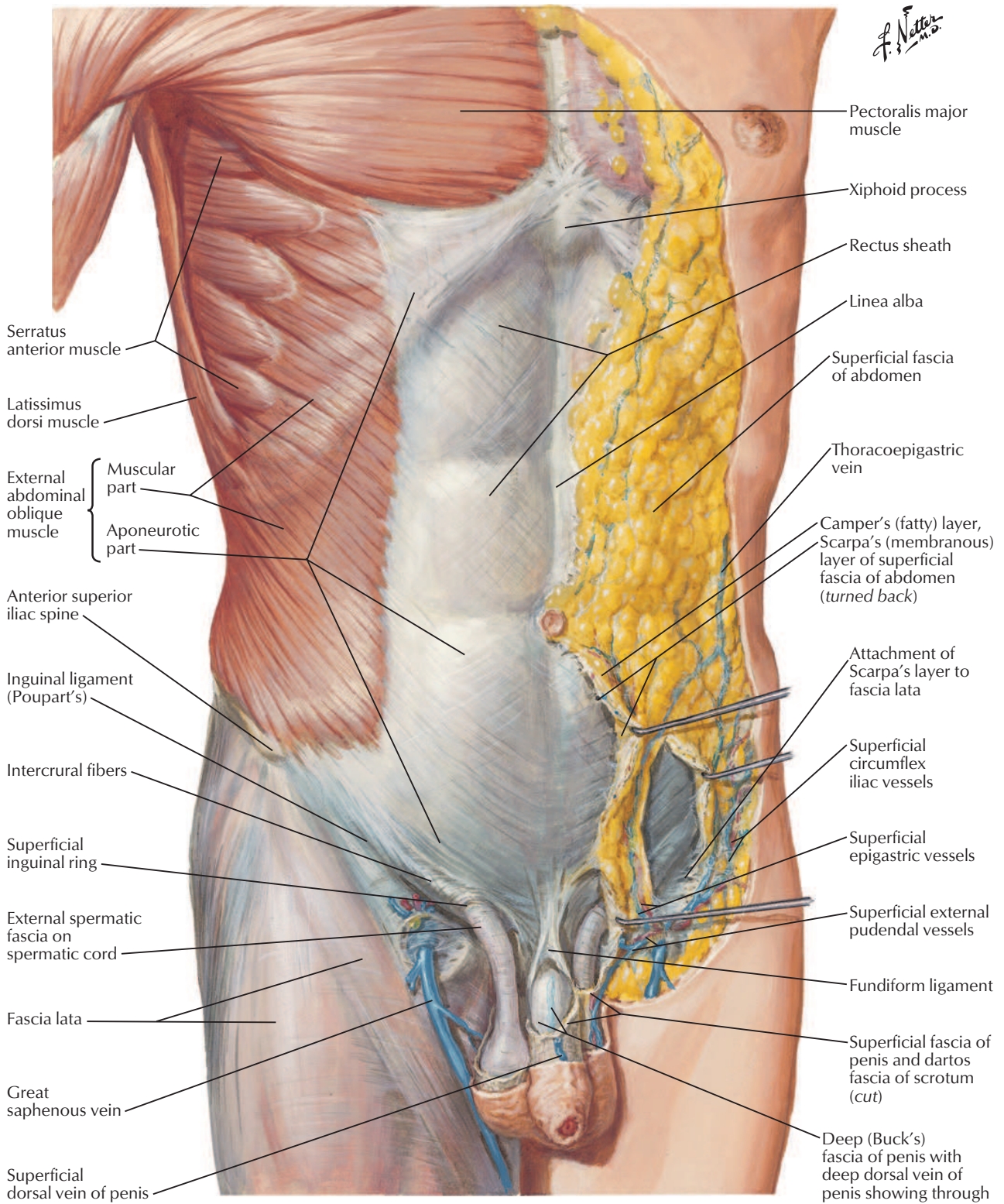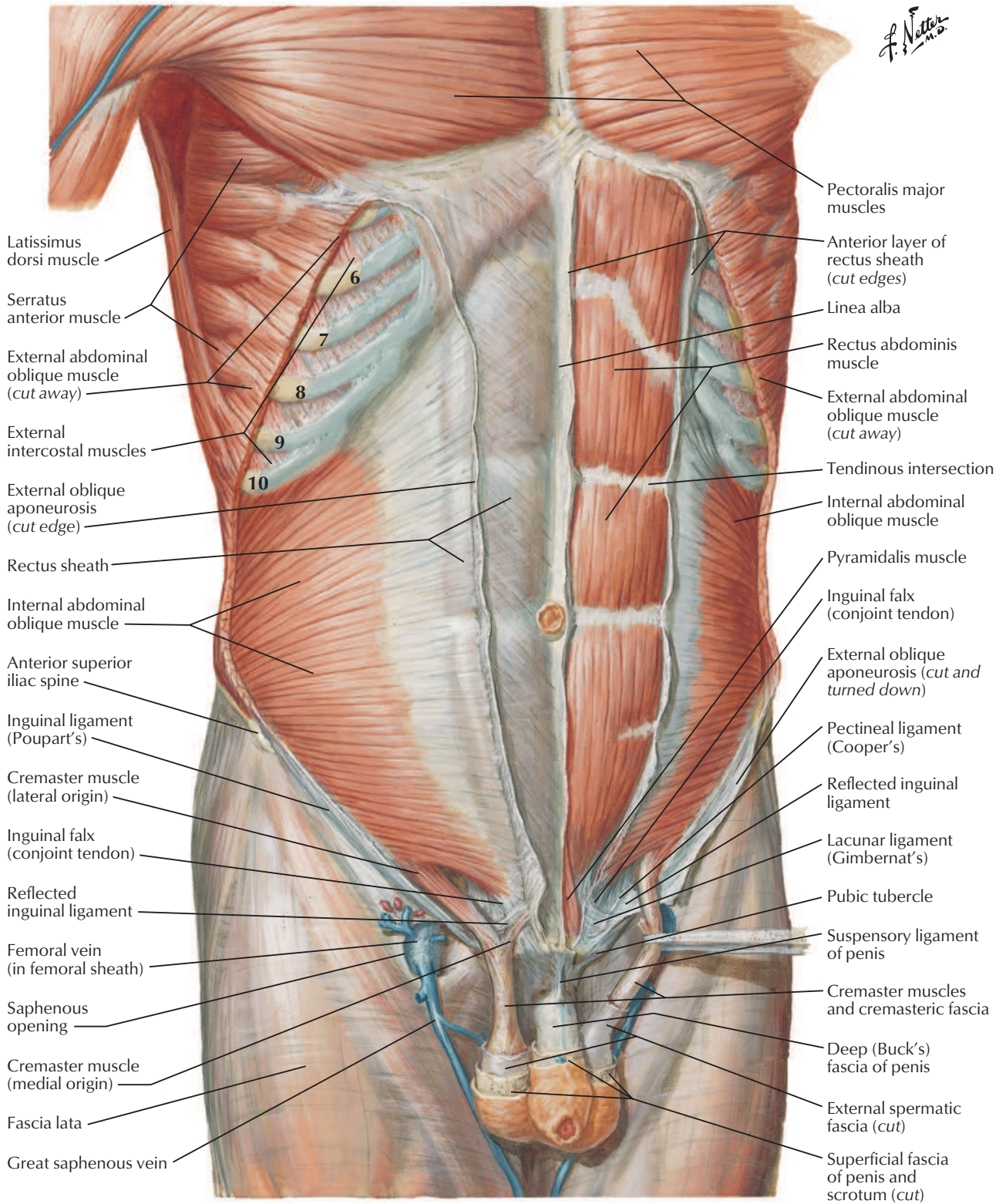
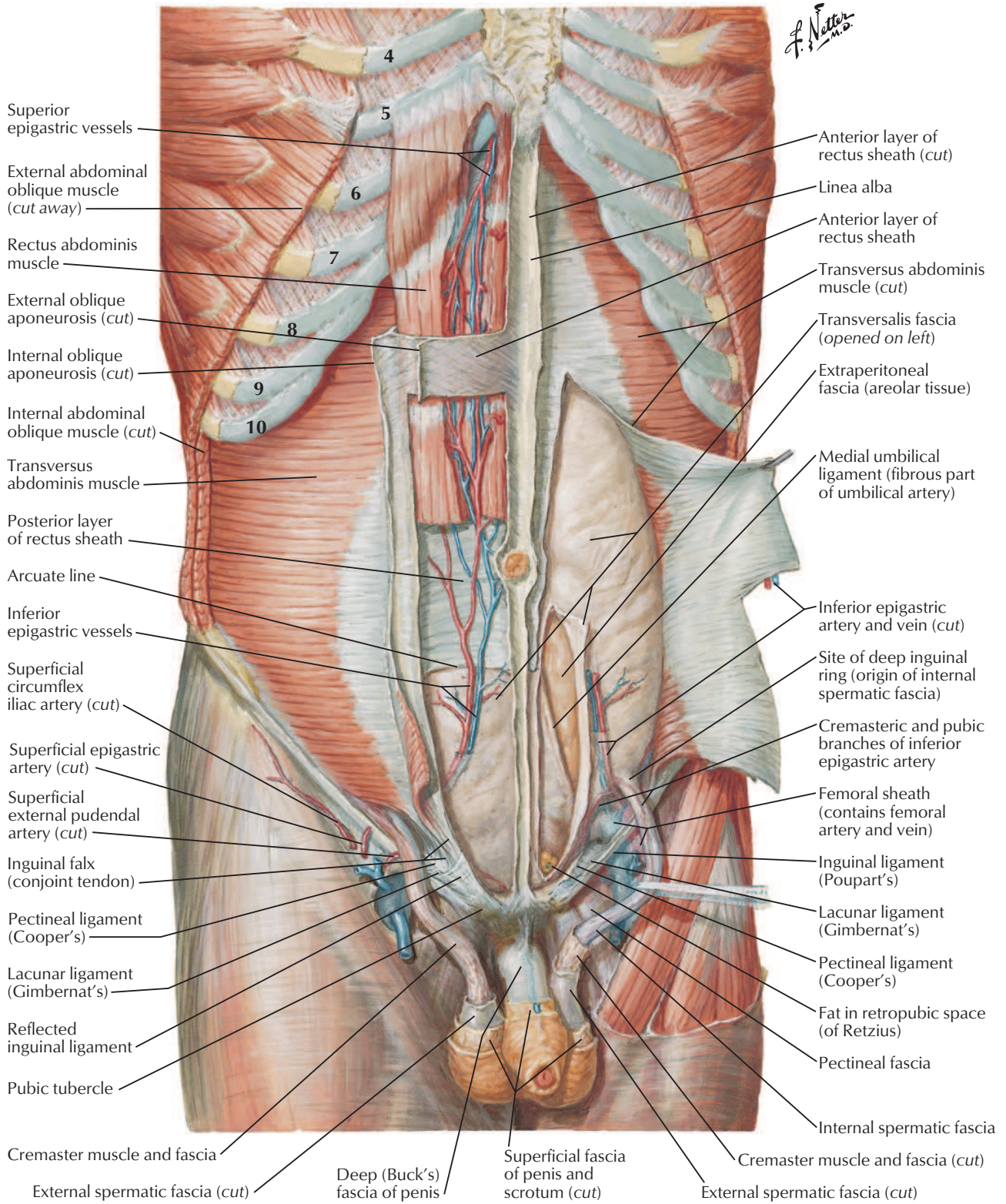


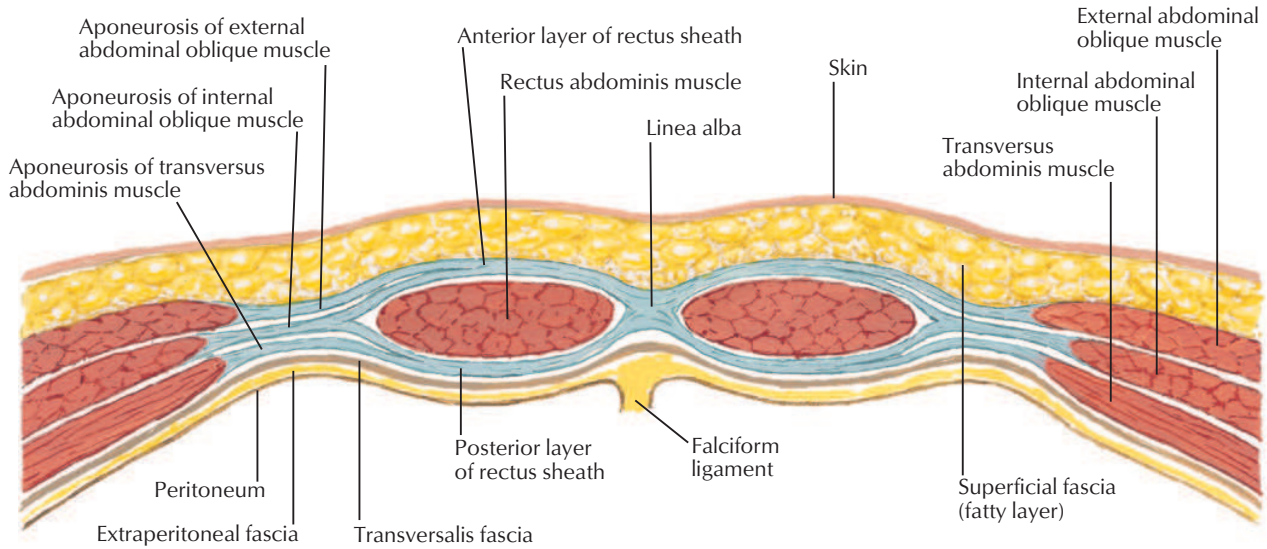
*F. Netter M.D.*





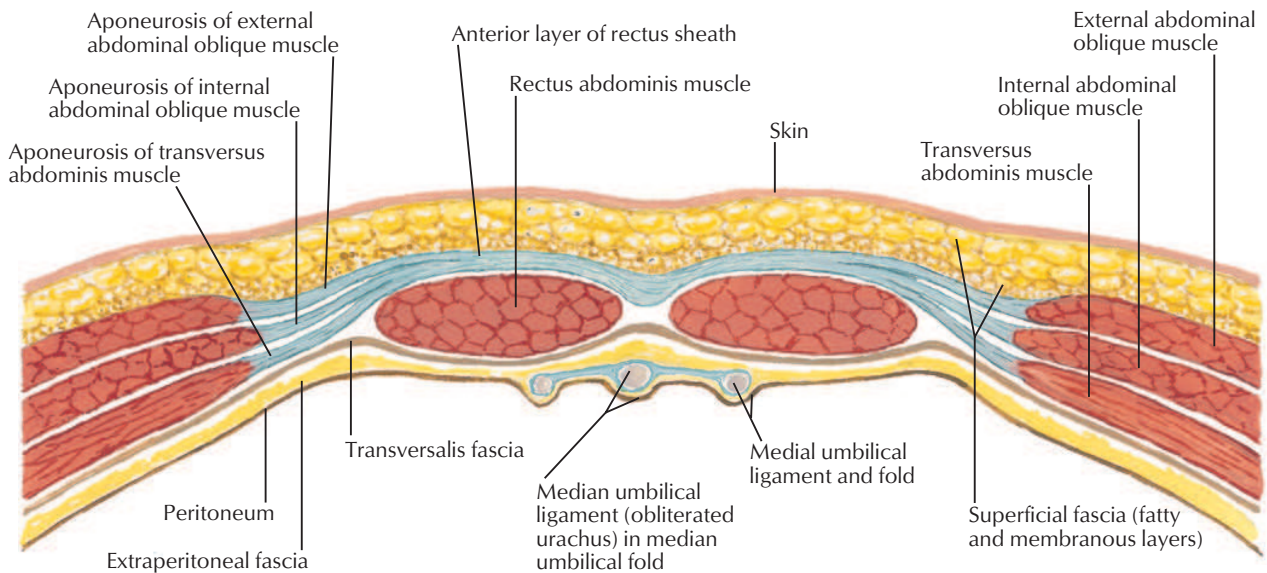


Section above arcuate line



Aponeurosis of internal abdominal oblique muscle splits to form anterior and posterior layers of rectus sheath. Aponeurosis of external abdominal oblique muscle joins anterior layer of sheath; aponeurosis of transversus abdominis muscle joins posterior layer. Anterior and posterior layers of rectus sheath unite medially to form linea alba.

Section below arcuate line



Aponeurosis of internal abdominal oblique muscle does not split at this level but passes completely anterior to rectus abdominis muscle and is fused there with both aponeurosis of external abdominal oblique muscle and that of transversus abdominis muscle. Thus, posterior wall of rectus sheath is absent below arcuate line, leaving only transversalis fascia.

*F. Netter M.D.*

