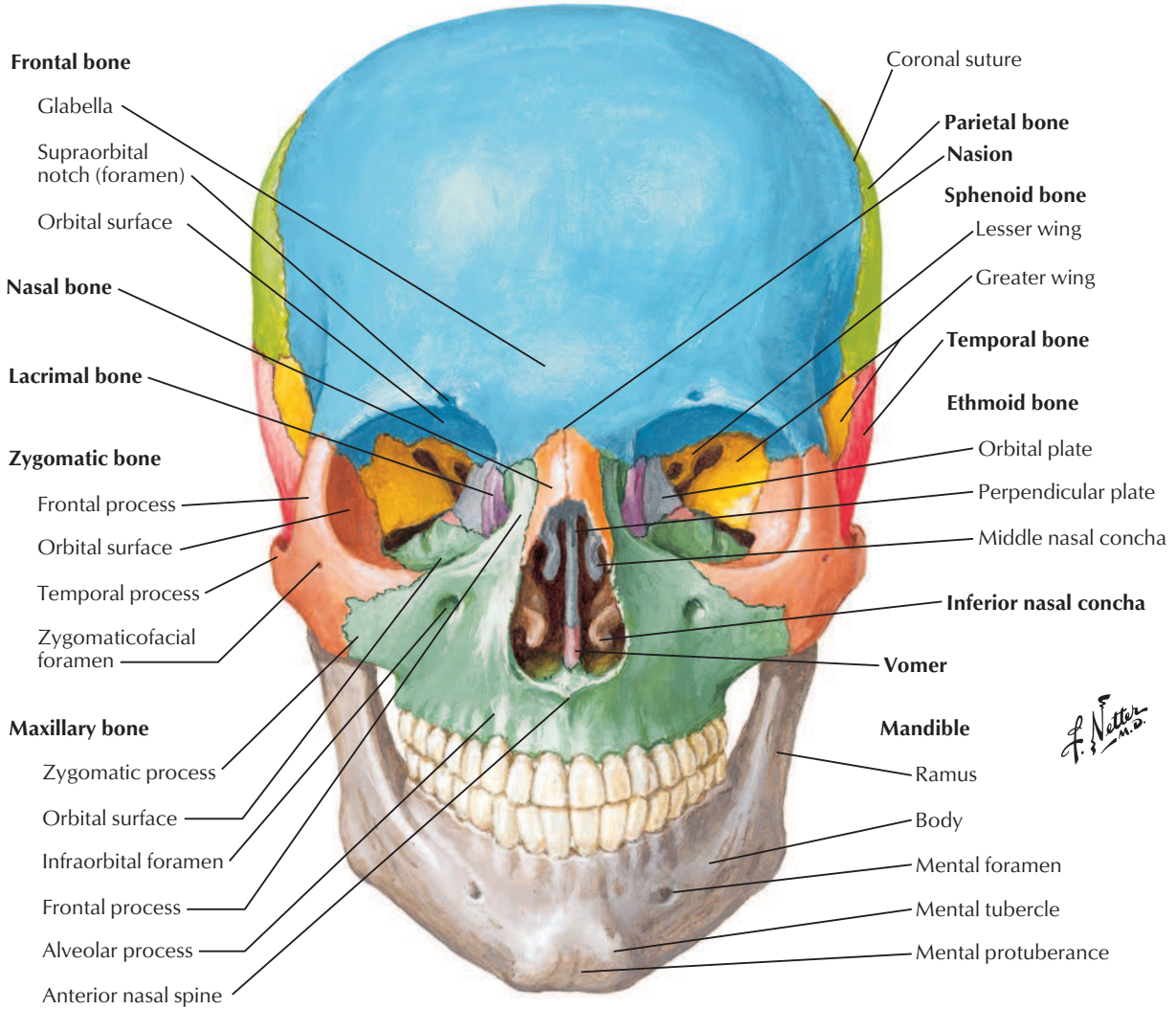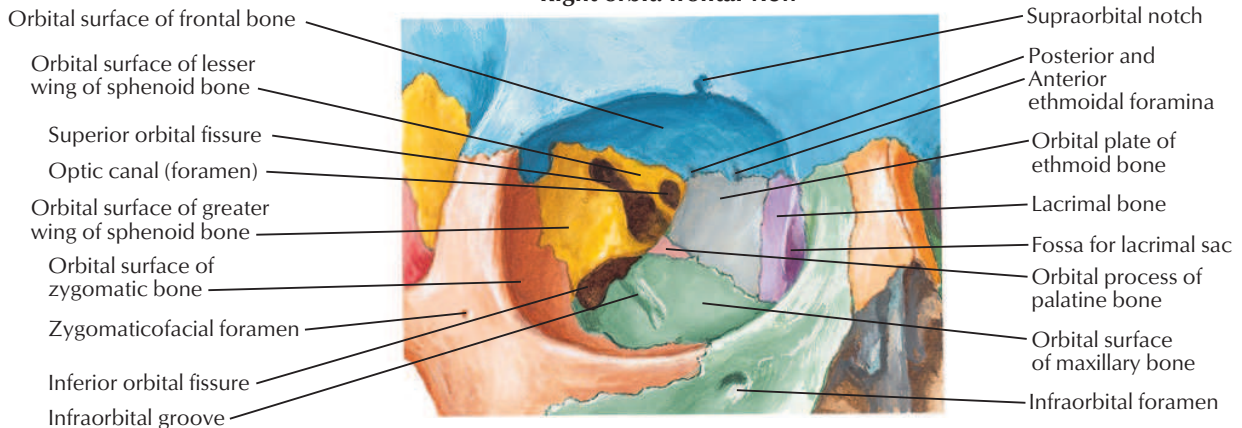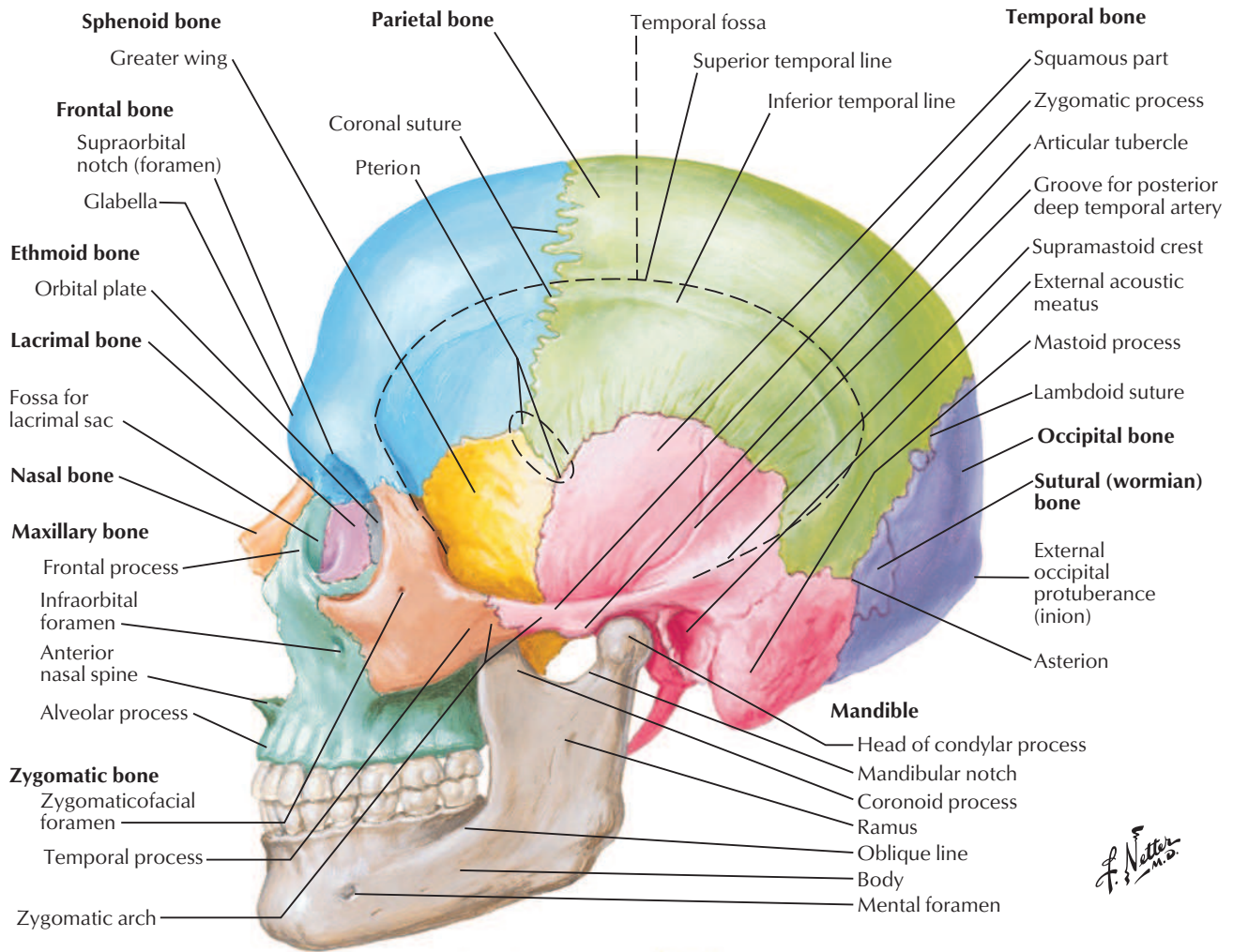
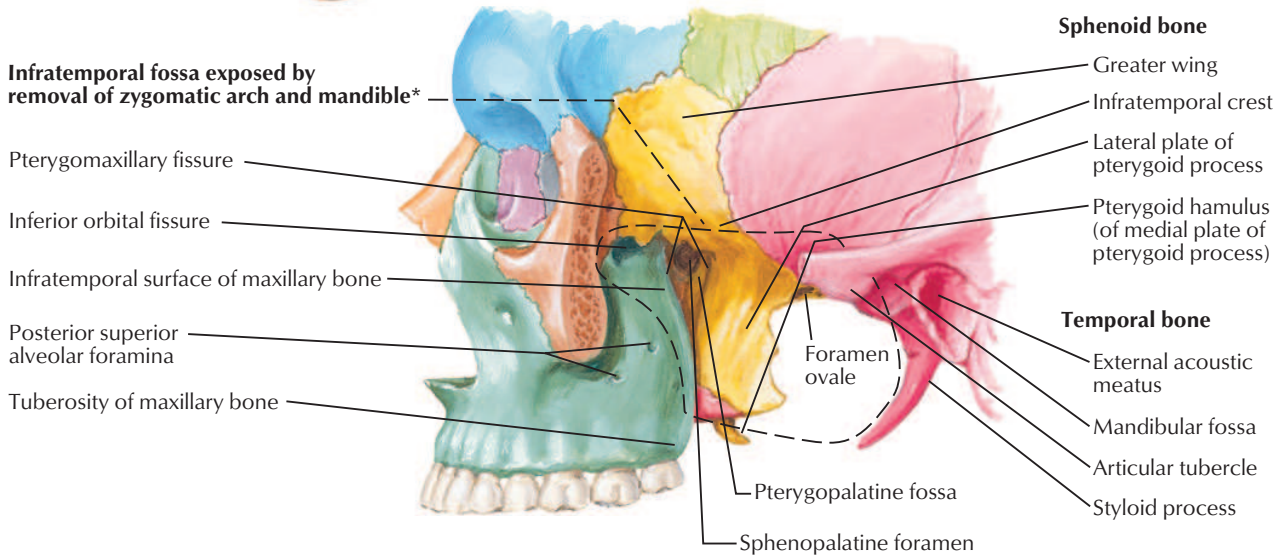


Right orbit: frontal view

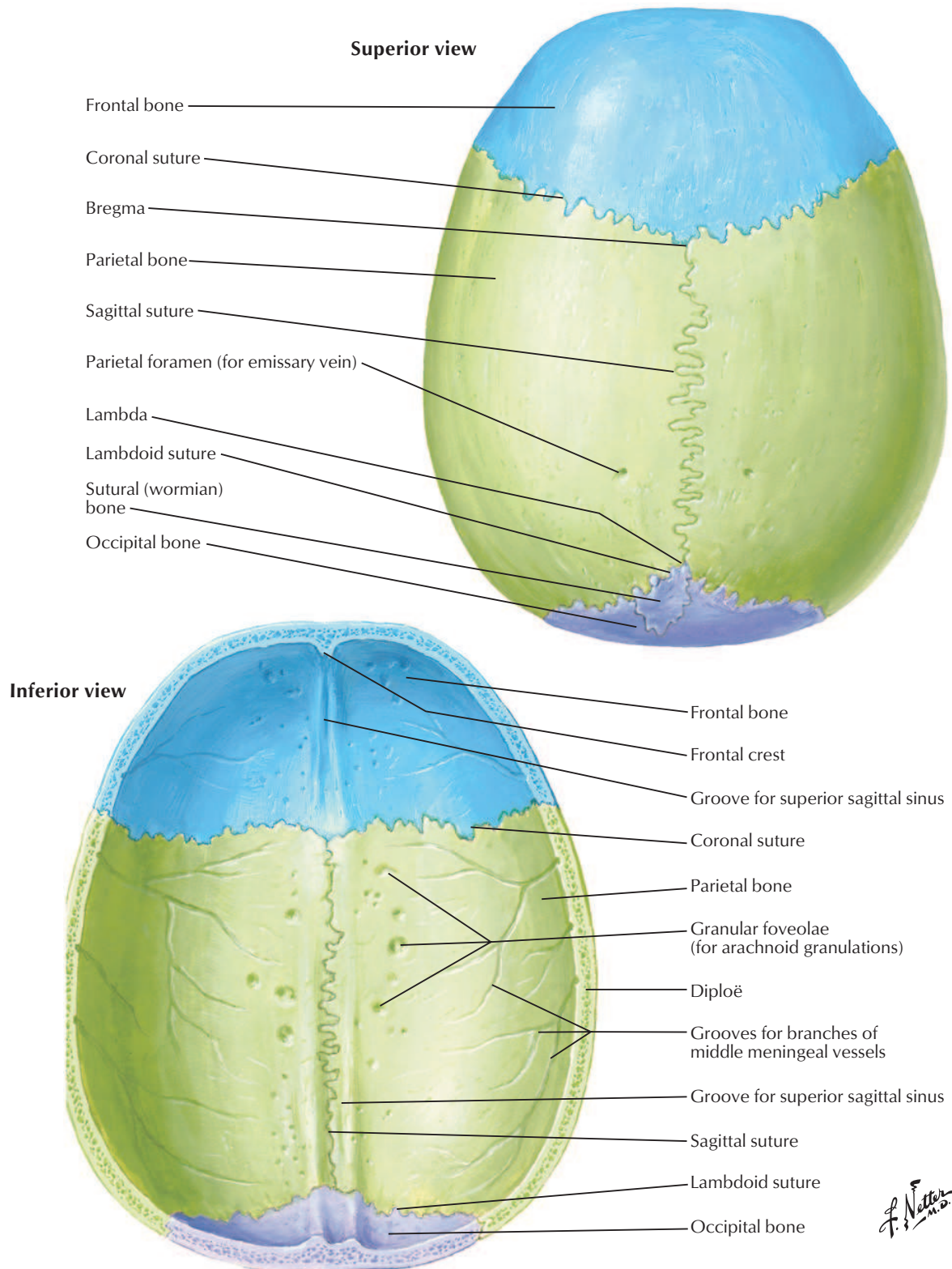


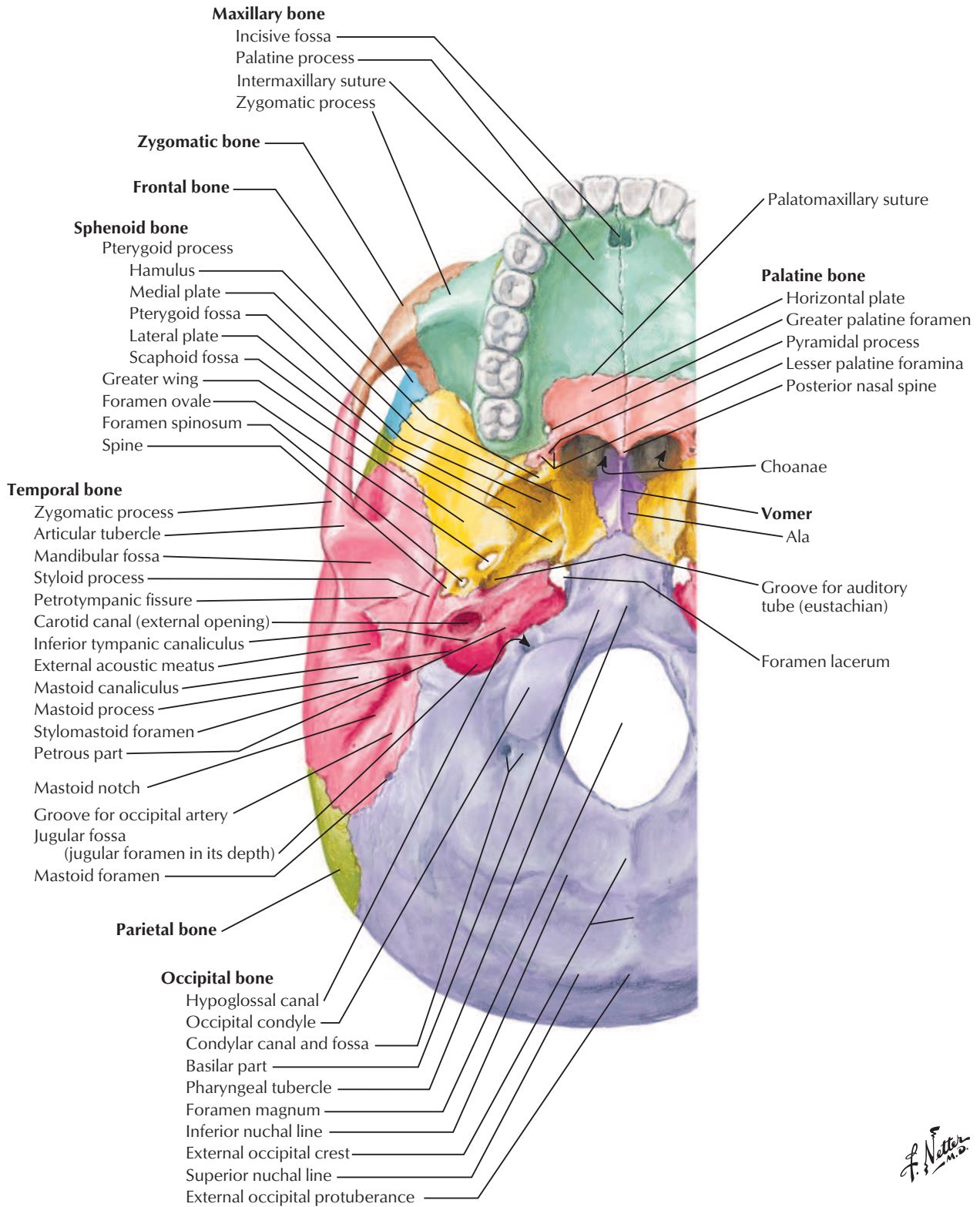
Skull: Lateral View

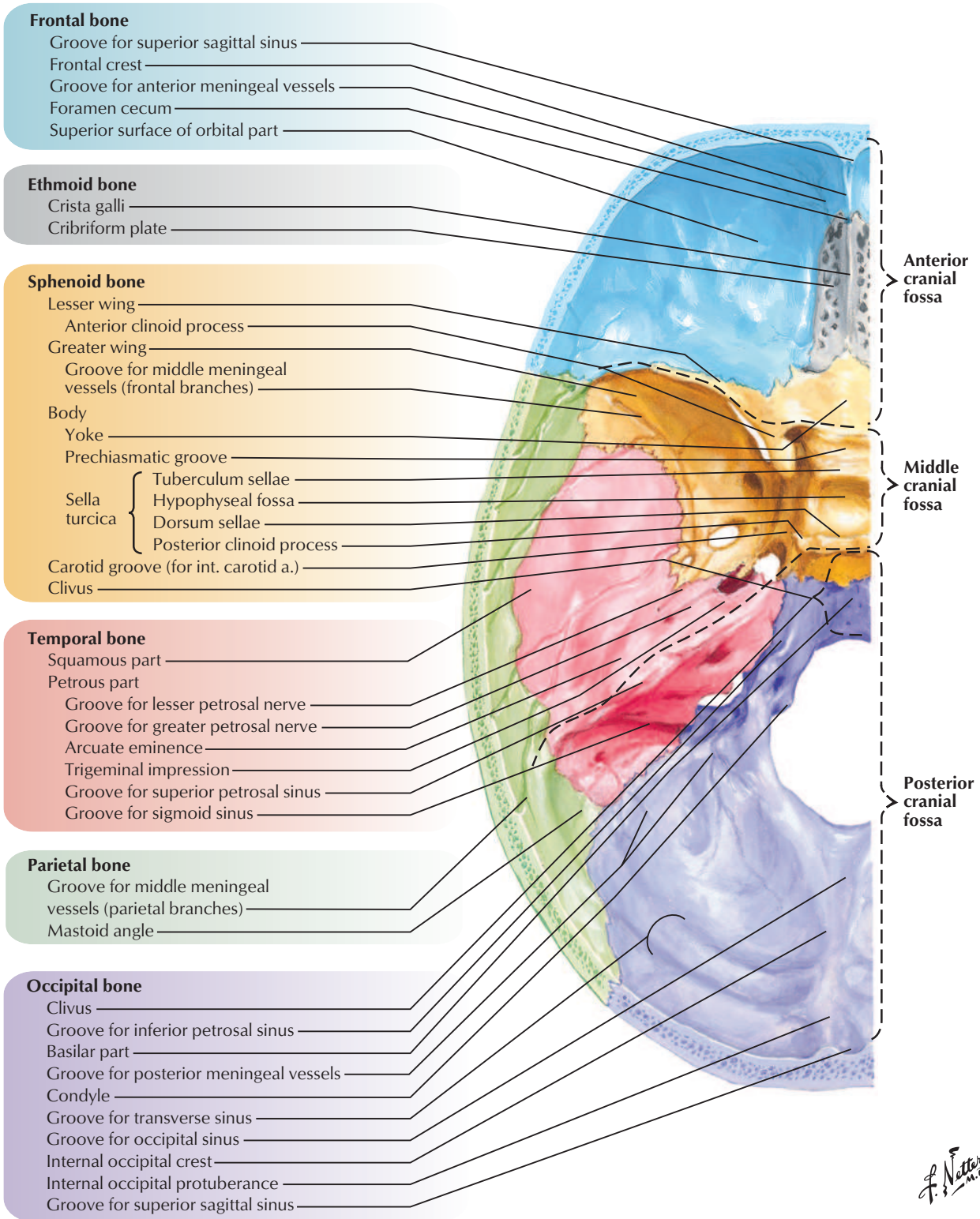
See also [Plates 14, 15, 22](#)

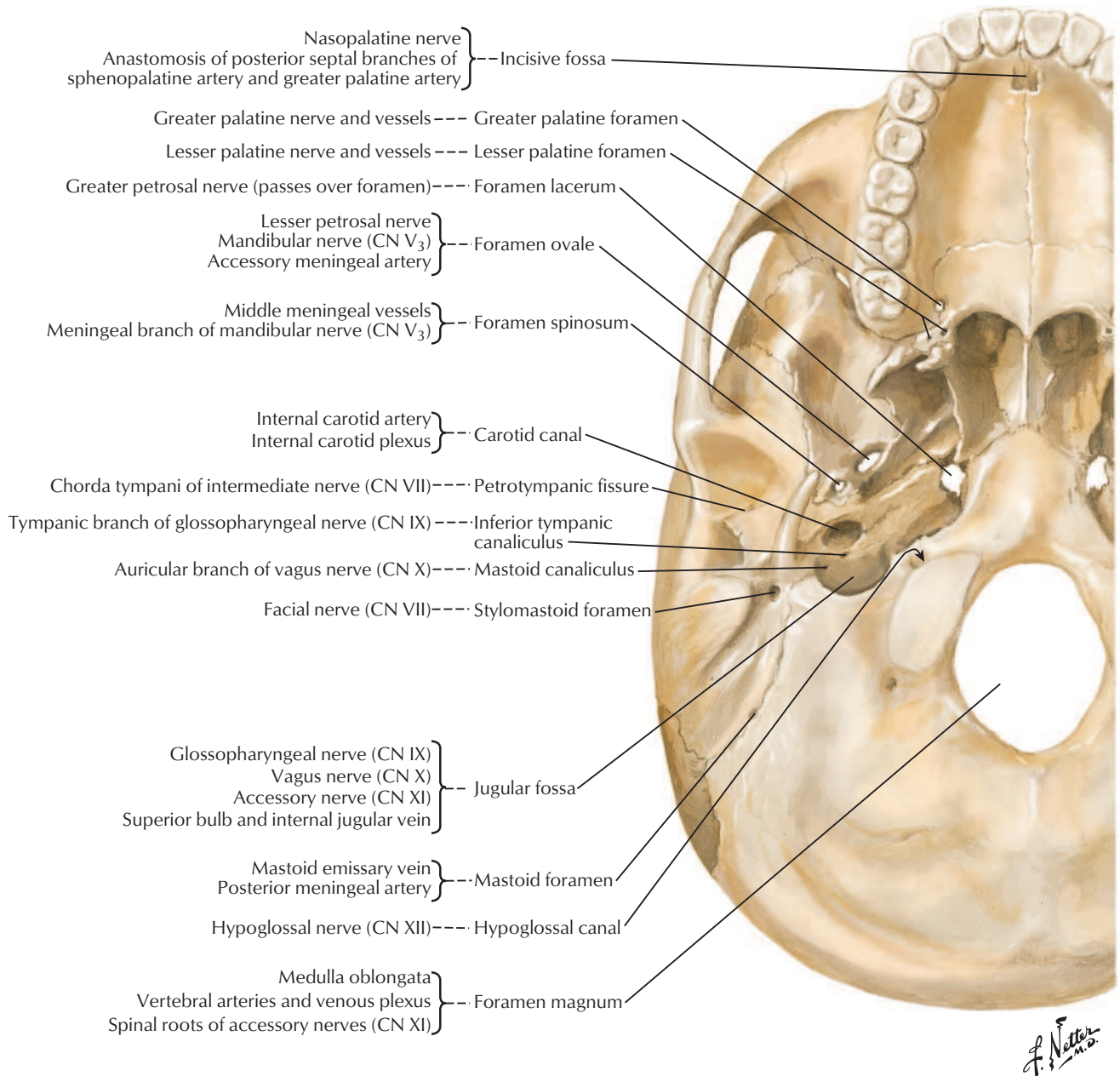



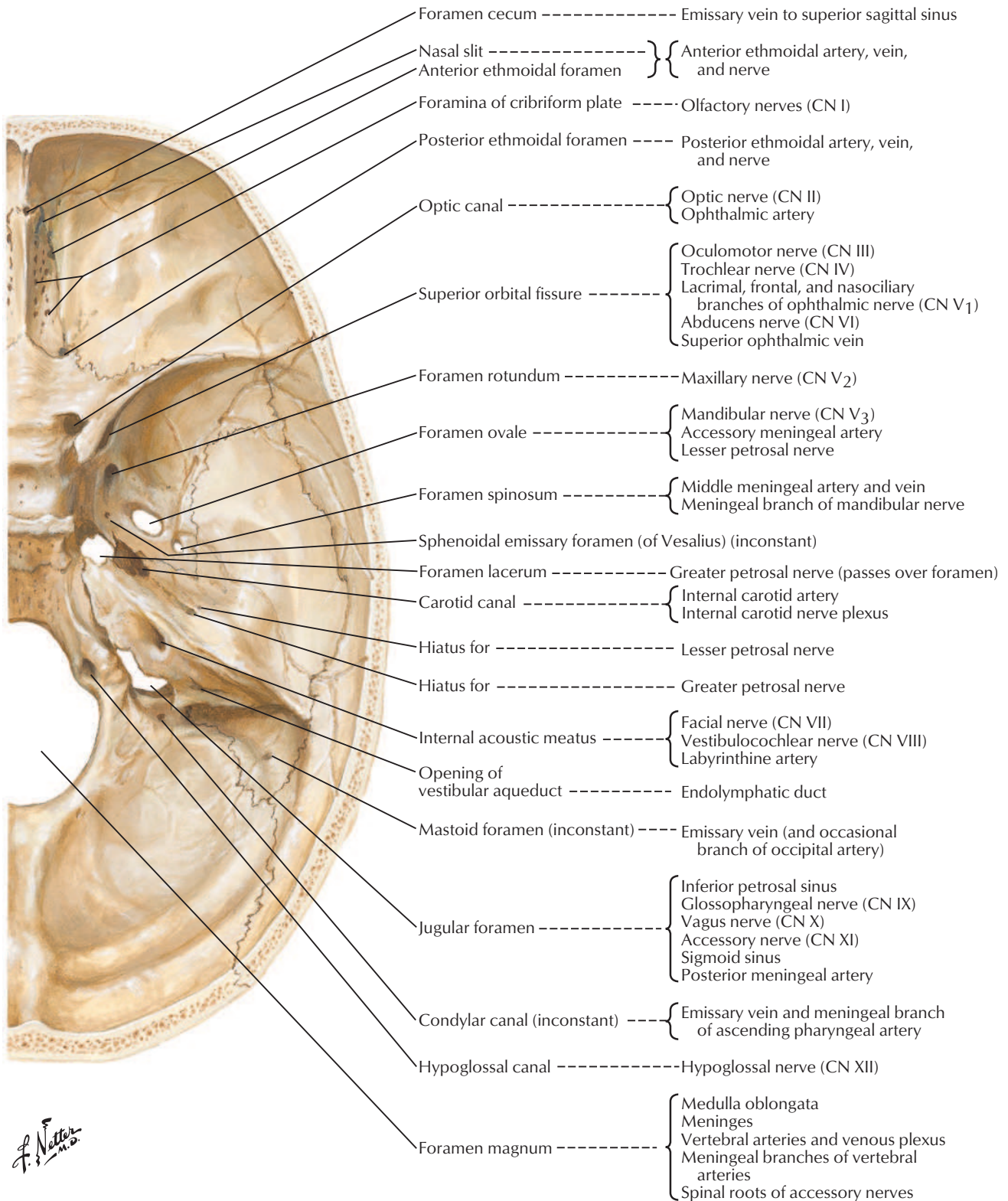
*Superficially, mastoid process forms posterior boundary.



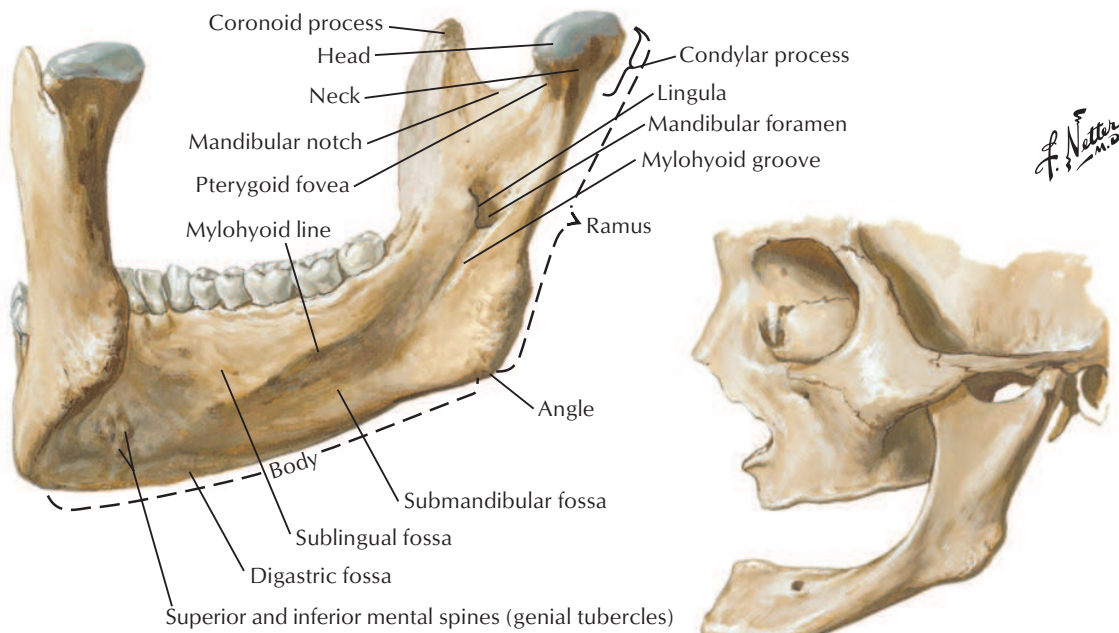
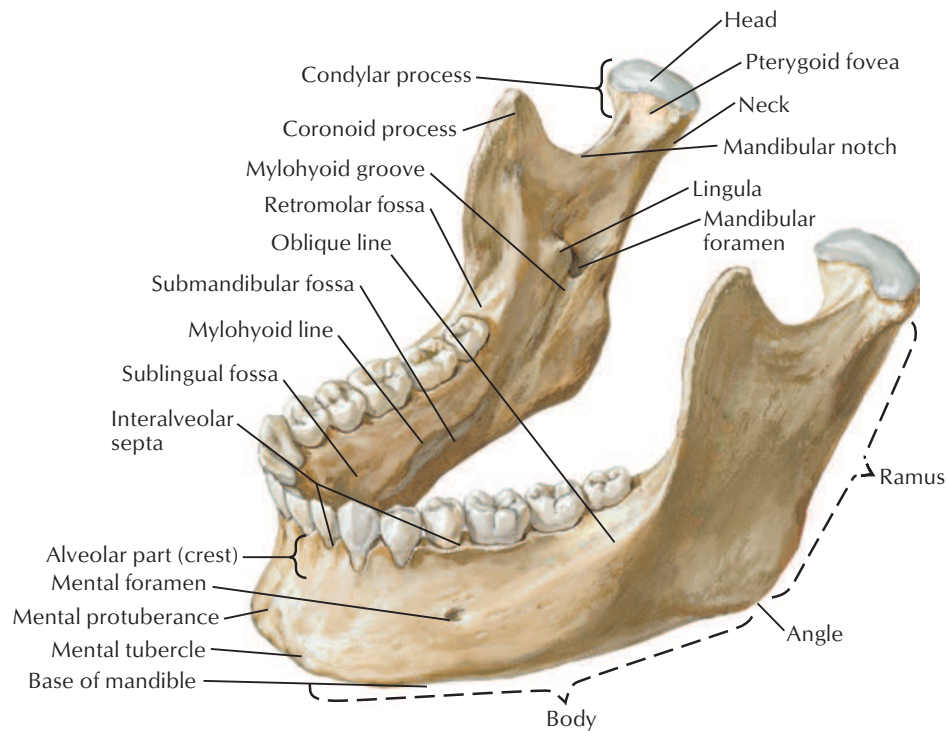






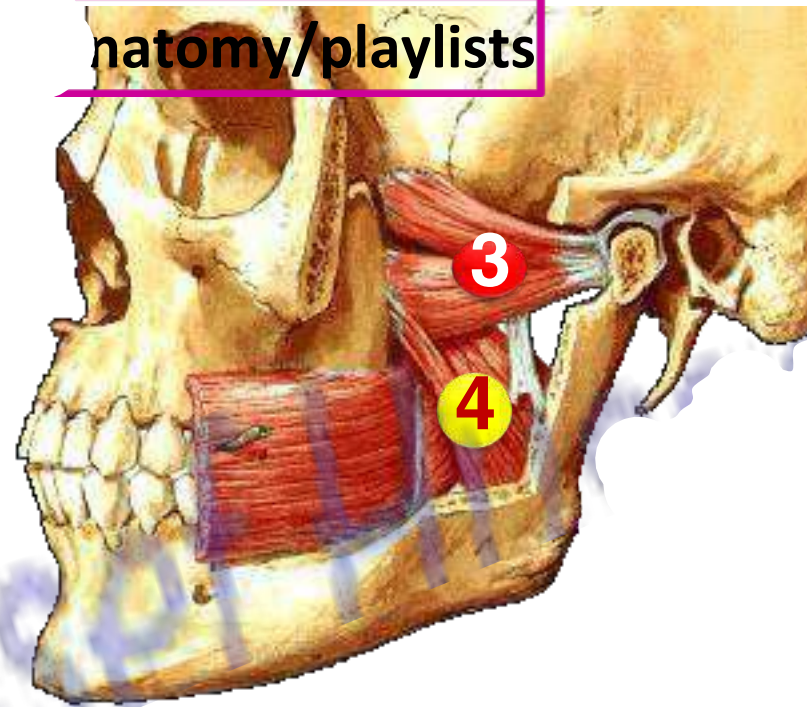
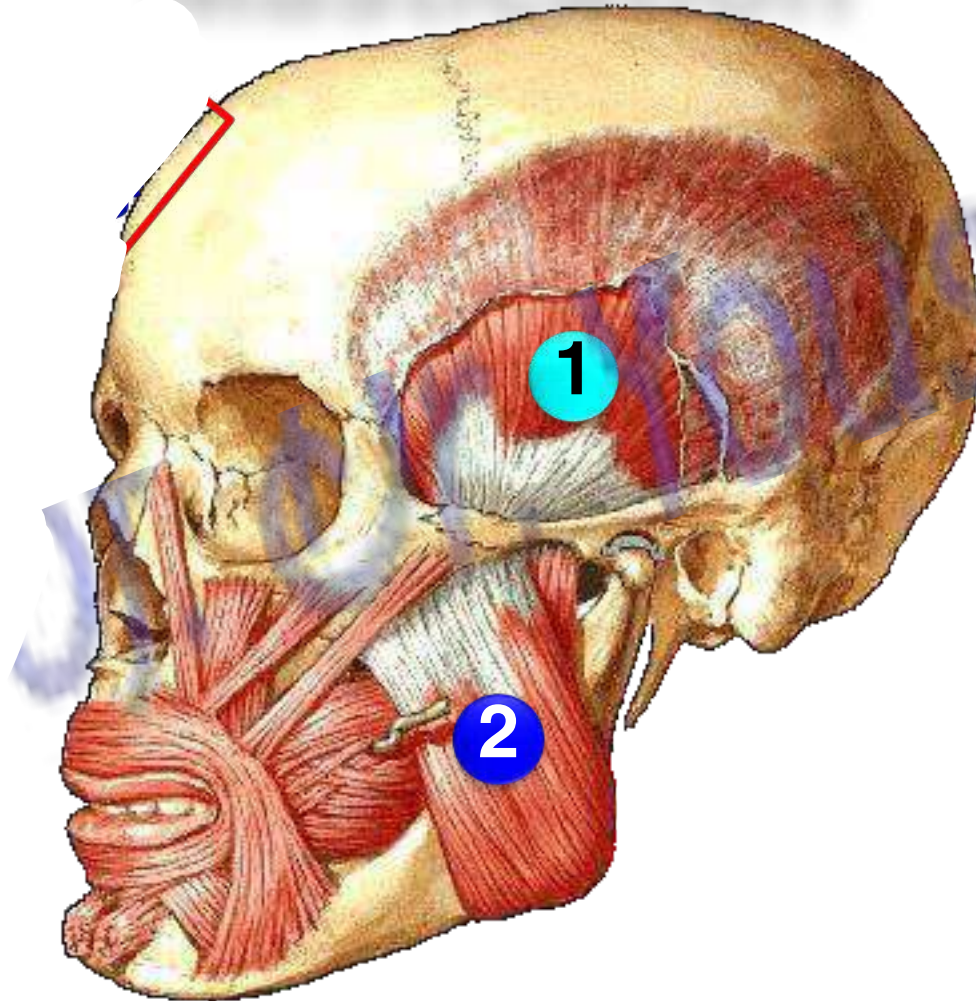


F. Netter M.D.



Mandible of aged person (edentulous)

Muscles of Mastication



1. Temporalis
2. Masseter
3. Lateral Pterygoid
4. Medial pterygoid

Temporalis

Origin From Temporal fossa and temporal fascia

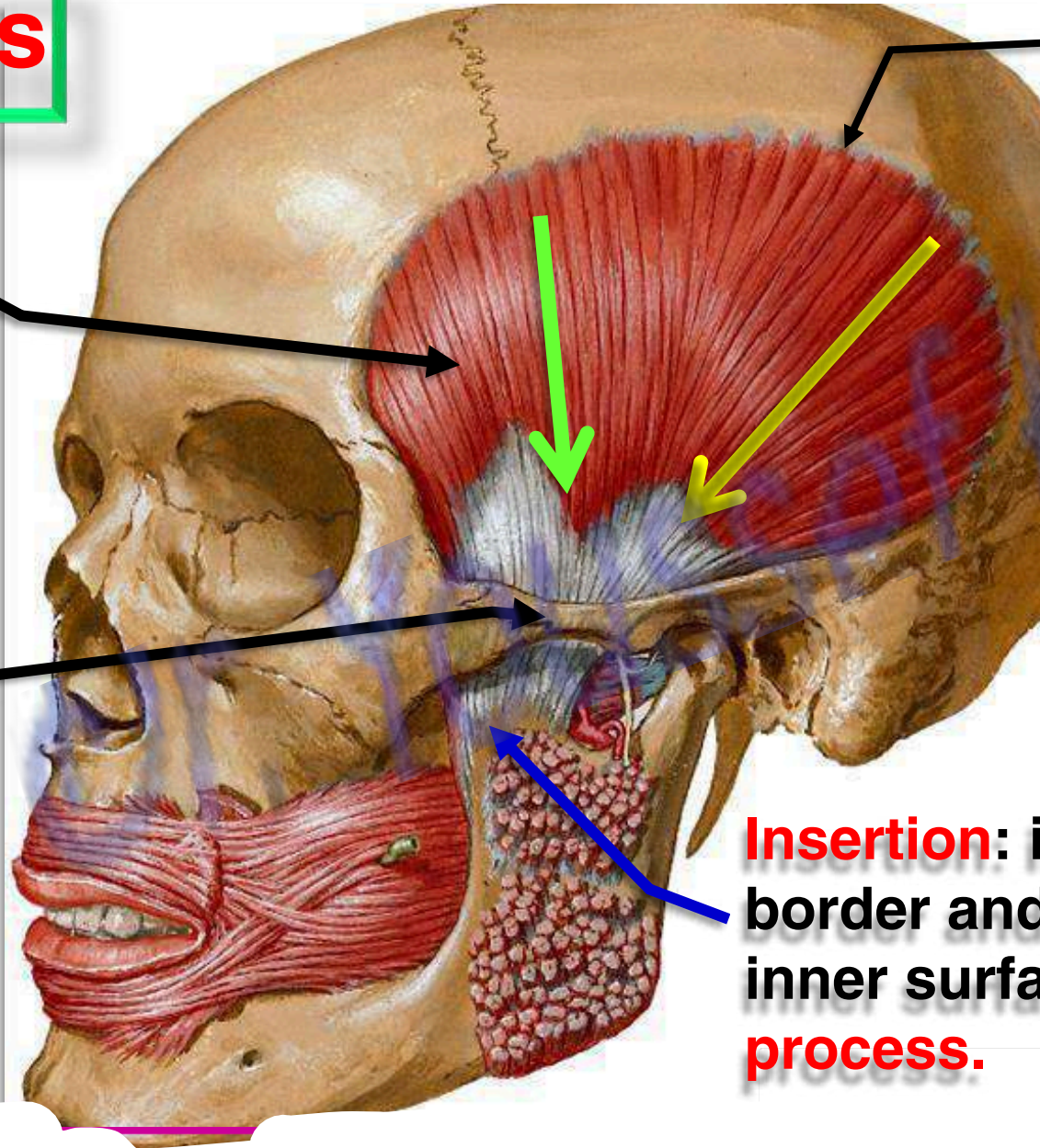
Zygomatic arch.

Fan shaped muscle

Origin From Inferior temporal line

- **Direction of fibres;**
 - **Anterior** fibers are vertical downward.
 - **Posterior** fibers are downward and forward.

Insertion: into the tip, anterior border and posterior border and inner surface of the **coronoid process.**



Masseter muscle

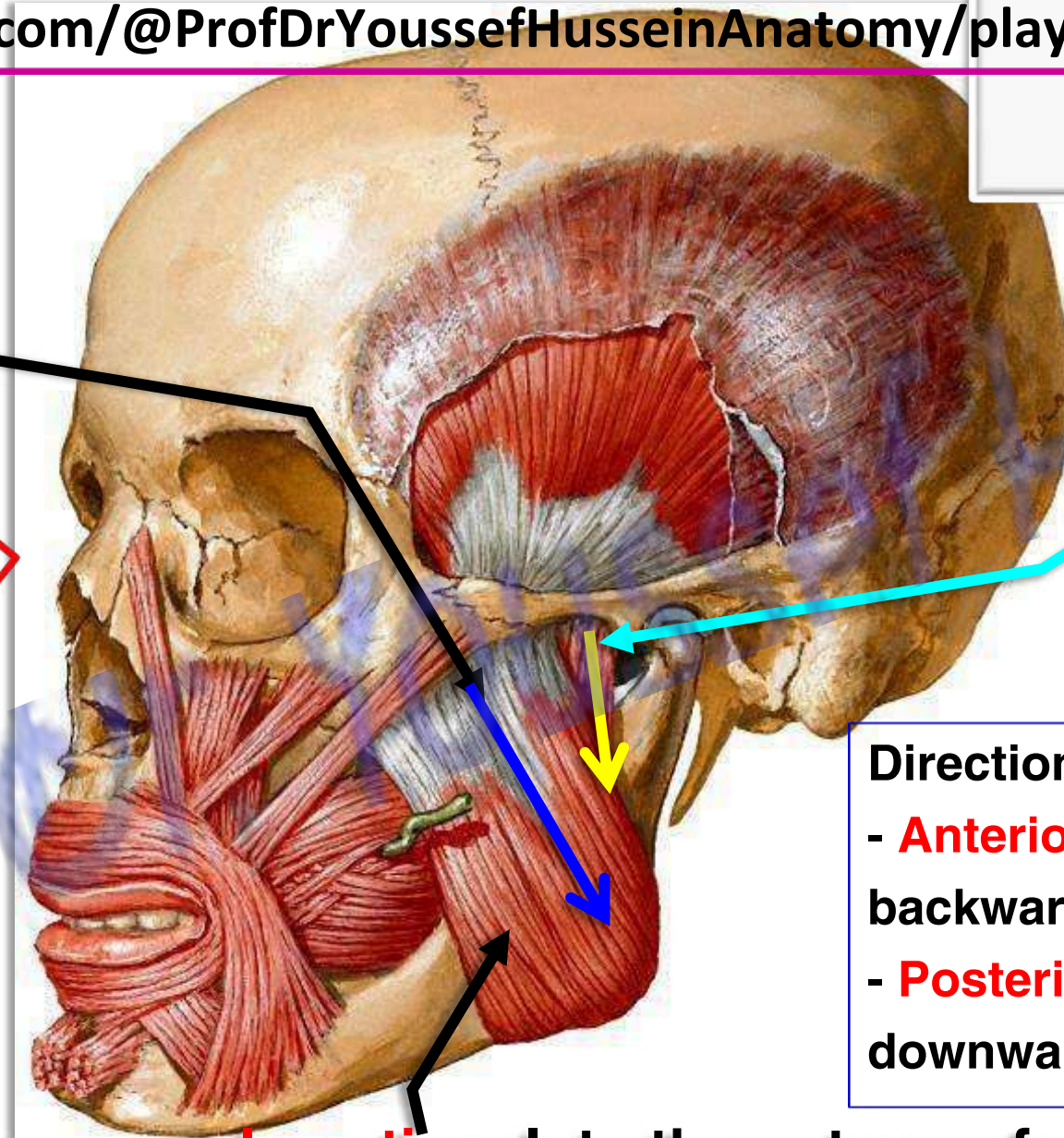
Origin: Superficial fibers from lower border zygomatic arch

Origin: Deep fibers from deep surface of zygomatic arch

Direction of the fibres:

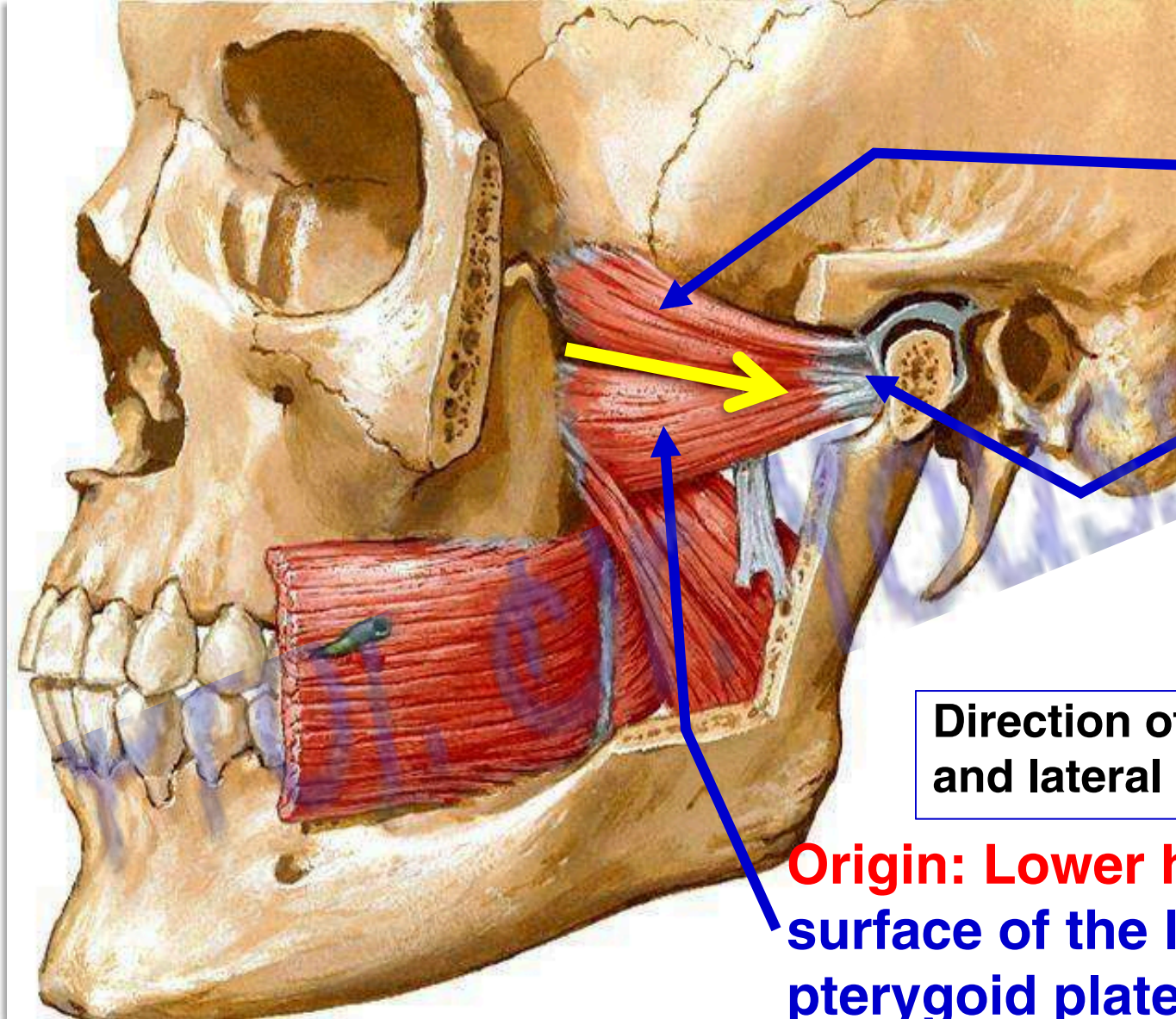
- **Anterior** directed downwards and backwards.
- **Posterior** directed vertically downwards.

Insertion: Into the outer surface of the ramus of the mandible



اليوتيوب د. يوسف حسين

Lateral Pterygoid muscle



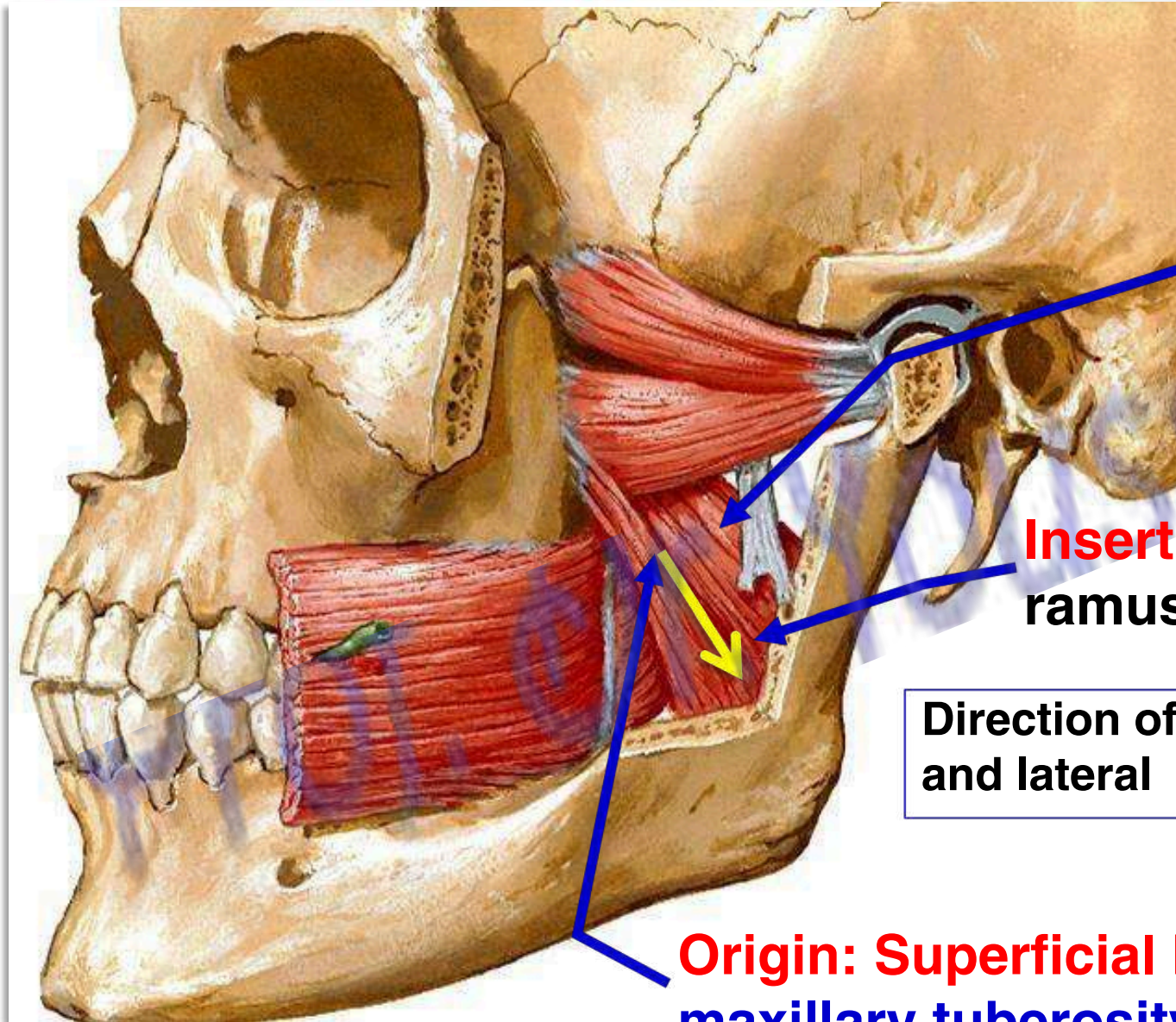
Origin: Upper head from infratemporal surface of greater wing of sphenoid

- **Insertion:** Pterygoid fovea on anterior aspect of neck of mandible.
- Capsule and articular disc of temporomandibular joint.

Direction of the fibres: horizontally backward and lateral

Origin: Lower head lateral surface of the lateral pterygoid plate

Medial Pterygoid muscle



Origin: Deep head from medial surface of lateral pterygoid plate

Insertion: Into the inner surface of the ramus and angle of the mandible

Direction of the fibres: downward, backward and lateral

Origin: Superficial head from maxillary tuberosity

Deep Relations

Lateral pterygoid

3rd part of Maxillary artery

Buccal nerve

Between 2 heads

Inferior Relations

★ 1st part of maxillary artery

2nd part of maxillary artery

Mandibular nerve
Middle meningeal artery

Otic ganglion

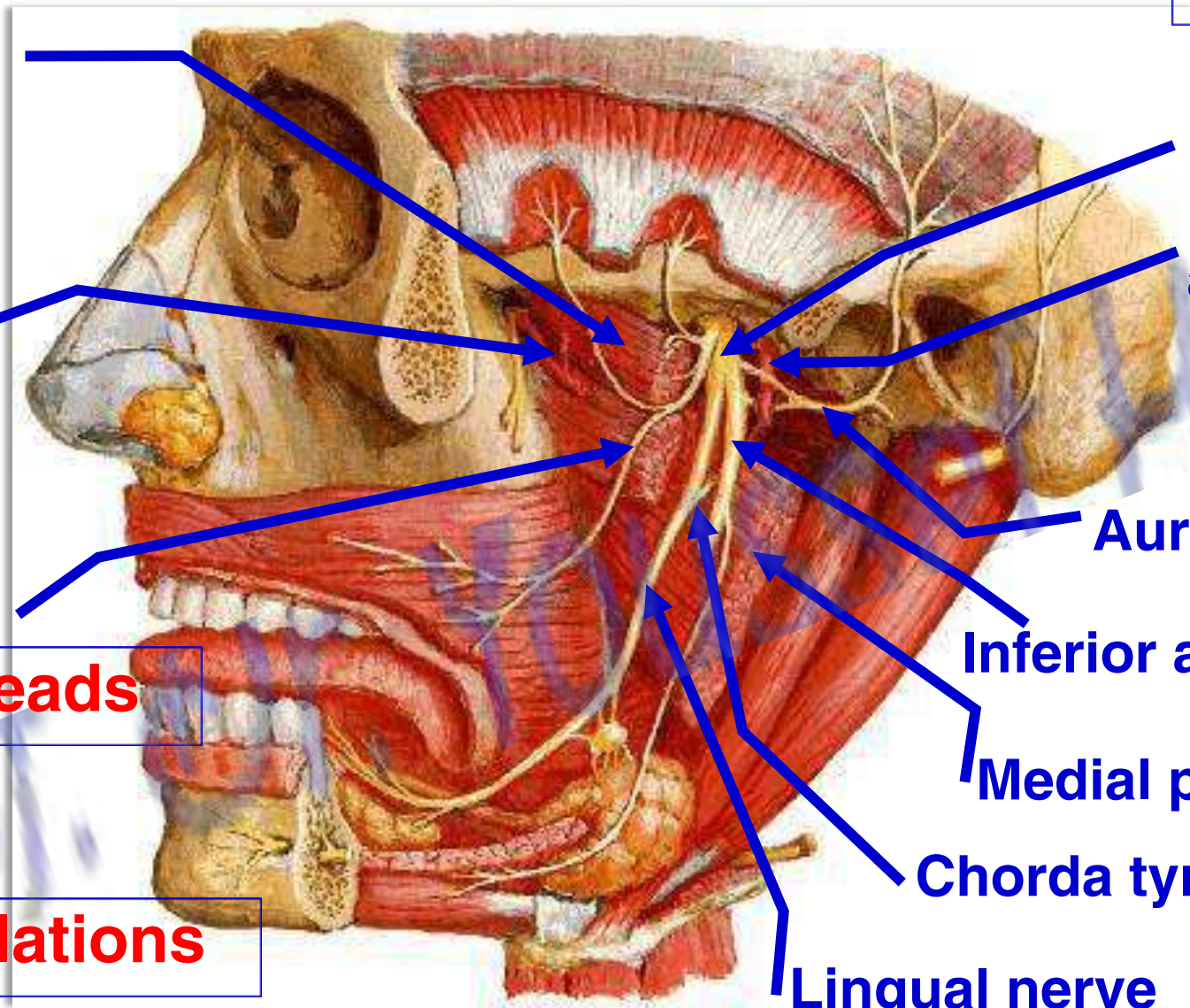
Auriculotemporal nerve

Inferior alveolar nerve ★

Medial pterygoid muscle

Chorda tympani

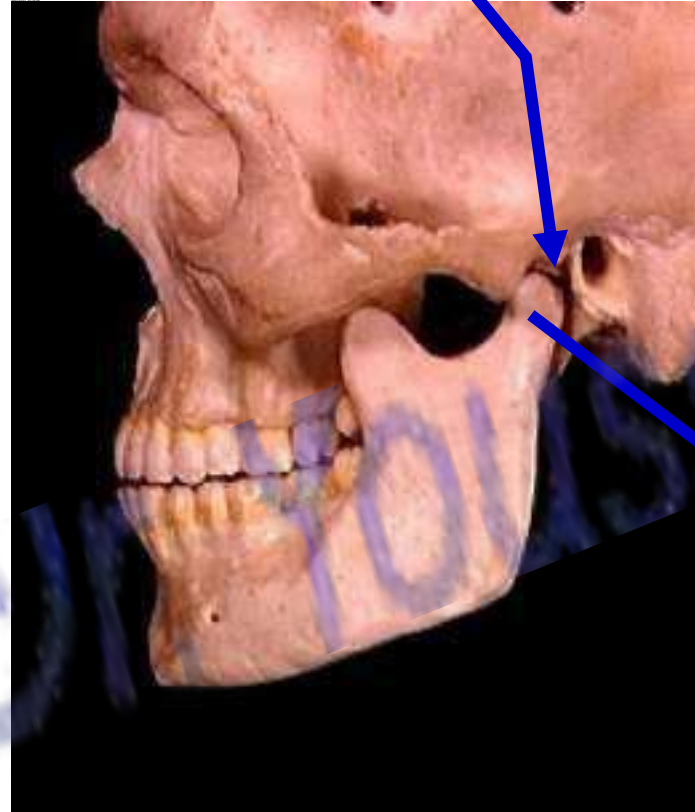
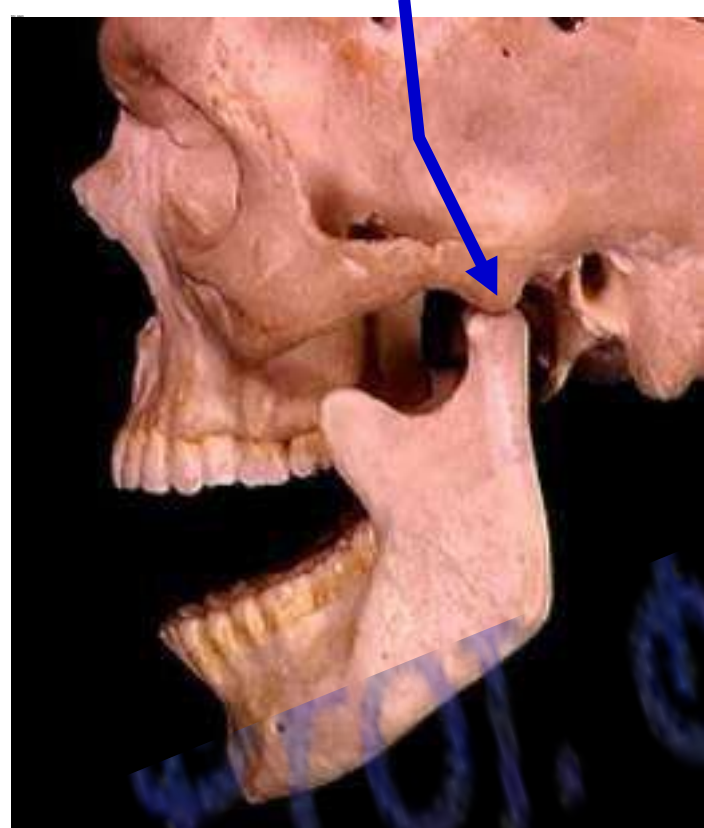
Lingual nerve ★



Type: synovial joint of **Condylloid variety**

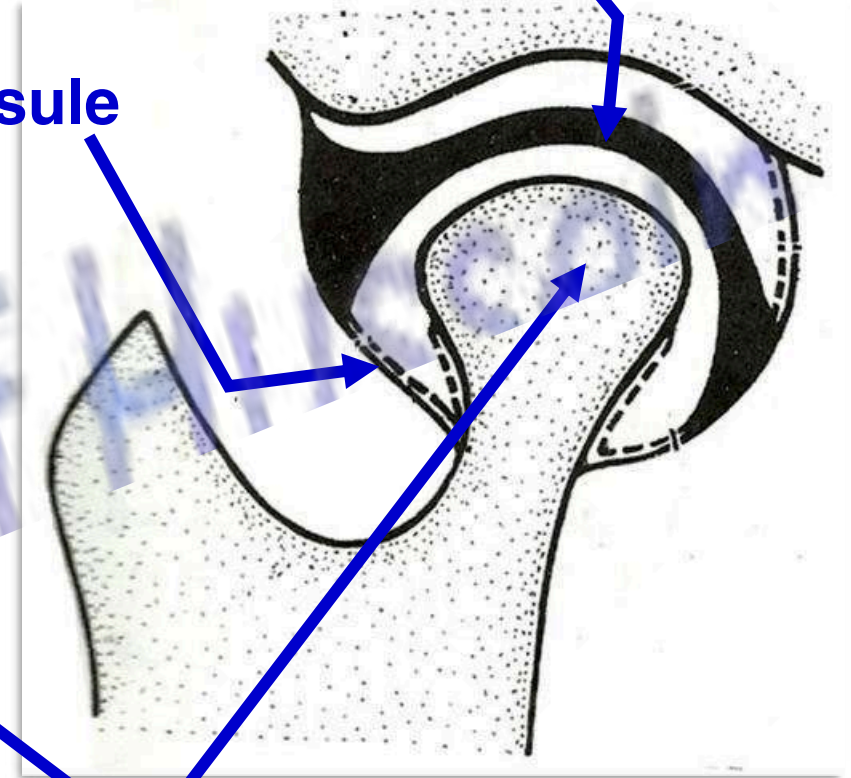
Articular tubercle

Mandibular fossa



Capsule

Articular disc



Head of mandible

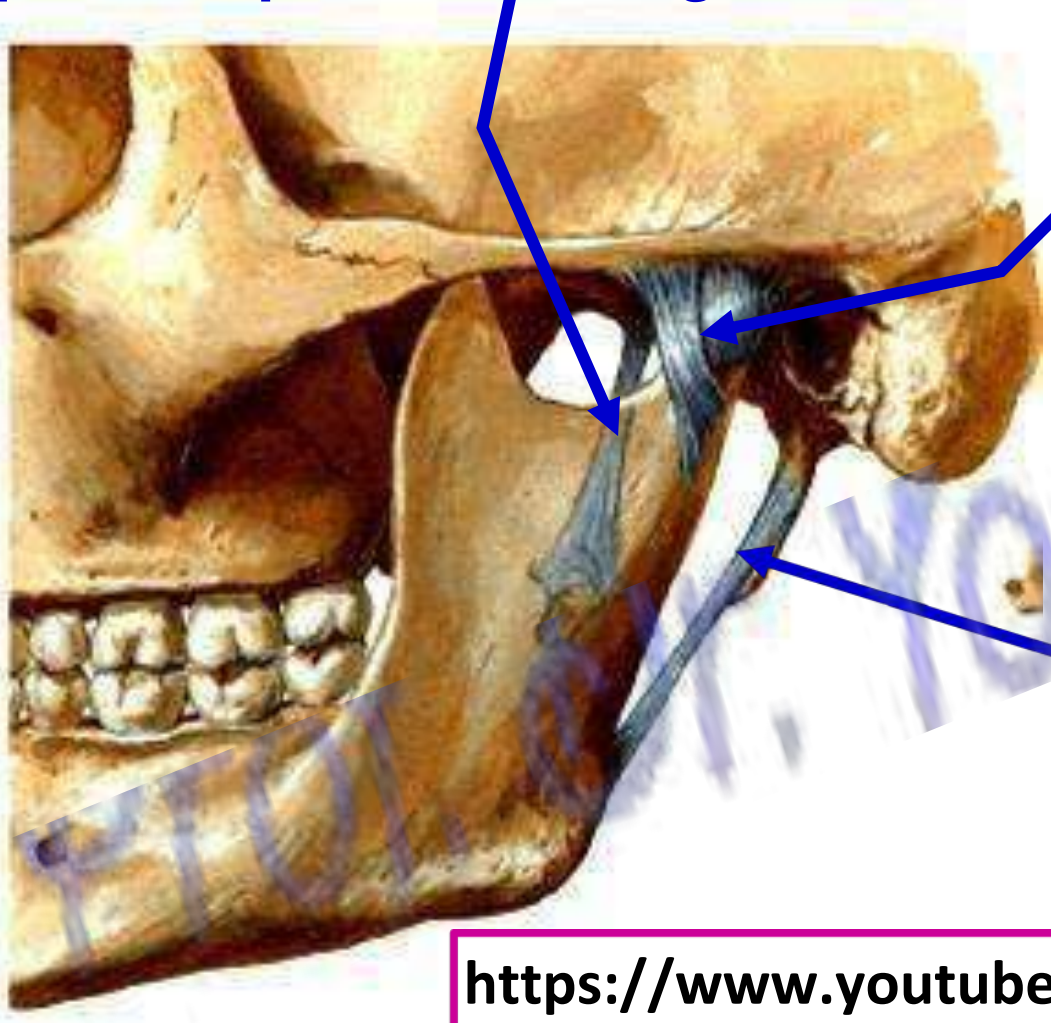
dr_youssefhussein@yahoo.com

- **Articular surfaces:** a) Head (condyle) of the mandible.
b) Articular (glenoid) fossa and articular tubercle of temporal bone.
c) Articular disc divided the cavity into upper and lower parts.
- **Capsule:** attached around the articular surfaces. It is lined by synovial membrane.

2- Sphenomandibular ligament from spine of sphenoid to lingula

3- Tempromandibular ligament from articular eminence (root of zygomatic arch) to lateral side of neck of mandible

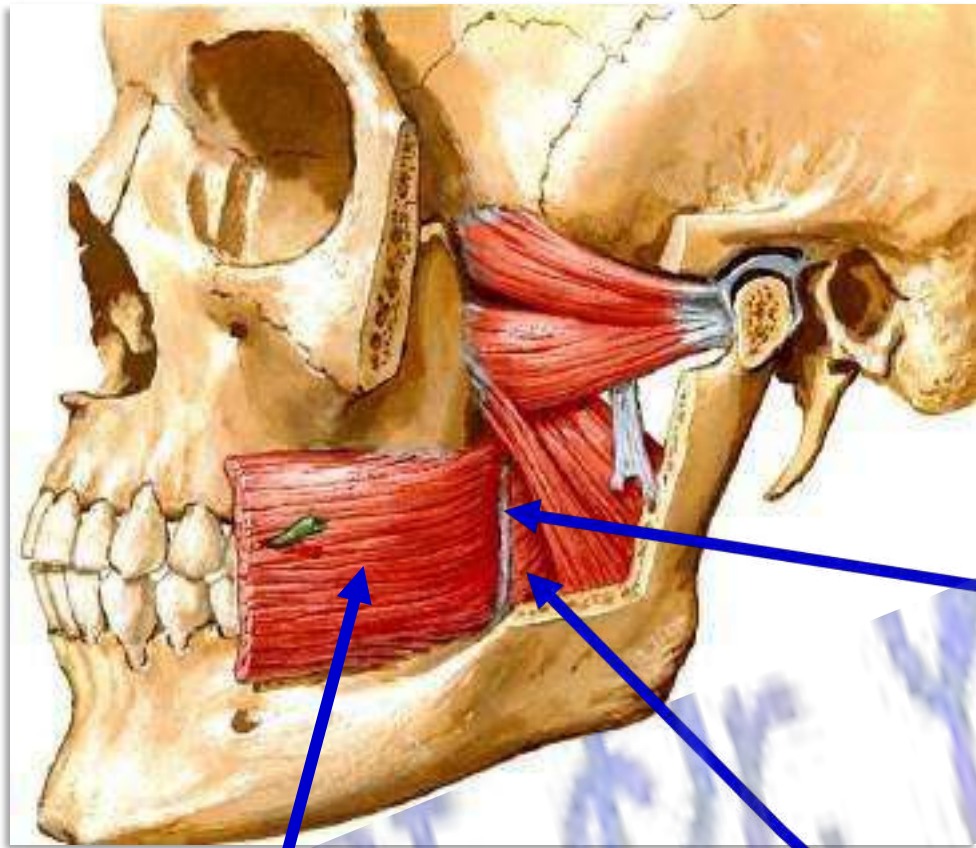
1- Stylomandibular ligament from styloid process to angle of mandible, separates parotid gland from submandibular gland



اليوثيوب د. يوسف حسين

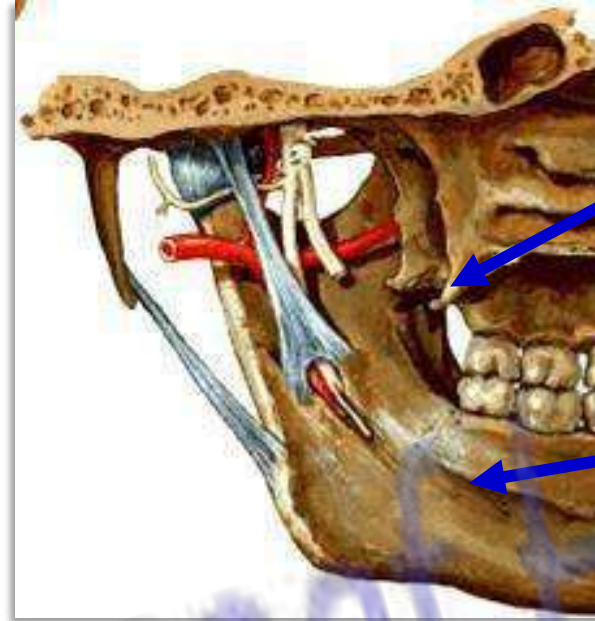
<https://www.youtube.com/@ProfDrYoussefHusseinaAnatomy/playlists>

Ligaments of temporomandibular joint



Buccinator

Superior constrictor muscle of pharynx



Pterygoid hamulus

Mylohyoid line

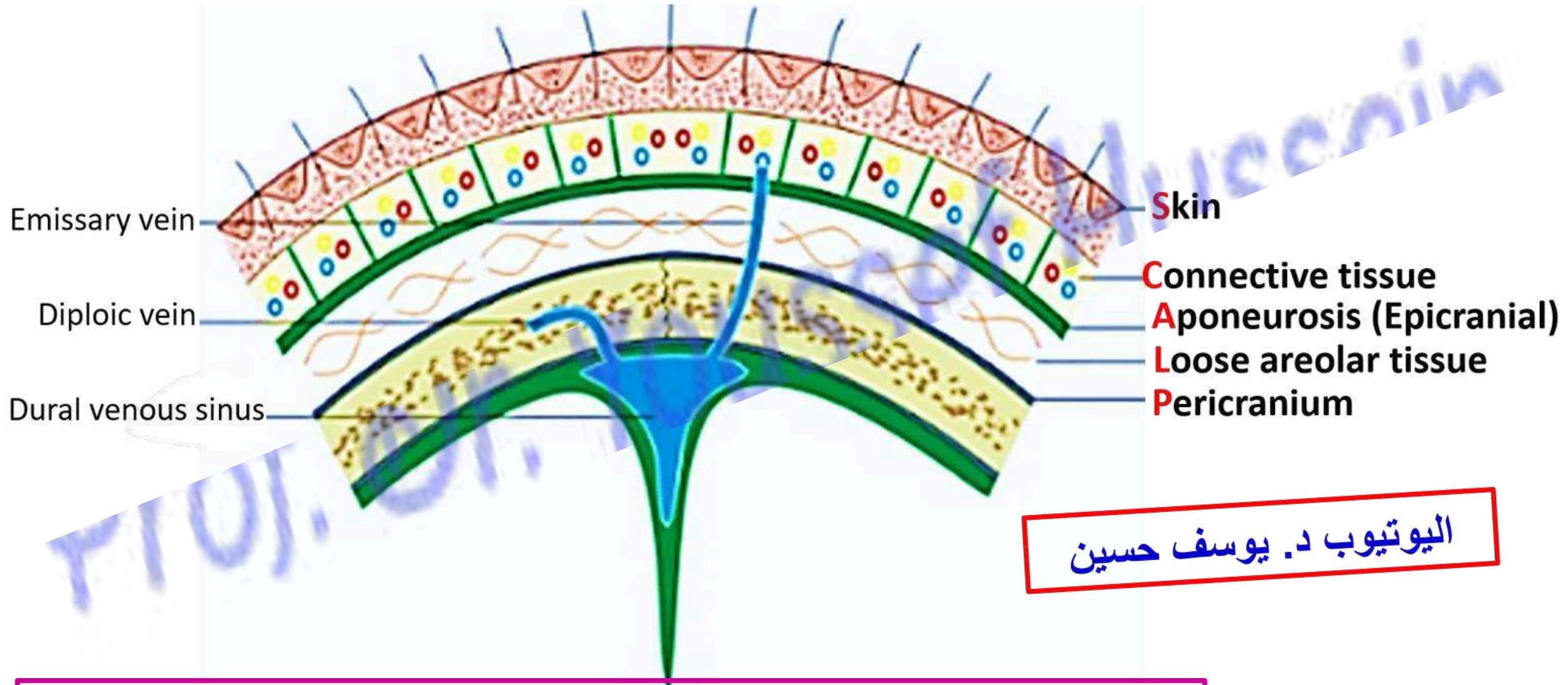
4- Pterygomandibular ligament: extends from **pterygoid hamulus** to the **posterior end of mylohyoid line** of mandible.

-It gives originto buccinator and superior constrictor muscle of the pharynx.

dr_youssefhussein@yahoo.com

Ligaments of temporomandibular joint

Layers of the scalp : 5 layers (S.C.A.L.P.)



اليوثيوب د. يوسف حسين

Epicranial aponeurosis

Occipitofrontalis Muscle

Frontal belly

**Skin of the eye
brow and root
of the nose**

Occipital belly

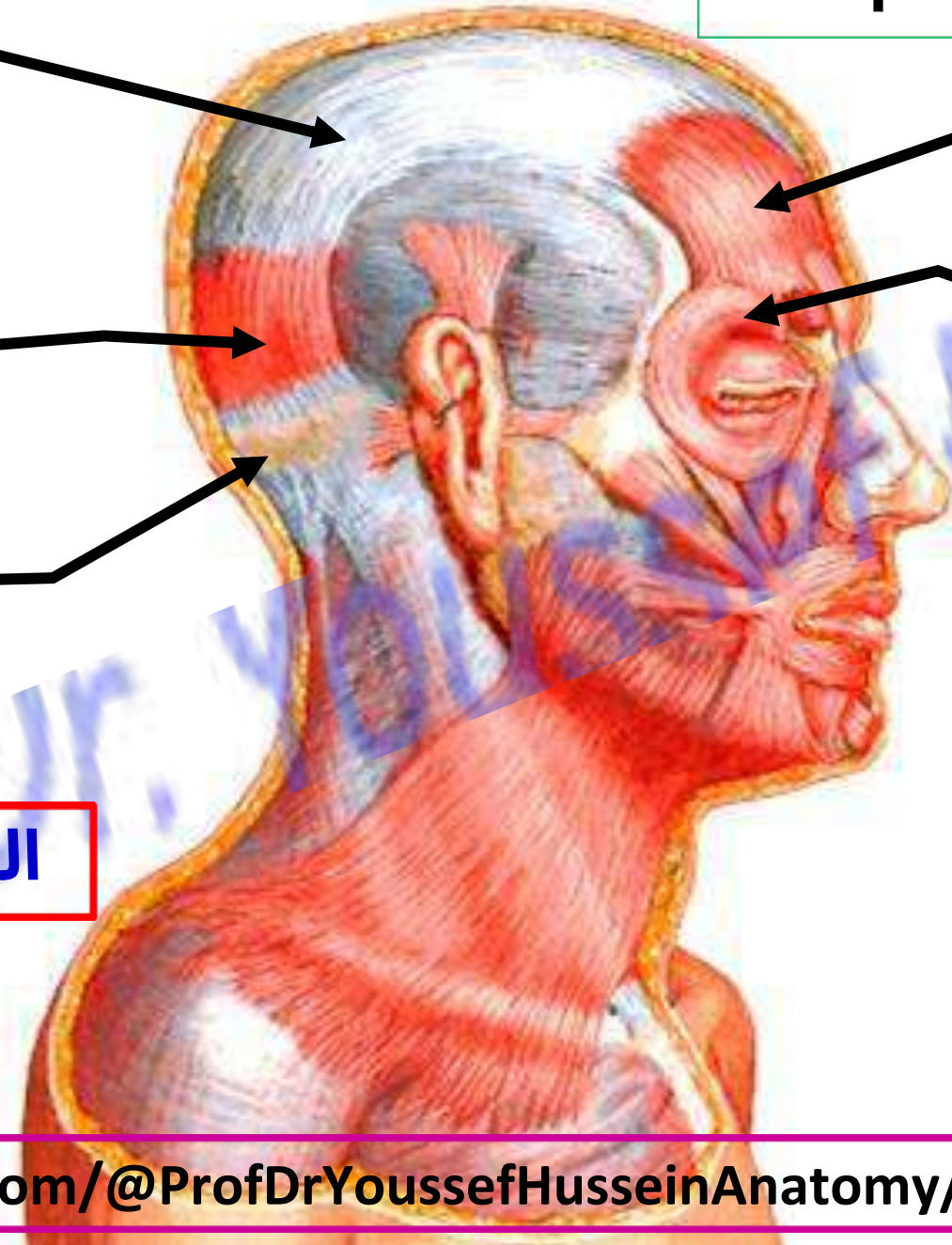
No bony attachment

**Nerve supply is facial
nerve (2nd pharyngeal
arch)**

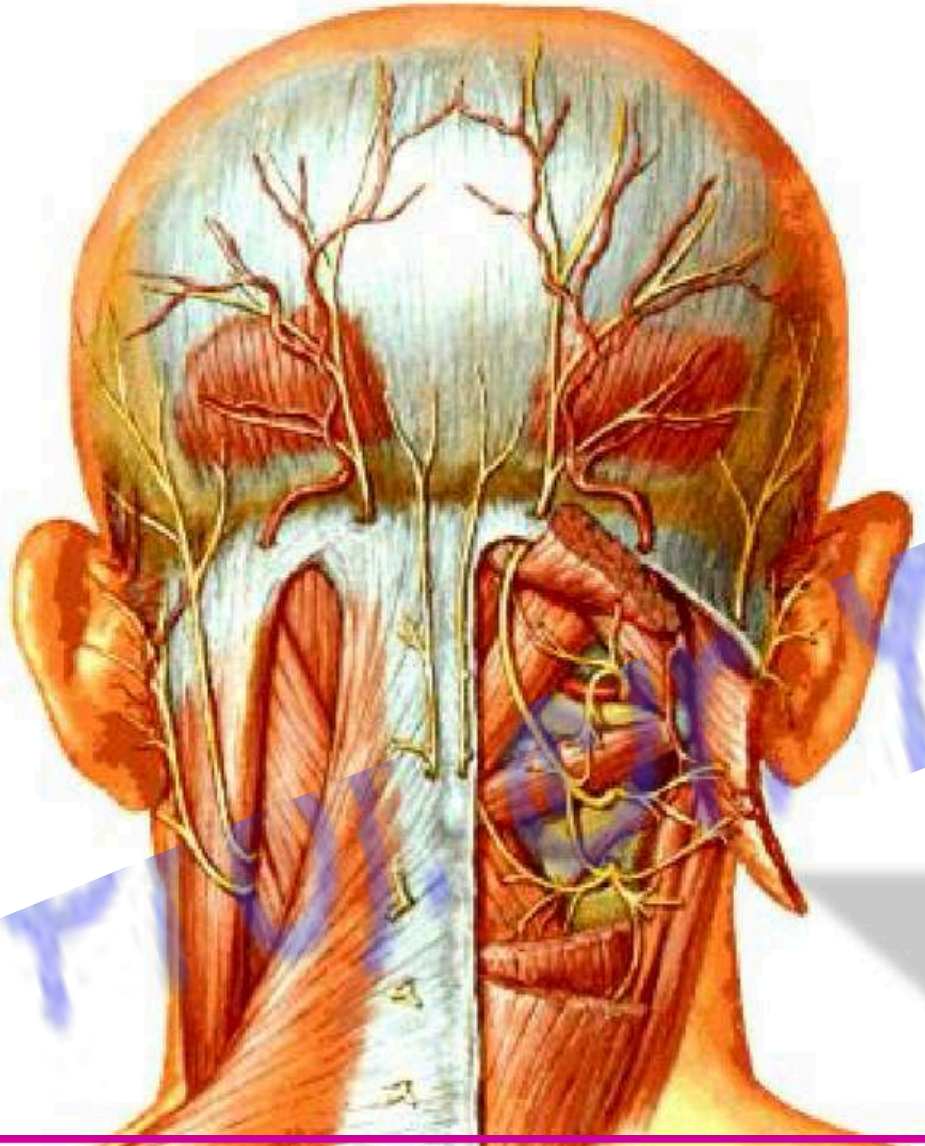
**Highest nuchal
line**

البيوتوب د. يوسف حسين

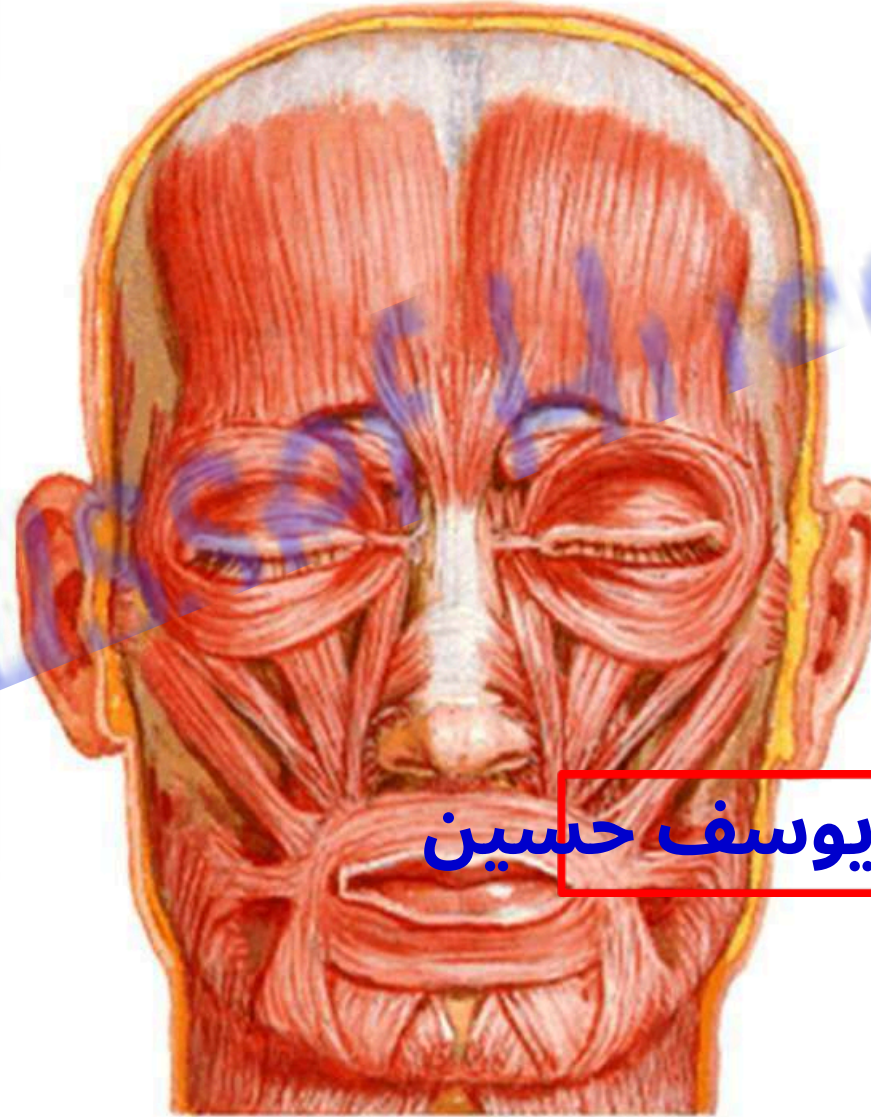<https://www.youtube.com/@ProfDrYoussefHusseinAnatomy/playlists>



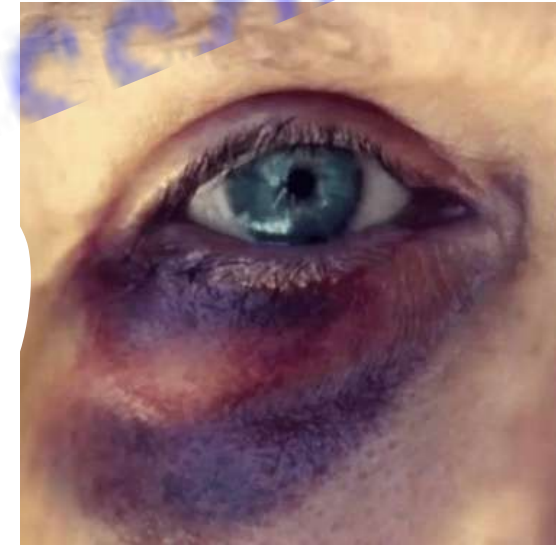Occipital bellies



Frontal bellies



اليوتيوب د. يوسف حسين



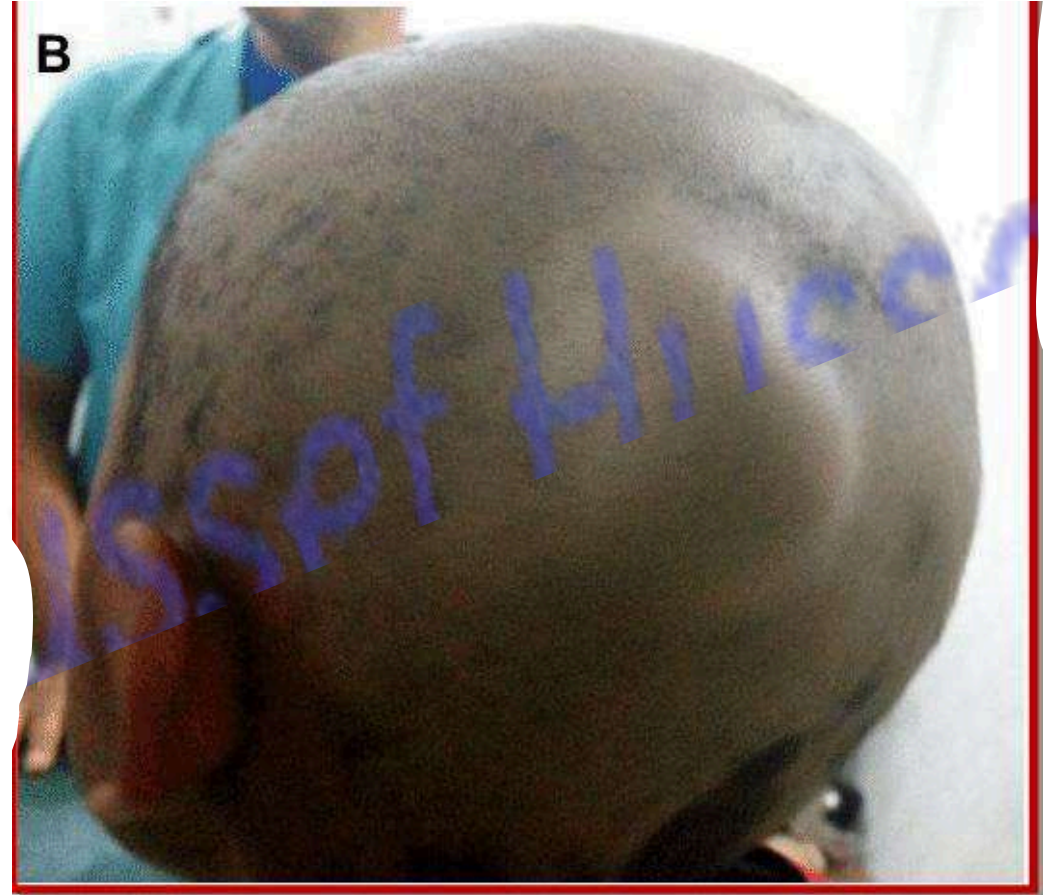البيوتوب د. يوسف حسين

diffuse

- The first 3 layers attached together and move on the underlying layer.

- Bleeding under the first 3 layers forms **hematoma** extending throughout the scalp and reach the upper eye lids (**Blackeye**).

- Fracture of the skull bone produces a localized hematoma because the periosteum is firmly attached to the sutures.

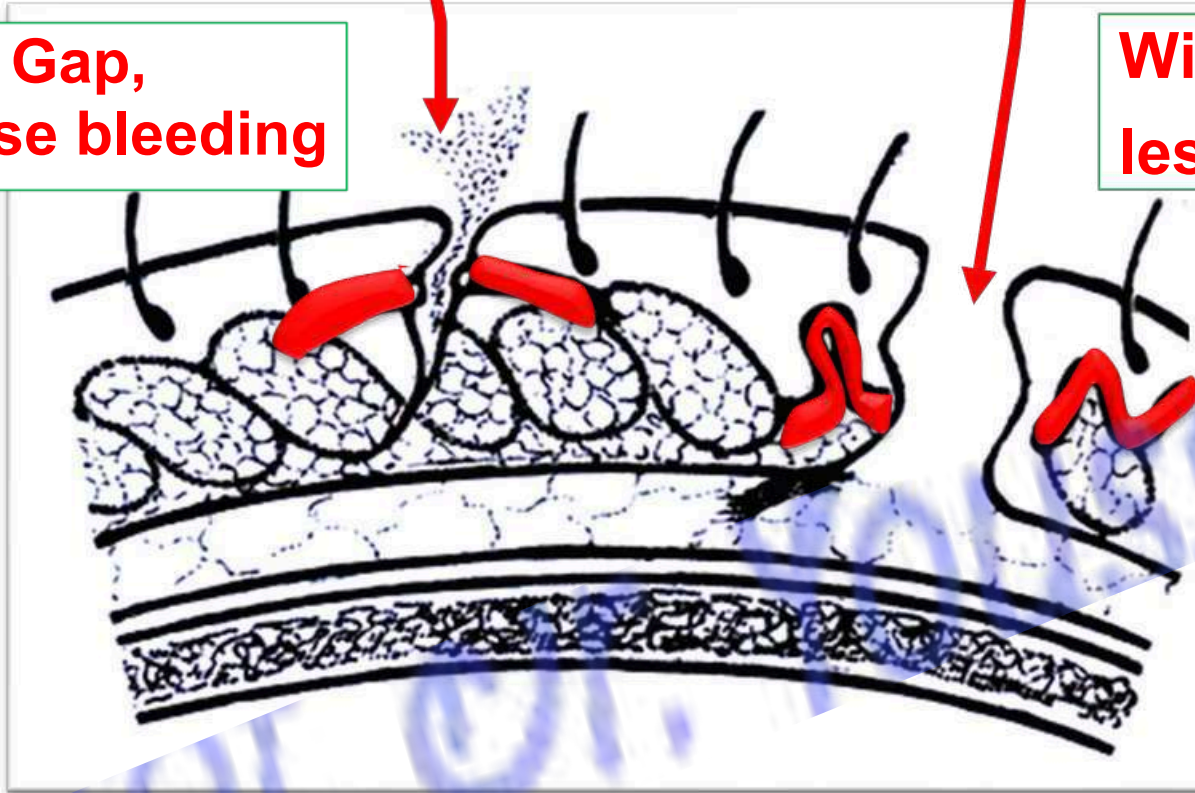
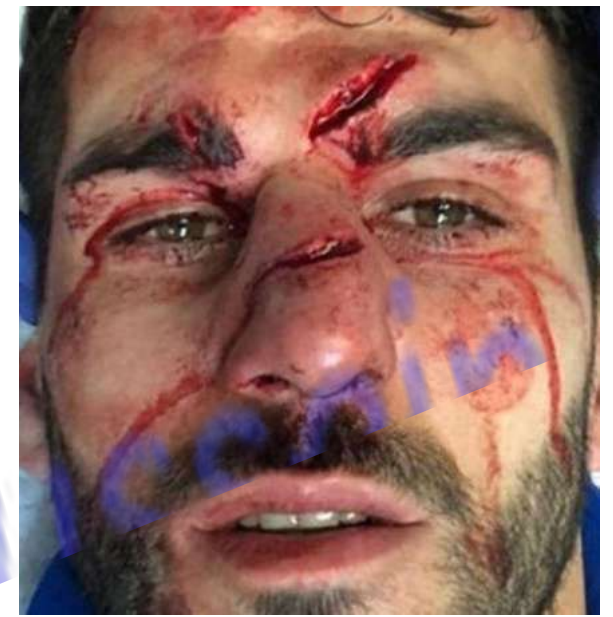

Cut wound in subcutaneous area

Cut wound involving epicranial aponeurosis

Small Gap,
Profuse bleeding

Wide Gap,
less bleeding



Horizontal Cut wound of The front of scalp leading to Wide Gap due to **retraction** of occipitofrontalis muscle

اليوتيوب د. يوسف حسين

<https://www.youtube.com/@ProfDrYoussefHusseinAnatomy/playlists>

Nerves in front auricle

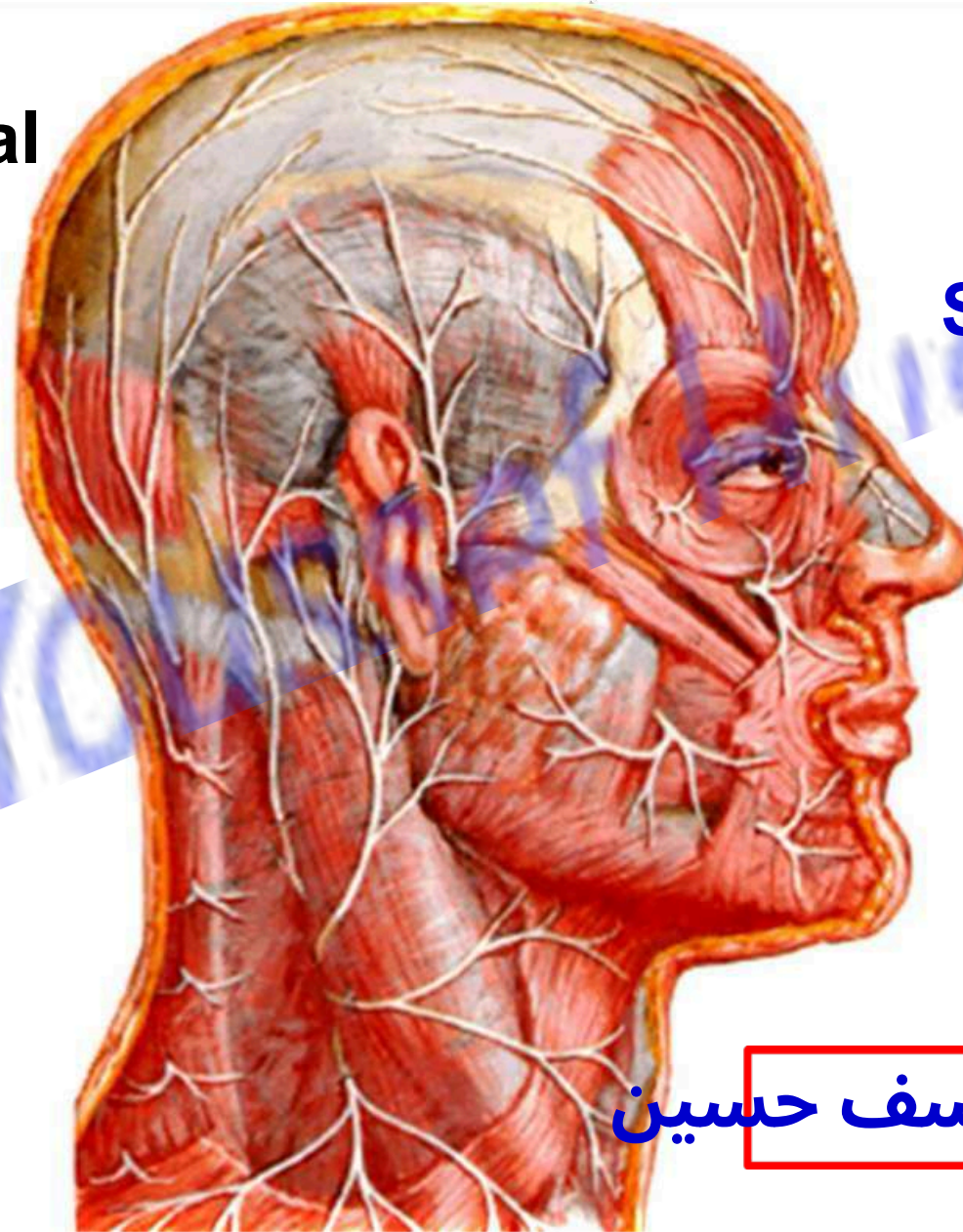
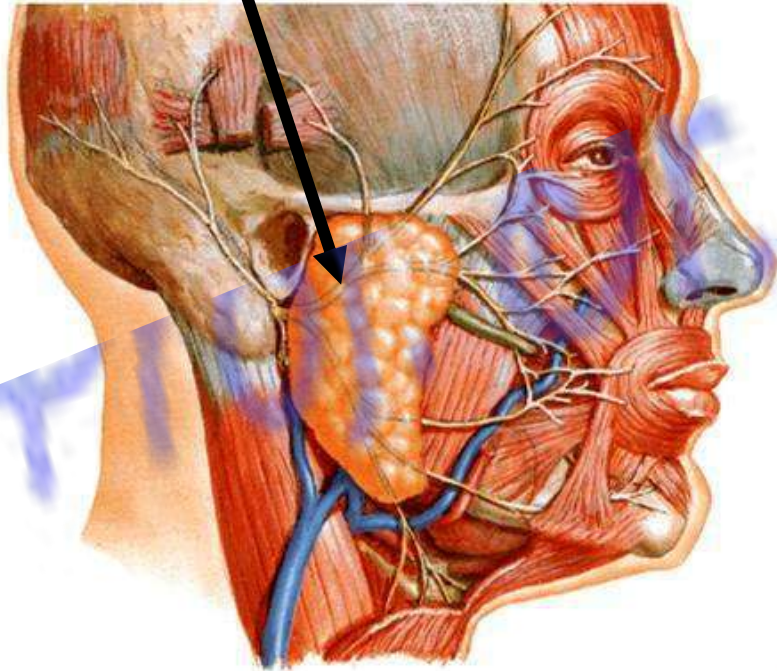
**Auriculotemporal
nerve S**

**Temporal nerve
M**

Zygomaticotemporal nerve S

**Supraorbital
nerve S**

**Supratrochlear
nerve S**

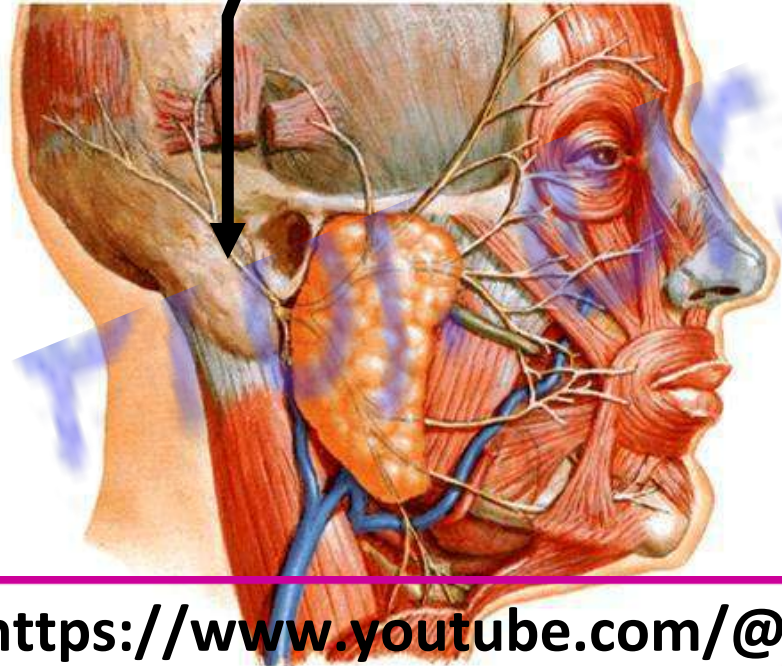


اليوتيوب د. يوسف حسين

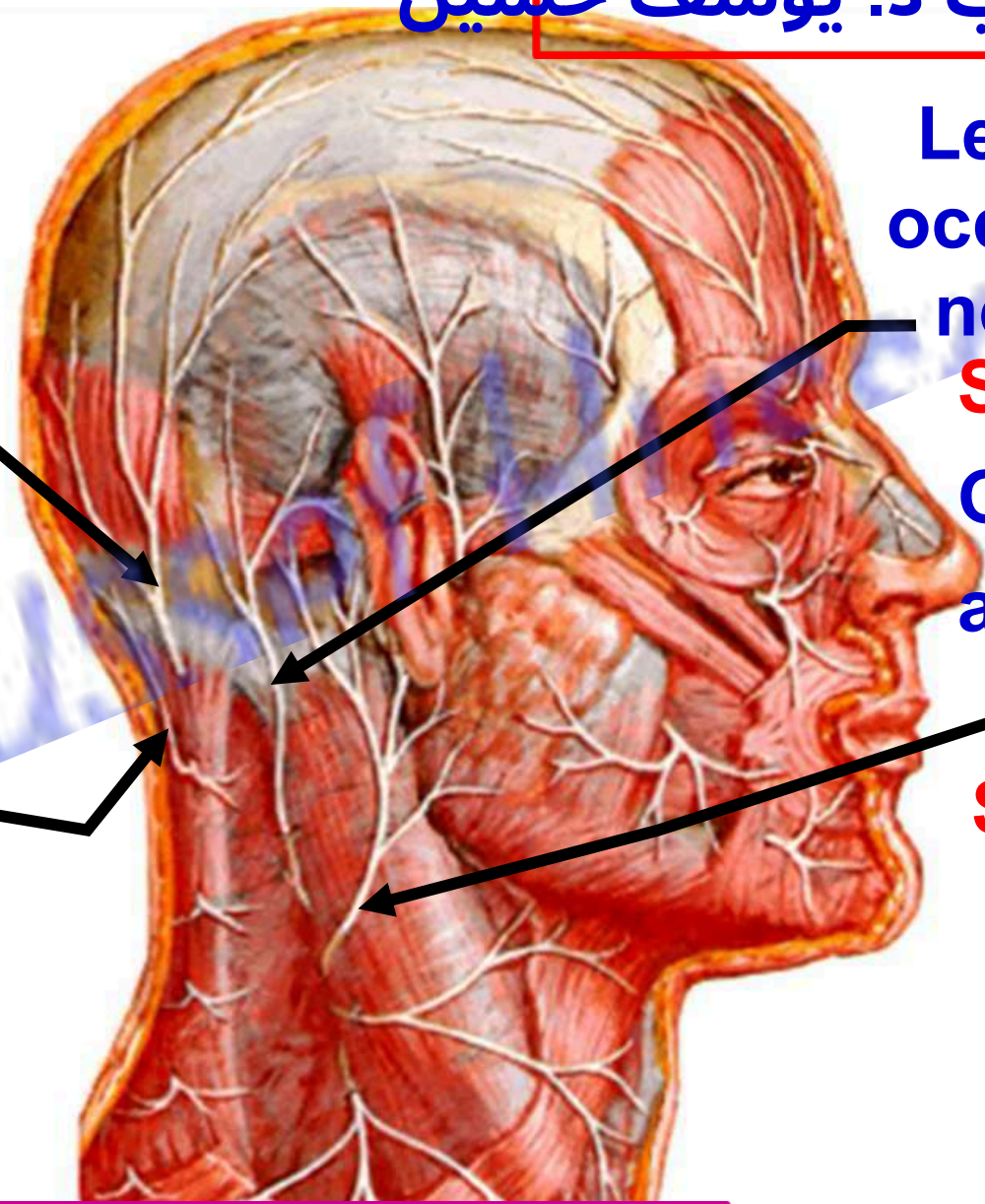
Nerves behind auricle

S=C2 Greater occipital nerve

Posterior auricular nerve
M

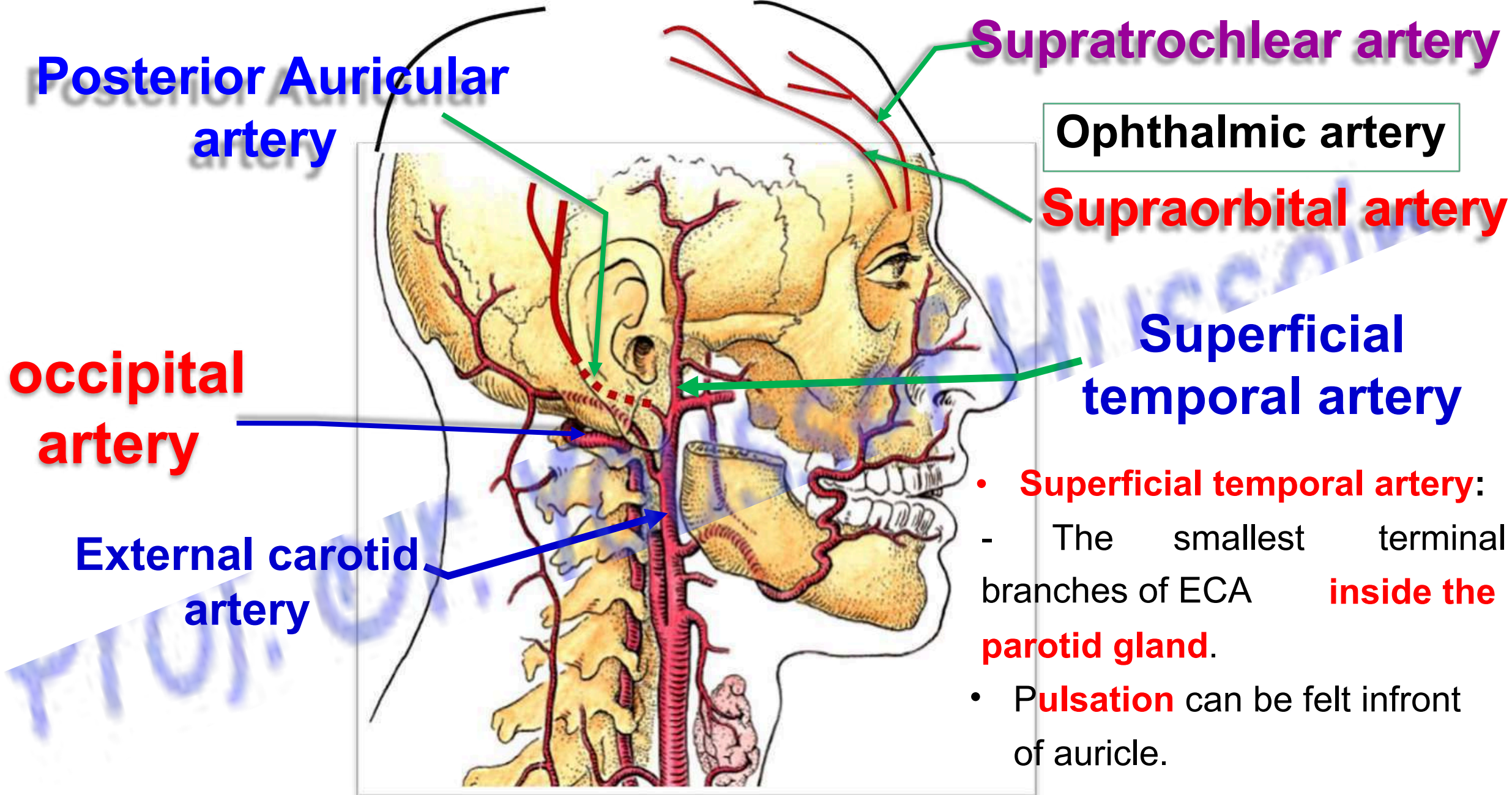


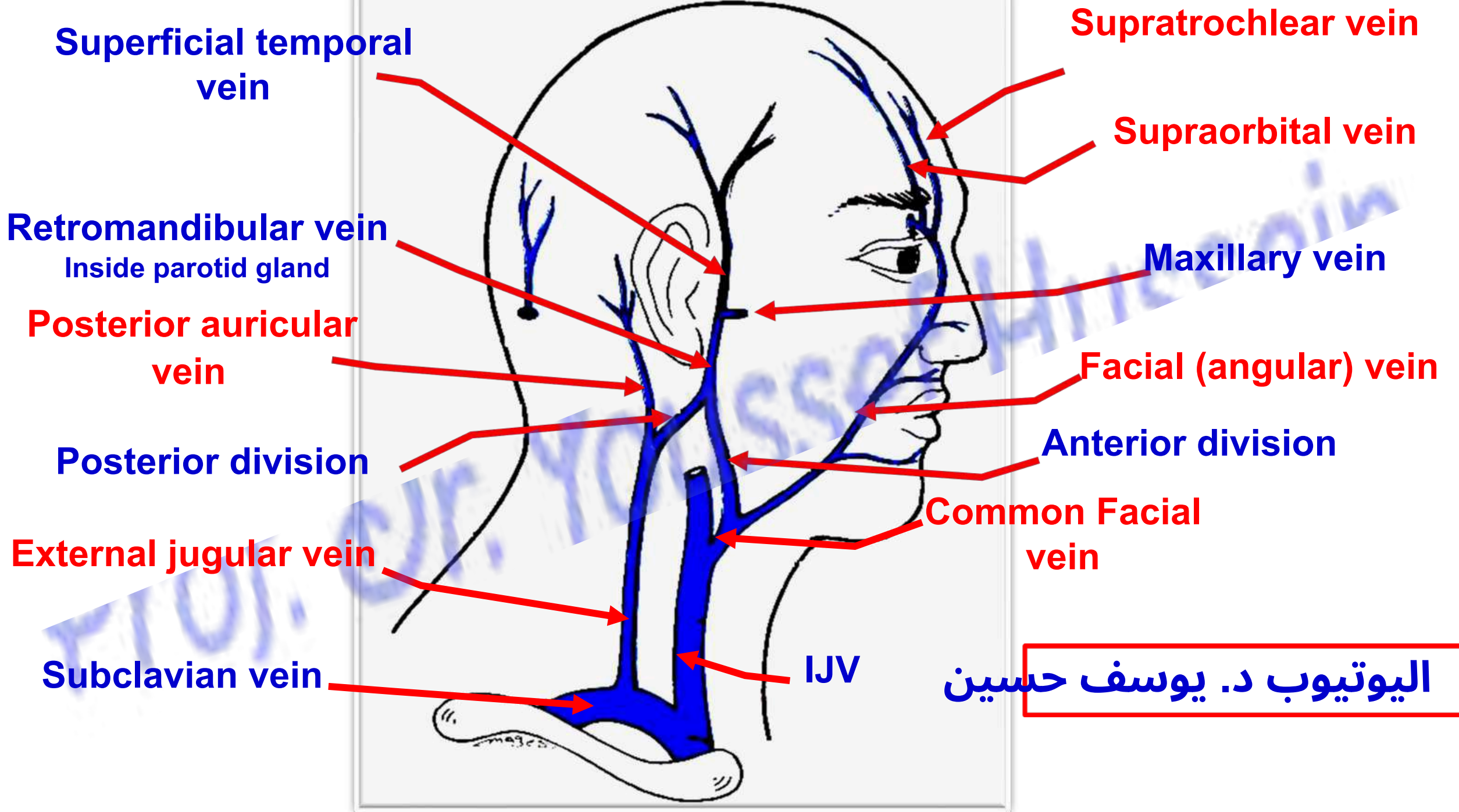
3rd occipital nerve
S=C3



Lesser occipital nerve
S=C2

Great auricular nerve
S=C2&3





Superficial temporal vein

Retromandibular vein
Inside parotid gland

Posterior auricular vein

Posterior division

External jugular vein

Subclavian vein

Supratrochlear vein

Supraorbital vein

Maxillary vein

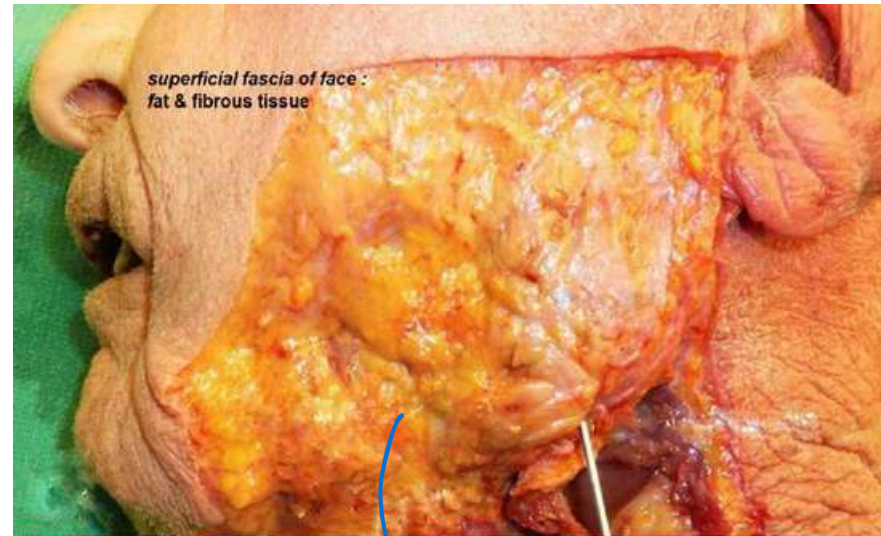
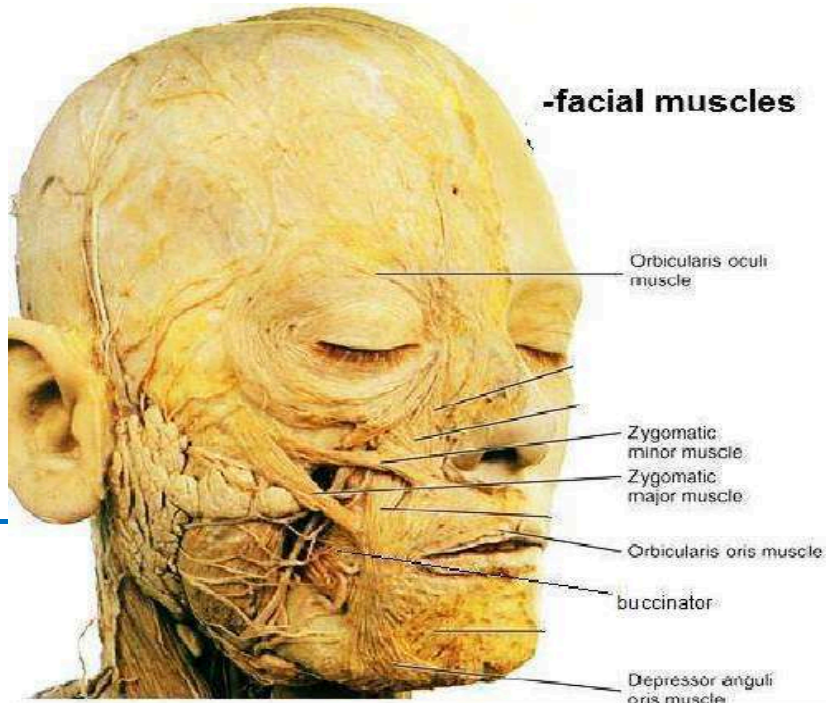
Facial (angular) vein

Anterior division

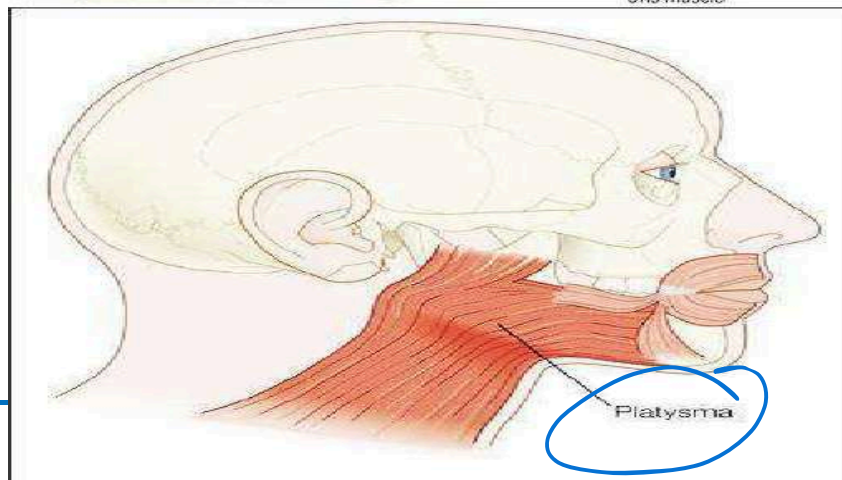
Common Facial vein

IJV

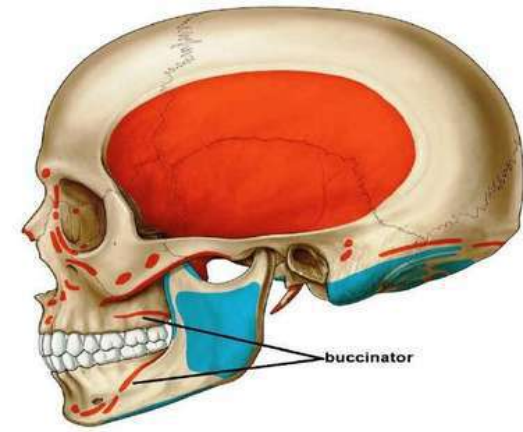
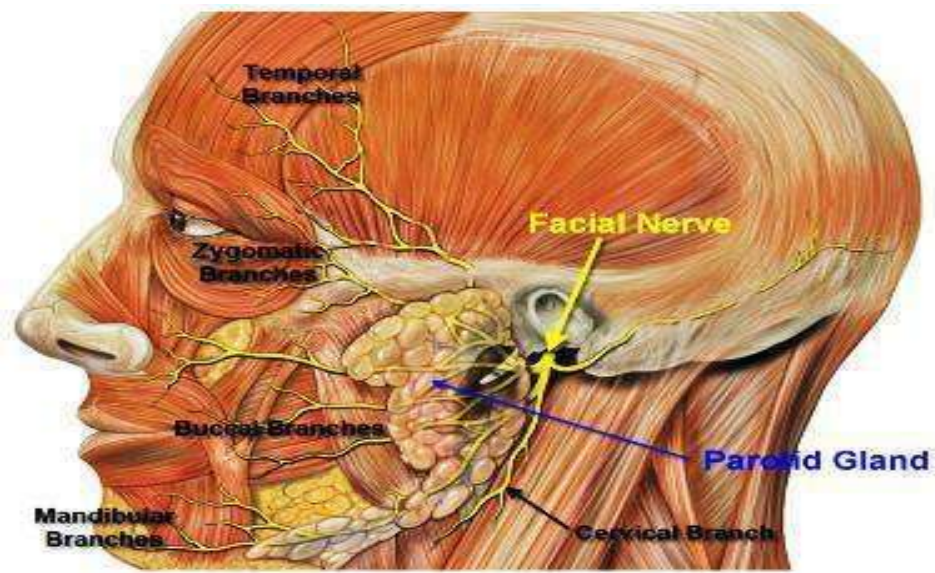
البيوتوب د. يوسف حسين



superficial fascia

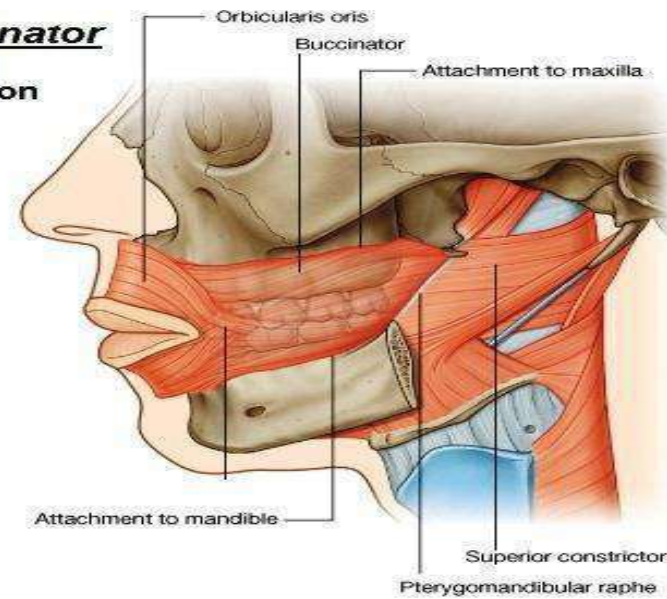


Small muscles e.g.
zygomaticus major
zygomaticus minor
depressor anguli
oris

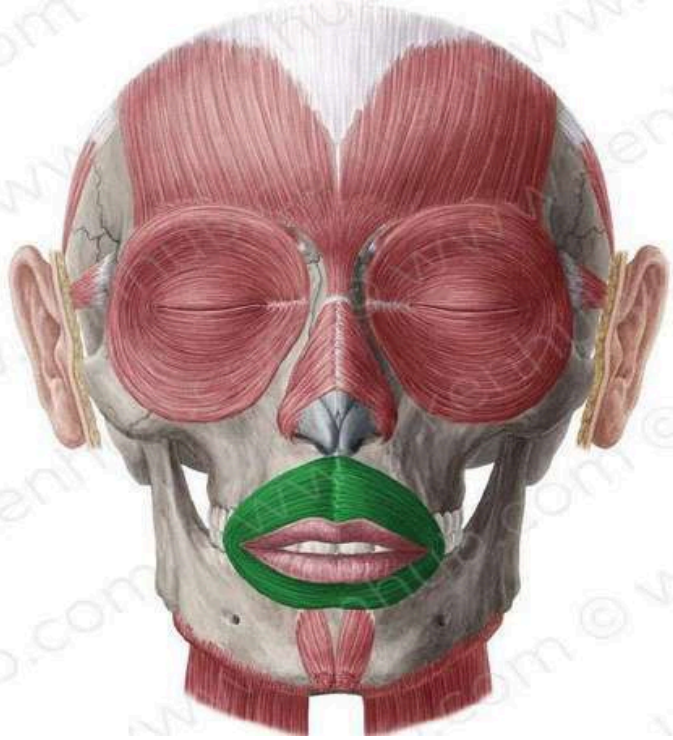

Buccinator N.S: buccal br. of facial n.

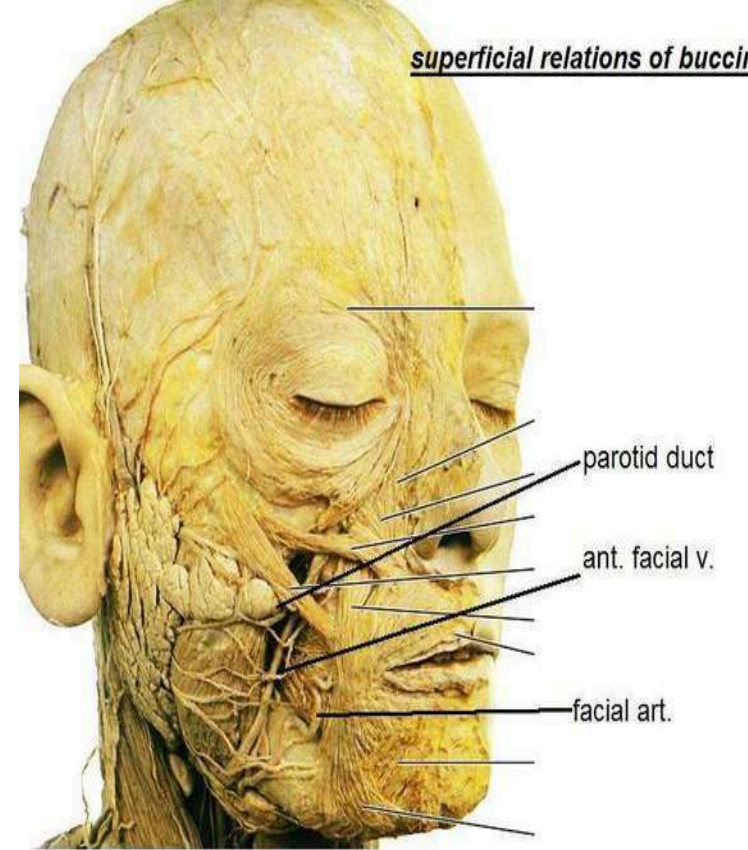
buccinator
-origin
-insertion



Muscles Buccinator: muscle of cheek



Orbicularis oris: sphincter of mouth



crossed by
facial artery
ant facial vein
pierced by
parotid duct

structure

Muscles

Orbicularis Oculi: sphincter of eye

parts, attachments & action:

Orbital part:

O: medial palpebral lig. & the near bone

I: the fibres form complete ellipse around orbital opening to insert in the medial palpebral

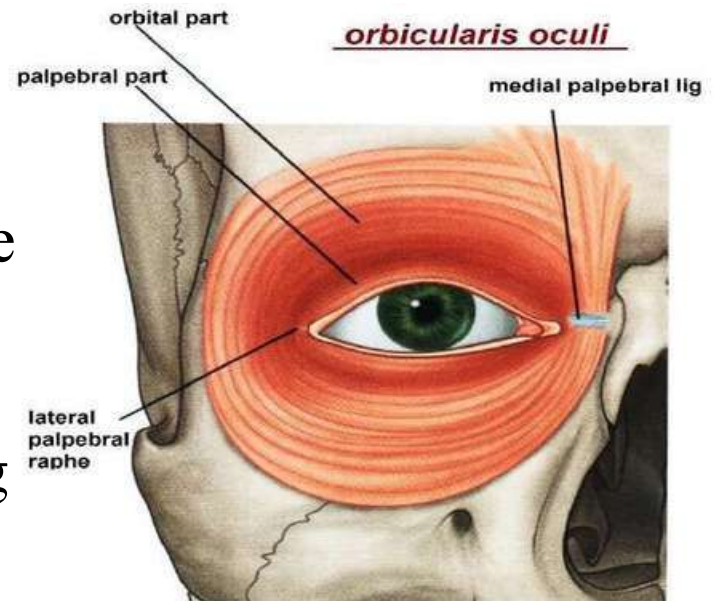
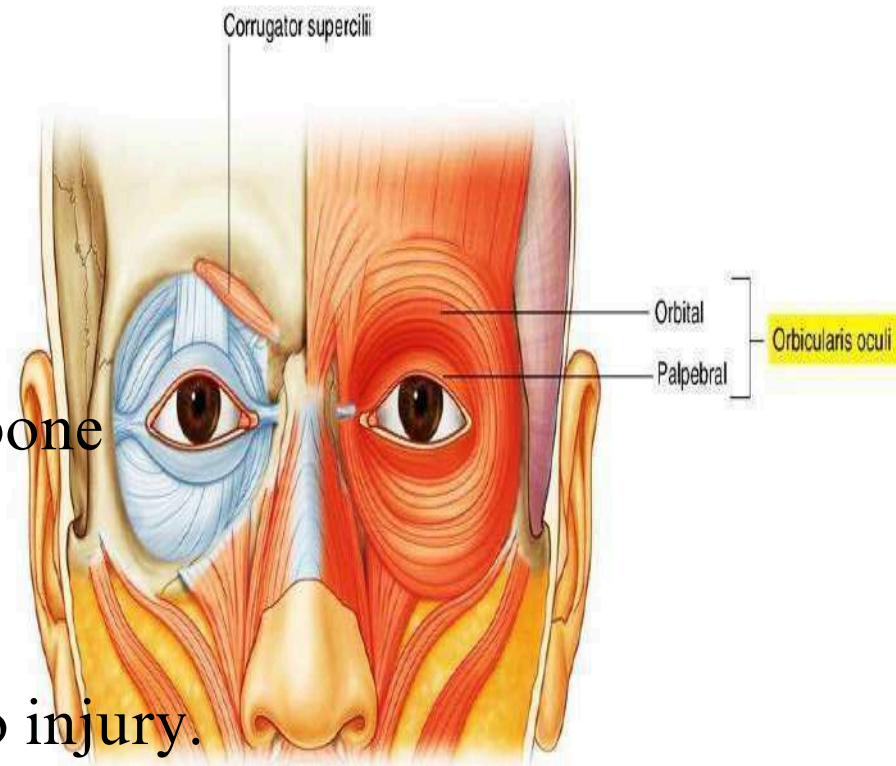
A: light closure of eye in exposure to injury.

Palpebral part:

O: medial palpebral lig.

I: the fibers curve within the eye lids then the upper & lower fiber decussate at lateral angle of eye forming the lateral palpebral raphe

A: light closure of eye in sleep & blinking



structure

Muscles

orbicularis oculi

parts, attachments & action:

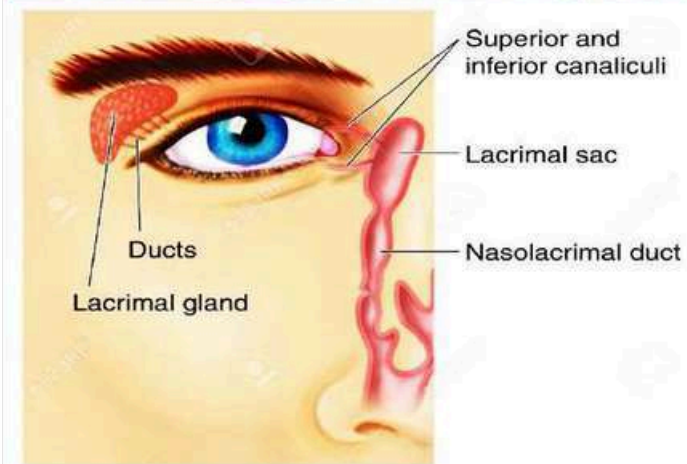
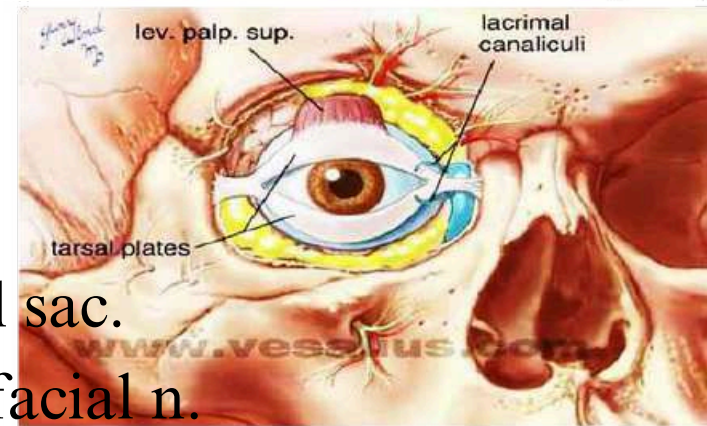
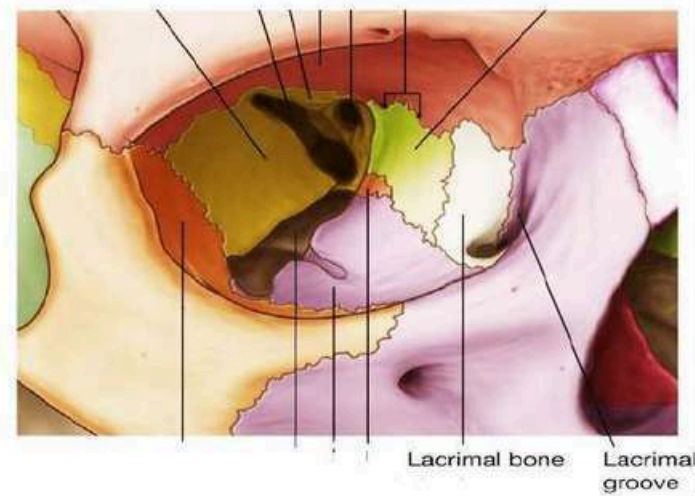
Lacrimal part:

O: post. lacrimal crest &
fascia covering lacrimal sac.

I: to tarsi of eyelids.

A: drainage of tears by dilating the lacrimal sac.

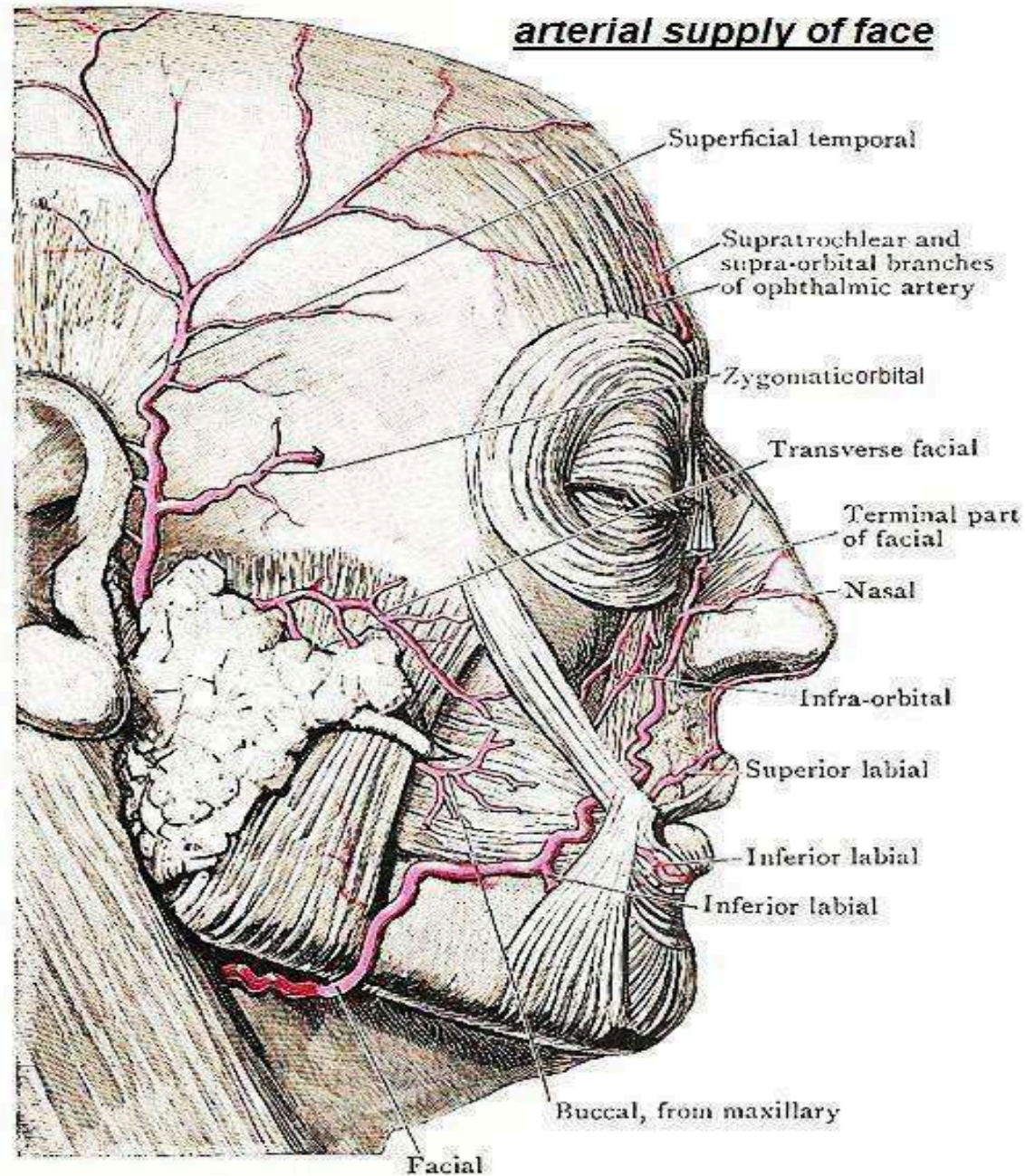
N.S: temporal and zygomatic branches of facial n.



internal carotid art: gives
ophthalmic art. Which gives
-supratrochlear art. -
supraorbital art.

External carotid art: gives **superficial
temporal art.** Which gives transverse
facial art. **maxillary art.:** which gives
infra orbital art. inferior alveolar art.
Giving mental art. buccal art. **facial
art. (main)**

facial art.

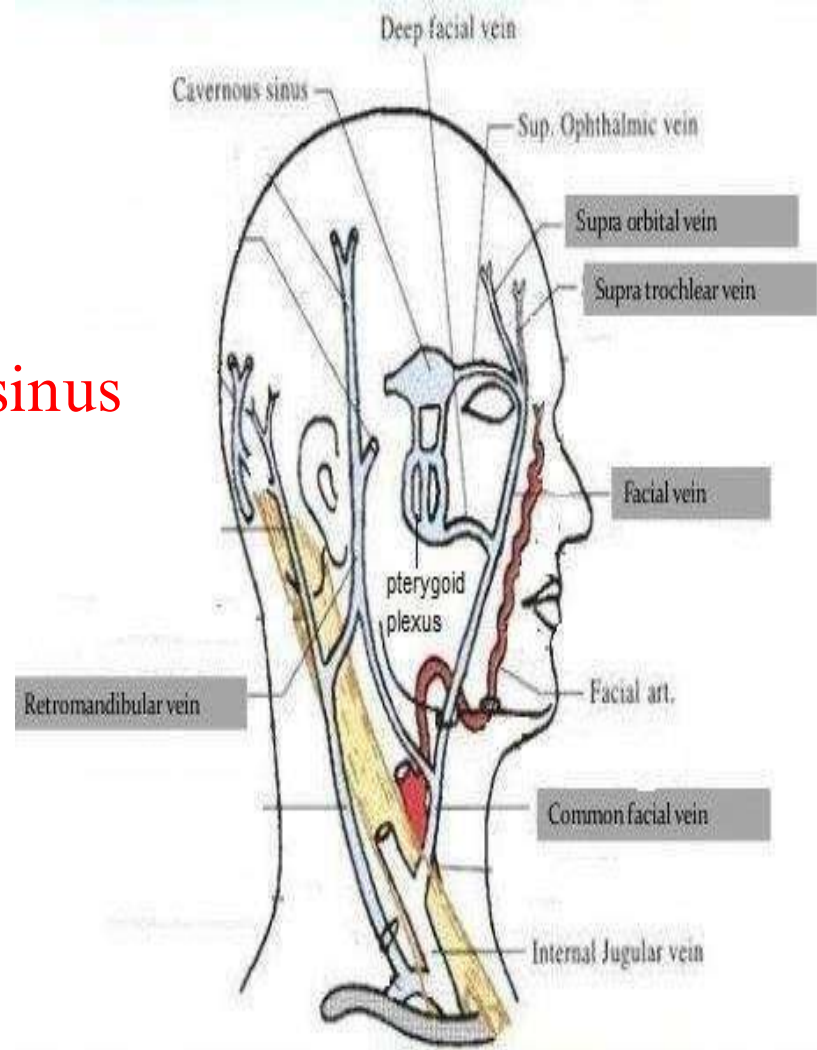
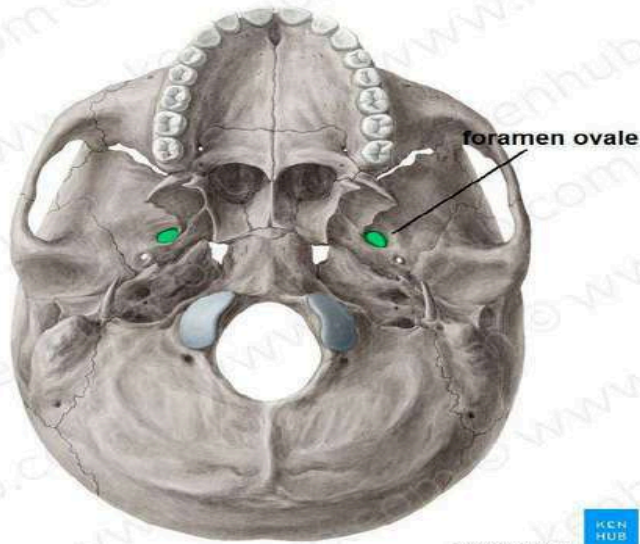


Ant. facial v.

Connections:

ant. facial v. is connected to **cavernous sinus** by 2 valveless veins

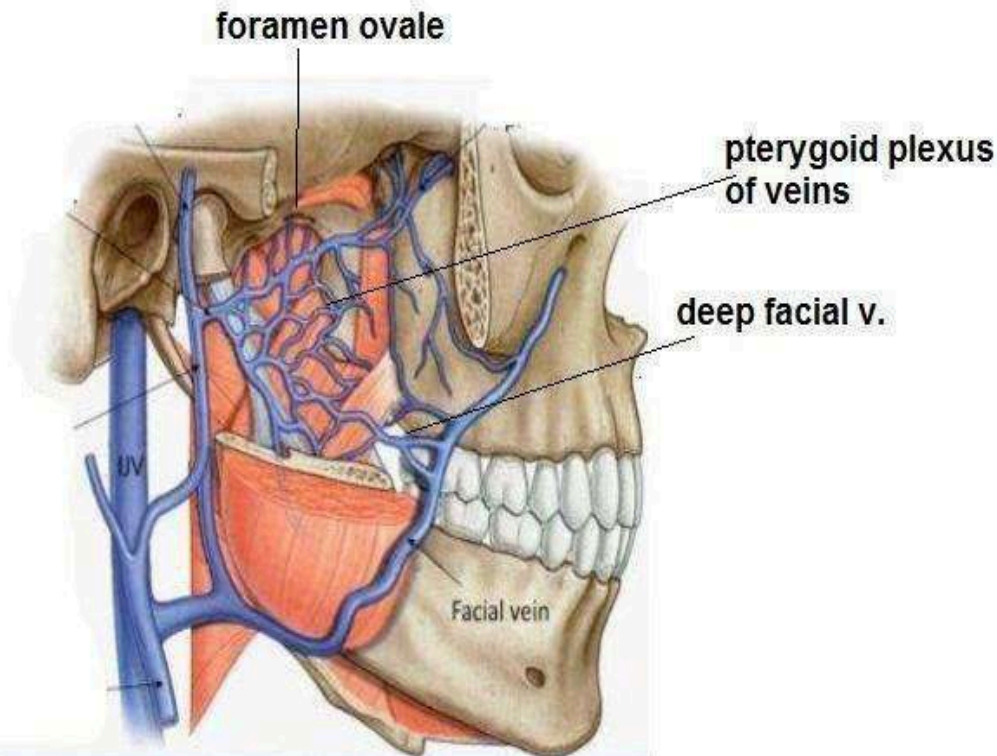
- 1-superior ophthalmic v.
- 2-deep facial v. to pterygoid plexus of veins to cavernous sinus through emissary v. pass through foramen ovale



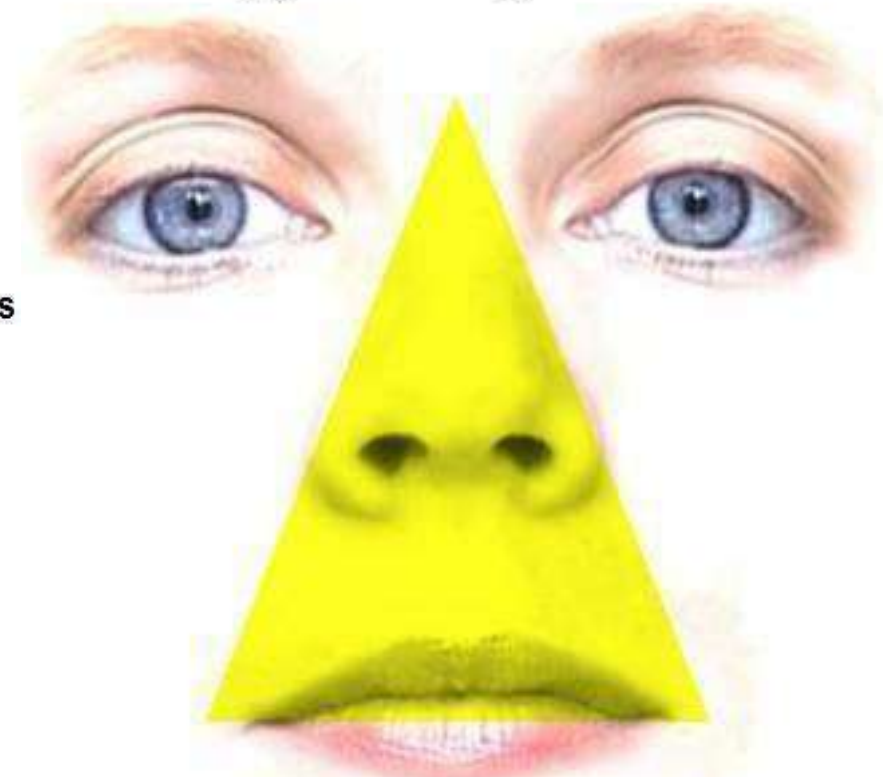
Applied anatomy:

dangerous area of face is the triangular area around nose & upper lip as infection pass from ant. facial v. to cavernous sinus by the 2 valveless veins:

- 1-superior ophthalmic v.
- 2-deep facial v.....



Danger Triangle of Face

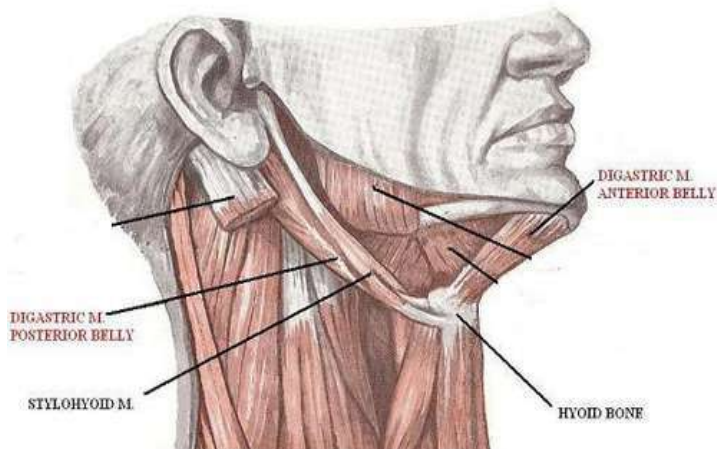
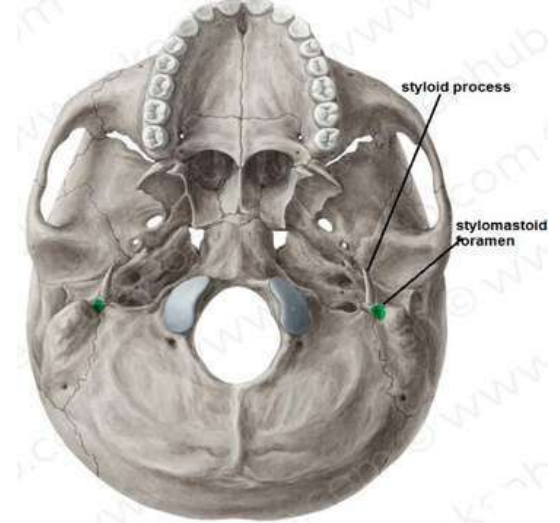


<http://medchrome.com>

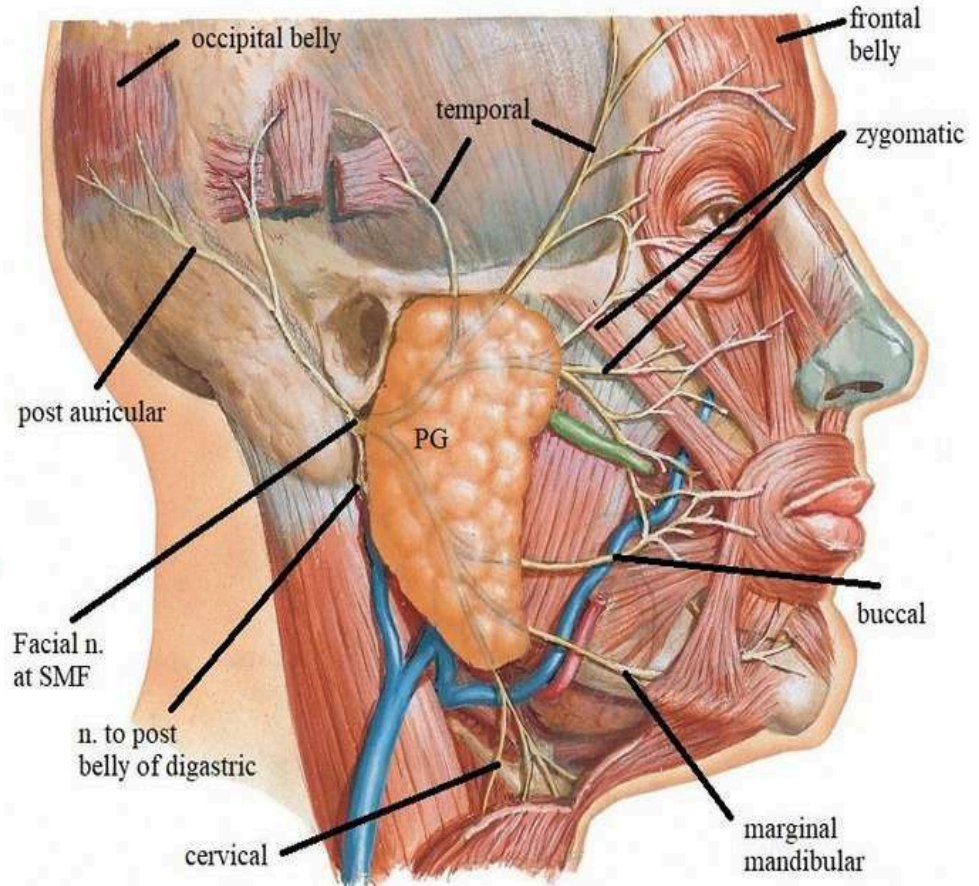


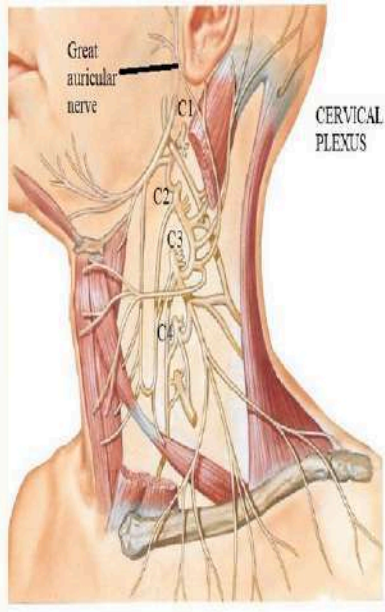
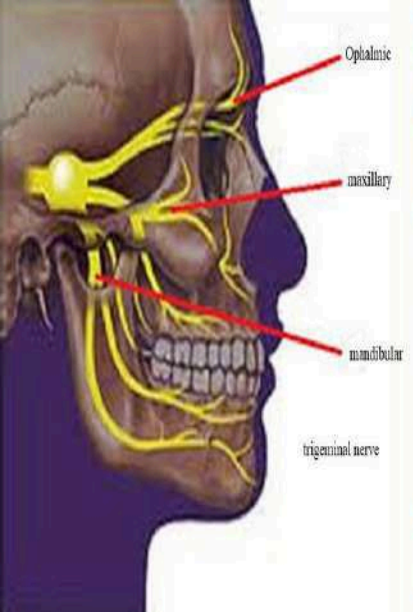
deviation of mouth to normal side in facial n. palsy

Injury of facial nerve

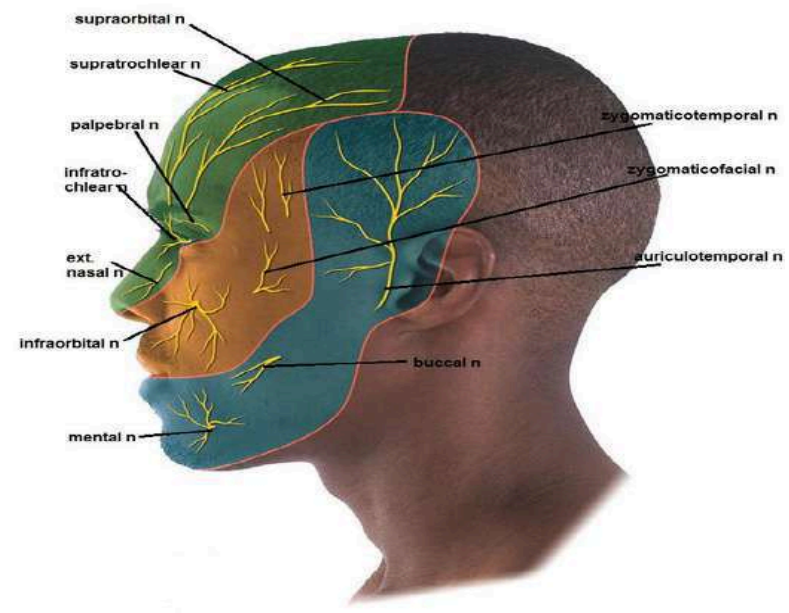
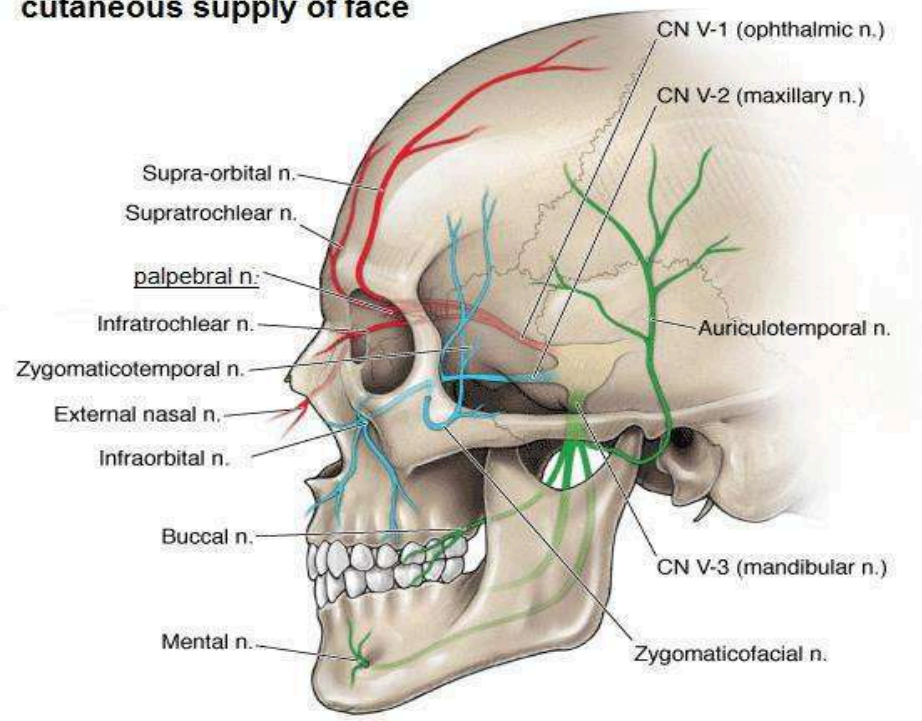


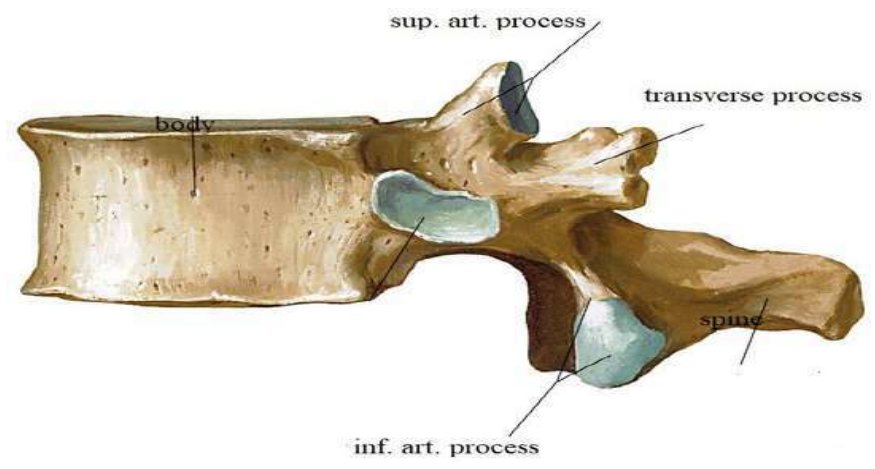
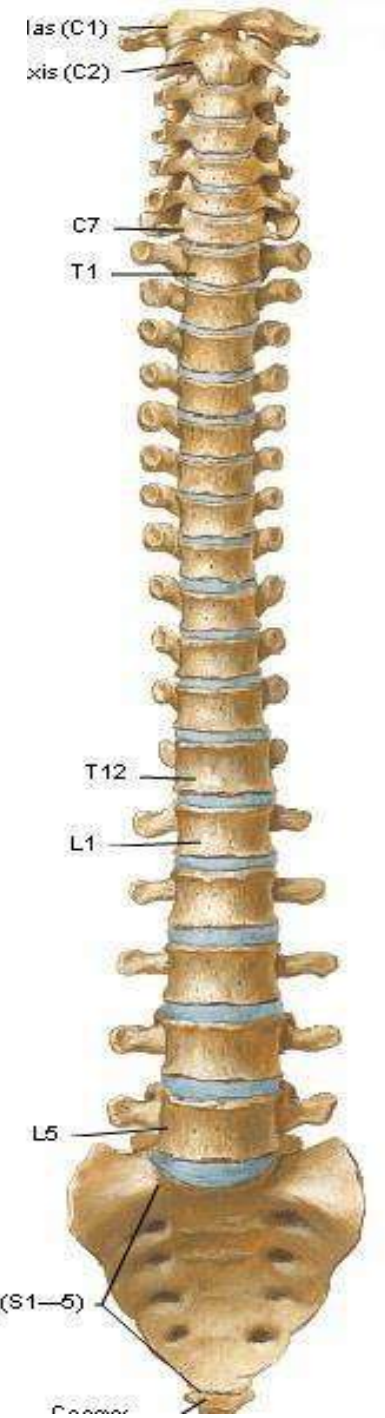
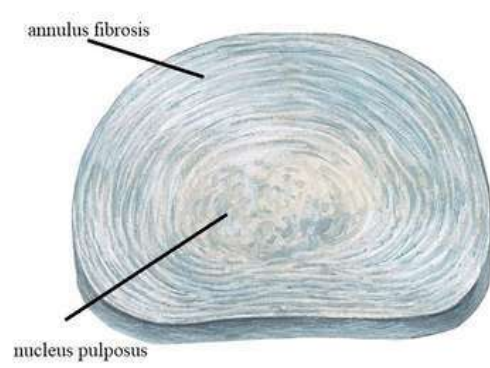
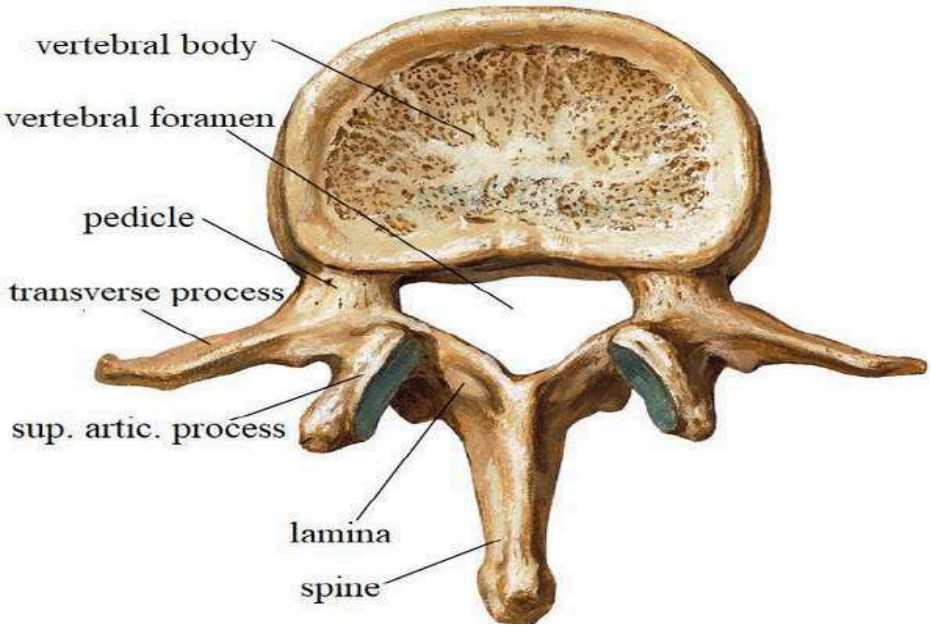
Nerve to post belly of digastric

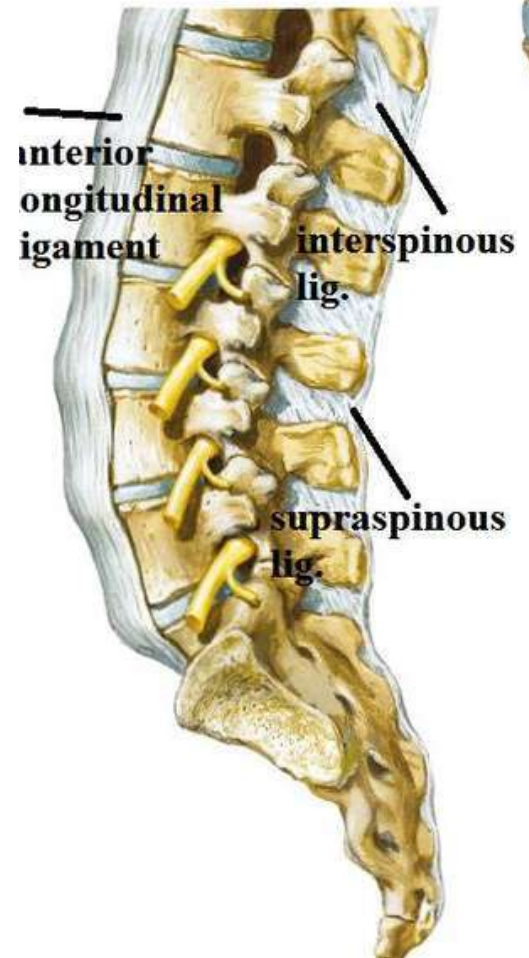
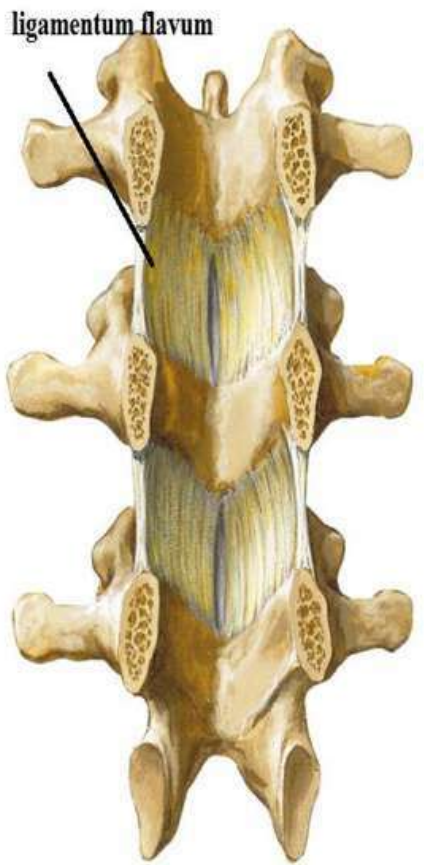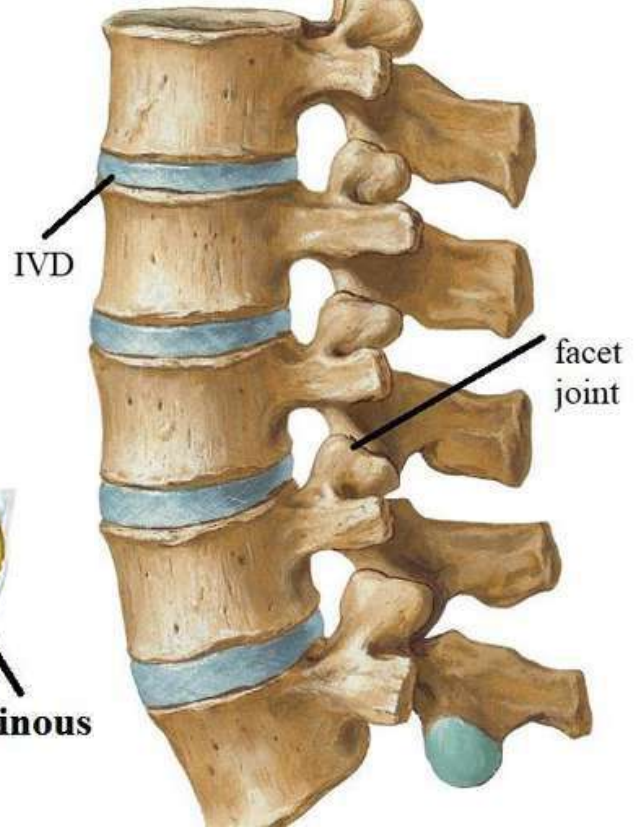

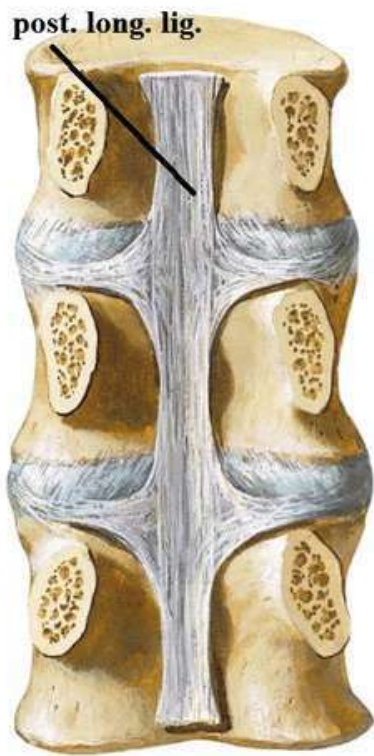


cutaneous supply of face







How to identify the vertebra

-If it has a **foramen in the transverse process** :

it is a cervical vertebra

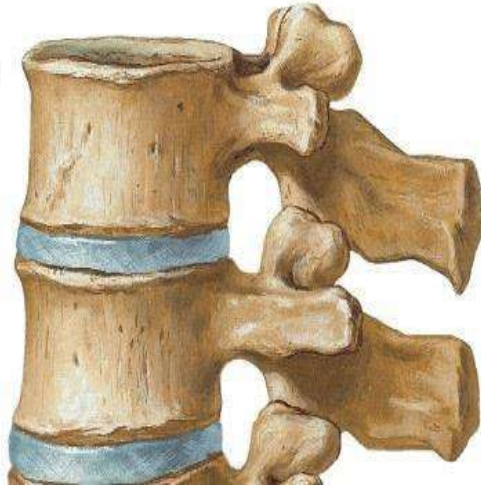-If **no foramen in the transverse process** with a **facet on the side of the body** of the vertebra :

it is thoracic vertebra

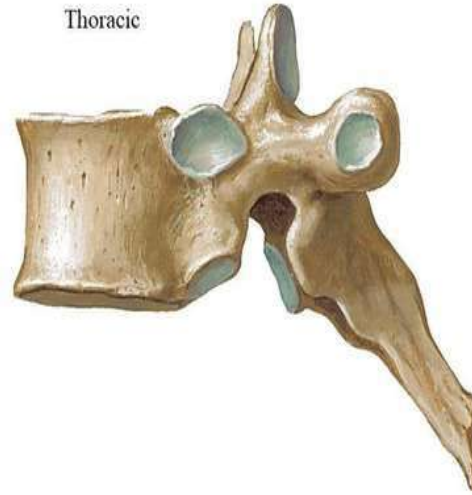
-If **no foramen in the transverse process** and **the body has no facet** :

it is lumbar vertebra.

Lumbar



Thoracic



cervical



CERVICAL VERTEBRAE

NO. 7

characters

- 1-presence of foramen transversarium
- 2-bifid spine

classified into

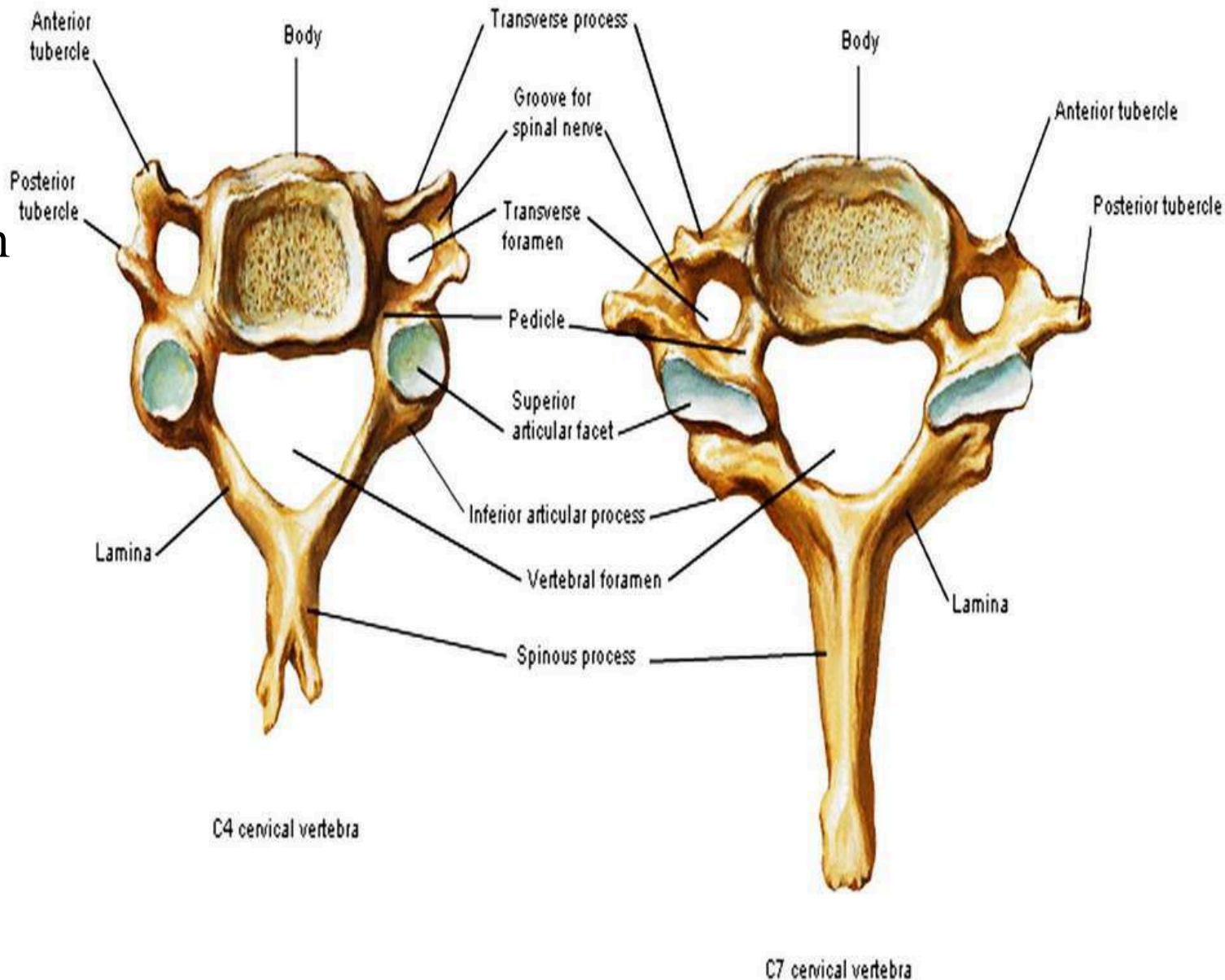
a- Typical 3-6.

b-atypical

1 (atlas)

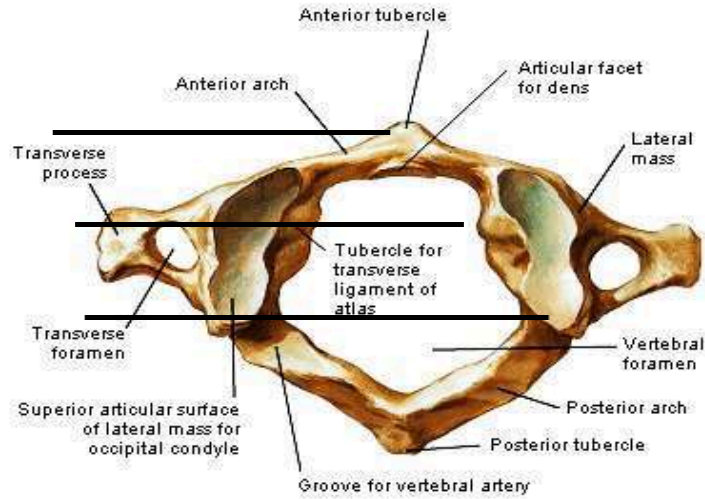
2 (axis)

7 its spine is not bifid

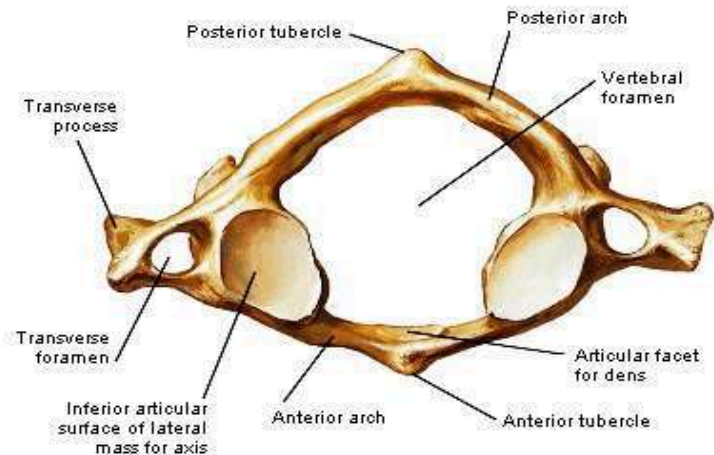


CERVICAL VERTEBRAE

C1 ATLAS

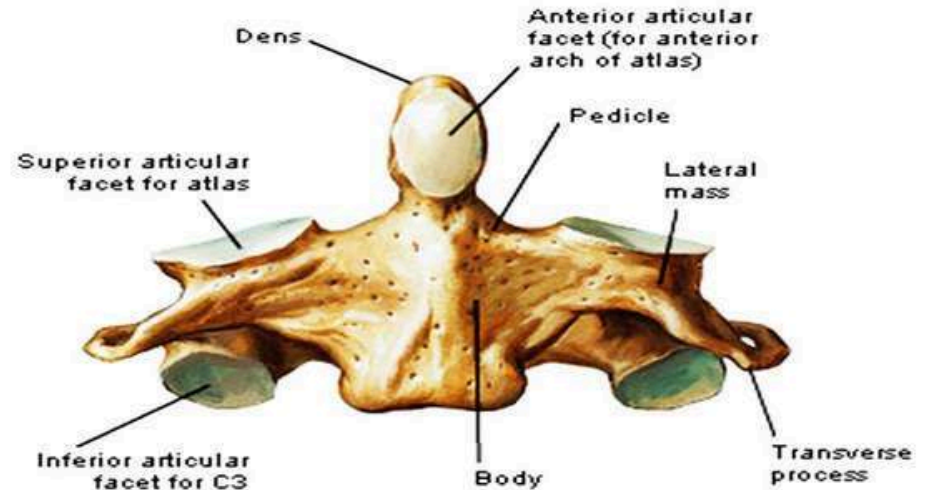


Atlas (C1): superior view

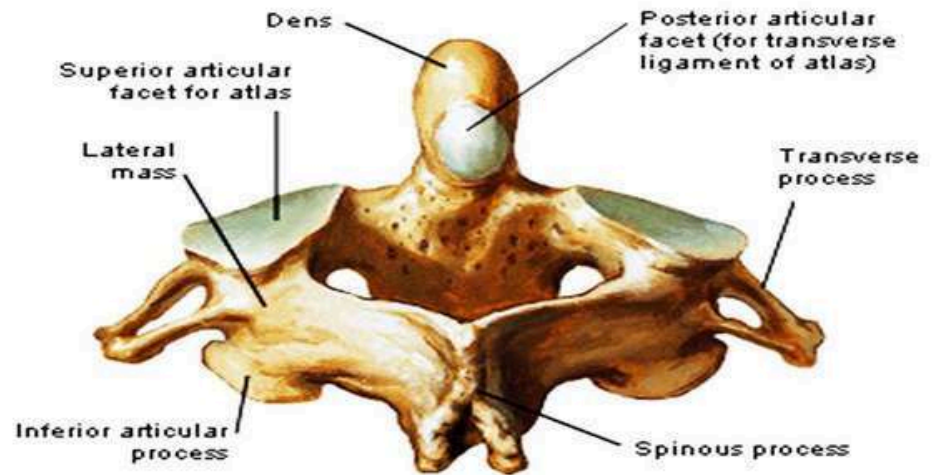


Atlas (C1): inferior view

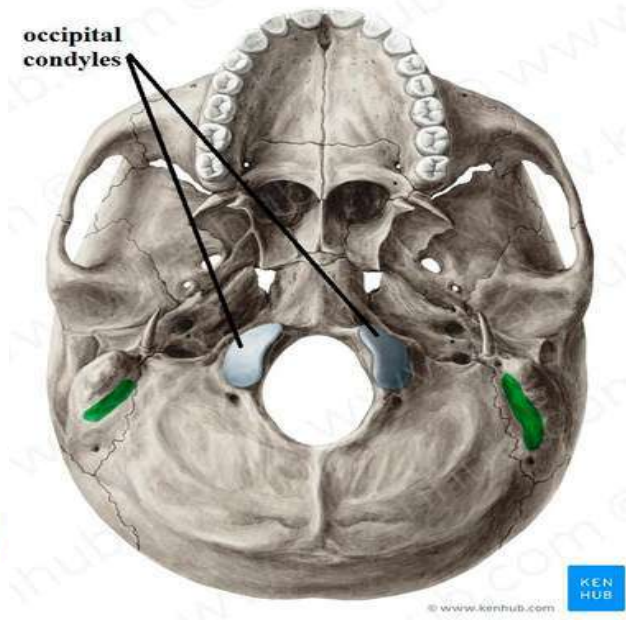
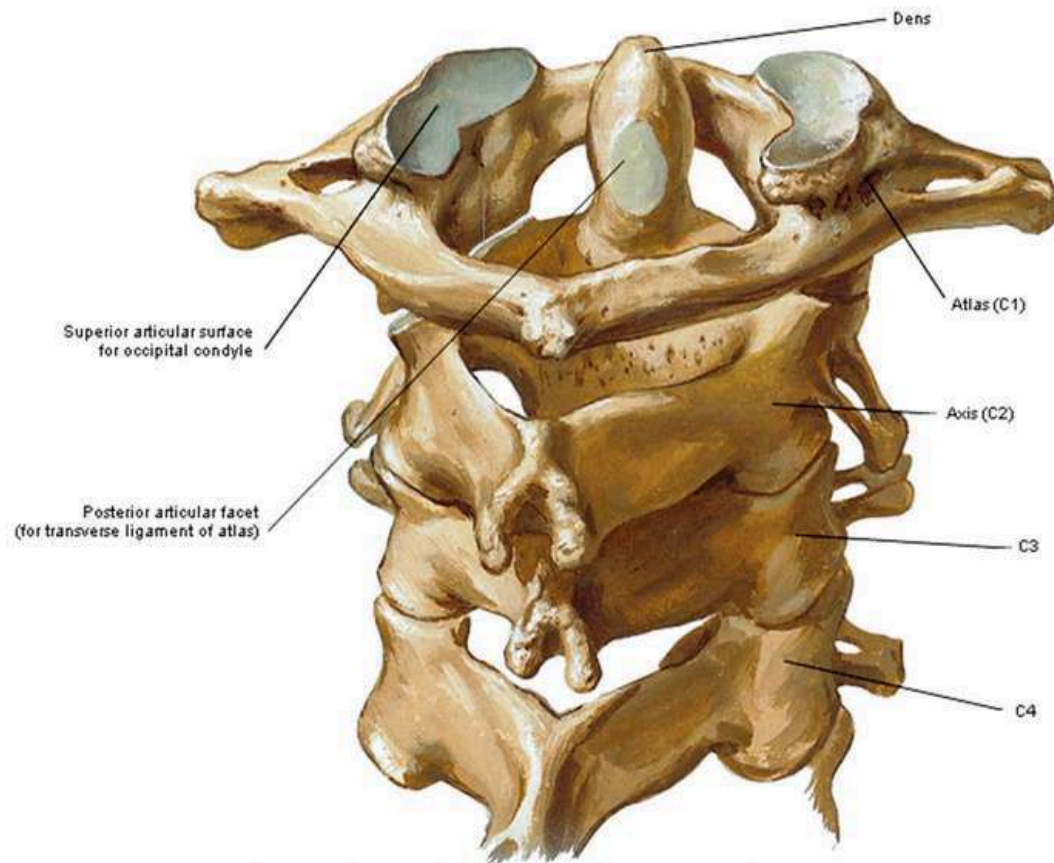
C2 AXIS



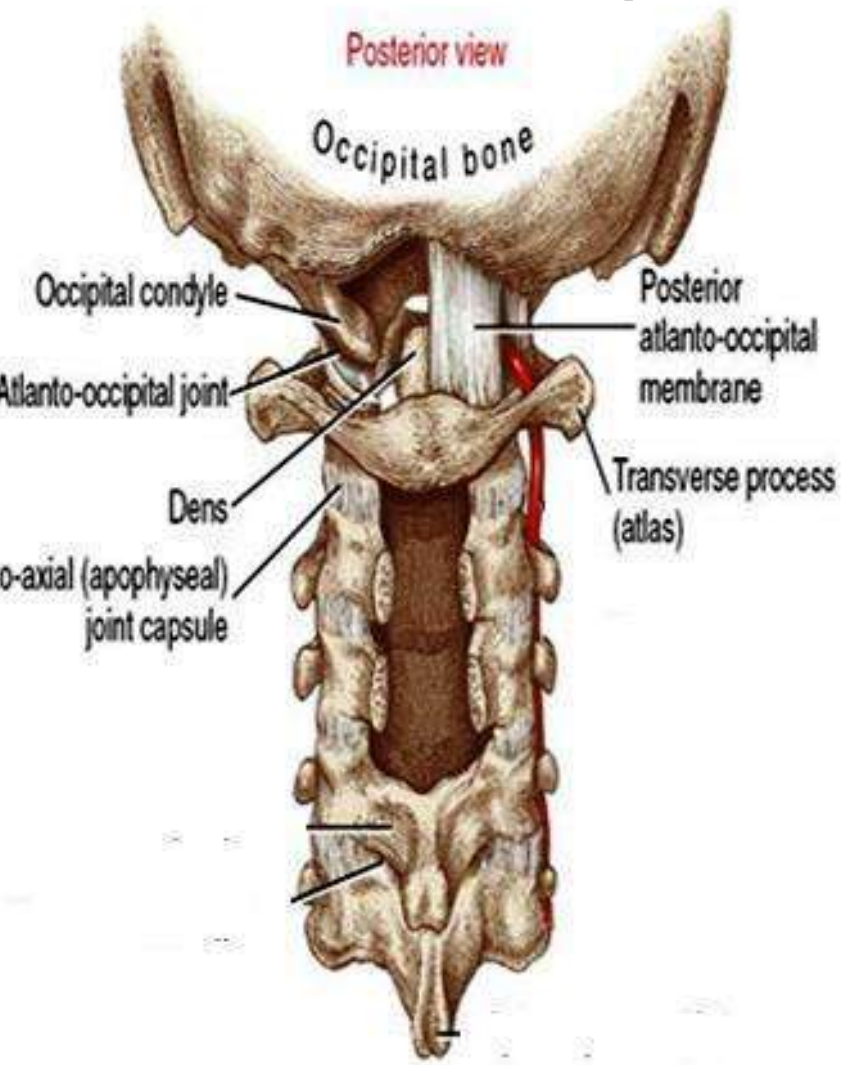
Axis (C2): anterior view



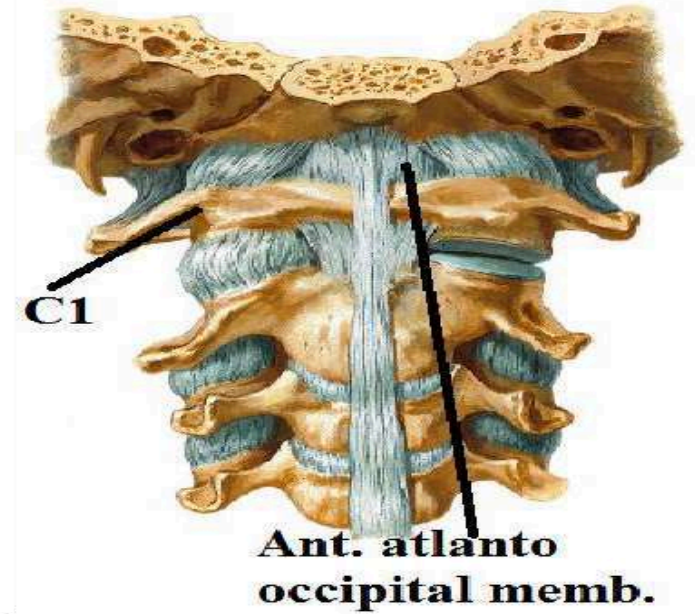
Axis (C2): posterosuperior view



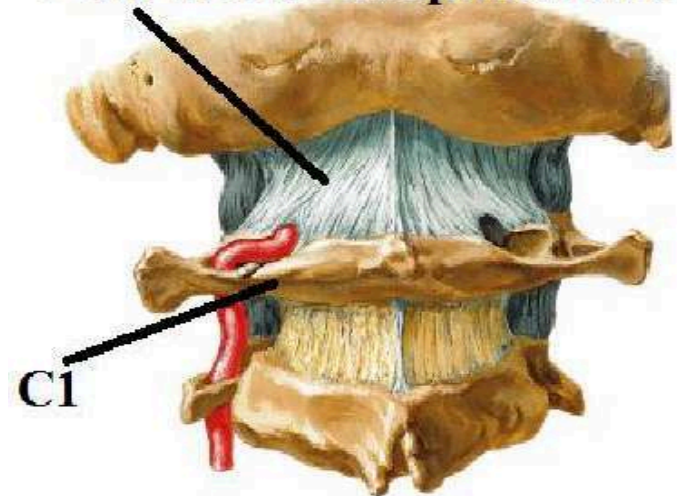
Atlanto occipital joint



1-Anterior Atlanto-occipital membrane

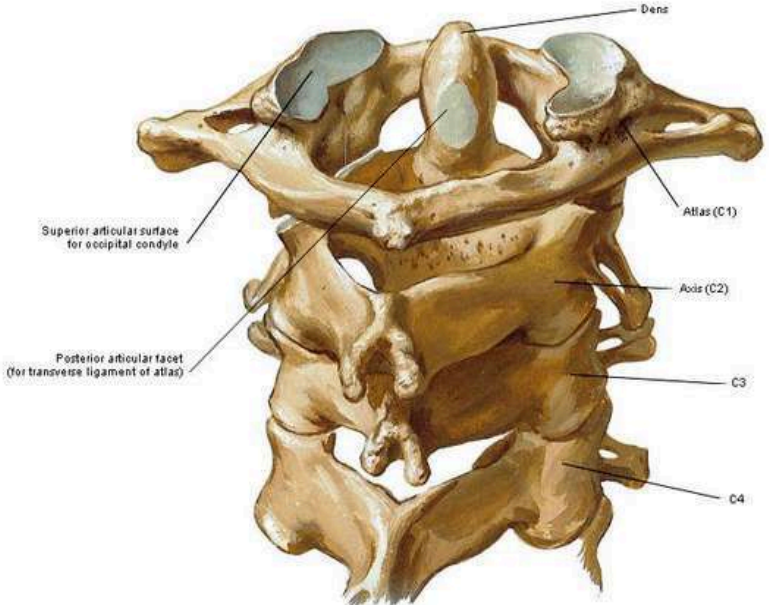


Post. atlanto occipital memb.



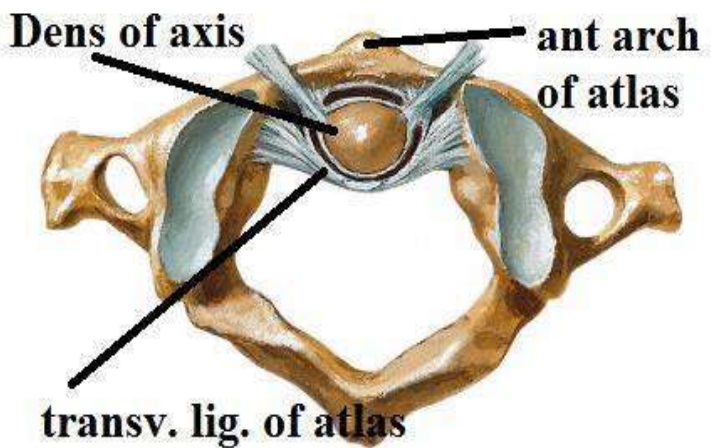
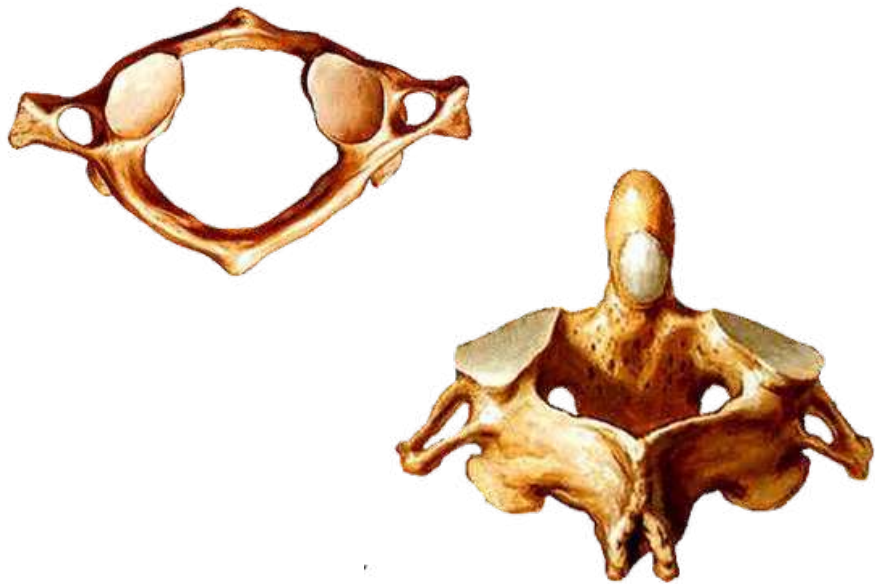2-Posterior Atlanto-occipital membrane.

Atlanto axial joints



Atlanto axial joints

3 joints (1 median & 2 lateral Atlanto axial)

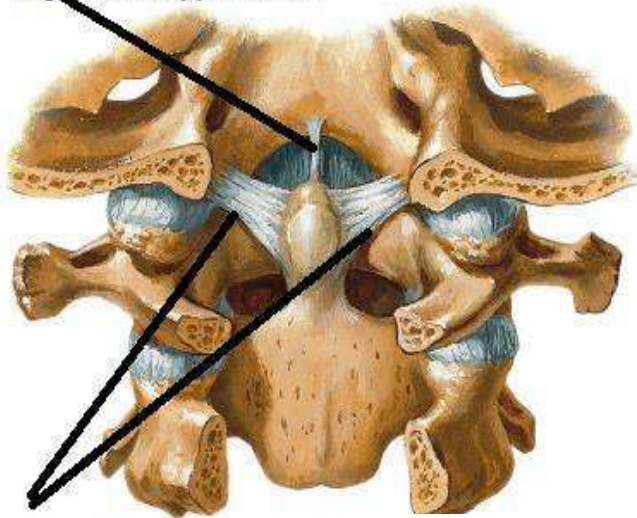


1-Apical ligament.

2-Alar ligament.

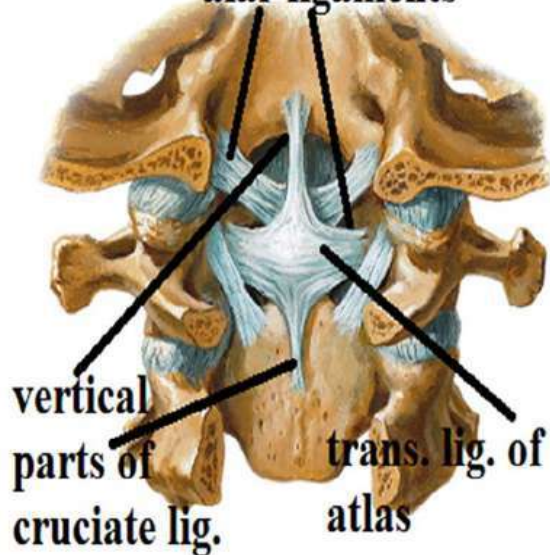
3-Cruciate ligament:

apical ligament



alar ligament

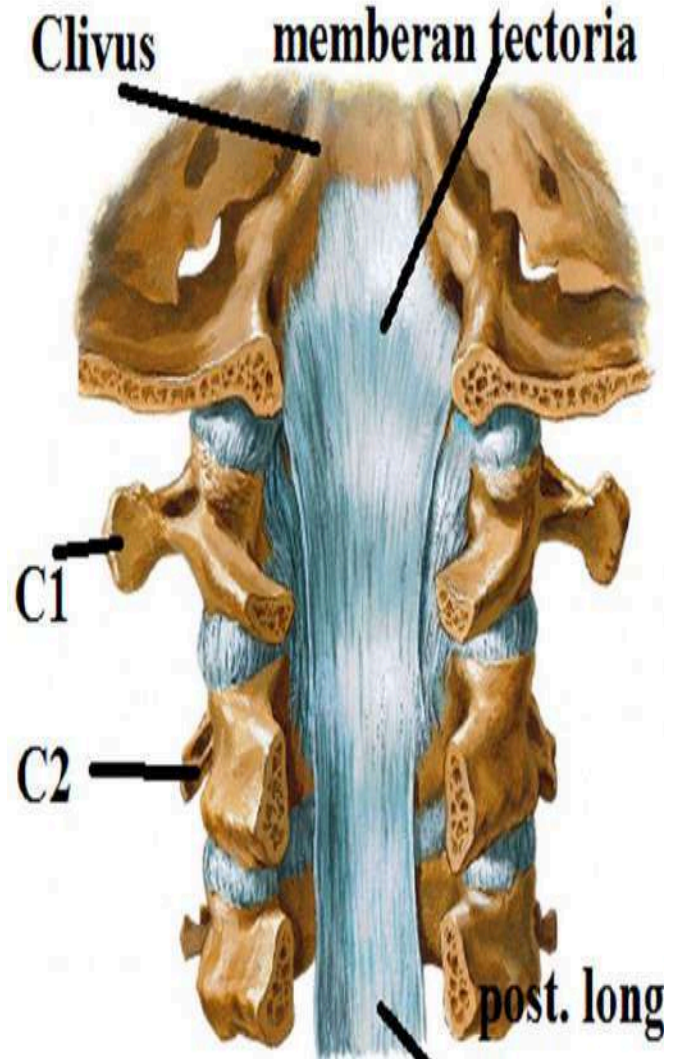
alar ligaments



vertical
parts of
cruciate lig.

trans. lig. of
atlas

4-Memberana tectoria



Clivus

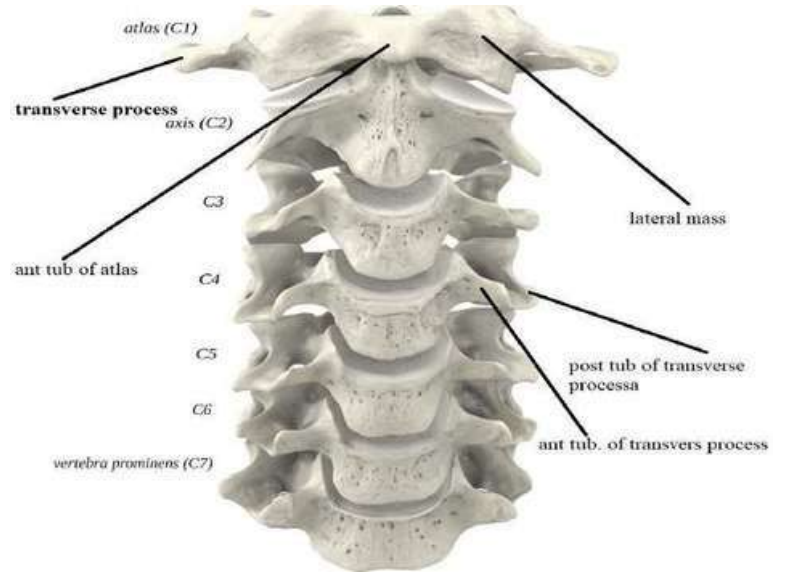
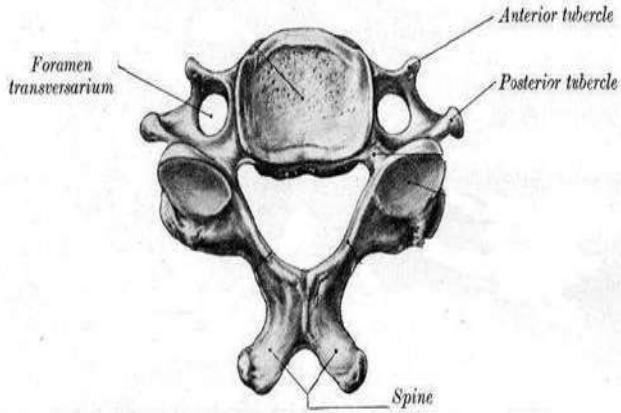
memberana tectoria

C1

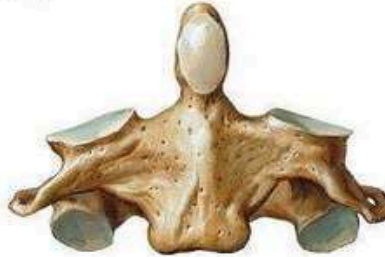C2

post. long

typical cervical vertebra. Superior aspect.



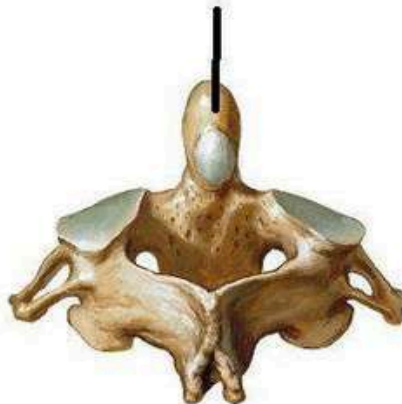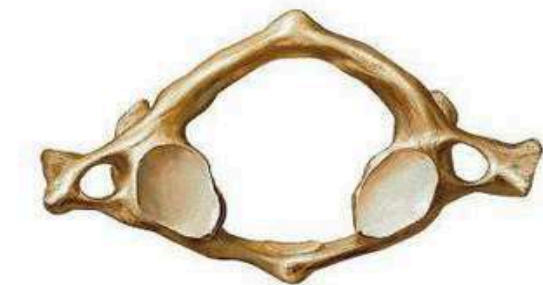
ANT.ARCH **ANT.TUBERCLE**



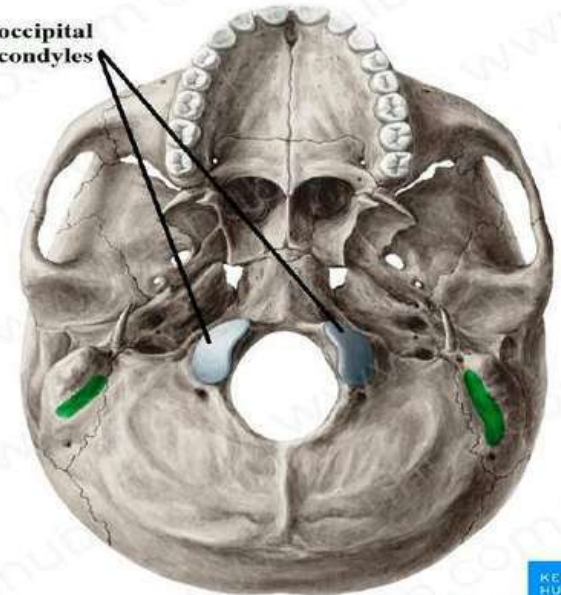
POST.ARCH **LATERAL MASS**

DENS

POST.TUBERCLE



occipital condyles



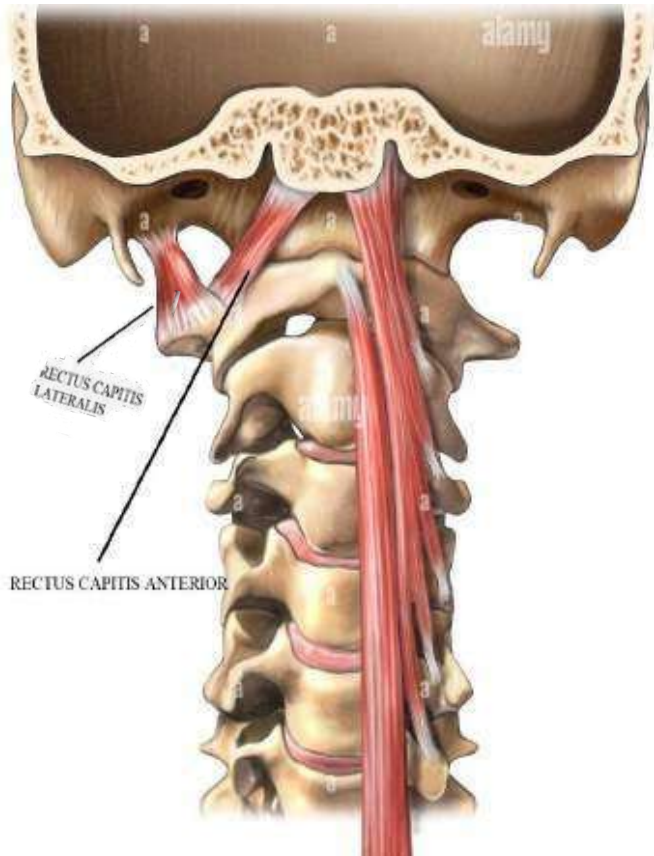
Prevertebral muscles

١-Rectus capitis anterior

٢-Rectus capitis lateralis

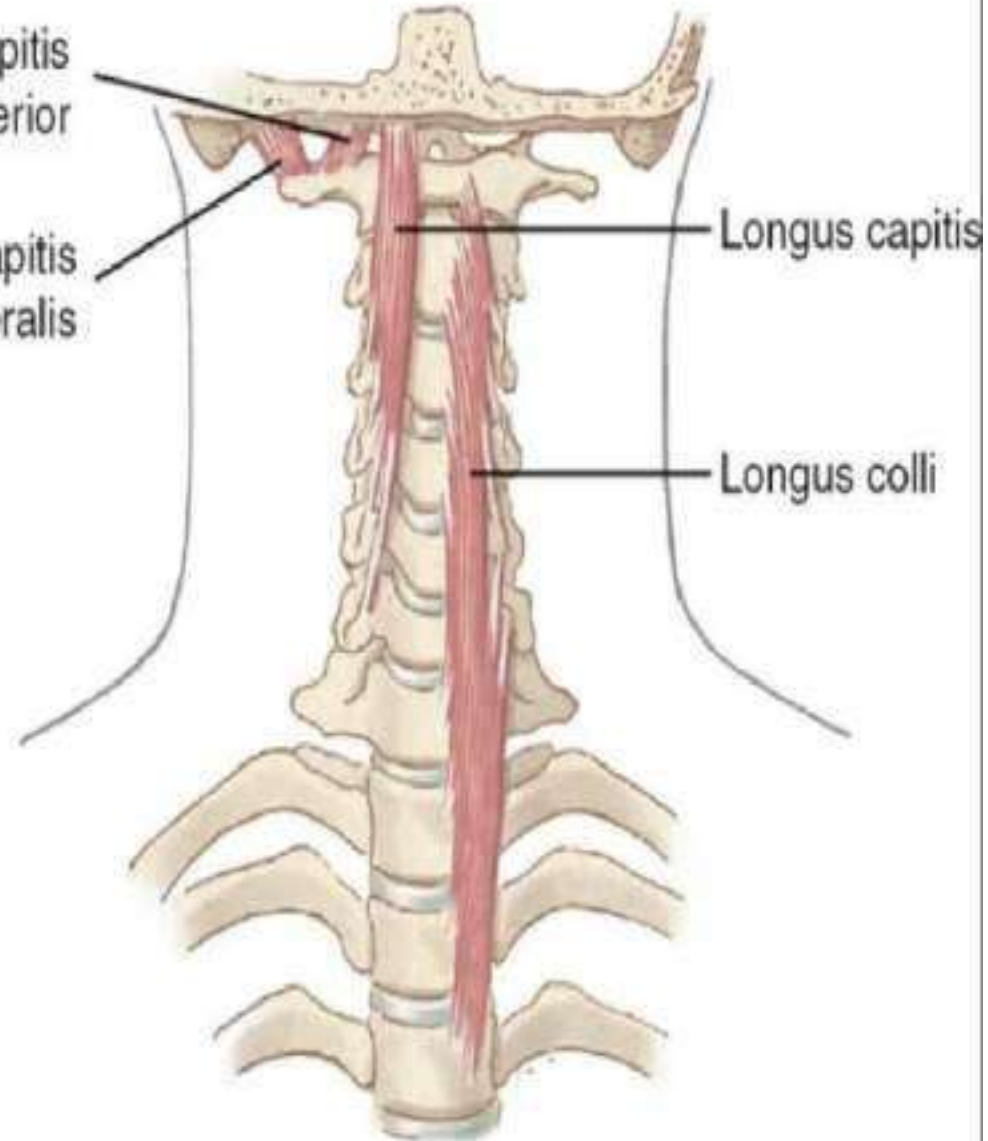
٣-Longus coli

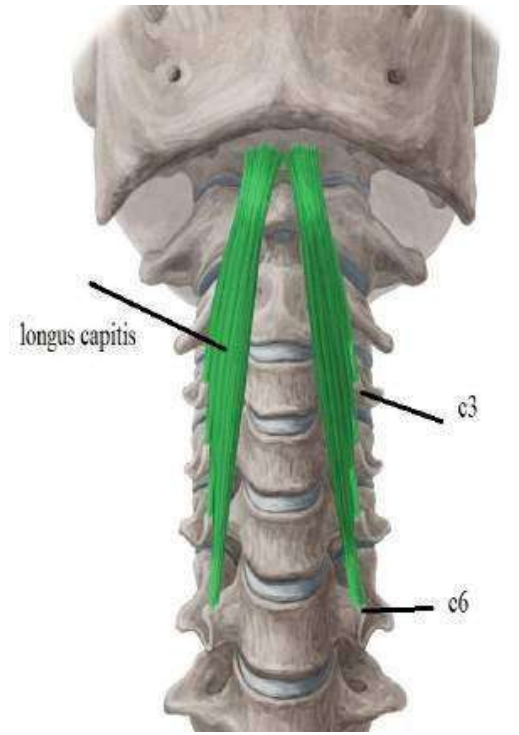
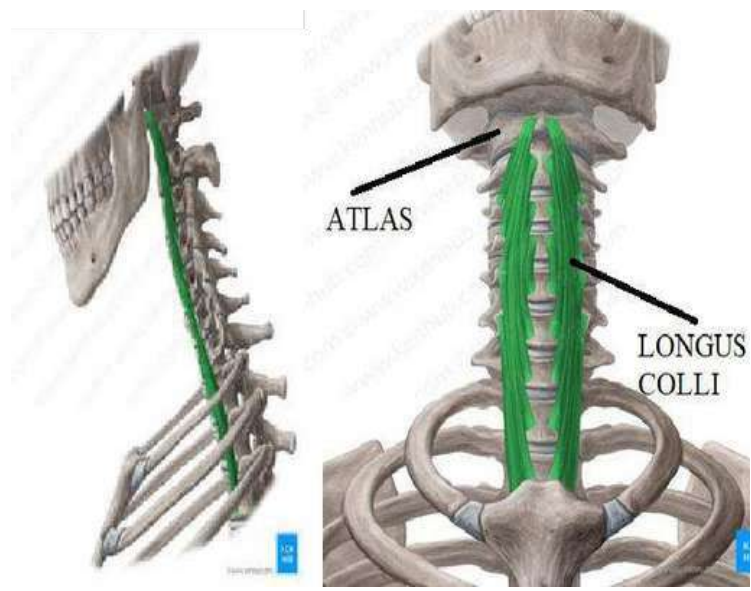
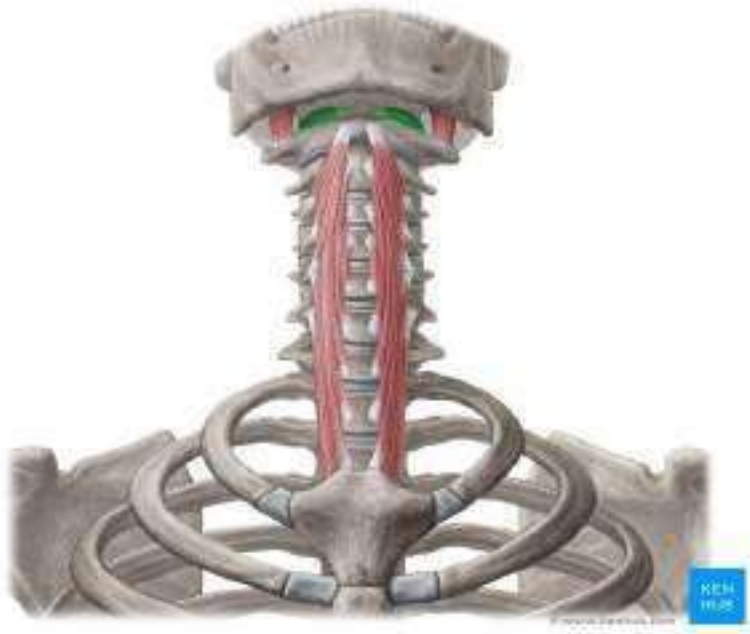٤-Longus capitis



Rectus capitis anterior

Rectus capitis lateralis





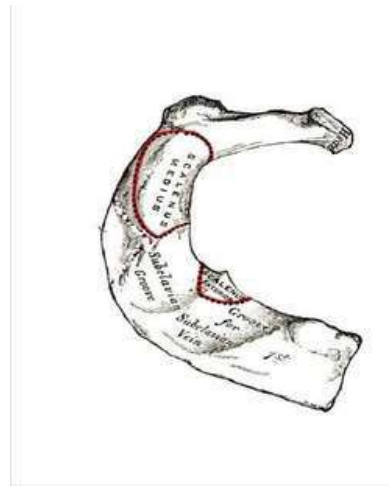
Paravertebral muscles

ι-Scalenus minimus

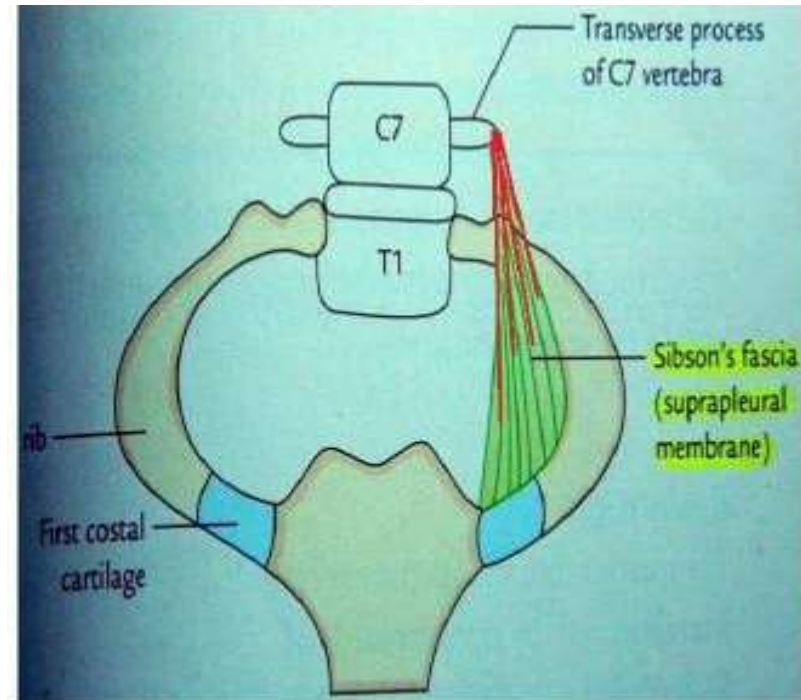
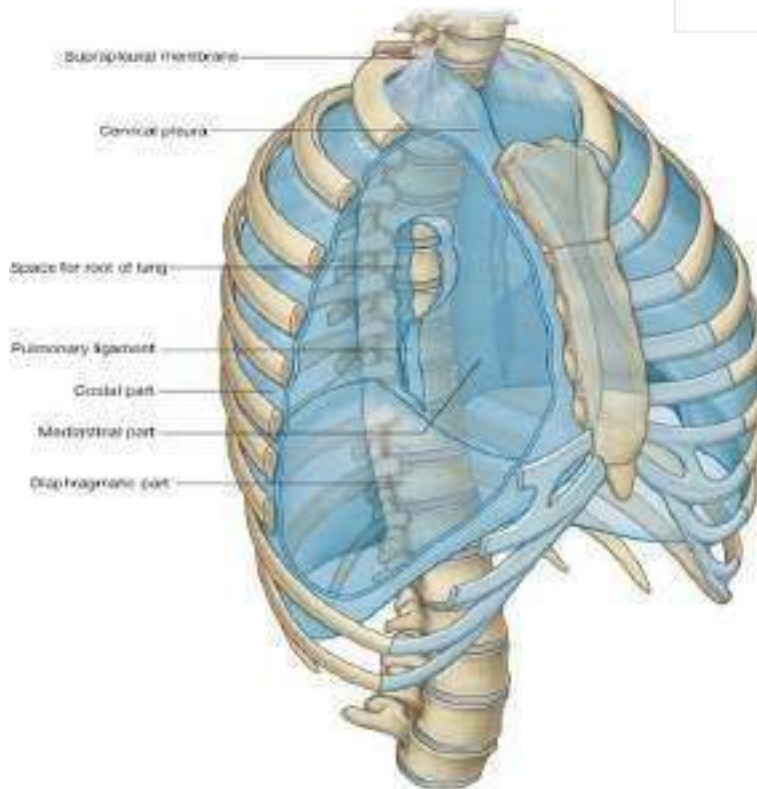
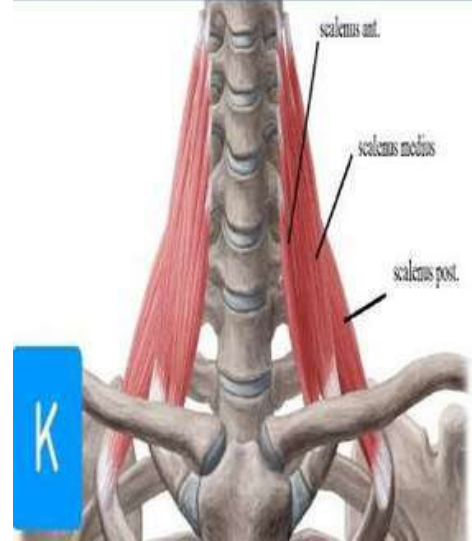
ϒ-Scalenus anterior Ϛ-

Scalenus medius ε-Scalenus

posterior



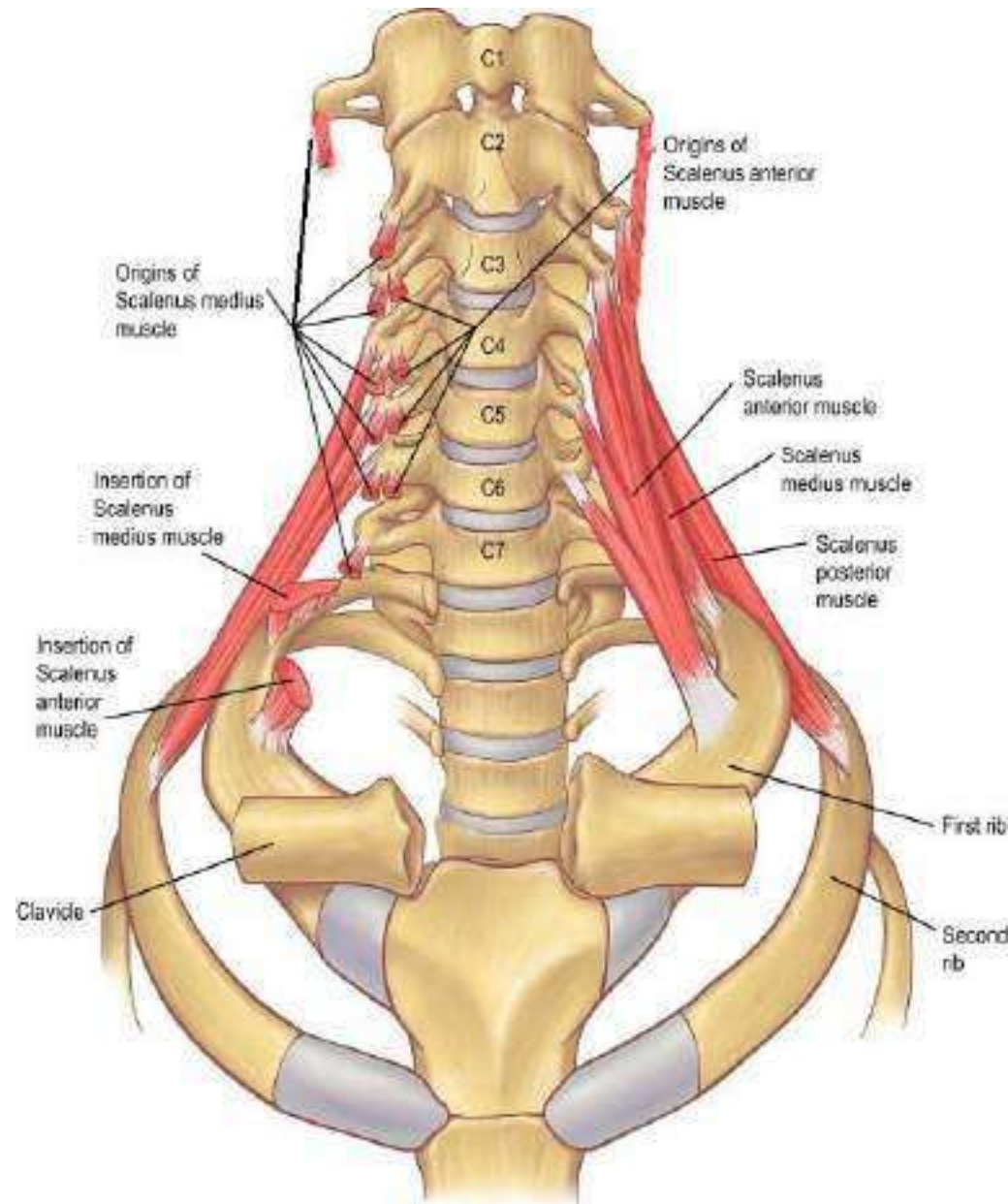
Scalene muscles

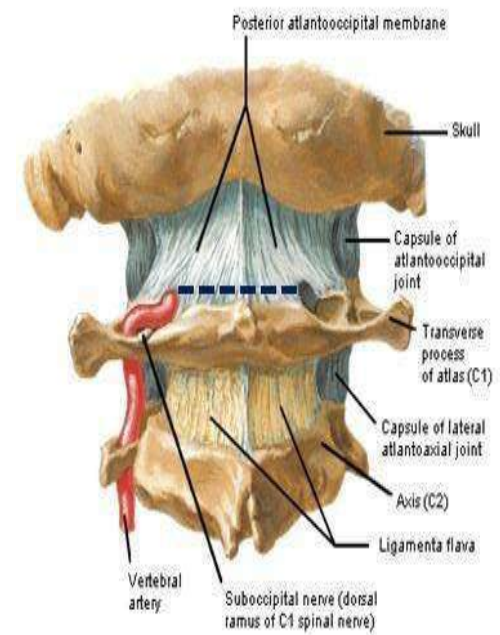
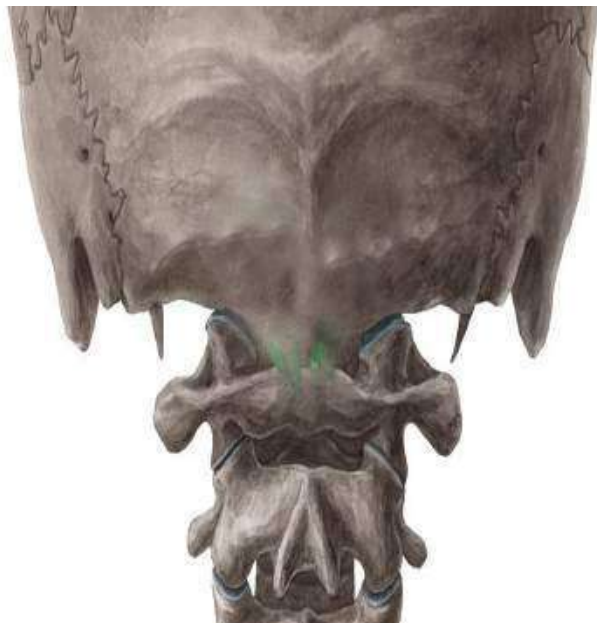

ϒ-Scalenus anterior

ϛ-Scalenus medius

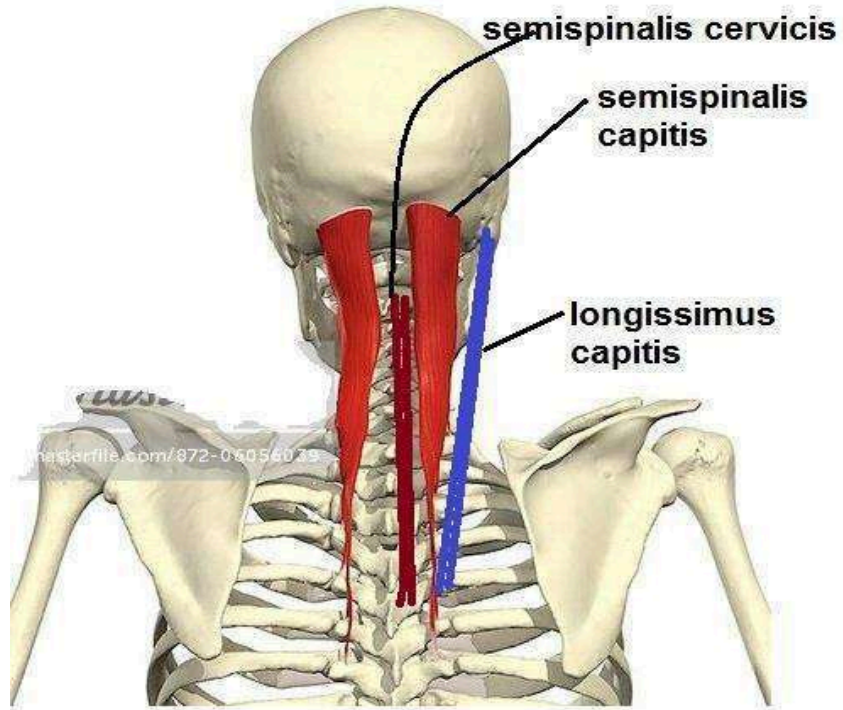
Ϝ-Scalenus posterior



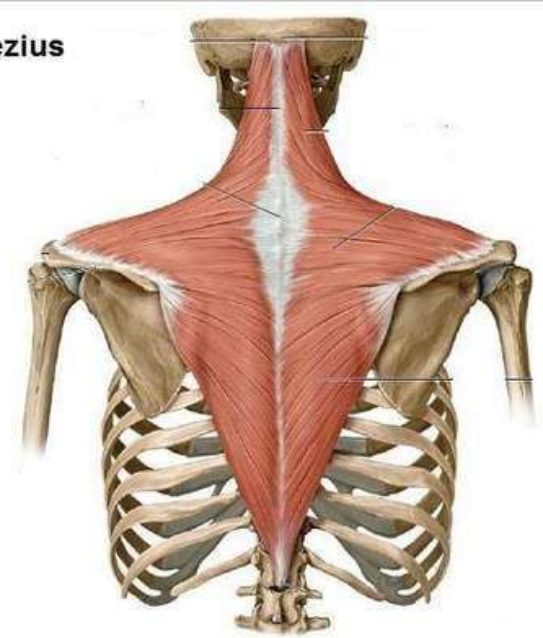


1st LAYER

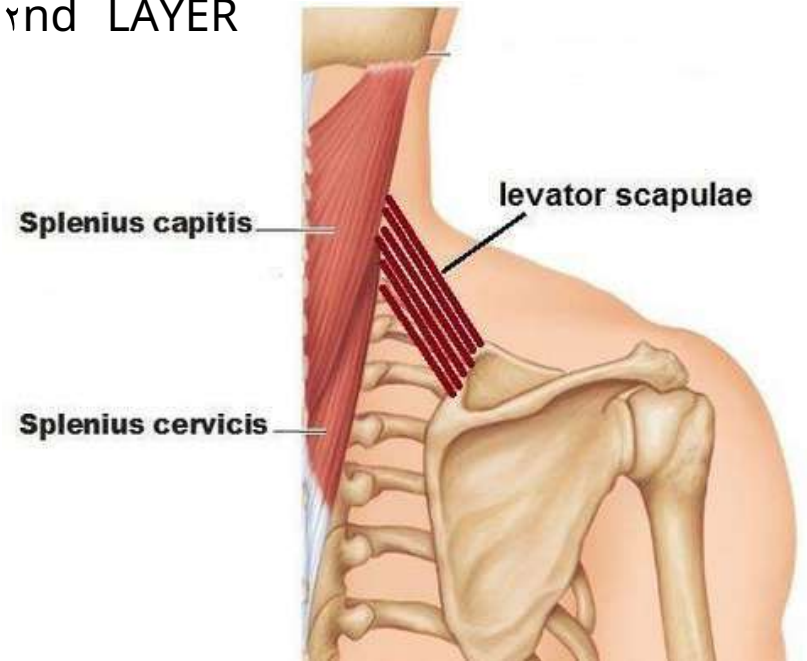
2nd LAYER



trapezius



2nd LAYER

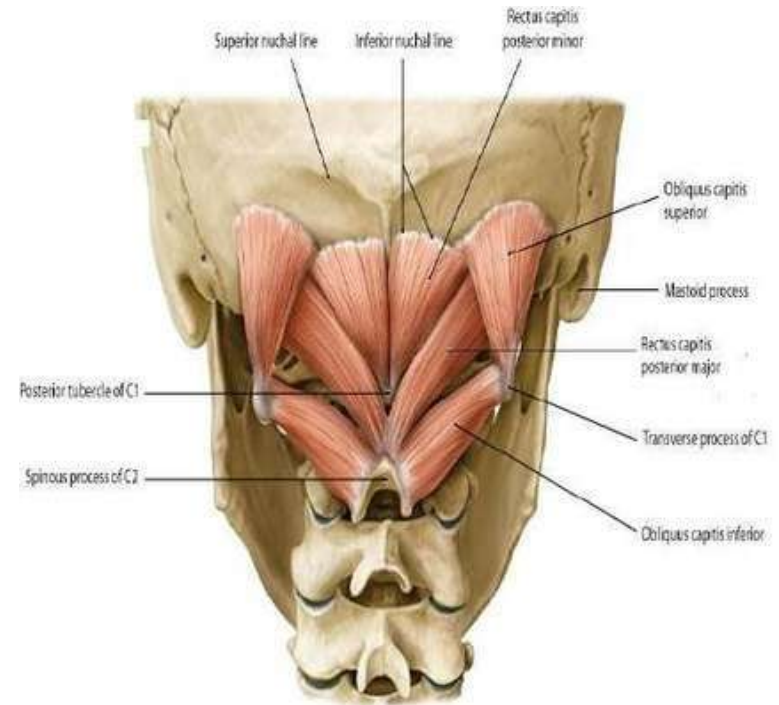


Postvertebral muscles

ξTH LAYER

(SUBOCCIPITAL
MUSCLES)

RECTUS CAPITIS POSTERIOR MINOR
RECTUS CAPITIS POSTERIOR MAJOR
INFERIOR OBLIQUE
SUPERIOR OBLIQUE



SUBOCCIBITAL TRIANGLE

Boundaries:-

Inferior: -inferior oblique

Above & lateral: -superior oblique

Above & medial: -

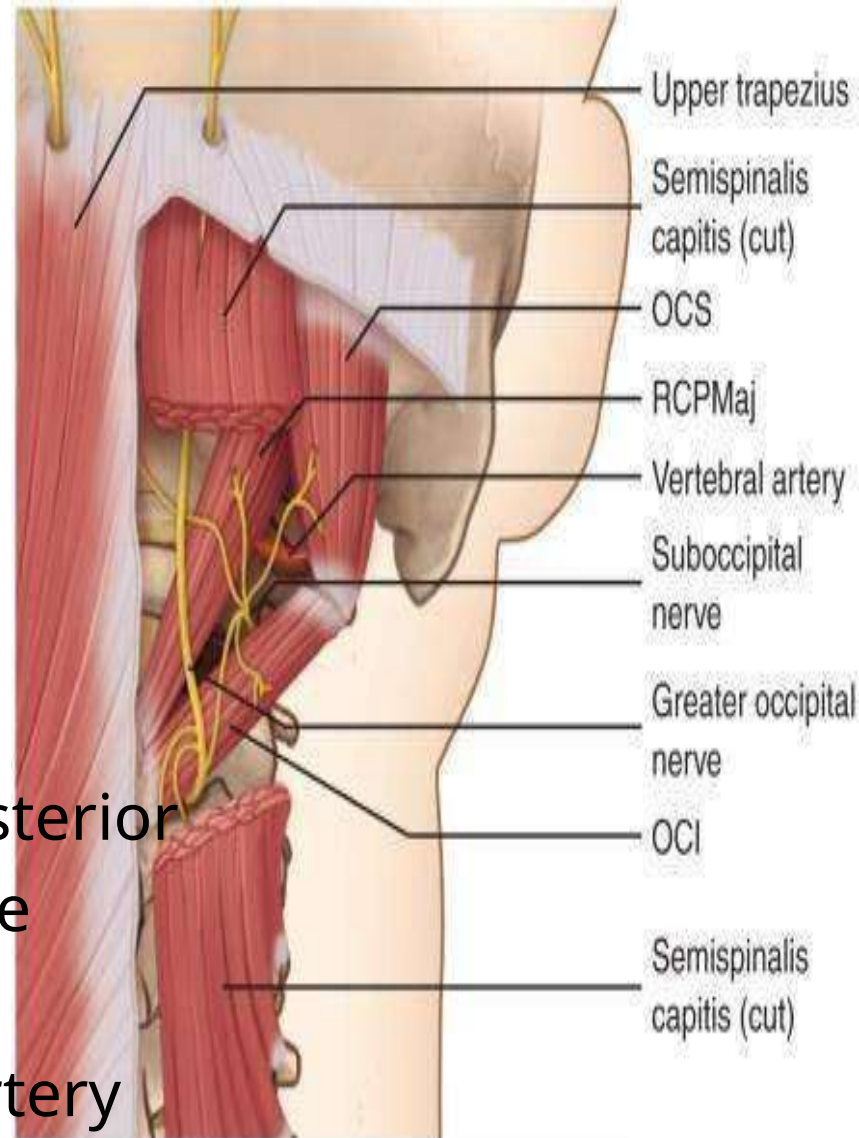
rectus capitis post. Major & minor

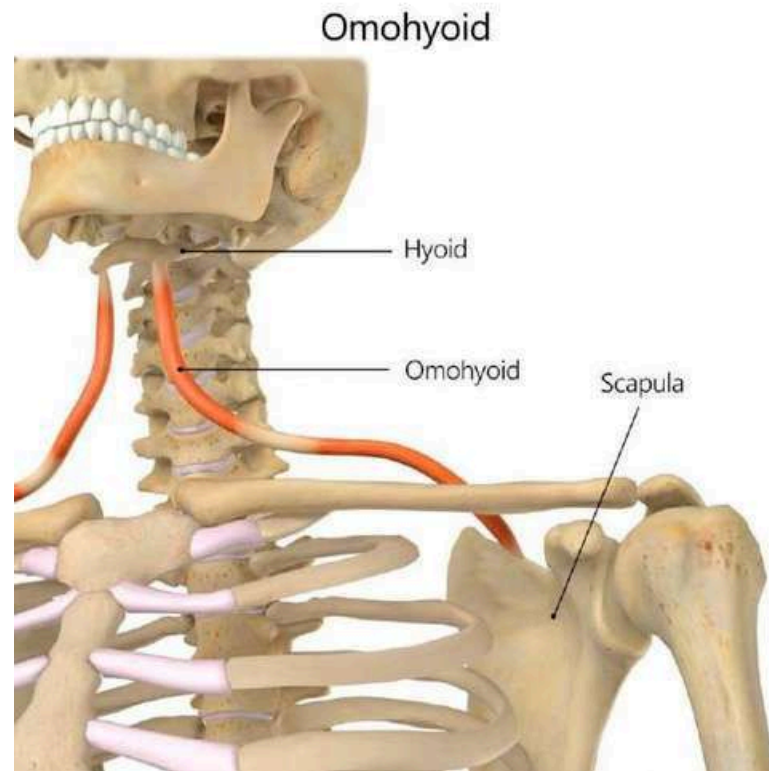
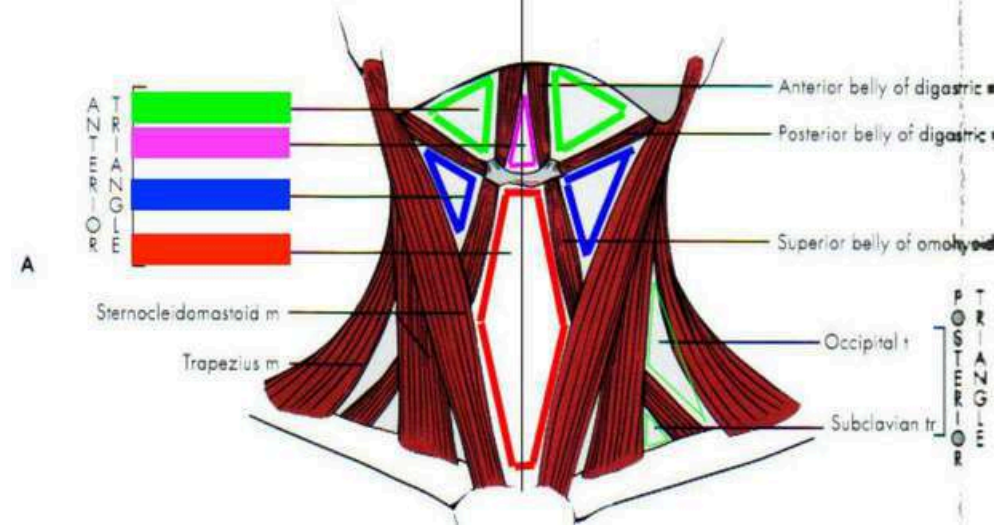
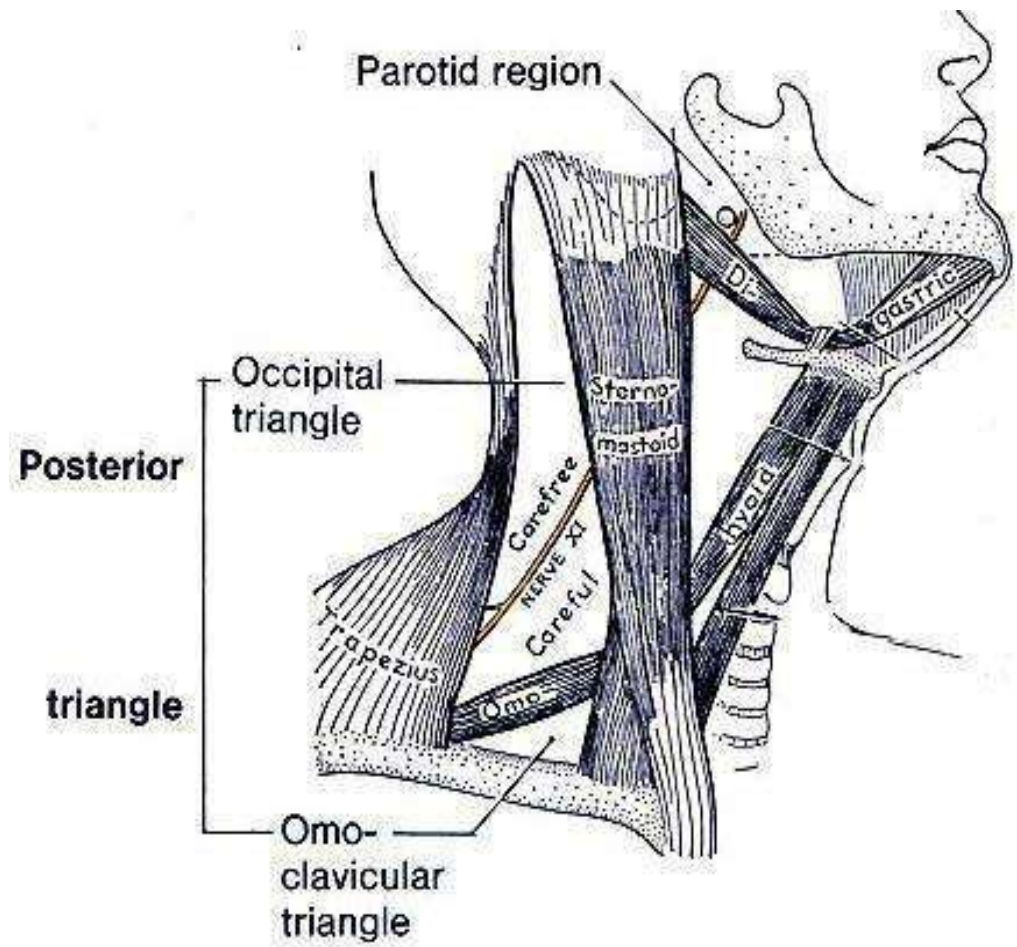
Roof: -

semispinalis capitis &
longissimuscapitis &
greater occipital nerve

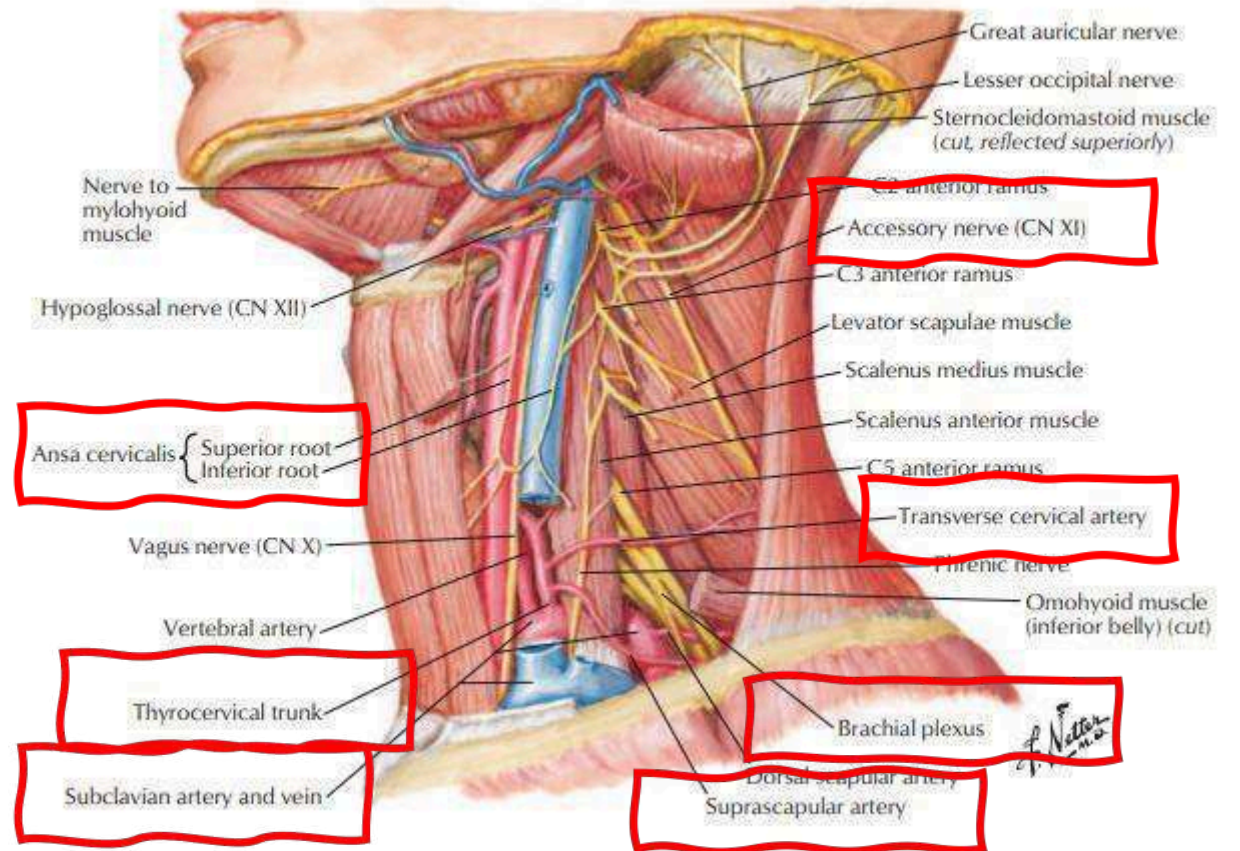
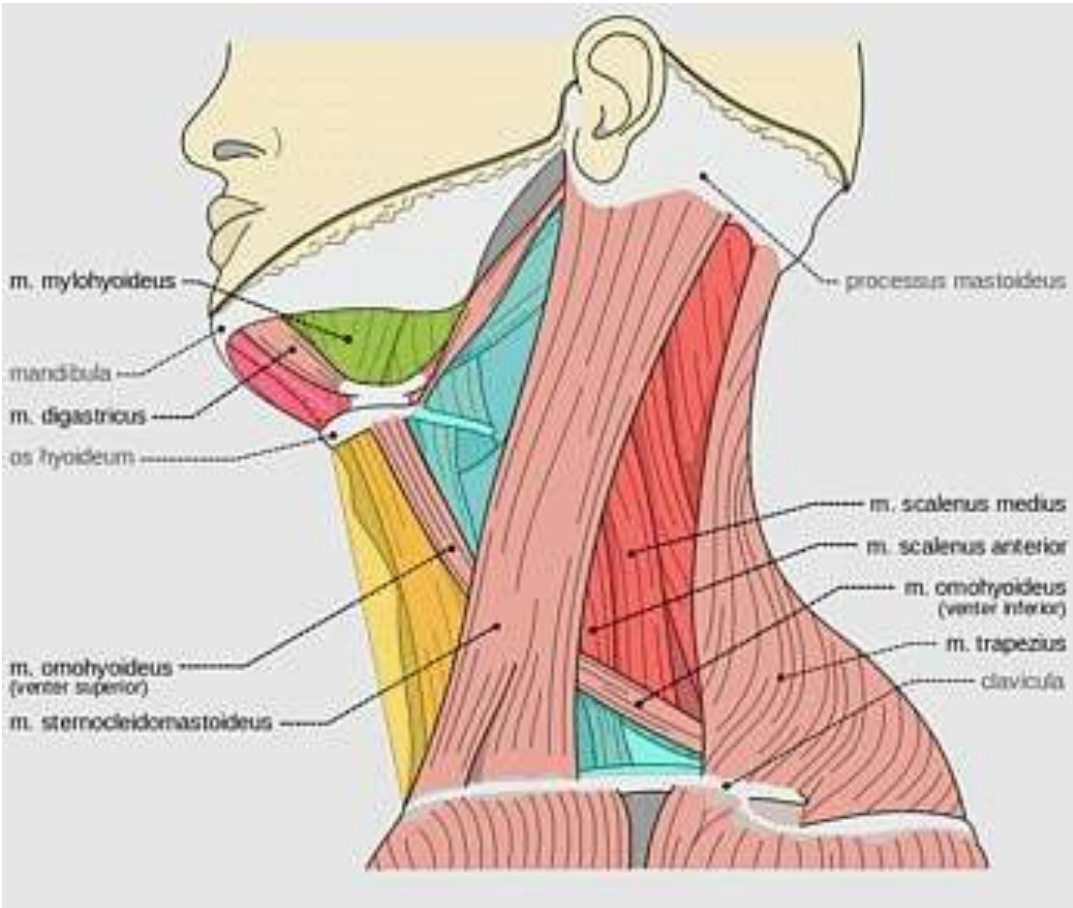
Floor: -posterior arch of atlas & posterior
atlanto-occipital membrane

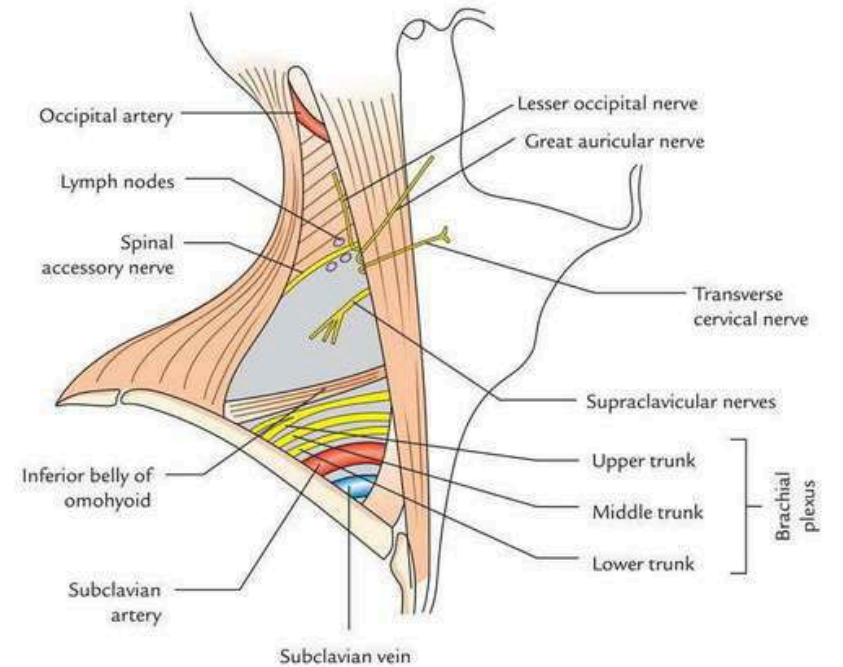
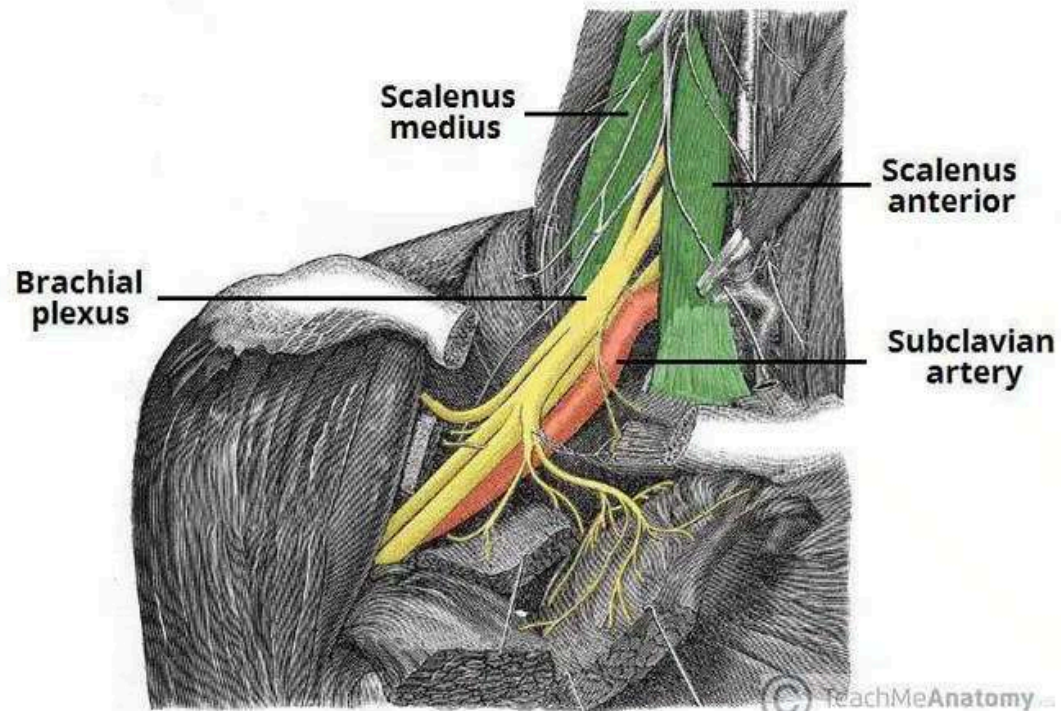
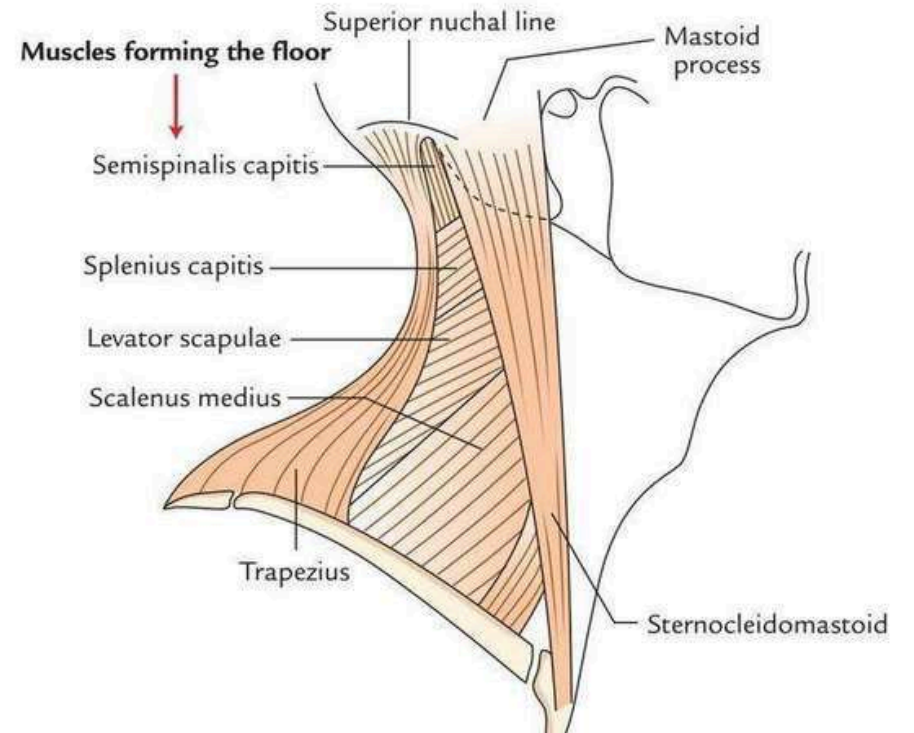
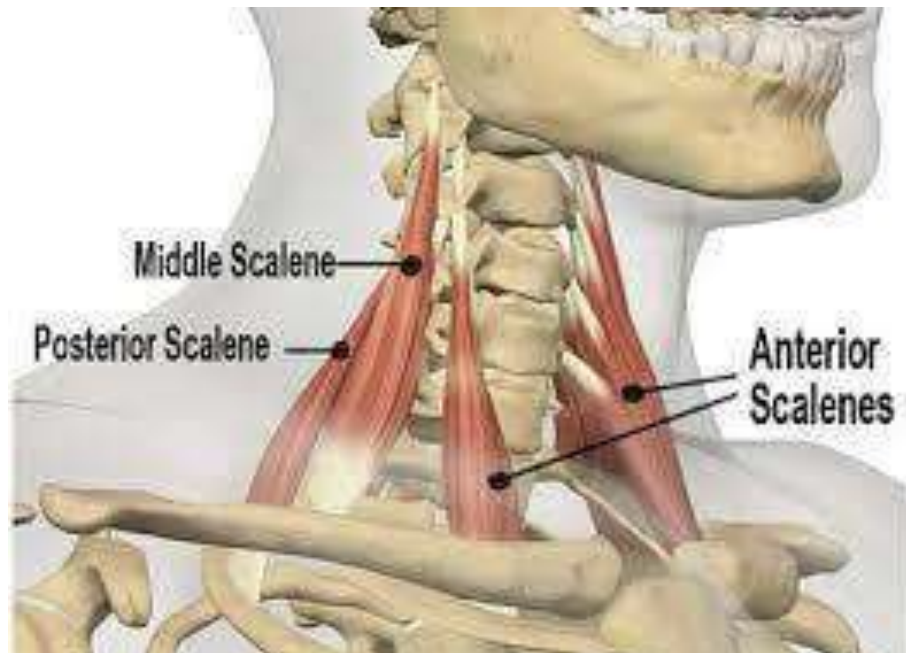
Contents: - dorsal ramus of c
rdpart of vertebral artery

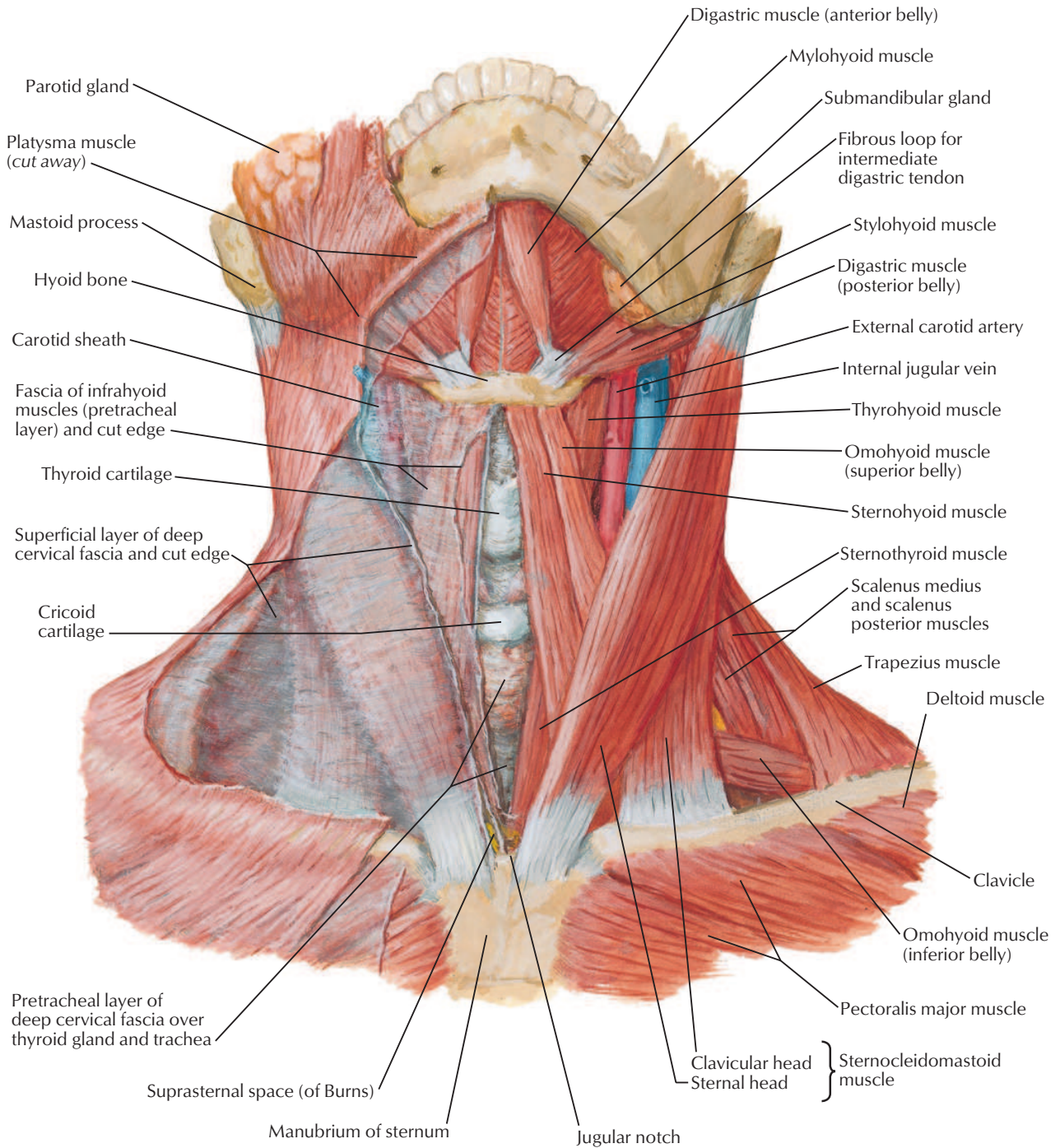




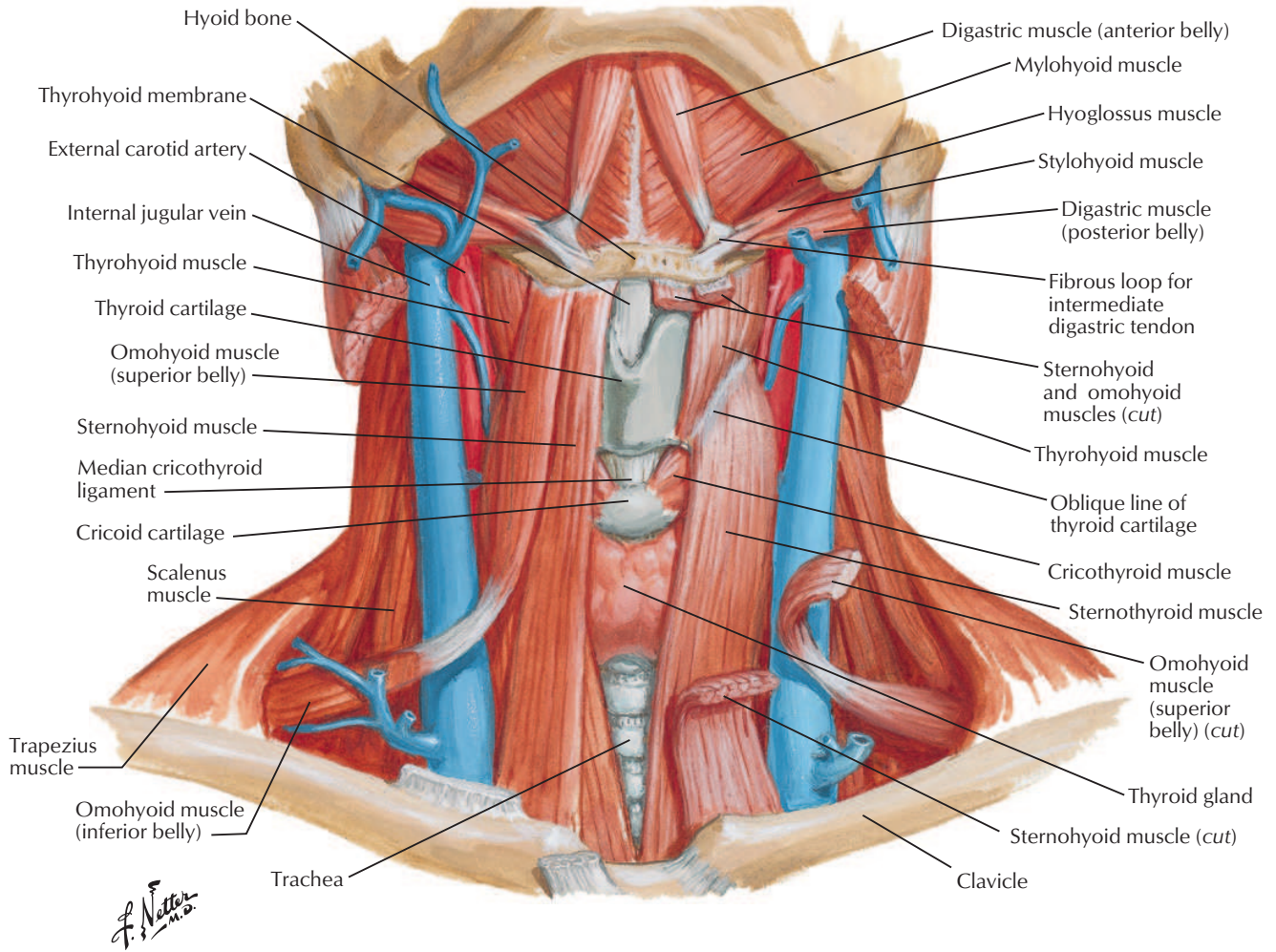
مش هاي الصورة اللي بالمحاضرة بس هاي اوضح بكثير



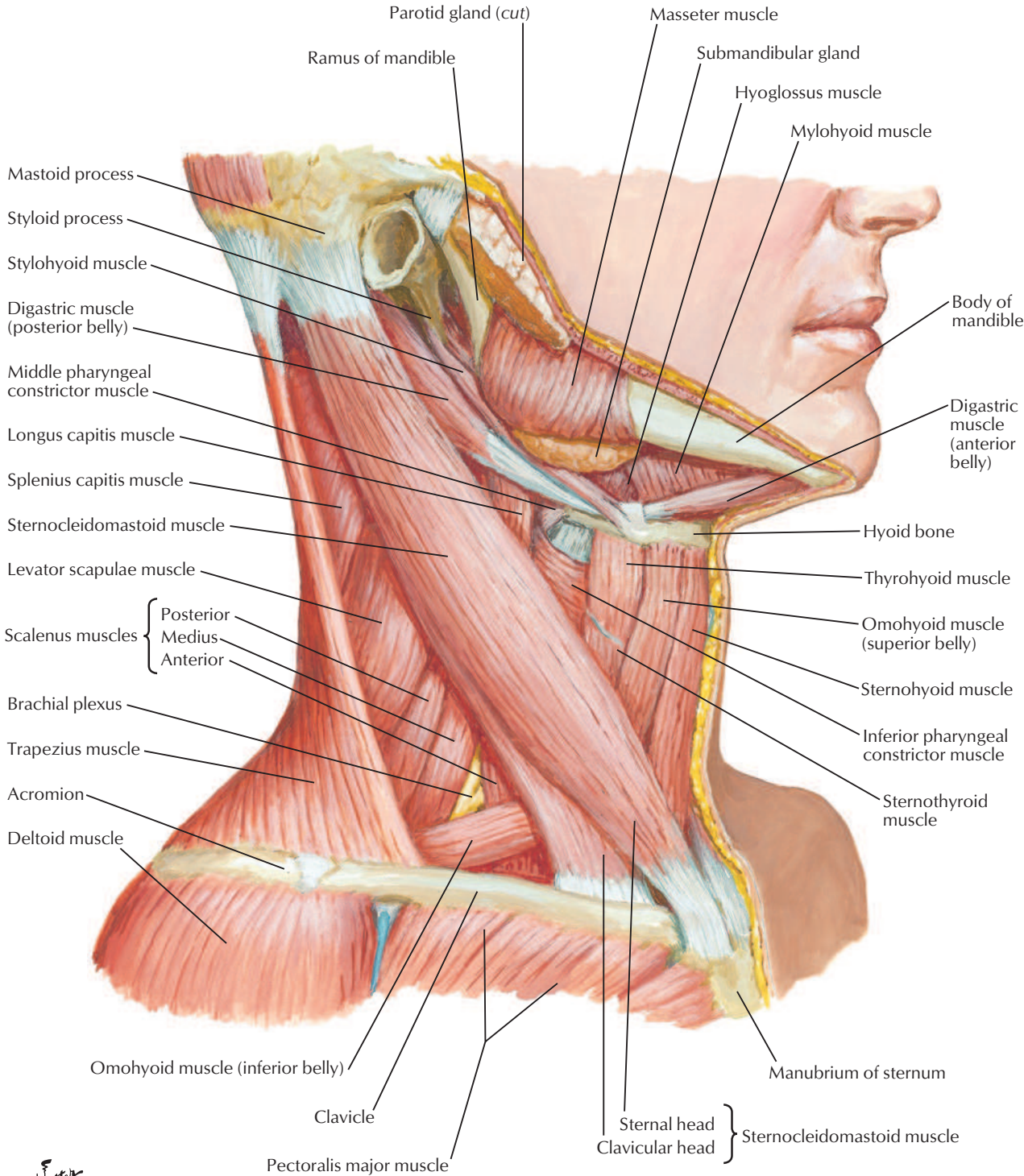




F. Netter M.D.

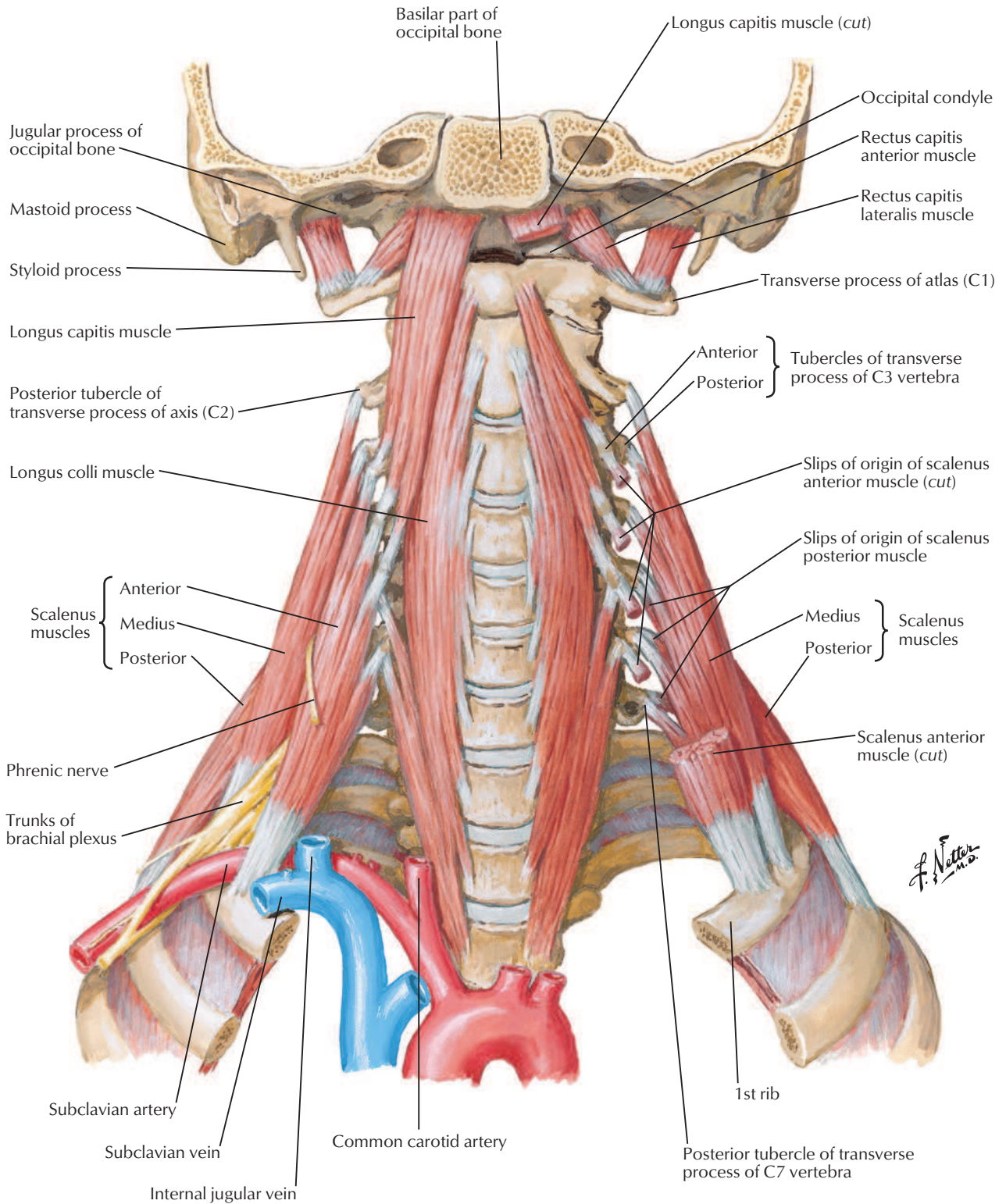


See also Plates 32, 35, 38

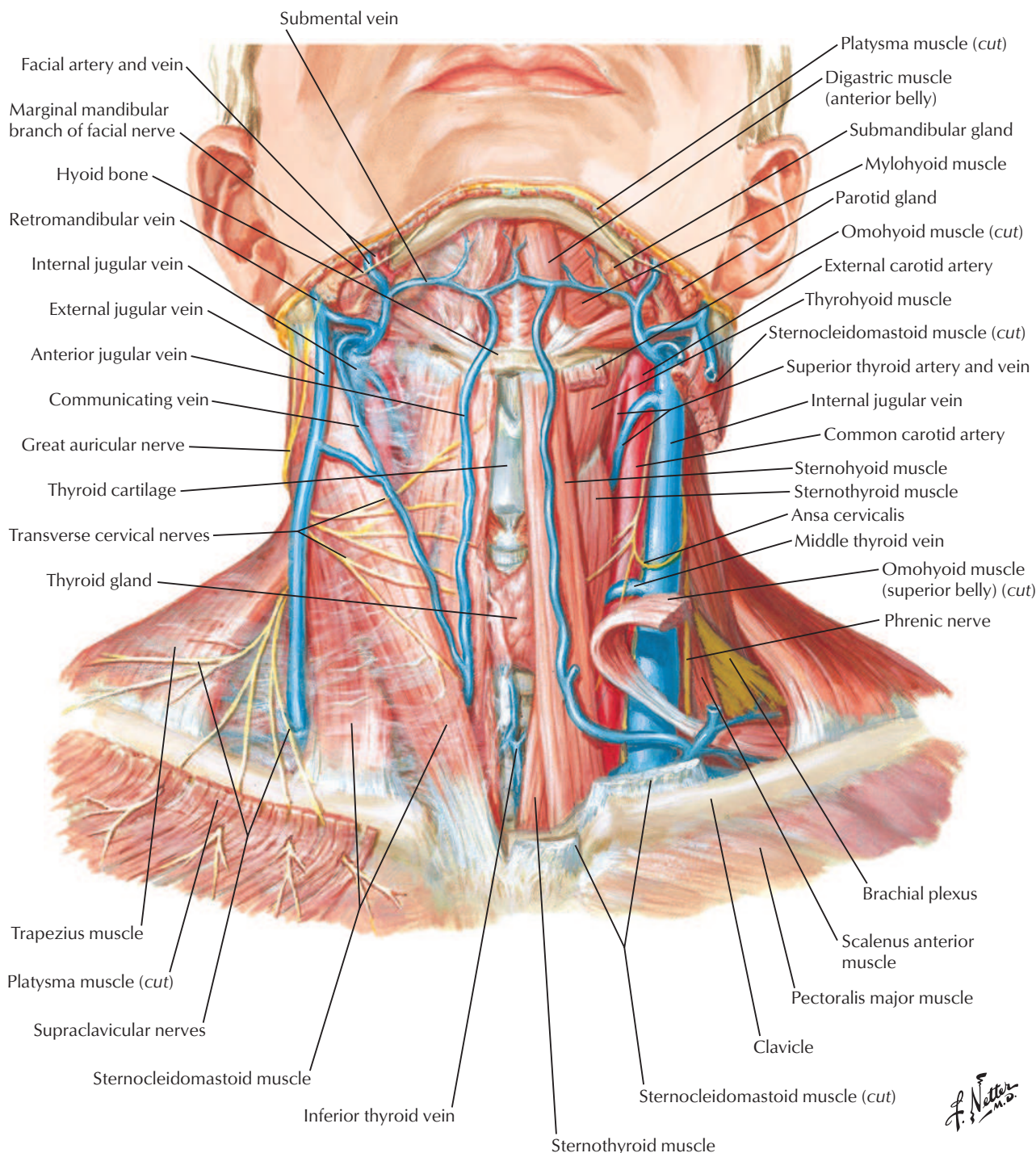


F. Netter M.D.

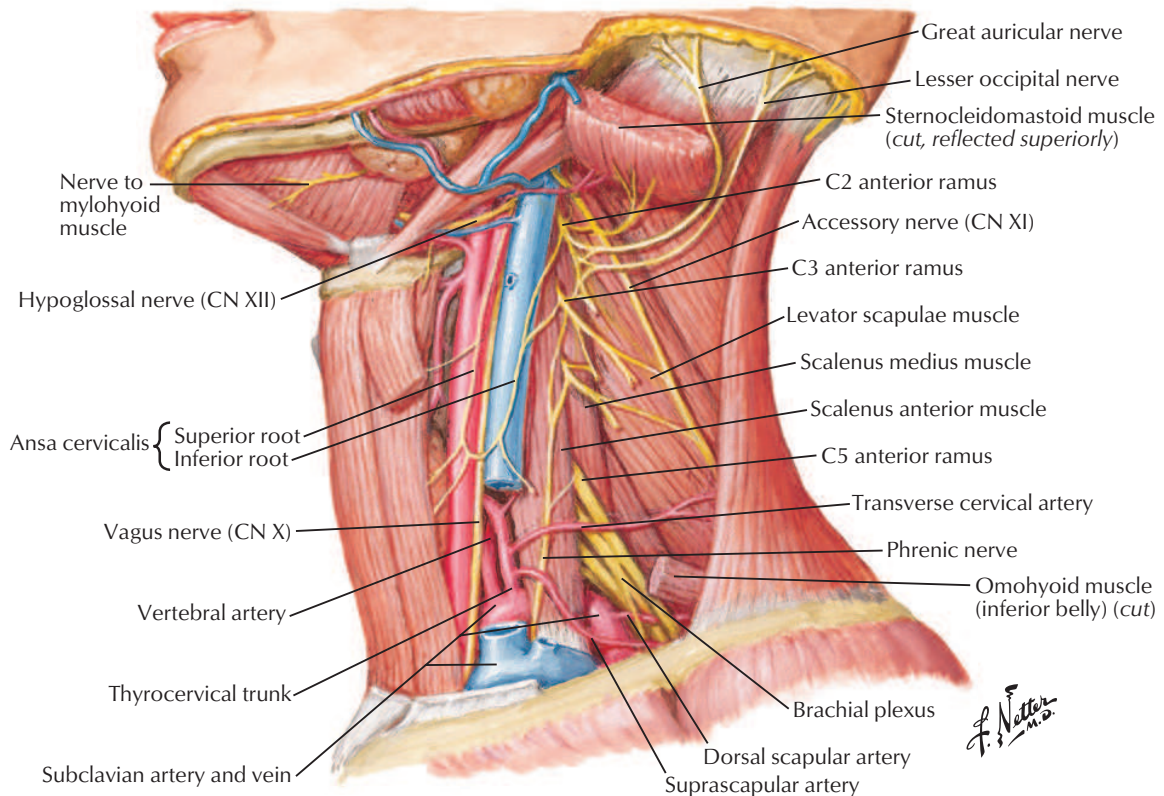
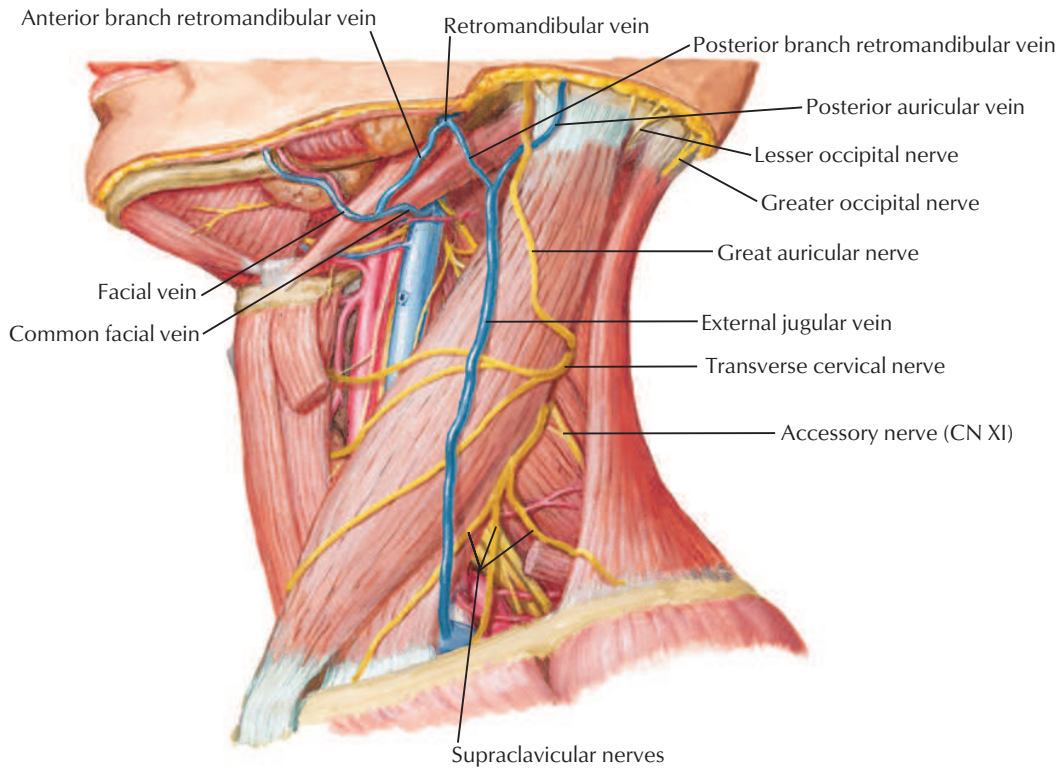
Anterior and Lateral Cervical Muscles



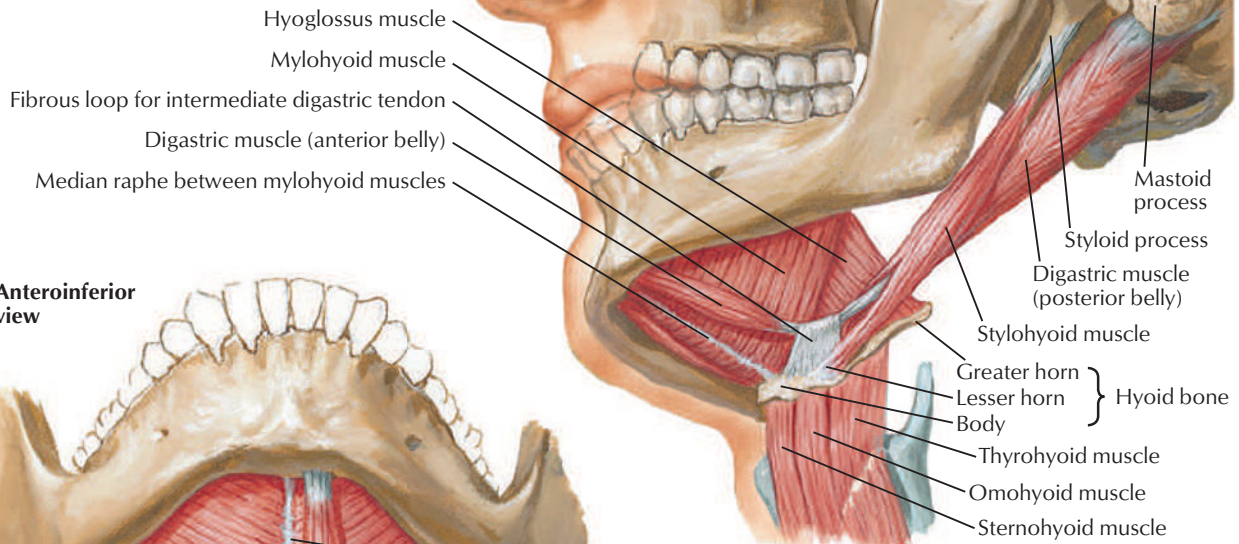
For deep veins of neck see [Plate 84](#)



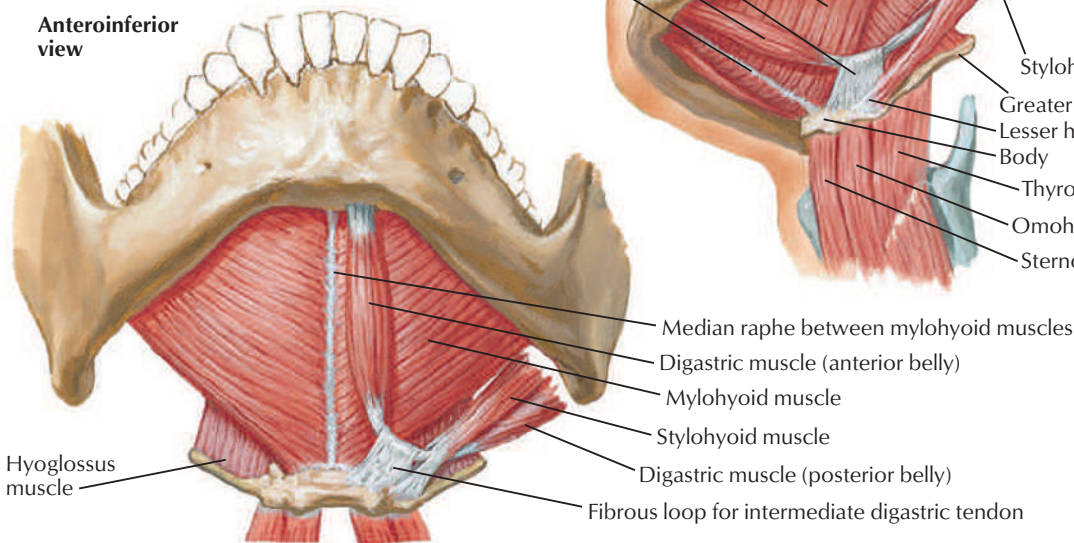
F. Netter M.D.



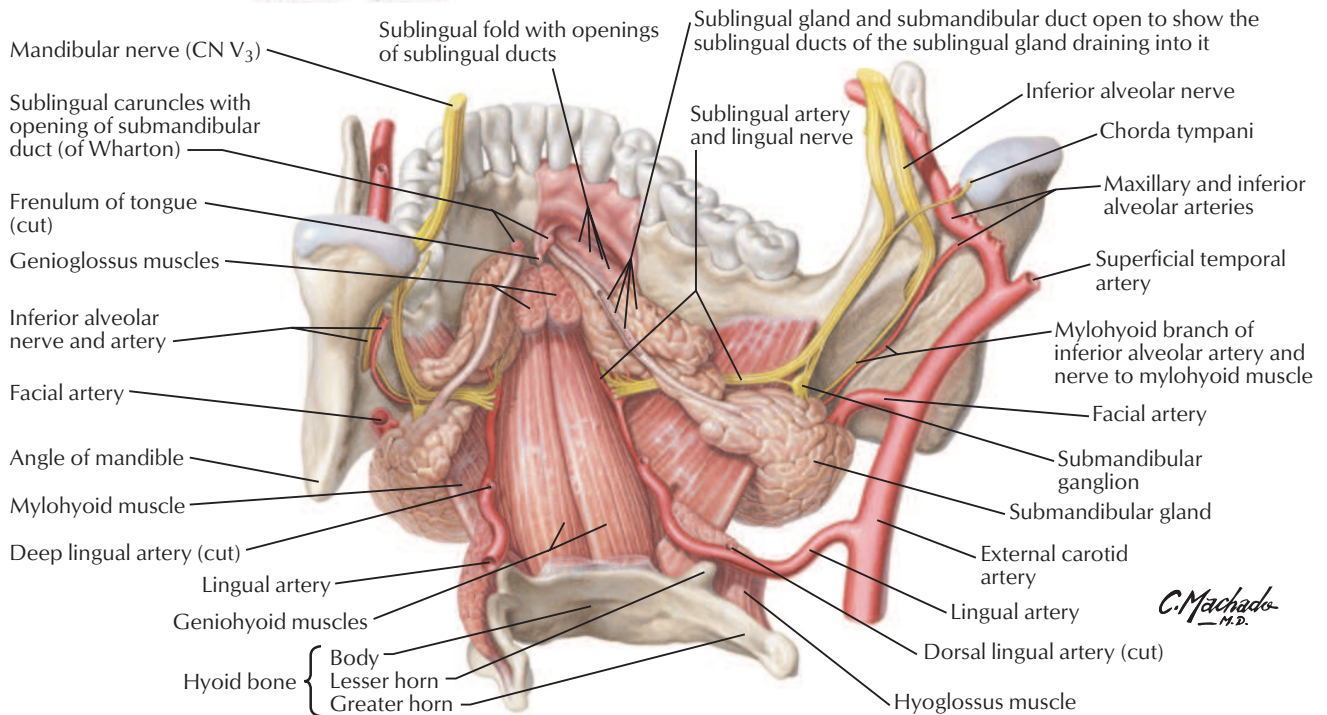
Lateral, slightly inferior view



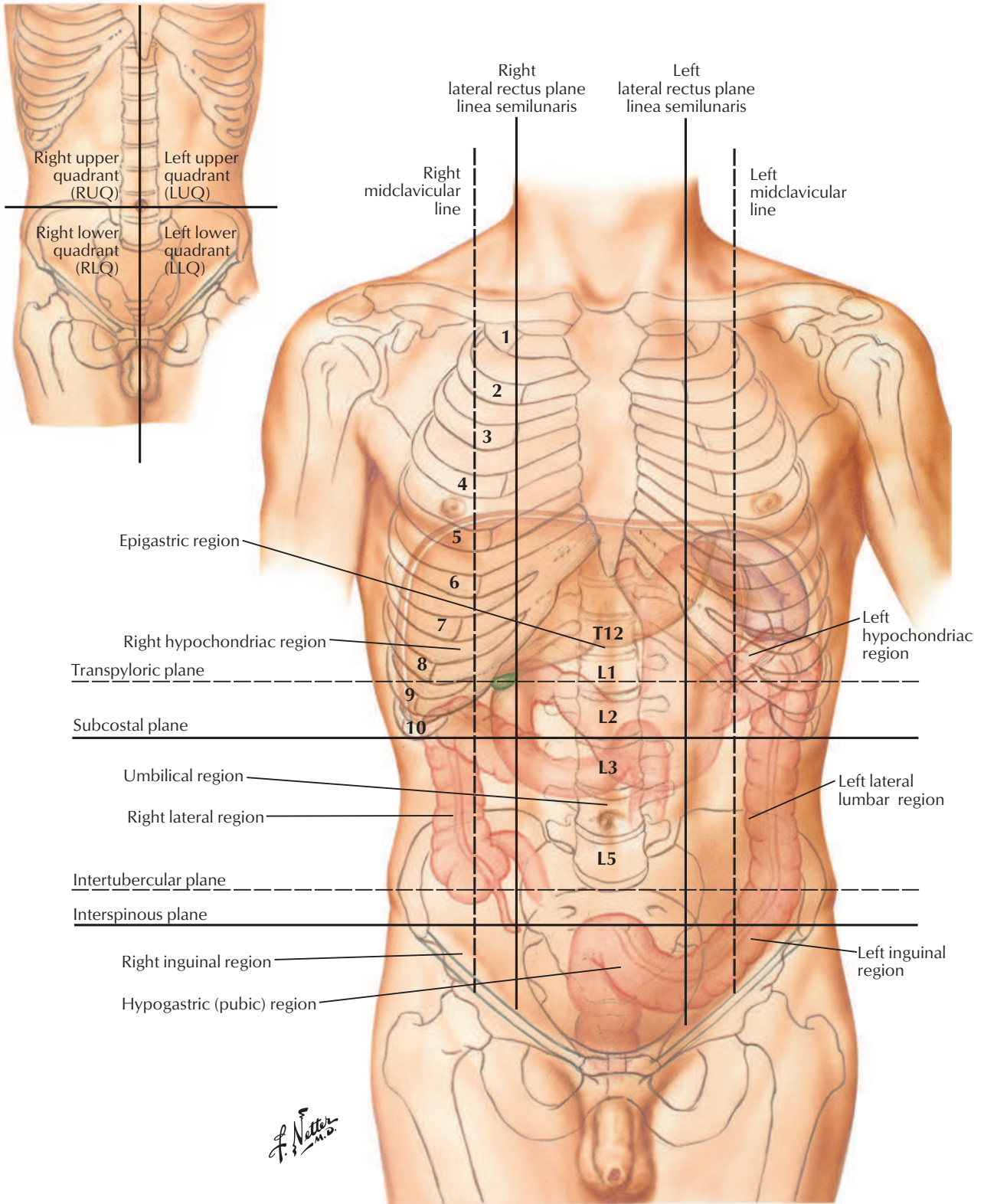
Anteroinferior view

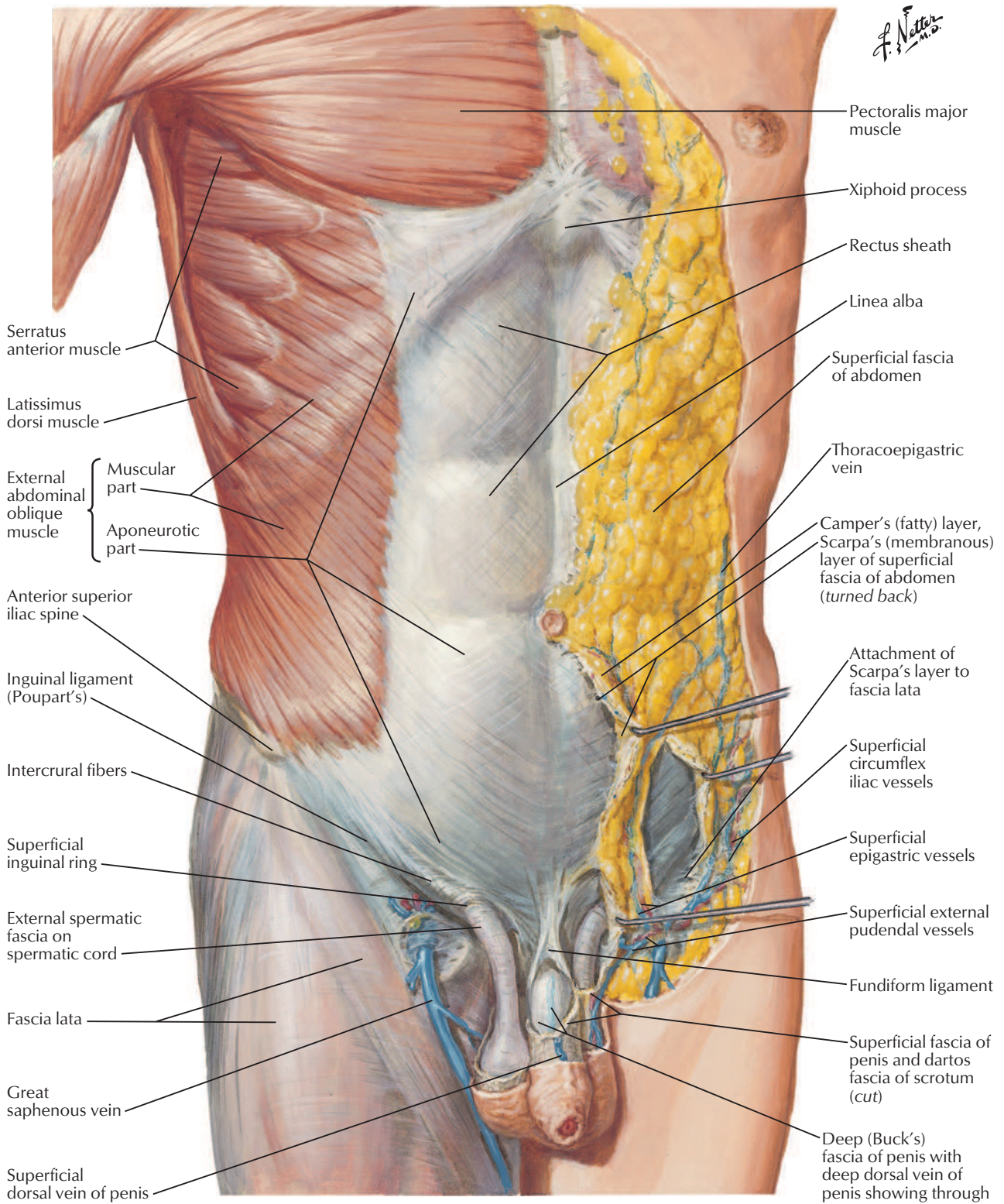


F. Netter M.D.

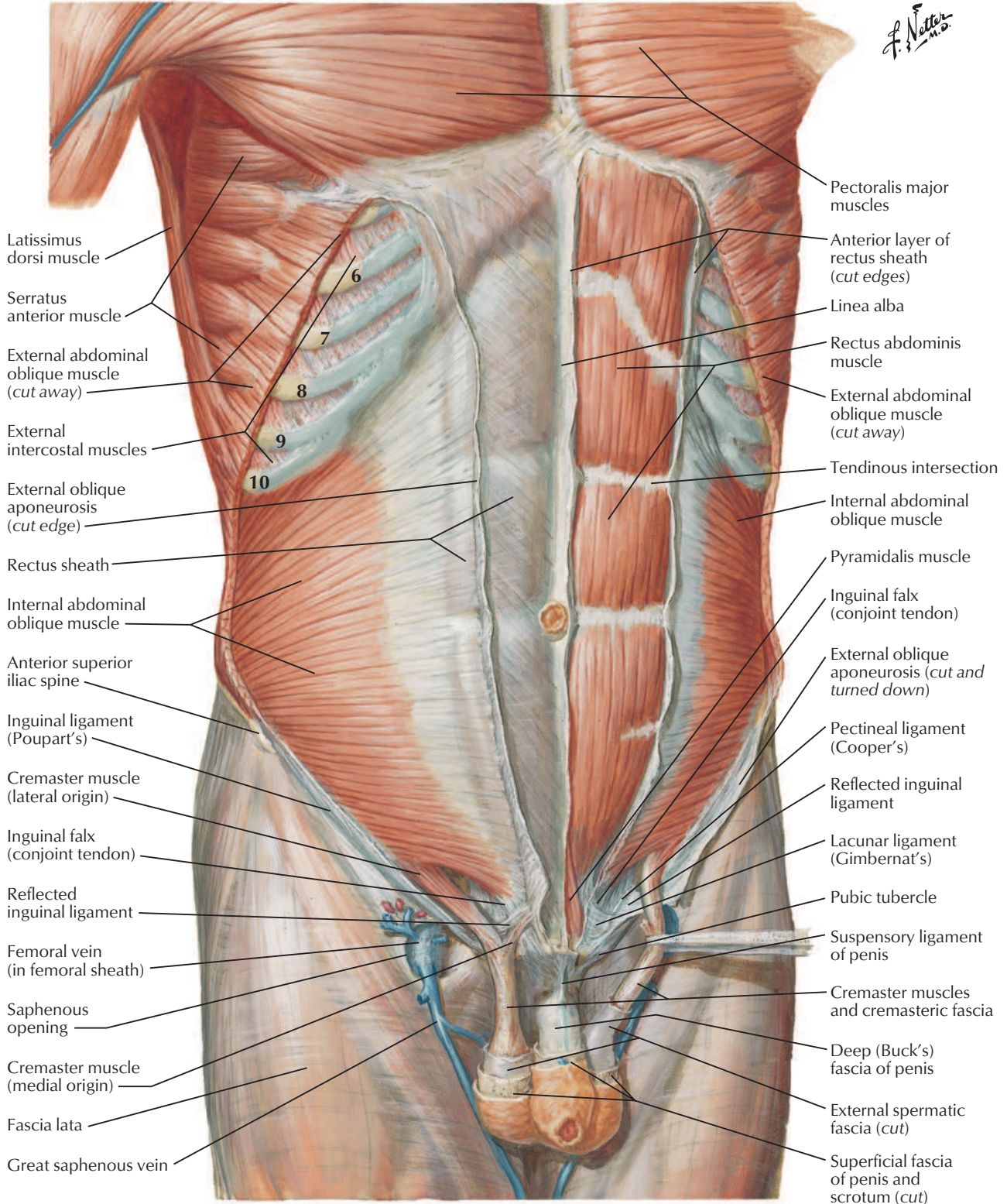


C. Machado M.D.



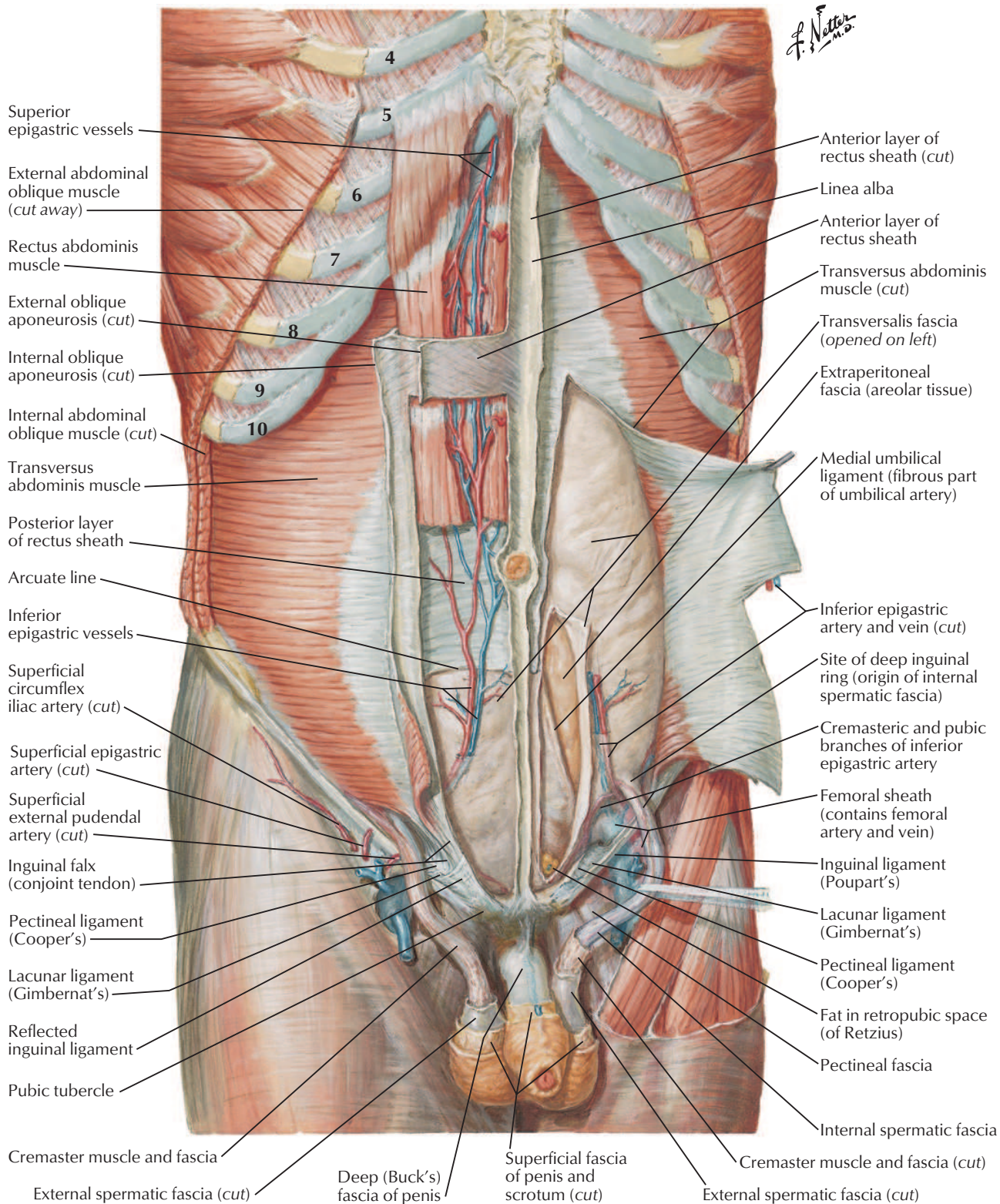


F. Netter M.D.



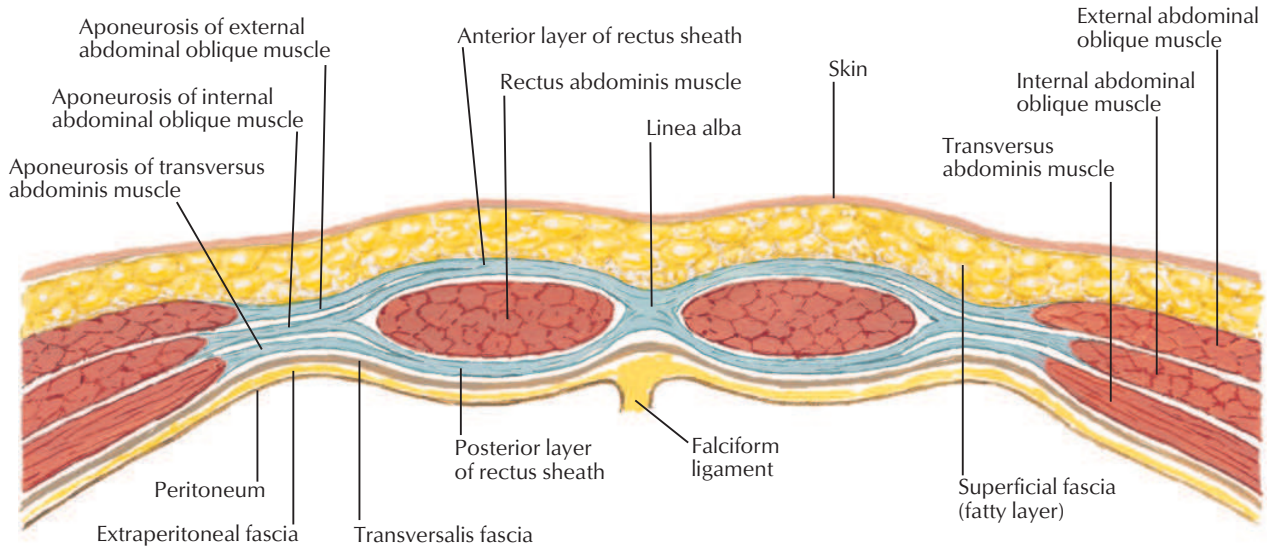


F. Netter M.D.



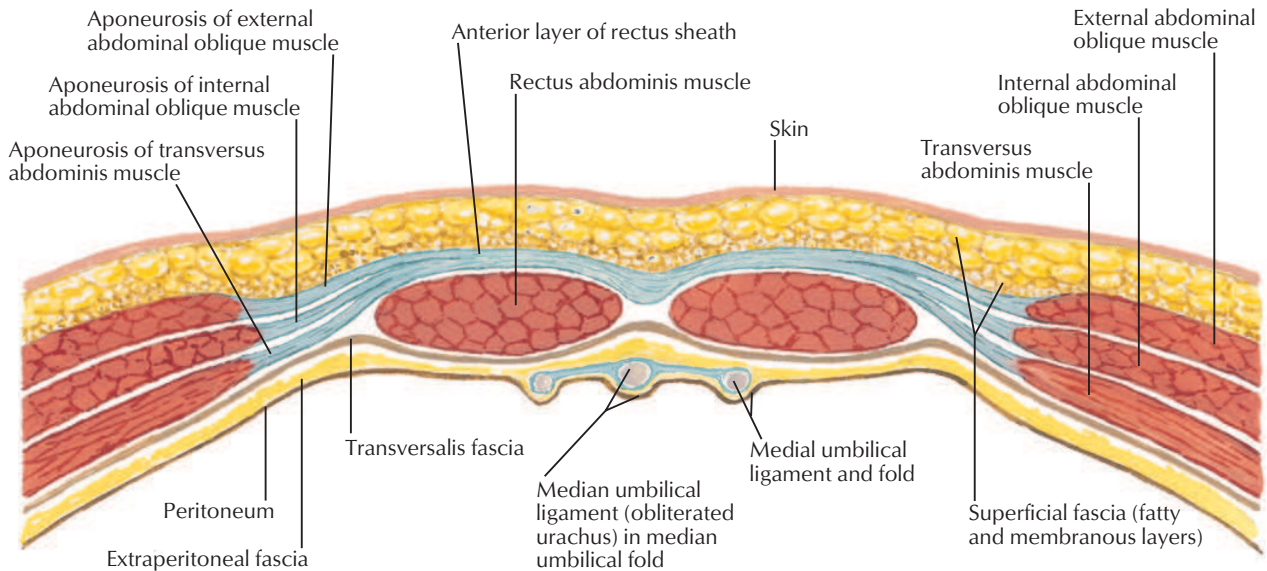


Section above arcuate line



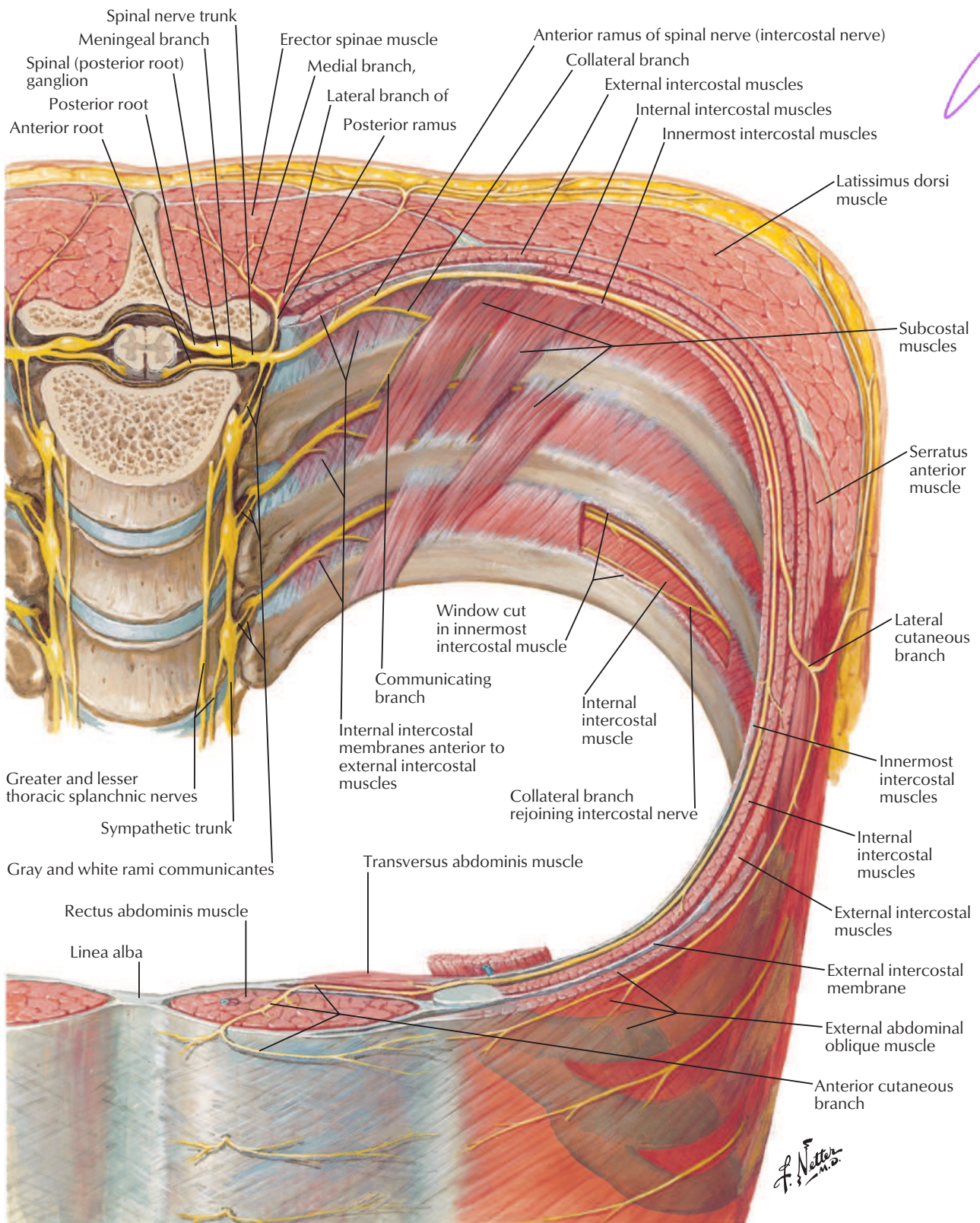
Aponeurosis of internal abdominal oblique muscle splits to form anterior and posterior layers of rectus sheath. Aponeurosis of external abdominal oblique muscle joins anterior layer of sheath; aponeurosis of transversus abdominis muscle joins posterior layer. Anterior and posterior layers of rectus sheath unite medially to form linea alba.

Section below arcuate line

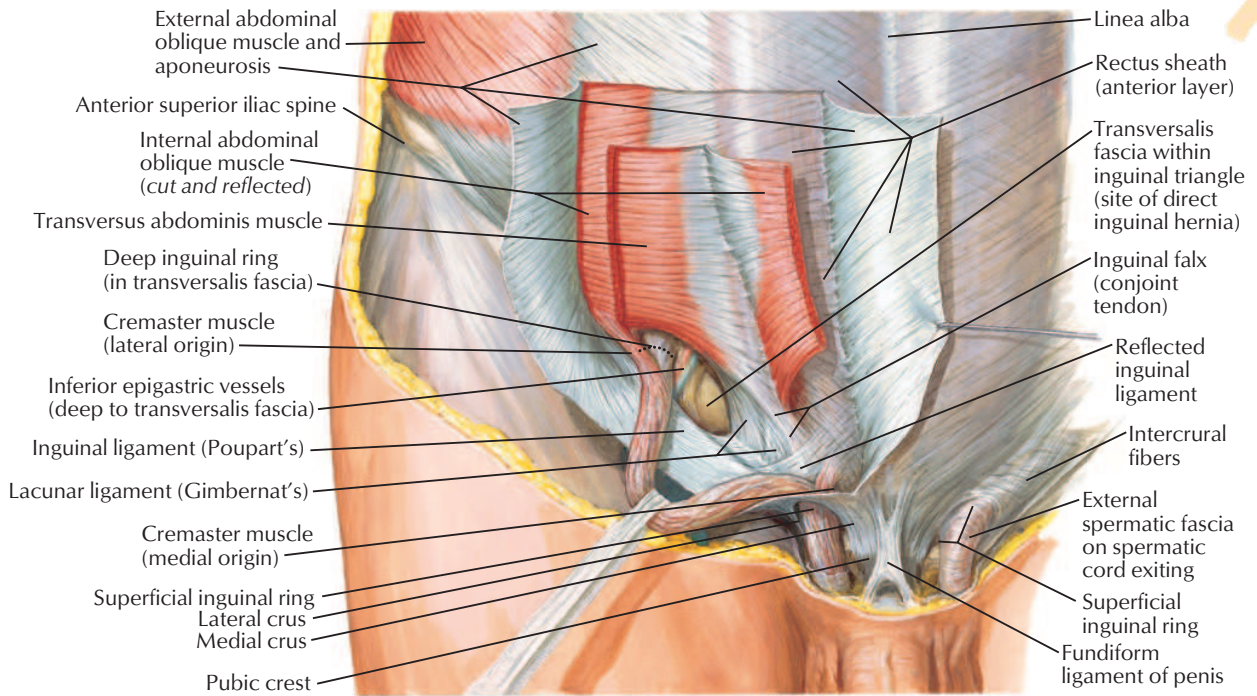


Aponeurosis of internal abdominal oblique muscle does not split at this level but passes completely anterior to rectus abdominis muscle and is fused there with both aponeurosis of external abdominal oblique muscle and that of transversus abdominis muscle. Thus, posterior wall of rectus sheath is absent below arcuate line, leaving only transversalis fascia.

F. Netter M.D.

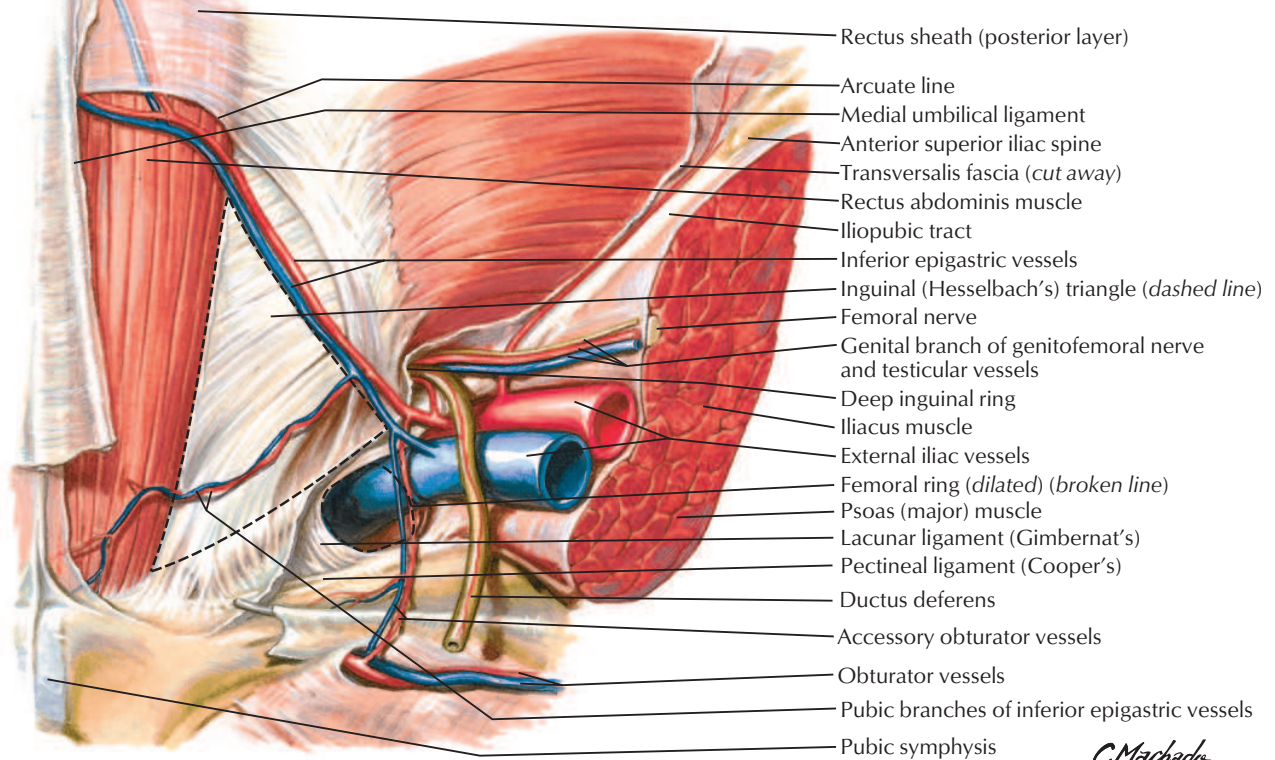


Anterior view



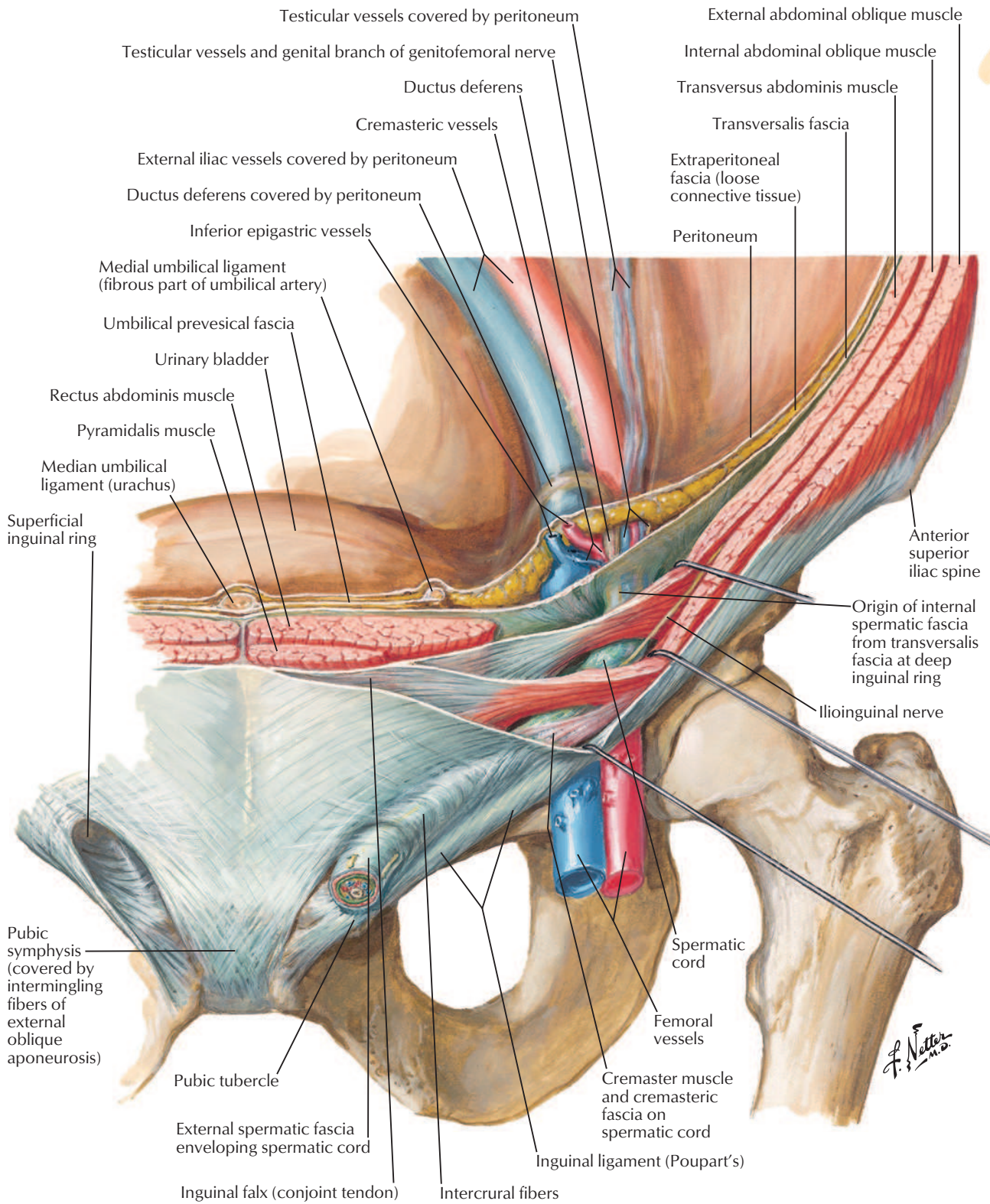
F. Netter M.D.

Posterior (internal) view



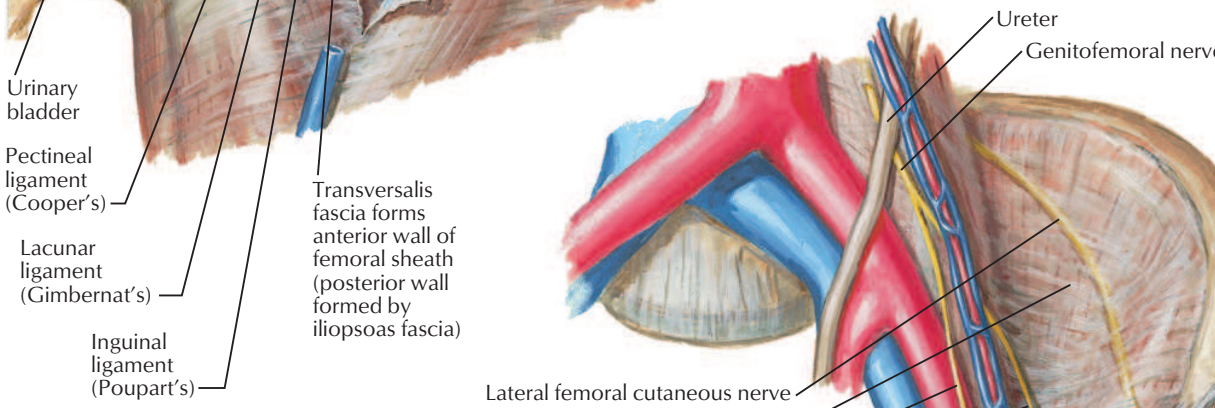
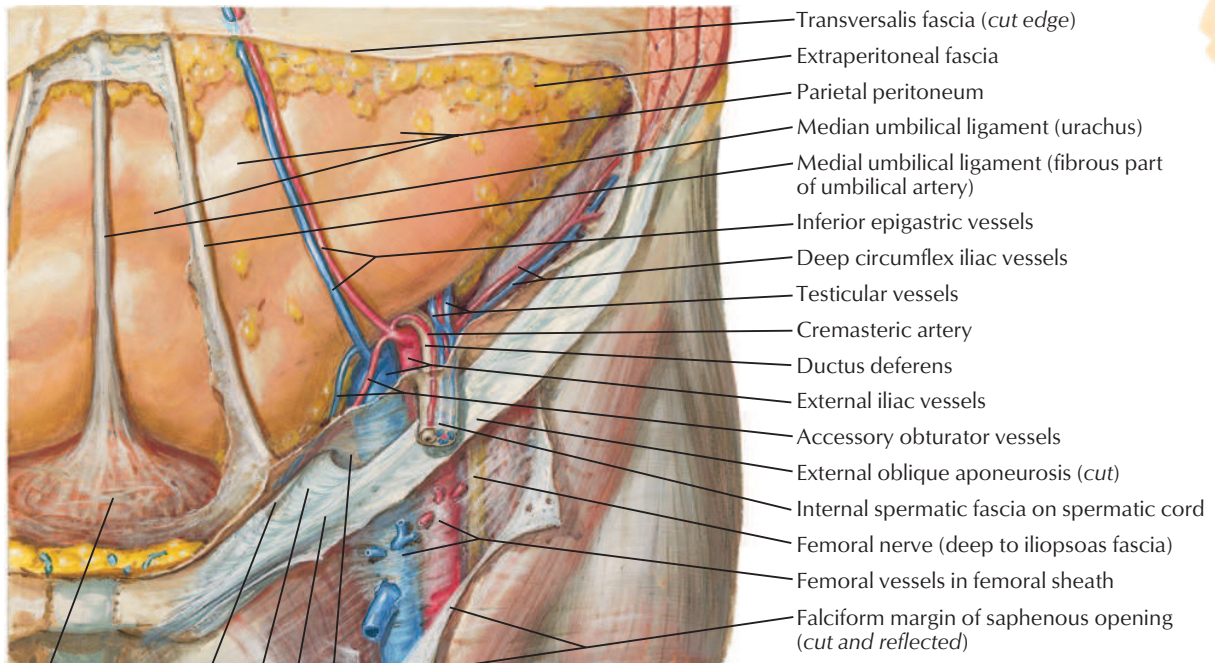
Hesselbach's triangle by Carlos Machado after Frank Netter

C. Machado M.D.



Femoral Sheath and Inguinal Canal

See also [Plates 253, 254, 256](#)



- Urinary bladder
- Pectineal ligament (Cooper's)
- Lacunar ligament (Gimbernat's)
- Inguinal ligament (Poupart's)

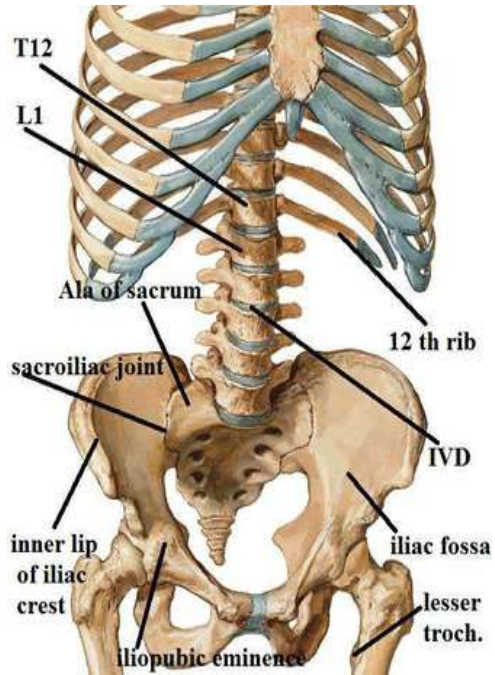
Transversalis fascia forms anterior wall of femoral sheath (posterior wall formed by iliopsoas fascia)

- Transversalis fascia (cut edge)
- Extraperitoneal fascia
- Parietal peritoneum
- Median umbilical ligament (urachus)
- Medial umbilical ligament (fibrous part of umbilical artery)
- Inferior epigastric vessels
- Deep circumflex iliac vessels
- Testicular vessels
- Cremasteric artery
- Ductus deferens
- External iliac vessels
- Accessory obturator vessels
- External oblique aponeurosis (cut)
- Internal spermatic fascia on spermatic cord
- Femoral nerve (deep to iliopsoas fascia)
- Femoral vessels in femoral sheath
- Falciform margin of saphenous opening (cut and reflected)

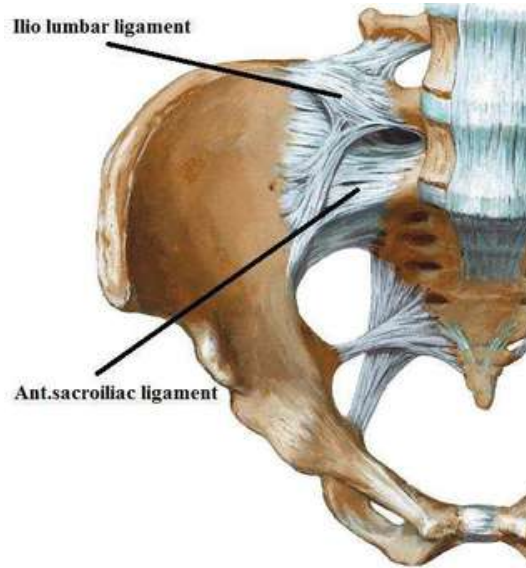
- Ureter
- Genitofemoral nerve
- Lateral femoral cutaneous nerve
- Iliac fascia
- Genital branch of genitofemoral nerve
- Femoral branch of genitofemoral nerve
- Testicular vessels
- External iliac vessels
- Inferior epigastric vessels
- Ductus deferens and cremasteric artery
- Pectineal ligament (Cooper's)
- Femoral ring
- Transversalis fascia forms anterior wall of femoral sheath
- Lacunar ligament (Gimbernat's)
- Inguinal ligament (Poupart's)
- Lymph node (Cloquet's) in femoral canal
- Femoral sheath (cut open)



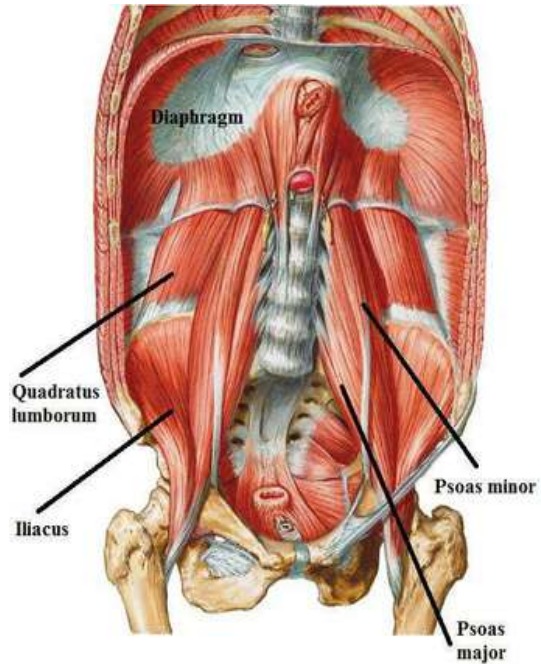
skeleton



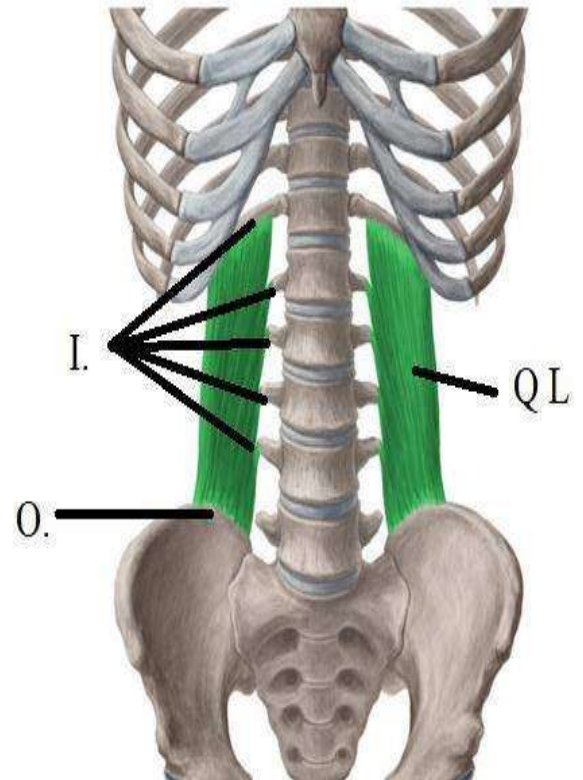
skeleton



post. abd. wall muscles

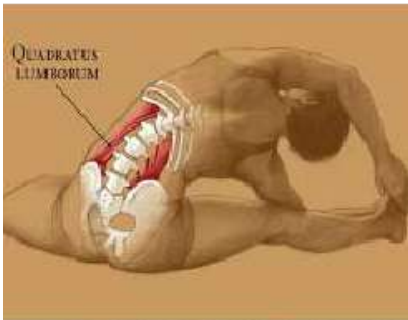
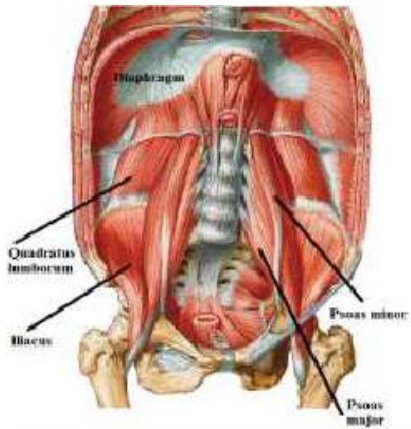


T-QUADRATUS LUMBORUM



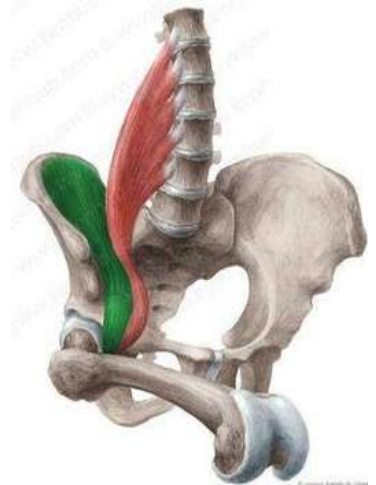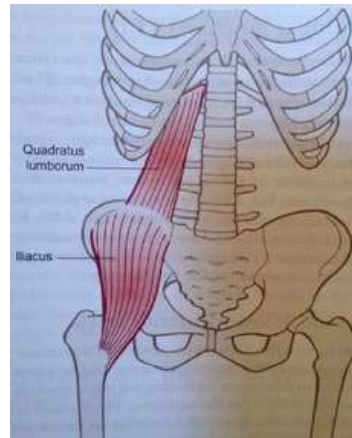
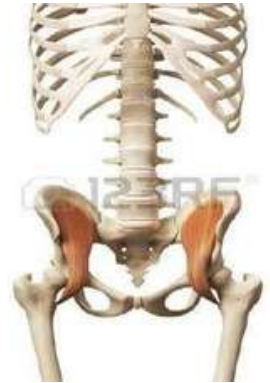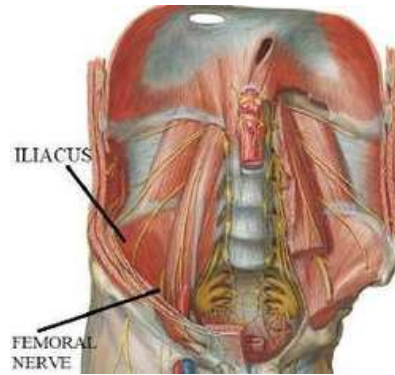
1-QUADRATUS LUMBORUM

A.:-

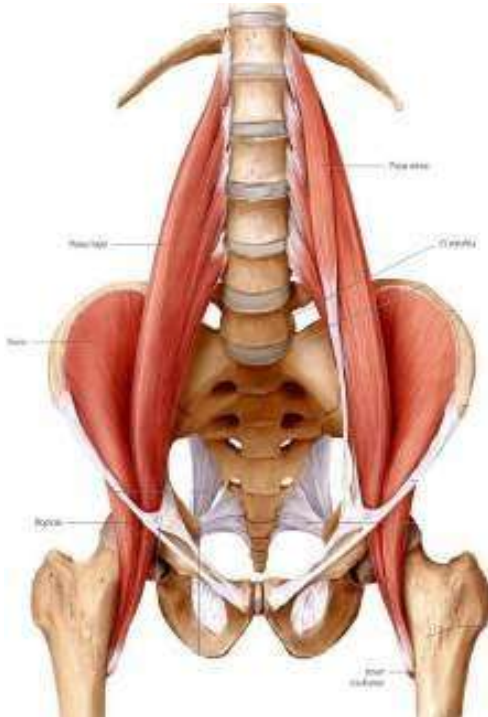

ILIACUS

O.:-

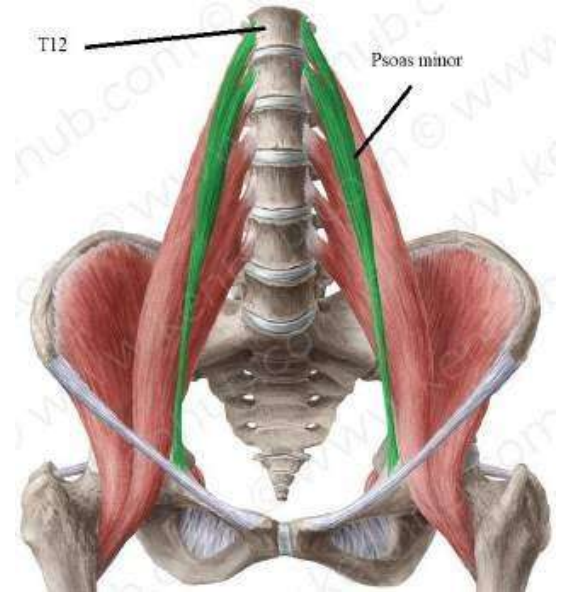


PSOAS MAJOR



PSOAS MINOR (may be absent)

0.:-

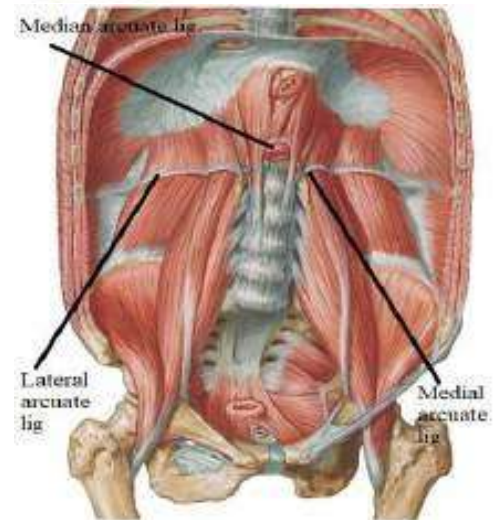
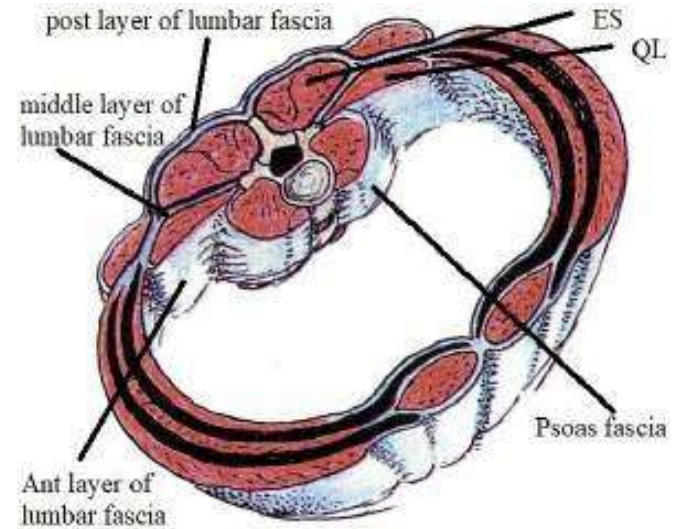


fascia of post. abd. wall

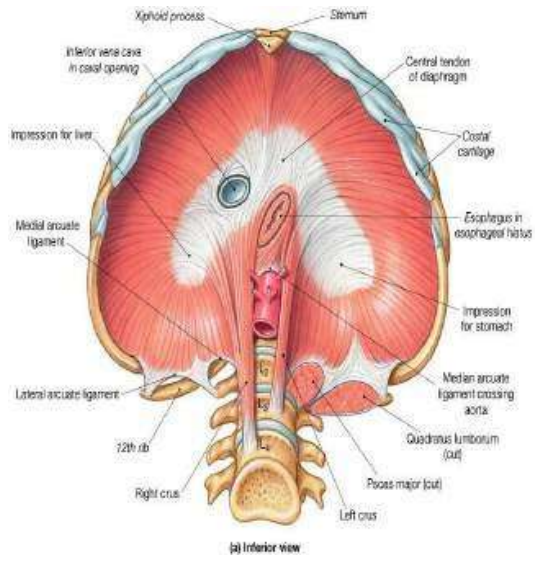
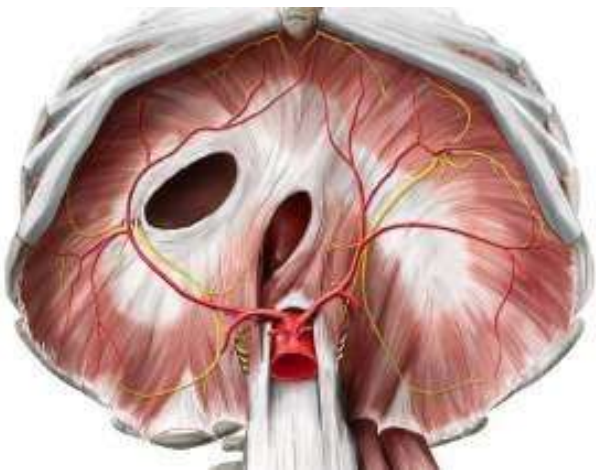
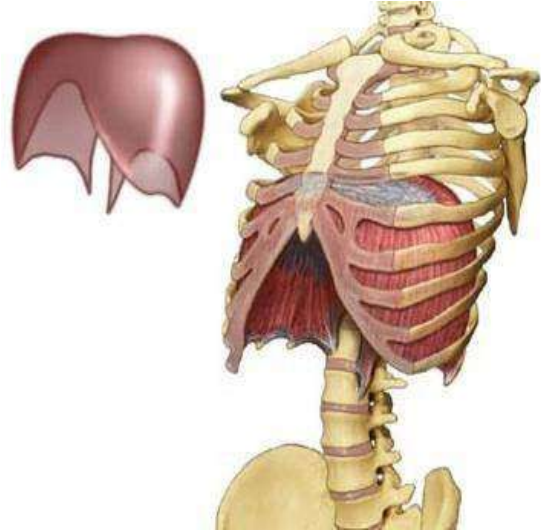
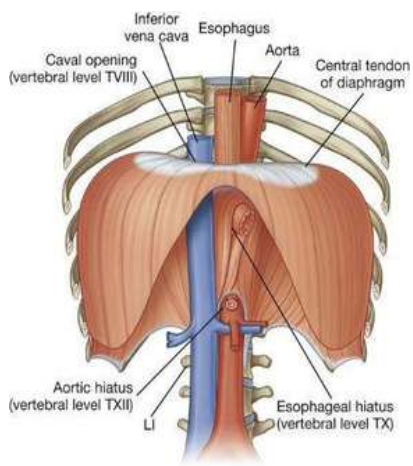
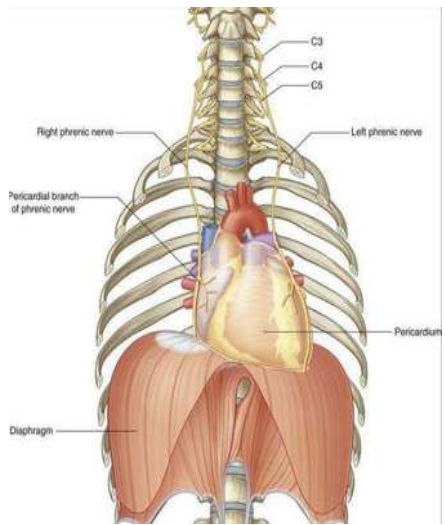
1-iliac fascia:

2-psoas fascia:

3-lumbar (thoracolumbar) fascia:-



diaphragm



(a) Inferior view