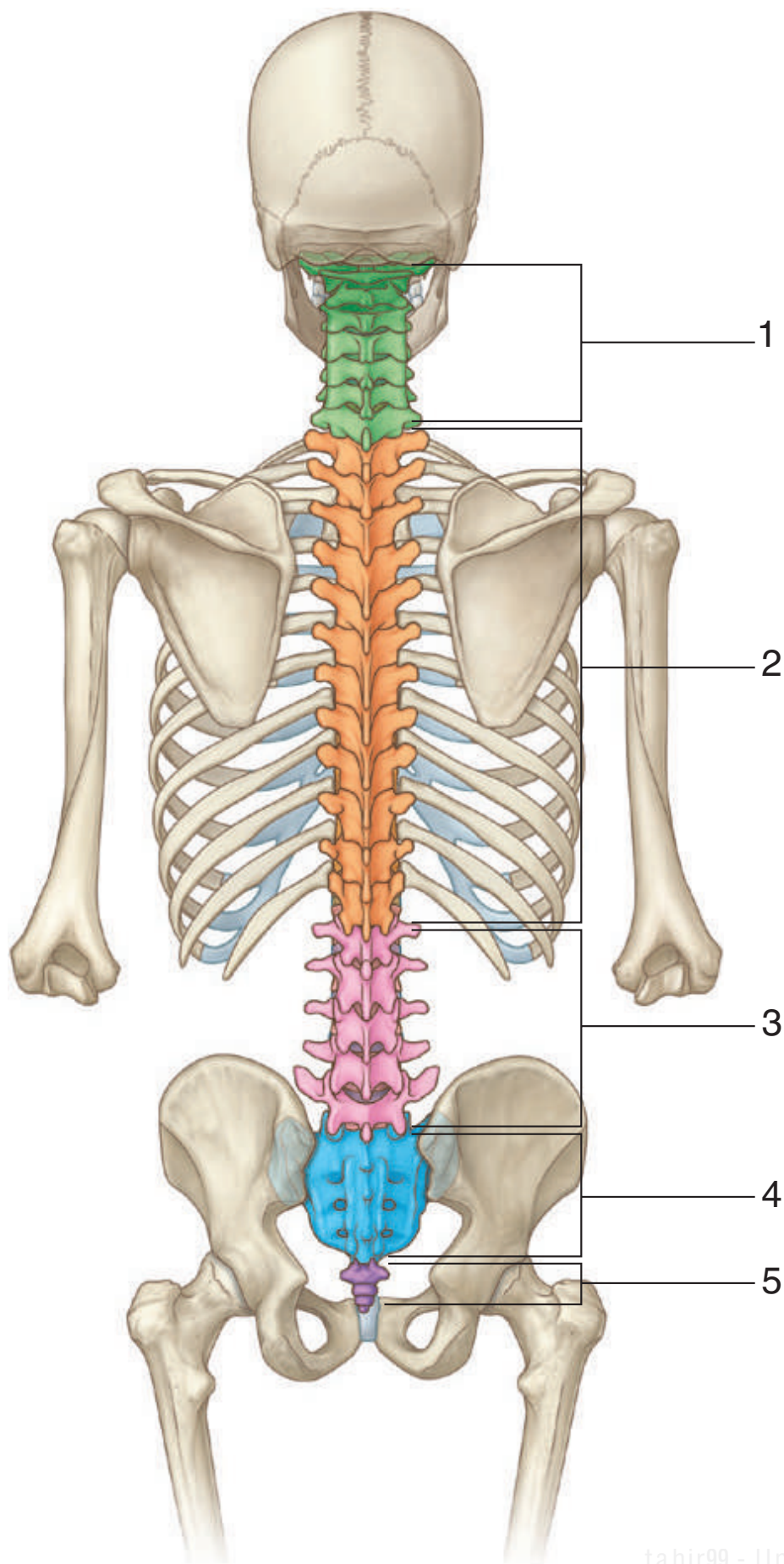




SKELETAL FRAMEWORK: VERTEBRAL COLUMN

*Identify the indicated vertebral regions.
How many vertebrae are in each region?*



SKELETAL FRAMEWORK: VERTEBRAL COLUMN



1. Cervical (7 vertebrae; C1-CVII)
2. Thoracic (12 vertebrae; T1-TXII)
3. Lumbar (5 vertebrae; L1-LV)
4. Sacral (5 fused vertebrae I-V; sacrum)
5. Coccygeal (3 or 4 coccygeal vertebrae; coccyx)

IN THE CLINIC:

- **Vertebral fractures can result in damage to the spinal cord or to spinal nerves.**

Figure from Gray's Anatomy for Students, 3rd edition, p. 56.

SKELETAL FRAMEWORK: TYPICAL VERTEBRA



1. Vertebral body
2. Vertebral foramen
3. Transverse process
4. Spinous process
5. Lamina
6. Pedicle
7. Superior articular process
8. Inferior articular process
9. Inferior vertebral notch
10. Superior vertebral notch

IN THE CLINIC:

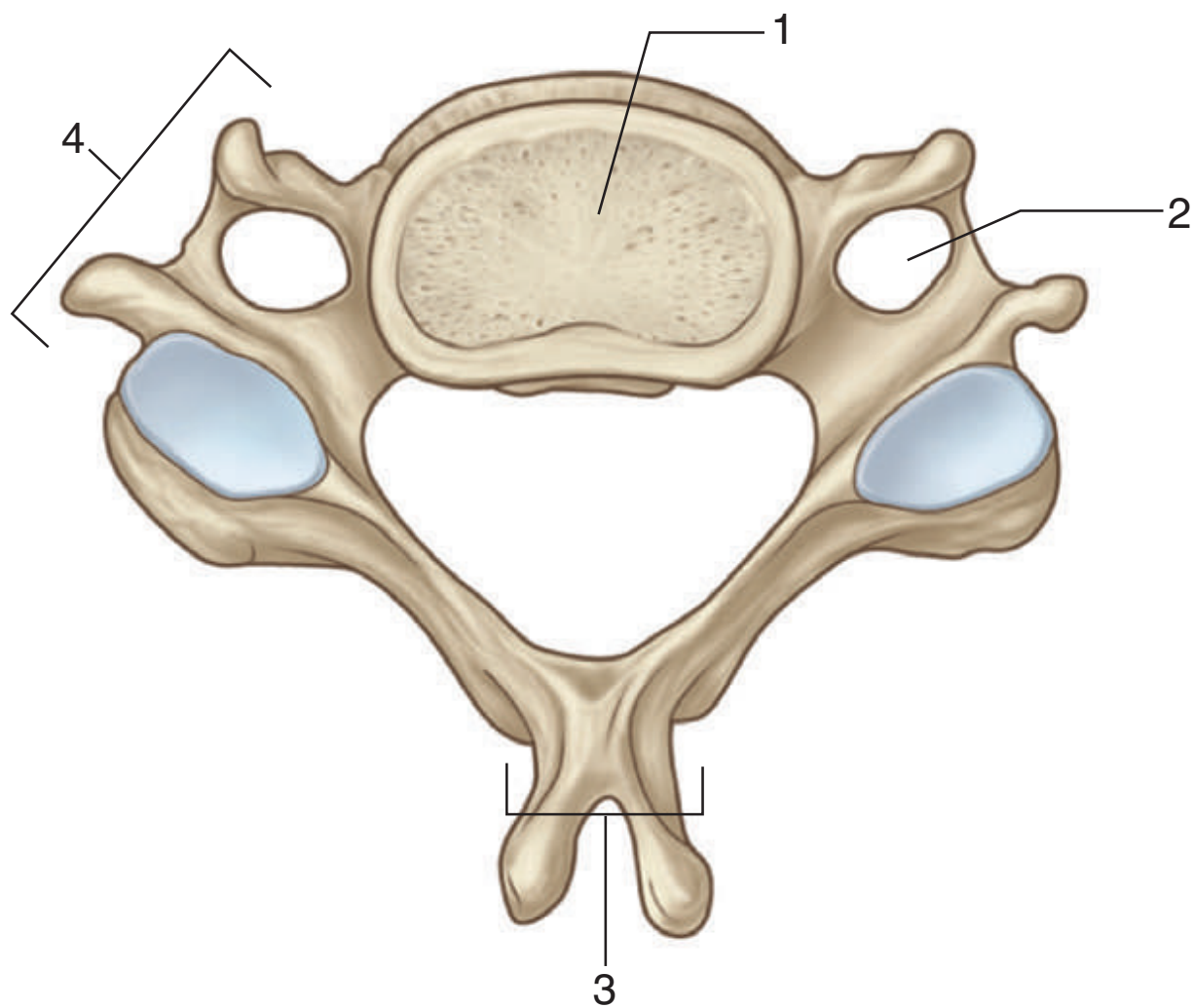
- **During surgery, a laminectomy (removal of the laminae) is used to access the vertebral canal.**

Figure from Gray's Anatomy for Students, 3rd edition, p. 57.

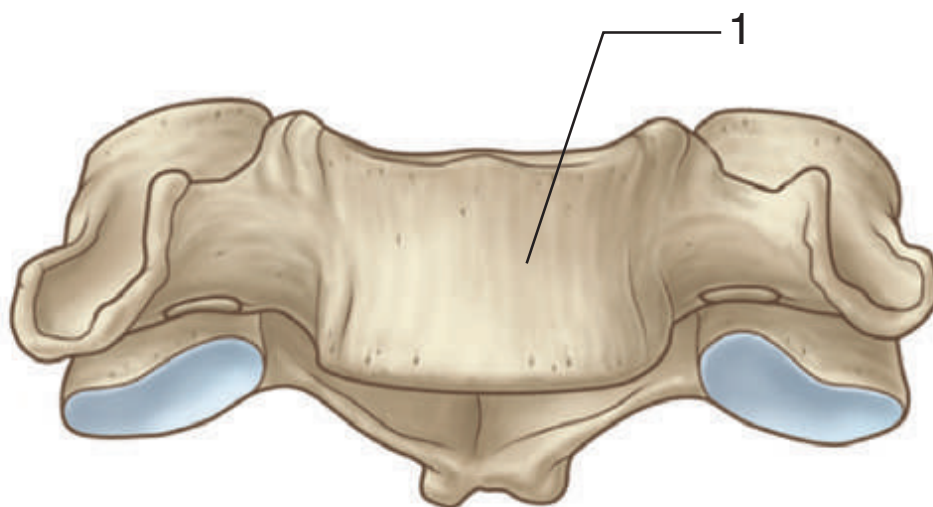


SKELETAL FRAMEWORK: VERTEBRA 1

From which region of the vertebral column is this vertebra? Identify the indicated structures.



Superior view



Anterior view

SKELETAL FRAMEWORK: VERTEBRA 1



This vertebra is from the cervical region.

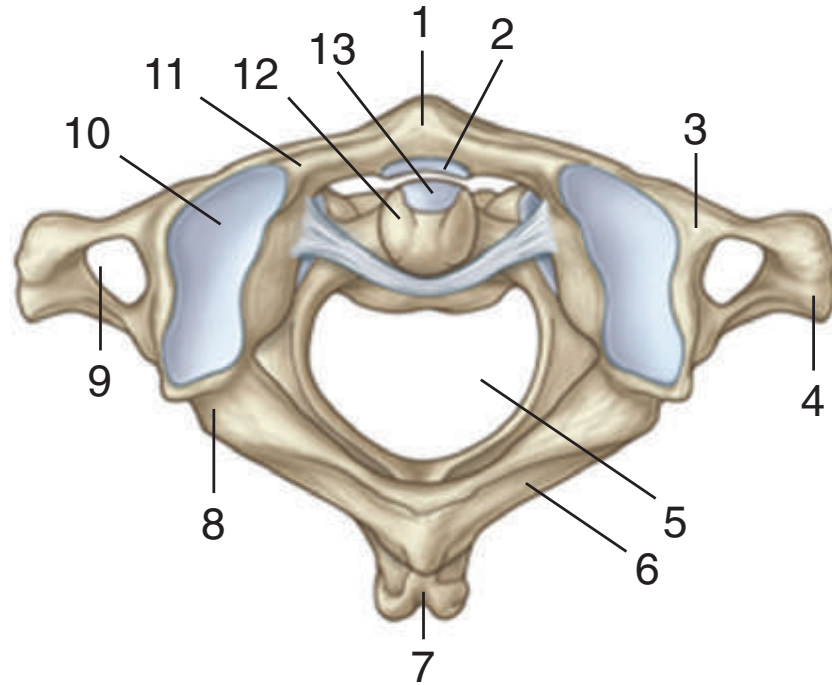
1. Vertebral body
2. Foramen transversarium
3. Spinous process
4. Transverse process

IN THE CLINIC:

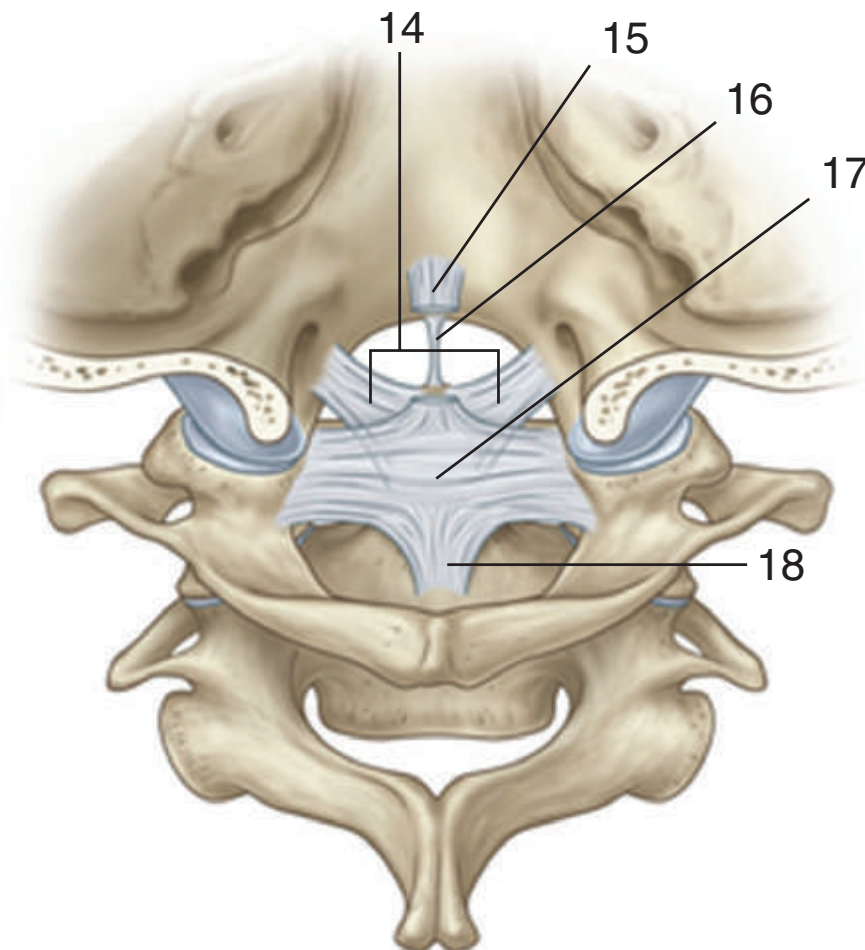
- **The vertebral artery and associated veins pass through the foramen transversarium and can be damaged in this location.**

Figure from Gray's Anatomy for Students, 3rd edition, p. 69.

Identify these two vertebrae. Identify the indicated structures.



A Superior view



B Posterior view

SKELETAL FRAMEWORK: ATLAS, AXIS, AND LIGAMENTS



A. Atlas and Axis (superior view)

1. Anterior tubercle
2. Articular facet for dens
3. Lateral mass
4. Transverse process
5. Vertebral foramen
6. Posterior arch
7. Posterior tubercle
8. Groove for vertebral artery
9. Foramen transversarium
10. Superior articular facet
11. Anterior arch
12. Dens
13. Anterior articular facet

B. Ligaments (posterior view)

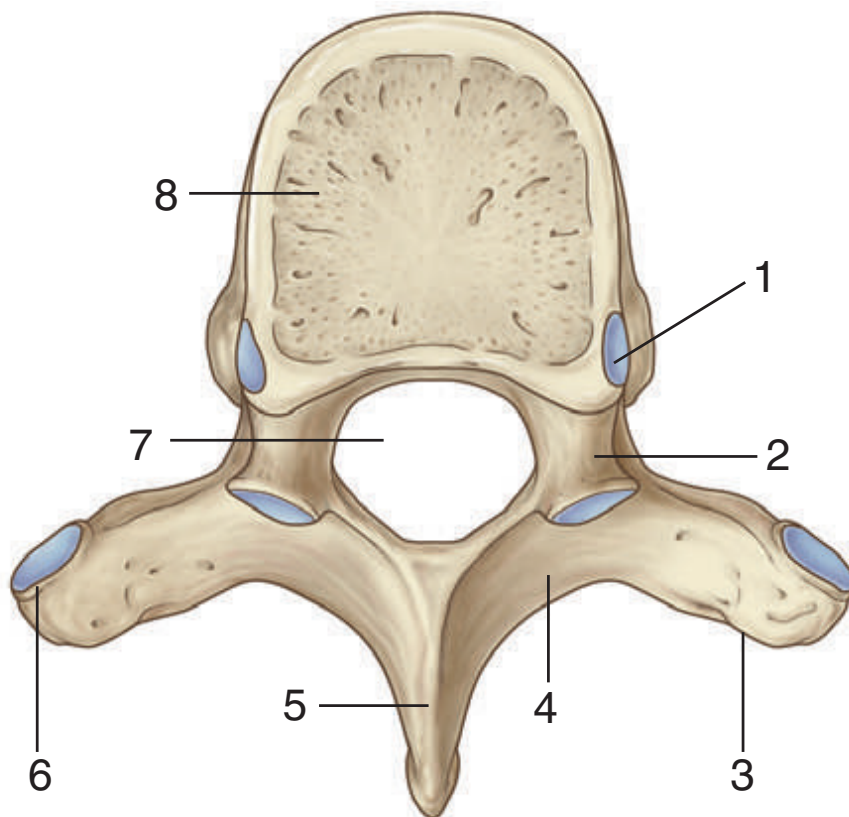
14. Alar ligaments
15. Superior longitudinal band of cruciform ligament
16. Apical ligament of dens
17. Transverse ligament of atlas
18. Inferior longitudinal band of cruciform ligament

Figure from Gray's Atlas of Anatomy, 2nd edition, p. 537.

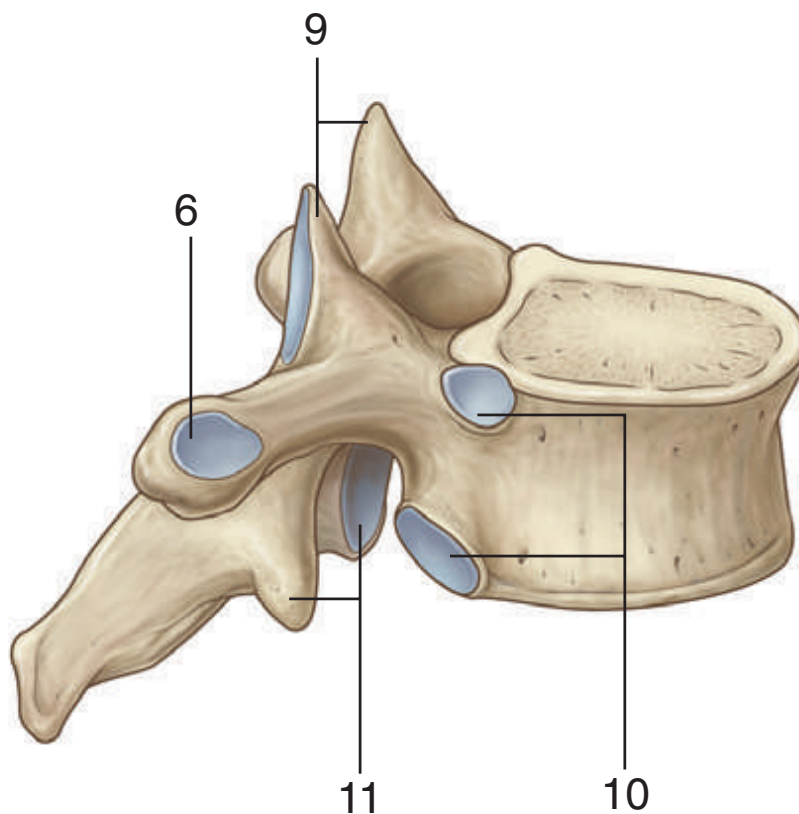


SKELETAL FRAMEWORK: VERTEBRA 2

From which region of the vertebral column is this vertebra? Identify the indicated structures.



Superior view



Lateral view

SKELETAL FRAMEWORK: VERTEBRA 2



This vertebra is from the thoracic region.

1. Superior demifacet for articulation with head of rib above
2. Pedicle
3. Transverse process
4. Lamina
5. Spinous process
6. Facet for articulation with tubercle of rib
7. Vertebral foramen
8. Vertebral body
9. Superior articular processes
10. Demifacets for articulation with head of ribs
11. Inferior articular processes

IN THE CLINIC:

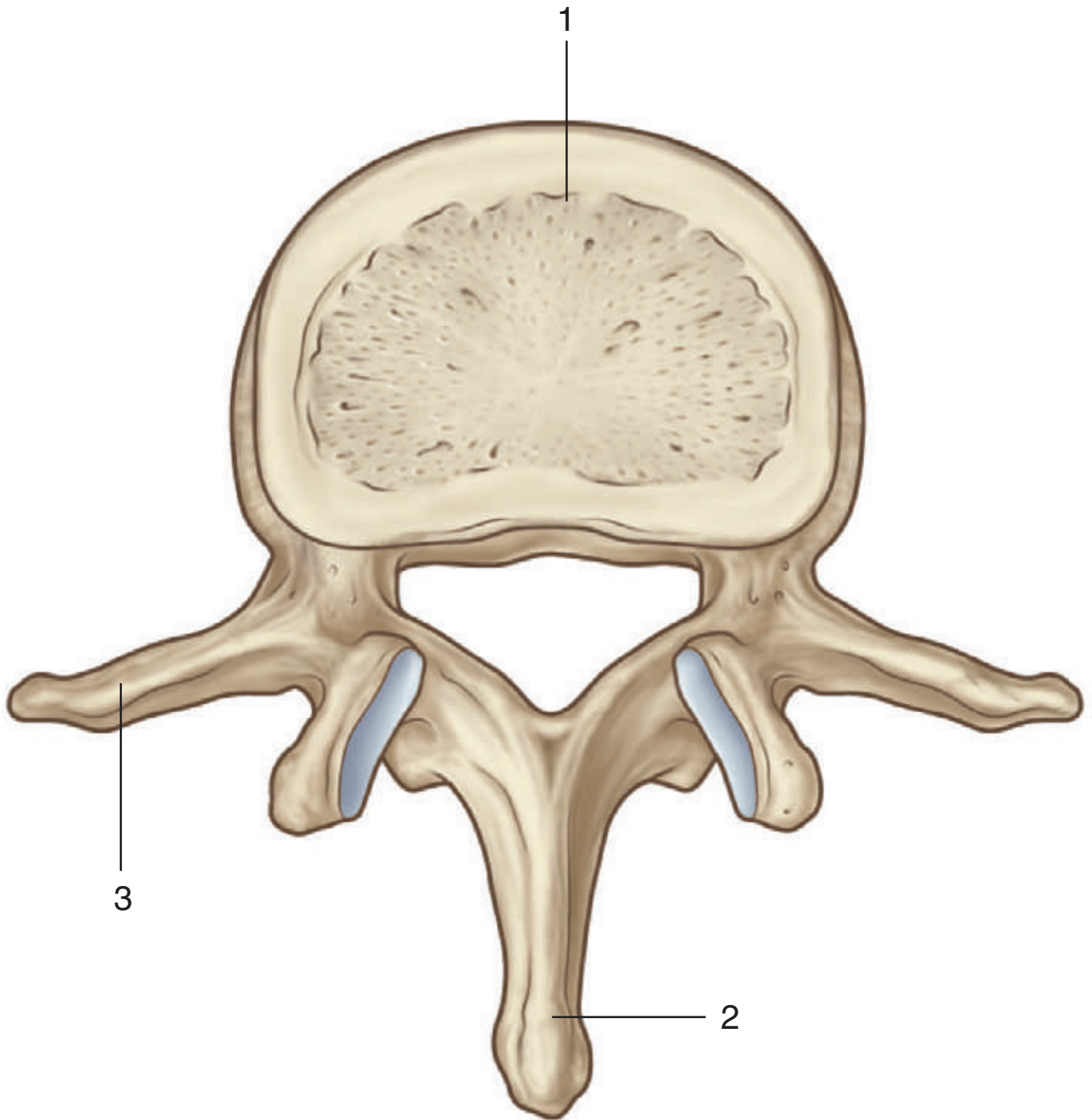
- **Osteoporosis can result in collapse of the vertebral body.**

Figure from Gray's Anatomy for Students, 3rd edition, p. 143.



SKELETAL FRAMEWORK: VERTEBRA 3

From which region of the vertebral column is this vertebra? Identify the indicated structures.



Superior view

SKELETAL FRAMEWORK: VERTEBRA 3

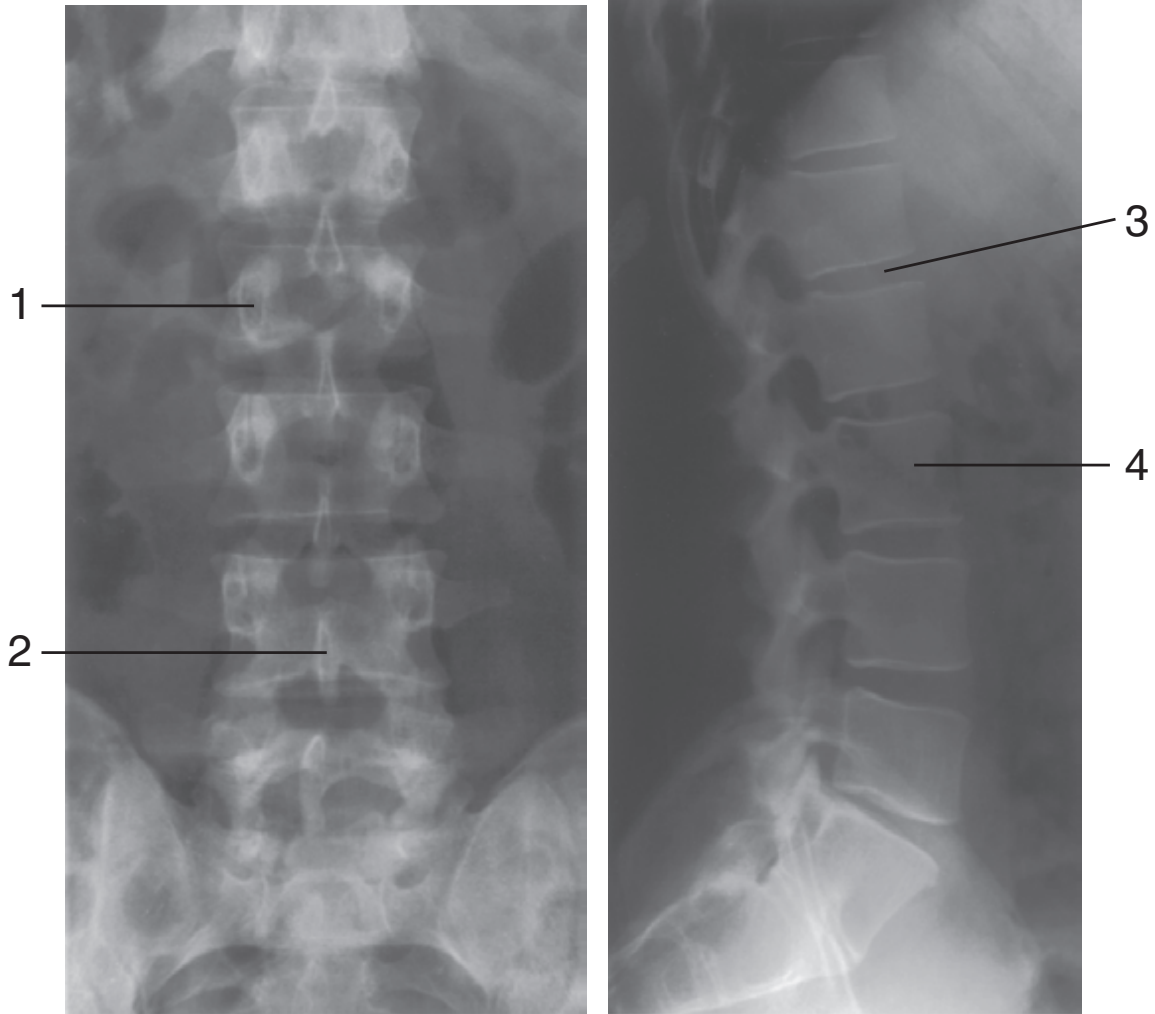


This vertebra is from the lumbar region.

1. Vertebral body
2. Spinous process
3. Transverse process

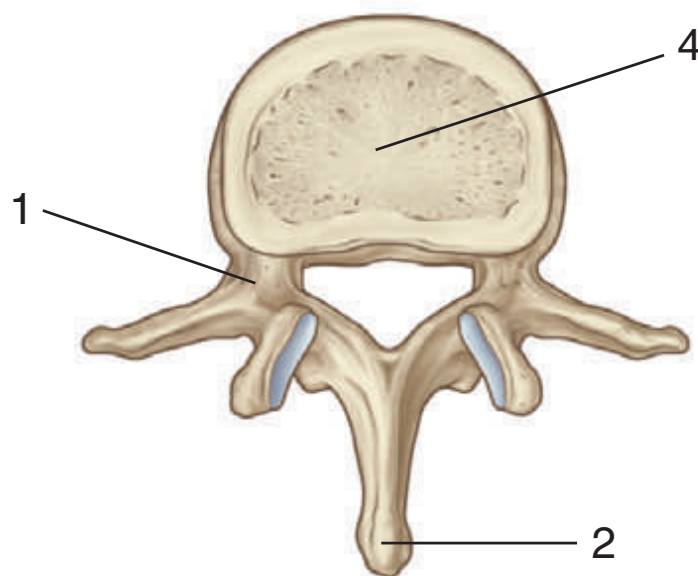
Figure from Gray's Anatomy for Students, 3rd edition, p. 70.

Which region of the vertebral column is imaged in these radiographs? Identify the indicated structures.



Anterior-posterior view

Lateral view



Superior view

SKELETAL FRAMEWORK: VERTEBRA RADIOGRAPH III



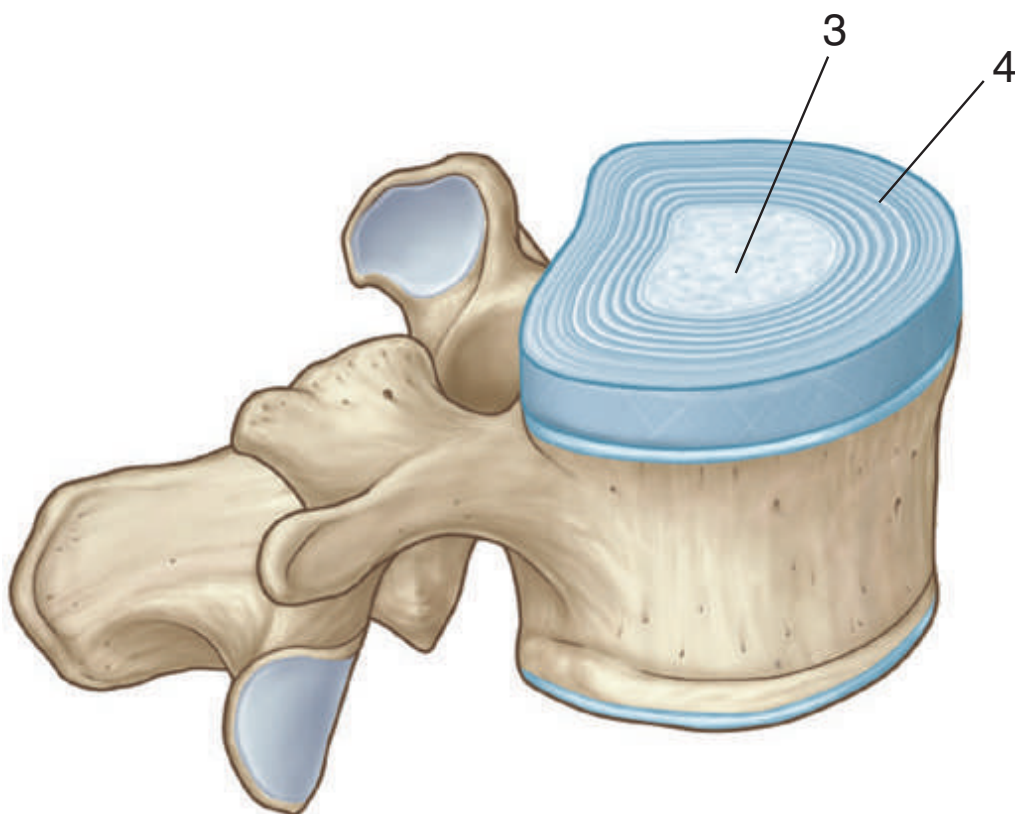
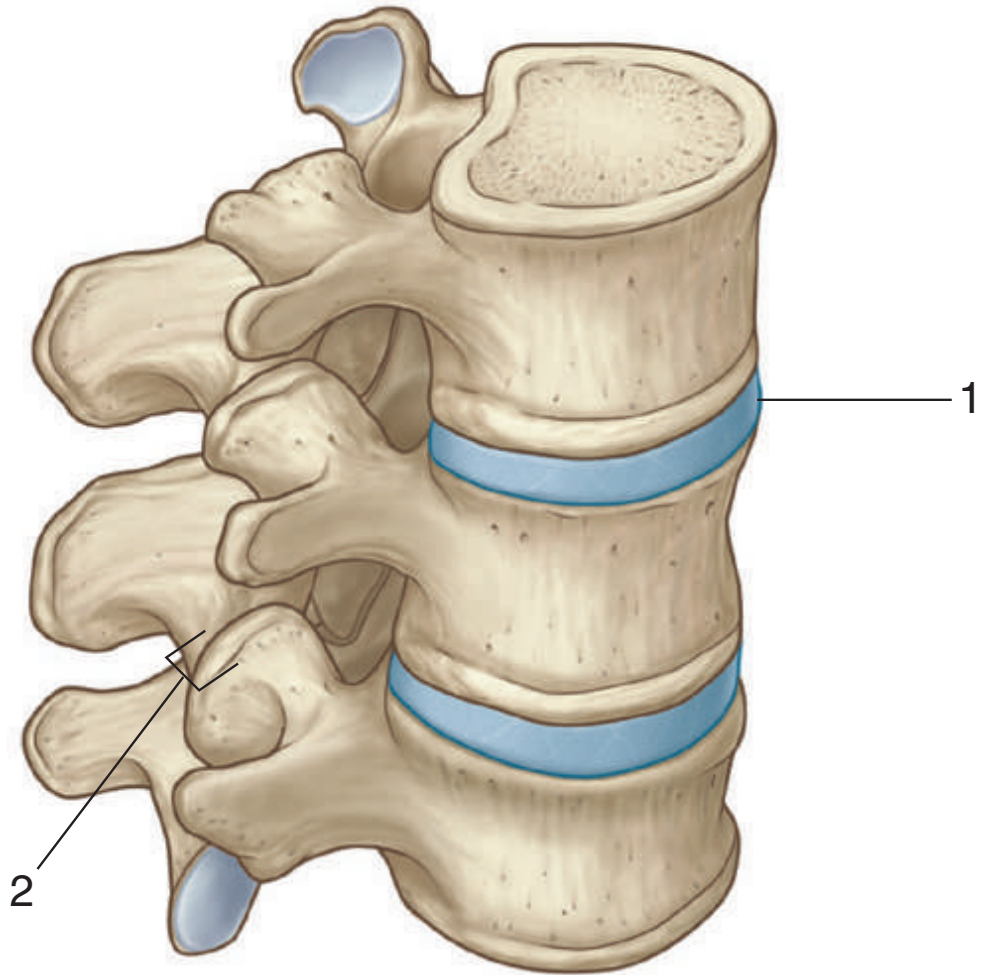
These radiographs show the lumbar region.

1. Pedicle
2. Spinous process
3. Intervertebral disc
4. Vertebral body

Figure from Gray's Anatomy for Students, 3rd edition, pp. 67-68.



Identify the indicated structures.



SKELETAL FRAMEWORK: INTERVERTEBRAL JOINTS

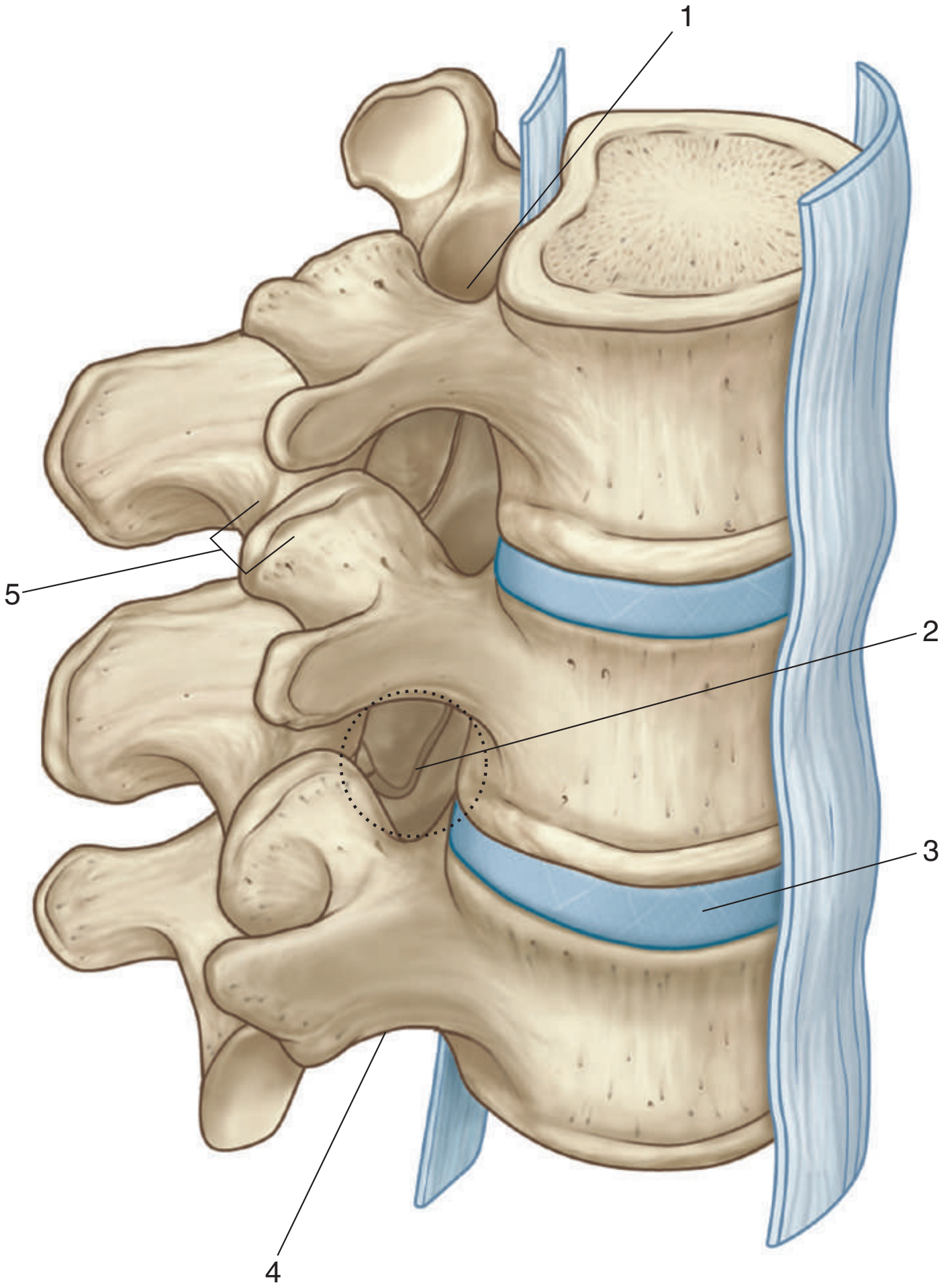


1. Intervertebral disc
2. Zygapophysial joint
3. Nucleus pulposus
4. Anulus fibrosus

Figure from Gray's Anatomy for Students, 3rd edition, p. 77 and 79.

**SKELETAL FRAMEWORK:
INTERVERTEBRAL FORAMEN**

Identify the indicated structures.



SKELETAL FRAMEWORK: INTERVERTEBRAL FORAMEN



1. Superior vertebral notch
2. Intervertebral foramen
3. Intervertebral disc
4. Inferior vertebral notch
5. Zygapophysial joint

IN THE CLINIC:

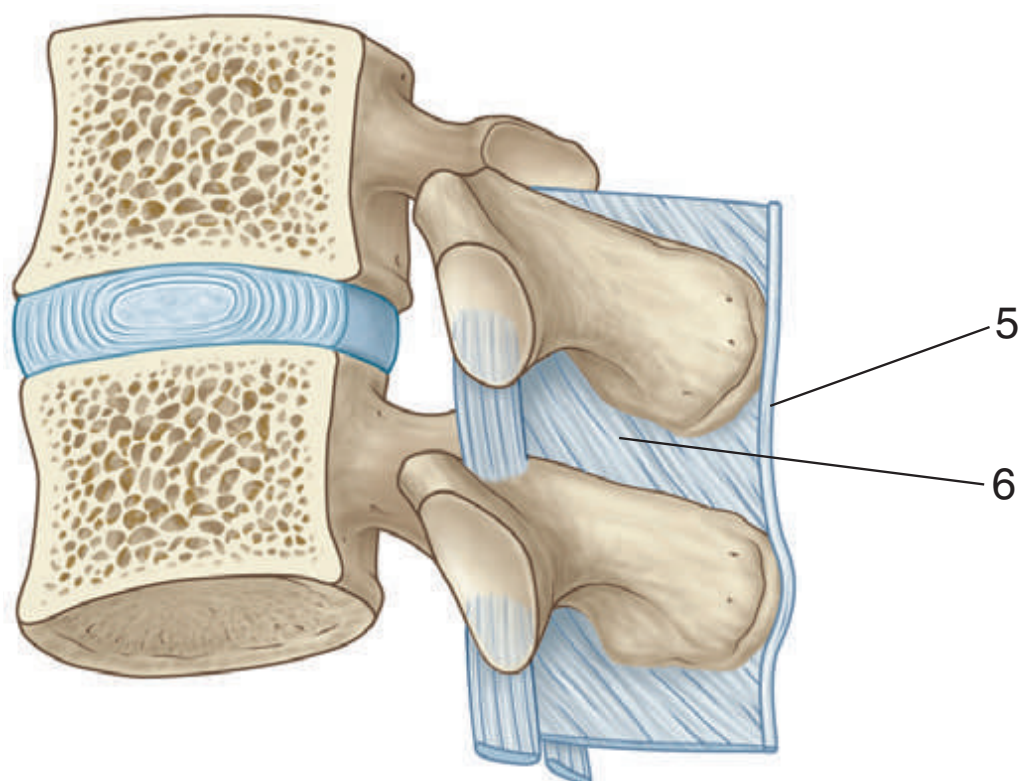
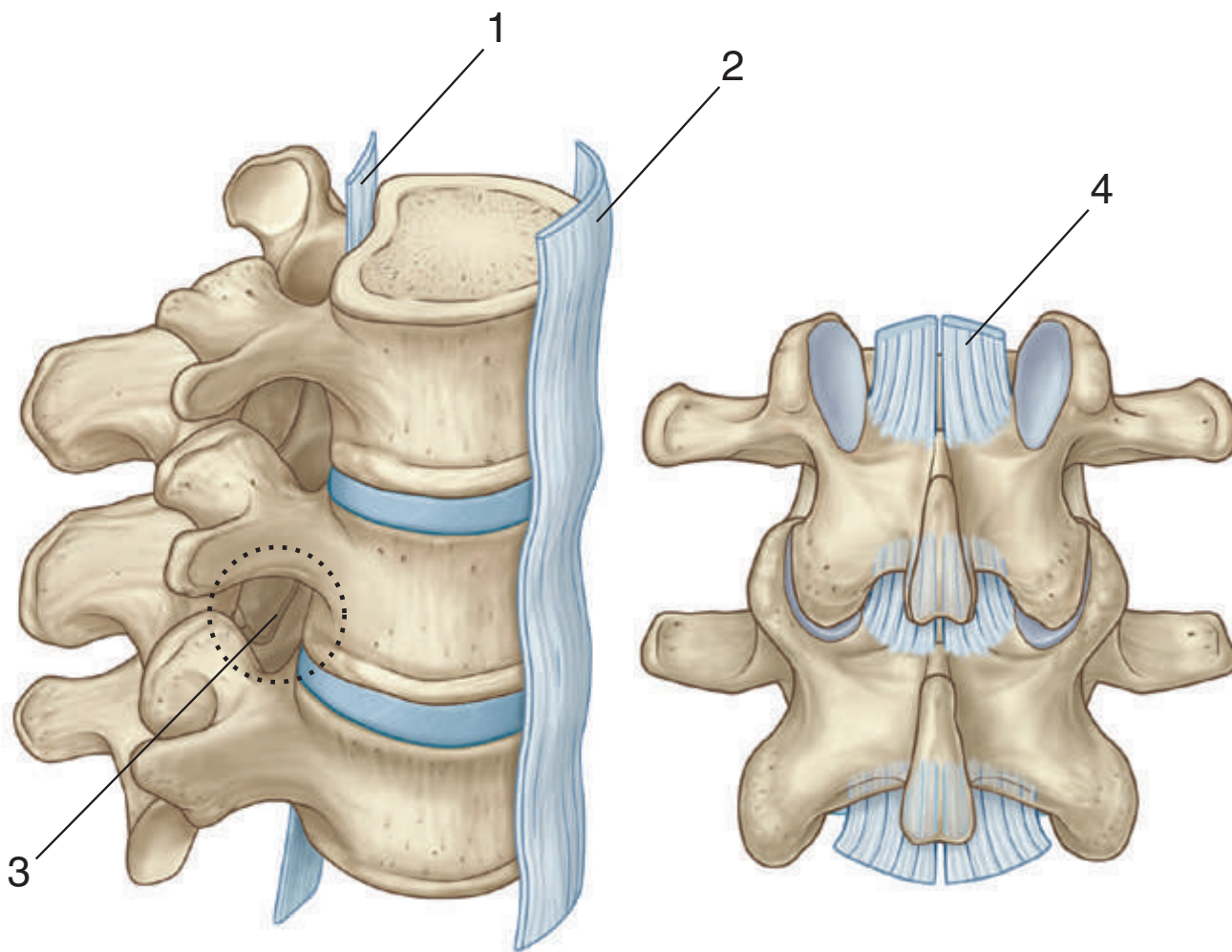
- **The intervertebral foramen is surrounded by bone and joints. Passing through the foramen is a spinal nerve and vessels. Any pathology in structures forming the boundaries of the foramen can affect the spinal nerve.**

Figure from Gray's Anatomy for Students, 3rd edition, p. 80.



SKELETAL FRAMEWORK: VERTEBRAL LIGAMENTS

Identify the indicated structures.



SKELETAL FRAMEWORK: VERTEBRAL LIGAMENTS



1. Posterior longitudinal ligament
2. Anterior longitudinal ligament
3. Intervertebral foramen
4. Ligamentum flavum
5. Supraspinous ligament
6. Interspinous ligament

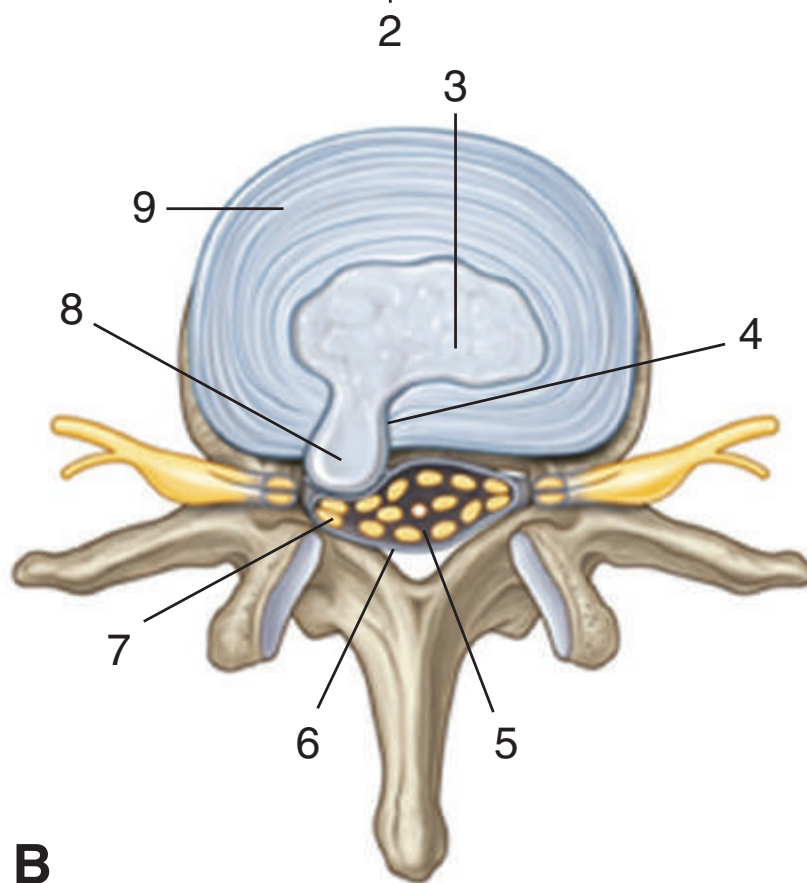
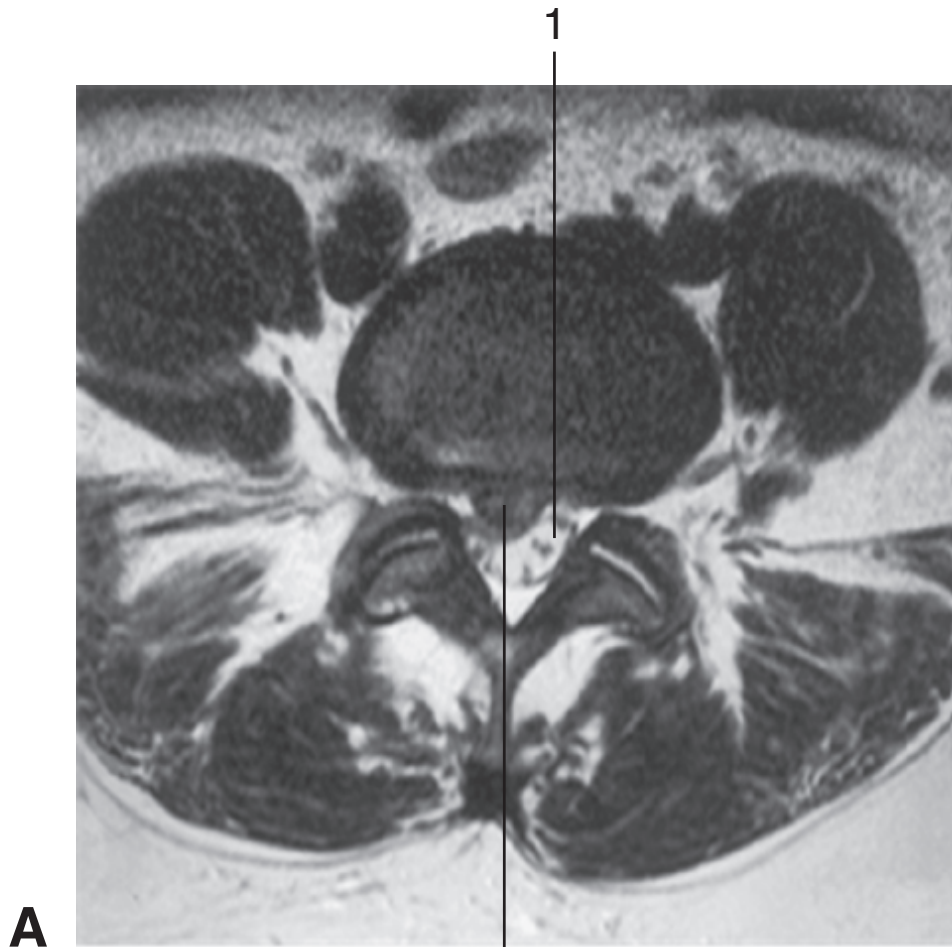
IN THE CLINIC:

- **When doing a lumbar puncture in the midline, a needle passes through the supraspinous and interspinous ligaments into the vertebral canal.**
- **Spinal nerves pass through the intervertebral foramen. Any pathology that reduces the dimensions of the foramen can compress the nerve, causing motor and sensory deficits and pain.**

Figure from Gray's Anatomy for Students, 3rd edition, pp. 80-82.

**SKELETAL FRAMEWORK:
INTERVERTEBRAL DISC PROTRUSION**

Identify A and B. Identify the indicated structures.



SKELETAL FRAMEWORK: INTERVERTEBRAL DISC PROTRUSION



- A. Intervertebral disc protrusion in lower lumbar region of vertebral column
 - 1. Vertebral canal containing cerebrospinal fluid (CSF) and cauda equina
 - 2. Disc protrusion (herniated disc)
- B. Intervertebral disc protrusion (superior view)
 - 3. Nucleus pulposus
 - 4. Defect in anulus fibrosus
 - 5. Cauda equina
 - 6. Dura
 - 7. Compression of spinal nerve roots
 - 8. Herniation of nucleus pulposus
 - 9. Anulus fibrosus

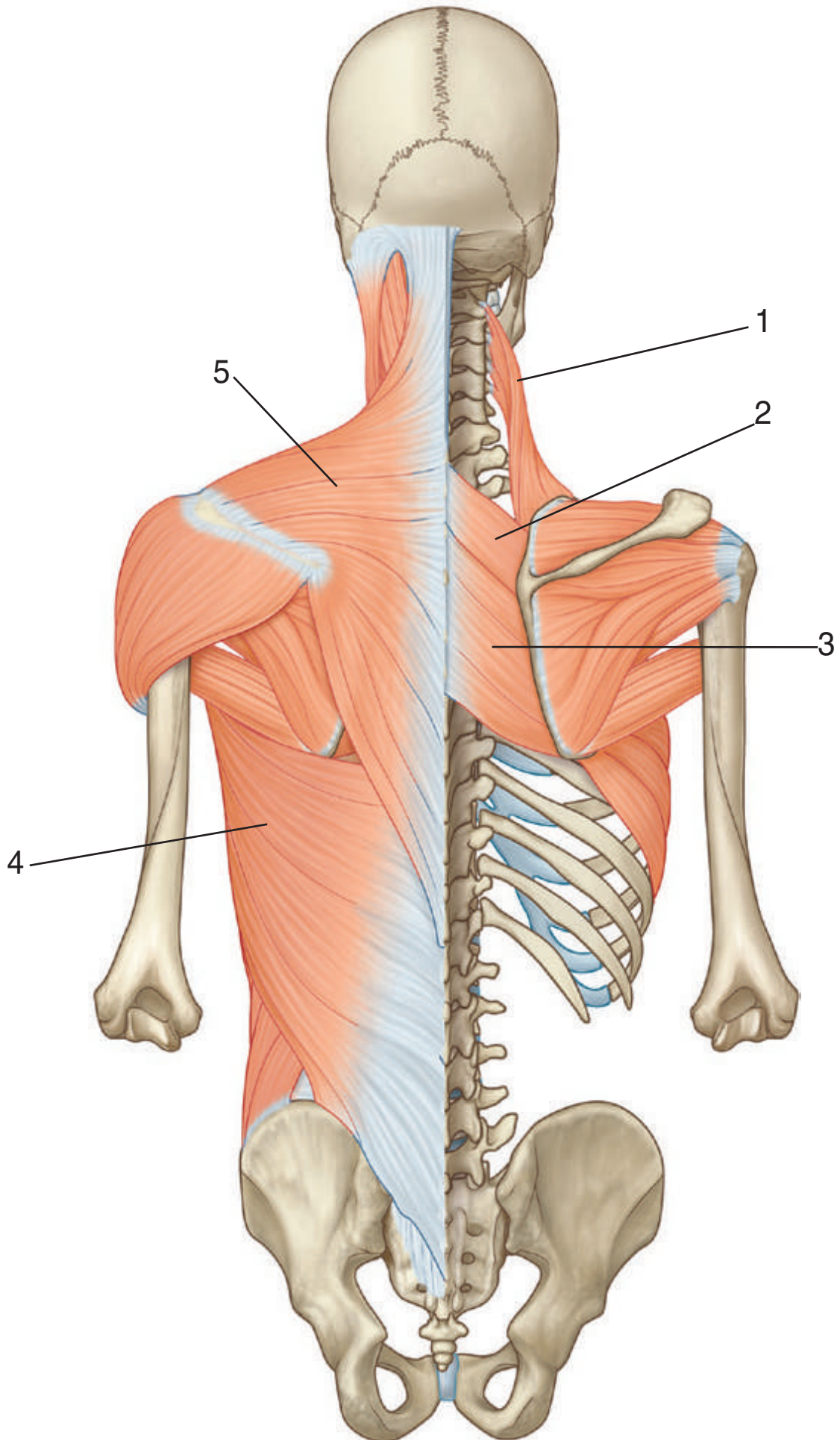
IN THE CLINIC:

- **Herniation of the nucleus pulposus through a weakened anulus fibrosus can impinge on the spinal cord or spinal nerve.**

Figure from Gray's Atlas of Anatomy, 2nd edition, p. 33.



Identify the indicated muscles.



MUSCLES: SUPERFICIAL GROUP



1. Levator scapulae
2. Rhomboid minor
3. Rhomboid major
4. Latissimus dorsi
5. Trapezius

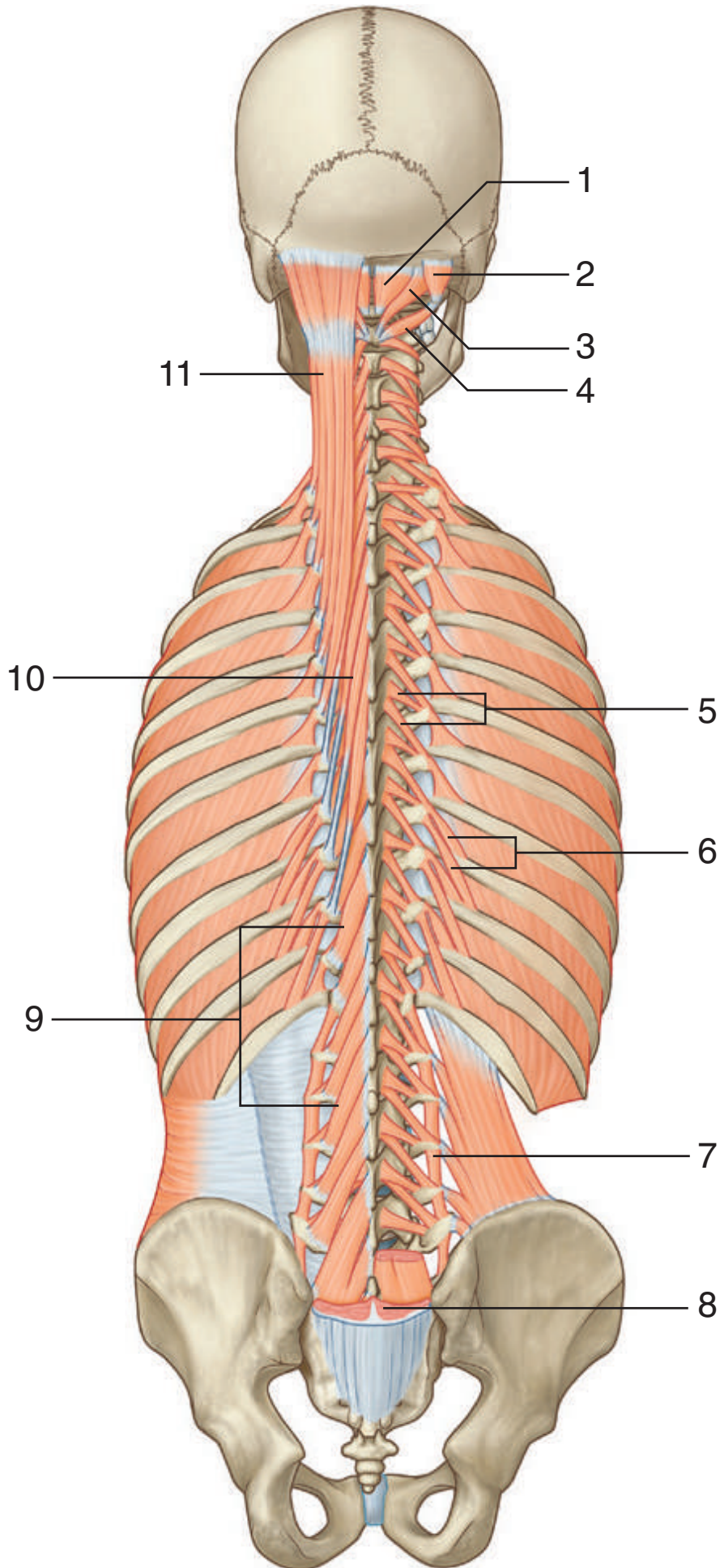
IN THE CLINIC:

- **The function of the trapezius muscle can be used to test cranial nerve XI (accessory nerve).**
- **The function of the levator scapulae, rhomboid major, and rhomboid minor muscles can be used to assess the status of the anterior rami of spinal nerves C3-C5 (levator scapulae, C3-C5; rhomboids, C4-C5).**

Figure from Gray's Anatomy for Students, 3rd edition, p. 86.

MUSCLES: TRANSVERSOSPINALIS AND SEGMENTALS

Identify the indicated muscles.



MUSCLES: TRANSVERSOSPINALIS AND SEGMENTALS

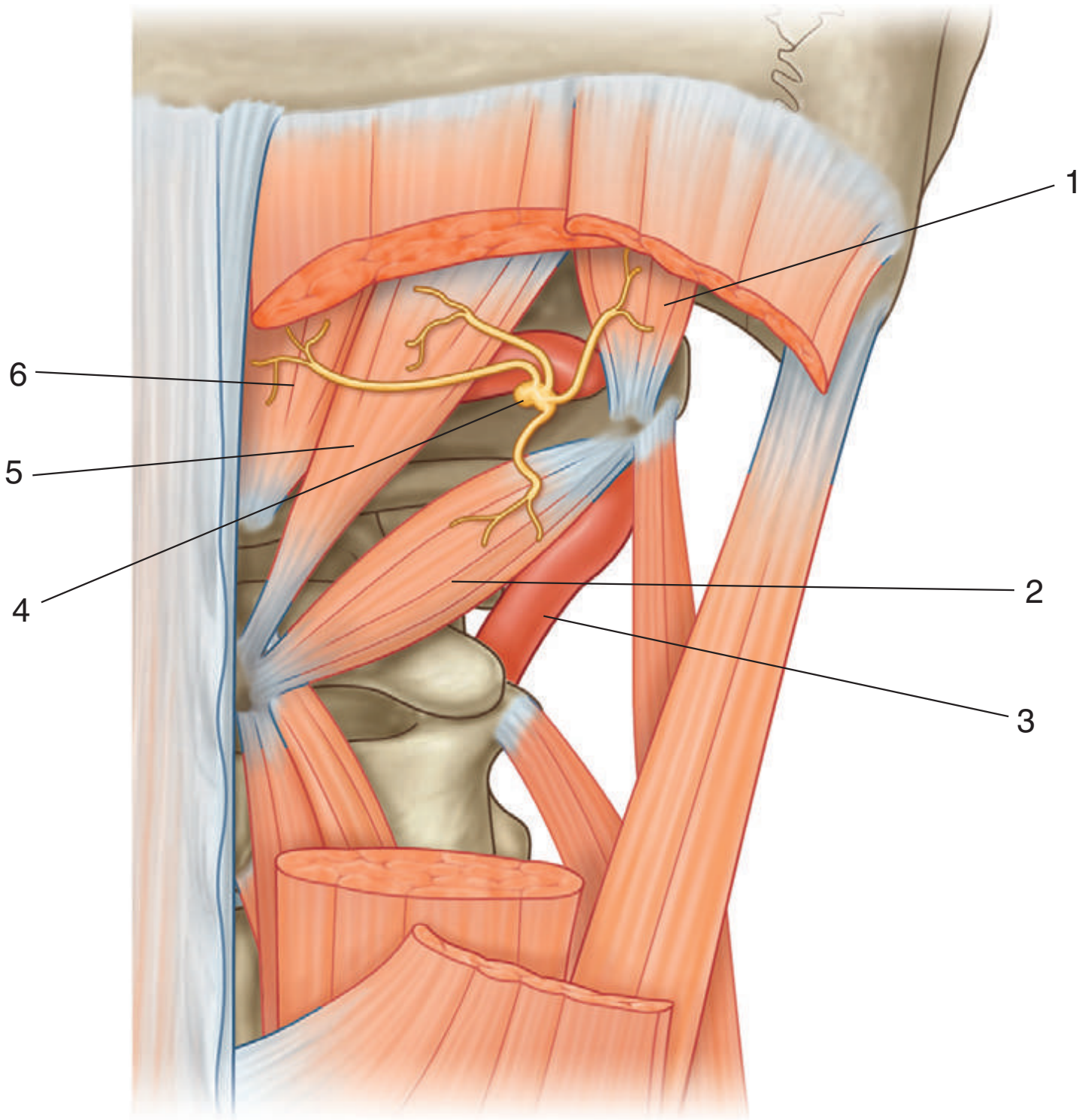


1. Rectus capitis posterior minor
2. Obliquus capitis superior
3. Rectus capitis posterior major
4. Obliquus capitis inferior
5. Rotatores thoracis (short, long)
6. Levatores costarum (short, long)
7. Intertransversarius
8. Erector spinae (cut)
9. Multifidus
10. Semispinalis thoracis
11. Semispinalis capitis

Figure from Gray's Anatomy for Students, 3rd edition, p. 96.



Identify the indicated structures.



MUSCLES: SUBOCCIPITAL REGION



1. Obliquus capitis superior muscle
2. Obliquus capitis inferior muscle
3. Vertebral artery
4. Posterior ramus of C1
5. Rectus capitis posterior major muscle
6. Rectus capitis posterior minor muscle

IN THE CLINIC:

- **The vertebral artery and the posterior ramus of C1 are located in the suboccipital triangle formed by the obliquus capitis superior muscle, rectus capitis posterior major muscle, and obliquus capitis inferior muscle. The suboccipital triangle can be used to access the vertebral artery.**

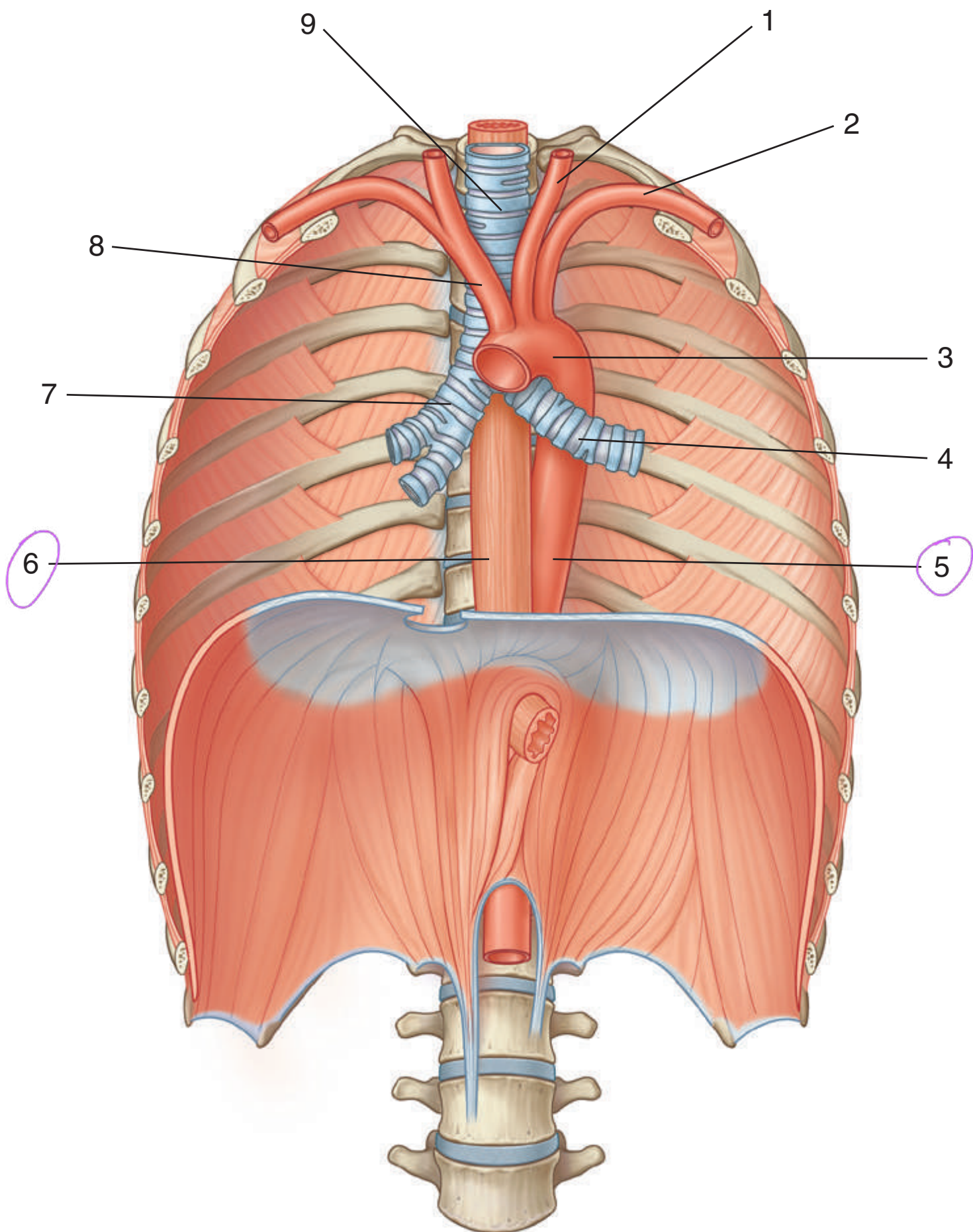
Figure from Gray's Anatomy for Students, 3rd edition, p. 98.



POSTERIOR MEDIASTINUM



Identify the indicated structures.



POSTERIOR MEDIASTINUM

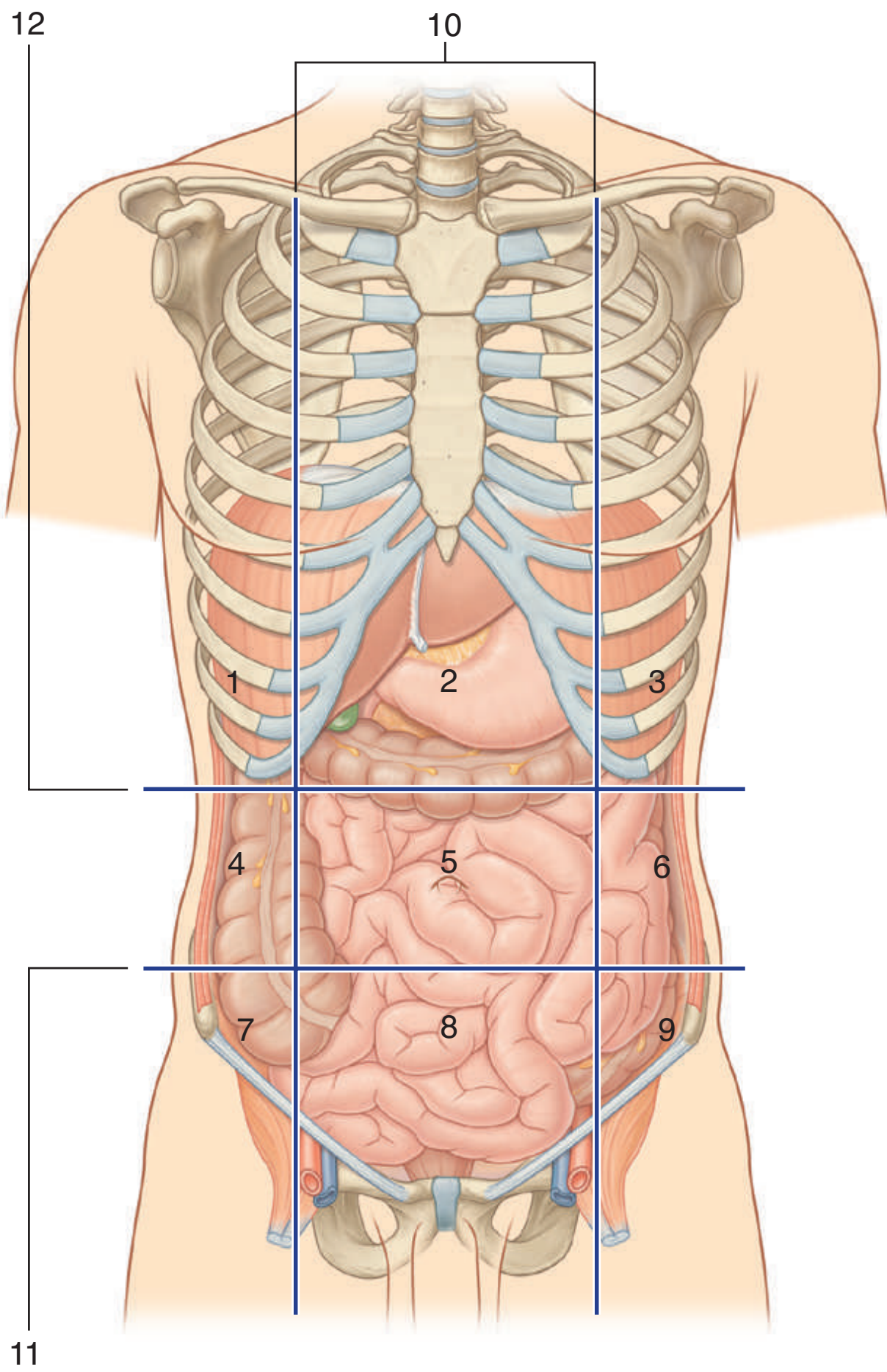
1. Left common carotid artery
2. Left subclavian artery
3. Arch of aorta
4. Left main bronchus
5. Thoracic aorta
6. Esophagus
7. Right main bronchus
8. Brachiocephalic trunk
9. Trachea

Figure from Gray's Anatomy for Students, 3rd edition, p. 223.



ABDOMINAL WALL: NINE-REGION PATTERN

Identify the indicated abdominal regions and the planes that separate them.



ABDOMINAL WALL: NINE-REGION PATTERN



1. Right hypochondrium
2. Epigastric
3. Left hypochondrium
4. Right flank
5. Umbilical region
6. Left flank
7. Right groin
8. Pubic region
9. Left groin
10. Midclavicular planes
11. Intertubercular plane
12. Subcostal plane

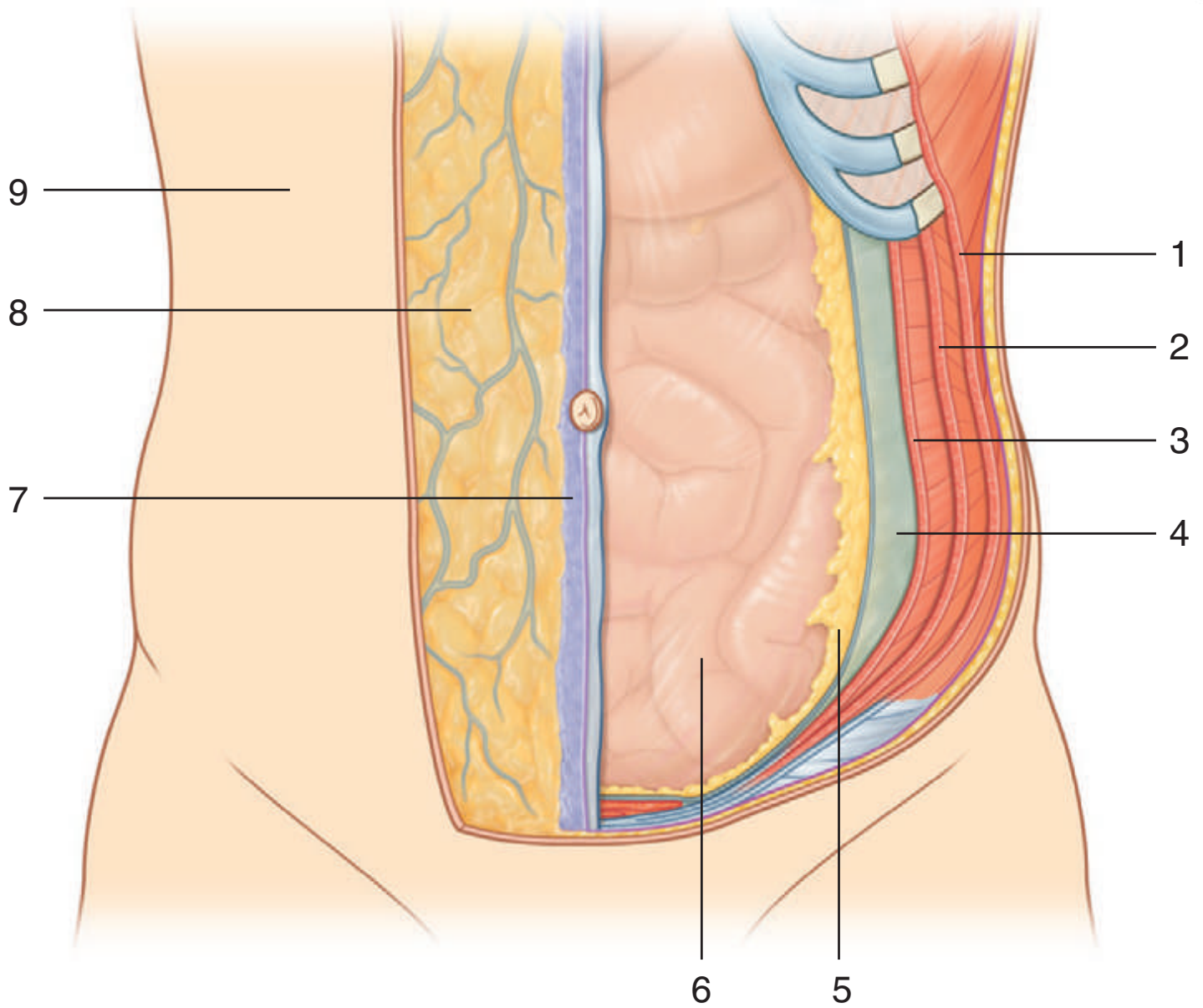
IN THE CLINIC:

- **Topographic divisions of the abdomen are used to describe the location of abdominal organs and the pain associated with abdominal problems. The two schemes most often used are a four-quadrant pattern (not illustrated on this card) and a nine-region organizational pattern.**

Figure from Gray's Anatomy for Students, 3rd edition, p. 278.



Identify the indicated layers of the abdominal wall.



ABDOMINAL WALL: LAYERS OVERVIEW



n

1. External oblique muscle
2. Internal oblique muscle
3. Transversus abdominis muscle
4. Transversalis fascia
5. Extraperitoneal fascia
6. Parietal peritoneum
7. Superficial fascia—membranous layer (Scarpa's fascia)
8. Superficial fascia—fatty layer (Camper's fascia)
9. Skin

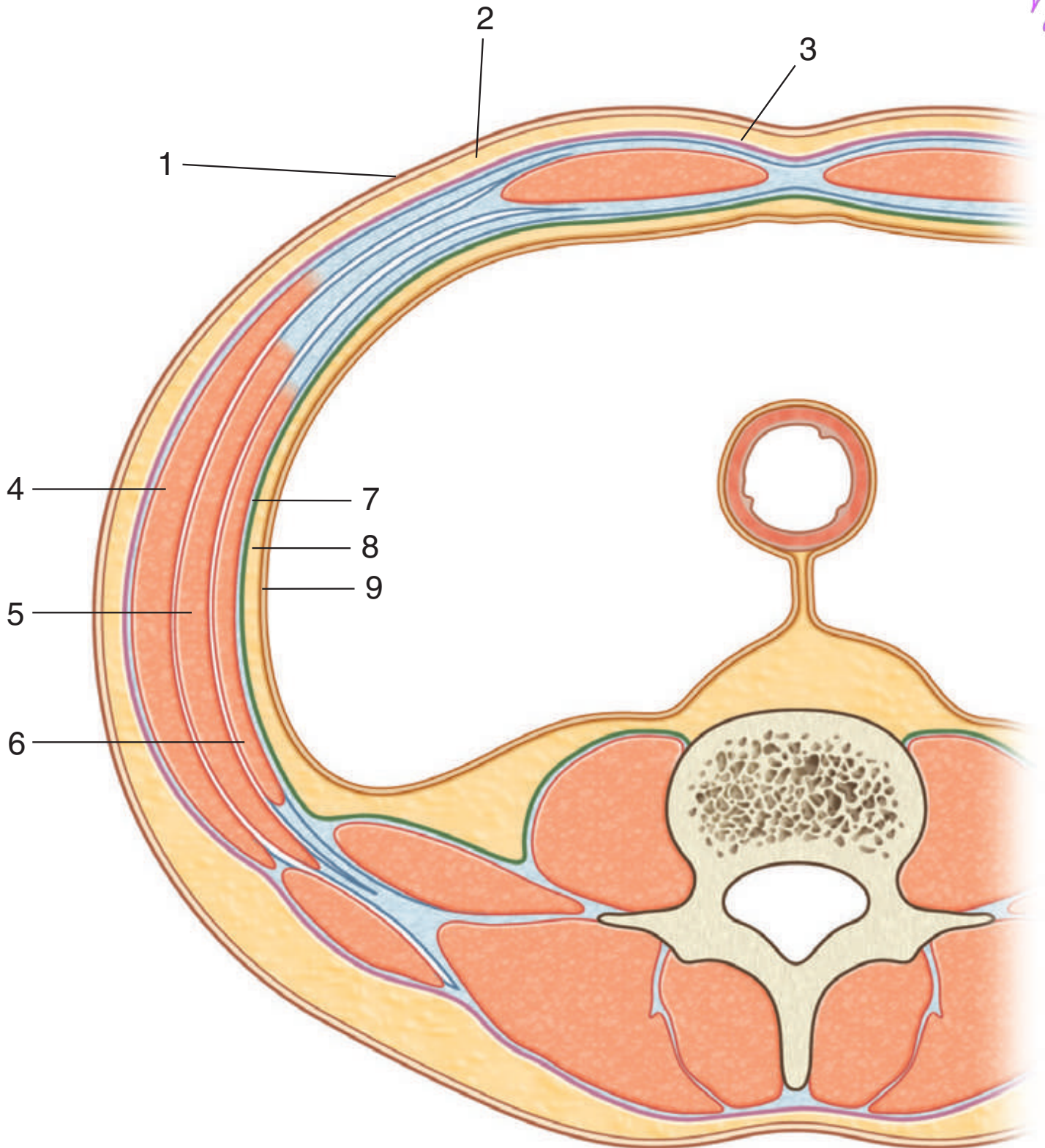
IN THE CLINIC:

- **The abdominal wall is bounded superiorly by the xiphoid process and costal margins, posteriorly by the vertebral column, and inferiorly by the upper parts of the pelvic bones. Its layers consist of skin, superficial fascia (subcutaneous tissue), muscles and their associated deep fascias, extraperitoneal fascia, and parietal peritoneum.**

Figure from Gray's Anatomy for Students, 3rd edition, p. 280.



Identify the indicated layers in this transverse section of the abdominal wall.



ABDOMINAL WALL: TRANSVERSE SECTION



1. Skin
2. Superficial fascia—fatty layer (Camper's fascia)
3. Superficial fascia—membranous layer (Scarpa's fascia)
4. External oblique muscle
5. Internal oblique muscle
6. Transversus abdominis muscle
7. Transversalis fascia
8. Extraperitoneal fascia
9. Parietal peritoneum



IN THE CLINIC:

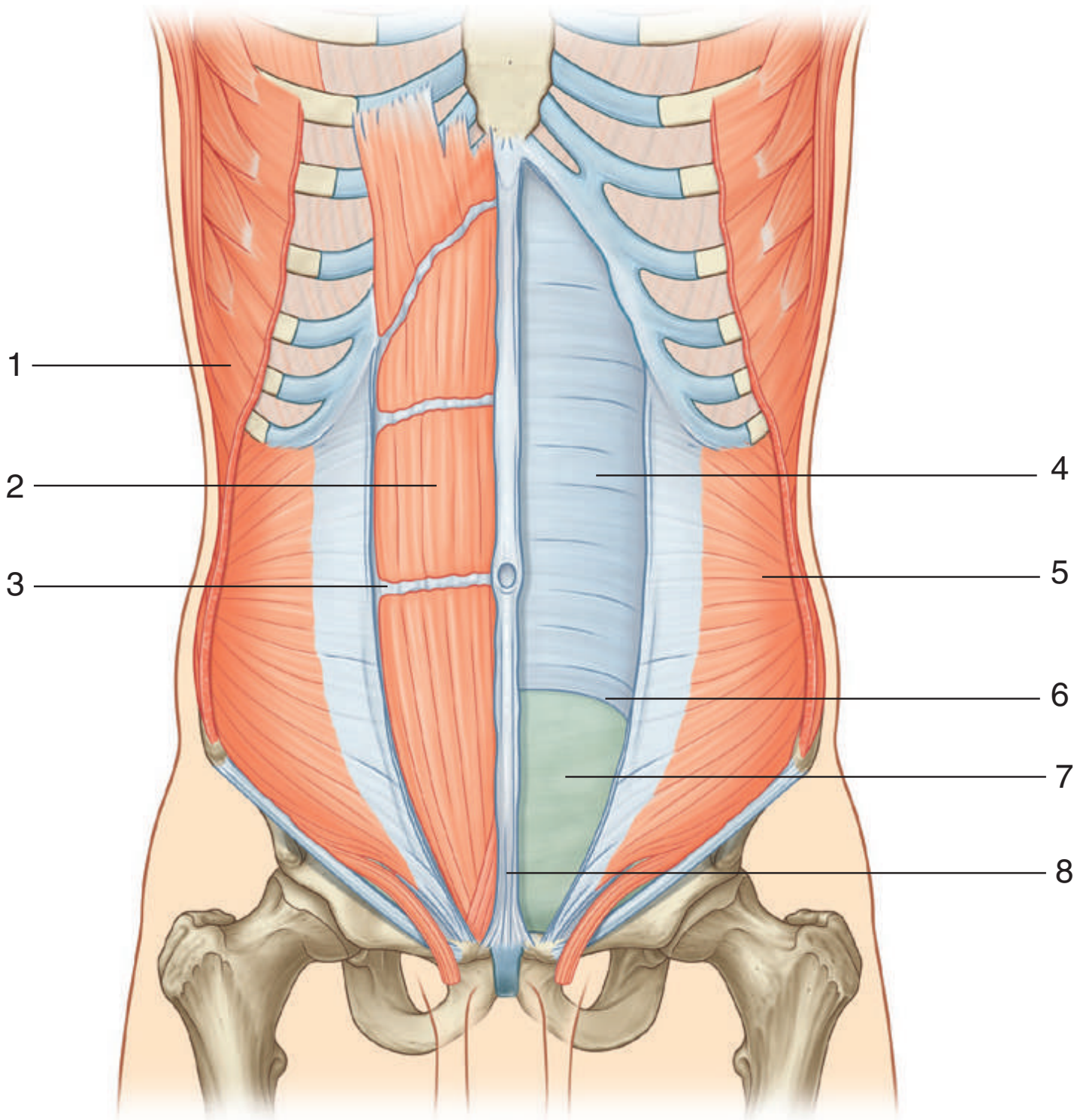
- **The continuous lining of the abdominal walls by the parietal peritoneum forms a sac. This sac is closed in men but has two openings in women, where the uterine tubes provide a passage to the outside. The closed sac in men and the semi-closed sac in women is called the peritoneal cavity.**

Figure from Gray's Anatomy for Students, 3rd edition, p. 288.



Identify the indicated structures related to the rectus abdominis muscle and its sheath.

21



RECTUS ABDOMINIS



1. External oblique muscle
2. Rectus abdominis muscle
3. Tendinous intersection
4. Posterior wall of rectus sheath
5. Internal oblique muscle
6. Arcuate line
7. Transversalis fascia
8. Linea alba



IN THE CLINIC:

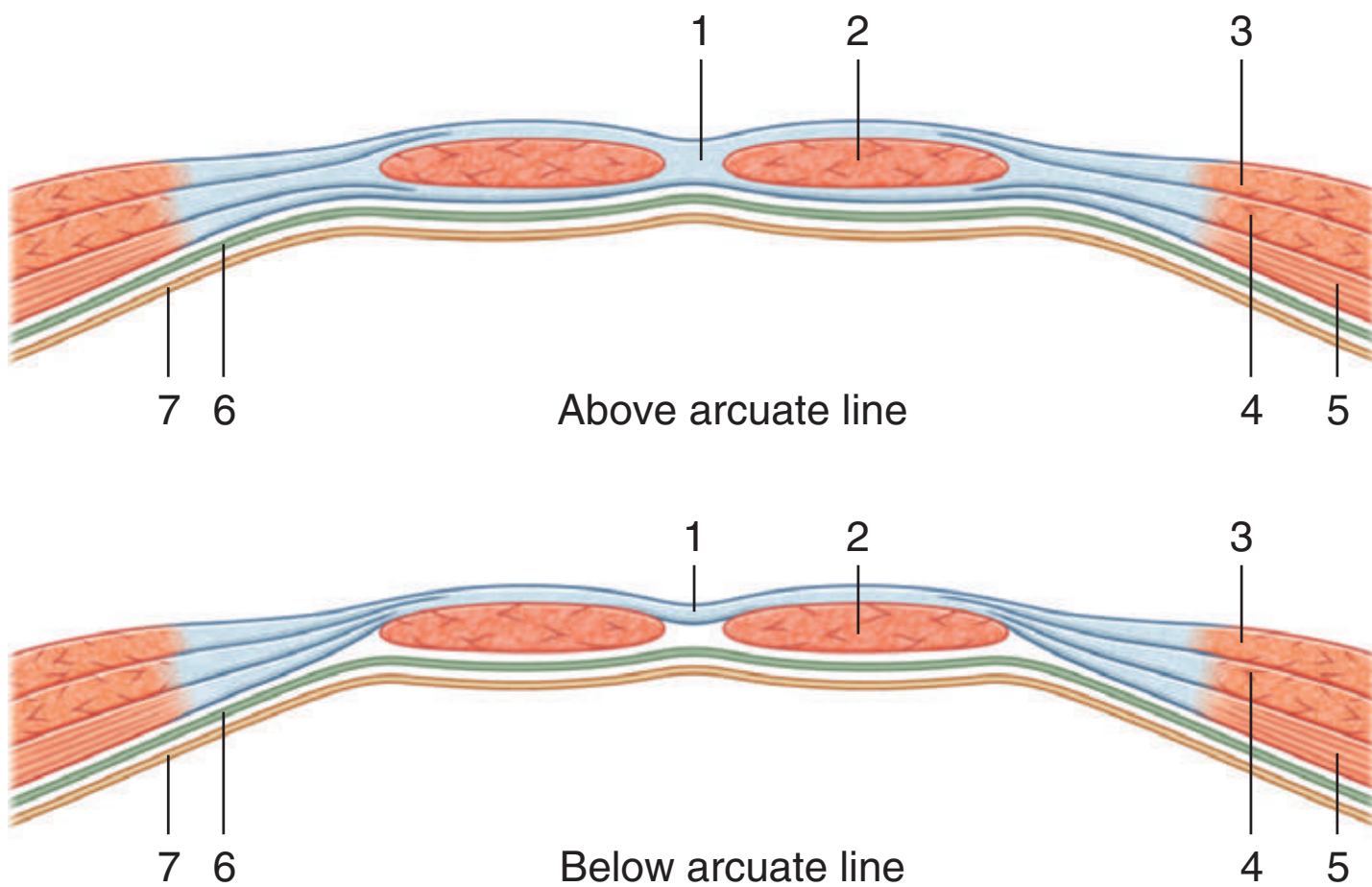
- **Along the course of the rectus abdominis muscle it is intersected by three or four transverse fibrous bands, or tendinous intersections, clearly visible on individuals with a well-developed rectus abdominis.**

Figure from Gray's Anatomy for Students, 3rd edition, p. 282.



Identify the indicated structures related to the rectus sheath.

7



RECTUS SHEATH



1. Linea alba
2. Rectus abdominis muscle
3. External oblique muscle
4. Internal oblique muscle
5. Transversus abdominis muscle
6. Transversalis fascia
7. Parietal peritoneum

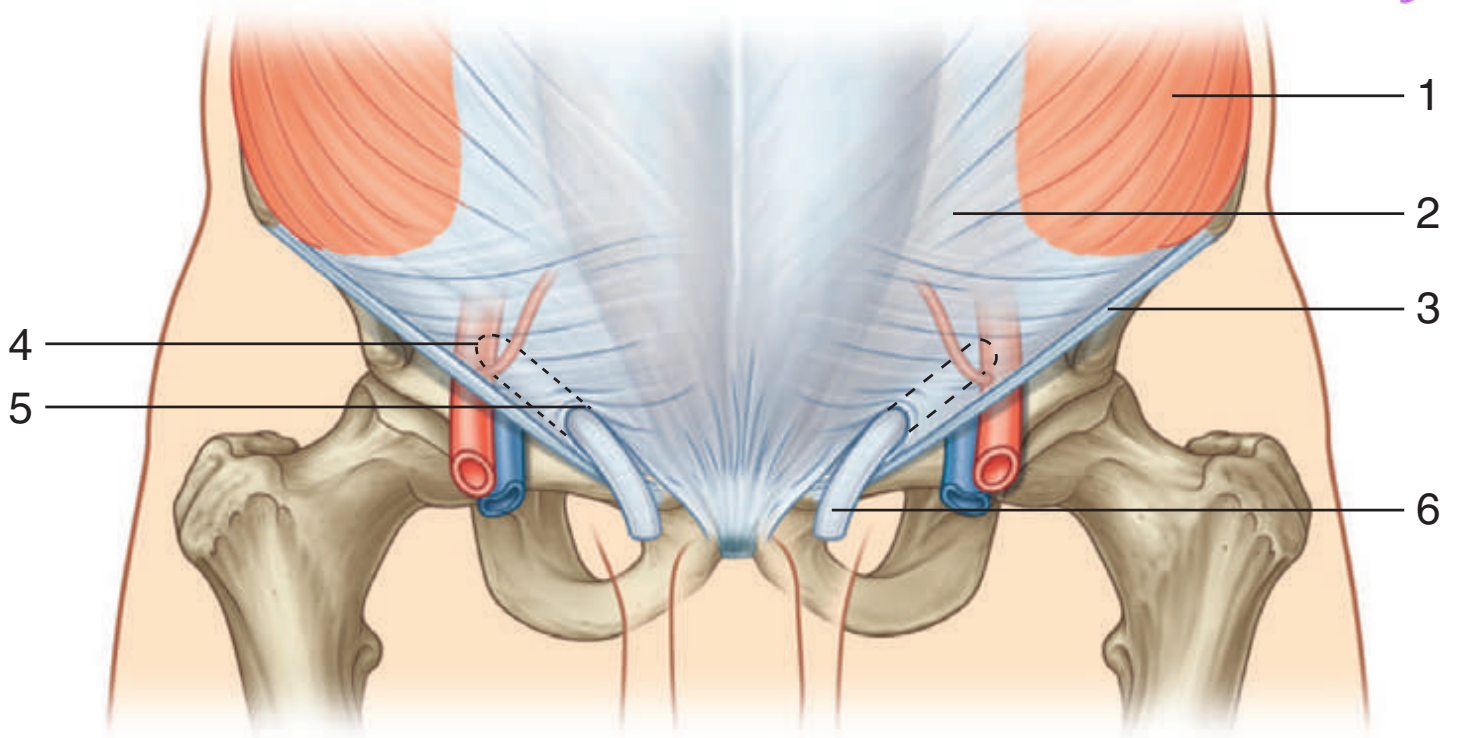
IN THE CLINIC:

- **The rectus sheath completely encloses the upper three fourths of the rectus abdominis muscle and covers the anterior surface of the lower one fourth of the muscle. Because no sheath covers the posterior surface of the lower quarter of the rectus abdominis muscle, the muscle at this point is in direct contact with the transversalis fascia.**

Figure from Gray's Anatomy for Students, 3rd edition, p. 287.



Identify the indicated structures related to the inguinal canal.



INGUINAL CANAL



1. External oblique muscle
2. Aponeurosis of external oblique
3. Inguinal ligament
4. Position of deep inguinal ring
5. Superficial inguinal ring
6. Spermatic cord

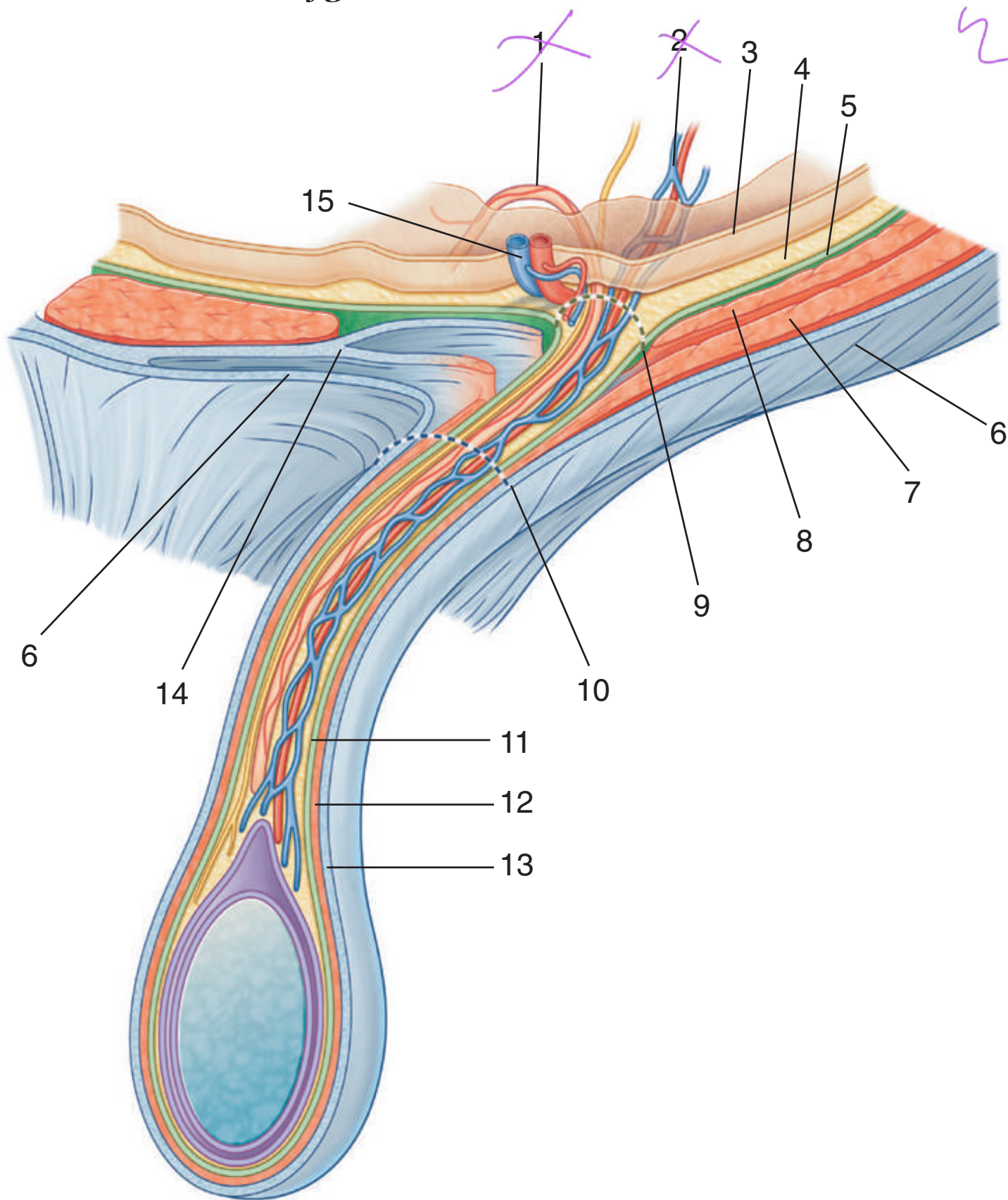
IN THE CLINIC:

- **The groin, or inguinal region, is the area at the junction of the anterior abdominal wall and the thigh. The inguinal canal is situated in this area. Potential weaknesses in the abdominal wall may occur during development, permitting the peritoneal sac to protrude through it and producing an inguinal hernia. This sac may contain abdominal viscera. Inguinal hernias may occur in both sexes, although they are more common in males.**

Figure from Gray's Anatomy for Students, 3rd edition, p. 294.



Identify the indicated structures.



SPERMATIC CORD



1. Ductus deferens
2. Testicular artery and pampiniform plexus of veins
3. Parietal peritoneum
4. Extraperitoneal fascia
5. Transversalis fascia
6. External oblique aponeurosis
7. Internal oblique muscle
8. Transversus abdominis muscle
9. Deep inguinal ring
10. Superficial inguinal ring
11. Internal spermatic fascia
12. Cremasteric fascia
13. External spermatic fascia
14. Conjoint tendon
15. Inferior epigastric vessels

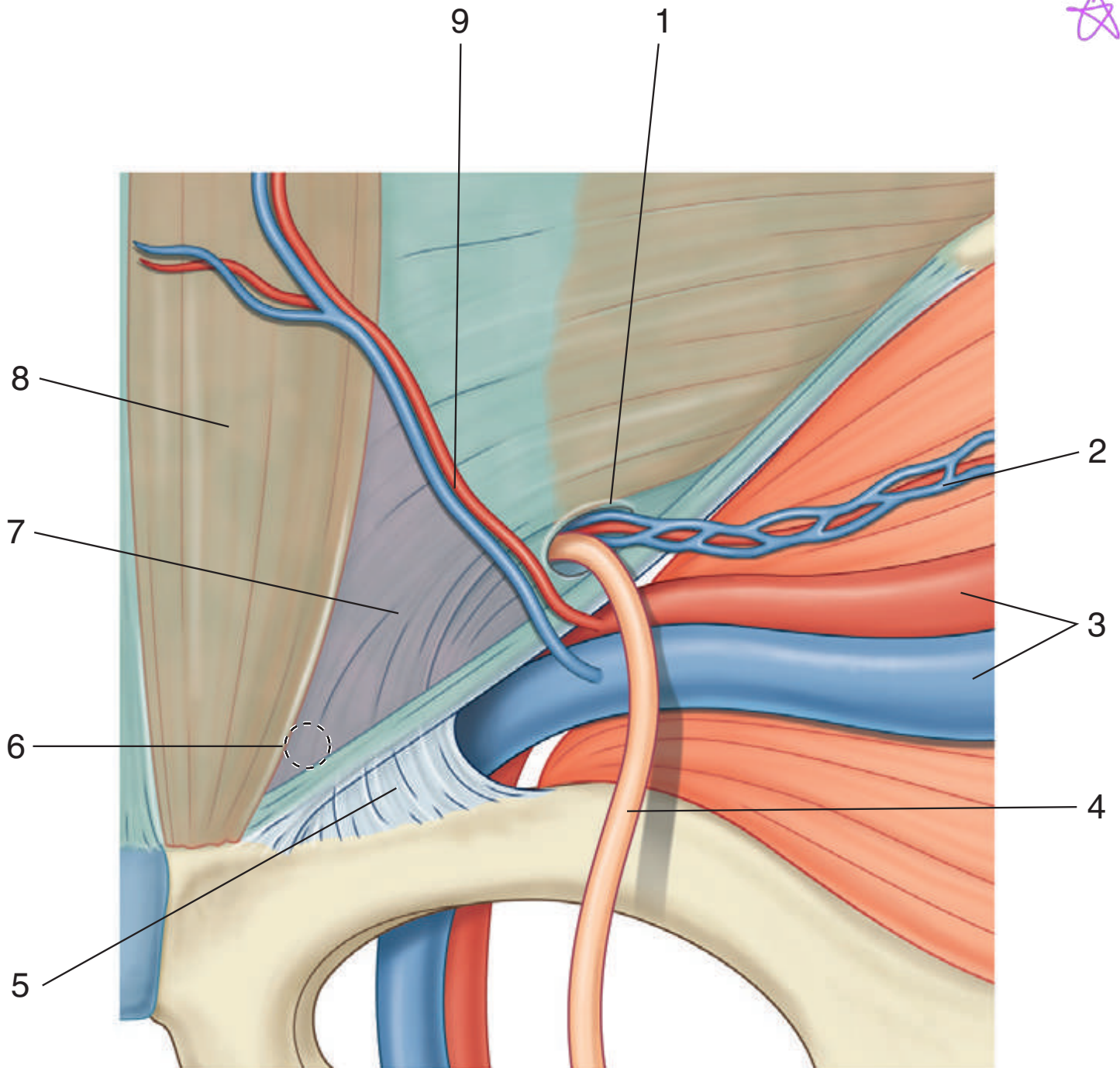
IN THE CLINIC:

- **The spermatic cord is formed from the structures passing between the abdominopelvic cavities and the testis and from the three fascial coverings that enclose these structures. The structures enter the deep inguinal ring and pass through the inguinal canal, exiting from the superficial inguinal ring having acquired the three fascial coverings. This collection of structures and fascias descends into the scrotum, where the structures connect with the testes and the fascias surround the testes.**

Figure from Gray's Anatomy for Students, 3rd edition, p. 298.



Identify the indicated structures in an internal view of the inguinal region.



INGUINAL REGION: INTERNAL VIEW



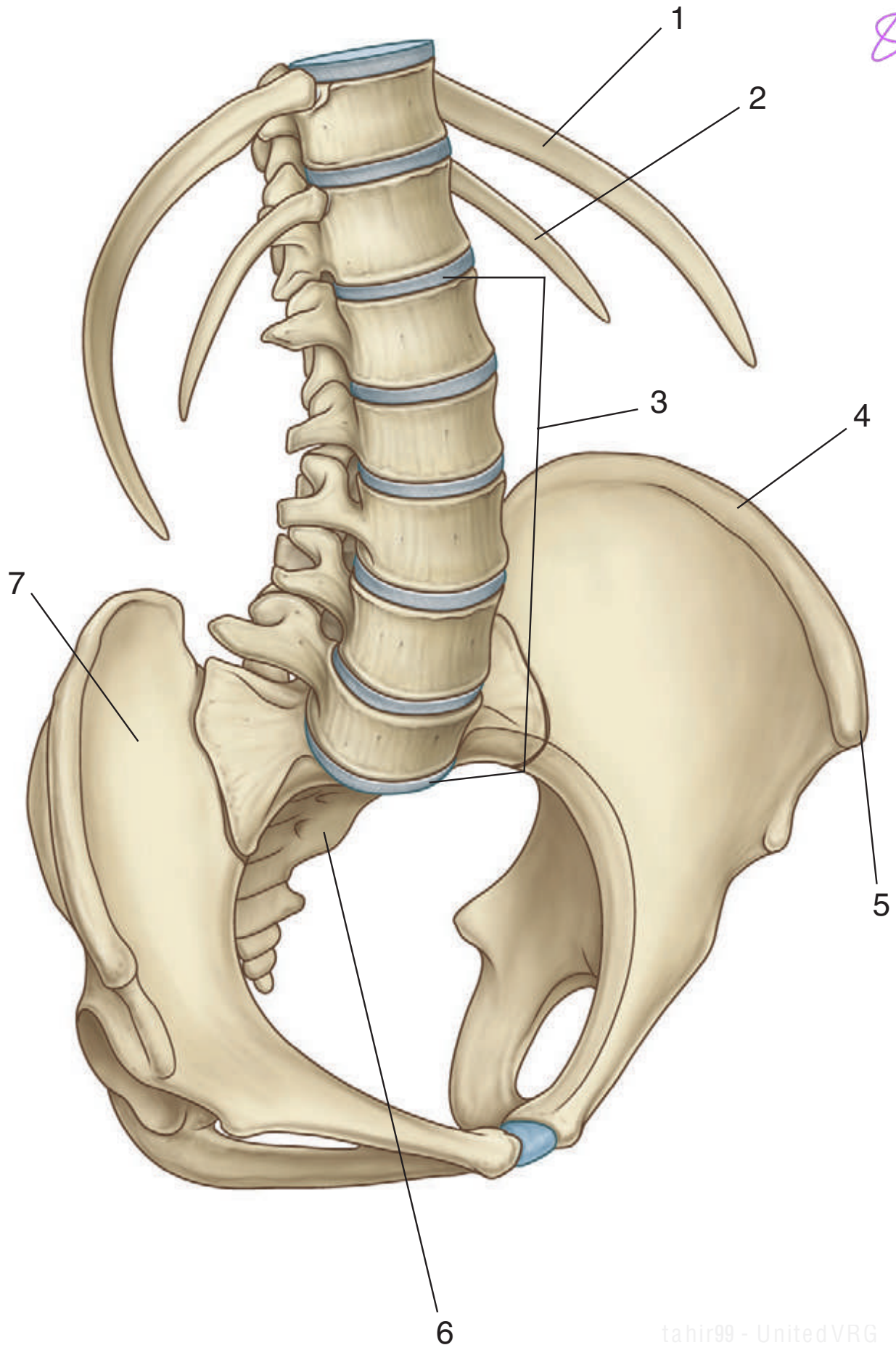
1. Deep inguinal ring
2. Testicular vessels
3. External iliac artery and vein
4. Ductus deferens
5. Lacunar ligament
6. Position of superficial inguinal ring
7. Inguinal triangle
8. Rectus abdominis muscle
9. Inferior epigastric vessels

IN THE CLINIC:

- **Indirect inguinal hernia:** A protruding peritoneal sac enters the deep inguinal ring, lateral to the inferior epigastric vessels, and passes through the inguinal canal. If the hernia is large enough, the sac may emerge through the superficial inguinal ring and, in men, enter the scrotum.
- **Direct inguinal hernia:** A protruding peritoneal sac pushes forward, medial to the inferior epigastric vessels, through the posterior wall of the inguinal canal. If the hernia is large enough, the sac may emerge through the superficial inguinal ring.

Figure from Gray's Anatomy for Students, 3rd edition, p. 300.

Identify the indicated bones and bony landmarks of the posterior abdominal wall.



POSTERIOR ABDOMINAL REGION: BONES



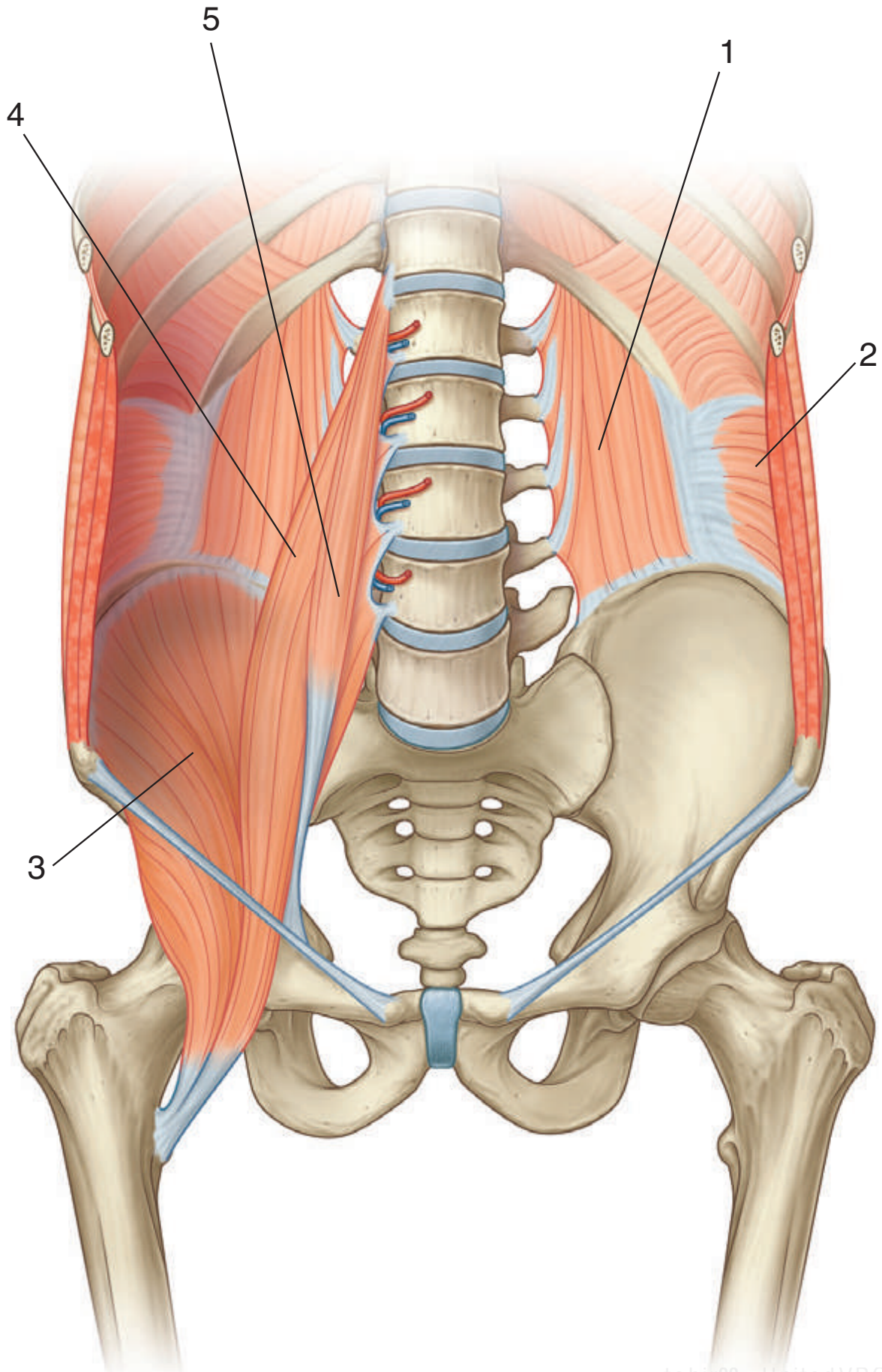
1. Rib XI
2. Rib XII
3. Lumbar vertebrae
4. Iliac crest
5. Anterior superior iliac spine
6. Sacrum
7. Ilium

IN THE CLINIC:

- **Projecting into the midline of the posterior abdominal area are the bodies of five lumbar vertebrae and their associated intervertebral discs. The prominence of these structures is due to the normal secondary curvature (a forward convexity) of this part of the vertebral column.**

Figure from Gray's Anatomy for Students, 3rd edition, p. 367.

Identify the indicated muscles of the posterior abdominal wall.



POSTERIOR ABDOMINAL REGION: MUSCLES



1. Quadratus lumborum muscle
2. Transversus abdominis muscle
3. Iliacus muscle
4. Psoas major muscle
5. Psoas minor muscle

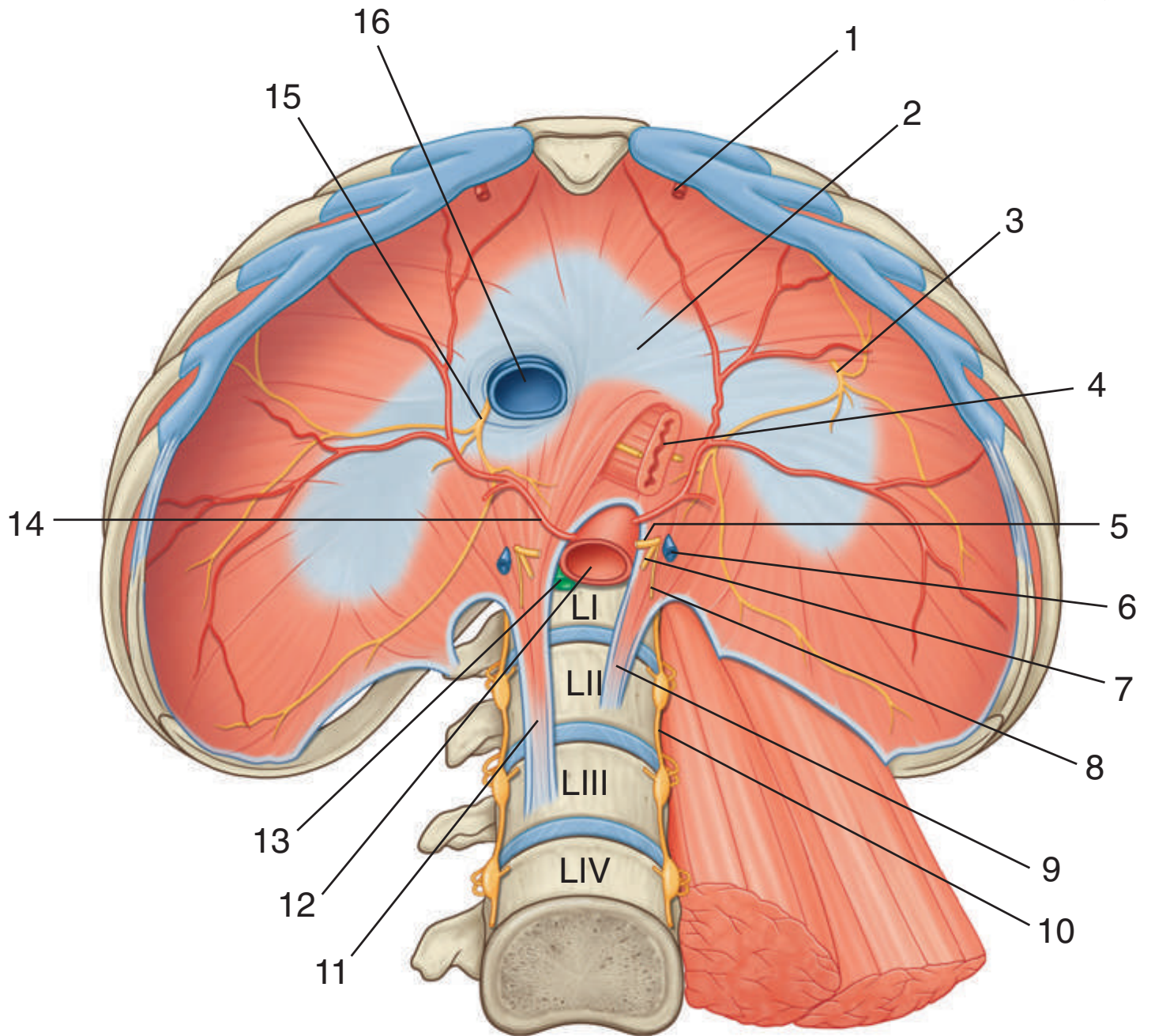
IN THE CLINIC:

- **The psoas muscle and its sheath arise from the lumbar vertebrae and the intervertebral discs between each vertebra. With certain infections, typically tuberculosis, the disc is preferentially affected. As the infection develops, it spreads anteriorly and anterolaterally into the psoas muscle sheath and may appear as a mass below the inguinal ligament in the femoral triangle.**

Figure from Gray's Anatomy for Students, 3rd edition, p. 368.



Identify the indicated structures related to the diaphragm.



DIAPHRAGM



1. Superior epigastric artery
2. Central tendon
3. Left phrenic nerve
4. Esophagus with anterior and posterior vagal trunks
5. Greater splanchnic nerve
6. Hemi-azygos vein
7. Lesser splanchnic nerve
8. Least splanchnic nerve
9. Left crus
10. Sympathetic trunk
11. Right crus
12. Aorta
13. Thoracic duct
14. Inferior phrenic artery
15. Right phrenic nerve
16. Inferior vena cava

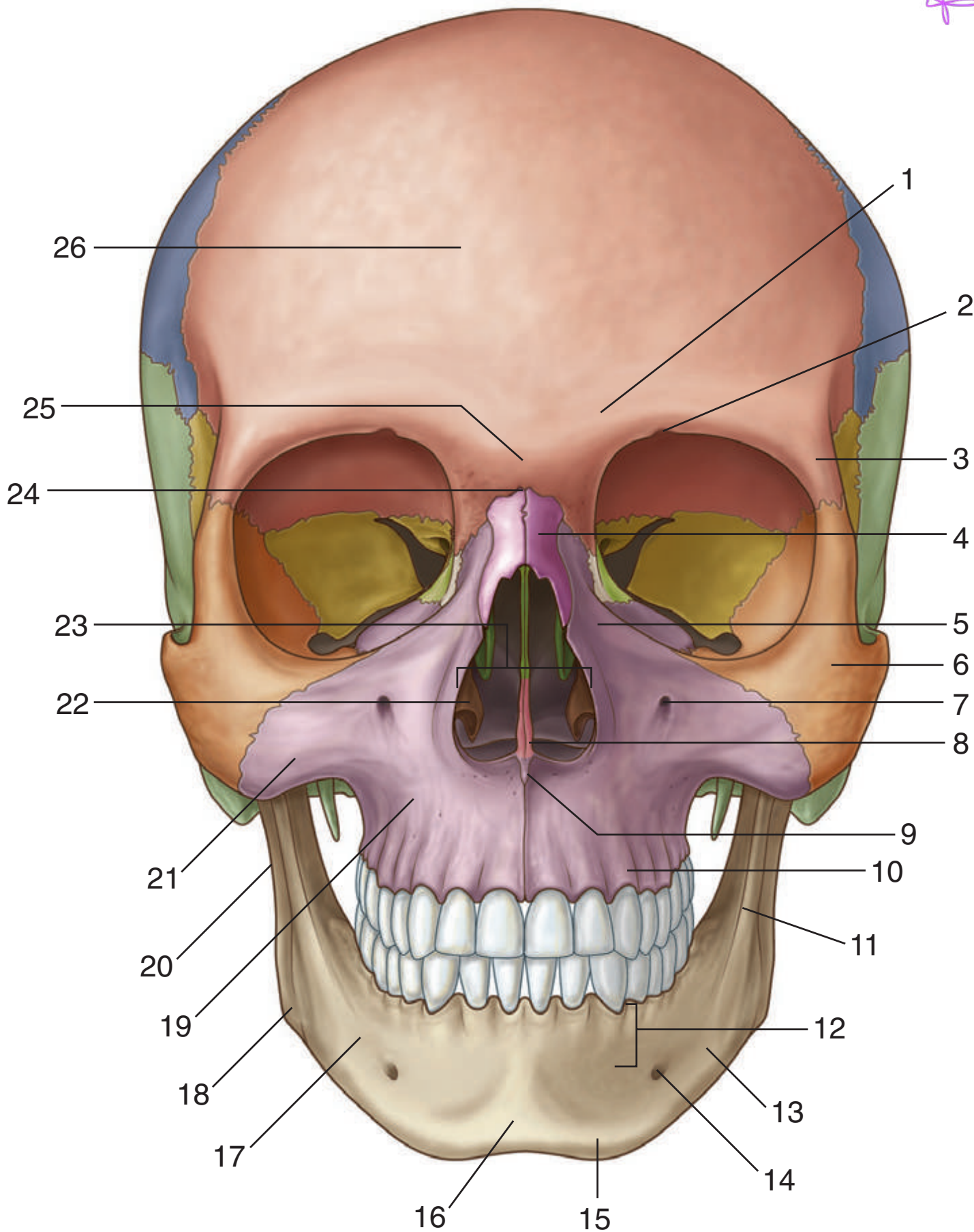
IN THE CLINIC:

- **At the level of the esophageal hiatus, the diaphragm may be lax, allowing the stomach to herniate into the posterior mediastinum. This may produce symptoms of acid reflux. Ulceration and bleeding may also occur.**

Figure from Gray's Anatomy for Students, 3rd edition, p. 3694.



Identify the indicated features and bones in this anterior view of the skull.





SKULL: ANTERIOR VIEW



1. Superciliary arch
2. Supra-orbital notch (foramen)
3. Zygomatic process (of frontal bone)
4. Nasal bone
5. Frontal process (of maxilla)
6. Zygomatic bone
7. Infra-orbital foramen
8. Nasal crest
9. Anterior nasal spine
10. Alveolar process (of maxilla)
11. Oblique line (of mandible)
12. Alveolar part (of mandible)
13. Mandible
14. Mental foramen
15. Mental tubercle
16. Mental protuberance
17. Body of mandible
18. Angle of mandible
19. Maxilla
20. Ramus of mandible
21. Zygomatic process (of maxilla)
22. Inferior nasal concha
23. Piriform aperture
24. Nasion
25. Glabella
26. Frontal bone

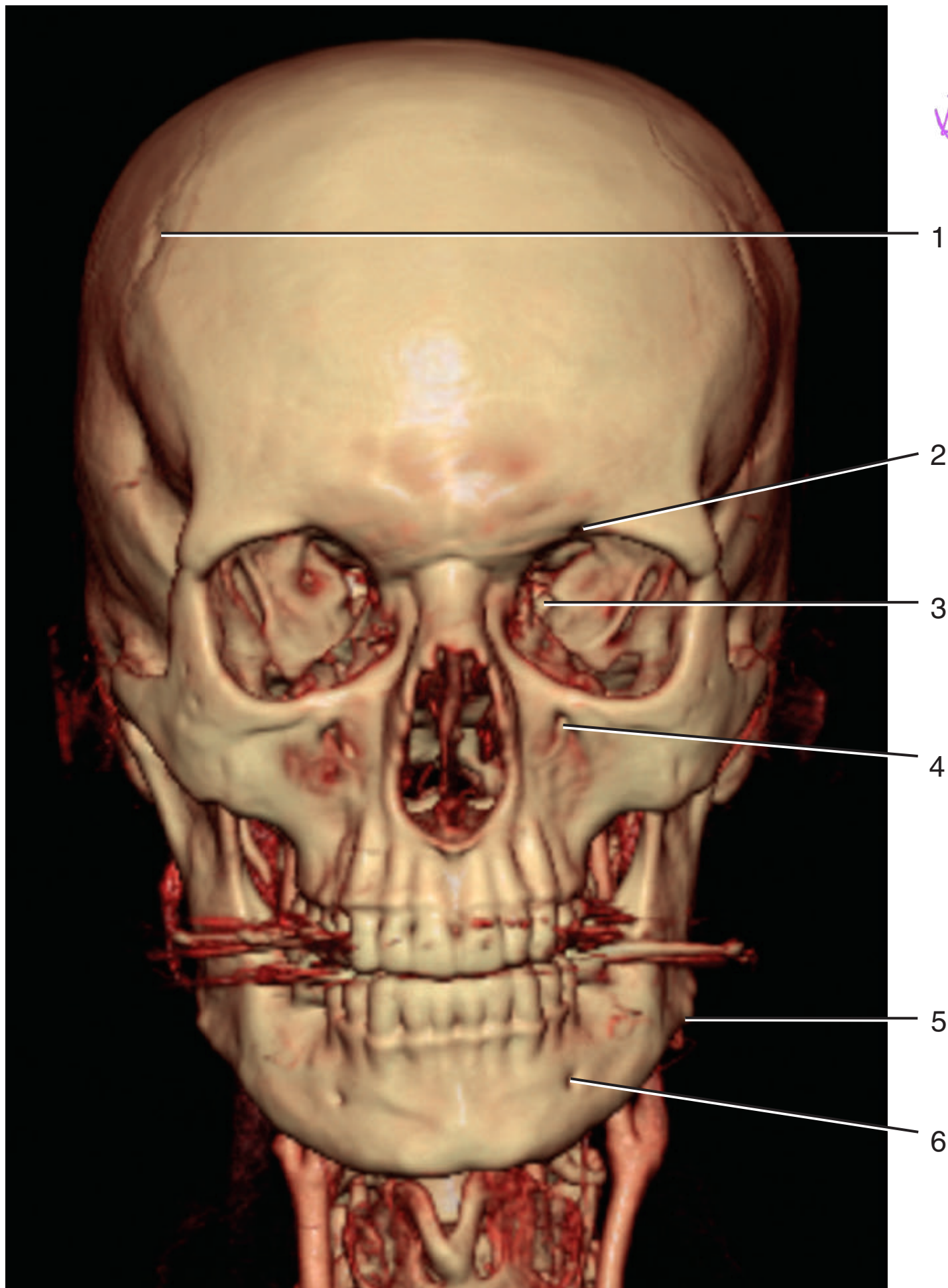
Figure from Gray's Anatomy for Students, 3rd edition, p. 855.



MULTIDETECTOR CT: ANTERIOR VIEW OF SKULL



Identify the indicated structures.





MULTIDETECTOR CT: ANTERIOR VIEW OF SKULL

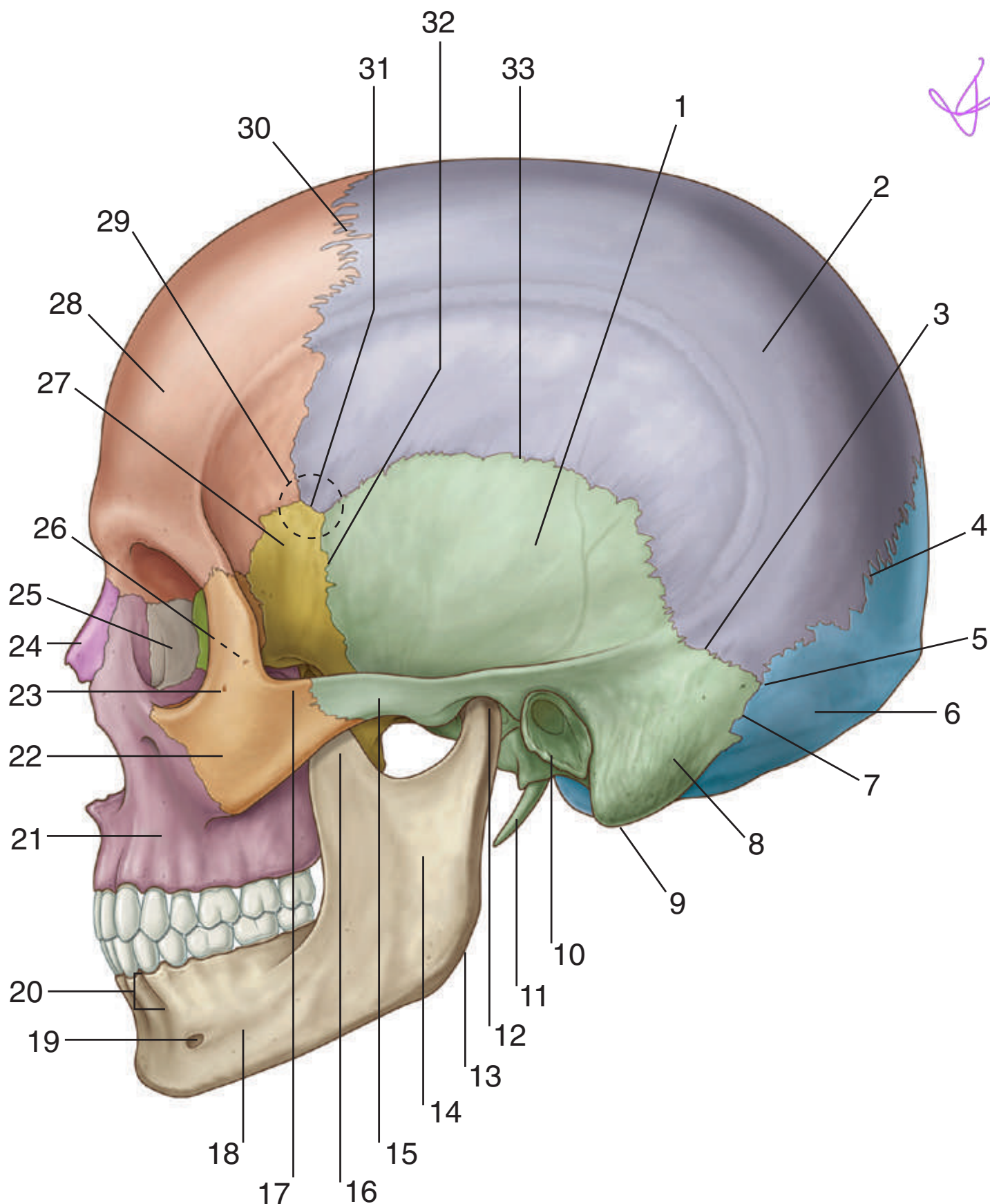


1. Coronal suture
2. Supra-orbital notch (foramen)
3. Superior orbital fissure
4. Infra-orbital foramen
5. Angle of mandible
6. Mental foramen

Figure from Gray's Basic Anatomy, p. 417.



Identify the indicated features and bones in this lateral view of the skull.





SKULL: LATERAL VIEW



1. Squamous part (of temporal bone)
2. Parietal bone
3. Parietomastoid suture
4. Lambdoid suture
5. Asterion
6. Occipital bone
7. Occipitomastoid suture
8. Mastoid part of temporal bone
9. Mastoid process
10. Tympanic part (of temporal bone)
11. Styloid process
12. Condylar process (of mandible)
13. Angle (of mandible)
14. Ramus of mandible
15. Zygomatic process (of temporal bone)
16. Coronoid process (of mandible)
17. Temporal process (of zygomatic bone)
18. Body of mandible
19. Mental foramen
20. Alveolar part (of mandible)
21. Maxilla
22. Zygomatic bone
23. Zygomaticofacial foramen
24. Nasal bone
25. Lacrimal bone
26. Zygomaticotemporal foramen (on deep surface of zygomatic bone)
27. Greater wing (of sphenoid bone)
28. Frontal bone
29. Pterion
30. Coronal suture
31. Sphenoparietal suture
32. Sphenosquamous suture
33. Squamous suture

Figure from Gray's Anatomy for Students, 3rd edition, p. 857.

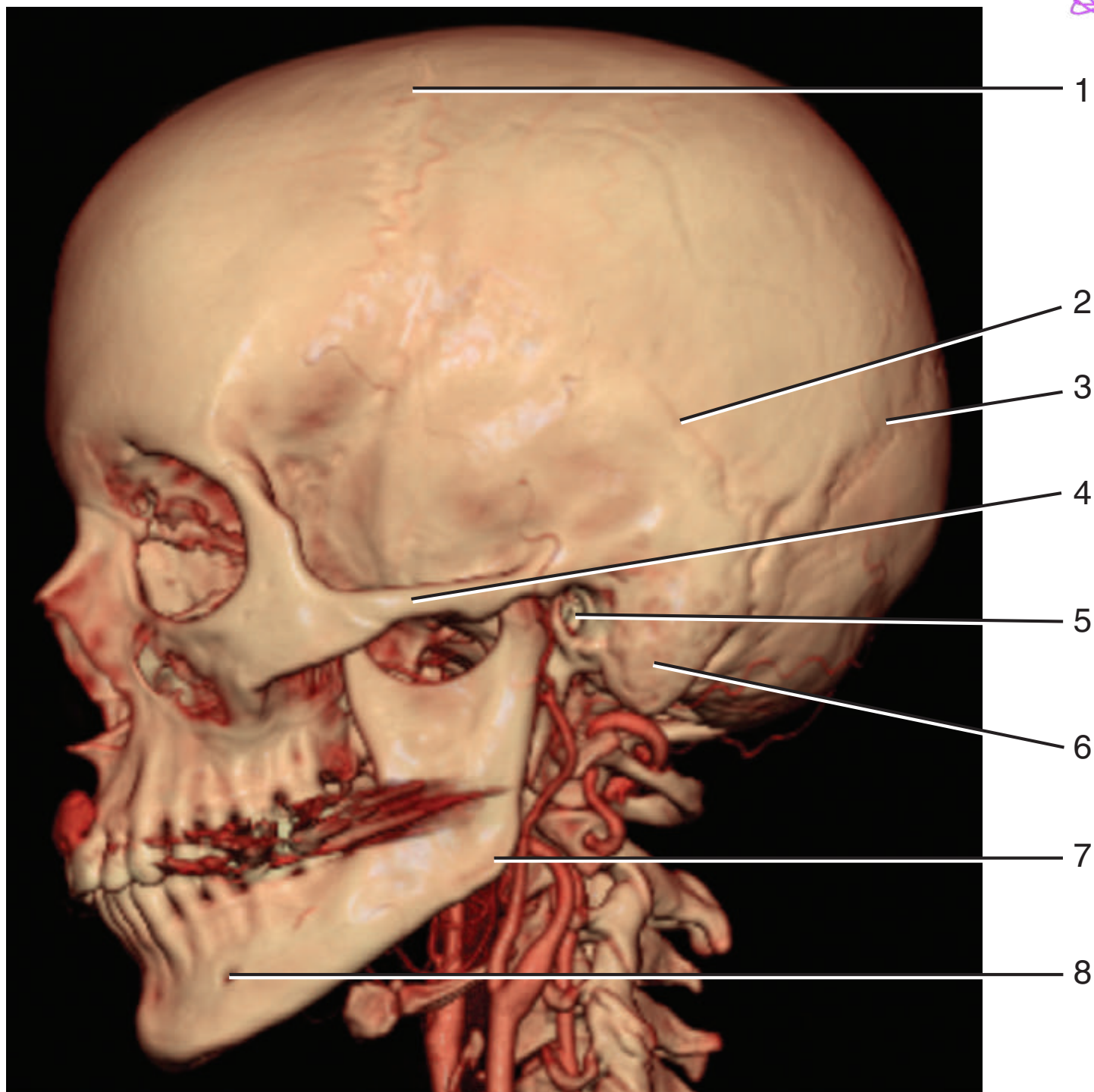


MULTIDETECTOR CT: LATERAL VIEW OF SKULL



Identify the indicated structures.

8



MULTIDETECTOR CT: LATERAL VIEW OF SKULL



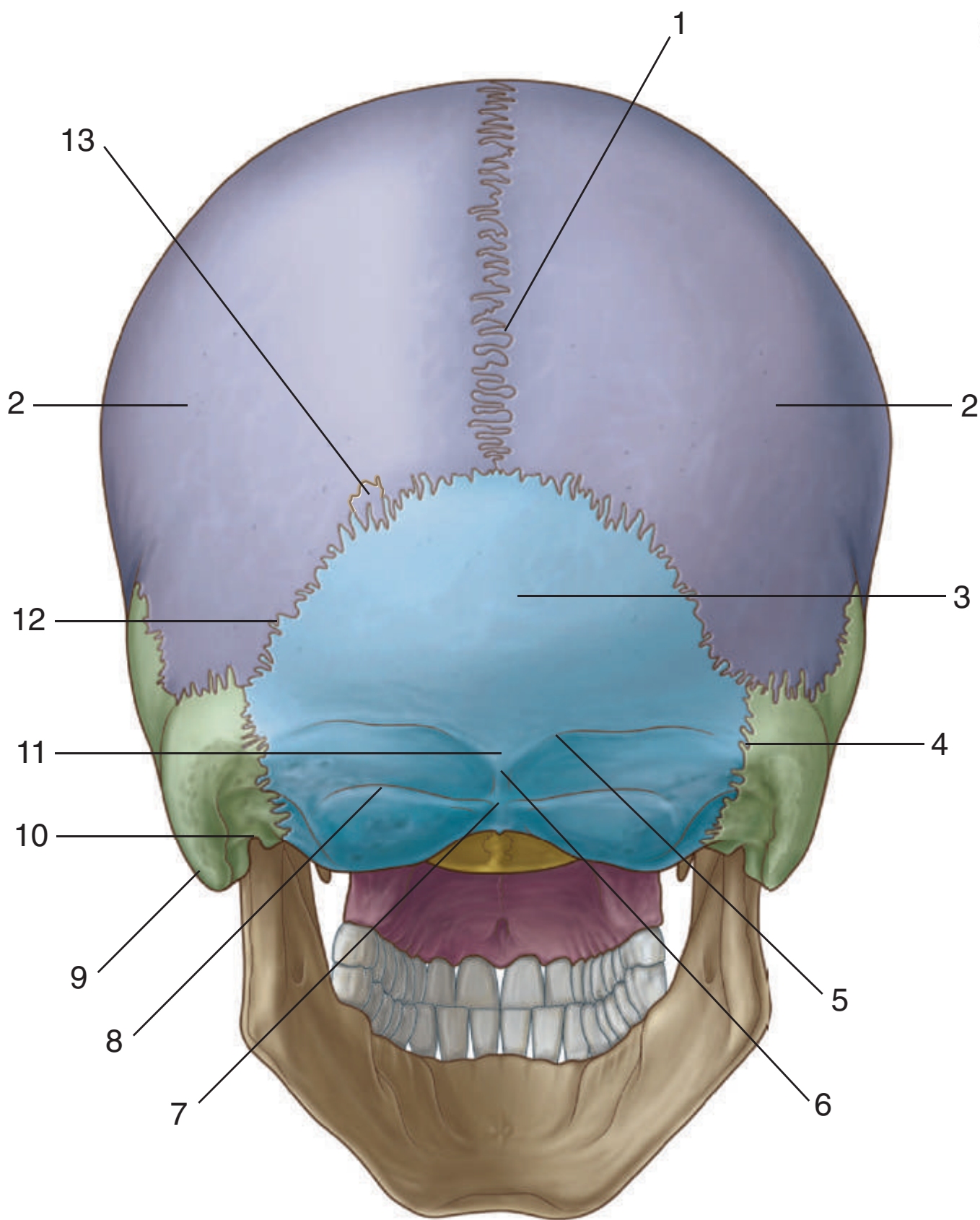
1. Coronal suture
2. Squamous suture
3. Lamboid suture
4. Zygomatic arch
5. External acoustic meatus
6. Mastoid process
7. Angle of mandible
8. Mental foramen

Figure from Gray's Basic Anatomy, p. 419.



Identify the indicated features and bones in this posterior view of the skull.

Handwritten signature





SKULL: POSTERIOR VIEW

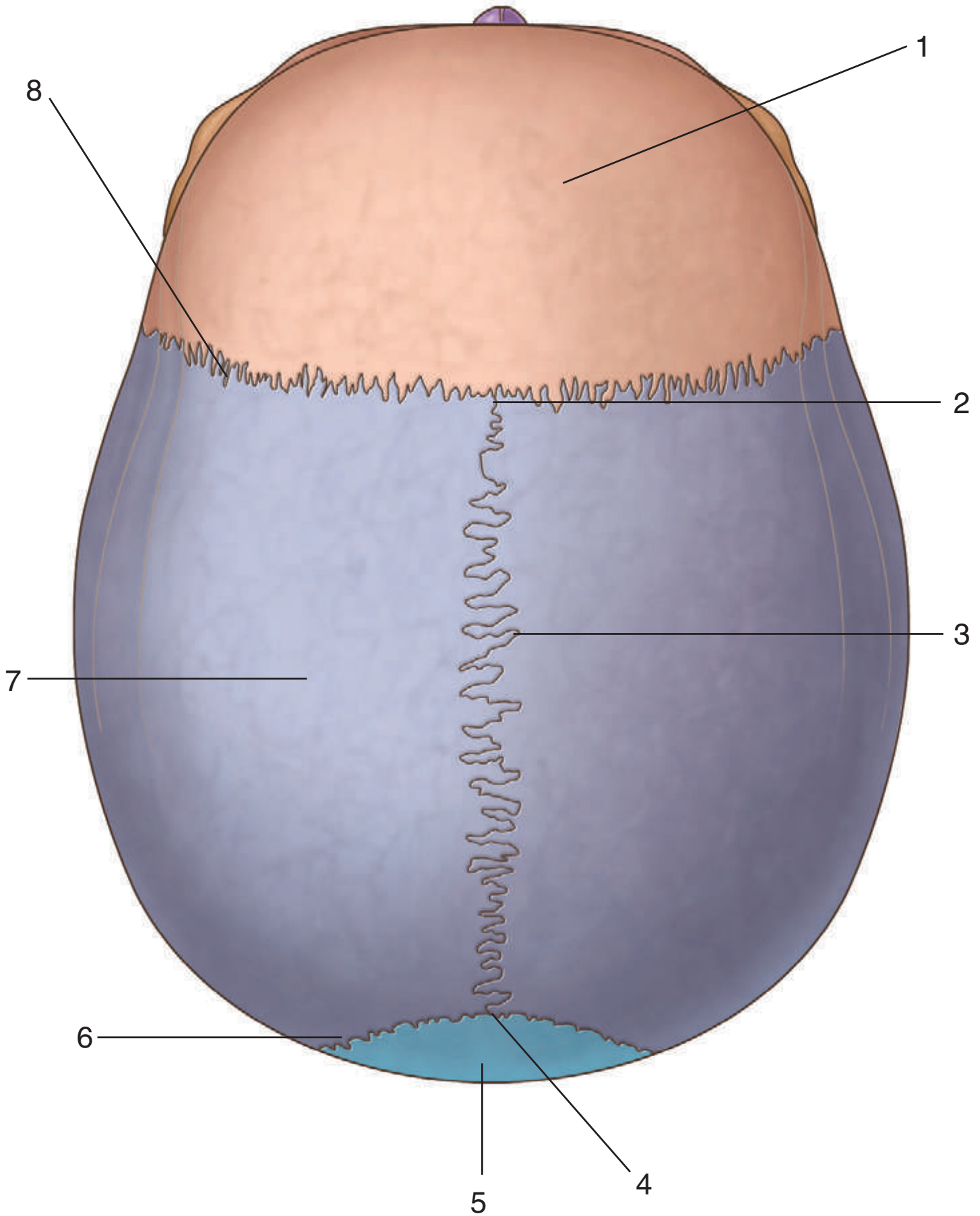


1. Sagittal suture
2. Parietal bone
3. Squamous part (of occipital bone)
4. Occipitomastoid suture
5. Superior nuchal line
6. Inion
7. External occipital crest
8. Inferior nuchal line
9. Mastoid process
10. Mastoid notch
11. External occipital protuberance
12. Lambdoid suture
13. Sutural bone

Figure from Gray's Anatomy for Students, 3rd edition, p. 859.



Identify the indicated features and bones in this superior view of the skull.





SKULL: SUPERIOR VIEW

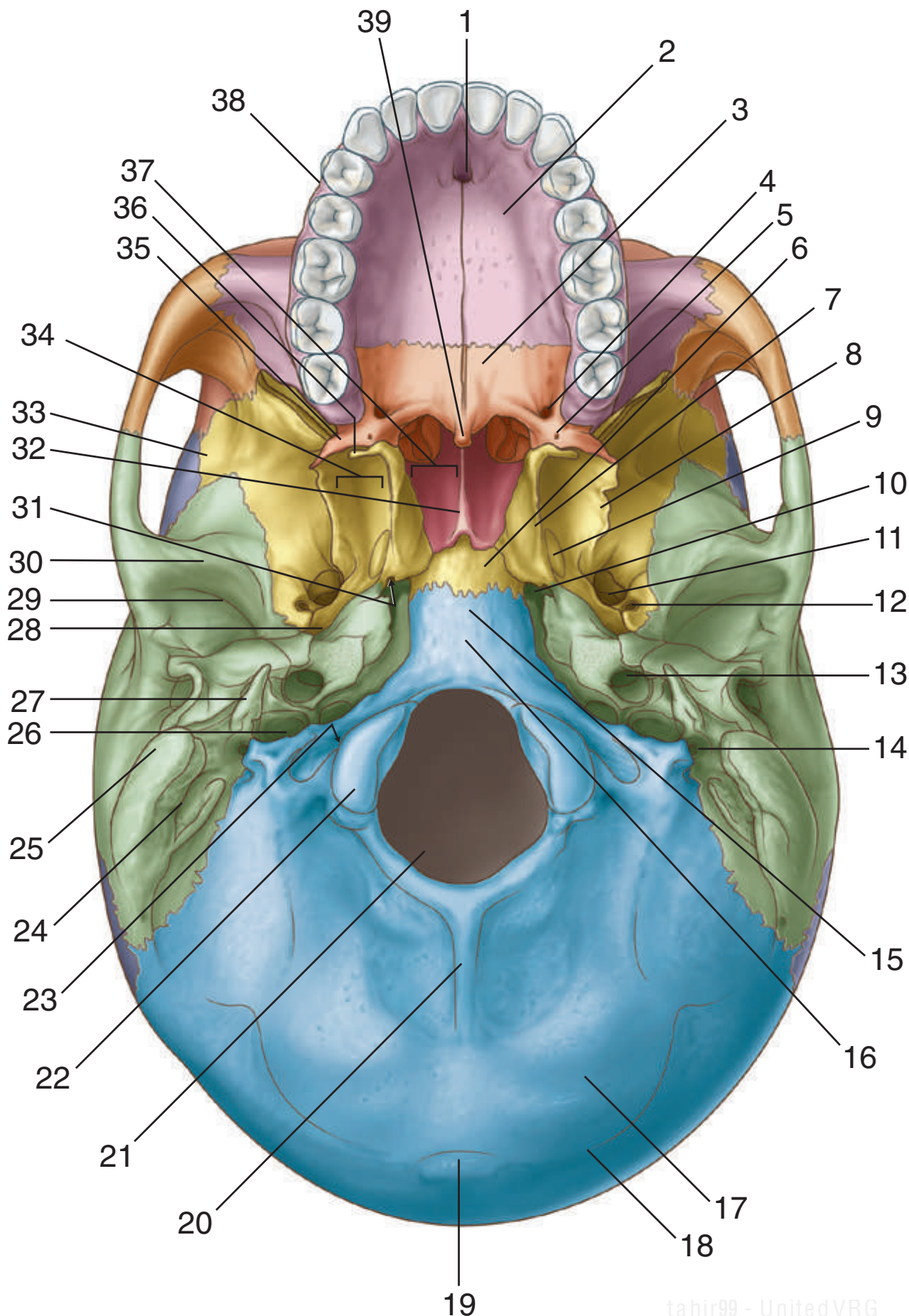


1. Frontal bone
2. Bregma
3. Sagittal suture
4. Lambda
5. Occipital bone
6. Lambdoid suture
7. Parietal bone
8. Coronal suture

Figure from Gray's Anatomy for Students, 3rd edition, p. 860.



Identify the indicated structures in this inferior view of the skull.





SKULL: INFERIOR VIEW

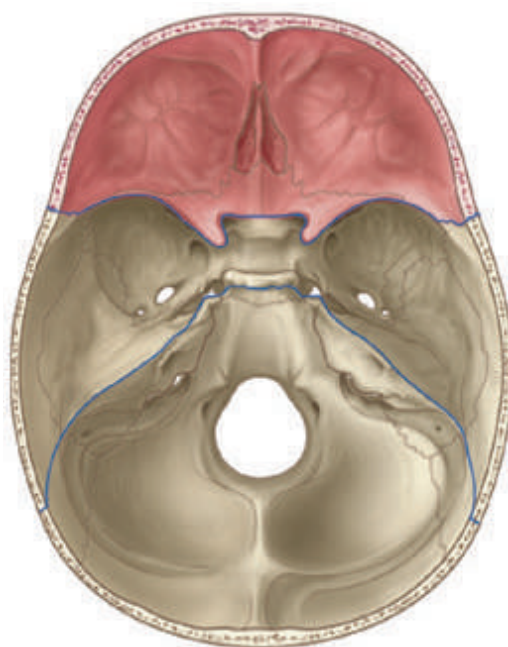
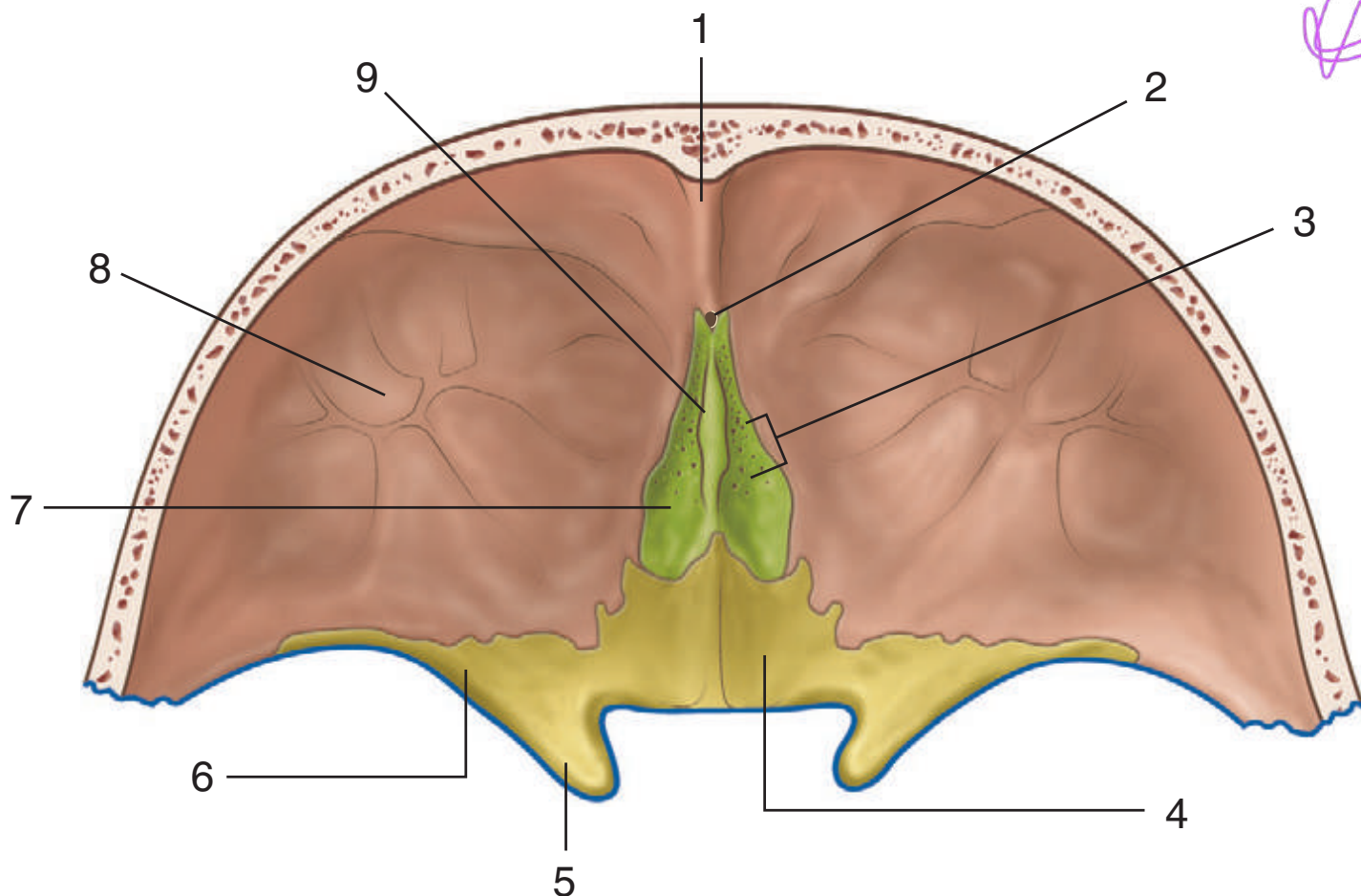


1. Incisive fossa
2. Hard palate (palatine process of maxilla)
3. Hard palate (horizontal plate of palatine bone)
4. Greater palatine foramen
5. Lesser palatine foramen
6. Body of sphenoid
7. Medial plate of pterygoid process
8. Lateral plate of pterygoid process
9. Scaphoid fossa
10. Foramen lacerum
11. Foramen ovale
12. Foramen spinosum
13. Carotid canal
14. Stylomastoid foramen
15. Basilar part of occipital bone
16. Pharyngeal tubercle
17. Inferior nuchal line
18. Superior nuchal line
19. External occipital protuberance
20. External occipital crest
21. Foramen magnum
22. Occipital condyle
23. Hypoglossal canal
24. Mastoid notch
25. Mastoid process
26. Jugular foramen
27. Styloid process
28. Groove for auditory tube
29. Mandibular fossa
30. Articular tubercle
31. Opening of pterygoid canal
32. Vomer
33. Greater wing (of sphenoid bone)
34. Pterygoid fossa
35. Pyramidal process of palatine bone
36. Pterygoid hamulus
37. Posterior nasal aperture (choana)
38. Alveolar arch
39. Posterior nasal spine

Figure from Gray's Anatomy for Students, 3rd edition, p. 861.



Identify the indicated structures in the anterior cranial fossa.



SKULL: ANTERIOR CRANIAL FOSSA



1. Frontal crest
2. Foramen caecum
3. Foramina of cribriform plate
4. Body of sphenoid
5. Anterior clinoid process
6. Lesser wing of sphenoid
7. Cribriform plate
8. Orbital part of frontal bone
9. Crista galli

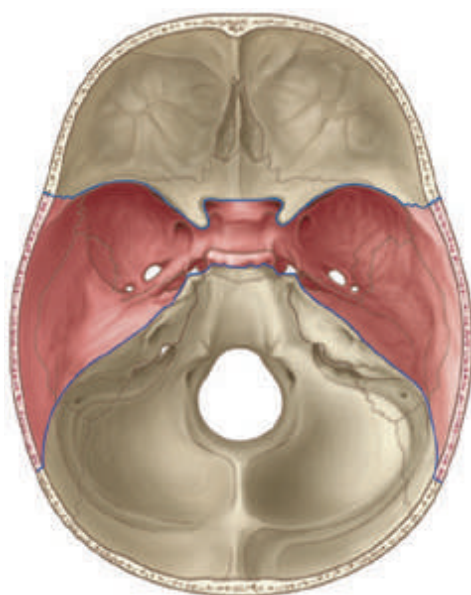
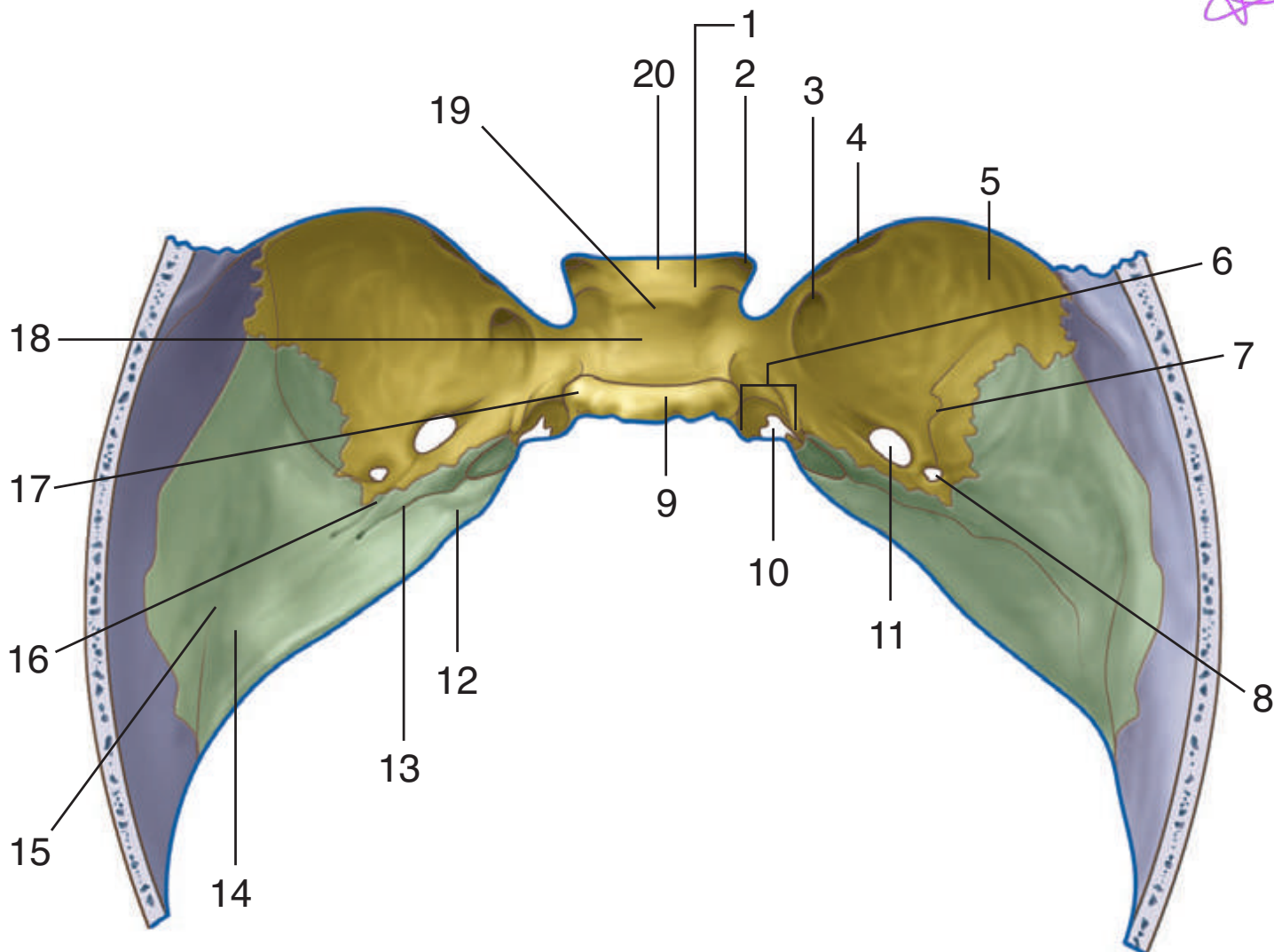
IN THE CLINIC:

- **Treatment of primary brain injury is extremely limited. Axonal disruption and cellular death are generally irrecoverable. When the brain is injured, it tends to swell; however, it is encased in a fixed space (cranial cavity), and this swelling impairs cerebral function. Furthermore, it decreases venous return, necessitating a higher arterial pressure. This causes the brain to swell further, causing compression of the brain. Compression of the brain may result in extrusion of the brainstem (coning) through the foramen magnum.**

Figure from Gray's Anatomy for Students, 3rd edition, p. 865.



Identify the indicated structures in the middle cranial fossa.





SKULL: MIDDLE CRANIAL FOSSA



1. Middle clinoid process
2. Optic canal
3. Foramen rotundum
4. Superior orbital fissure
5. Greater wing (of sphenoid)
6. Groove for internal carotid artery
7. Groove for middle meningeal artery
8. Foramen spinosum
9. Dorsum sellae
10. Foramen lacerum
11. Foramen ovale
12. Trigeminal impression
13. Groove and hiatus for greater petrosal nerve
14. Arcuate eminence
15. Tegmen tympani
16. Groove and hiatus for lesser petrosal nerve
17. Posterior clinoid process
18. Hypophysial fossa
19. Tuberculum sellae
20. Chiasmatic sulcus

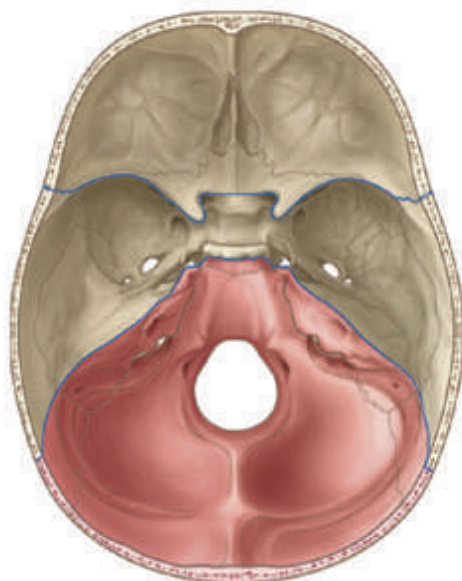
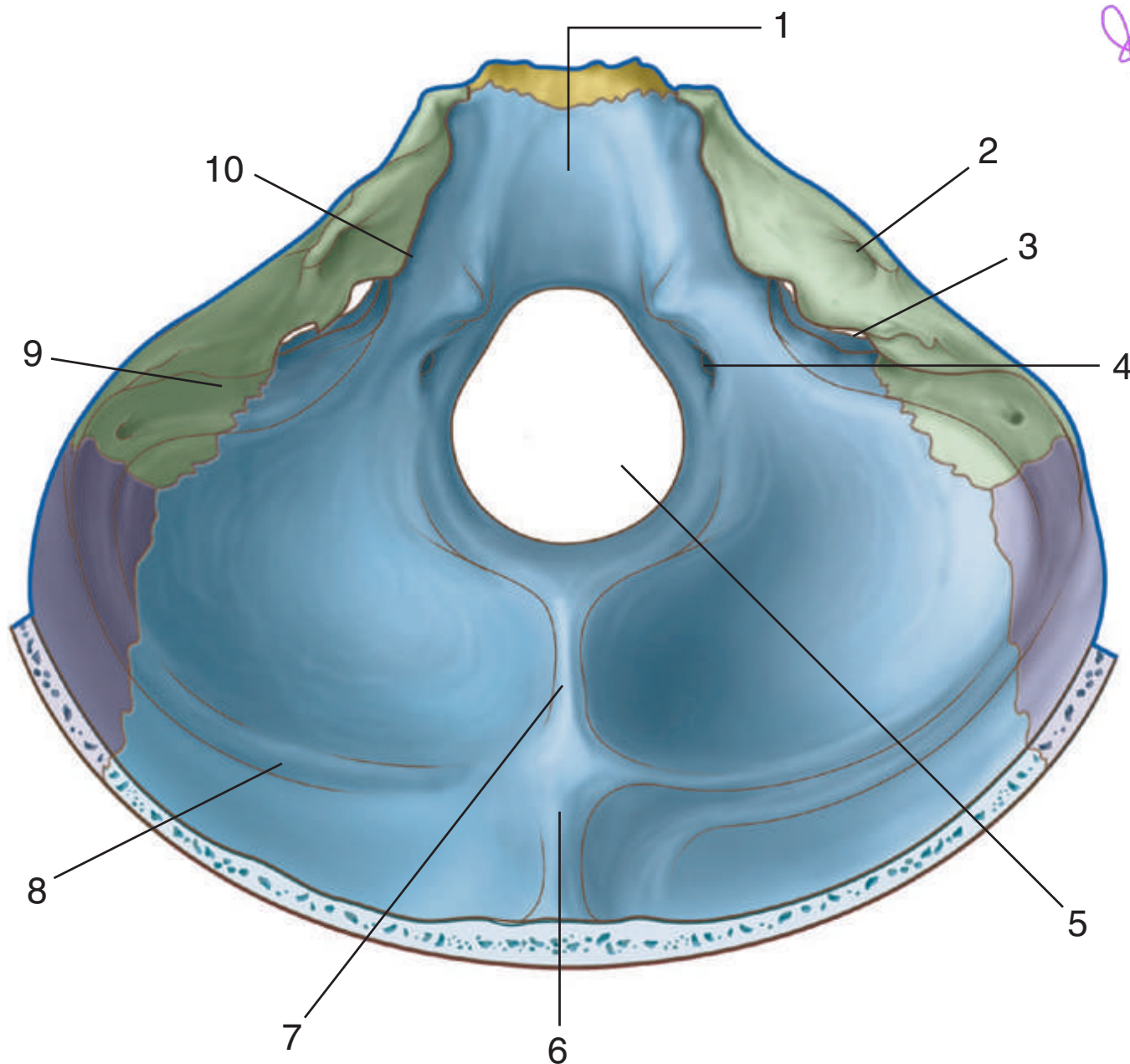
IN THE CLINIC:

- **Determination of the site from which a tumor arises is important because misinterpretation of the location can have serious consequences for the patient. When assessing any tumor in the brain, it is important to determine whether it is within the brain or outside the brain. Tumors outside the brain include meningiomas, typically found around the falx cerebri, and acoustic neuromas, typically found around the cerebellopontine angle associated with the vestibulocochlear nerve (VIII).**

Figure from Gray's Anatomy for Students, 3rd edition, p. 867.



Identify the indicated structures in the posterior cranial fossa.





SKULL: POSTERIOR CRANIAL FOSSA



1. Clivus
2. Internal acoustic meatus
3. Jugular foramen
4. Hypoglossal canal
5. Foramen magnum
6. Internal occipital protuberance
7. Internal occipital crest
8. Groove for transverse sinus
9. Groove for sigmoidal sinus
10. Groove for inferior petrosal sinus

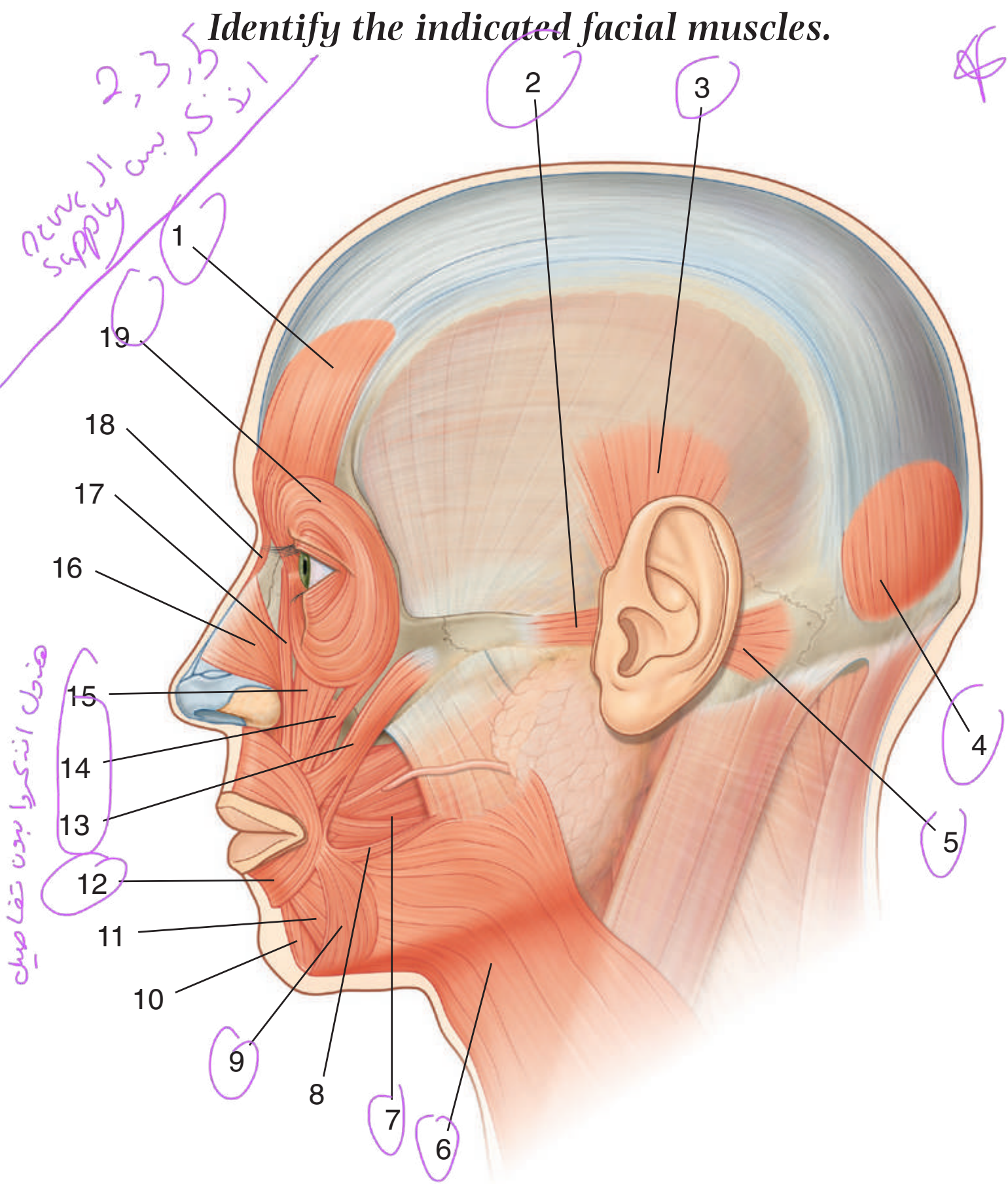
IN THE CLINIC:

- **The Glasgow Coma Scale is used to assess the level of consciousness in head-injured patients. There is a total score of 15 points. A score of 15/15 indicates a patient is alert and fully oriented, whereas 3/15 indicates a deep coma. The points score consists of the best motor response, 6 points best score; best verbal response, 5 points best score; and best eye movement response, 4 points best score.**

Figure from Gray's Anatomy for Students, 3rd edition, p. 869.



Identify the indicated facial muscles.



1

2

3

19

18

17

16

15

14

13

12

11

10

9

8

7

6

4

5



FACIAL MUSCLES



1. Frontal belly of occipitofrontalis
2. Anterior auricular
3. Superior auricular
4. Occipital belly of occipitofrontalis
5. Posterior auricular
6. Platysma
7. Buccinator
8. Risorius
9. Depressor anguli oris
10. Mentalis
11. Depressor labii inferioris
12. Orbicularis oris
13. Zygomaticus major
14. Zygomaticus minor
15. Levator labii superioris
16. Nasalis
17. Levator labii superioris alaeque nasi
18. Procerus
19. Orbicularis oculi

IN THE CLINIC:

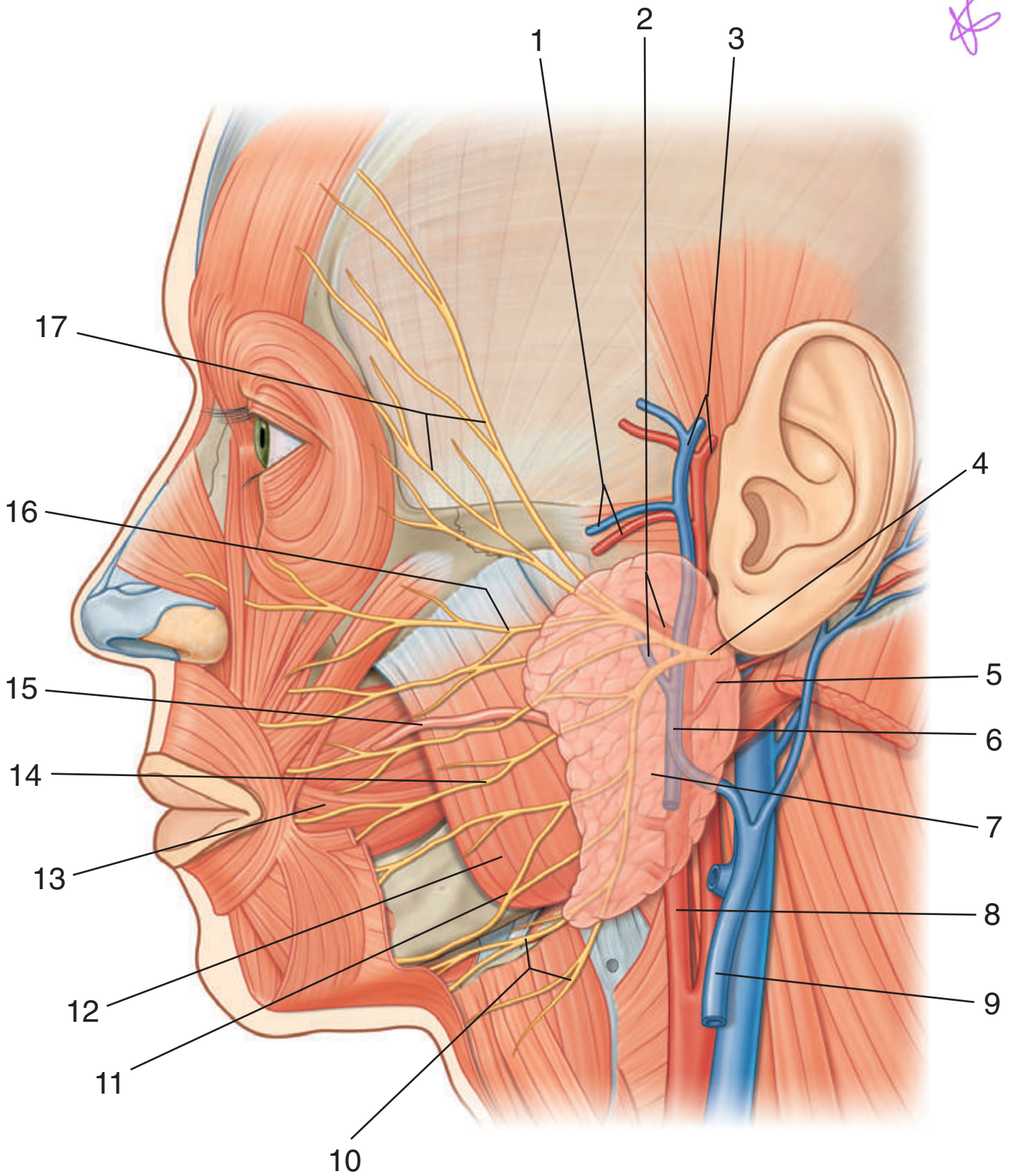
All muscles of facial expressions are innervated by the facial nerve (VII). The complexity of the facial nerve (VII) is demonstrated by the different pathologic processes and sites at which these processes occur. Common sites of pathology that involve the facial nerve include the following:

- **Central lesions: a primary brainstem lesion affecting sensory and motor functions of the nerve, including its special components.**
- **At and around the geniculate ganglion: accompanied by loss of motor function on the same side of the face, taste to the anterior two thirds of the tongue, lacrimation, and some salivation.**
- **At and around the stylomastoid foramen: loss of motor function on the same side of the face.**

Figure from Gray's Anatomy for Students, 3rd edition, p. 904.



Identify the indicated structures in this lateral view of the face.





LATERAL FACE



1. Transverse facial artery and vein
2. Maxillary artery and vein
3. Superficial temporal artery and vein
4. Facial nerve (VII)
5. Posterior auricular artery
6. Retromandibular vein
7. Parotid gland
8. External carotid artery
9. External jugular vein
10. Cervical branches of the facial nerve (VII)
11. Marginal mandibular branches of the facial nerve (VII)
12. Masseter muscle
13. Buccinator muscle
14. Buccal branches of the facial nerve (VII)
15. Parotid duct
16. Zygomatic branches of the facial nerve (VII)
17. Temporal branches of the facial nerve (VII)

IN THE CLINIC:

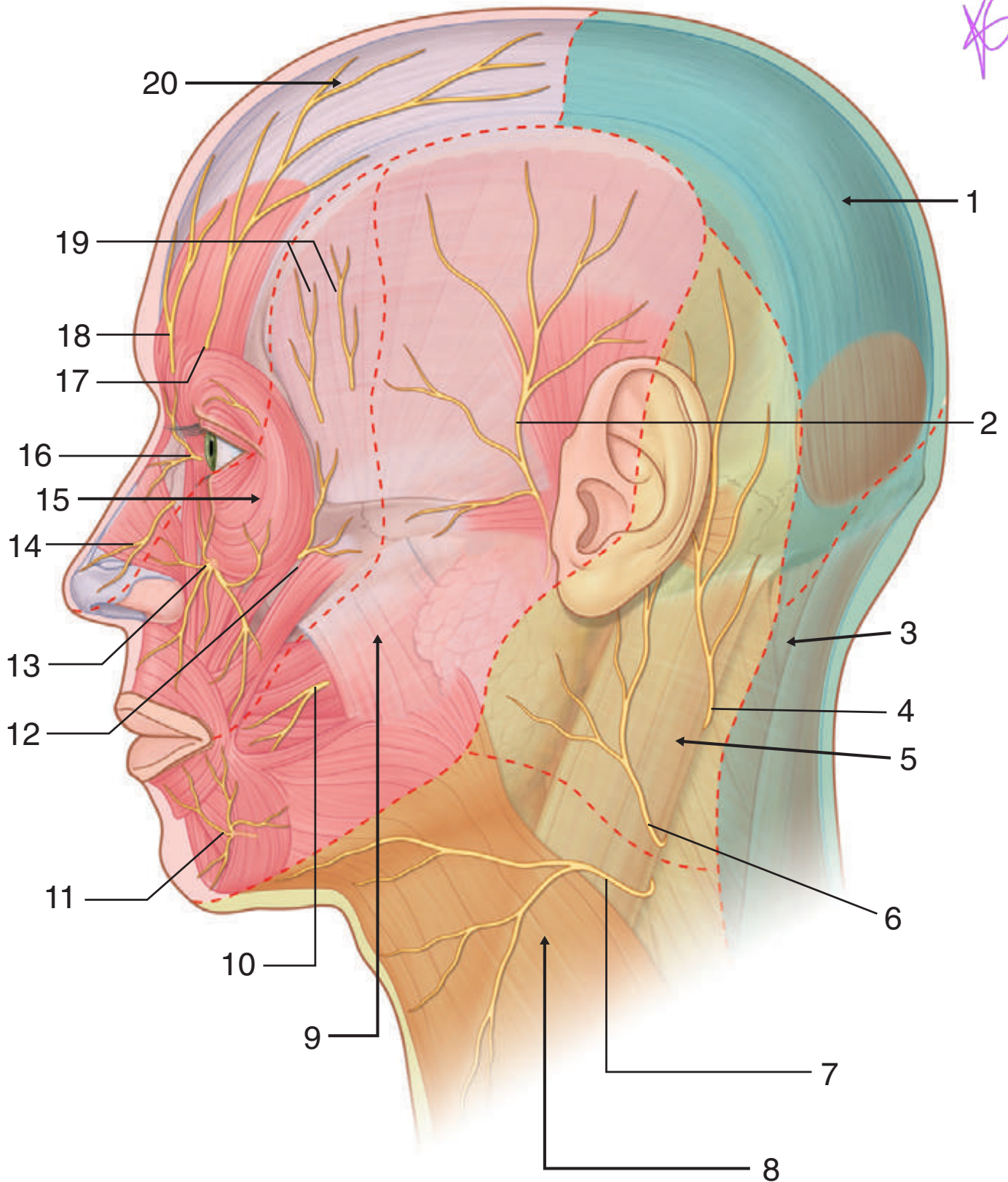
- **The most common tumors of the parotid gland are benign. Their importance is in relation to their anatomic position. The relationship of the tumor to the branches of the facial nerve (VII) must be defined because resection may damage the facial nerve (VII).**

Figure from Gray's Anatomy for Students, 3rd edition, p. 911.



Identify the indicated branches of the trigeminal nerve or the nerve supply to the area indicated in this lateral view of the face and neck.

16



SENSORY NERVES OF THE HEAD



1. Greater occipital
2. Auriculotemporal
3. Third occipital
4. Lesser occipital
5. Lesser occipital and greater auricular
6. Greater auricular
7. Transverse cervical
8. Transverse cervical
9. Mandibular [V₃]
10. Buccal
11. Mental
12. Zygomaticofacial
13. Infra-orbital
14. External nasal
15. Maxillary [V₂]
16. Infratrochlear
17. Supra-orbital
18. Supratrochlear
19. Zygomaticotemporal
20. Ophthalmic [V₁]

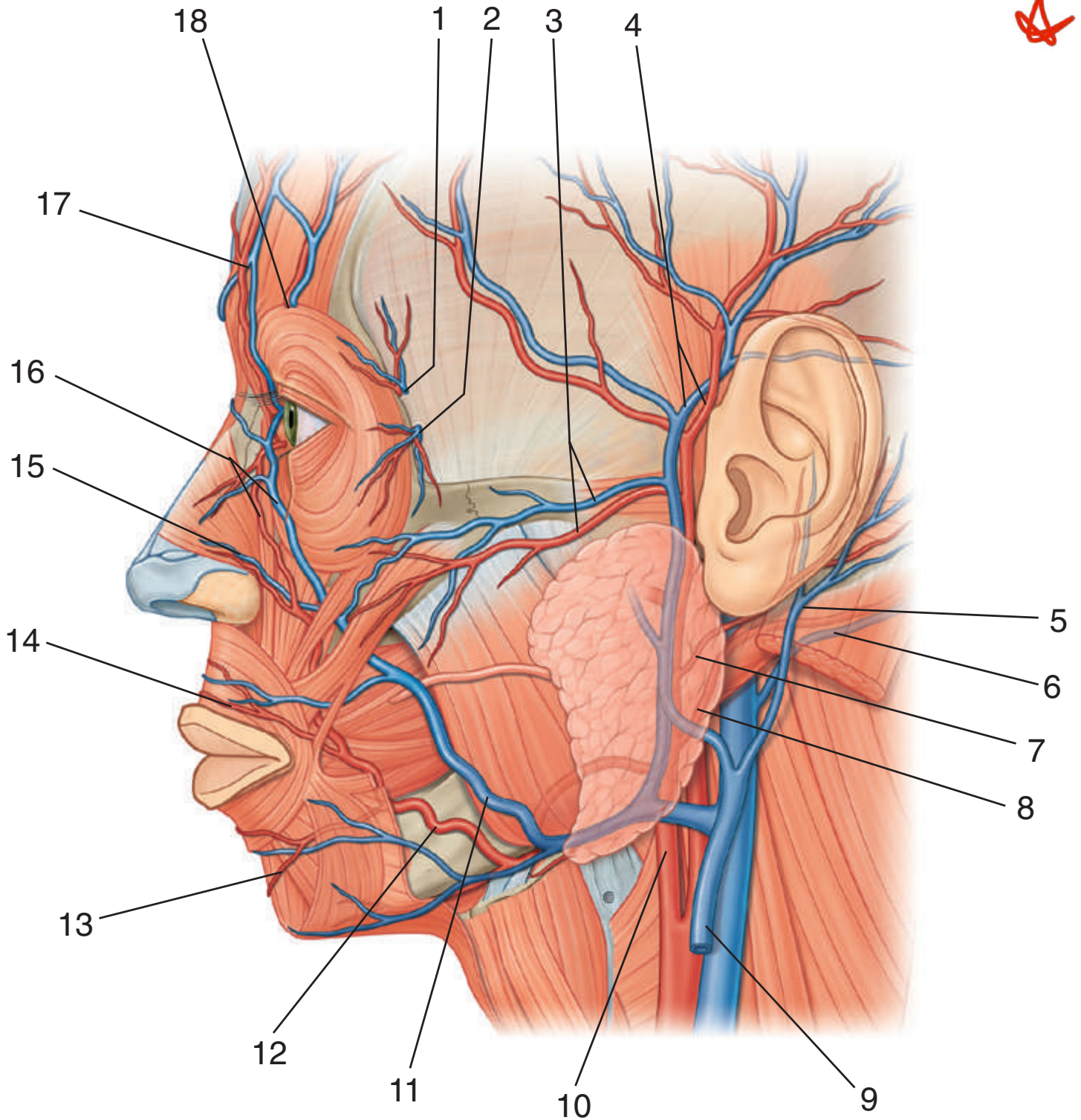
IN THE CLINIC:

- **Trigeminal neuralgia (tic douloureux) is a complex sensory disorder of the sensory portion of the trigeminal nerve (V). Typically the pain is in the region of the mandibular (V₃) and maxillary (V₂) nerves and is of sudden onset, is excruciating, and may be triggered by touching a sensitive region of skin.**

Figure from Gray's Anatomy for Students, 3rd edition, p. 915.



Identify the indicated arteries and veins in this lateral view of the face.





VESSELS OF THE LATERAL FACE



1. Zygomaticotemporal artery and vein
2. Zygomaticofacial artery and vein
3. Transverse facial artery and vein
4. Superficial temporal artery and vein
5. Posterior auricular vein
6. Occipital vein
7. Posterior auricular artery
8. Occipital artery
9. External jugular vein
10. External carotid artery
11. Facial vein
12. Facial artery
13. Inferior labial artery and vein
14. Superior labial artery and vein
15. Lateral nasal artery and vein
16. Angular artery and vein
17. Supratrochlear artery and vein
18. Supra-orbital artery and vein

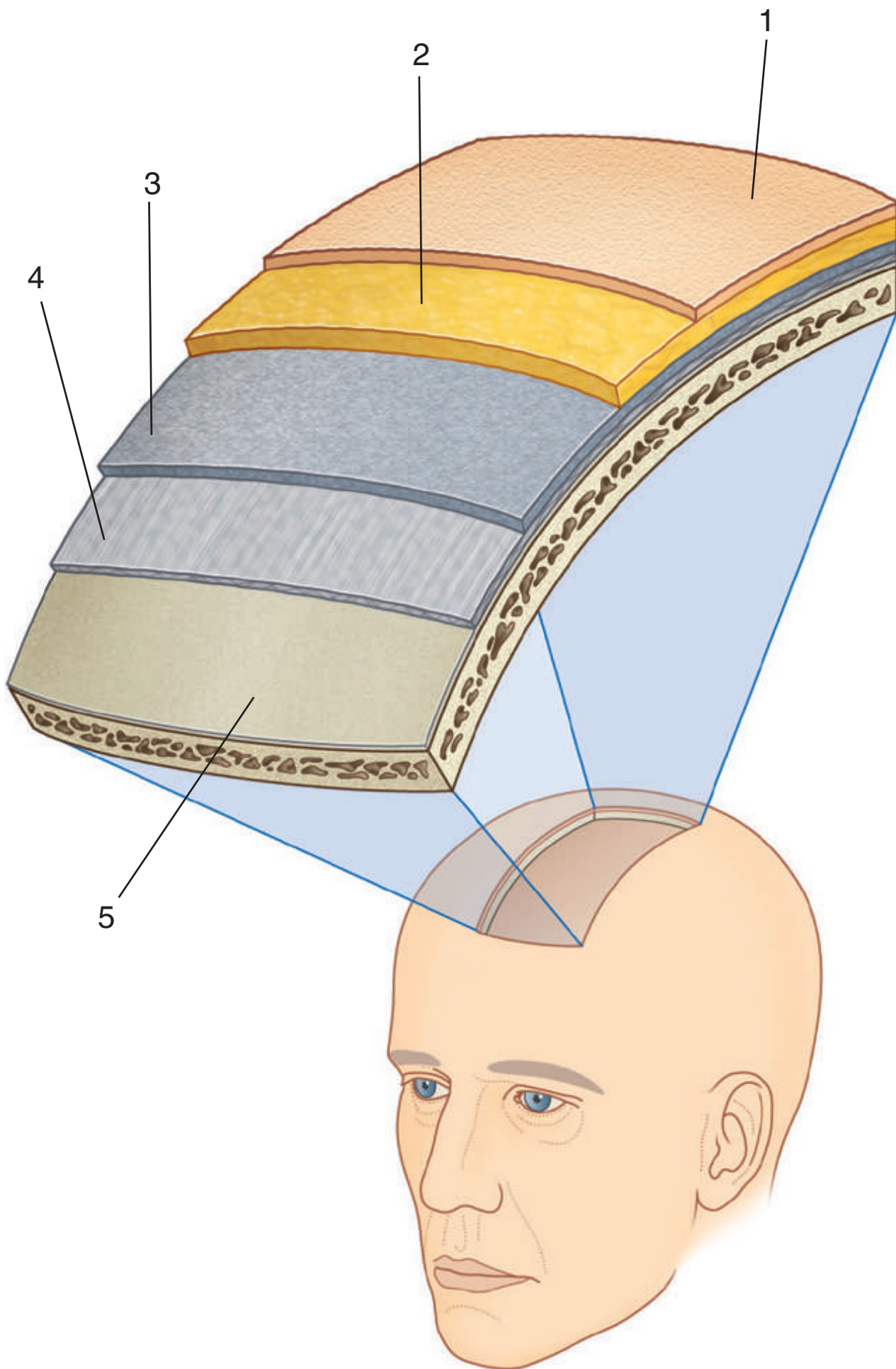
IN THE CLINIC:

- **As it crosses the face, the facial vein has numerous connections with venous channels passing into deeper regions of the head. Near the medial corner of the orbit it communicates with ophthalmic veins. In the area of the cheek it communicates with veins passing into the infra-orbital foramen. It also communicates with veins passing into deeper regions of the face. Because of these possible connections, infection of the face, primarily above the mouth, should be handled with great care to prevent the spread of infections in an intracranial direction.**

Figure from Gray's Anatomy for Students, 3rd edition, p. 917.



Identify the indicated layers of the scalp.





SCALP



1. Skin
2. Dense connective tissue
3. Aponeurotic layer
4. Loose connective tissue
5. Pericranium

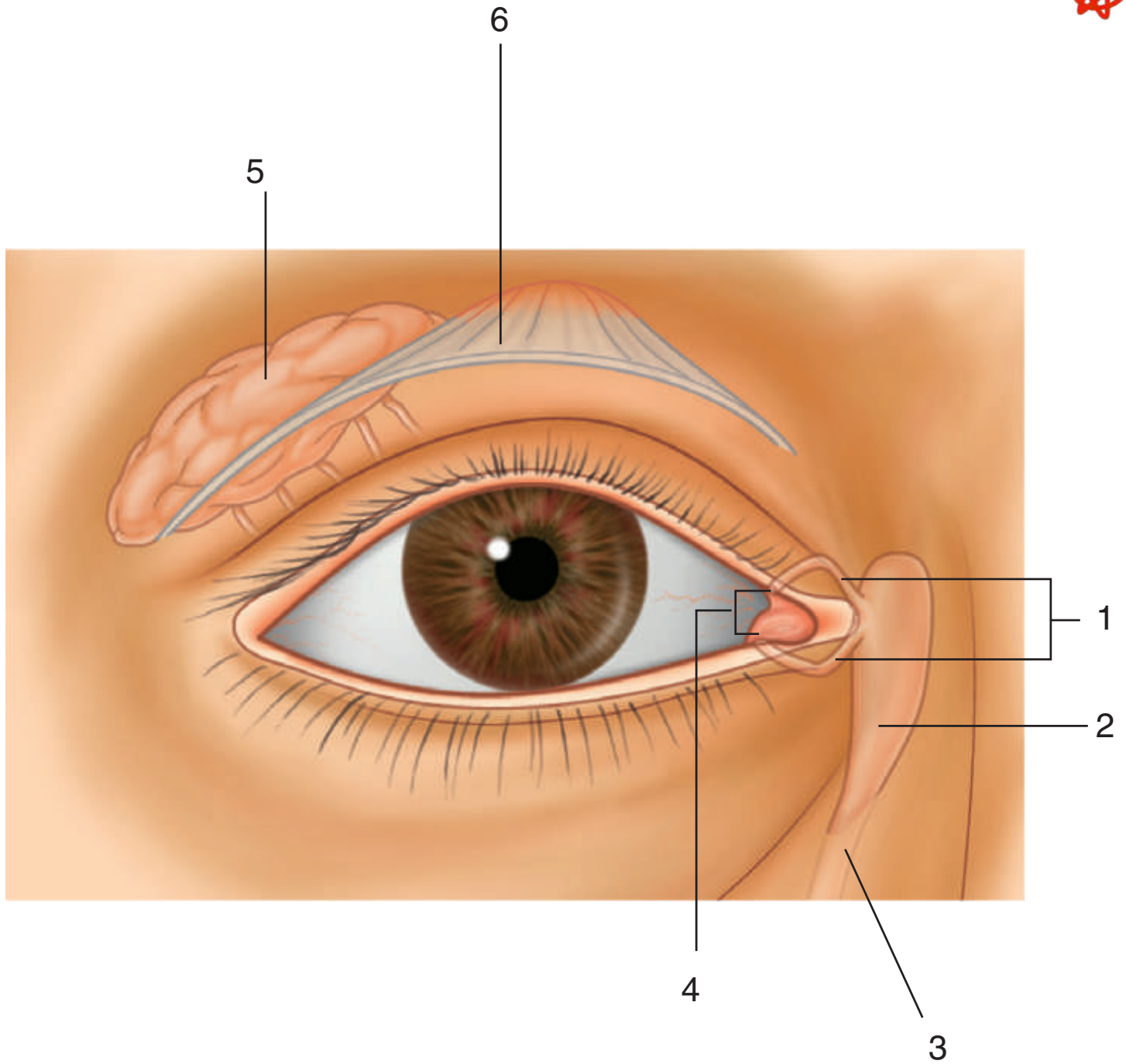
IN THE CLINIC:

- **The first three layers of the scalp form a single unit. This unit is sometimes referred to as the scalp proper and is the tissue torn away during serious scalping injuries.**
- **When the scalp is cut, the dense connective tissue surrounding the vessels tends to hold the cut vessels open. This results in profuse bleeding.**
- **Because of the consistency of the loose connective tissue, infections tend to localize and spread through this layer.**

Figure from Gray's Anatomy for Students, 3rd edition, p. 922.



Identify the indicated parts of the lacrimal apparatus and the related structures.





LACRIMAL APPARATUS



1. Lacrimal canaliculi
2. Lacrimal sac
3. Nasolacrimal duct
4. Puncta
5. Lacrimal gland
6. Tendon of levator palpebrae superioris muscle

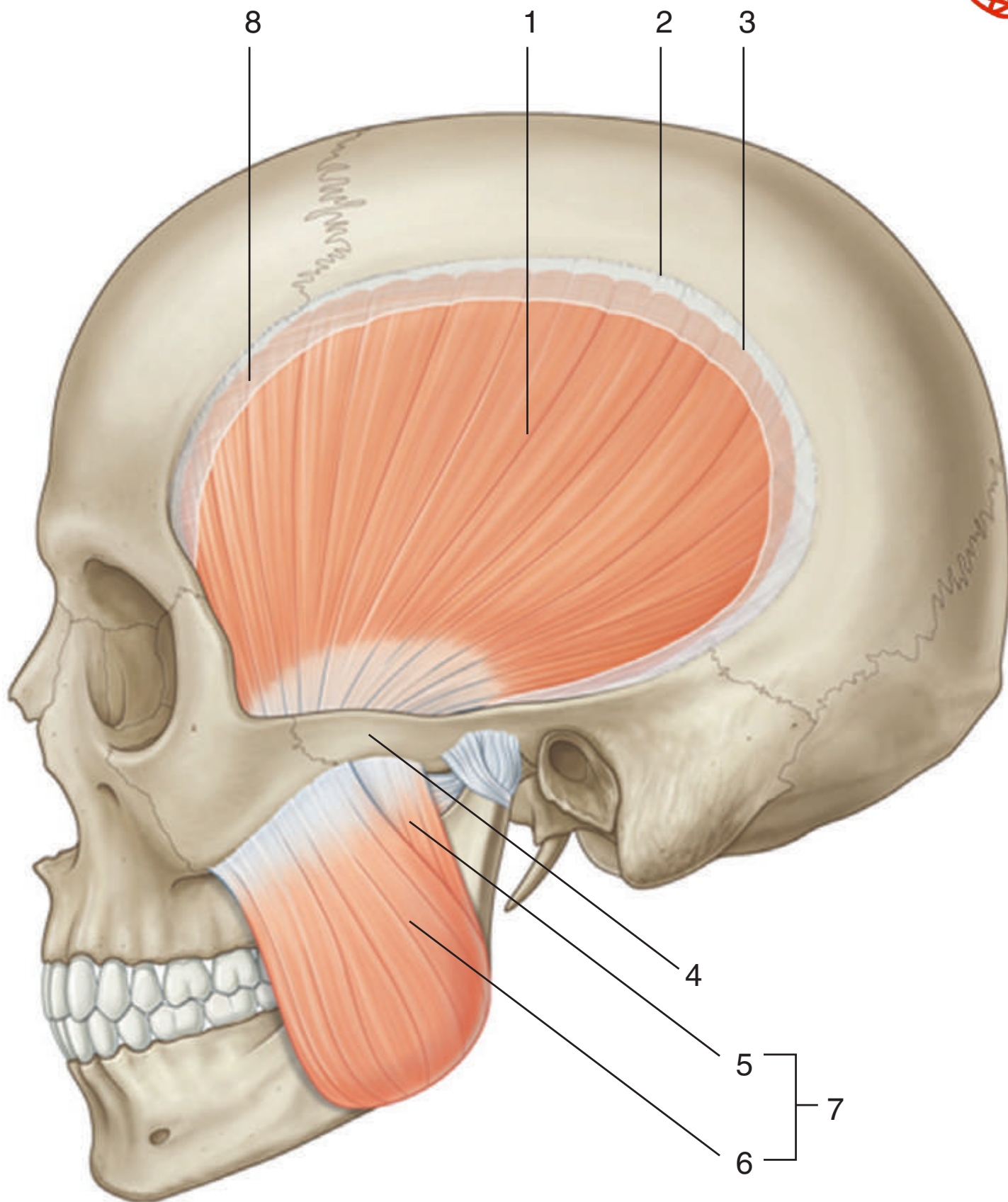
Figure from Gray's Anatomy for Students, 3rd edition, p. 932.



INFRATEMPORAL REGION: MUSCLES OF MASTICATION



Identify the indicated muscles.





INFRATEMPORAL REGION: MUSCLES OF MASTICATION

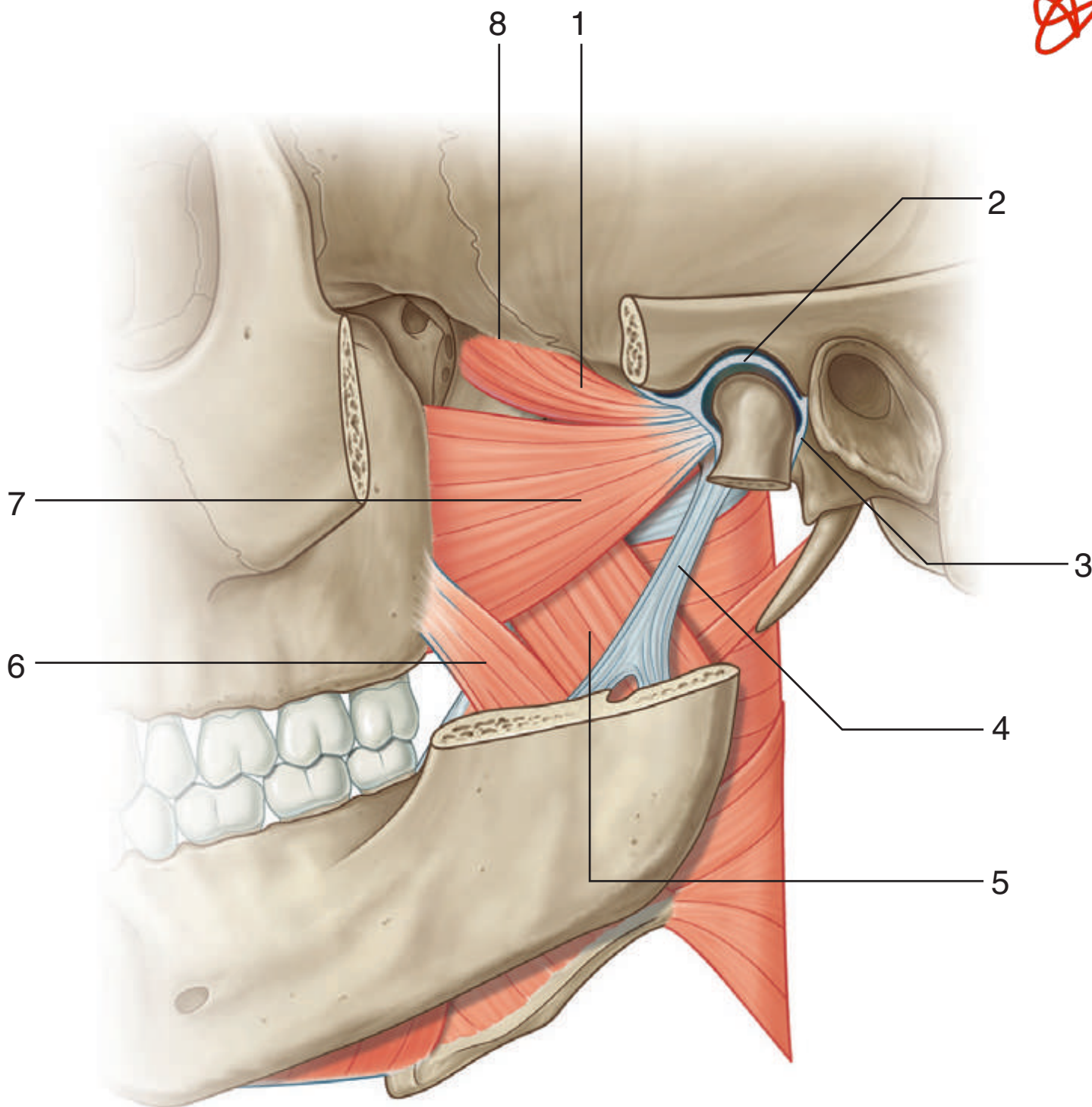


1. Temporalis muscle
2. Superior temporal line
3. Inferior temporal line
4. Zygomatic arch
5. Deep part (of masseter muscle)
6. Superficial part (of masseter muscle)
7. Masseter muscle
8. Cut temporal fascia

Figure from Gray's Atlas of Anatomy, 2nd edition, p. 526.



Identify the indicated structures.





INFRATEMPORAL REGION: MUSCLES



1. Upper head of lateral pterygoid muscle
2. Articular disc (of temporomandibular joint)
3. Capsule (of temporomandibular joint)
4. Sphenomandibular ligament
5. Deep head medial pterygoid muscle
6. Superficial head medial pterygoid muscle
7. Lower head lateral pterygoid muscle
8. Infratemporal crest

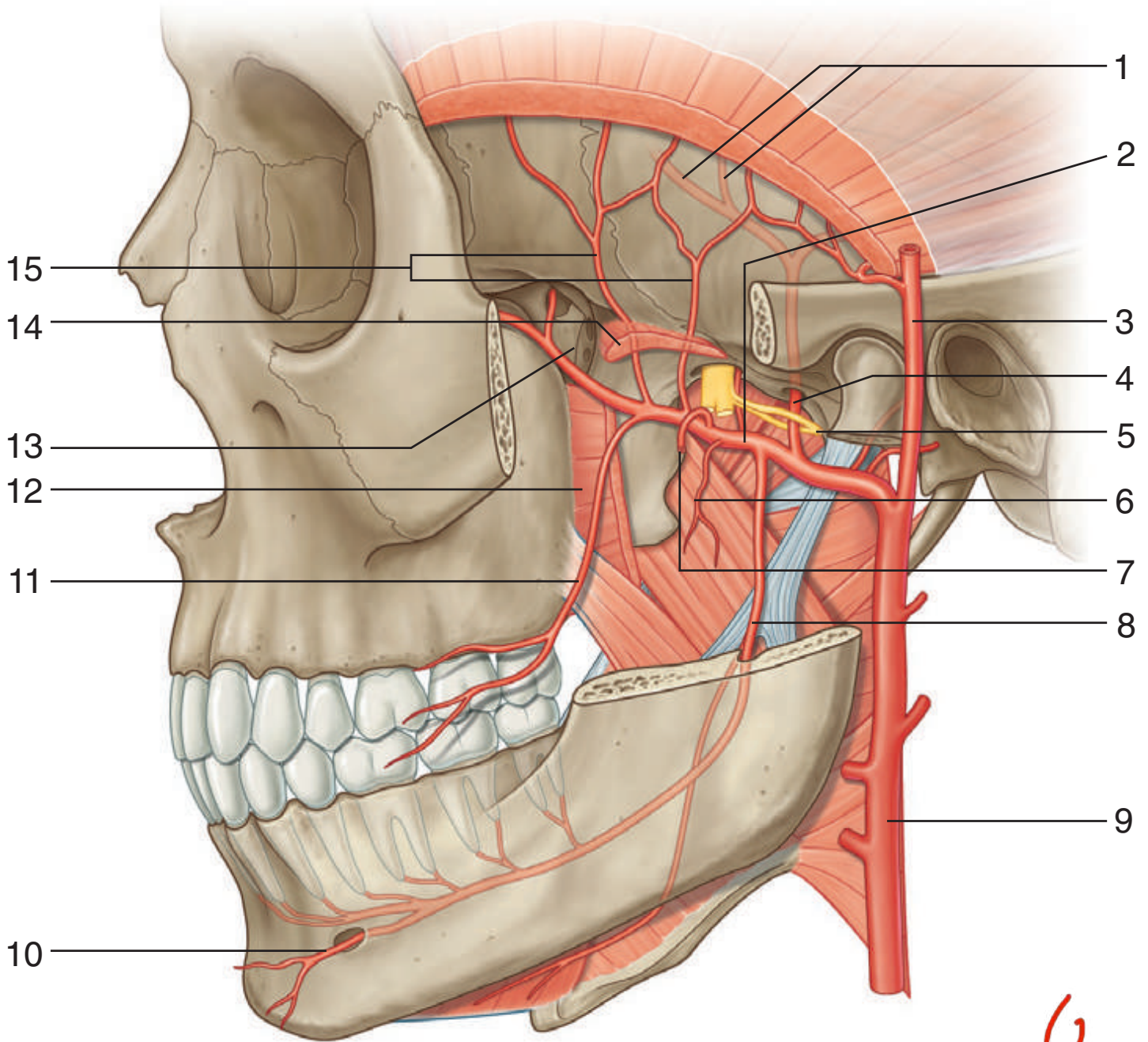
IN THE CLINIC:

- **The lateral pterygoid facilitates opening the mouth by pulling the head of the mandible forward onto the articular tubercle of the temporal bone. In a lesion to V₃ on one side, the anterior aspect of the mandible points to the side of the lesion when the mouth is opened.**

Figure from Gray's Anatomy for Students, 3rd edition, p. 983.



Identify the indicated arteries and related structures.



Handwritten red text: "فواجر" (Fawajir)



INFRATEMPORAL REGION: ARTERIES



1. Branches of middle meningeal artery in cranial cavity
2. Maxillary artery
3. Superficial temporal artery
4. Middle meningeal artery
5. Auriculotemporal nerve
6. Pterygoid artery
7. Artery to masseter (cut)
8. Inferior alveolar artery
9. External carotid
10. Mental artery
11. Buccal artery
12. Lower head of lateral pterygoid (cut) muscle
13. Pterygopalatine fossa
14. Upper head of lateral pterygoid (cut) muscle
15. Deep temporal arteries

IN THE CLINIC:

- **The middle meningeal artery is a branch of the maxillary artery in the infratemporal fossa. Damage to the middle meningeal artery in the cranial cavity can lead to an extradural (epidural) hematoma.**
- **In addition to supplying structures in the infratemporal and temporal regions, the maxillary artery supplies all the upper teeth, all the lower teeth, the hard and soft palates, and much of the nasal cavity.**

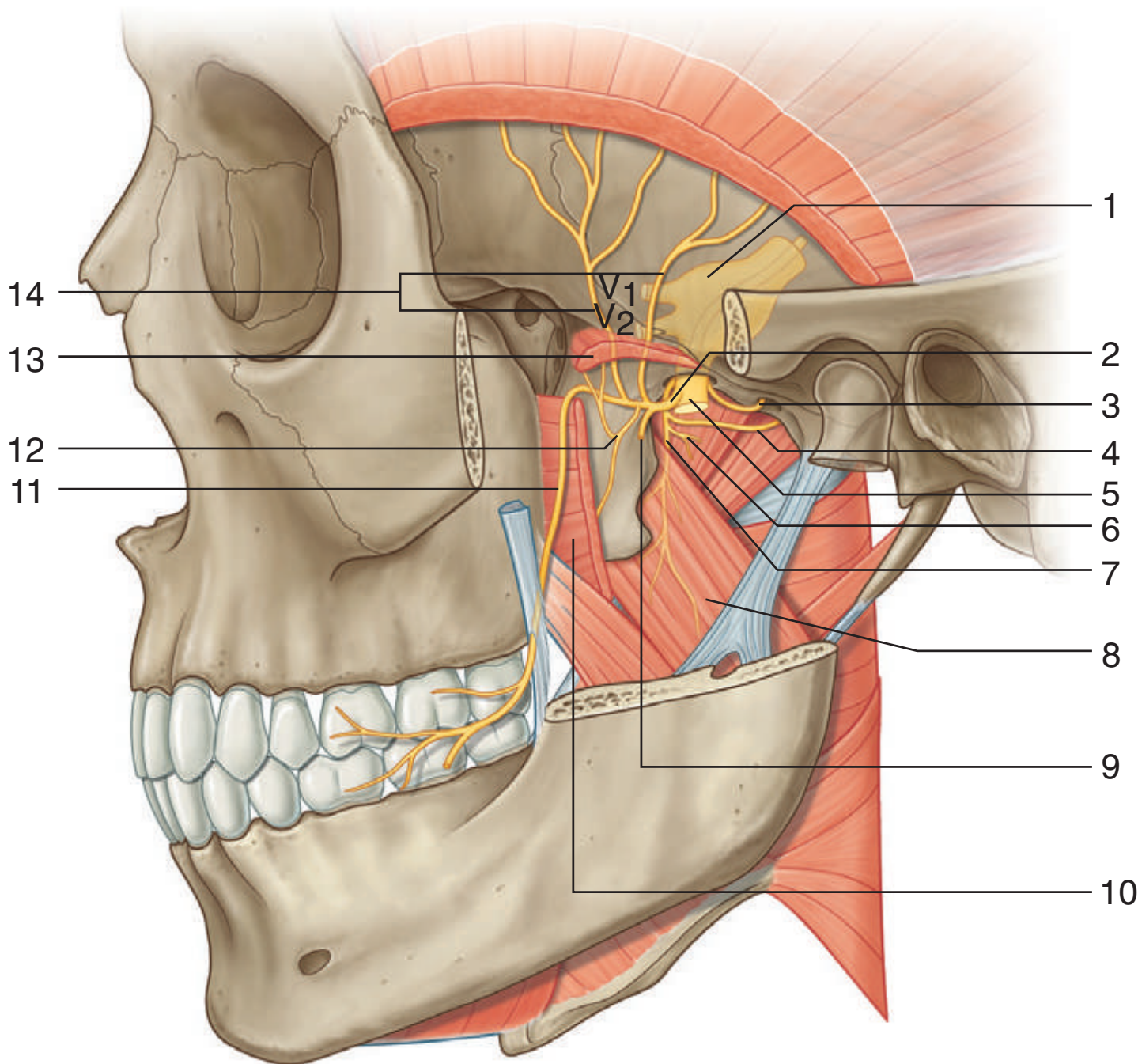
Figure from Gray's Anatomy for Students, 3rd edition, p. 985.



INFRATEMPORAL REGION: NERVES, PART 1



Identify the indicated nerves and related structures.



الحنك

INFRATEMPORAL REGION: NERVES, PART 1



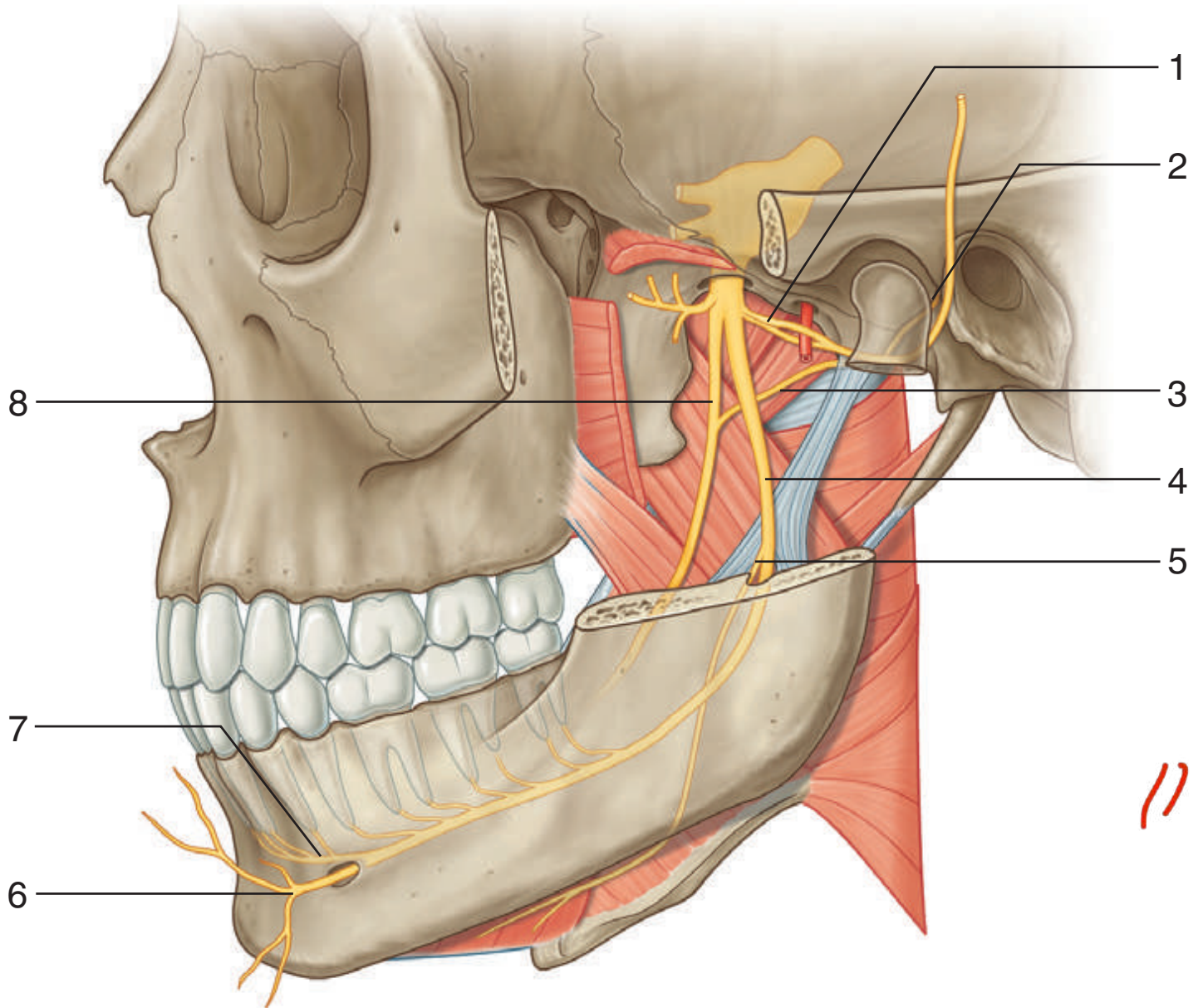
1. Trigeminal ganglion
2. Anterior trunk (of V₃)
3. Meningeal nerve
4. Branch to tensor tympani
5. Posterior trunk (of V₃)
6. Branch to tensor veli palatini
7. Nerve to medial pterygoid
8. Deep head medial pterygoid
9. Masseteric nerve
10. Lower head lateral pterygoid (cut)
11. Buccal nerve
12. Nerve to lateral pterygoid
13. Upper head lateral pterygoid (cut)
14. Deep temporal nerves

IN THE CLINIC:

- **Except for the buccal nerve, which is sensory, the branches of the anterior trunk of the mandibular nerve are motor and supply the muscles of mastication as well as the tensor tympani and tensor veli palatini. The buccal nerve often is anesthetized during dental procedures because it innervates gingiva on the buccal side of the lower molar teeth.**

Figure from Gray's Anatomy for Students, 3rd edition, p. 984.

Identify the indicated nerves and related structures.



الحنك



INFRATEMPORAL REGION: NERVES, PART 2



1. Auriculotemporal nerve
2. Petrotympanic fissure
3. Chorda tympani nerve
4. Inferior alveolar nerve
5. Nerve to mylohyoid
6. Mental nerve
7. Incisive nerve
8. Lingual nerve

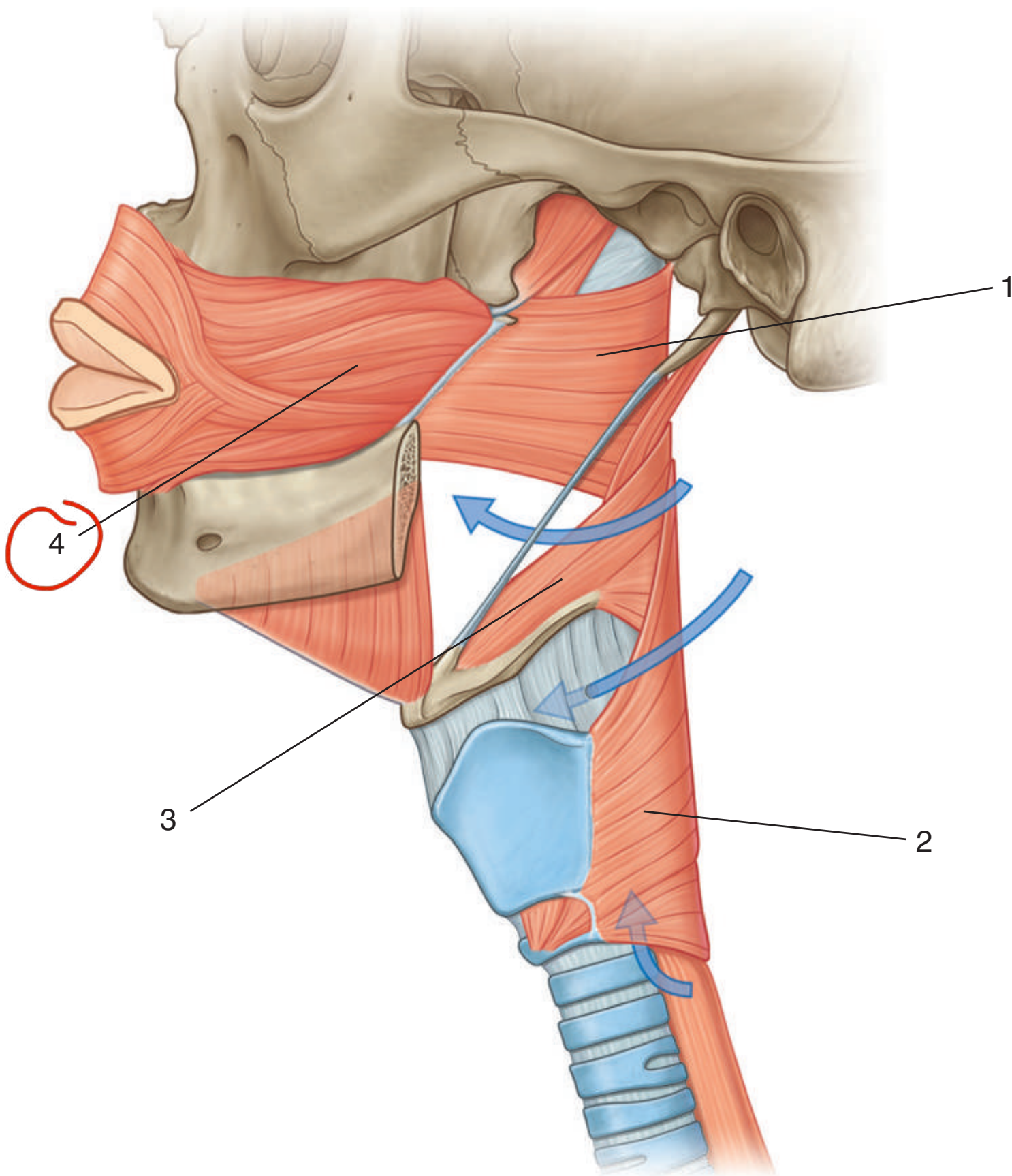
IN THE CLINIC:

- **Except for the nerve to the mylohyoid muscle, which is motor and originates from the inferior alveolar nerve, branches of the posterior trunk of the mandibular nerve are general sensory.**
- **The inferior alveolar nerve is sensory to all lower teeth and to gingiva associated with the buccal side of the incisor, canine, and premolars. The buccal gingiva of the molars is innervated by the buccal nerve. The lingual nerve is, in general, sensory to the tongue and the lingual gingiva of all the lower teeth. Anesthesia of the lower teeth and associated gingiva can be achieved by injecting anesthetic into the infratemporal fossa lateral to the sphenomandibular ligament. This anesthetizes the inferior alveolar and lingual nerves. A separate injection is used to anesthetize the buccal nerve.**

Figure from Gray's Anatomy for Students, 3rd edition, p. 985.



Identify the indicated muscles.





PHARYNX: LATERAL VIEW OF MUSCLES



1. Superior constrictor
2. Inferior constrictor
3. Middle constrictor
4. Buccinator

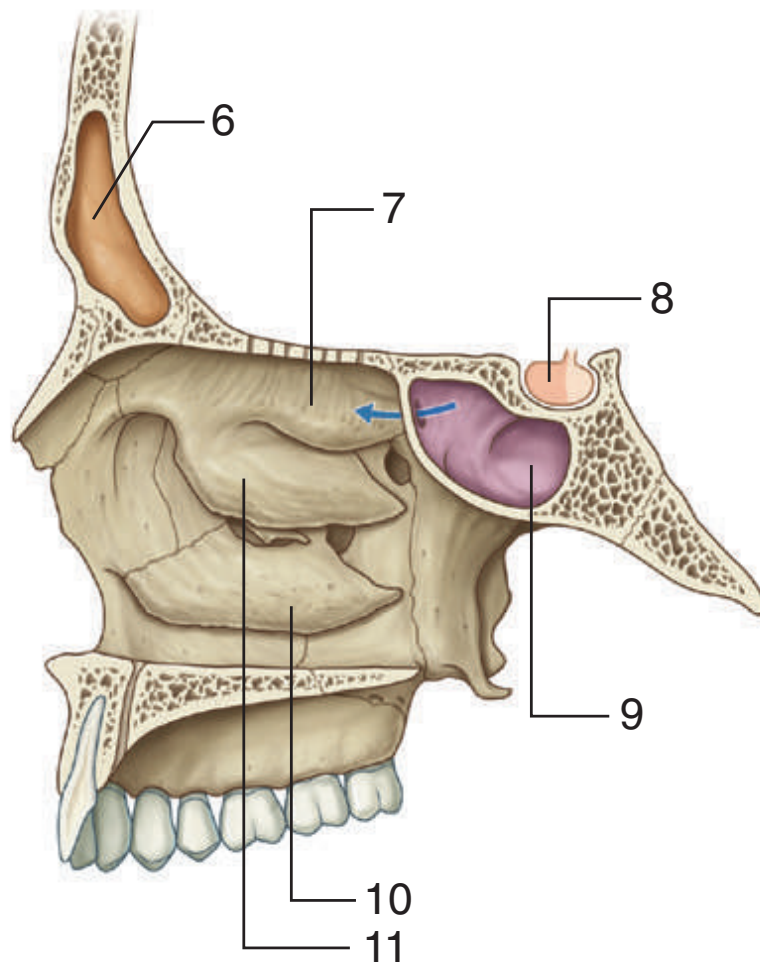
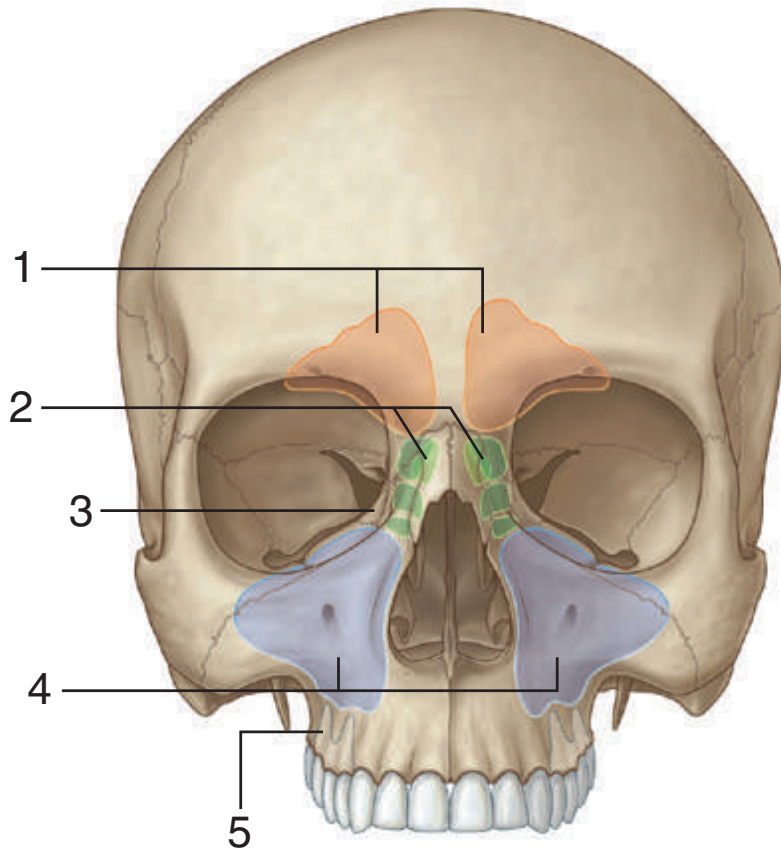
IN THE CLINIC:

- **The buccinator muscle of the cheek (a muscle of facial expression) and the superior constrictor of the pharynx are joined together by the pterygomandibular raphe.**

Figure from Gray's Anatomy for Students, 3rd edition, p. 1046.



Identify the indicated paranasal sinuses and related structures.





NASAL CAVITY: PARANASAL SINUSES



1. Frontal sinuses
2. Ethmoidal cells
3. Orbital plate of ethmoid bone
4. Maxillary sinuses
5. Roots of posterior upper molars
6. Frontal sinus
7. Superior concha
8. Pituitary gland
9. Sphenoidal sinus
10. Inferior concha
11. Middle concha

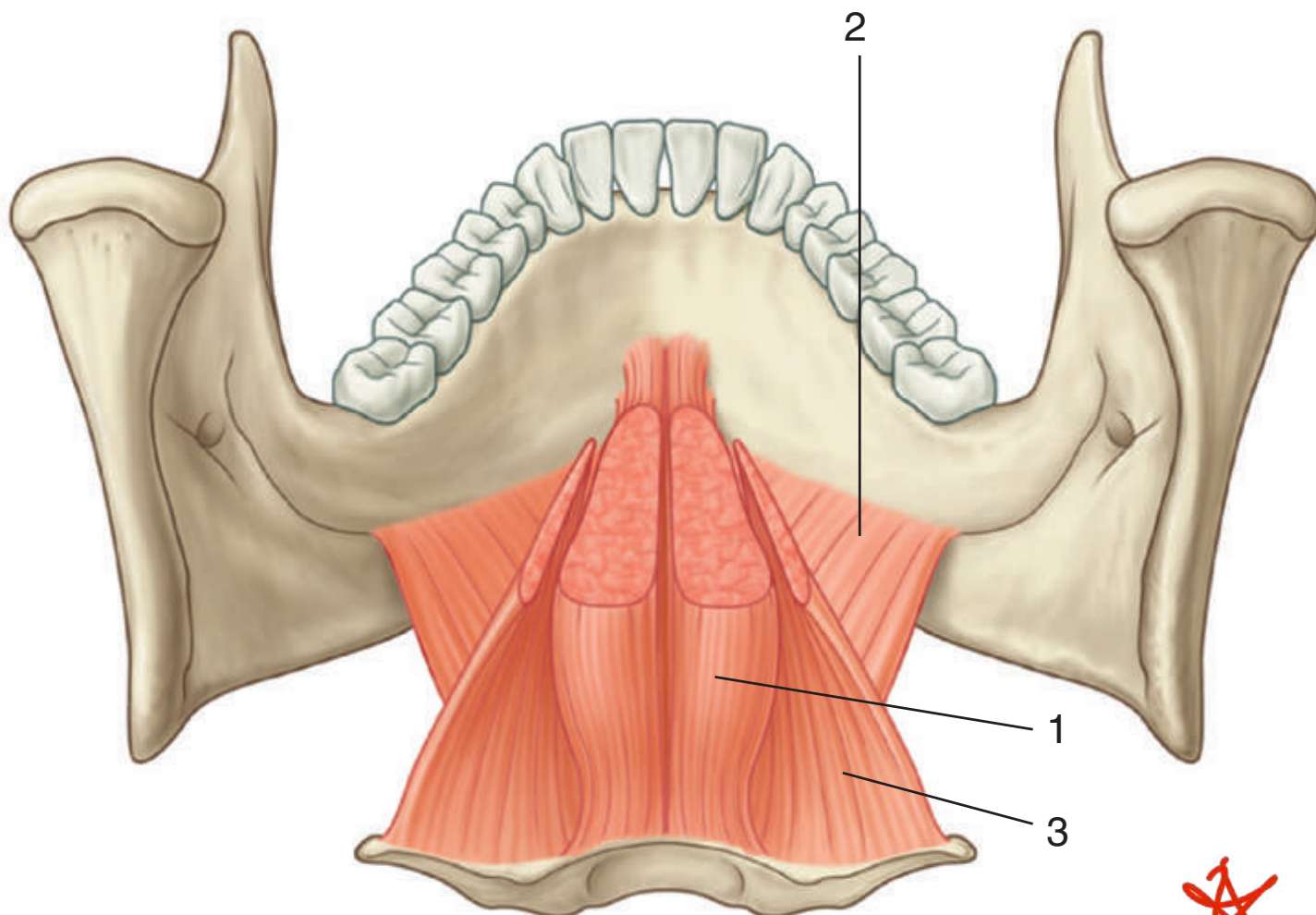
IN THE CLINIC:

- **The paranasal sinuses are lined by a mucus-secreting respiratory epithelium. The sinuses normally drain into the nasal cavities.**
- **Sinusitis is an infection of the sinuses.**
- **The maxillary sinuses are related to the roots of the upper molar teeth. Abscesses in these teeth can erode into the related sinus. Removal of the molars can generate a communication between the oral cavity and the related maxillary sinus—an “oronasal” fistula.**
- **The sphenoidal sinus and its bony walls separate the nasal cavity from the pituitary gland. The pituitary gland can surgically be accessed through the nasal cavity and sphenoidal sinus.**

Figure from Gray's Anatomy for Students, 3rd edition, pp. 1074 and 1075.



Identify the indicated muscles.





ORAL CAVITY: FLOOR



1. Genioglossus
2. Mylohyoid
3. Hyoglossus

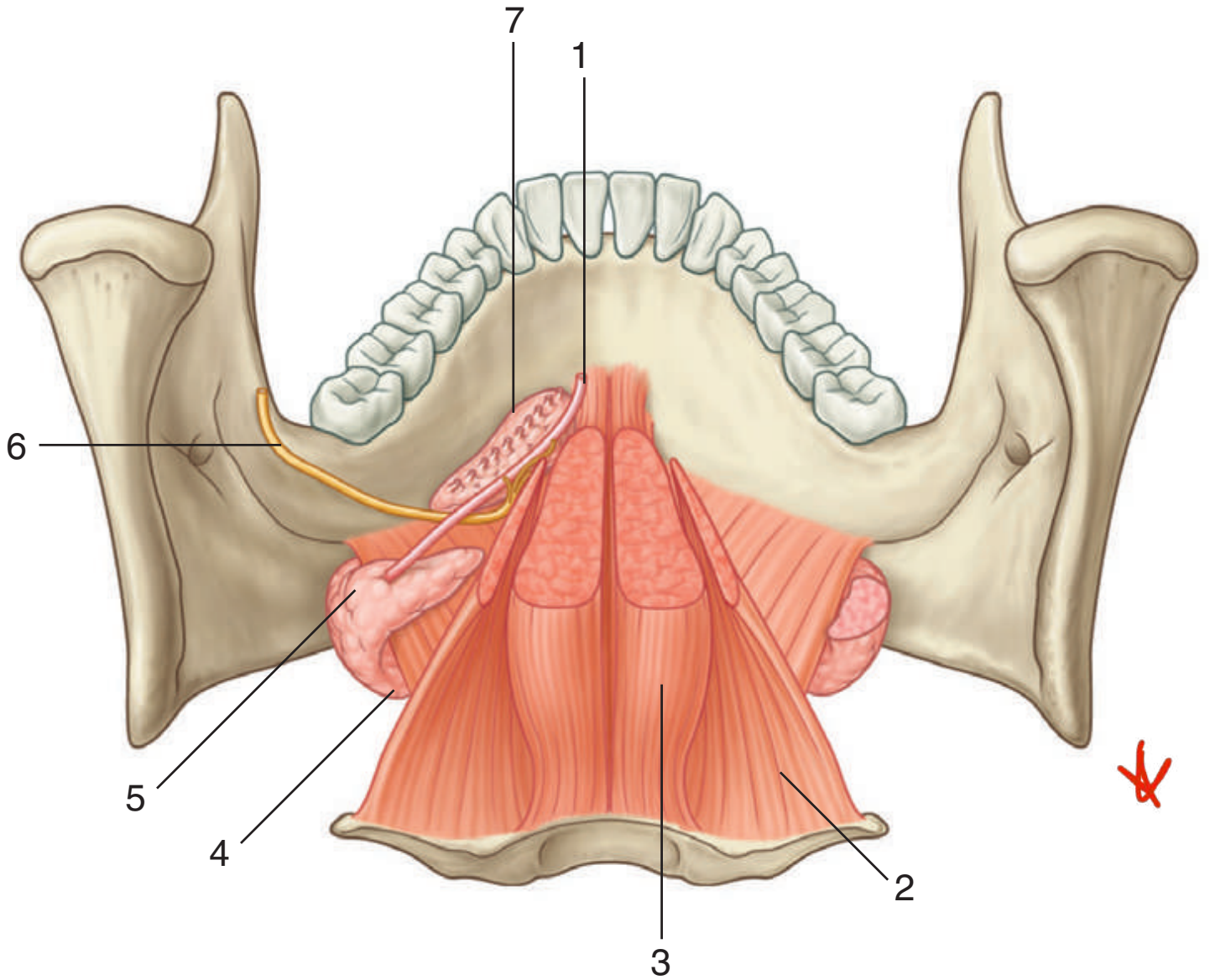
IN THE CLINIC:

- **The mylohyoid muscles together form a muscular diaphragm that defines the inferior limit of the floor of the oral cavity. The muscles on a patient can be palpated between two fingers—one finger placed inside the oral cavity lateral to the tongue and the other placed externally medial to the mandible on the same side.**
- **The genioglossus and hyoglossus muscles are extrinsic muscles of the tongue. The function of the genioglossus muscle is used to test the function of the hypoglossal nerve. A patient is asked to stick his or her tongue out. If the hypoglossal nerve on one side is not functioning, the tip of the tongue when protruded will point to the side where the nerve is affected.**

Figure from Gray's Anatomy for Students, 3rd edition, p. 1103.



Identify the indicated structures.





ORAL CAVITY: GLANDS



1. Submandibular duct
2. Hyoglossus muscle
3. Genioglossus muscle
4. Superficial submandibular gland
5. Deep submandibular gland
6. Lingual nerve
7. Sublingual gland

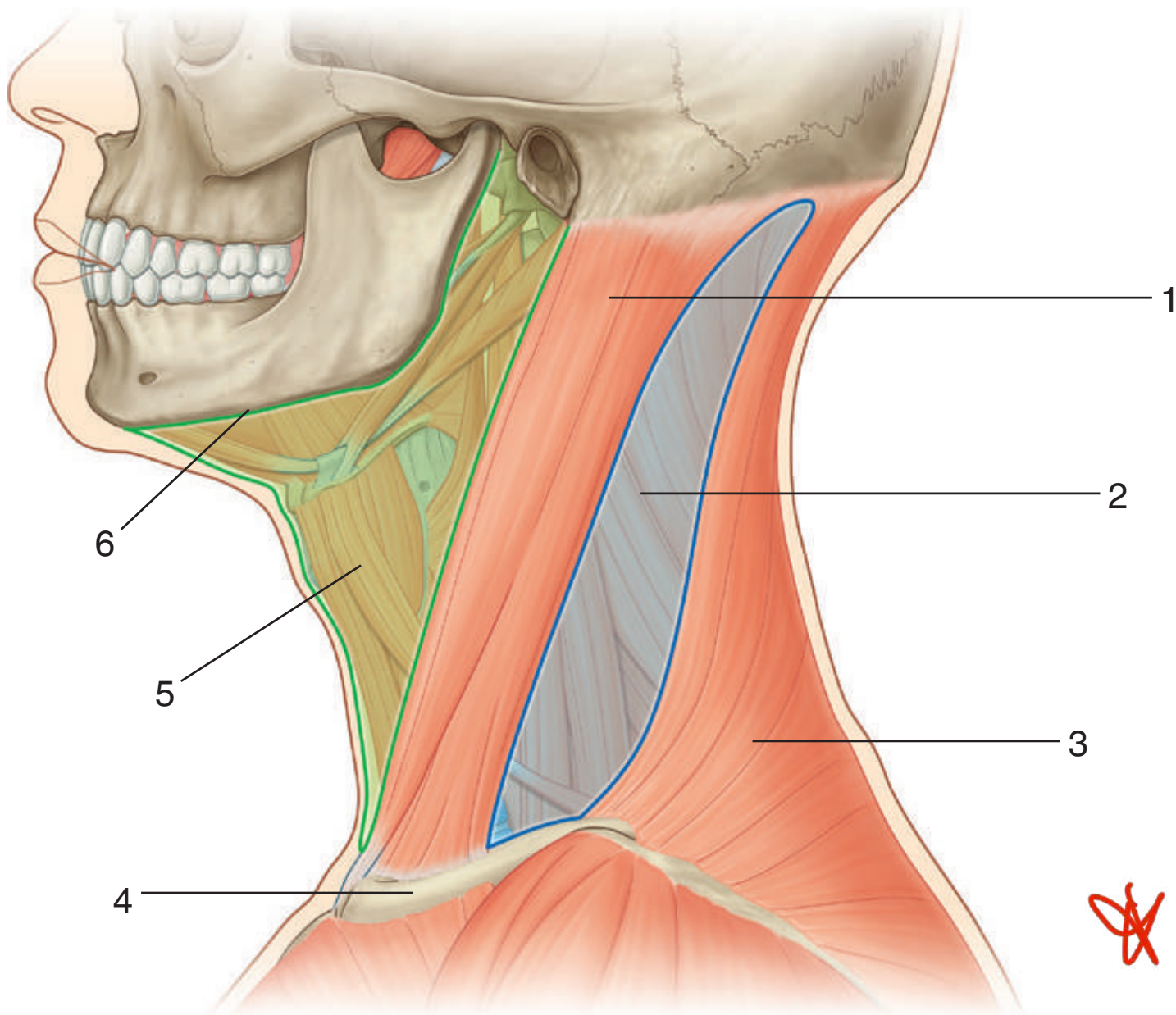
IN THE CLINIC:

- **The sublingual gland and opening of the submandibular duct can be visualized in the “open mouth” in the floor of the oral cavity.**
- **The submandibular duct can become blocked, causing pain, particularly when moving the tongue or when stimulating salivation.**

Figure from Gray's Anatomy for Students, 3rd edition, p. 1103.



Identify the triangles of the neck and features related to their boundaries.





NECK: TRIANGLES



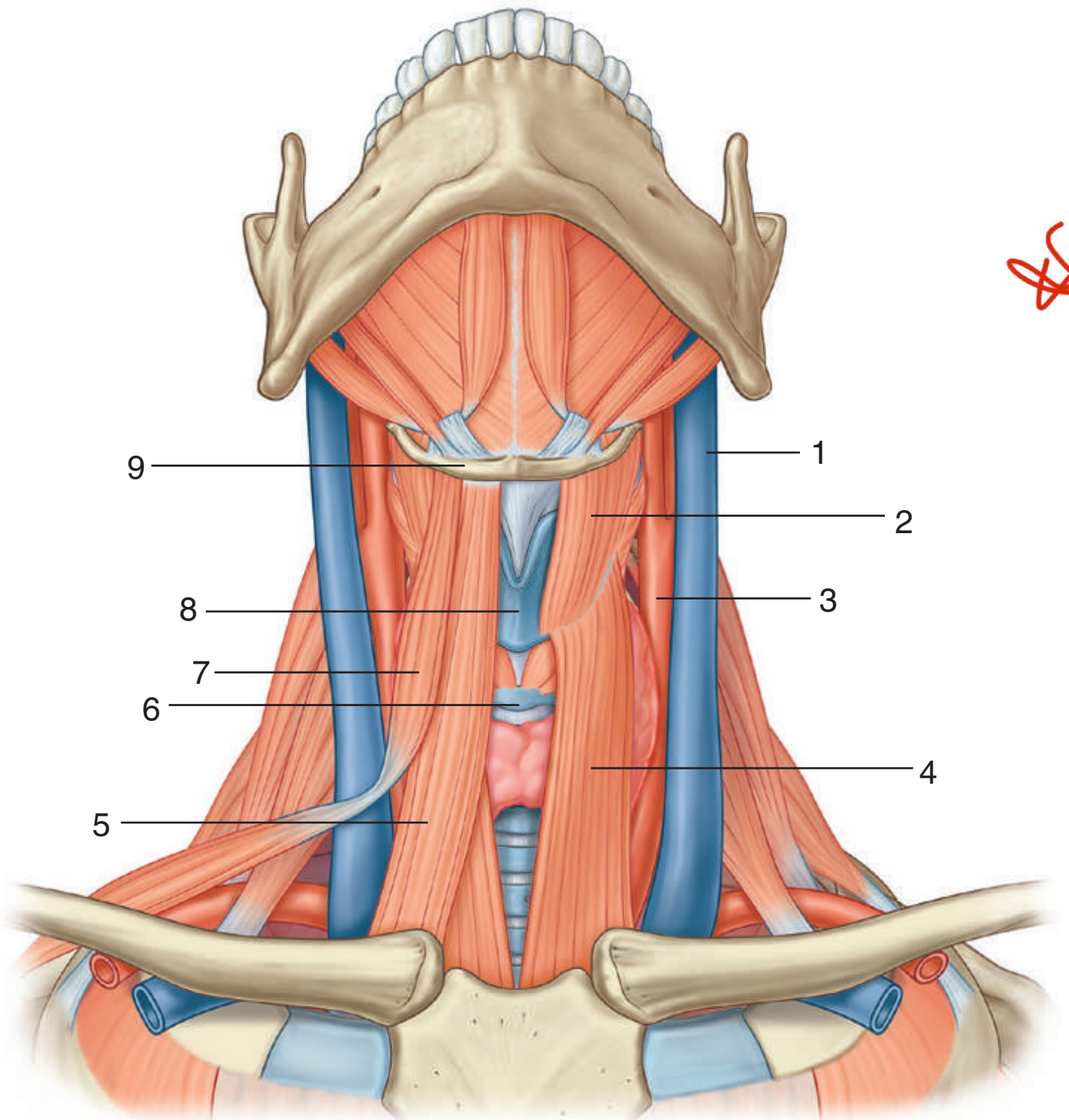
1. Sternocleidomastoid muscle
2. Posterior triangle
3. Trapezius muscle
4. Clavicle
5. Anterior triangle
6. Inferior border of mandible

IN THE CLINIC:

- **The boundaries of the anterior triangle are the anterior border of the sternocleidomastoid muscle, the inferior border of the mandible, and the midline of the neck. The boundaries of the posterior triangle are the posterior border of the sternocleidomastoid muscle, the anterior border of the trapezius muscle, and the middle one third of the clavicle.**

Figure from Gray's Anatomy for Students, 3rd edition, p. 1000.

Identify the indicated structures.





NECK: ANTERIOR TRIANGLE, INFRAHYOID MUSCLES



1. Internal jugular vein
2. Thyrohyoid muscle
3. Common carotid artery
4. Sternothyroid muscle
5. Sternohyoid muscle
6. Cricoid cartilage
7. Omohyoid muscle
8. Thyroid cartilage
9. Hyoid bone

IN THE CLINIC:

- **The four infrahyoid muscles are in the muscular triangle. They attach the hyoid bone to inferior structures and depress the hyoid bone. They also provide a stable point of attachment for the suprahyoid muscles.**

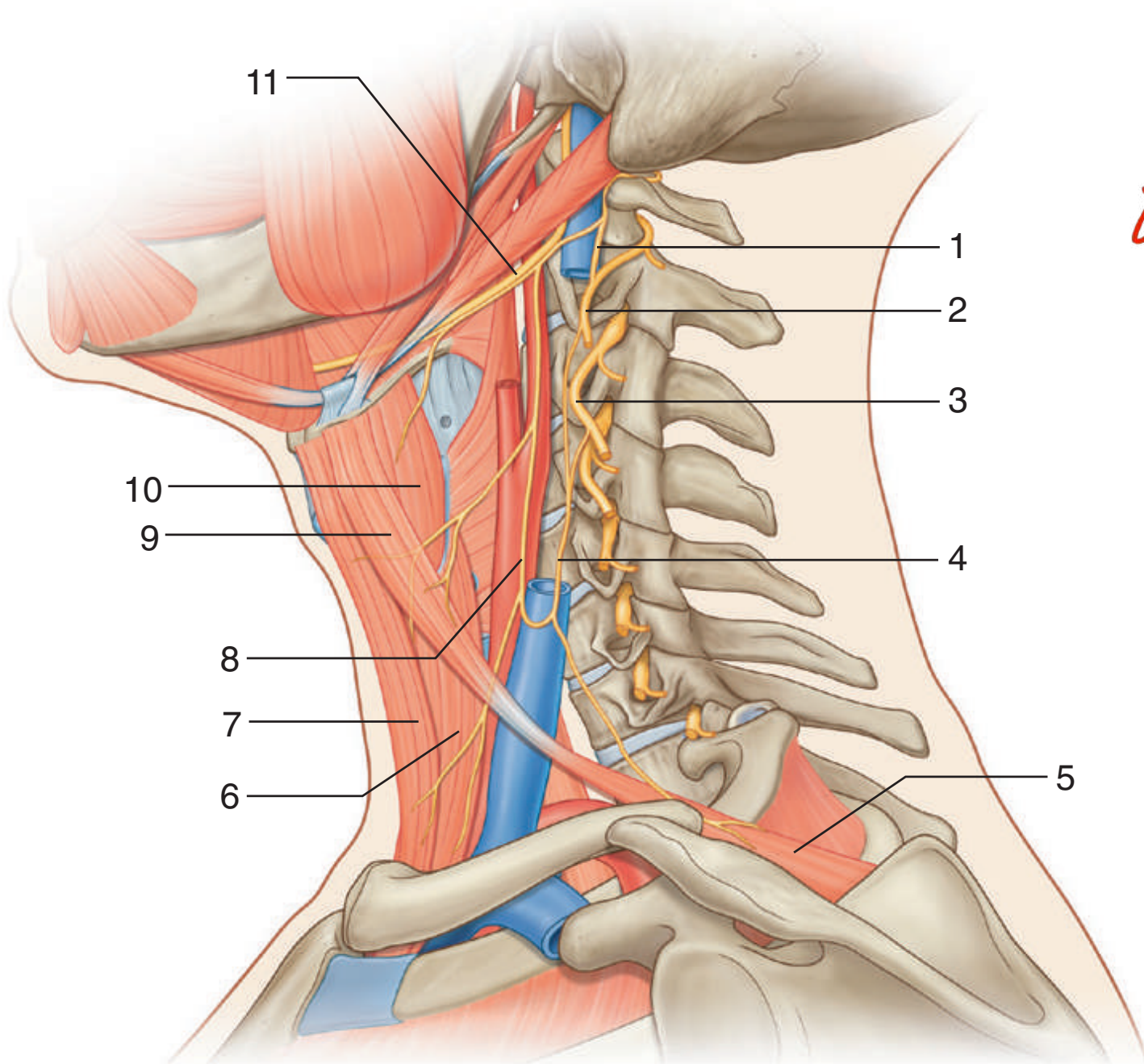
Figure from Gray's Anatomy for Students, 3rd edition, p. 1009.



NECK: ANTERIOR TRIANGLE, HYPOGLOSSAL NERVE, AND ANSA CERVICALIS



Identify the indicated structures and nerves.





NECK: ANTERIOR TRIANGLE, HYPOGLOSSAL NERVE, AND ANSA CERVICALIS



1. C1
2. C2
3. C3
4. Inferior root of ansa cervicalis
5. Omohyoid muscle (inferior belly)
6. Sternothyroid muscle
7. Sternohyoid muscle
8. Superior root of ansa cervicalis
9. Omohyoid muscle (superior belly)
10. Thyrohyoid muscle
11. Hypoglossal nerve (XII)

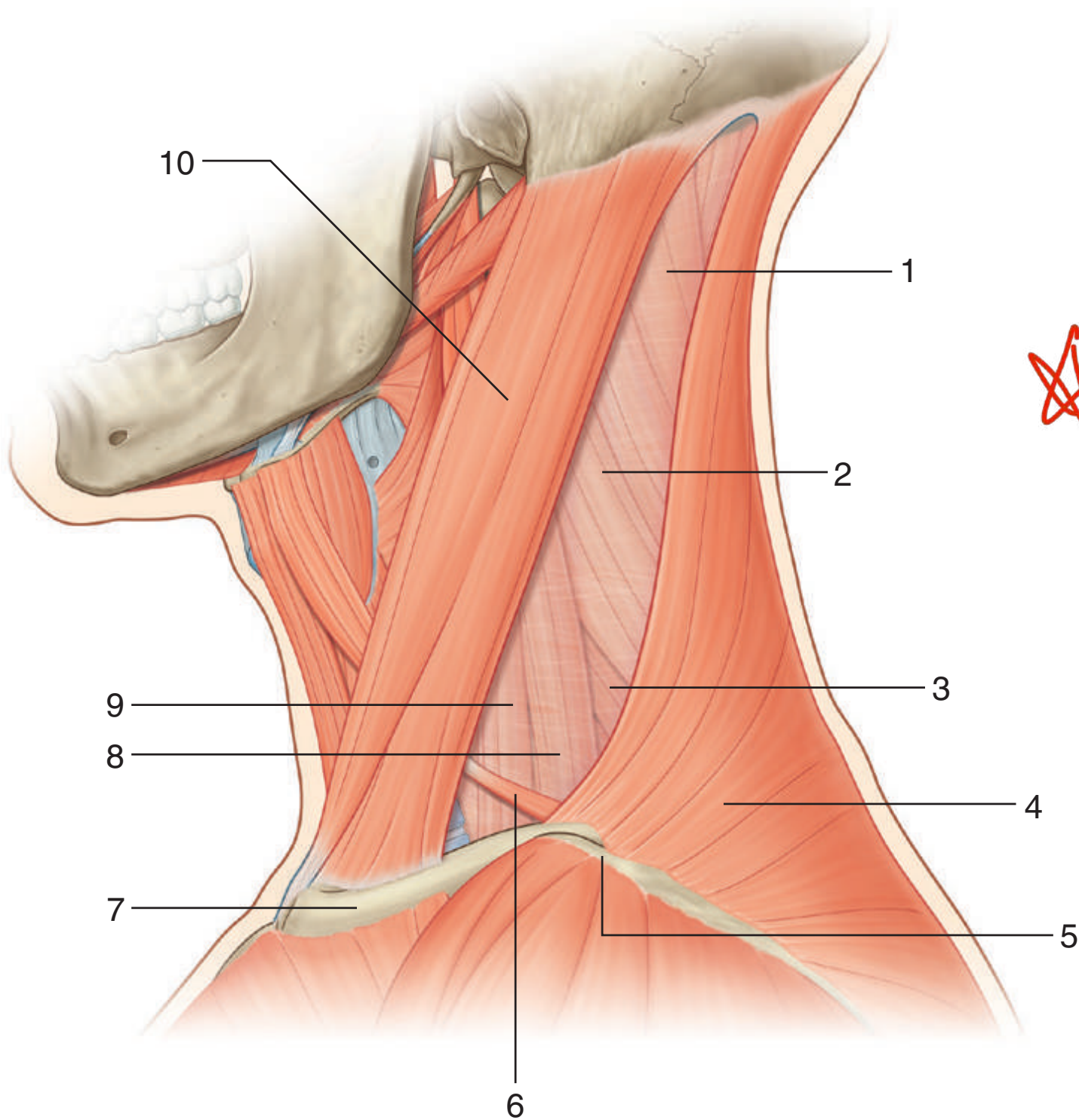
IN THE CLINIC:

- **The hypoglossal nerve (XII), which supplies the tongue, does not give off any branches as it passes through the anterior triangle of the neck.**
- **The ansa cervicalis is a loop of nerve fibers from cervical nerves C1 to C3 that innervate the muscles in the anterior triangle of the neck. The superior root is from C1 and innervates the thyrohyoid muscle, the superior belly of the omohyoid muscle, and the upper parts of the sternohyoid and sternothyroid muscles. The inferior root is from C2 and C3 and innervates the inferior belly of the omohyoid muscle and the lower parts of the sternohyoid and sternothyroid muscles.**

Figure from Gray's Anatomy for Students, 3rd edition, p. 1016.



Identify the indicated muscles and related structures of the posterior triangle of the neck.





NECK: POSTERIOR TRIANGLE, MUSCLES



1. Splenius capitis muscle
2. Levator scapulae muscle
3. Posterior scalene muscle
4. Trapezius muscle
5. Acromion of scapula
6. Inferior belly of omohyoid muscle
7. Clavicle
8. Middle scalene muscle
9. Anterior scalene muscle
10. Sternocleidomastoid muscle

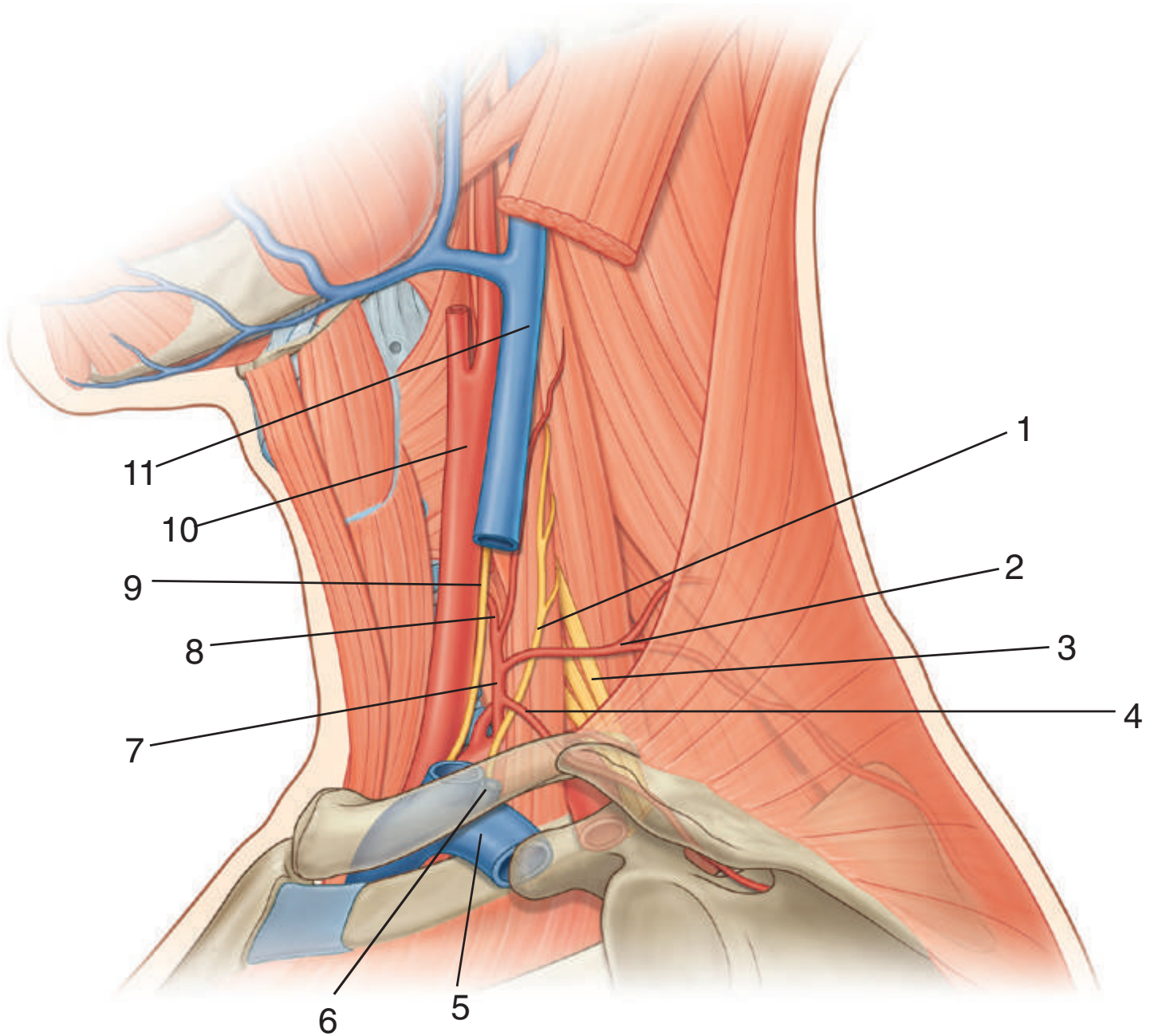
IN THE CLINIC:

- **The roof of the posterior triangle consists of an investing layer of cervical fascia that surrounds the sternocleidomastoid and trapezius muscles.**
- **The floor of the posterior triangle is covered by the prevertebral layer of cervical fascia and consists of the following muscles, beginning superiorly: splenius capitis; levator scapulae; and posterior, middle, and anterior scalene muscles.**

Figure from Gray's Anatomy for Students, 3rd edition, p. 1025.



Identify the indicated arteries, veins, and nerves related to the posterior triangle of the neck.





BASE OF NECK



1. Phrenic nerve
2. Transverse cervical artery
3. Brachial plexus
4. Suprascapular artery
5. Subclavian vein
6. External jugular vein
7. Thyrocervical trunk
8. Inferior thyroid artery
9. Vagus nerve (X)
10. Common carotid artery
11. Internal jugular vein

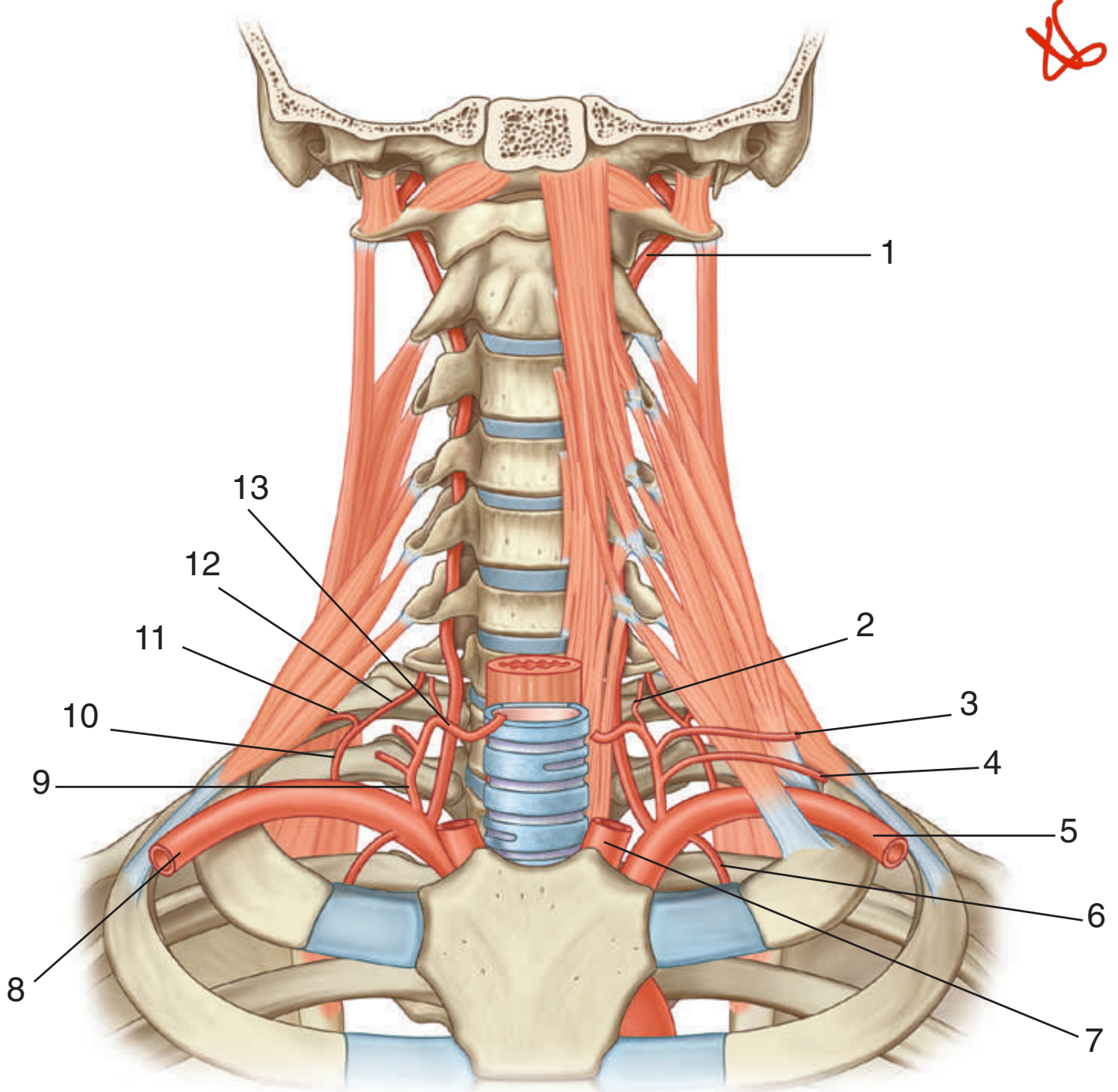
IN THE CLINIC:

- **Large-bore catheters can be inserted into larger central veins (central venous access) for the administration of large amounts of fluids or drugs that need rapid dilution. In the root of the neck this must be done carefully to avoid injury to surrounding structures. A misdirected subclavian vein procedure can puncture the cervical pleura, producing a pneumothorax, and an improperly performed internal jugular vein procedure can cause local hematoma and damage to the carotid artery.**

Figure from Gray's Anatomy for Students, 3rd edition, p. 1026.



Identify the indicated arteries in the base of the neck.





BASE OF NECK: ARTERIES



1. Vertebral artery
2. Ascending cervical artery
3. Transverse cervical artery
4. Suprascapular artery
5. Left subclavian artery
6. Internal thoracic artery
7. Left common carotid artery
8. Right subclavian artery
9. Thyrocervical trunk
10. Costocervical trunk
11. Supreme intercostal artery
12. Deep cervical artery
13. Inferior thyroid artery

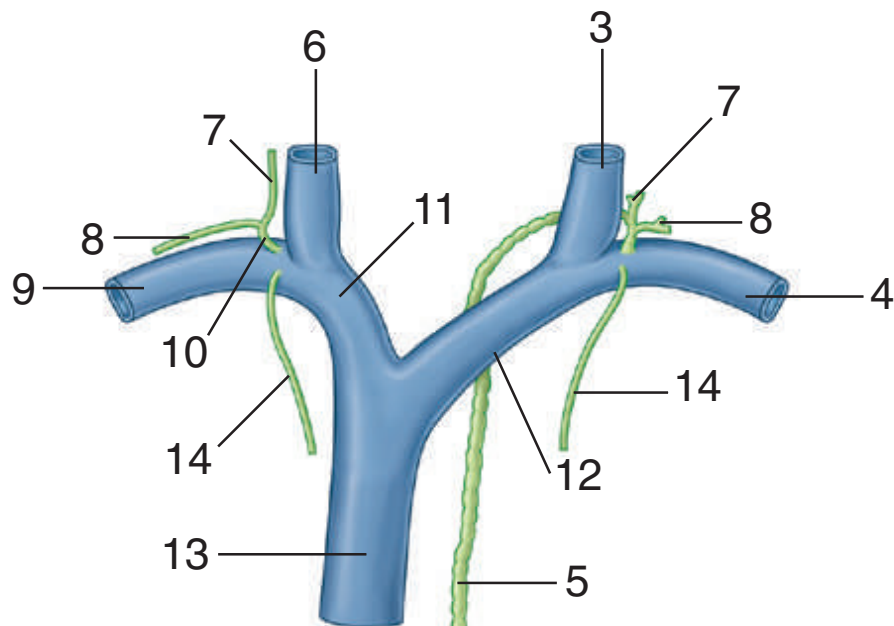
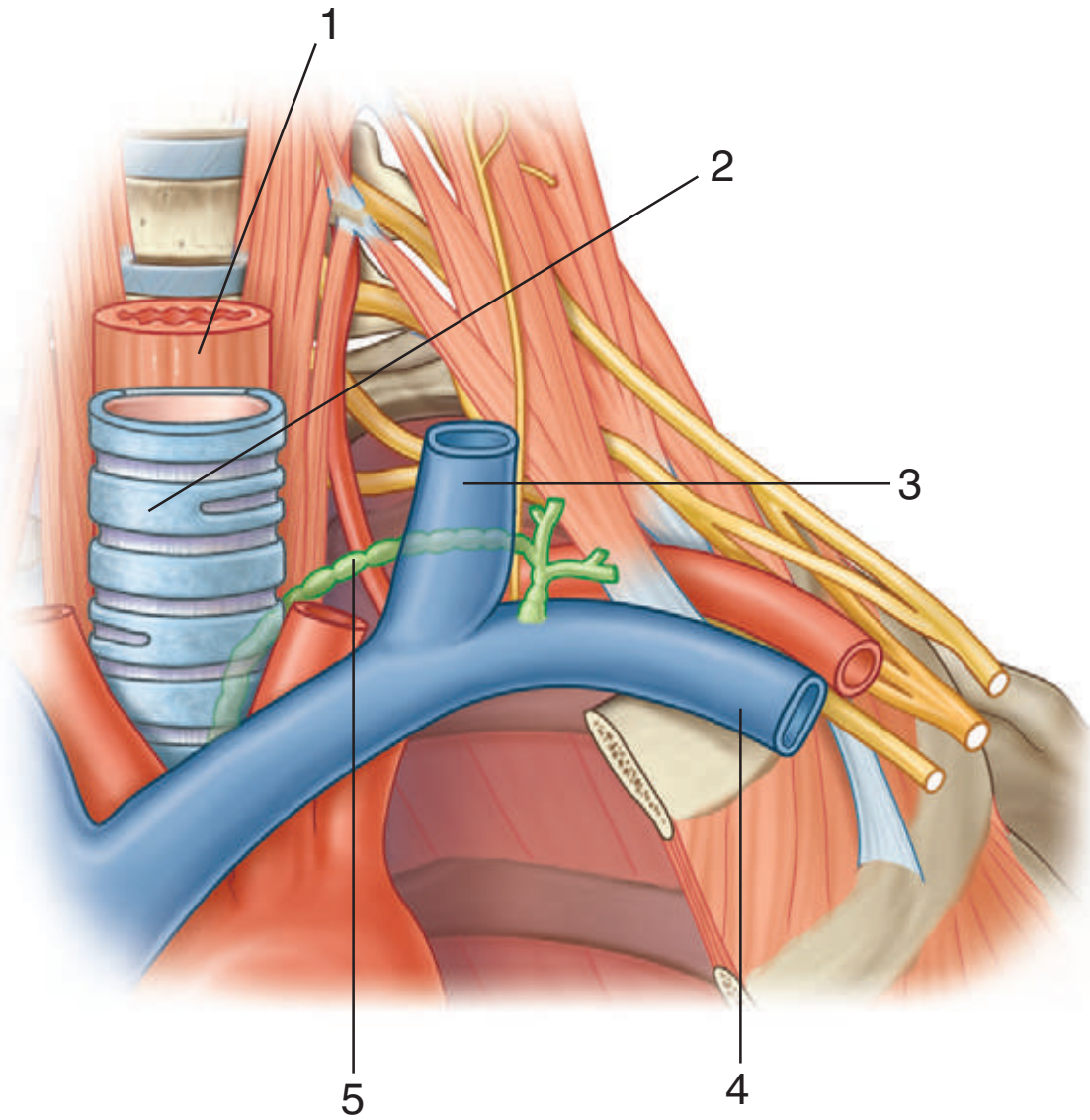
IN THE CLINIC:

- Each subclavian artery is divided into three parts by the anterior scalene muscle. The first part extends from the origin of the artery to the anterior scalene muscle. The second part is the portion of the artery posterior to the anterior scalene muscle. The third part is the portion of the artery lateral to the anterior scalene muscle before the artery reaches the lateral border of rib I. All branches (vertebral, thyrocervical trunk, internal thoracic, costocervical) from the subclavian arteries arise from the first part of the artery, except for the costocervical trunk on the right side, which arises from the second part.

Figure from Gray's Anatomy for Students, 3rd edition, p. 1031.



Identify the indicated structures.





BASE OF NECK: LYMPHATICS

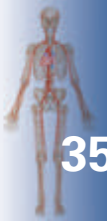

1. Esophagus
2. Trachea
3. Left internal jugular vein
4. Left subclavian vein
5. Thoracic duct
6. Right internal jugular vein
7. Jugular trunk
8. Subclavian trunk
9. Right subclavian vein
10. Right lymphatic duct
11. Right brachiocephalic vein
12. Left brachiocephalic vein
13. Superior vena cava
14. Bronchomediastinal trunk

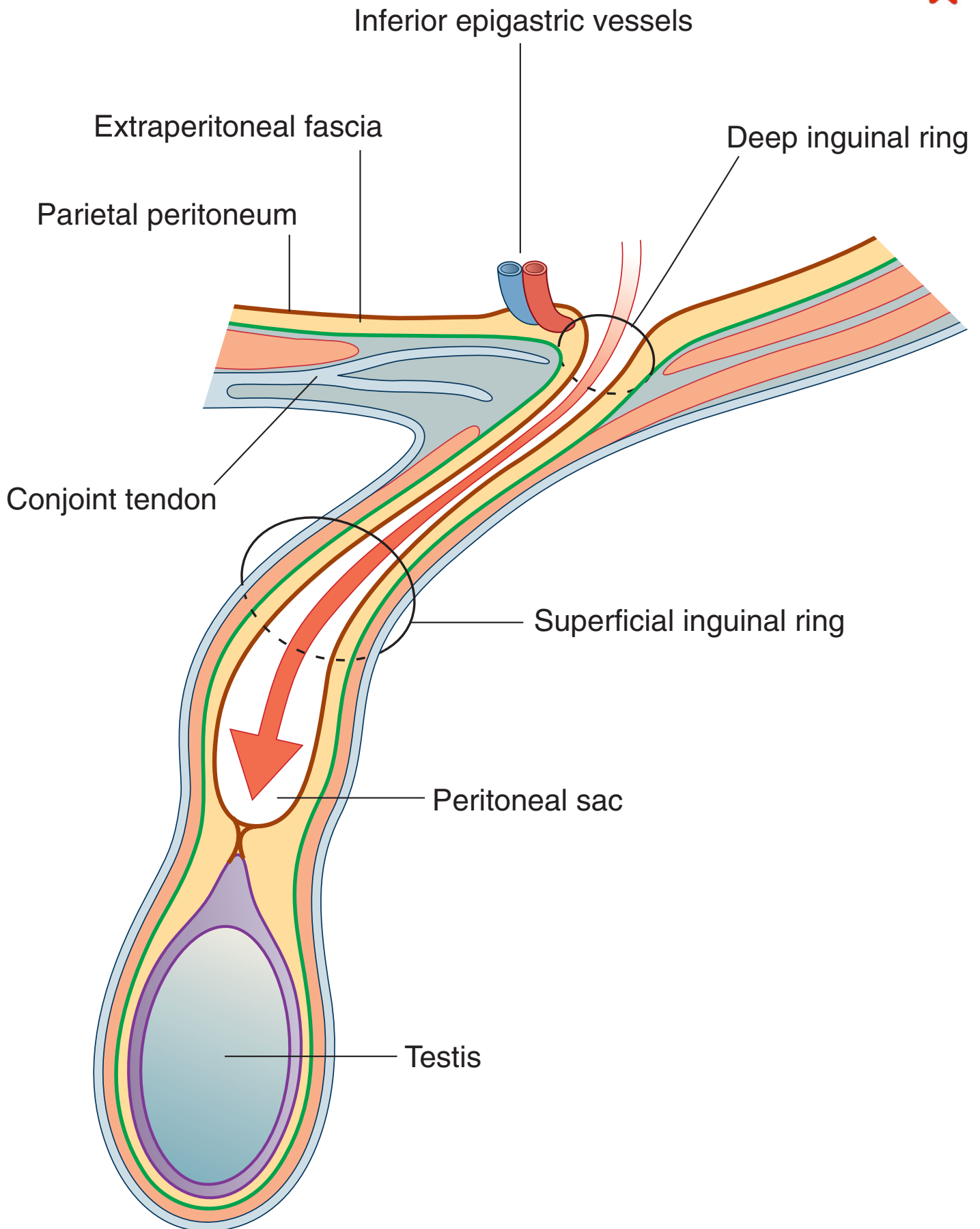
IN THE CLINIC:

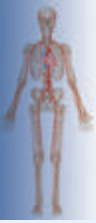- **The thoracic duct terminates in the junction between the left internal jugular and left subclavian veins. It may be joined at this junction by the left jugular trunk, which drains lymph from the left side of the head and neck, and the left subclavian trunk, which drains lymph from the left upper limb. The left bronchomediastinal trunk, which drains lymph from the left half of the thoracic structures, usually enters the left subclavian vein directly but may occasionally enter the thoracic duct. A similar confluence of lymphatic trunks occurs on the right side.**

Figure from Gray's Anatomy for Students, 3rd edition, p. 1037.



What type of inguinal hernia is indicated in the figure?





INGUINAL HERNIA I

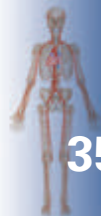

This is an indirect inguinal hernia.

IN THE CLINIC:

- **An indirect inguinal hernia follows the contents of the spermatic cord through the deep (internal) inguinal ring and inguinal canal. The neck of the hernia is lateral to the inferior epigastric vessels.**

Figure from Gray's Anatomy for Students, 3rd edition, p. 299.



What type of inguinal hernia is indicated in the figure?

