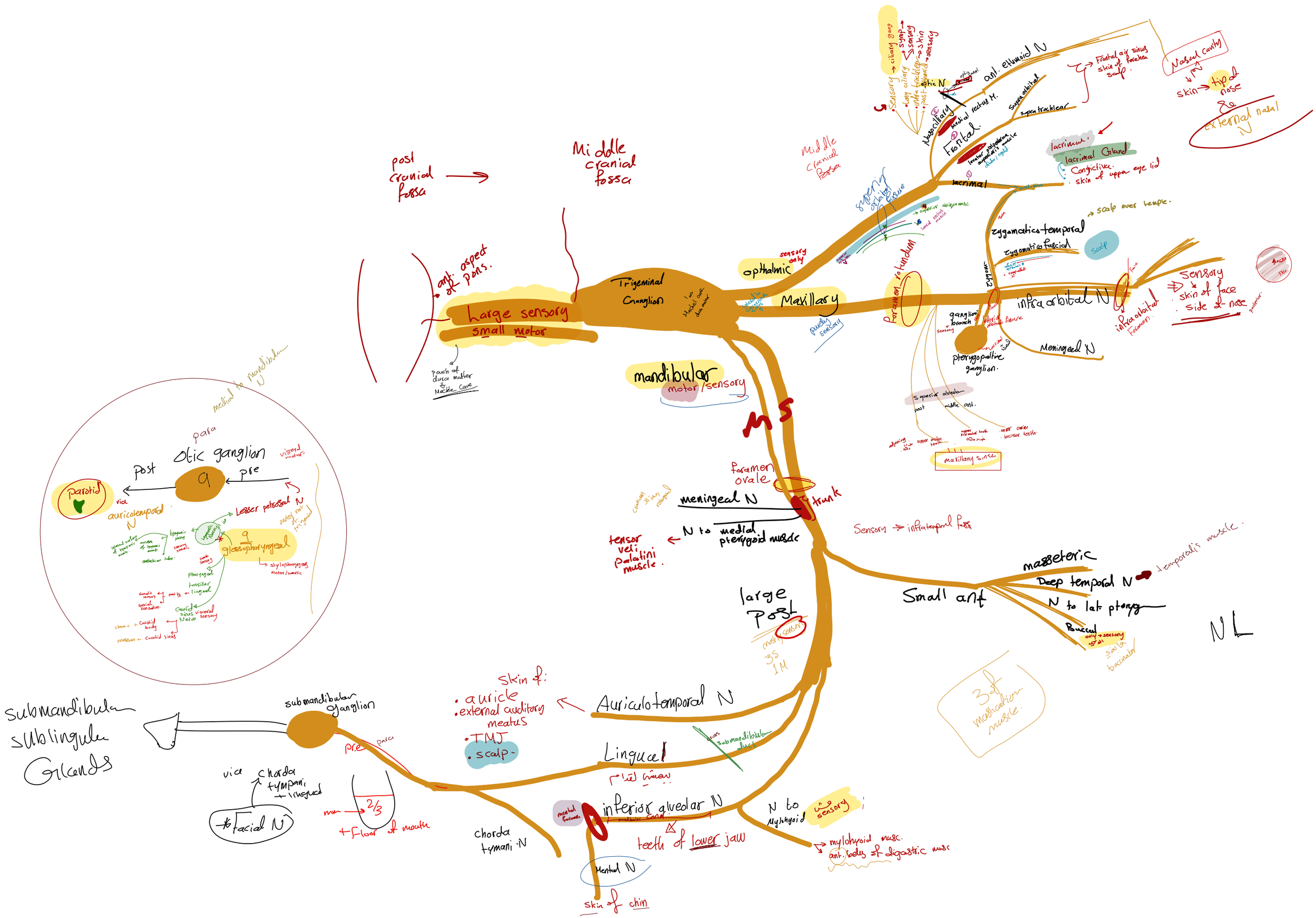
post cranial fossa
Middle cranial fossa
Middle cranial fossa
ant. aspect of pons.
Large sensory
small motor
pouch of dura matter
Meckle Cave
Trigeminal Ganglion
Medial one is motor
ophthalmic
sensory only
Maxillary
purely sensory
mandibular
motor/sensory
MS
Foramen rotundum
superior orbital fissure
superior oblique m.
lacrimal gland
lacrimal
Nasocilliary
Frontal
medial rectus M.
inferior oblique
superior rectus
inferior rectus
ciliary ganglion
sensory → ciliary ganglion
long ciliary → sympathetic → sensory
short ciliary → sympathetic → sensory
post-ganglionic → sensory
optic N
ant. ethmoid N
Frontal air sinus
skin of forehead
scalp.
Nasal cavity
skin → tip of nose
external nasal N
supratrochlear
supraorbital
lacrimal
lacrimal Gland
Conjuctiva.
skin of upper eye lid
zygomatic-temporal
scalp over temple.
zygomatic facial
scalp
zygomatic
infraorbital N
infraorbital Foramen.
sensory
skin of face
side of nose
Meningeal N
pterygopalatine ganglion.
ganglion branch
sensory
Superior alveolar
post
middle ant.
upper molar teeth
upper premolar teeth
upper canine
incisor teeth.
maxillary sinus
foramen ovale
trunk
meningeal N
N to medial pterygoid muscle
tensor veli palatini muscle.
Sensory → infratemporal fossa
large
Post
motor
sensory
3 motor
1 M
Small ant
masseteric
Deep temporal N
temporalis muscle.
N to lat pterygoid
Buccal
only sensory
buccinator
3 of mastication muscle.
NL
Auriculotemporal N
skin of:
• auricle
• external auditory meatus
• TMJ
• scalp
Lingual
submandibular duct
inferior alveolar N
teeth of lower jaw
mental foramen
Mental N
skin of chin
N to Mylohyoid
sensory
mylohyoid musc.
ant. body of digastric musc
Chorda tympani N
pre
post
submandibular ganglion
via chorda tympani + lingual
Facial N
mm → 2/3
+ Floor of mouth
submandibular
sublingular
Glands
medial to mandible N
para
Otic ganglion
visceral motor
post
pre
parotid
via
auriculotemporal N
Lesser petrosal N
motor root of trigeminal
9
glossopharyngeal
stylopharyngeal
motor/sensory
Pharyngeal
tonsillar
lingual
Carotid sinus
visceral sensory
Carotid body
chemo
pressure
Carotid sinus