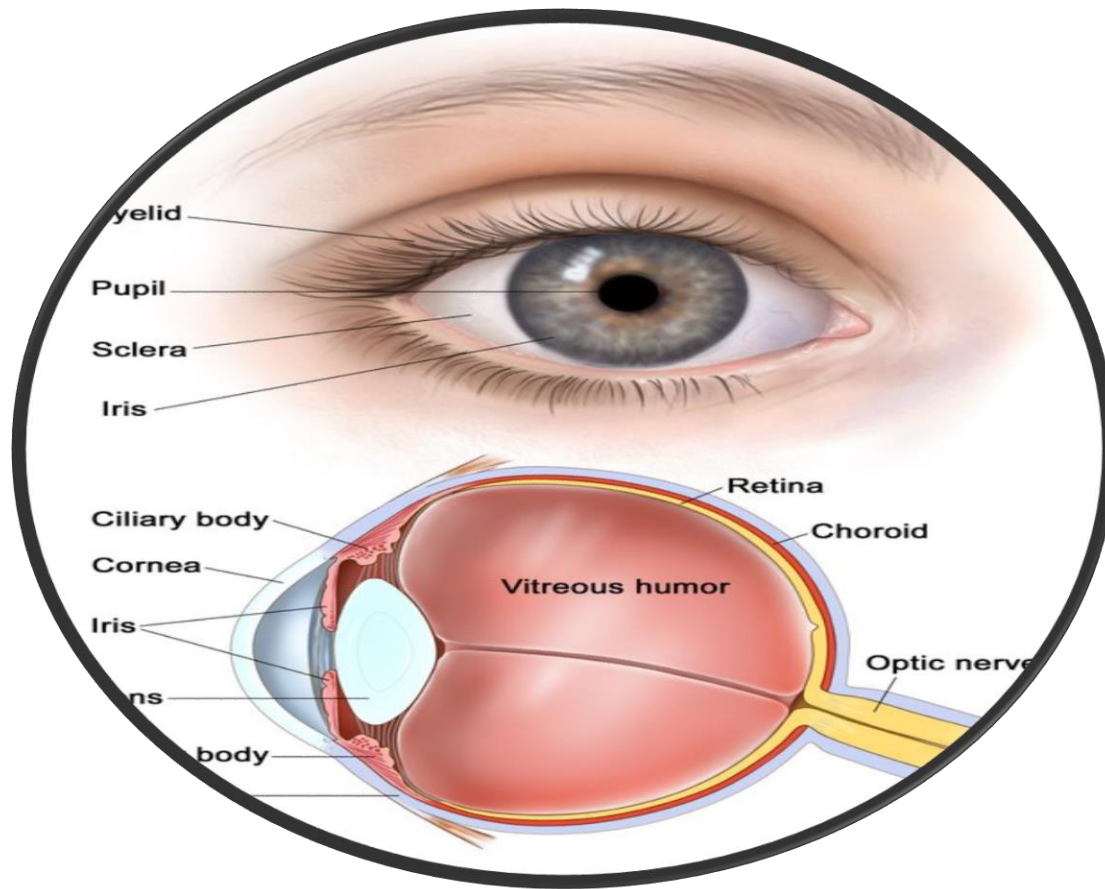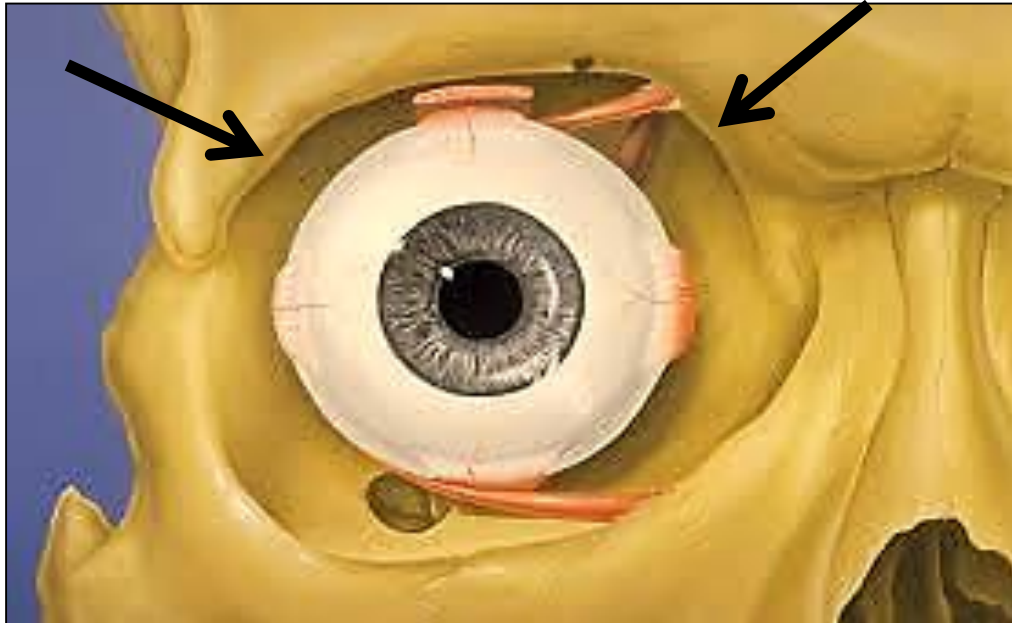


The eye (Part I)

Professor Dr . Hala El-mazar

- The eye is the organ of vision
- **Photosensitive:** detect light and convert it into electro-chemical signals that travel in neurons to the cerebrum
- The eyes located in bony cavities in the skull called orbits



Histologically each eye is composed of **three layers (tunics)**:

1- The external layer (**fibrous**) composed of:

Cornea

Sclera

2- The middle layer (**vascular, muscular, pigmented**) composed of:

Iris

Ciliary body

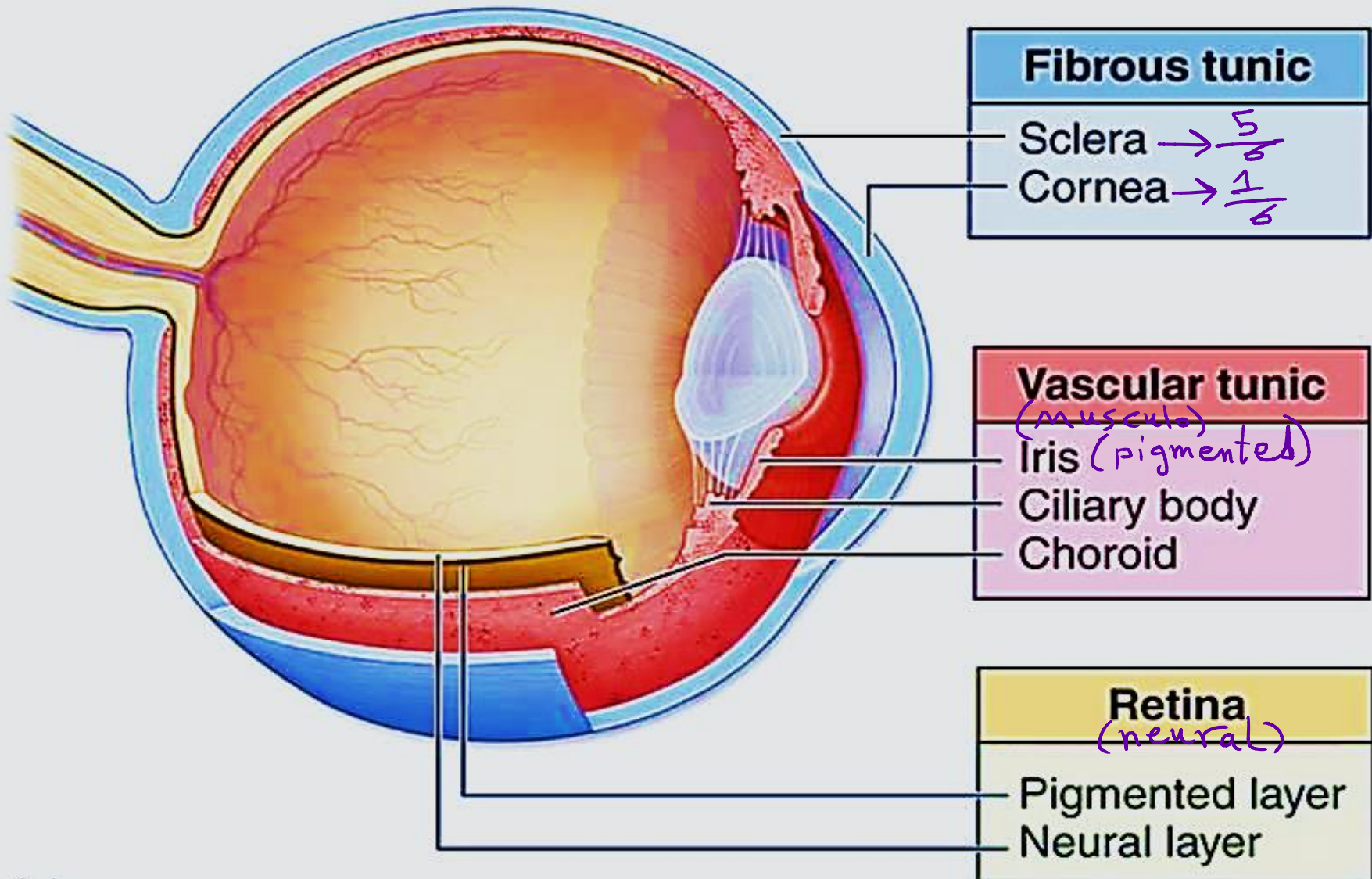
Choroid

3- The inner layer (**nervous**) composed of: **Retina**

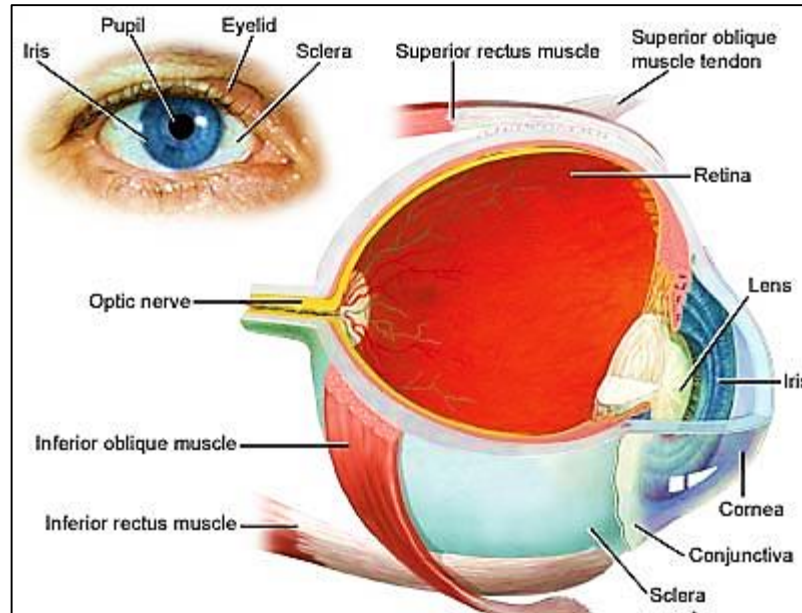
Pigmented epithelium

Neural layer

Layers (tunics) of the eye



(a)

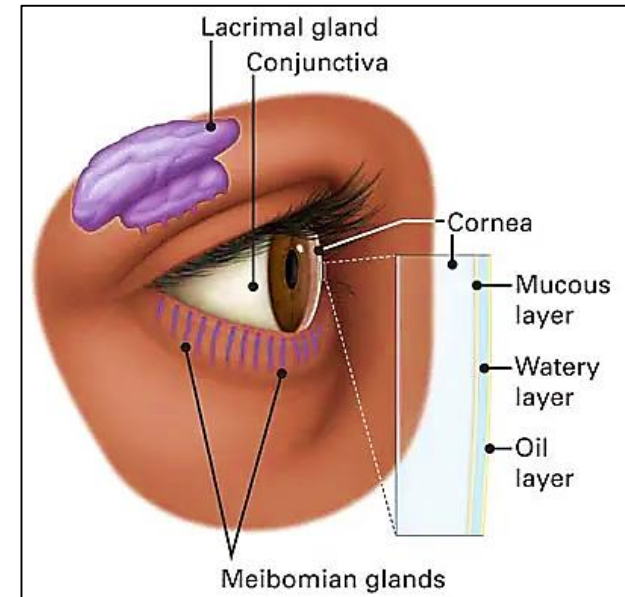
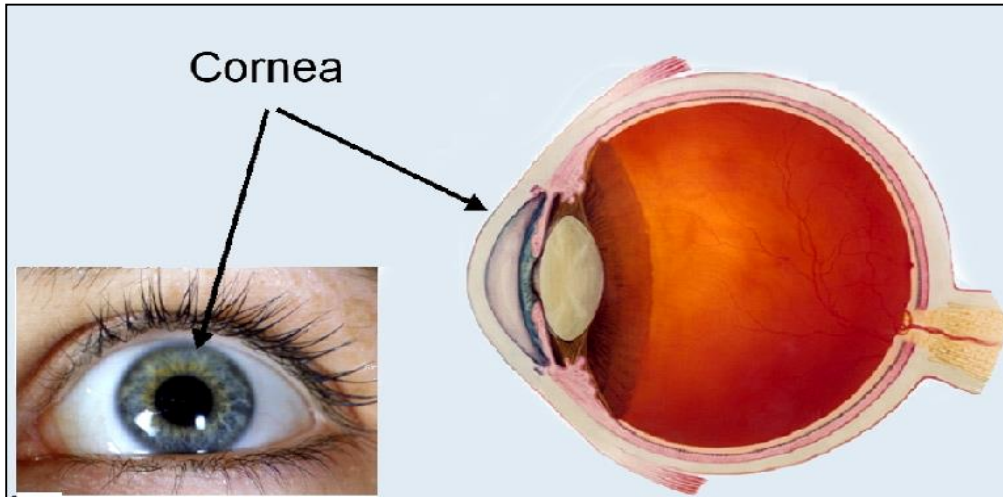


The external (fibrous) layer

A- the cornea

B- the sclera

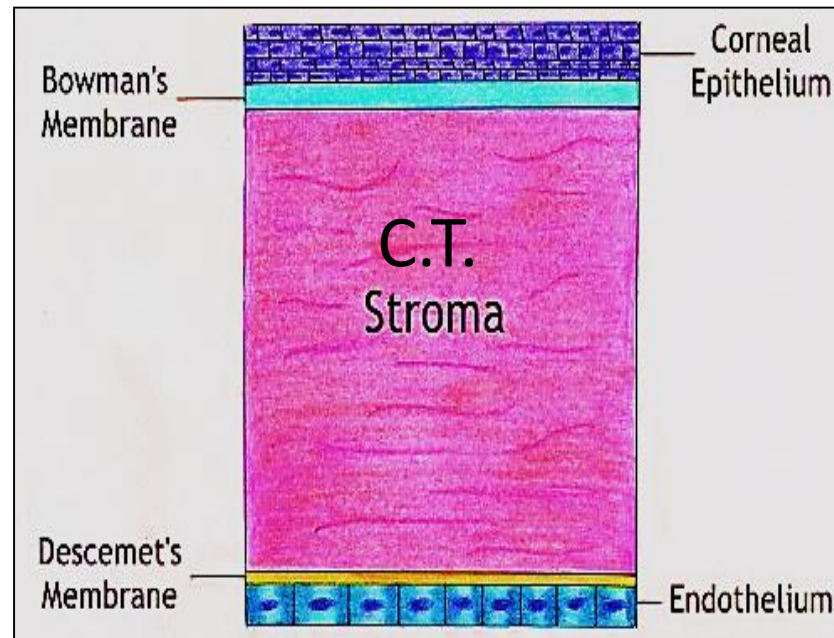
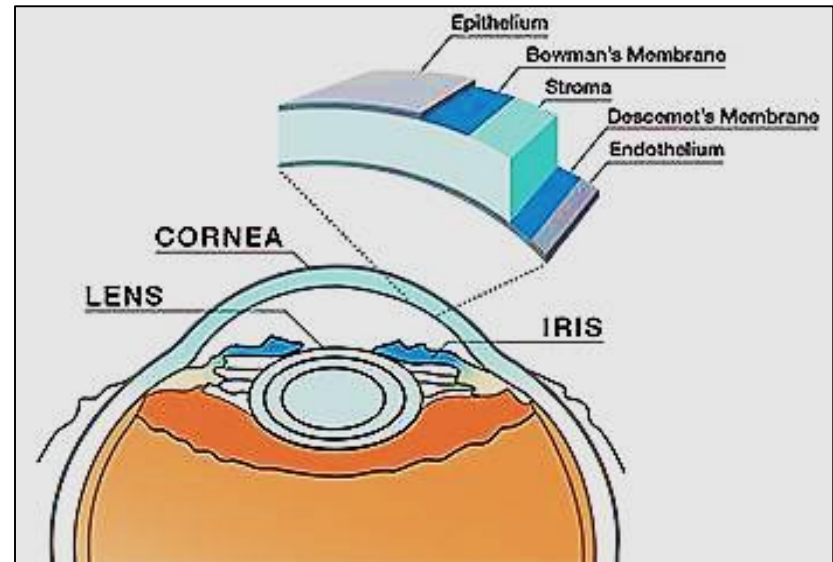
The cornea



- Dome shape, transparent (colorless)
- **Non vascular** anterior part of the outer (fibrous) layer
↳ easy to transplant
- Refracts (bend) the light entering the eye to help it focus on retina
- Is **richly supplied with sensory nerve endings** *→ very sensitive*
- Is kept wet by the secretion of the tarsal & lacrimal glands

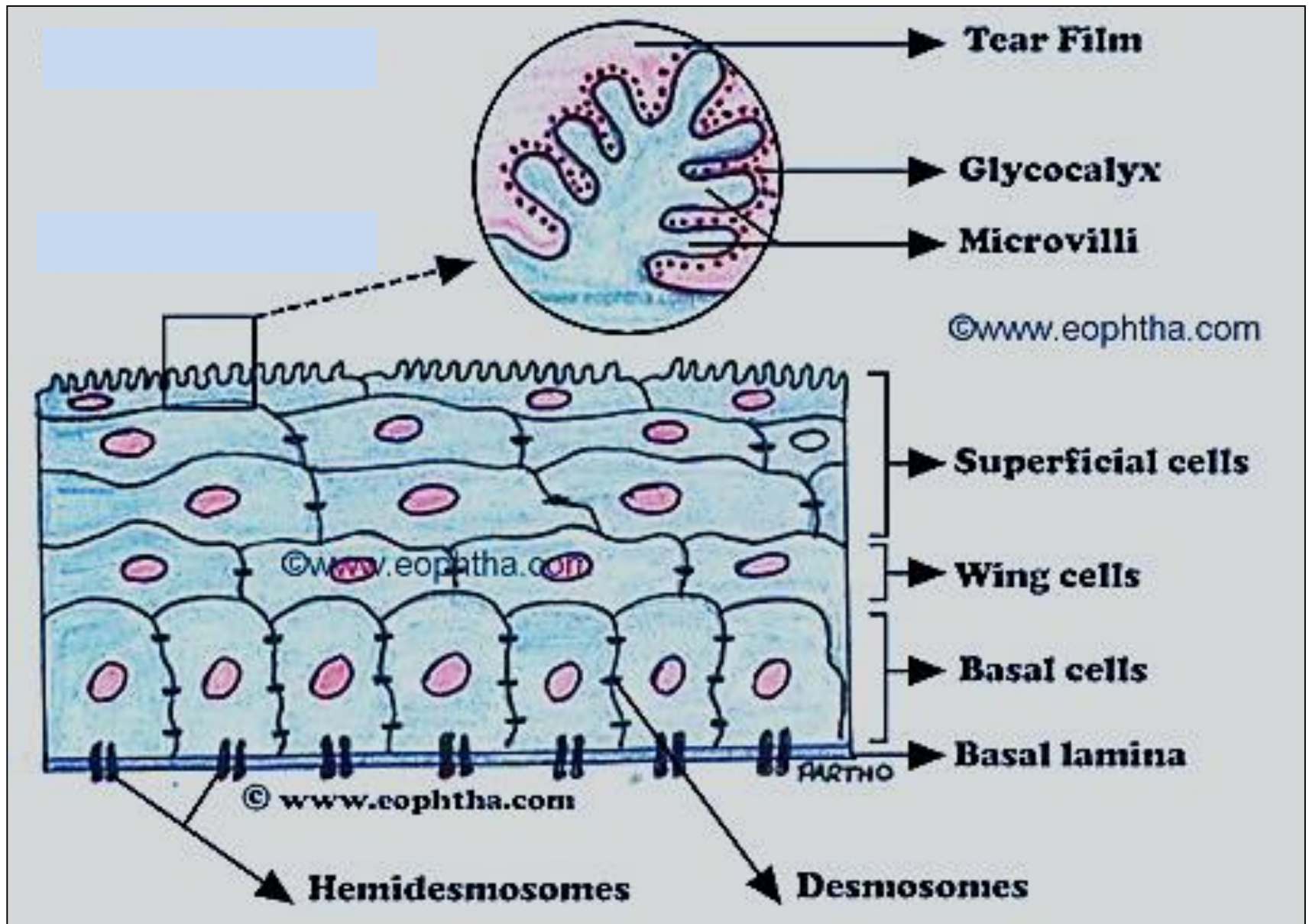
- Histologically the cornea composed of **5 layers**:

- A-** Anterior epithelium
- B-** Bowman's membrane
- C-** C.T. layer or stroma
- D-** Descemet's membrane
- E-** Endothelium



1- Anterior epithelium (10%) → Thickness

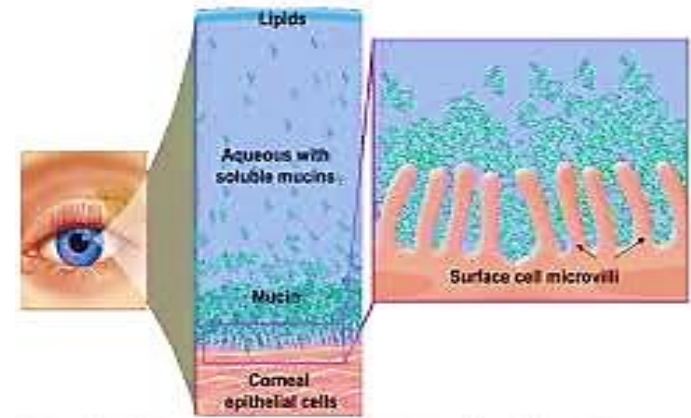
- It is non-keratinized stratified squamous epithelium
- It consists of 5-6 layers of cells
- The basal cells are columnar, show many mitotic figures, indicating high capacity of cell renewal & repair.
not stem cell
- intermediate layer consists of 3-4 layers of polyhedral cells, is richly supplied with free nerve endings (trigger blinking reflex)
wing cells
- The surface corneal cells are squamous show microvilli which function to retain a thin tear film over the corneal epithelium. constantly shed
→ hold tear film
→ nutrition + O₂ → avascular
- The epithelium is transparent due to continuous evaporation of water from its surface, & active exocytosis from endothelium layer



(The corneal epithelium)

Importance of microvilli on the superficial cells of the cornea:

- Increase the surface area: of the epithelial cells which helps in better adherence of the tear film
- Tear film stability: tear film is essential to provide the corneal epithelium with nutrients & maintain its hydration
- Transport and absorption: absorb water , electrolyte & nutrients into epithelial cells



Tear film structure:

1- mucus layer:

covers microvilli & forms a network over the conjunctival surface, secreted by conjunctival goblet cells & the stratified squamous cells of the conjunctive → *Mucin*

Function: Convert corneal epithelium from hydrophobic to hydrophilic layer → stabilize the tear film, provide lubrication for eyelid movements

2- Aqueous layer: (thick layer)

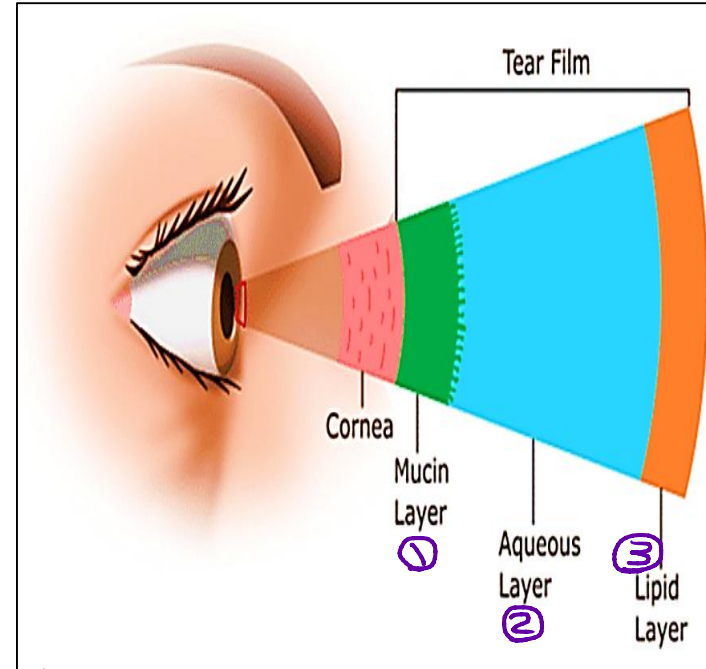
Secreted by lacrimal glands (watery secretion)

Function: supply oxygen to the avascular corneal epithelium & maintain constant electrolyte composition the corneal epithelium

3- Lipid layer: → *prevent evaporation of tear film*

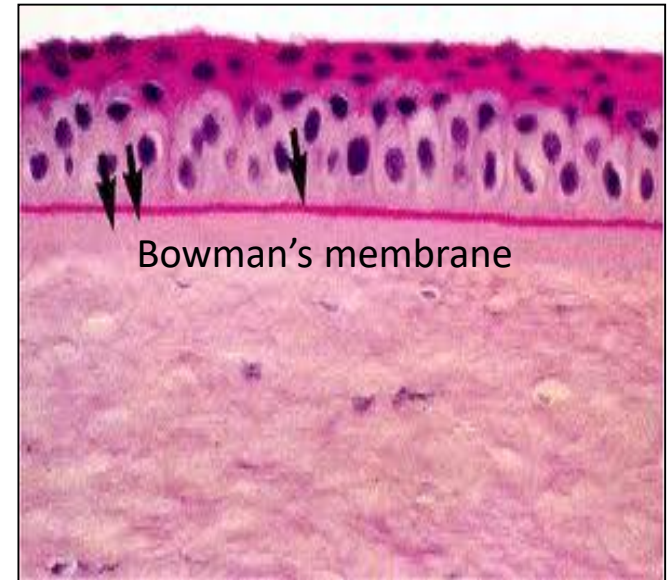
Secreted by tarsal glands of eye lids

Function: prevent evaporation, reduces friction during blinking & protects the surface fro dryness

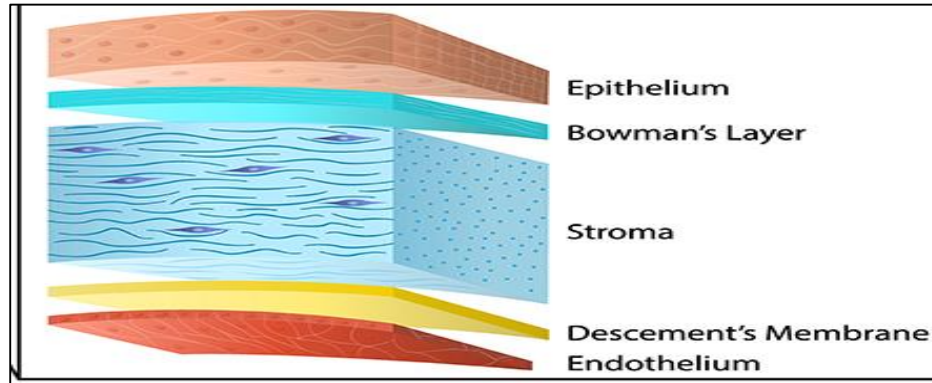


2- Bowman's membrane

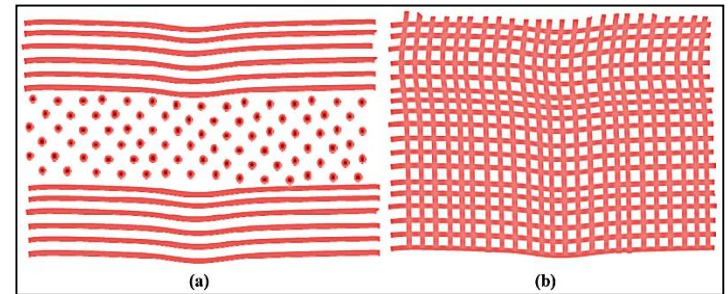
- It is a thick , non-cellular membrane BELOW the epithelium basement membrane
- Formed of protein fibers (collagen types ¹I & ⁵V)
- It acts as protective barrier to the stroma(next layer) against infection & provide support to sub-epithelial nerve plexus
→ protect the epithelial innervation
- If injured doesn't regenerates it heals by scar, and causes corneal opacity



3- C.T. (Stroma) → most important layer

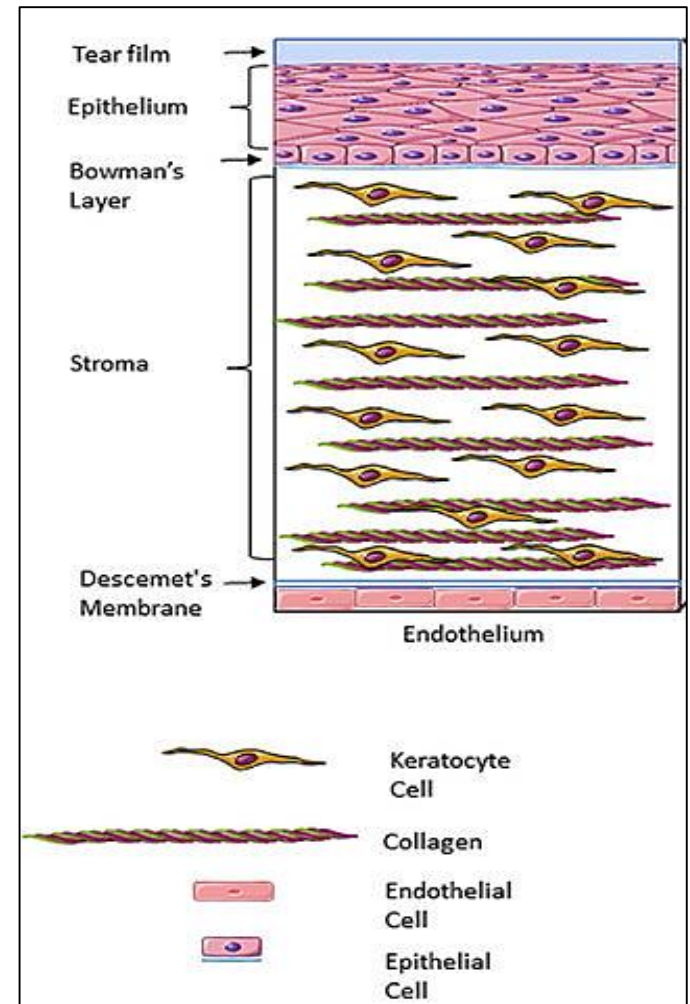


- The ^{very} thick layer of cornea (90% of the corneal thickness)
↳ 60 layers
- It is formed of layers of parallel collagen fibers (types I predominantly) arranged at right angles with each other.



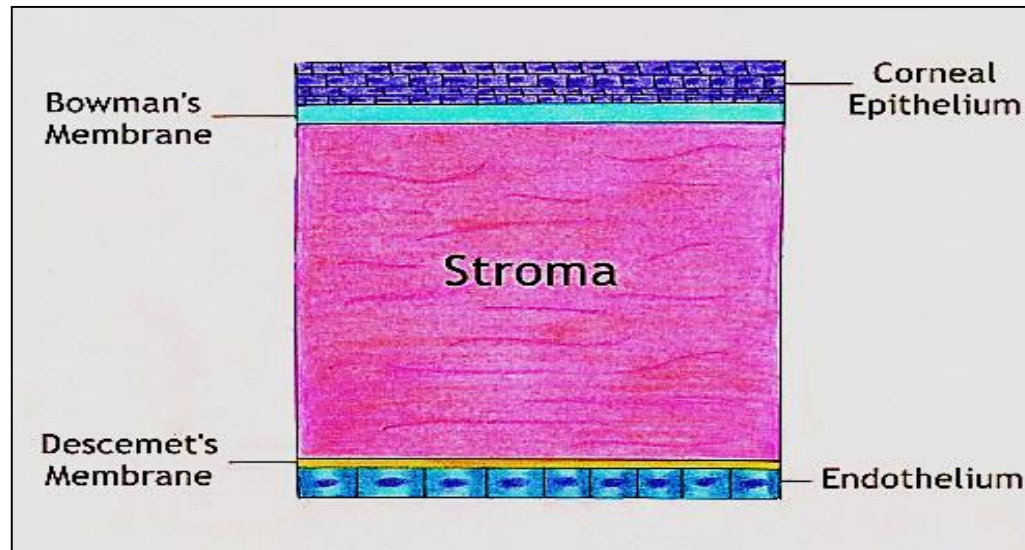
- the uniform arrangement of the ^{شبكة / ناضجة}
- Is called Lattice-like pattern. The collagen fibers are crucial for transparency & strength of the cornea

- Between the collagen fibers there are cells called keratocytes. they have role in synthesizing the collagen & matrix of stroma
- the matrix is secreted by these cells to maintain the nutriment & organization the spacing between stroma collagen fibers
- Stroma layer maintain the shape of cornea & withstand the pressure from inside the eye (intraocular pressure)
 ↳ prevent glaucoma



4- Descemet's membrane

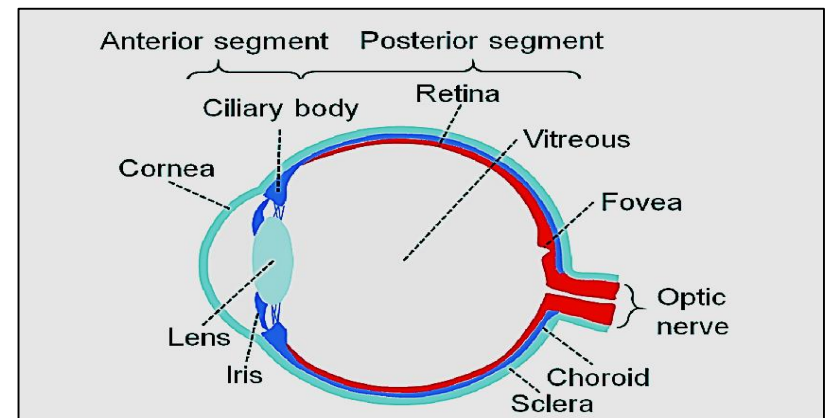
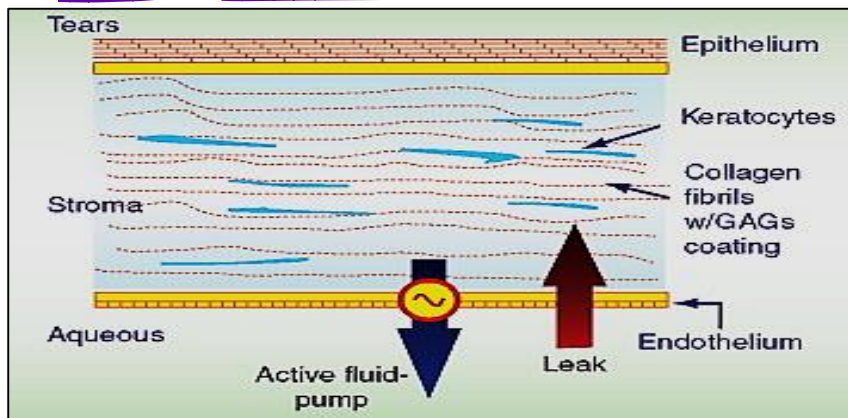
- It is a thick homogenous, non-cellular membrane composed of fine collagen fibers (type IV & VIII)
4 8
- Made by the endothelial cells of the next layer but is not consider as basement membrane for them
- Provide structural support to the endothelial layer



⊗ corneal epithelium
regenerate every (7-10) days

5- Endothelium

- A layer of simple squamous cells (limited- regeneration), avascular
- Cells of this layer are active in:
 - protein synthesis to maintain the Descemet's membrane
 - pumping excess water (^{ATP}active transport) into the adjacent anterior chamber → dispose of any excess fluid in stroma → maintain corneal transparency
 - The endothelium responsible for maintaining state of hydration within the cornea that provide maximum transparency & optimal light refraction

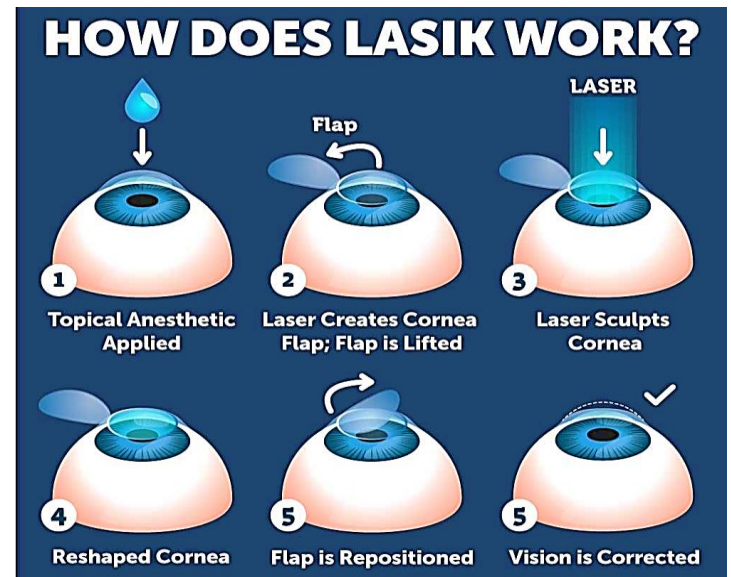

Why is the cornea transparent?

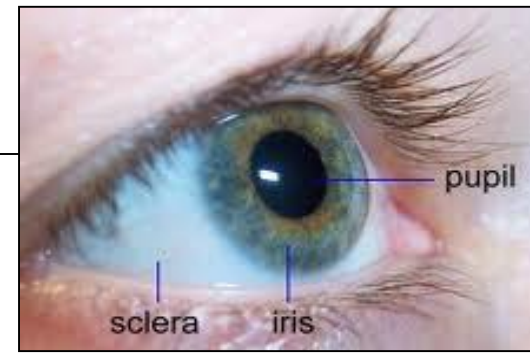
1. Avascular, no lymphatics. the cornea receives nutrients from aqueous humor and tear film
2. The surface epithelium is smooth & non-keratinized
3. Regular arrangement of collagen fibers cells, matrix in the stroma
4. Cells, fibers & matrix of corneal stroma have the same refractive index
5. The degree of hydration of the cornea is perfectly regulated through corneal endothelium

LASIK: → اعرف انه ينعملها في الstroma

- Surgical technique used to improve the shape or curvature of cornea to correct certain visual abnormalities e.g. myopia, hyperopia, astigmatism
- In this technique the corneal epithelium is displaced as a flap & the stroma is reshaped by excimer laser. The laser removes microscopic amounts of stroma to change curvature of the cornea
- Then the epithelium is repositioned and the rapid regenerative response of the epithelium will reestablish normal corneal physiology



The sclera



- Is thick white, opaque, fibrous layer (5/6)
- It provides sites for ocular ms. Insertion, structural support & protection to the eye. it is mostly avascular
not like cornea
- It consists of irregular white (type I collagen fibers) , intersect in various directions, elastic fibers & fibroblasts

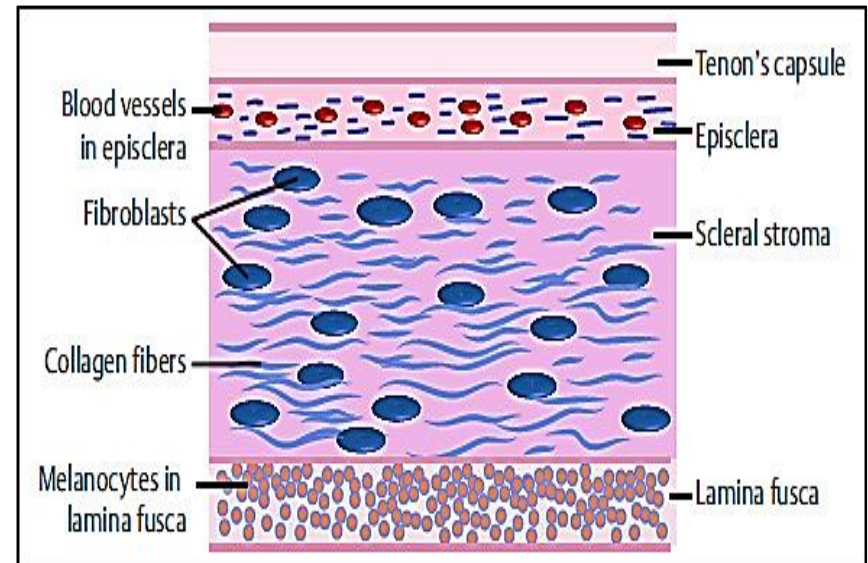
- Formed of **3 layers** :

Episclera → *vascular*

Stroma (Sclera proper stroma)

Lamina fusca

- Is covered by **conjunctiva** *above sclera*
 (clear mucus membrane)
Vascular → *highly*



Is the sclera avascular?

Is the sclera avascular?

Question:

Is the sclera avascular?

Avascular:

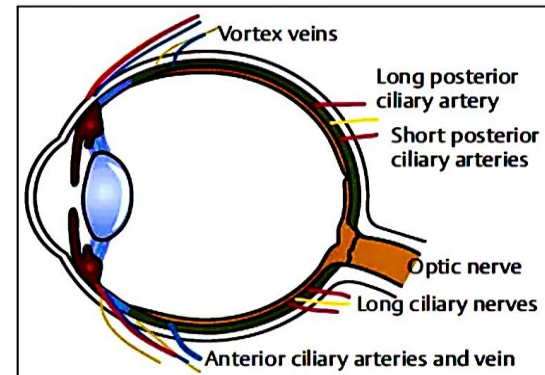
Avascular means that the part of the body does not have any blood vessels of its own. Blood vessels are the tubes or pathways for nutrient rich blood can reach that part of the body and take away the waste from that part of the body.

✓ Answer and Explanation:

Yes, the sclera or the white of the eyes is mostly avascular. There is a layer on the outside called the episclera that has blood vessels that can become visible when the person has episcleritis. This is also the layer that provides most of the nutrients needed by the sclera. The inner lining of the sclera called the lamina fusca also has blood vessels but are not visible that also provides the other nutritional needs of the sclera. There are also blood vessels that pass through the sclera that supplies blood to other parts of the eye like the iris, the conjunctiva and the optic nerve. The sclera does not need that many blood vessels because it does not need to change the collagen and other cells as much as the other parts of the body.

Blood Supply

It is almost avascular and gets its nourishment from the episclera and choroid.



Is the sclera avascular (without blood vessels)?

JAN 31, 2019

Question:

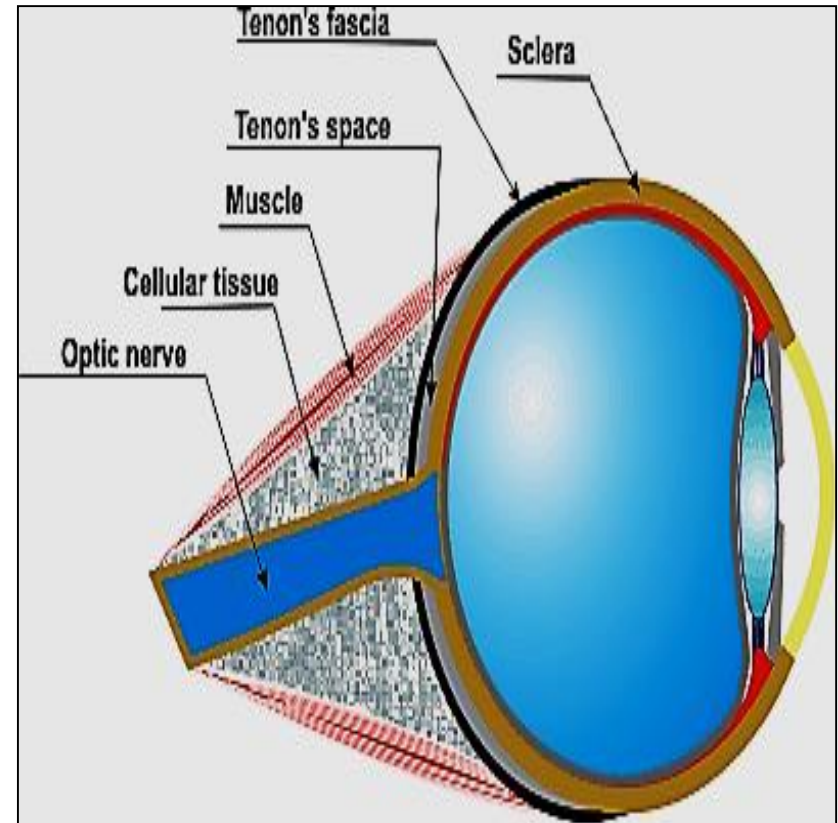
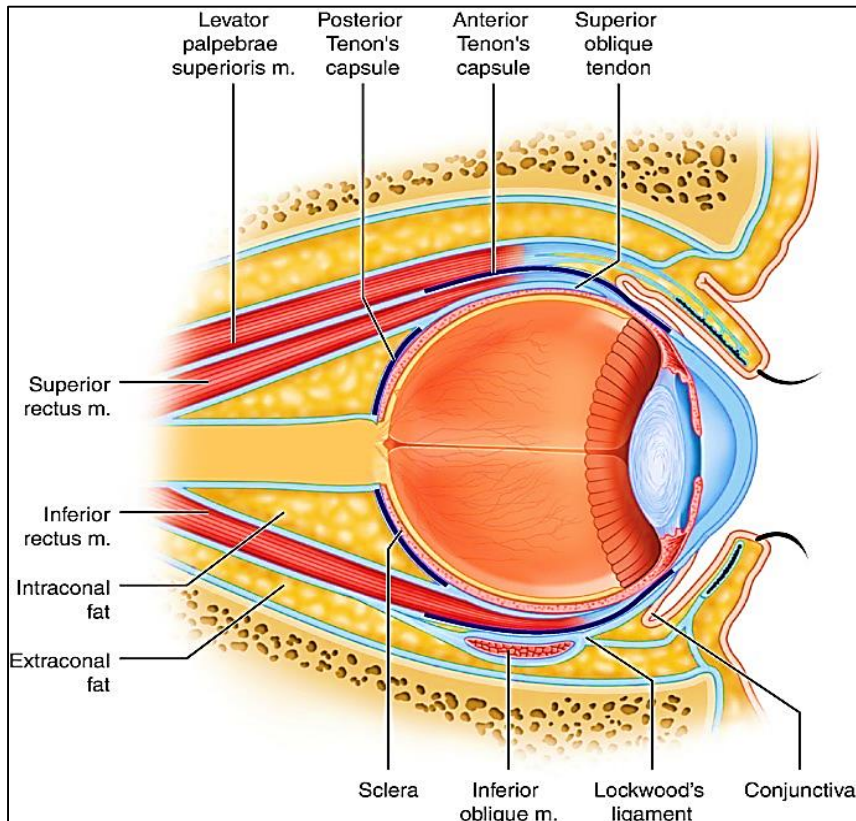
Is the sclera avascular (without veins)?

Answer:

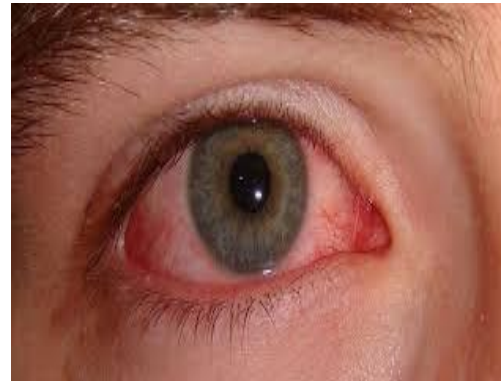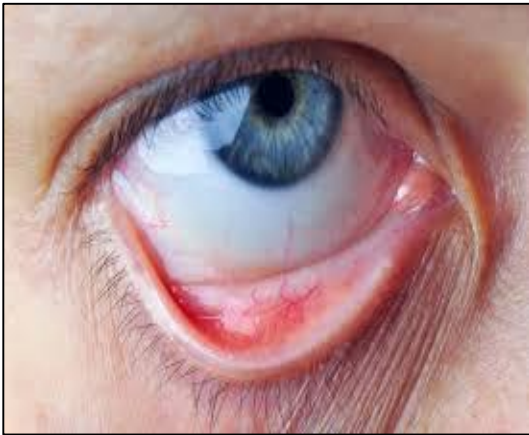There are three layers in the sclera (white part of the eye) and each of them contain blood vessels. They are usually not visible to the external observer except in certain inflammatory conditions. Blood vessels in the outermost layer, the episclera, dilate (widen) and become visible in a condition called episcleritis. The blood vessels in the middle layer of the sclera, called the stroma, are much sparser, but they also can be seen in someone with scleritis. The innermost portion of the sclera (called the lamina fusca) also contain blood vessels, but they are not visible.

In addition, there are a number of blood vessels passing through the sclera, including those that supply the conjunctiva (thin, transparent membrane covering the sclera), iris (colored part of eye), choroid (layer of tissue between the sclera and the retina), optic nerve (back of the eye that connects to the brain), extraocular muscles (muscles that control eye movement) and the sclera itself.

- The sclera is surrounded with Tenon's capsule (fascia): A thin fibrous layer surrounds the sclera & provides attachment to the extra-ocular muscles

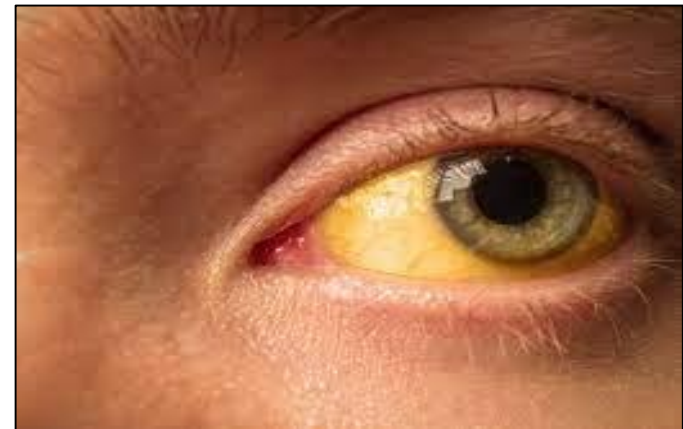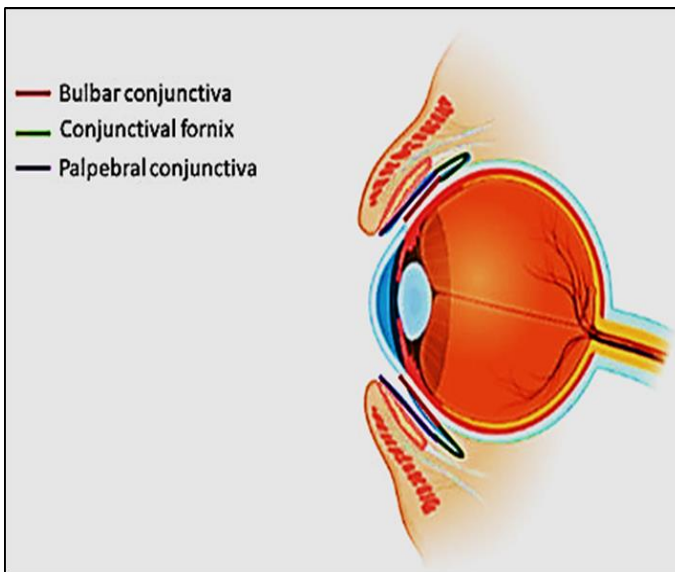


(Sclera and Ocular muscles)



Conjunctivitis (pink eye)
due to
Conjunctiva
inflammation of
conjunctiva .
Conjunctiva is vascular

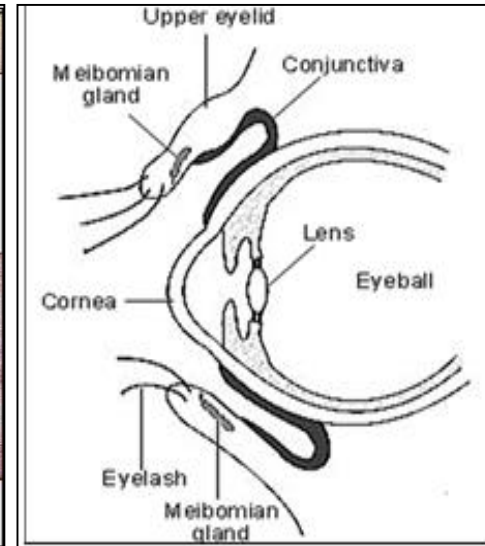
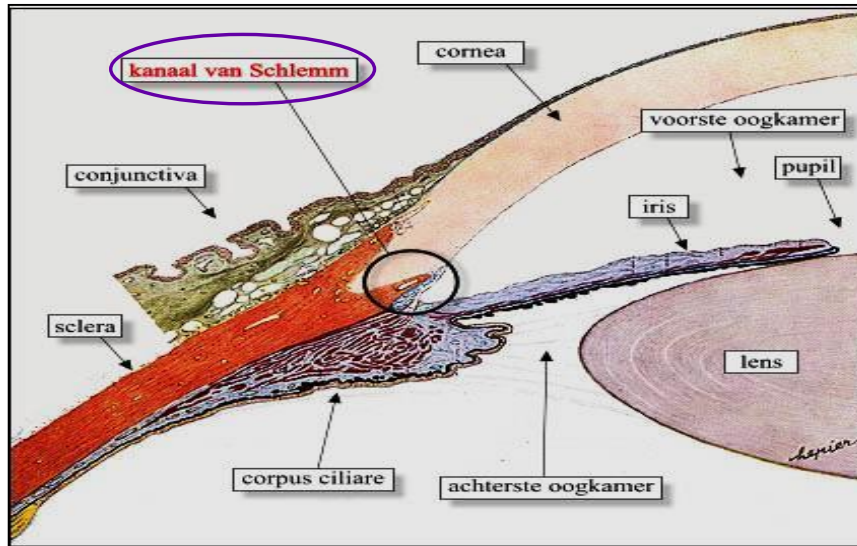
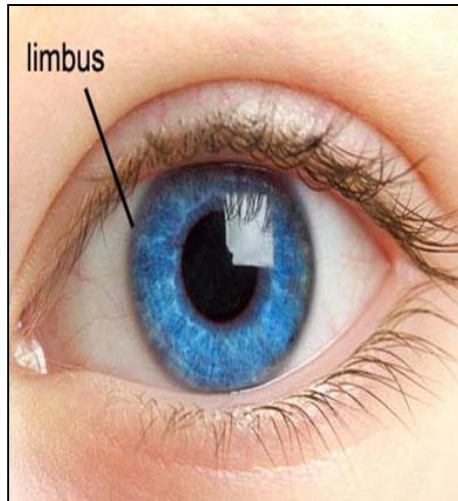
Conjunctiva



Jaundice

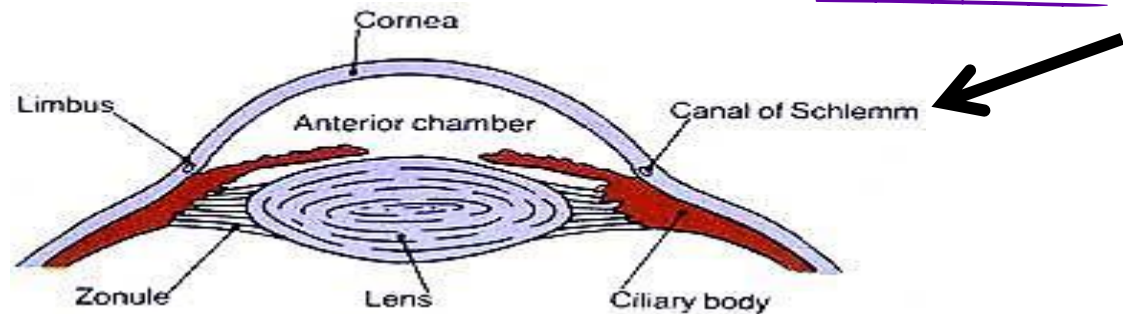
Yellow color of the sclera in jaundice
because collagen fibers can absorb and retain
bilirubin

The corneo- scleral junction (**limbus**)

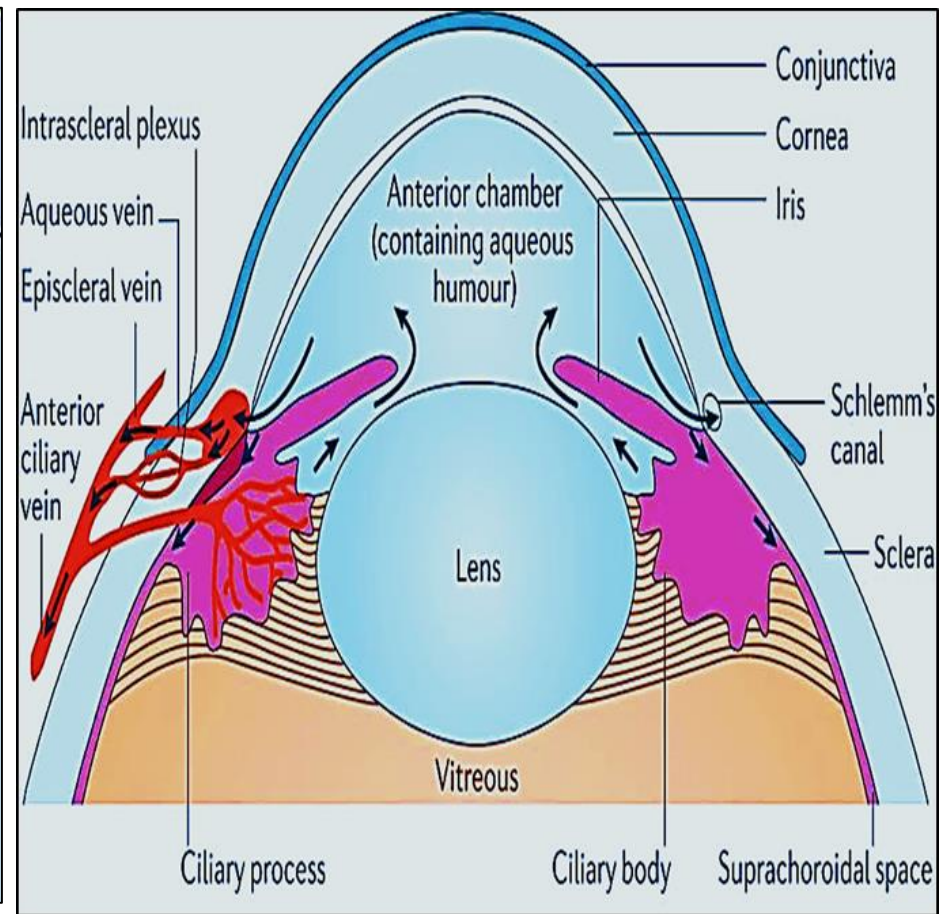
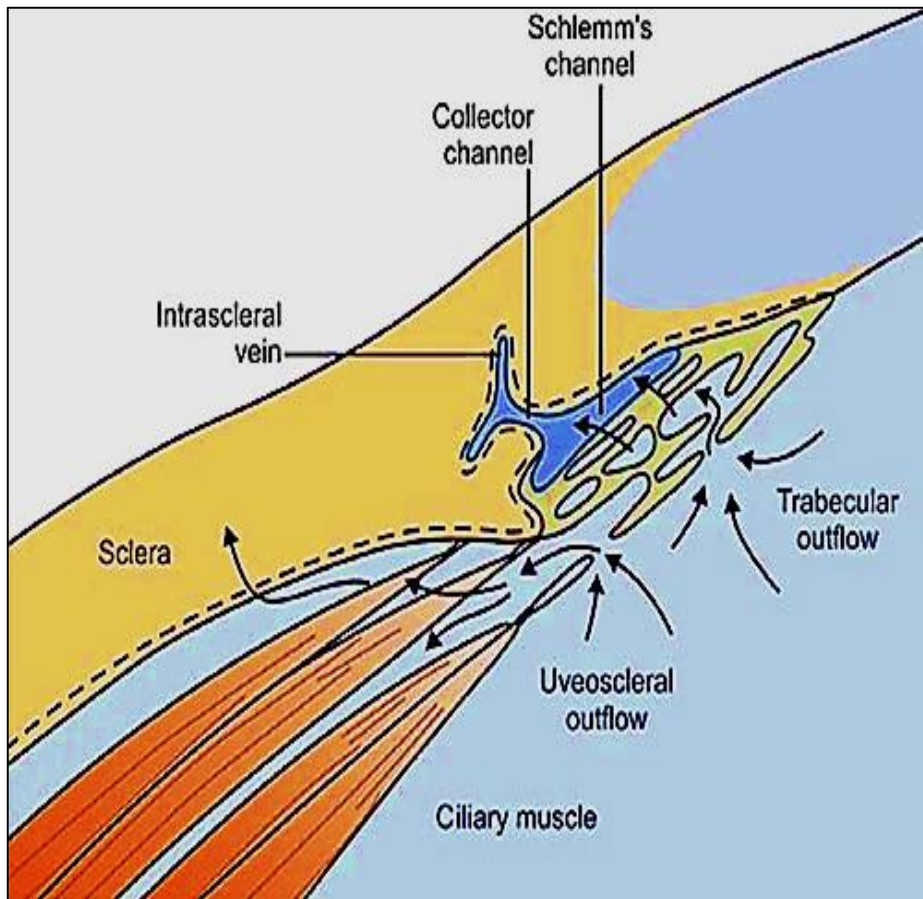


- Transitional area between cornea & sclera, contains **stem cells** for the corneal epithelium(limbal stem cells)
- Site for surgical incisions for cataract & glaucoma
- **Is a highly vascular zone**
- The corneal epithelium is continuous at the Limbus with the bulbar conjunctiva which covers the sclera
- Bowman's membrane stops abruptly at Limbus

- The regular stroma of the cornea is continuous with the irregular stroma of the sclera. At that point locate the canal of Schlemm (the aqueous humor is drained through that canal → venous system) .. (**Glaucoma**)

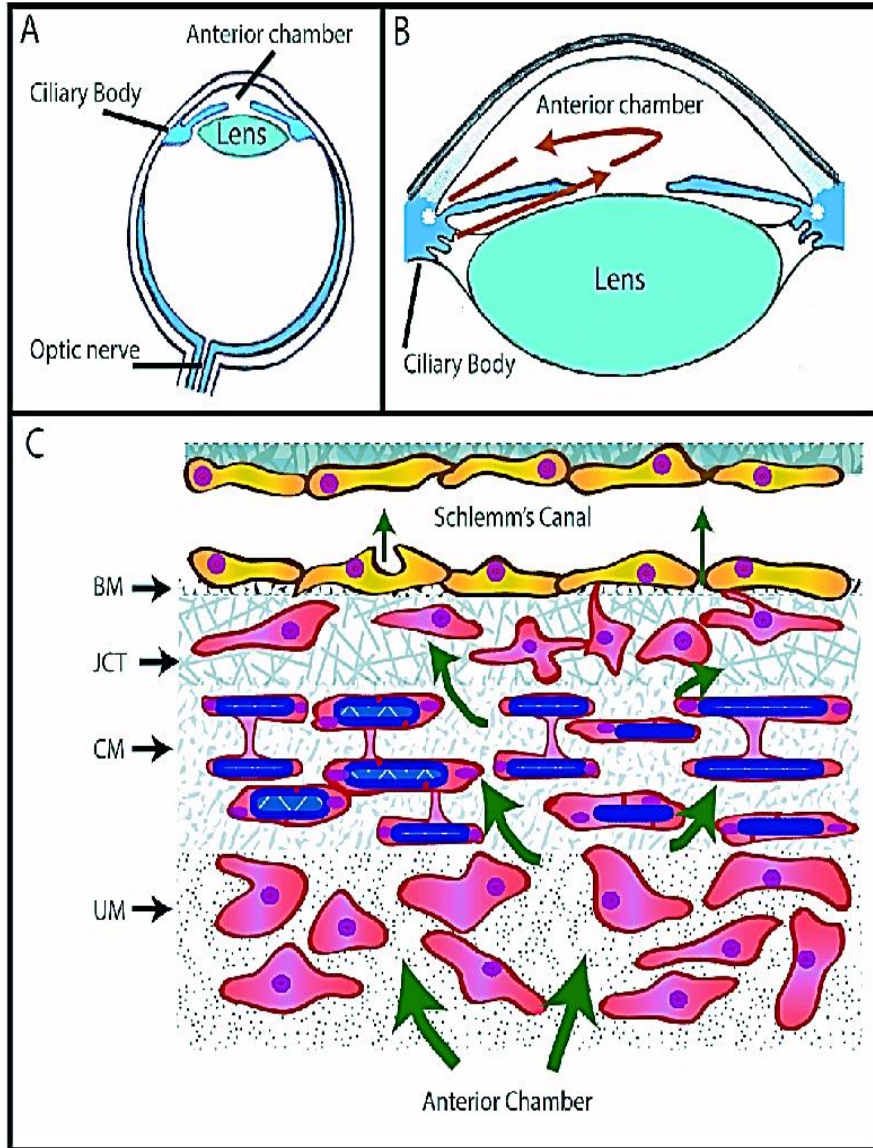


- Descemet's membrane become continuous with the Trabecular meshwork (**spaces of Fontana**)
- The endothelium on the posterior surface of the cornea extend & become reflected on the anterior surface of iris



Canal of Schlemm & Spaces of Fontana

- The spaces of Fontana : small spaces found at the irido-corneal angle, where the cornea meet with the iris.
- These spaces found within the trabecular meshwork (spongy tissue)& involved in the drainage of aqueous humor
- The spaces facilitate the flow of aqueous humor by providing passageways for the fluid to move before it enters Schlemm's canal → help maintain balance between aqueous humor production & drainage

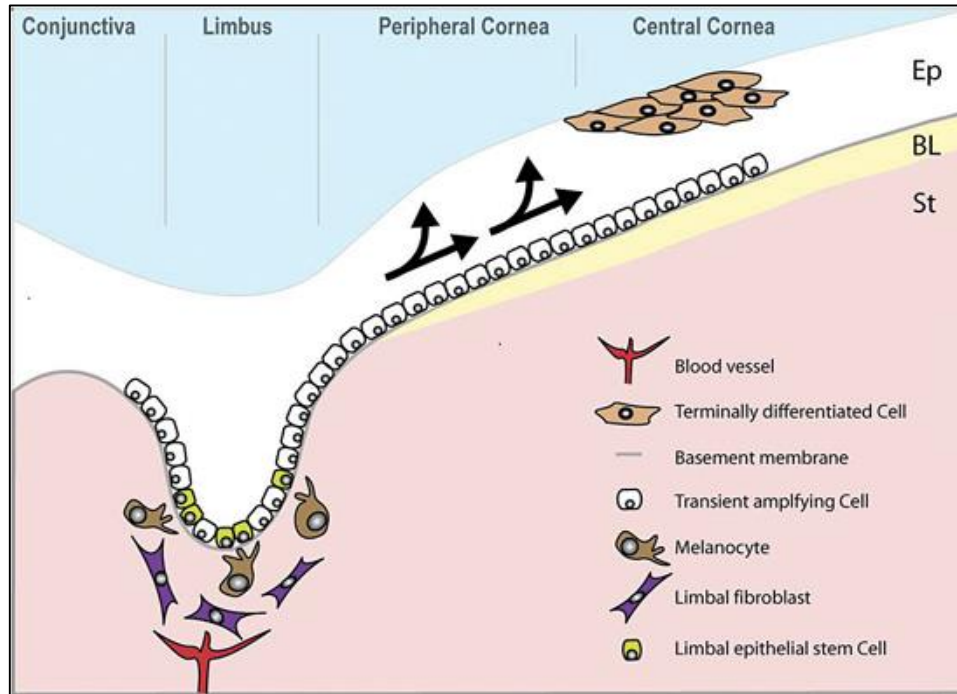


- Schematic of the trabecular meshwork and Schlemm's canal

Aqueous humor flows from the anterior chamber through the 3 layers of the trabecular meshwork called :

- 1- Uveoscleral meshwork (UM)
- 2- Corneoscleral meshwork (CM)
- 3- The juxtacanalicular tissue (JCT)

Aqueous humor (arrows) then crosses the basement membrane (BM) of Schlemm's Canal either paracellularly or transcellularly and enters into Schlemm's Canal.



The limbal epithelial stem cells are important for corneal epithelial cell renewal & regeneration . Corneal epithelial cells have a lifespan of 7–10 days

Limbal stem cell deficiency (LSCD) causes include: chemical & thermal burns, multiple ocular surgeries involving the limbal region, contact lens wear, and ocular surface inflammatory diseases.

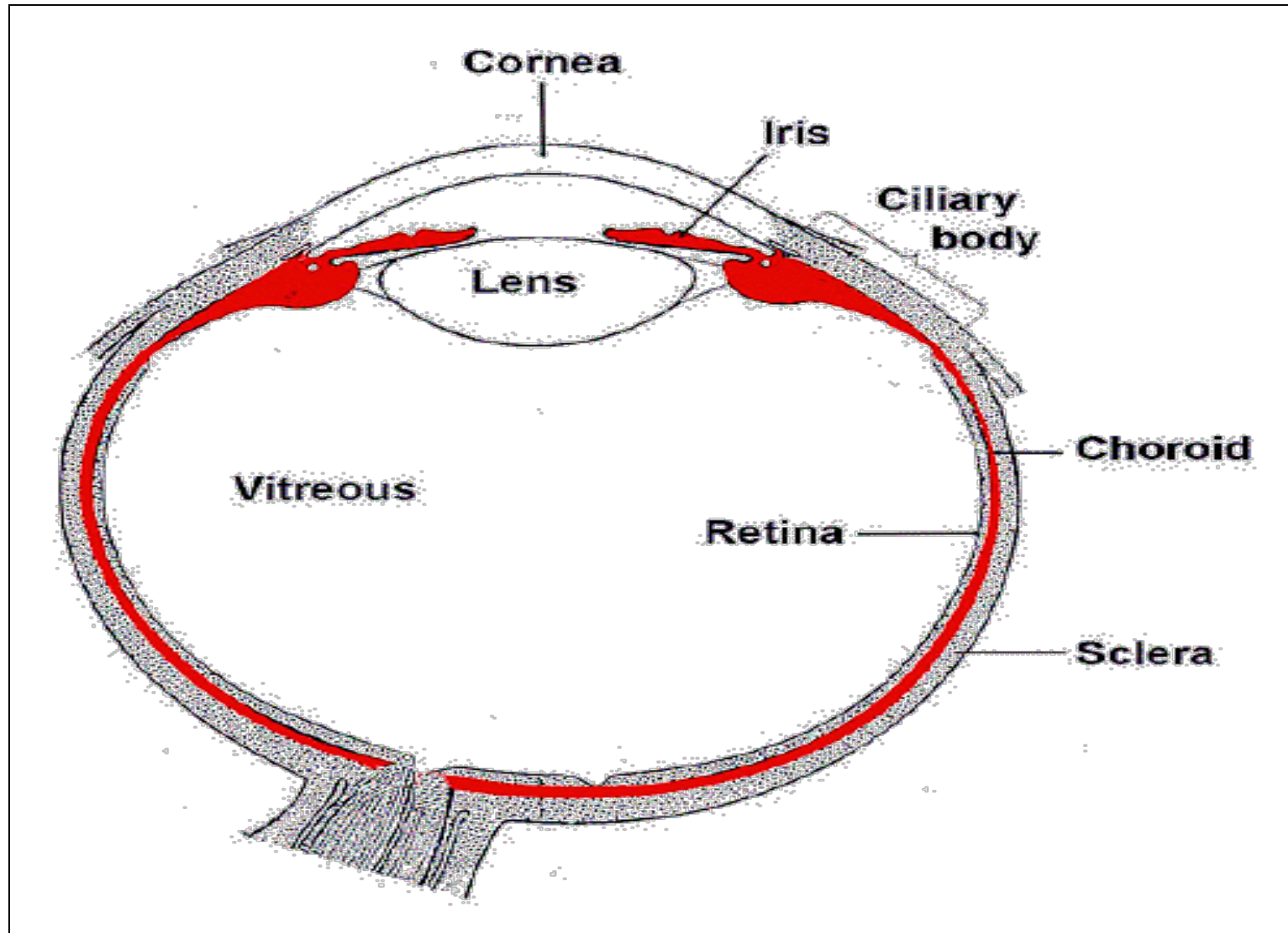
The middle (vascular) layer: uvea

A- Iris

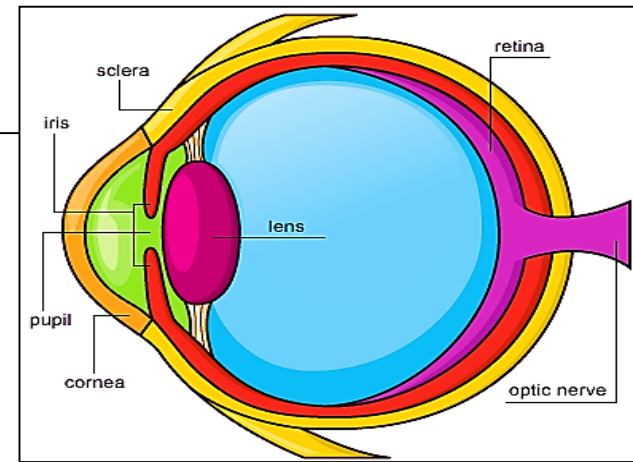
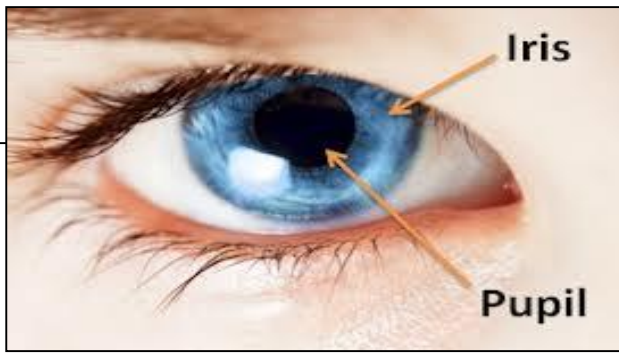
B- Ciliary body

C- Choroid

The middle (vascular, muscular, pigmented) layer of the eye



The Iris



- is the colored disc present between the anterior & posterior chambers of the eye (diaphragm of the eye)
- The pupil is the round open in the center of the iris
- The iris changes the pupil size to control amount of light & the depth of focus
- Its posterior surface share in the formation of aqueous humor
↓
mainly ciliary body³¹

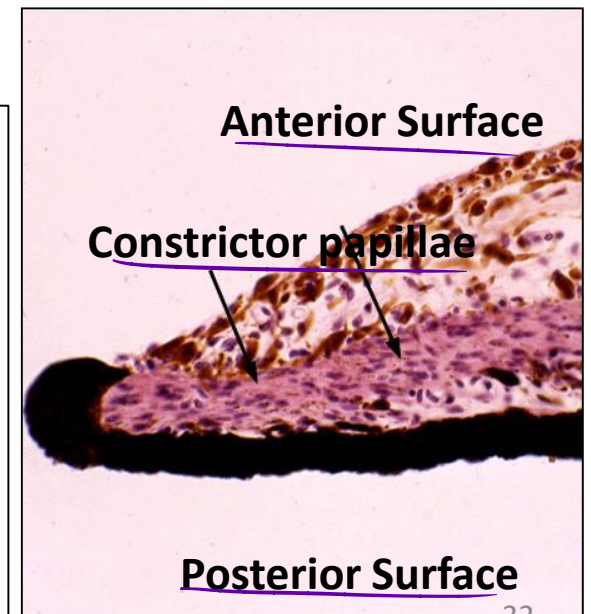
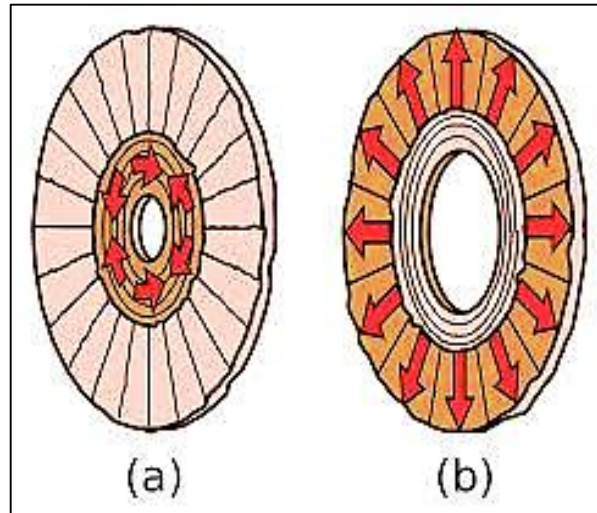
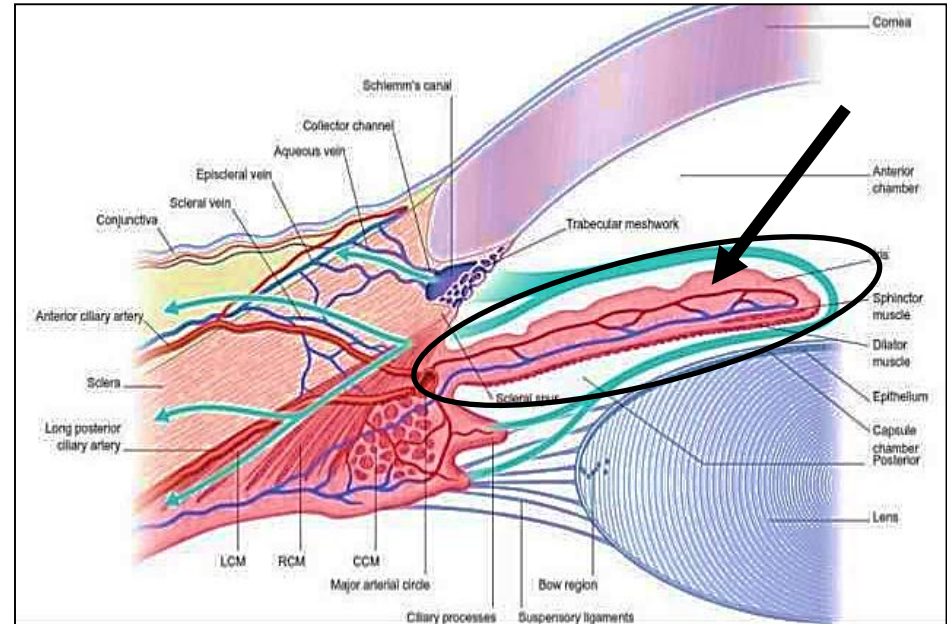
Structure of the iris

1- Anterior surface

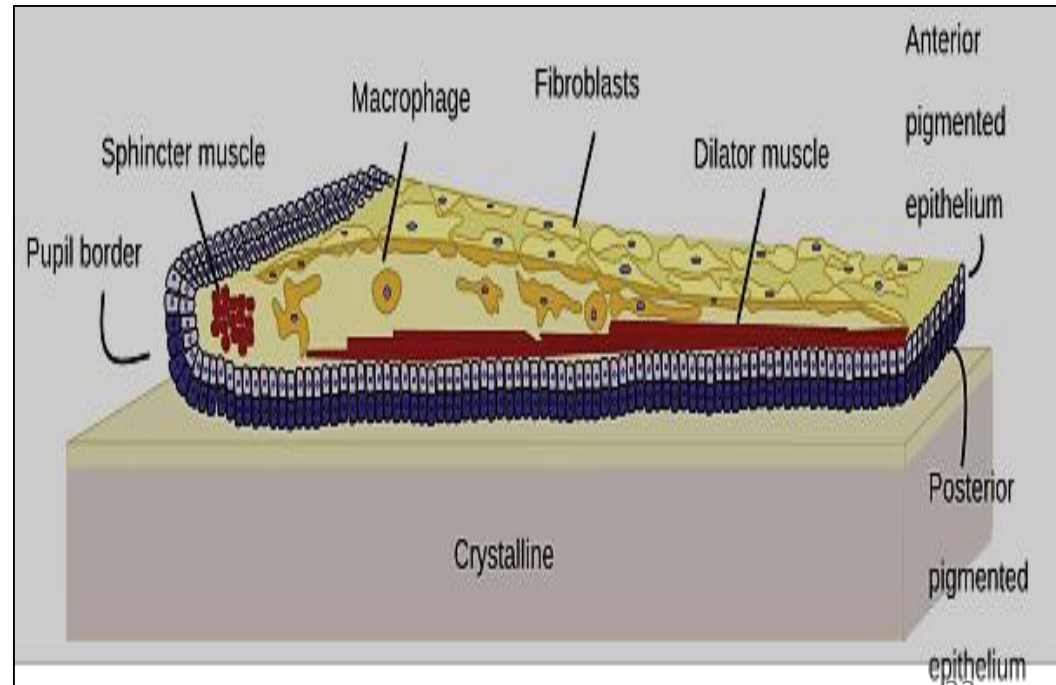
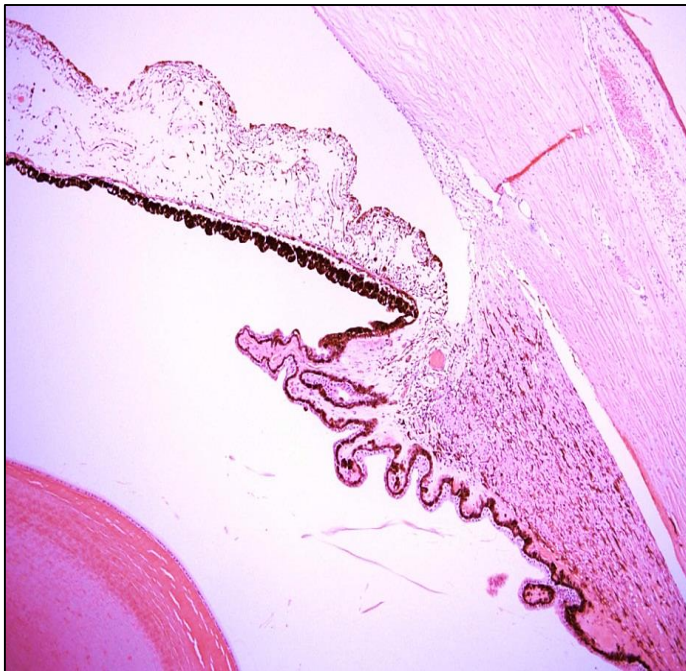
2- Stroma

- a. Loose vascular C.T.
- b. Muscles of the iris (2 ms)

3- Posterior surface



- **Anterior surface**: lined by **fibroblast** & **melanocytes** (**eye color**) is continuous with that covering the posterior surface of the **cornea**
- **Posterior surface**: made of **2 layers of pigmented cuboidal epithelium** continuous with that covering the **Ciliary body**, which prevents **stray light rays** from **interfering** with **image formation**

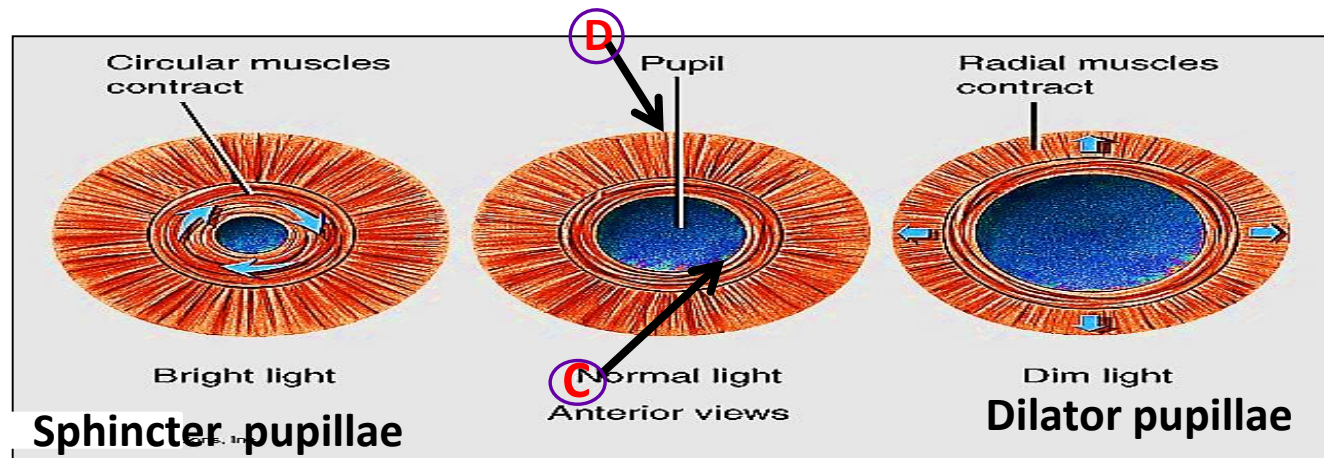


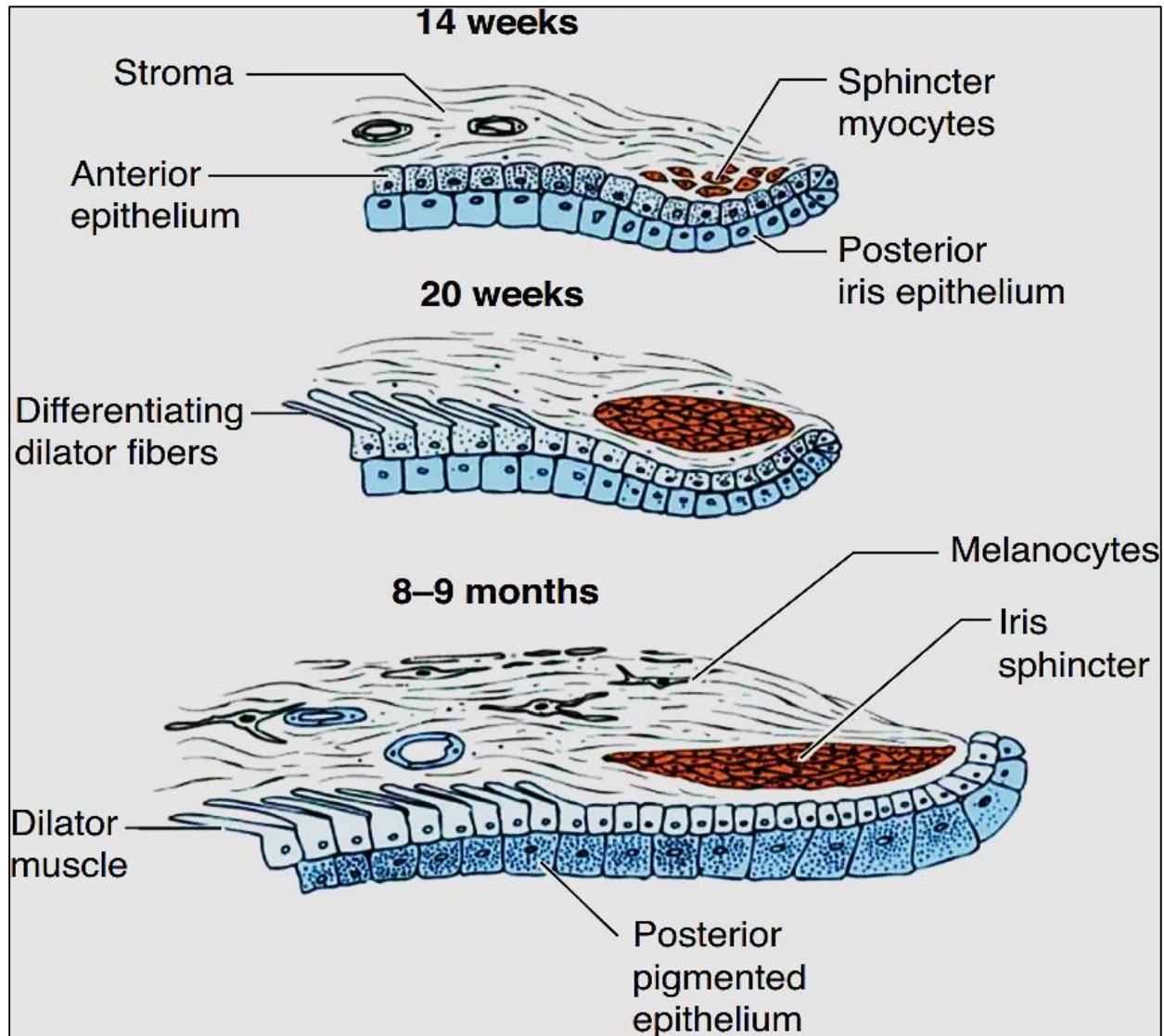
- Stroma (Inside of iris) :

a. Loose vascular C.T., rich in B.V. , fibroblasts, melanocytes

a. Muscles of the iris:

- The dilator pupillae muscle: is myoepithelial cells Radially arranged at the periphery of the iris. Its contraction → dilate pupil (sympathetic)
- The sphincter pupillae muscle: circular band of smooth ms, encircling the pupil. Its contraction → constrict the pupil ... (parasympathetic)

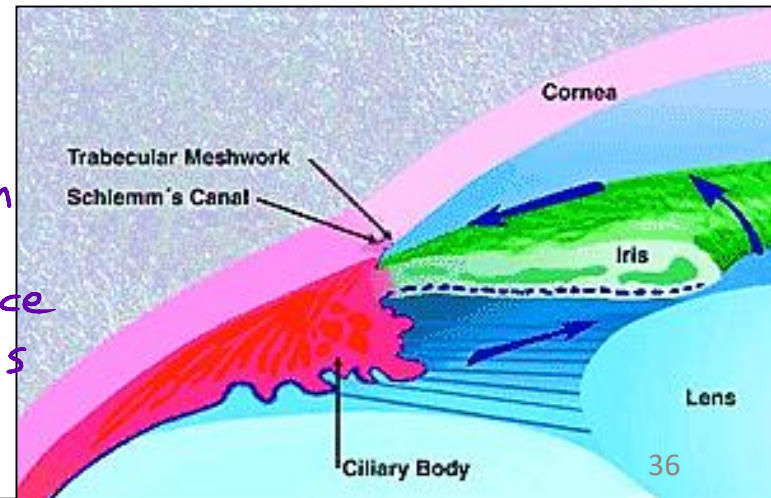




Dilator pupillae muscles are myoepithelial

The ciliary body

- Is a thick, triangular part at the level of the lens (composed of *Ciliary processes* & *Ciliary muscles*)
- Ciliary body located behind the iris & around the lens
Is positioned like a ring around the lens
- The Ciliary processes are attached to the suspensory ligaments of the lens & its epithelium form aqueous humor
- Ciliary body has 3 functions:
 1. Accommodation → near and far vision
 2. Production of aqueous humour
 3. Maintenance of lens zonules (ligaments)
↳ + posterior surface of iris

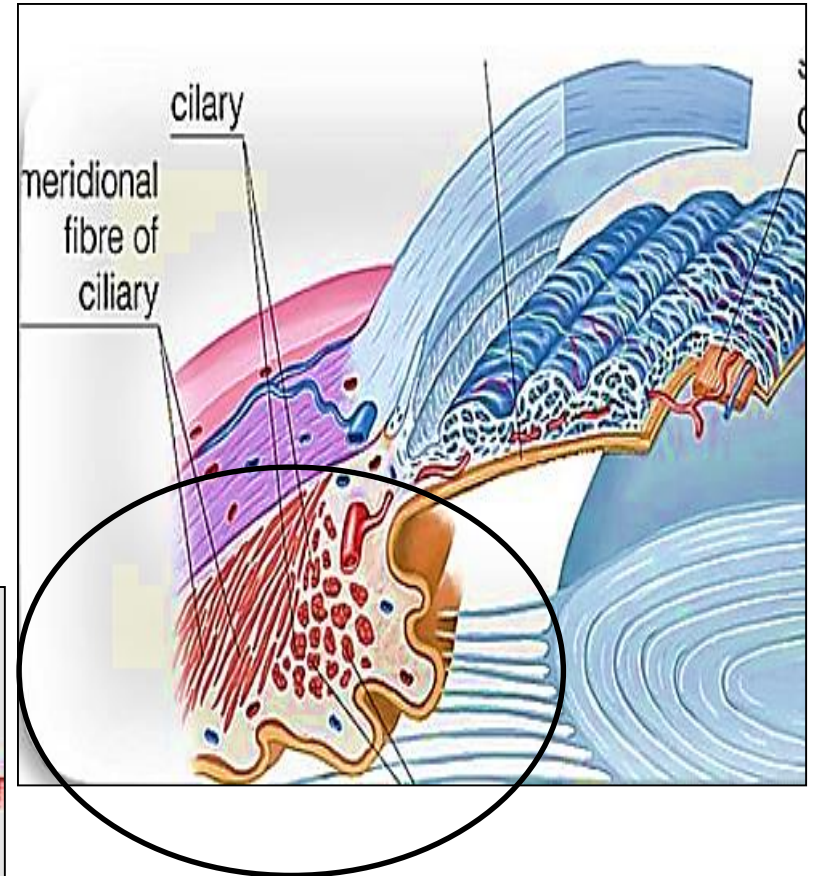
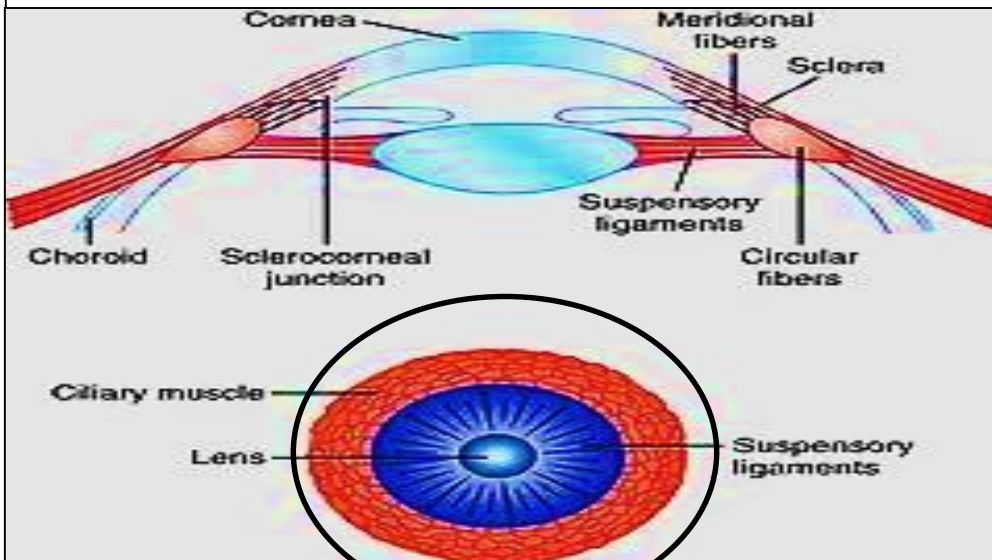


Histological structure of Ciliary body :

1- The ciliary epithelium

2- Vascular stroma

3- The ciliary muscle



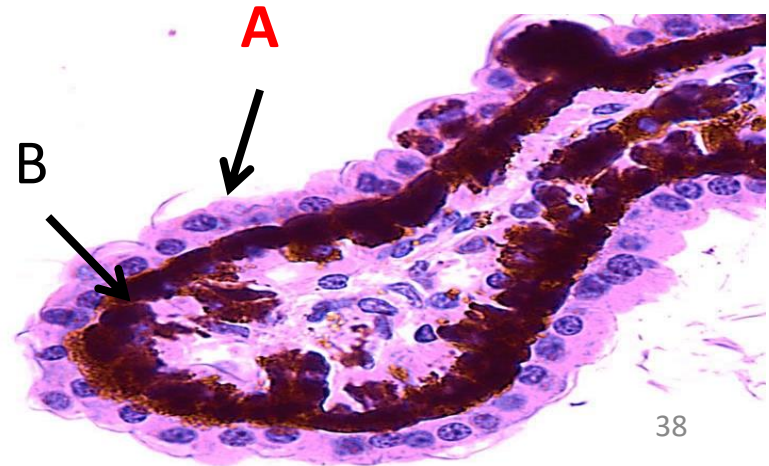
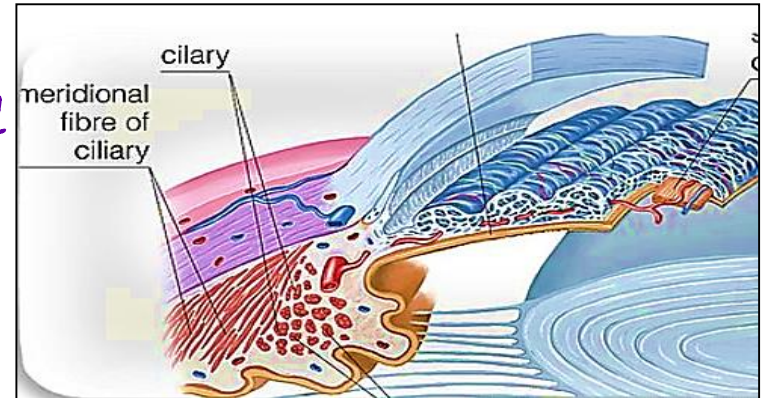
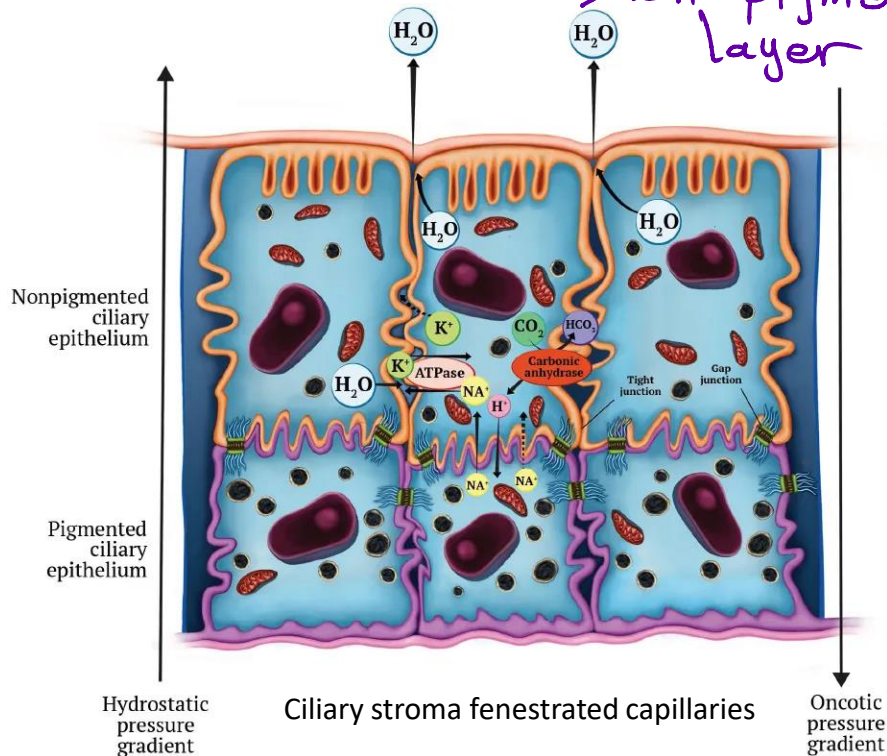
1- The ciliary epithelium:

a) It composed of two layers of cuboidal epithelium.

b) The surface cell layer is non-pigmented (A) ???

while the deep cell layer is pigmented (B) rich in melanin
& continues with retinal pigmented epithelium

c) It secretes the aqueous humor
→ non-pigmented layer

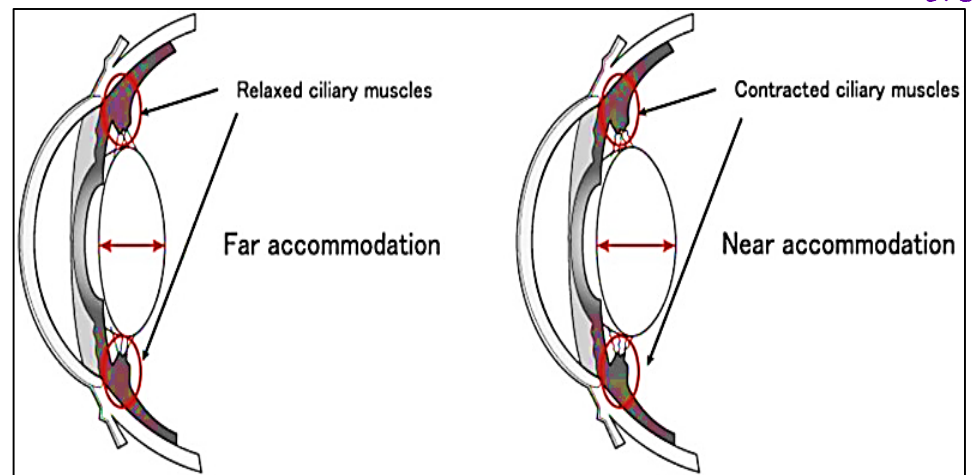
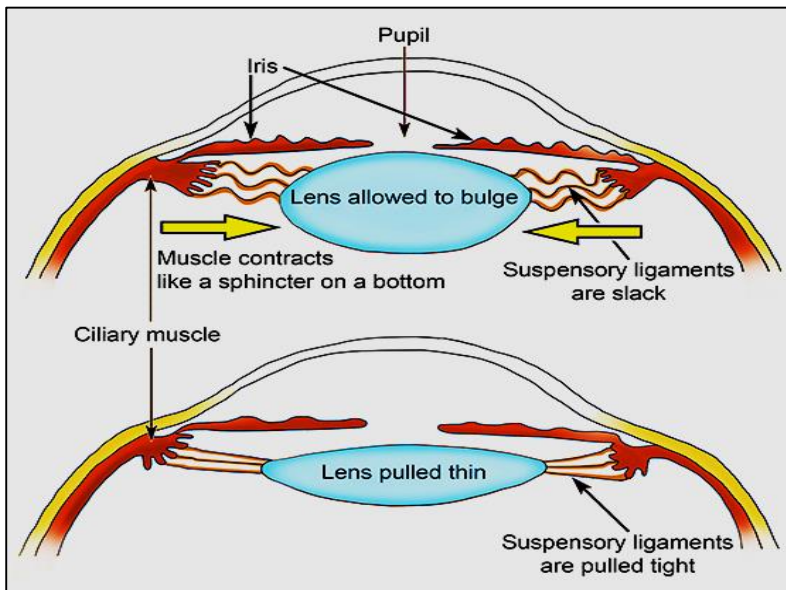


2- Stroma:

loose, highly vascular C.T., elastic fibers, & melanocytes

3- The ciliary muscle:

- smooth muscles attached to the suspensory ligament of the lens.
- They are responsible for the process of Accommodation



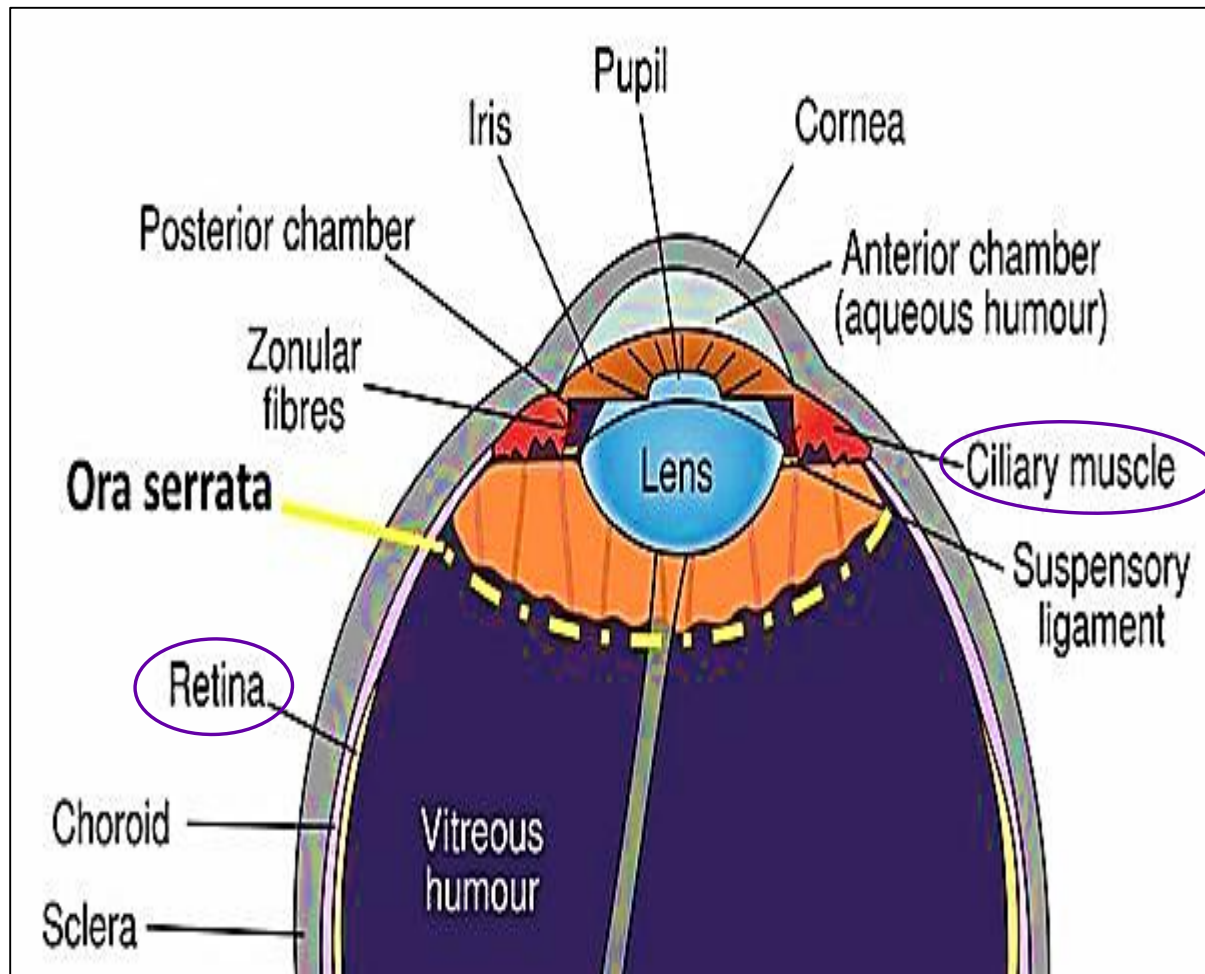
Accommodation :

the process by which the eye changes the shape of the lens to focus on objects at different distances

Accommodation is controlled by the ciliary muscle & zonules (ligaments of the lens)

The ciliary ms is a smooth ms when it contracts or relaxes it changes the shape of the lens

- **Contraction** of the ciliary ms **reduces** the tension on the ligaments allows the lens to become more rounded → ↑curvature helps focus on near objects
- **Relaxation** of the ciliary ms **increases** the tension on the ligaments → cause the lens to flatten helps focus on far objects



Ora serrata and pigmented epithelium

Is located at the junction between the ciliary body & retina

it defines the boundary between the neural retina (involved in vision) and the ciliary body (involved in production of aqueous humor & accommodation)

Thank you

