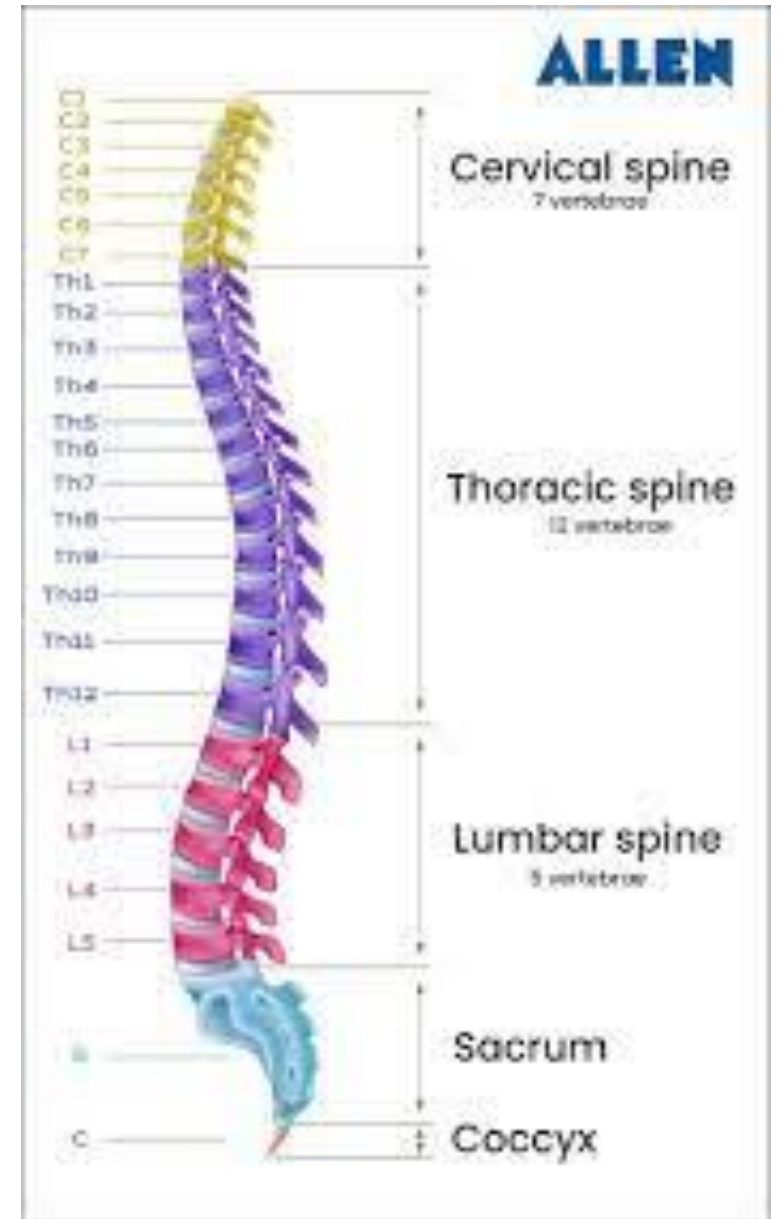
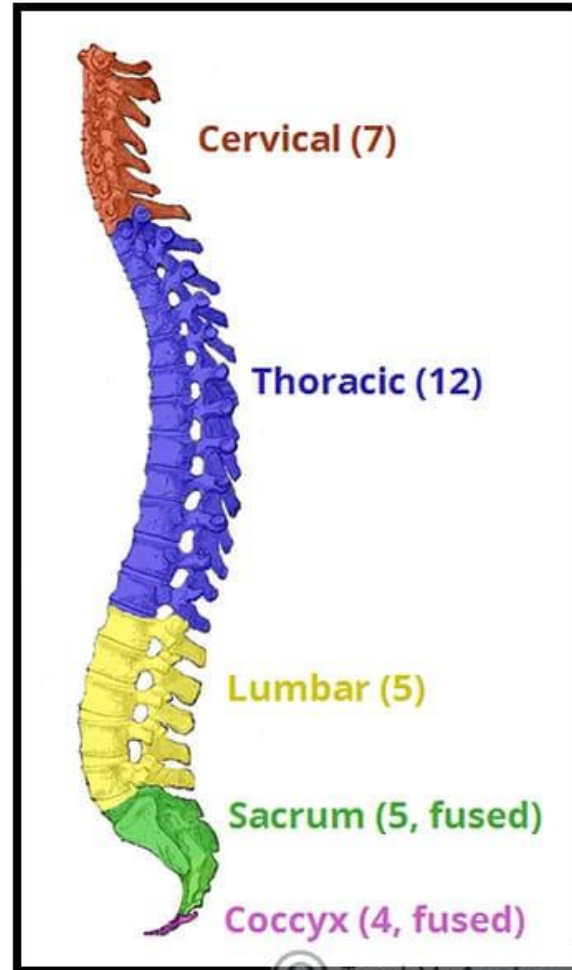
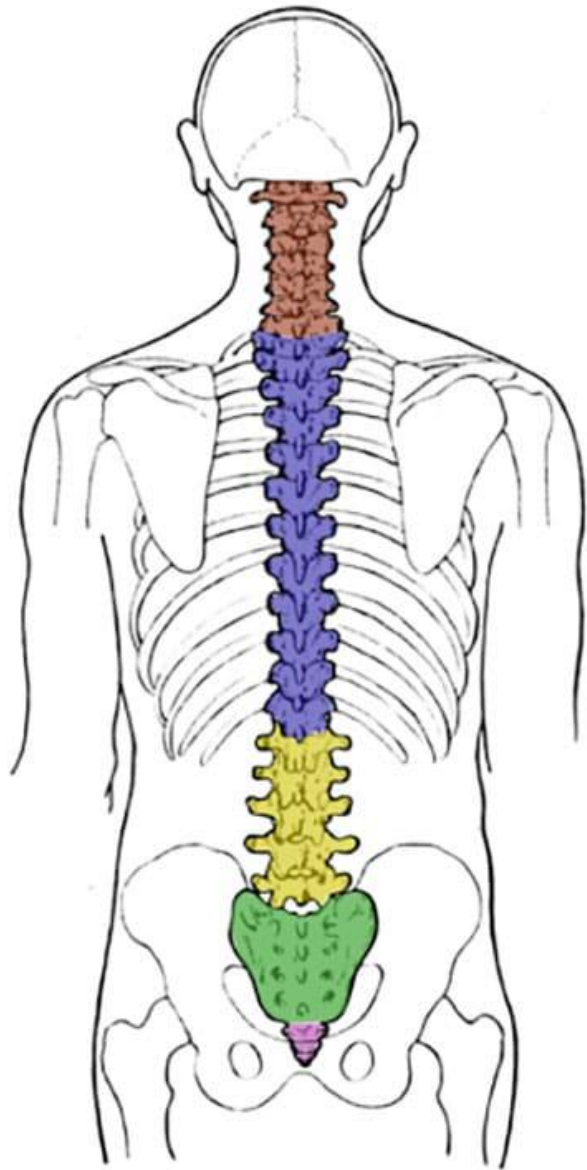


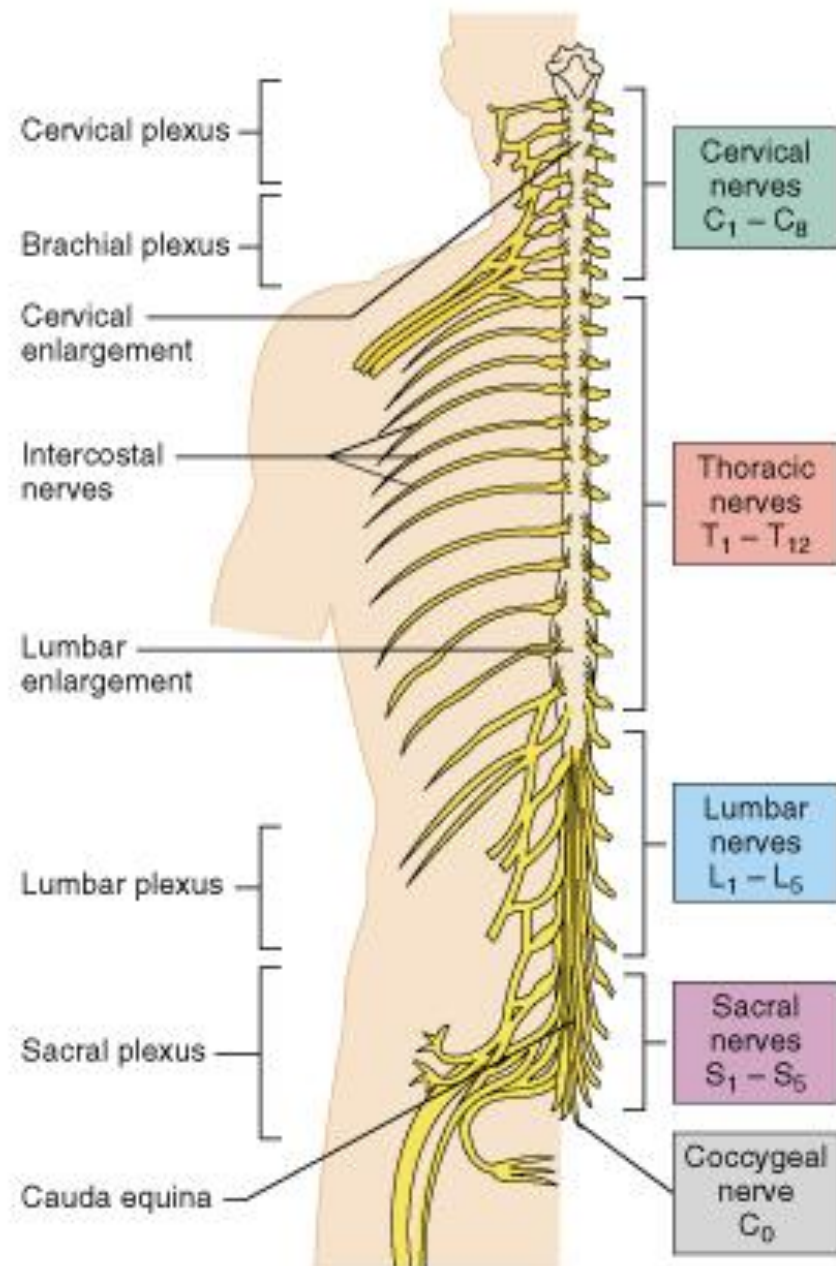


# NERVES OF THE LOWER LIMB OF THE LOWER LIMB

---

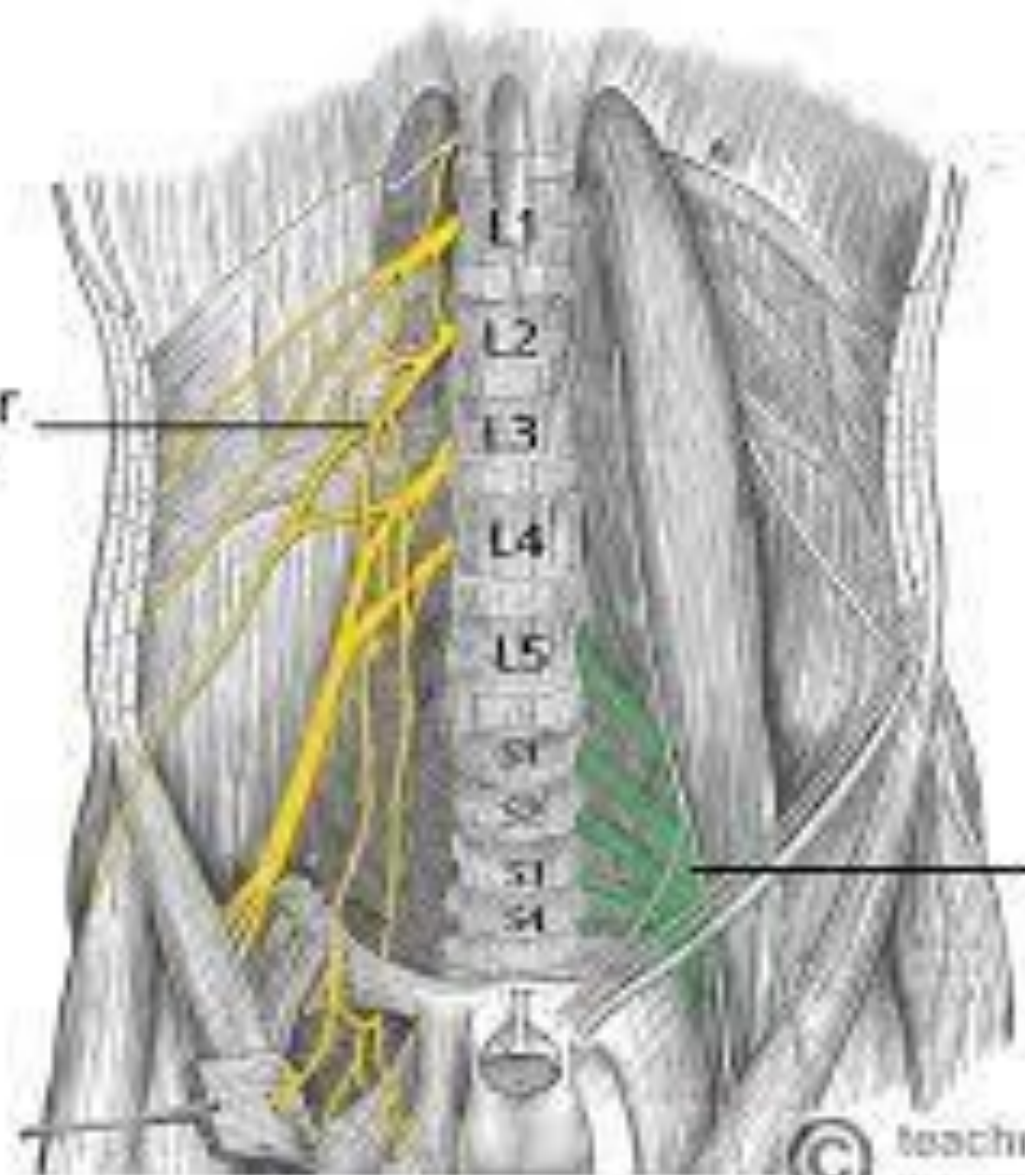
Dr. Amal Albtoosh







Lumbar  
Plexus



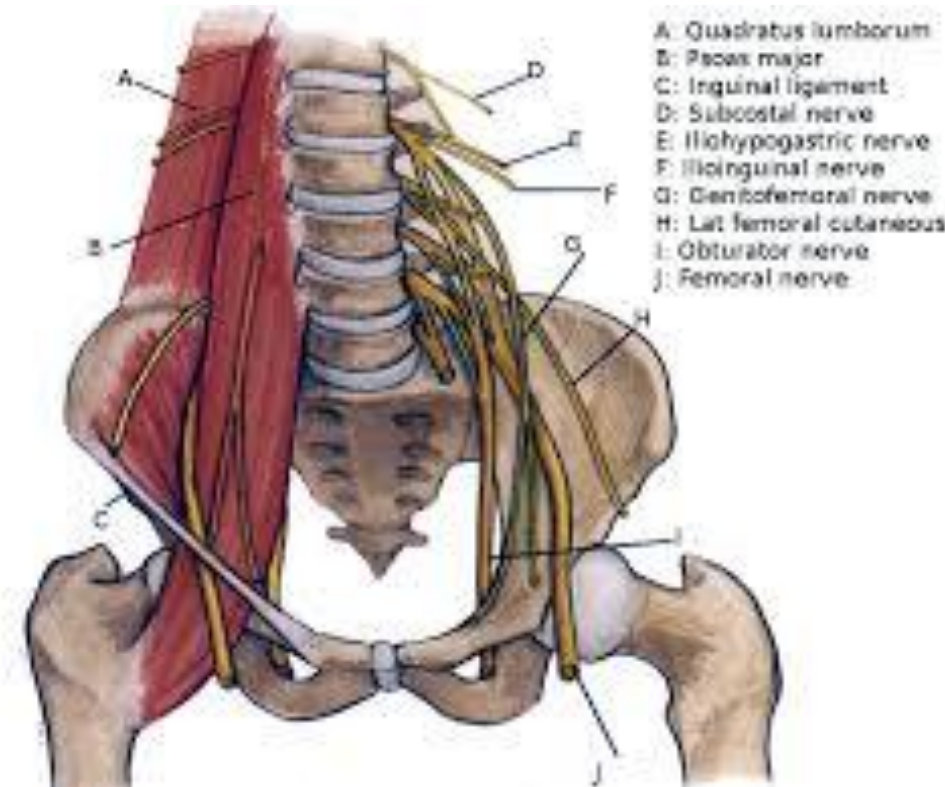
Sacral  
Plexus

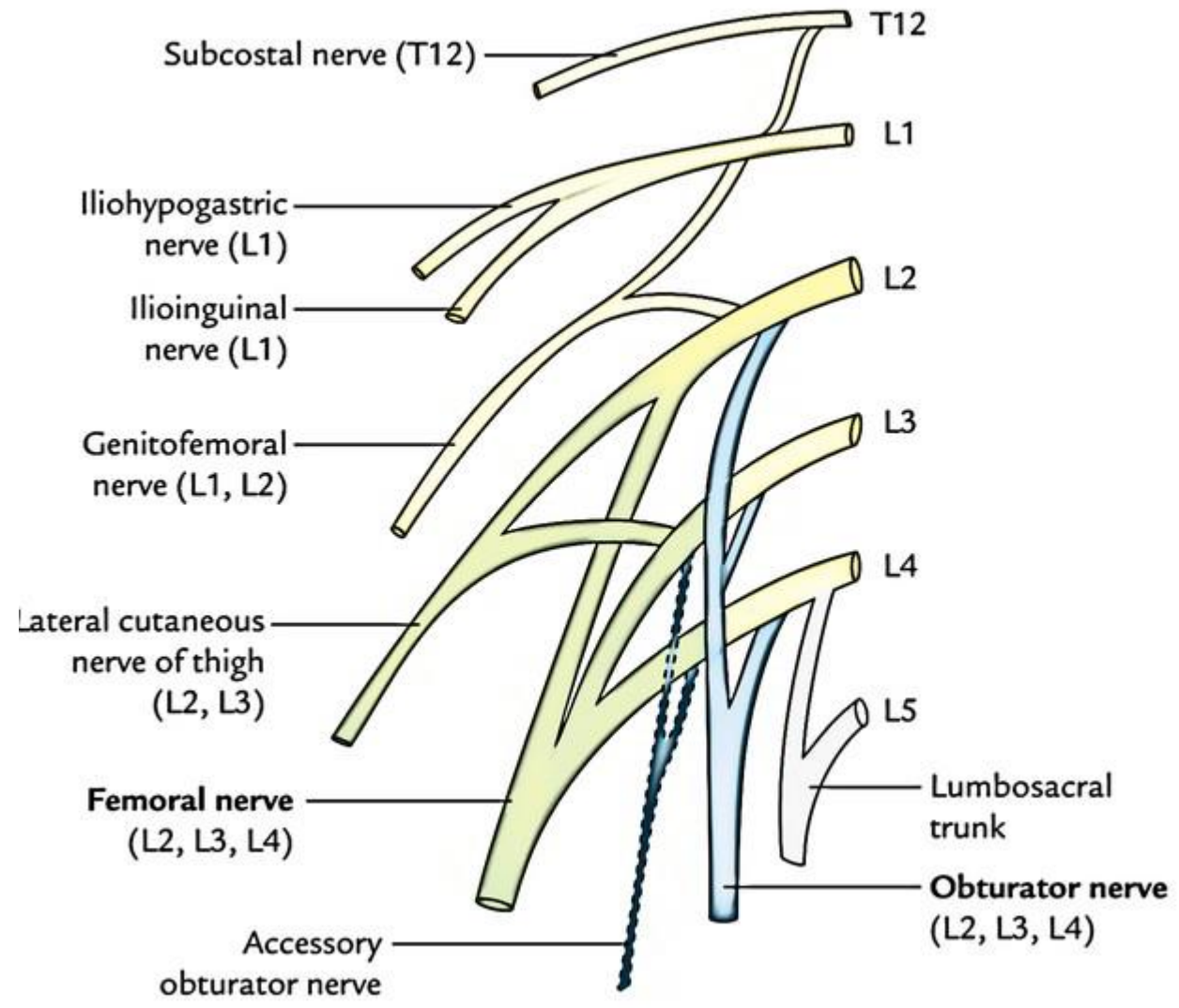


teachmeanatomy

# Lumbar plexus

- ❖ Is formed by the union of the ventral rami of the first three lumbar nerves and a part of the fourth lumbar nerve.
- ❖ other references: It is formed by the divisions of the first four **lumbar** nerves (L1-L4) and from contributions of the subcostal nerve (T12), which is the last thoracic nerve.
- ❖ Lies anterior to the transverse processes of the lumbar vertebrae within the substance of the psoas muscle.





## Obturator nerve (L2-L4)

- ❖ Arises from the lumbar plexus and enters the thigh through the obturator foramen.

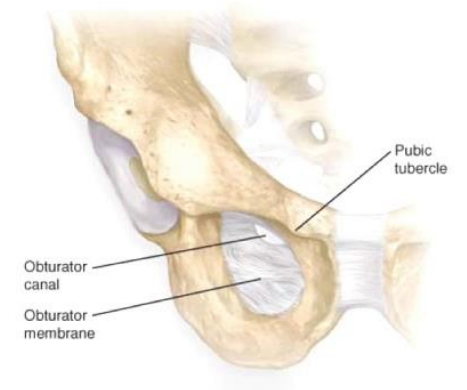
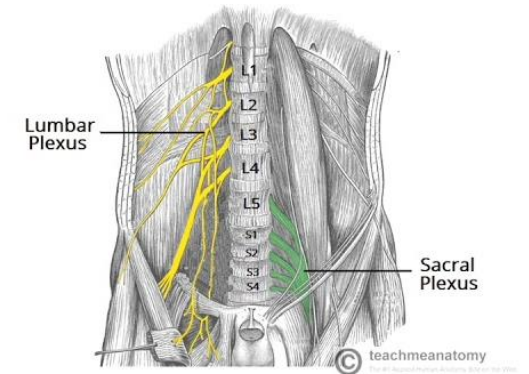
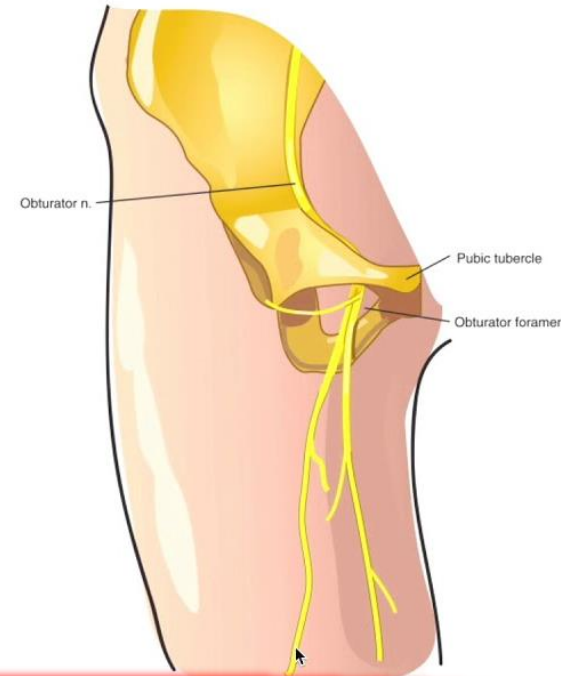
- ❖ Divides into anterior and posterior branches.

### 1. Anterior branch

- Innervates the adductor longus, adductor brevis, Gracilis, and pectineus muscles.

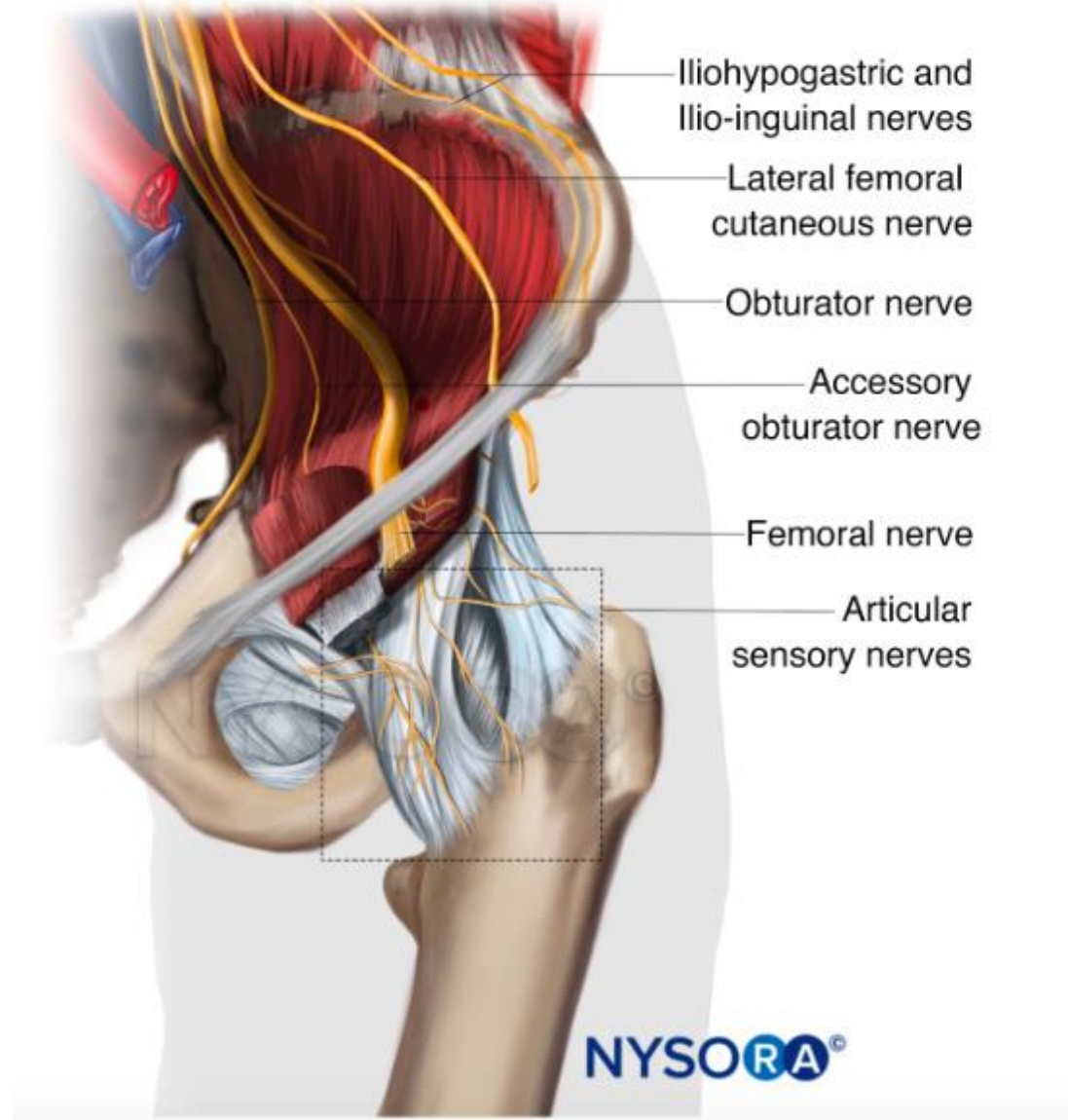
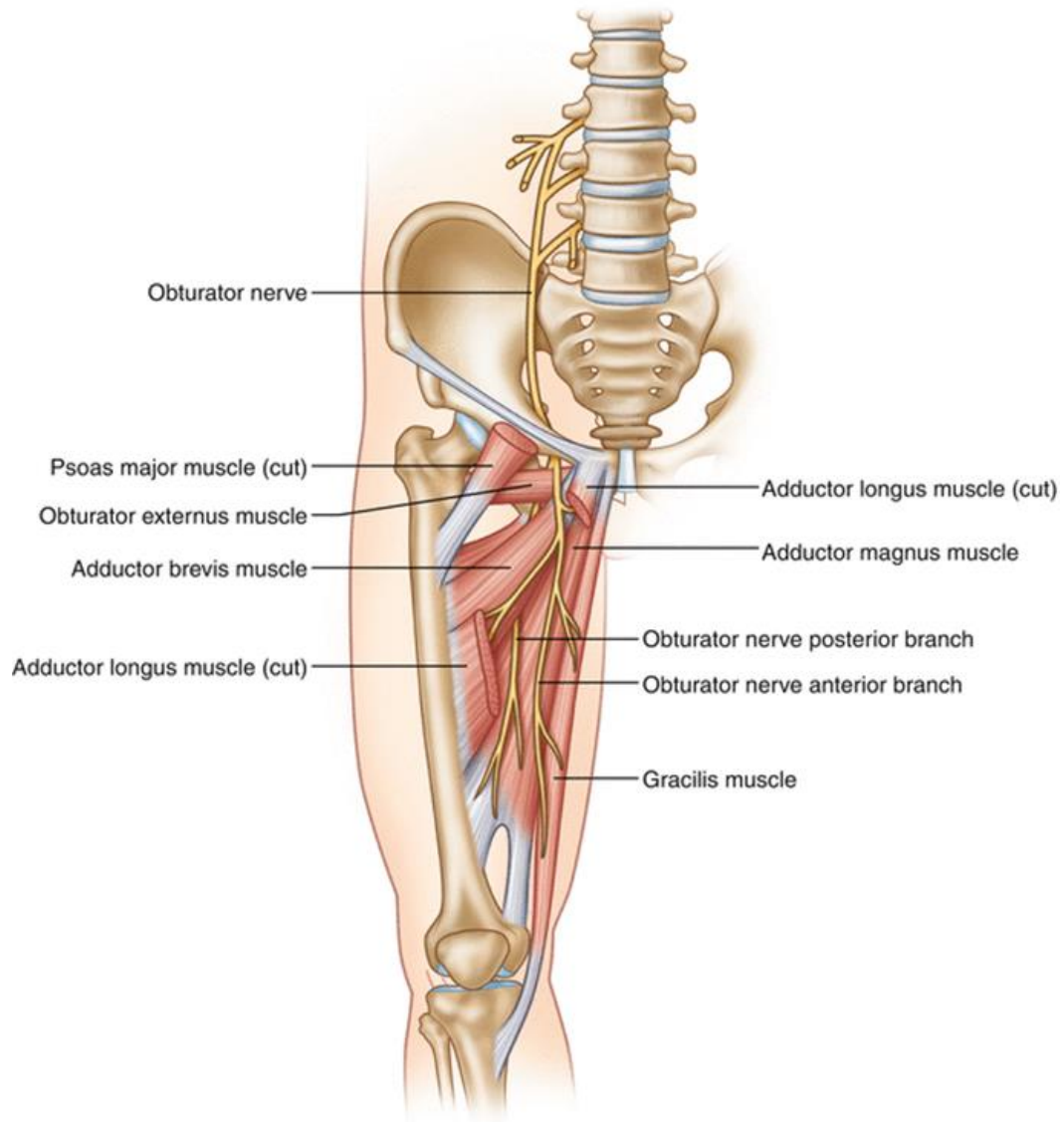
### 2. Posterior branch

- Innervates the anterior obturator externus, adductors brevis and magnus, as well as the knee joint.



An accessory obturator nerve (L3, L4) is present, almost 10% of the time.

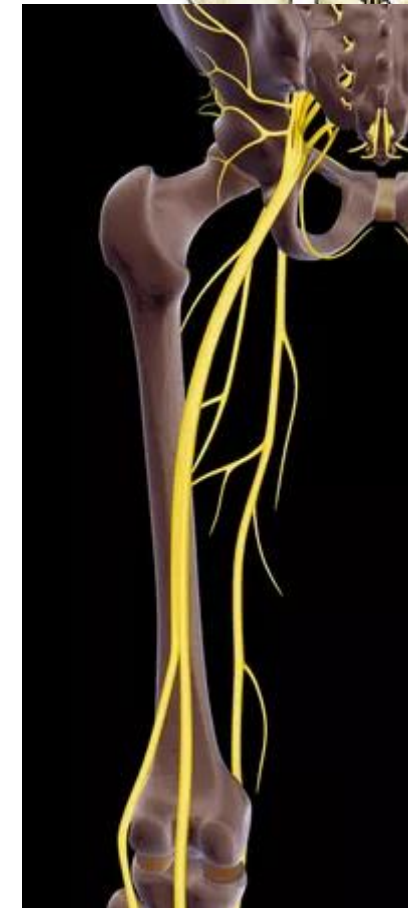
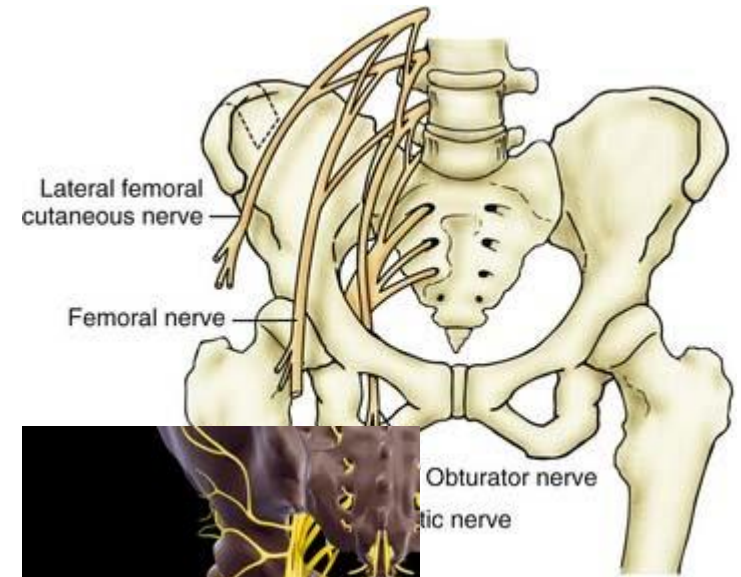






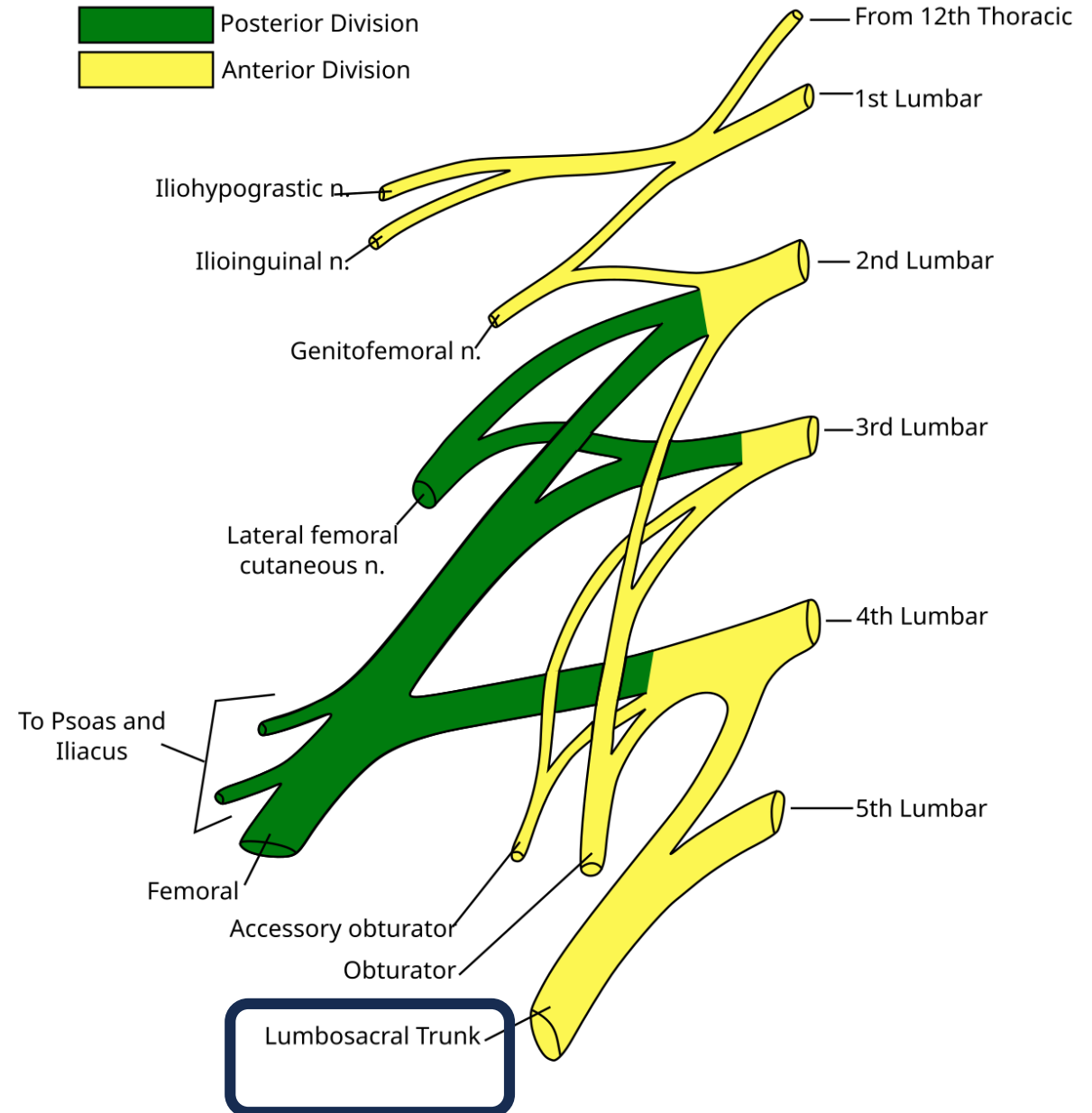
## Femoral nerve (L2-L4)

- Arises from the lumbar plexus within the substance of the psoas major, emerges between the iliacus and psoas major muscles, and enters the thigh by passing deep to the inguinal ligament and lateral to the femoral sheath.
- Gives rise to
  - ✓ Muscular branch
  - ✓ Articular branch to the hip and knee joints
  - ✓ Cutaneous branches, including the anterior femoral cutaneous nerve and the saphenous nerve, which descends through the femoral triangle and accompanies the femoral vessels in the adductor canal.



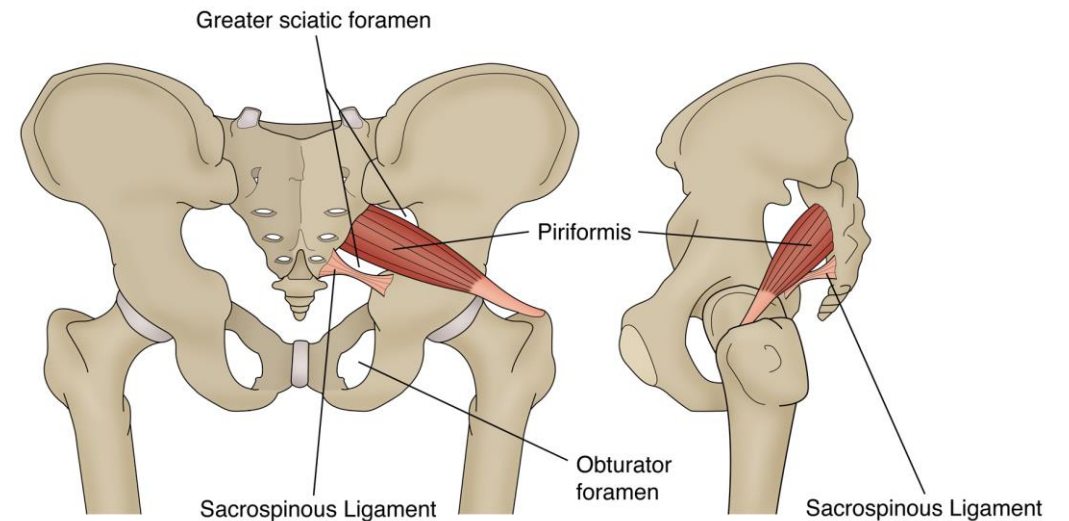
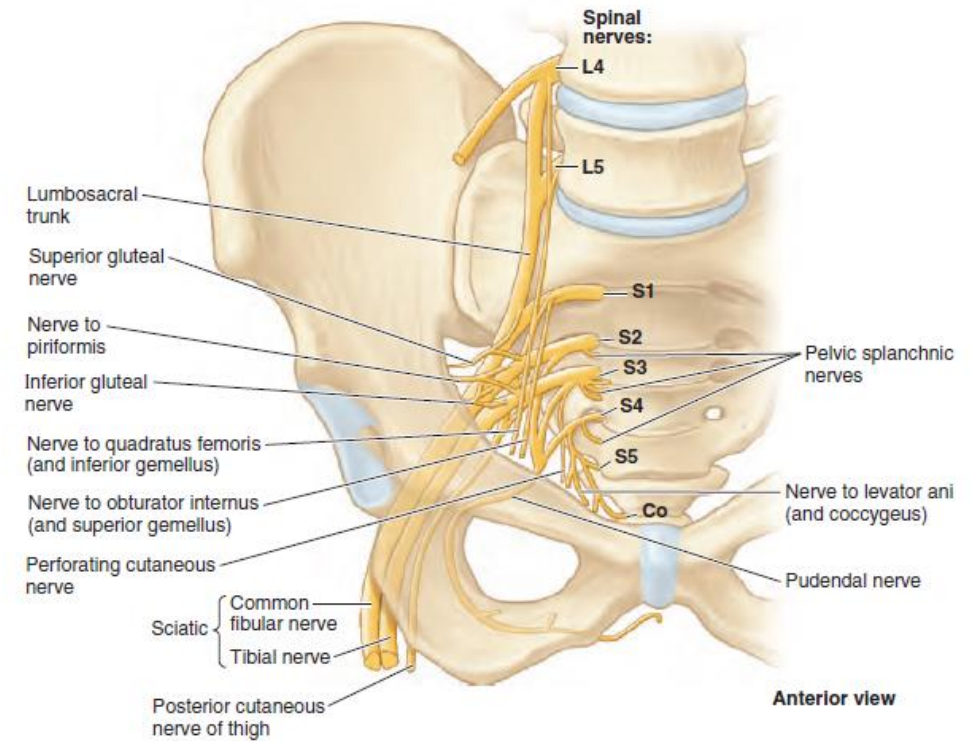
Obturator nerve  
tic nerve

**The lumbosacral trunk (L4, L5)** passes over the ala (wing) of the sacrum and descends into the pelvis to participate in the formation of the sacral plexus with the anterior rami of S1–S4 nerves

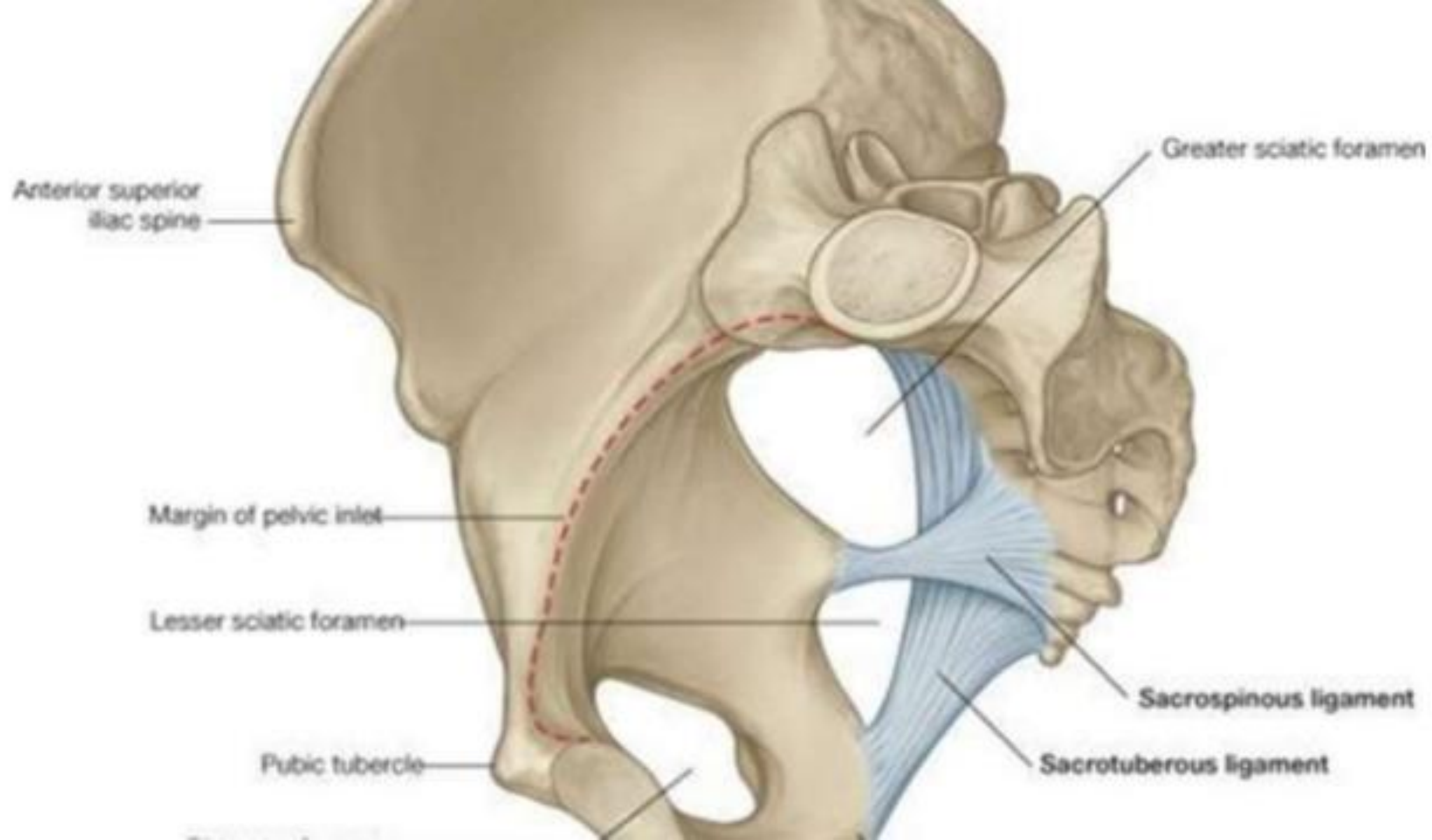


# Sacral plexus

- The **sacral plexus** is located on the posterolateral wall of the lesser pelvis.
- Most branches of the sacral plexus leave the pelvis through the *greater sciatic foramen*
- *Roots: ventral rami of L4- S3 (or S4)*

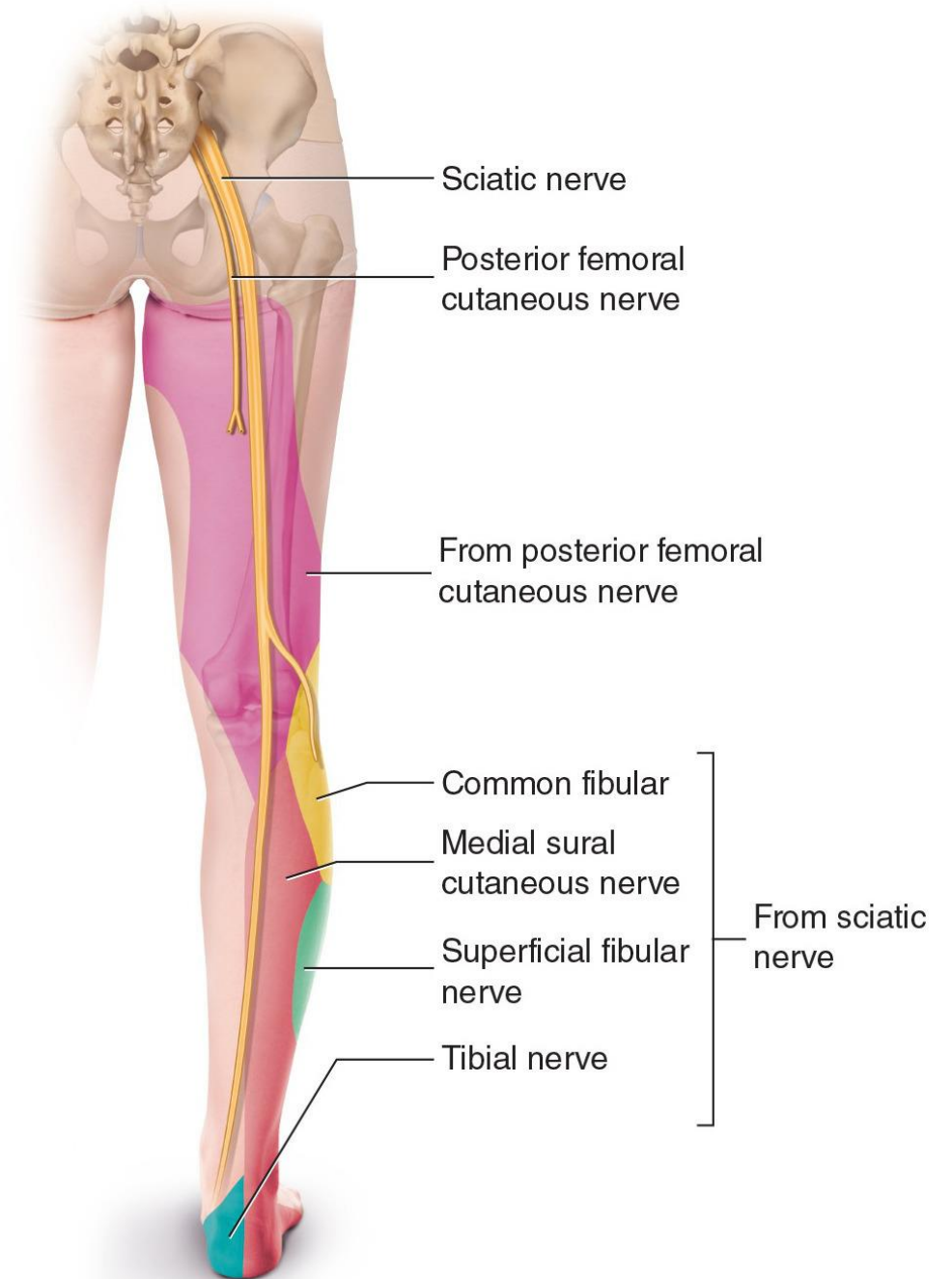






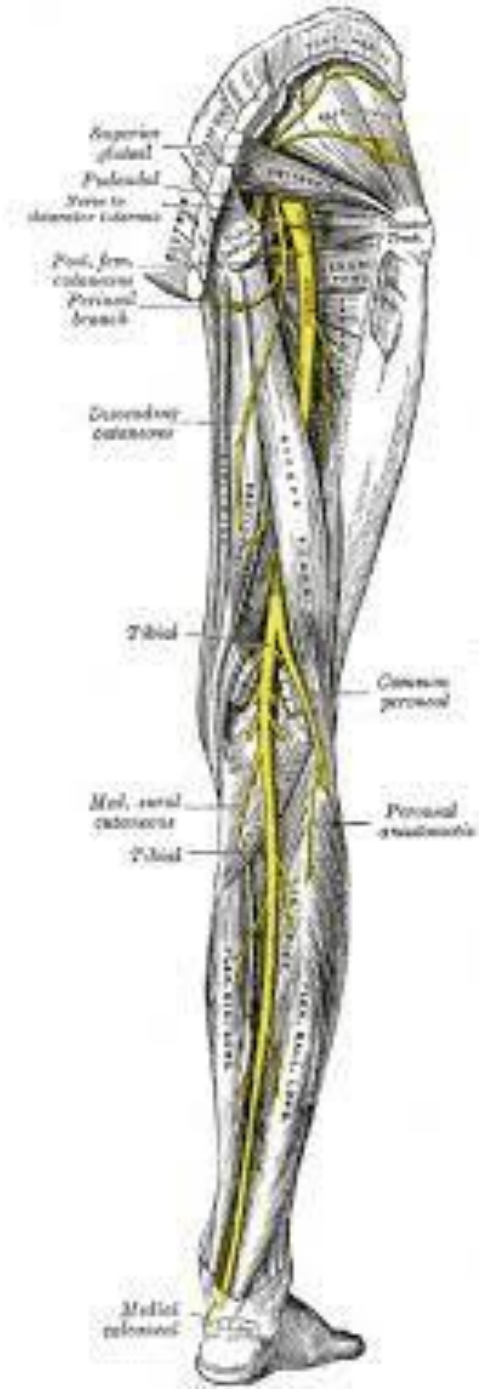
## Posterior femoral cutaneous nerve (S1-S3)

- Arises from the sacral plexus and enters the buttock through the greater sciatic foramen below the piriformis.
- Descends on the posterior thigh.
- Innervates the skin of the buttock, thigh, and calf as well as the scrotum or labia majora.



## • **SCIATIC NERVE (L4-S3)**

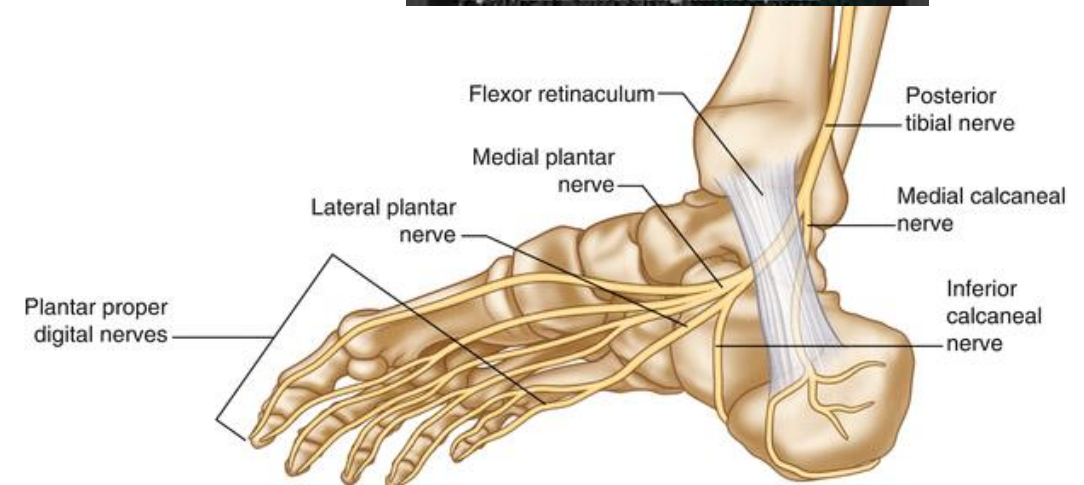
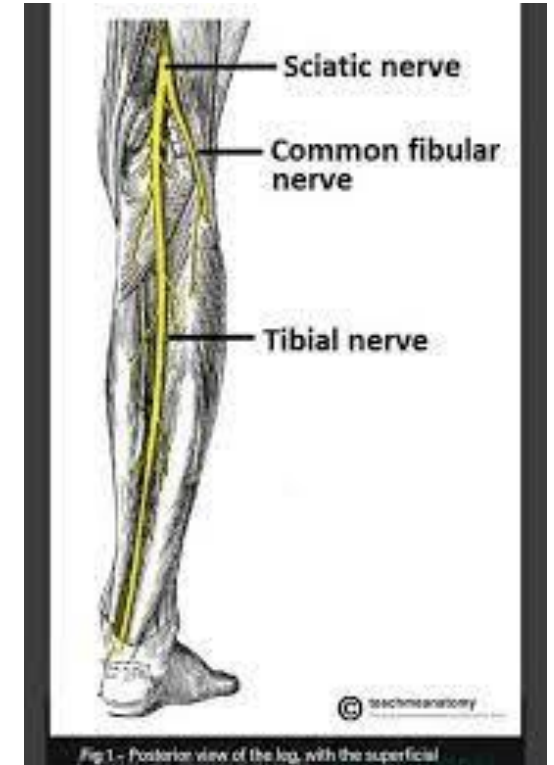
- Arises from the sacral plexus and is the largest nerve in the body.
- Enters the buttock through the greater sciatic foramen INFERIOR to the piriformis.
- Divides at the superior border of the popliteal fossa into the:
  - **TIBIAL NERVE**
  - **THE COMMON FIBULAR NERVE**





## Tibial nerve (L4-S1)

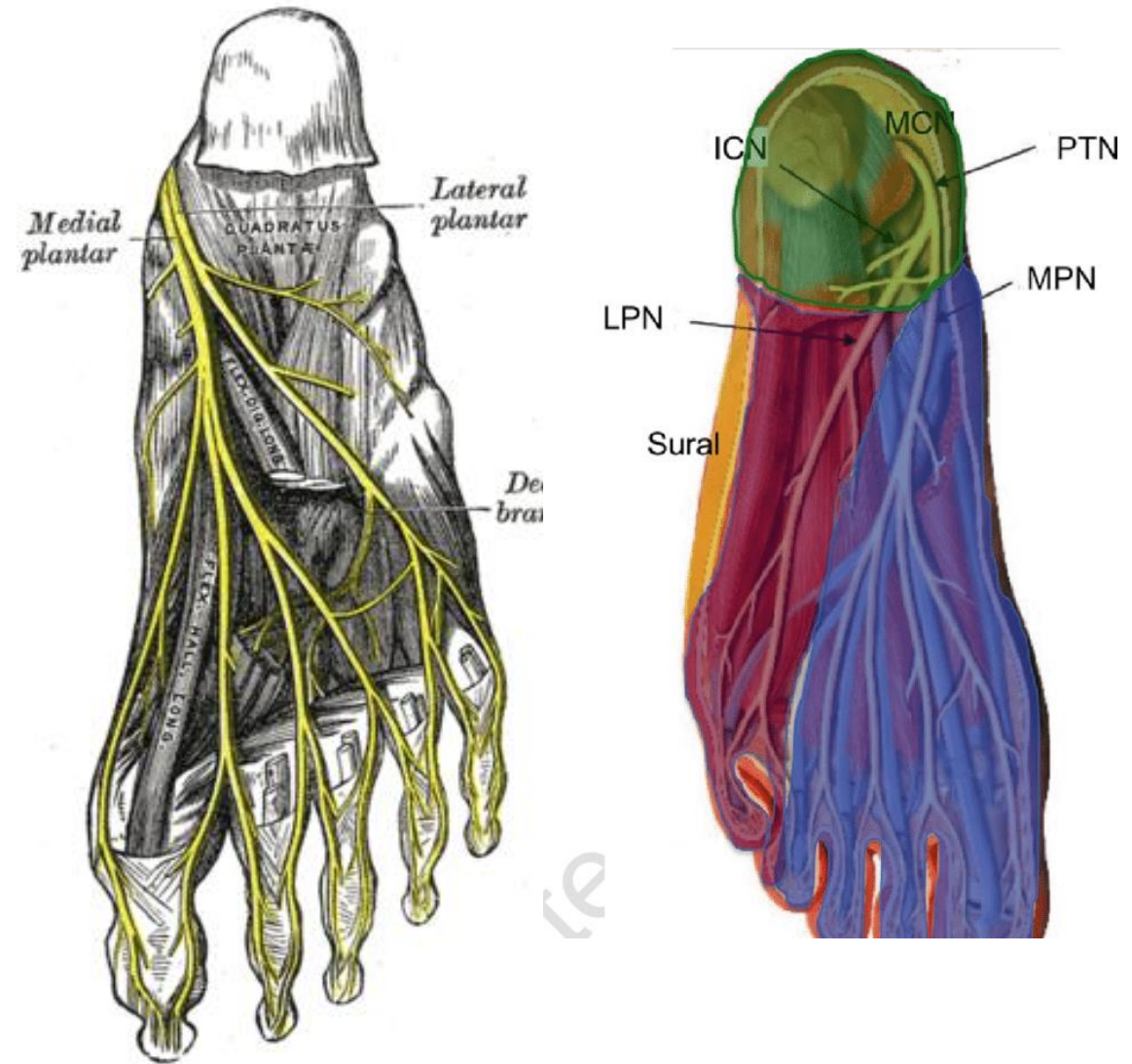
- ❑ Descends through the popliteal fossa and then lies on the posterior surface of the popliteus muscle.
- ❑ Gives rise to three articular branches to the knee joint.
- ❑ Gives rise to muscular branches to almost all posterior muscles' compartments of the thigh and leg.
- ❑ Gives rise to:
  - ✓ **THE MEDIAL SURAL CUTANEOUS NERVE**
  - ✓ **THE MEDIAL CALCANEAL BRANCH** to the skin of the heel and sole,
  - ✓ **THE ARTICULAR BRANCHES TO THE ANKLE JOINT.**
- ❑ Terminates deep to the flexor retinaculum where it divides into the **MEDIAL AND LATERAL PLANTAR NERVES.**



## TIBIAL NERVE

### (A) MEDIAL PLANTAR NERVE

- ❖ Arises beneath the flexor retinaculum as the **LARGER** terminal branch from the tibial nerve.
- ❖ Gives rise to **common digital branches** that divide into **proper digital branches**, which supply the flexor hallucis brevis, the first lumbrical muscle
- ❖ Innervates the skin of the medial three and one half toes.



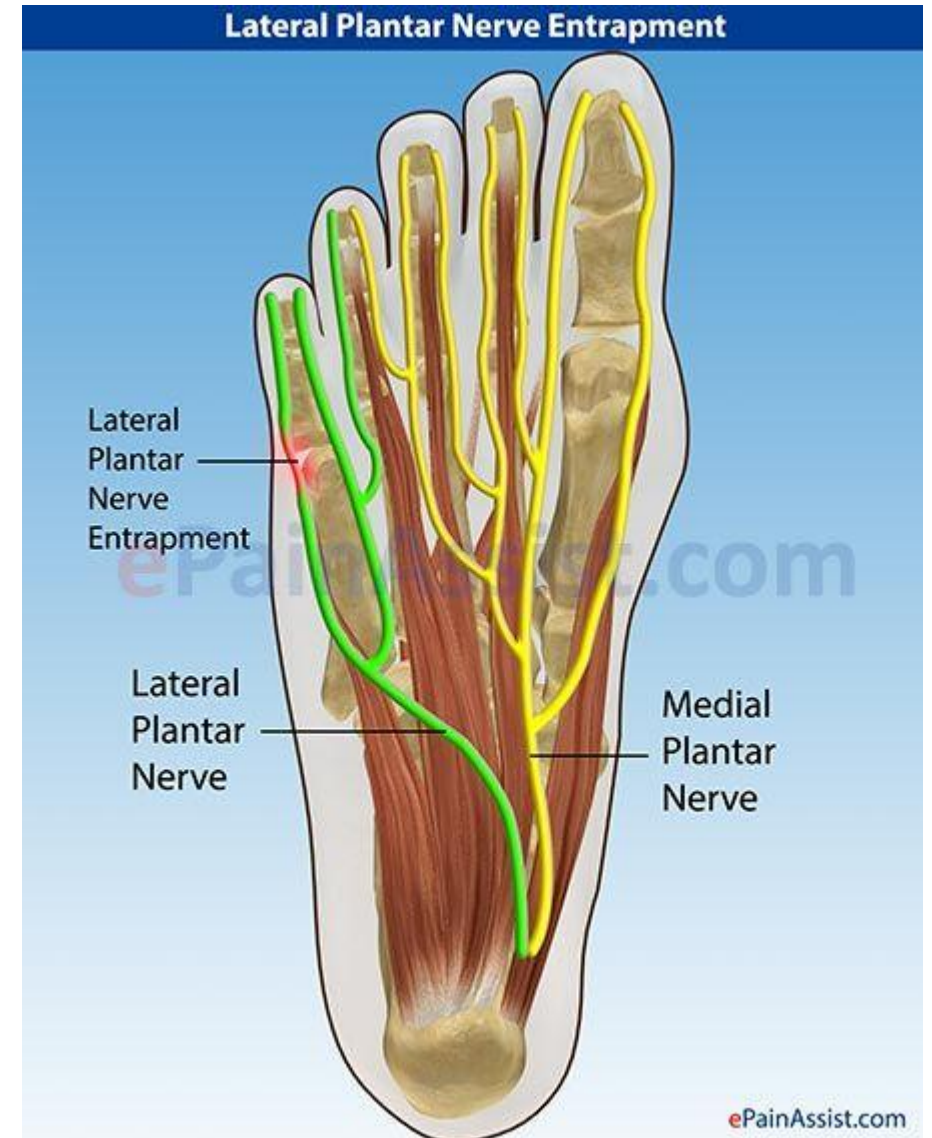
## TIBIAL NERVE

### B) LATERAL PLANTAR NERVE

❑ Is the **SMALLER** terminal branch of the tibial nerve.

❑ Divides Into:

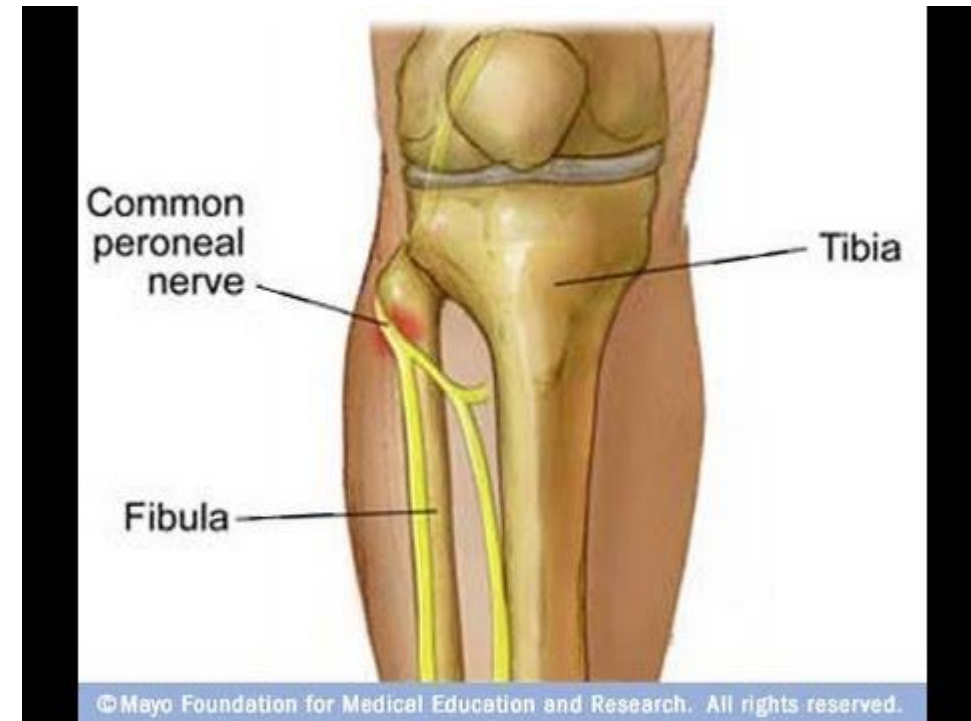
- 1) a superficial branch, which Innervates the flexor digiti minimi brevis.
- 2) a deep branch, which innervates the plantar and dorsal interossei, the lateral three lumbricals, and the adductor hallucis.



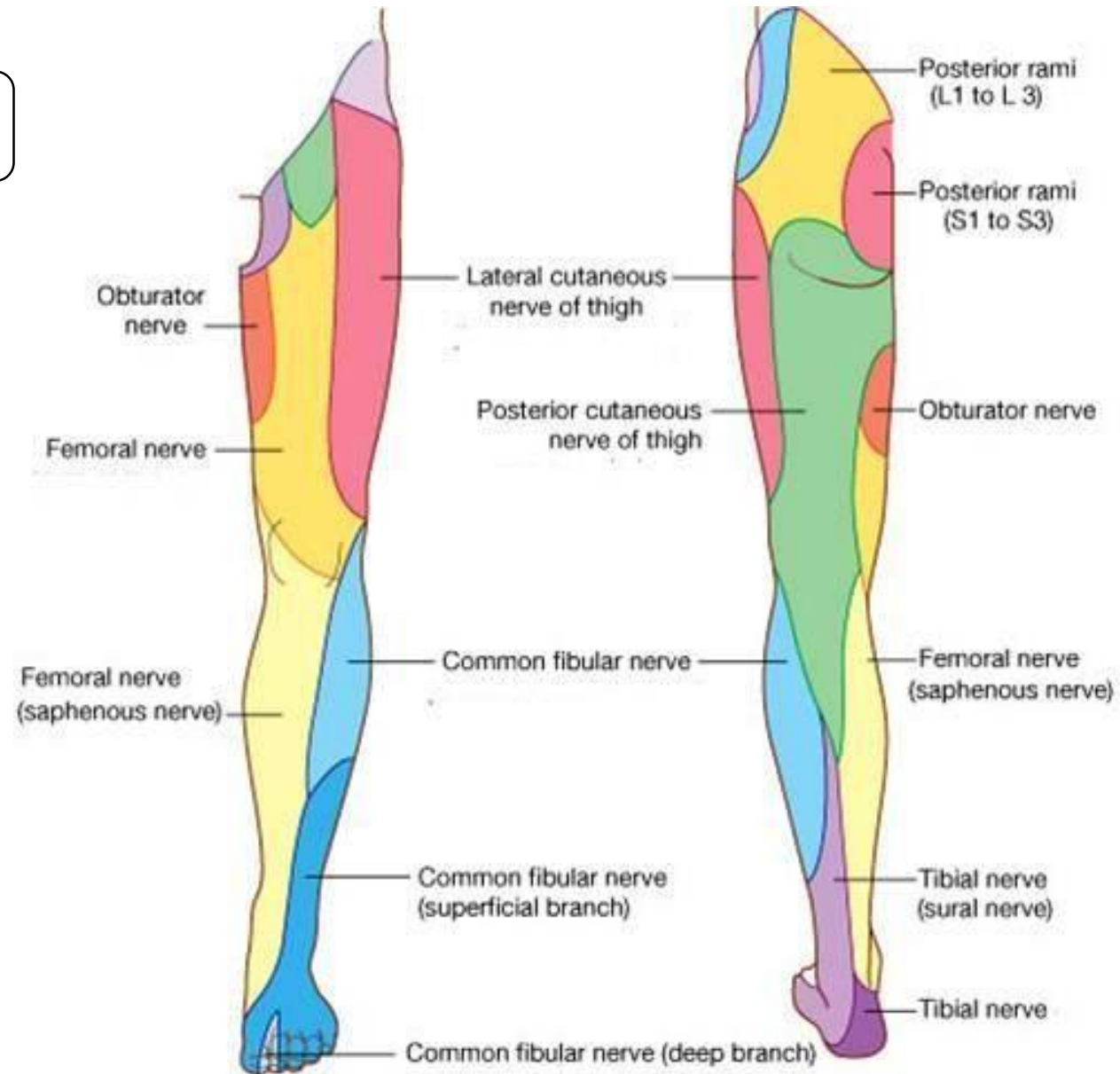


## COMMON FIBULAR(PERONEAL) NERVE (L4-S2)

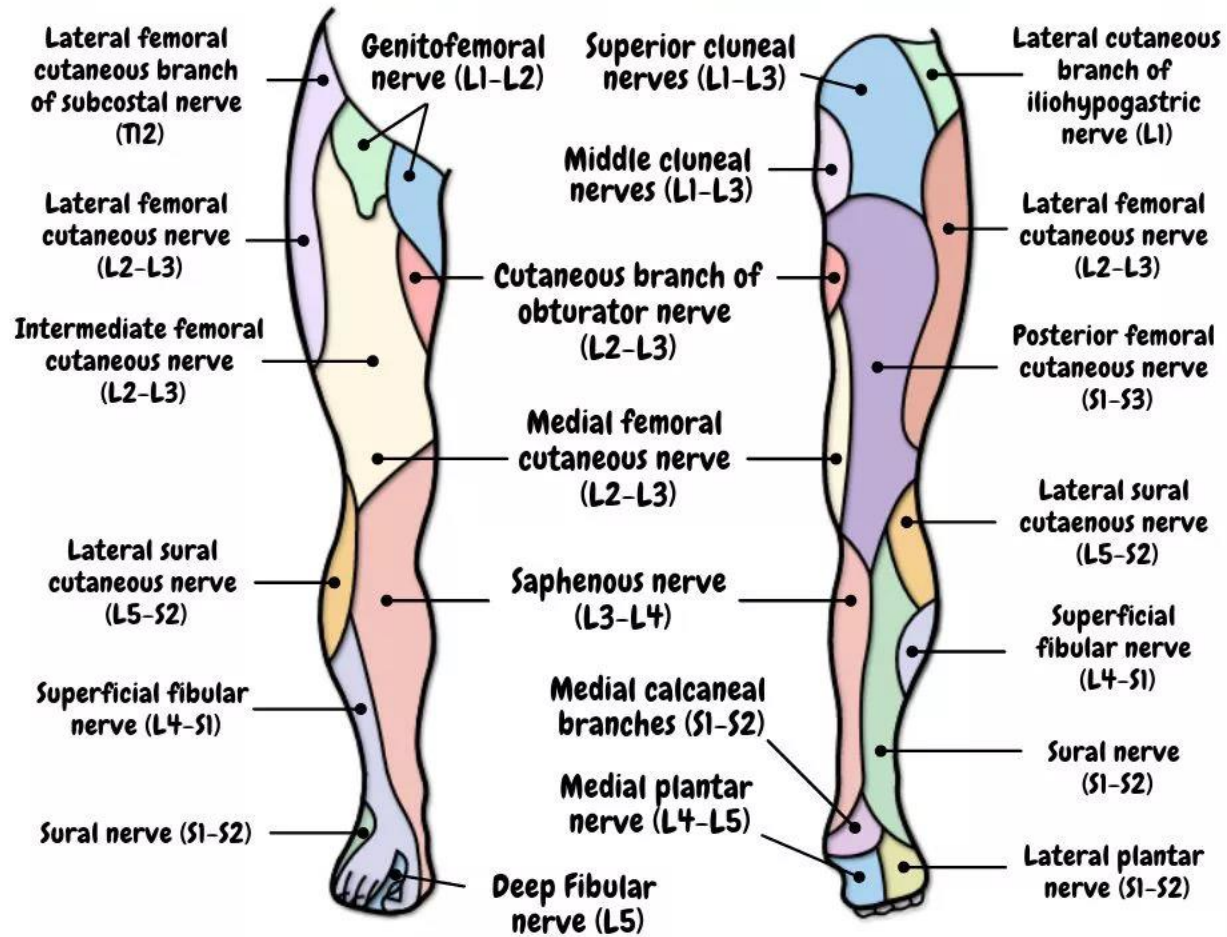
- ❑ Arises as the smaller terminal portion of the sciatic nerve at the apex of the popliteal fossa, descends through the fossa, and superficially crosses the lateral head of the gastrocnemius muscle.
- ❑ Passes behind the head of the fibula, then winds laterally around the neck of the fibula,
- ❑ pierces the fibularis longus, where it divides into the **DEEP** fibular and **SUPERFICIAL** fibular nerves.
- ✓ Gives rise to the lateral sural cutaneous nerve, which supplies the skin on the lateral part of the back of the leg, and the recurrent articular branch to the knee Joint



# CUTANEOUS INNERVATION



# Cutaneous Nerves



ANTERIOR

POSTERIOR

# Foot Nerves

## CUTANEOUS INNERVATION

