

وسهلا



أهلا

يُمنع أخذ السلايدات بدون
إذن المحرر واي اجراء
يخالف ذلك يقع تحت طائلة
المسؤولية القانونية
جميع المعلومات للاستخدام
التعليمي فقط

الأستاذ الدكتور يوسف حسين

كلية الطب - جامعة مؤتة - الأردن

دكتورة من جامعة كولونيا المانيا

Prof. Dr. Youssef Hussein Anatomy - YouTube

الواتس (أي استفسار)
00201224904207

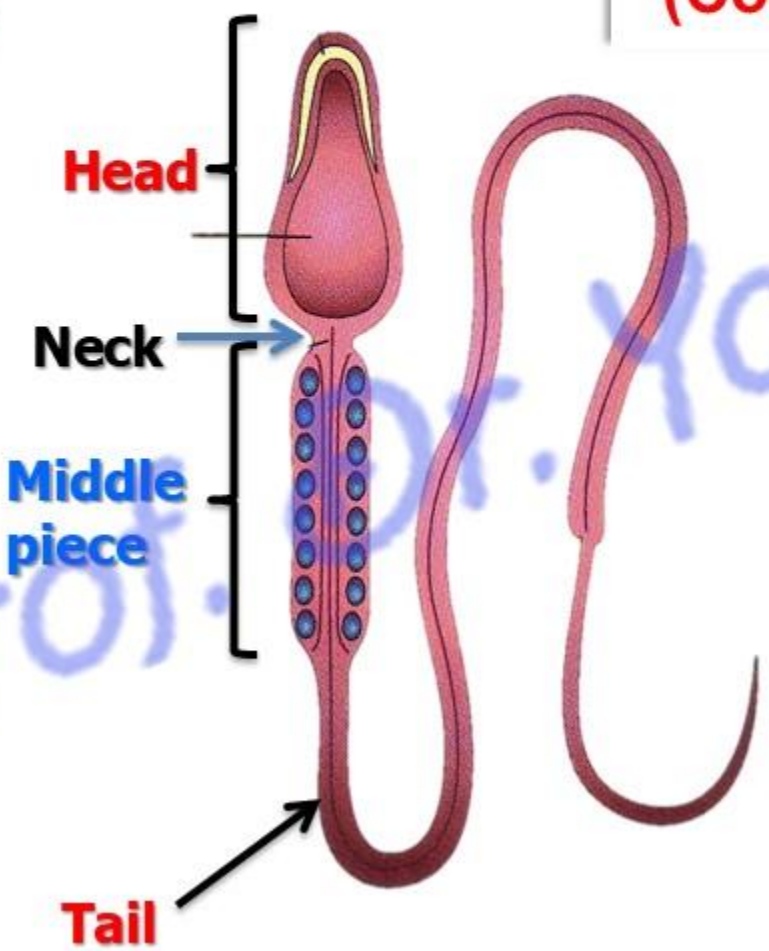
The first week Fertilization

- **Fertilization** is the fusion of male gamete (haploid sperm) & female gamete (haploid ovum) to form the **diploid zygote**.
- **Time of fertilization:** at ovulation that occurs about the 14th day of the ovarian cycle.
- **Site of fertilization:** at **ampulla of uterine tube** (lateral 1/3 of uterine tube).
- The lifespan of the ovum is **24 - 48 hours** while sperms about **3-4 days**, up to 5 days.

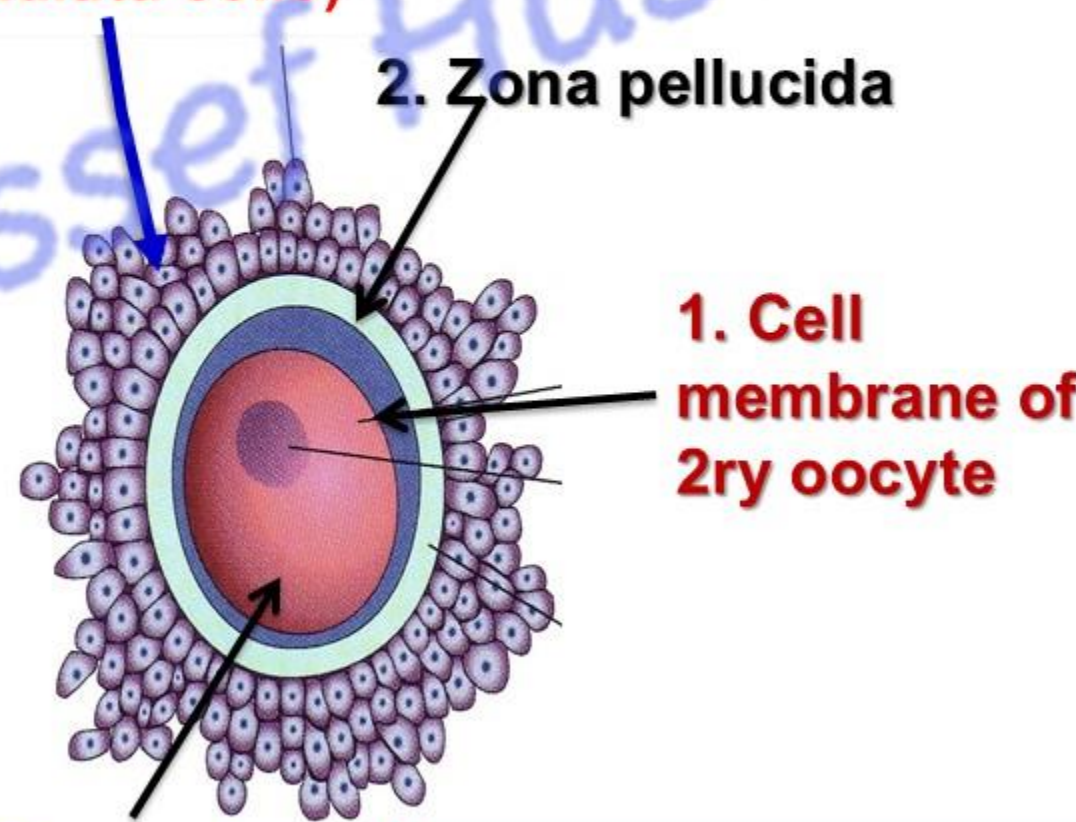
اليوثيوب - د. يوسف حسين

Sperm & Corona radiata (ovum)

dr_youssefhoussein@yahoo.com



3. Cumulus ovaricus
(Corona radiata cells)



Secondary oocyte

البيوتوب - د. يوسف حسين

اليوتايوب - د. يوسف حسين

Ampulla of uterine tube

**** The sperms reach lateral 1/3 of the fallopian tube by;**

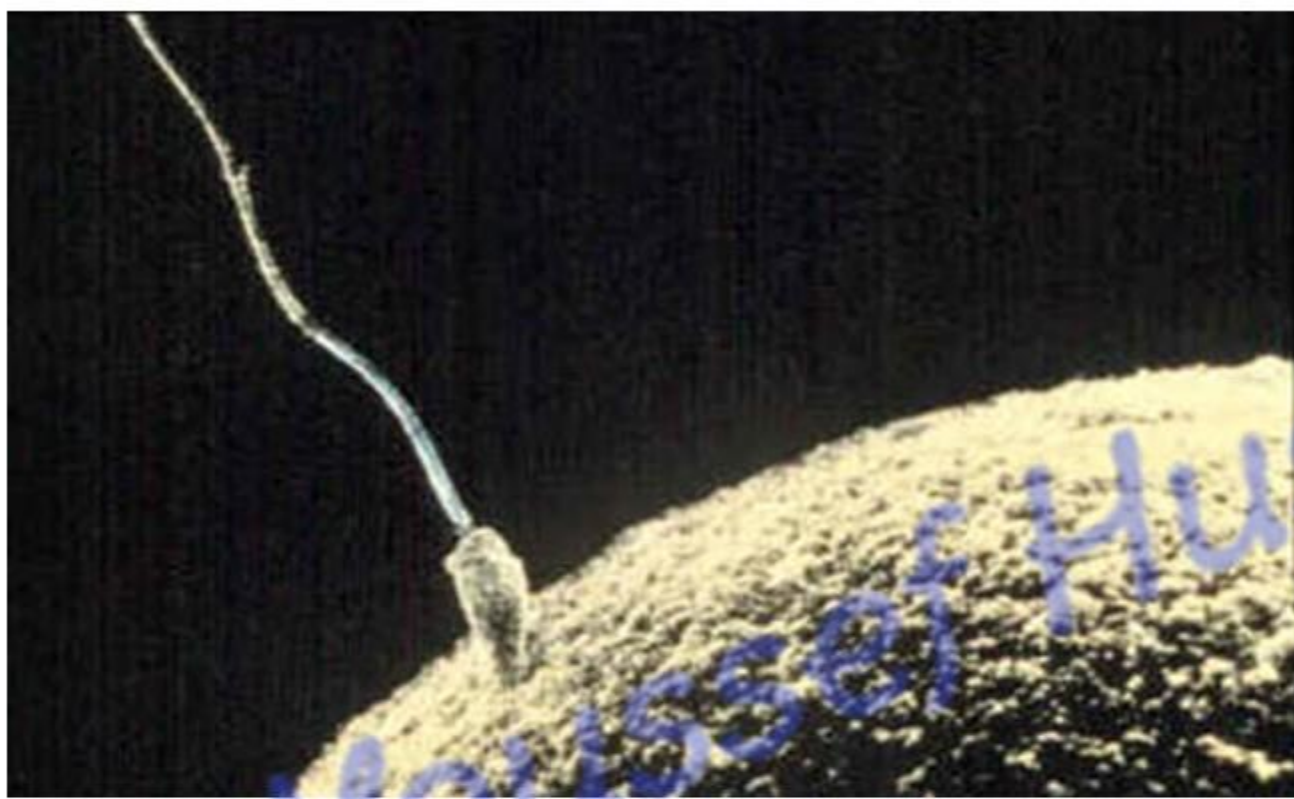
1- Movement of tails of the sperms.

2- Contraction of smooth muscle of the uterus and fallopian tubes.

3- Movement of the cilia of the uterine tube.

4- At ovulation, increase amount of **secretion** and become **less viscid**, making it more favorable for sperm transport.

□ The sperms reach in about 30-45 minutes up to 7 hours



dr_youssefhussein@yahoo.com

- **Number of sperm** about 20-200 million per ml
- **The average volume of semen** at ejaculation is 3-5 ml
- **About 200–300 sperms reach the site of fertilization in uterine tube**
- **Most of sperms able to fertilization within 48 hours.**
- **Only one sperm (its head and neck) can penetrate the secondary oocyte**

البيوتوب - د. يوسف حسين

Steps of Fertilization

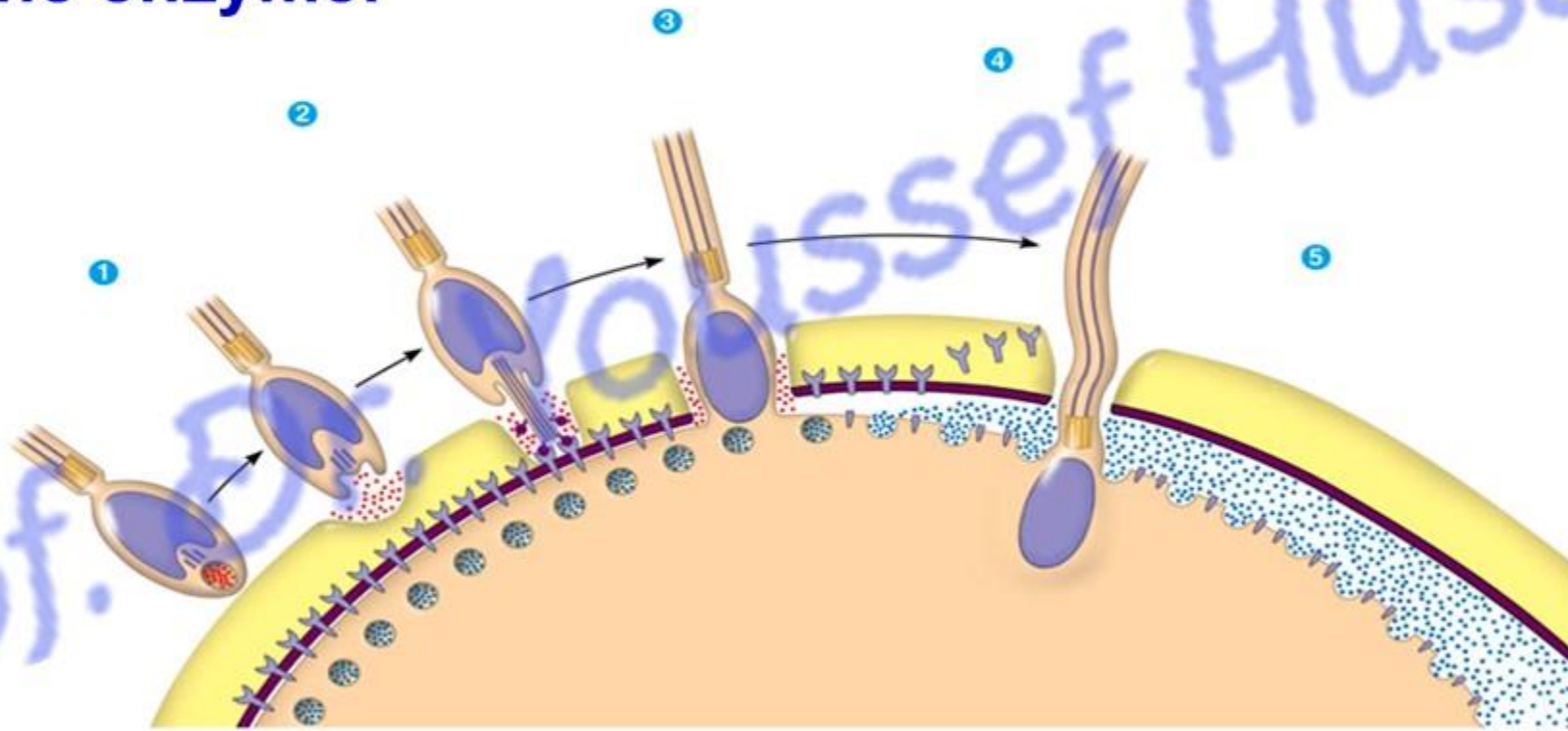
- **Capacitation, loss of** the glycoprotein coat from the acrosomal cap of the sperm head

Ejaculated



البيوتوب - د. يوسف حسين

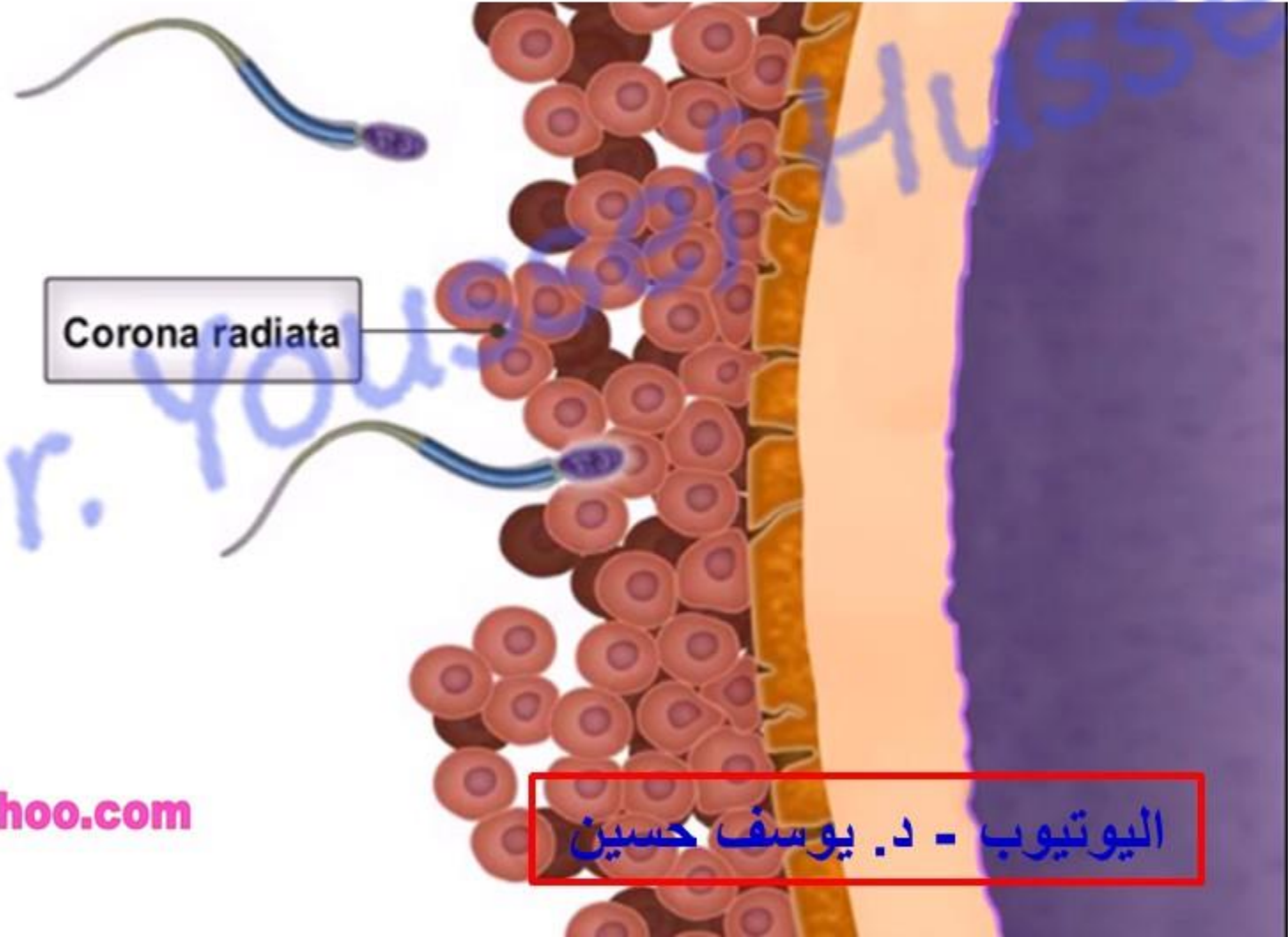
- **Acrosomal reaction**; release of the **proteolytic enzymes** from the acrosomal cap to help penetration of the sperm to the ovum.
 - They include **hyaluronidase enzyme, trypsin like enzyme and zona lysine enzyme.**



Penetration of the corona radiata cells

Penetration of corona radiata cells by :

- 1) Hyaluronidase enzyme of sperms.
- 2) Mucous secretion of Fallopian tube.

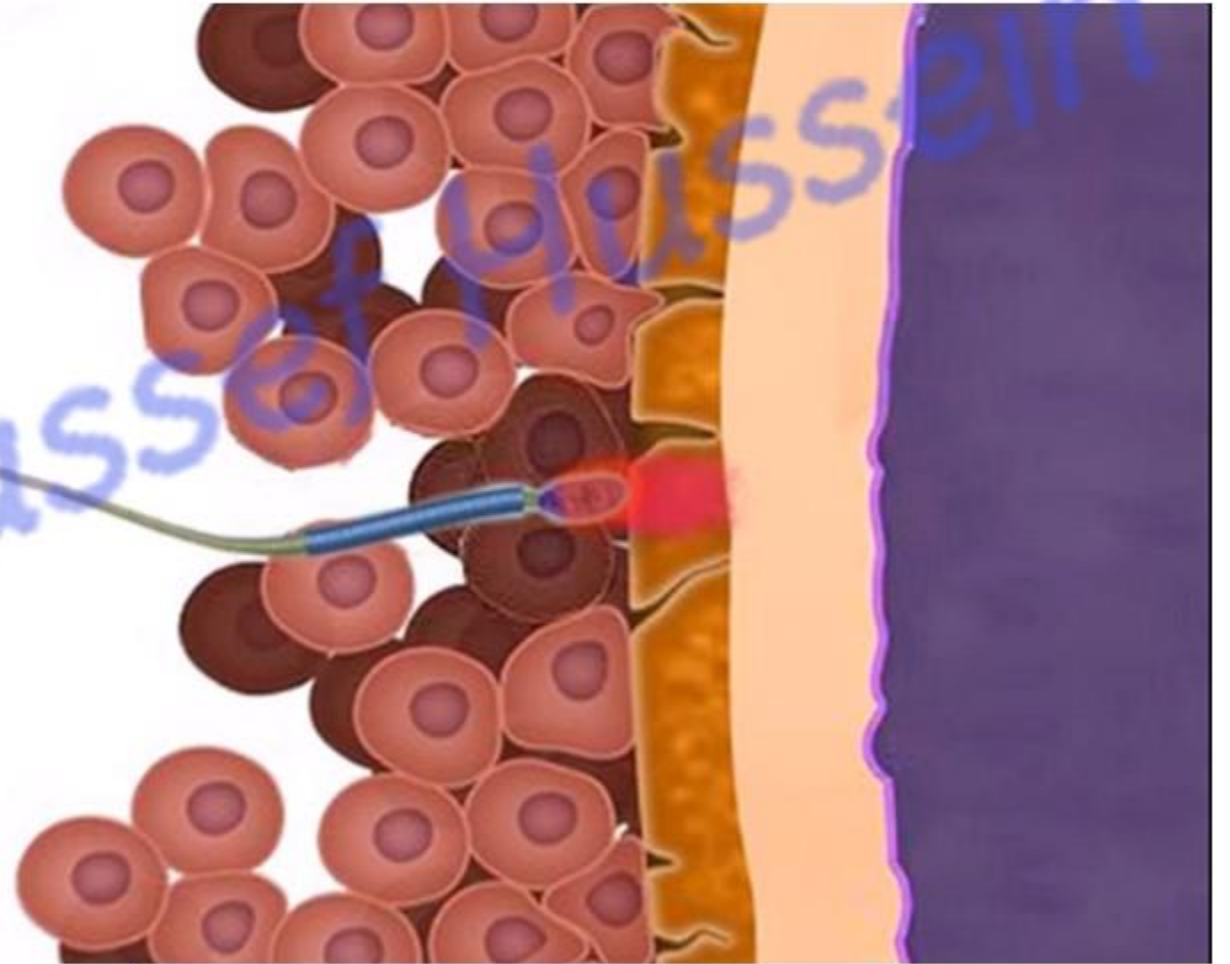


dr_youssefhussein@yahoo.com

اليوثيوب - د. يوسف حسين

Penetration of the Zona Pellucida

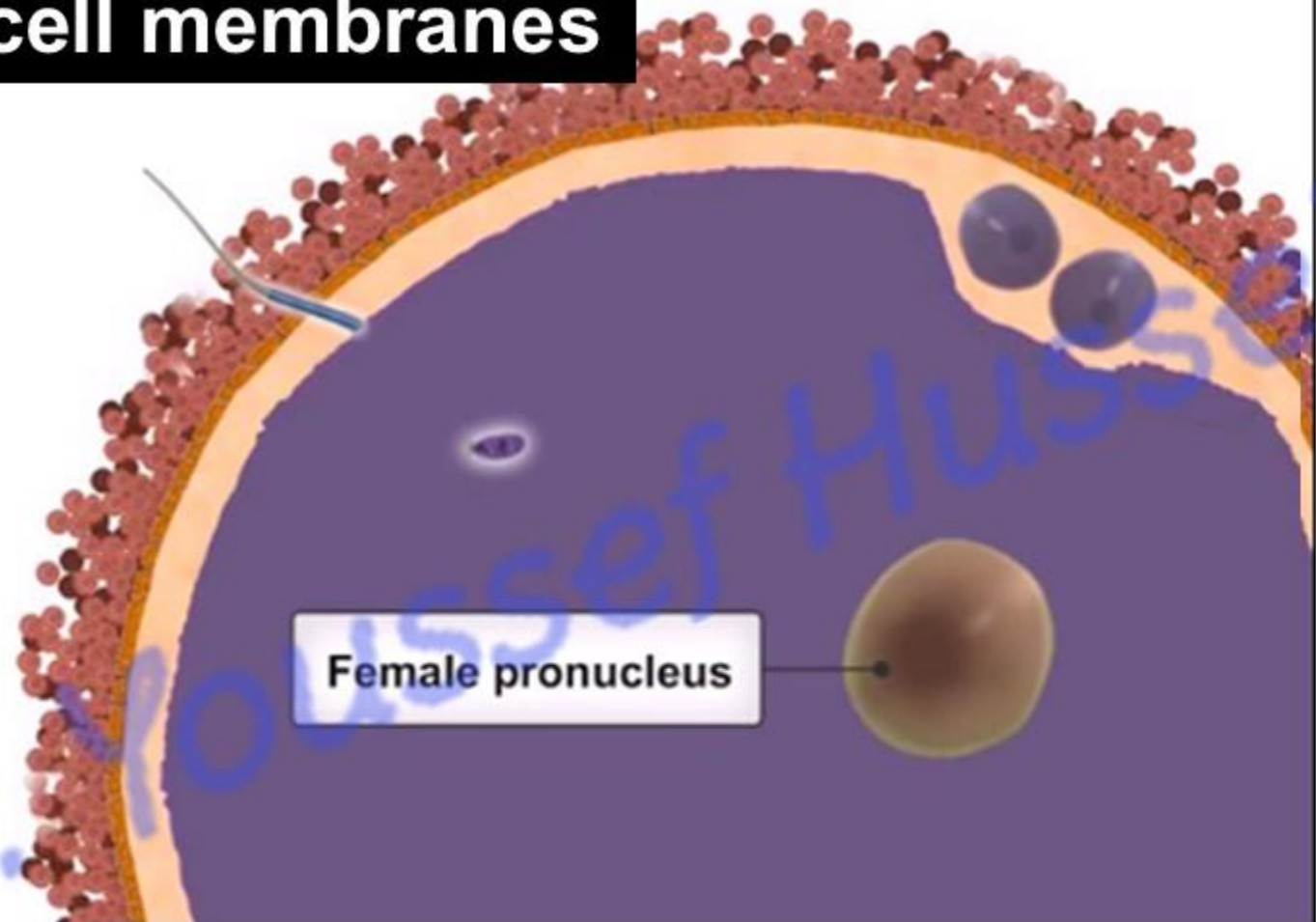
- **Penetration of the zona pellucida** by the **zona lysine enzyme** and **trypsin like enzyme** of the sperms.
- **Zona reaction:** After penetration of the sperm, the zona pellucida changes its **chemical composition** to prevent entry of other sperms.



Fusion of gametes cell membranes

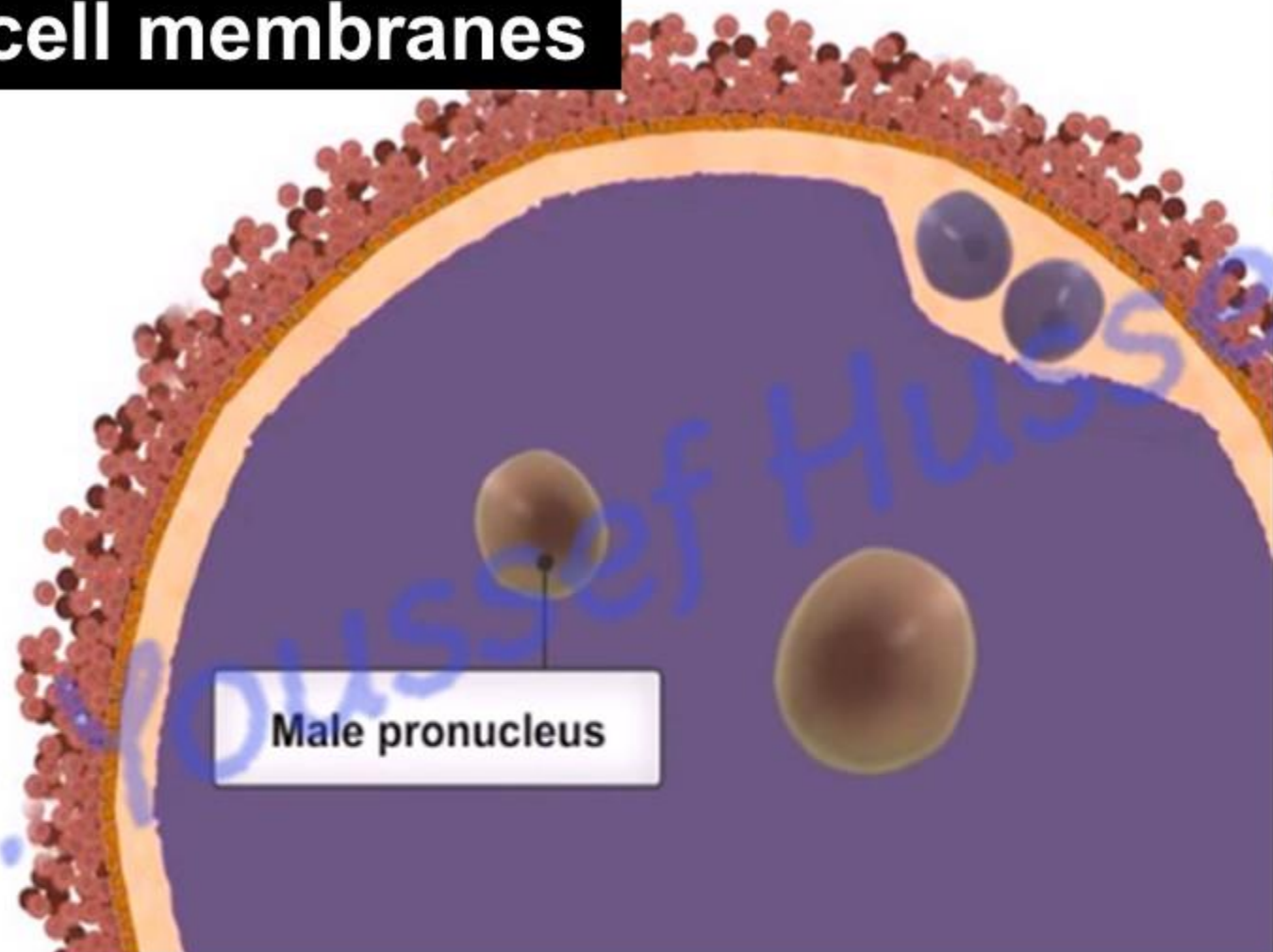
dr_youssefhussain@yahoo.com

اليوثيوب - د. يوسف حسين



- Cortical reaction:** after penetration of head and neck of sperm to cell membrane of the 2ry oocyte, It alters its **chemical composition** to prevent entry of other sperm.
- The 2ry oocyte completes the **2nd meiotic division** giving rise to definitive **ovum** and 2nd polar body. The nucleus of the ovum enlarged to form **female pronucleus**.

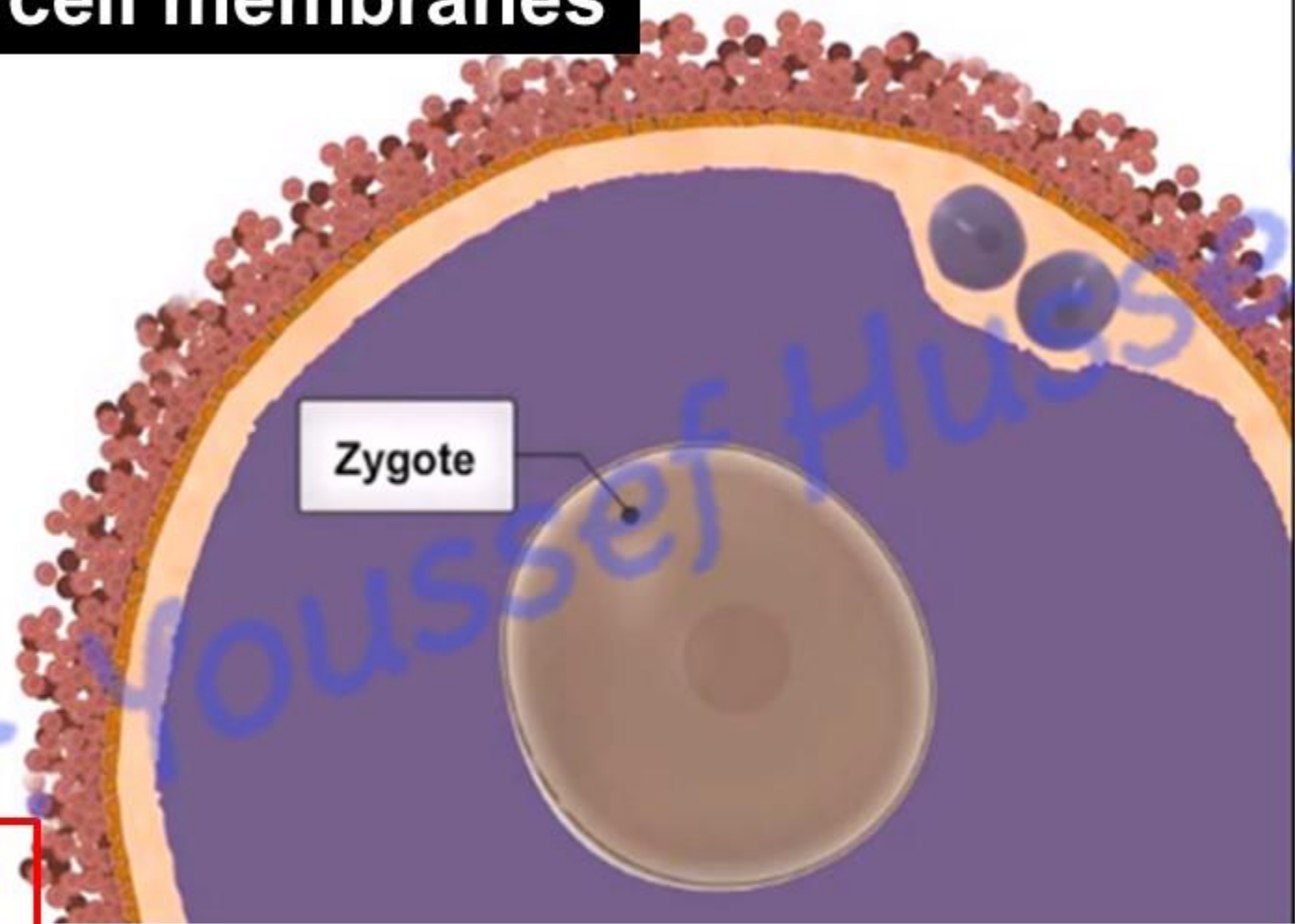
Fusion of gametes cell membranes



- Only head and neck of one sperm penetrates the ovum.
- The head of the sperm swells and forms the male pronucleus

البيوتوب - د. يوسف حسين

Fusion of gametes cell membranes



البيوتوب - د. يوسف حسين

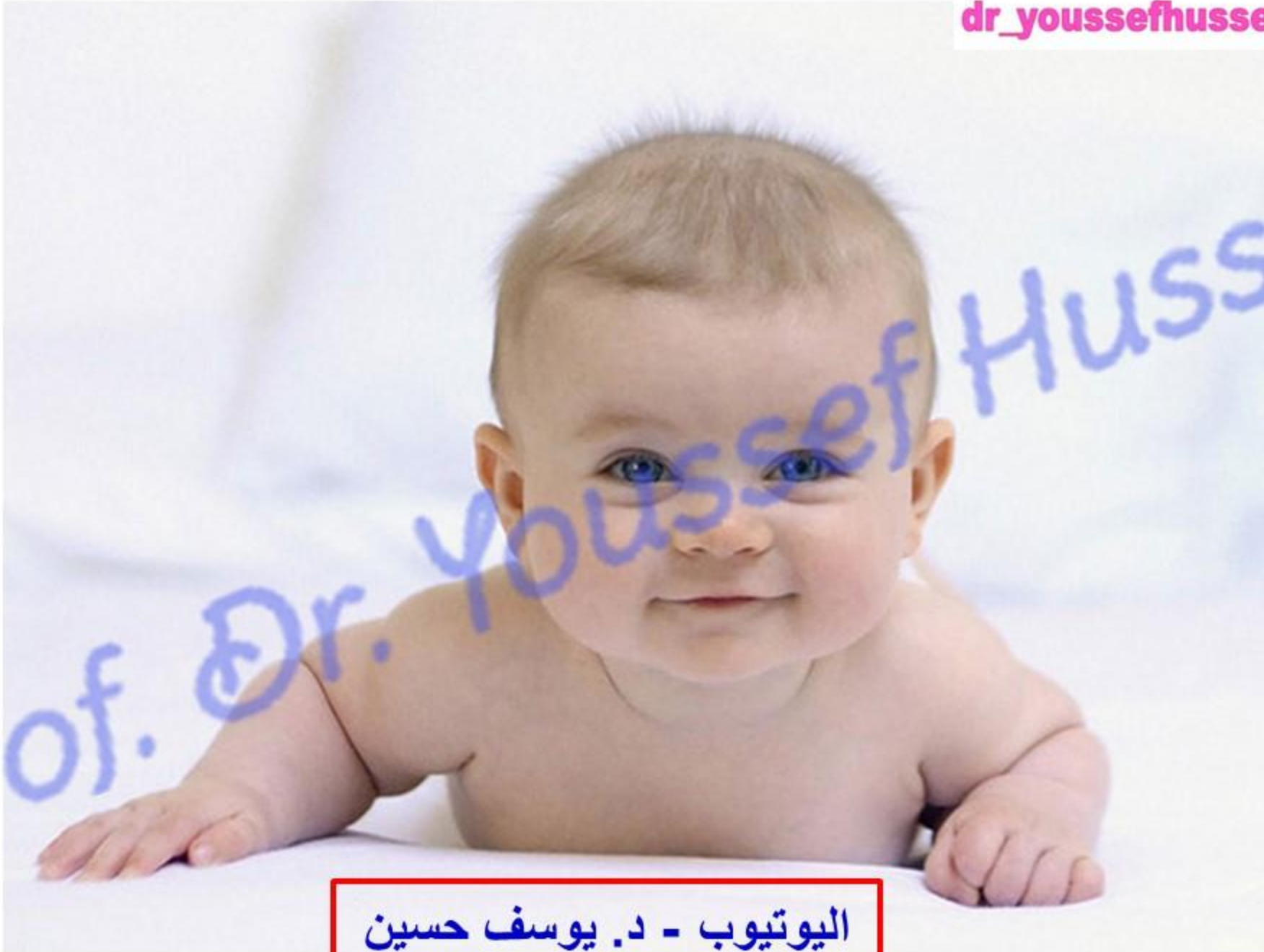- Both male and female pronuclei become in contact with each other and fuse together to form the **zygote** (46 chromosomes).

• Results of Fertilization

- **Formation of zygote.**
- **Restoration of diploid number (46 chromosomes).**
- **Determination of sex.**
- Determination of **general features.**
- **Cleavage (segmentation) starts.** Mitosis (cell division) in the new zygote uses **centriole derived from the neck of sperm** but the **oocyte has no centrioles.**
- **Only head and neck of the sperm penetrate, but the body that contains mitochondria does not penetrate, SO, all mitochondria in humans are of maternal origin.**
- Enlarged of **corpus luteum** and continues to secrete progesterone hormones till the 4th month of pregnancy. **After that, it degenerates and its function being carried by placenta.**
- **Increase Progesterone hormones leads to Inhibition of ovulation** and menstrual cycle due to inhibition of FSH from pituitary gland
- Increase Progesterone hormones leads to **formation of decidua, increase size of the breast.**

dr_youssefhussein@yahoo.com

Prof. Dr. Youssef Hussein



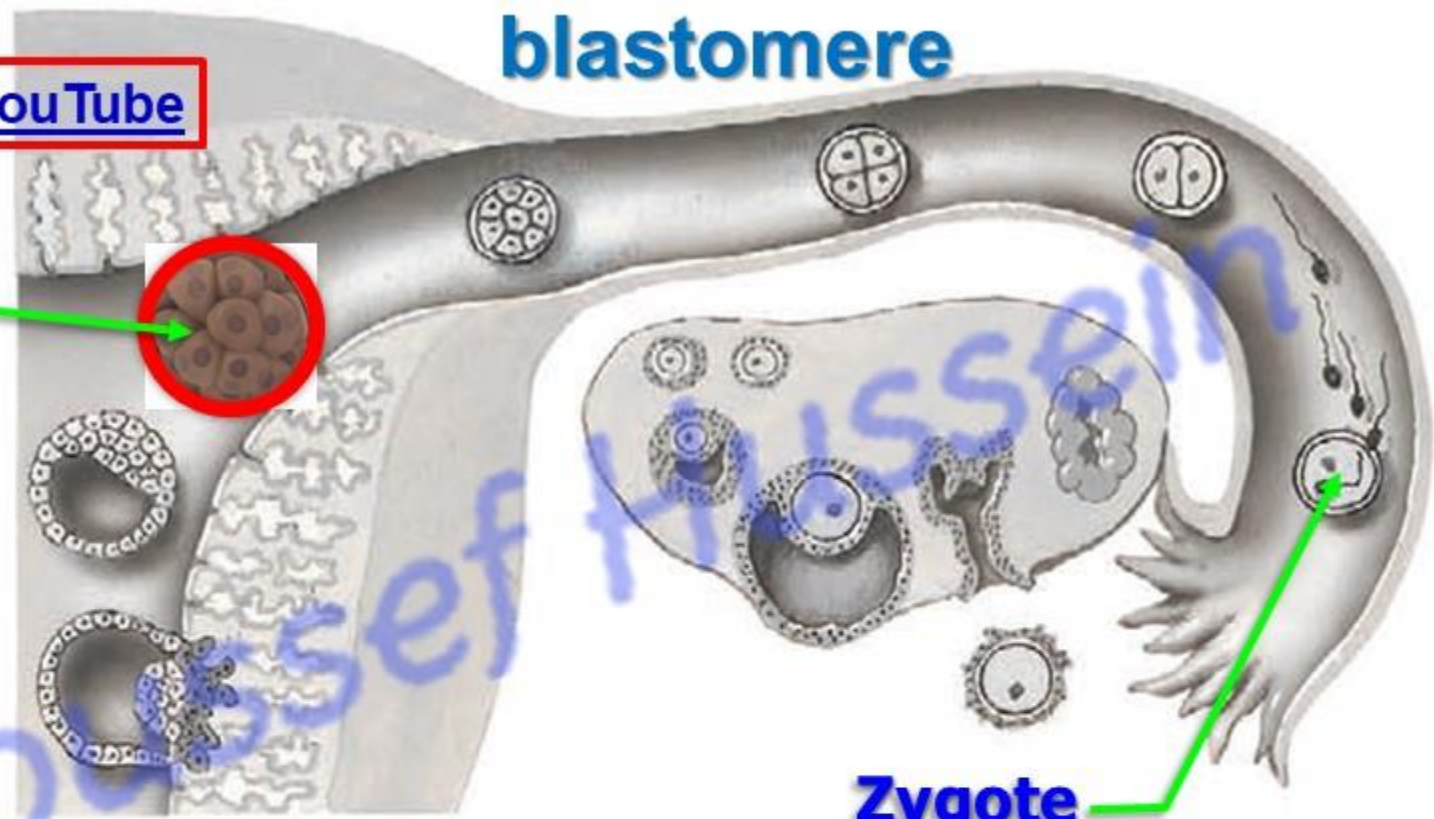اليوتيوب - د. يوسف حسين

Cleavage (Segmentation)

Morula

blastomere

Zygote



dr_youssefhussein@yahoo.com

- **Segmentation (Cleavage) Formation**

- The **zygote** divides repeatedly by **mitotic divisions** leading to an increasing number of cells.
- **Blastomere** is a type of cell produced during cleavage after fertilization and is essential for formation of the morula
- **Morula is a solid mass and formed of 16 cells surrounded by zona pellucida.**
- the morula typically enters the uterine cavity 3–4 days to 4–5 days after fertilization

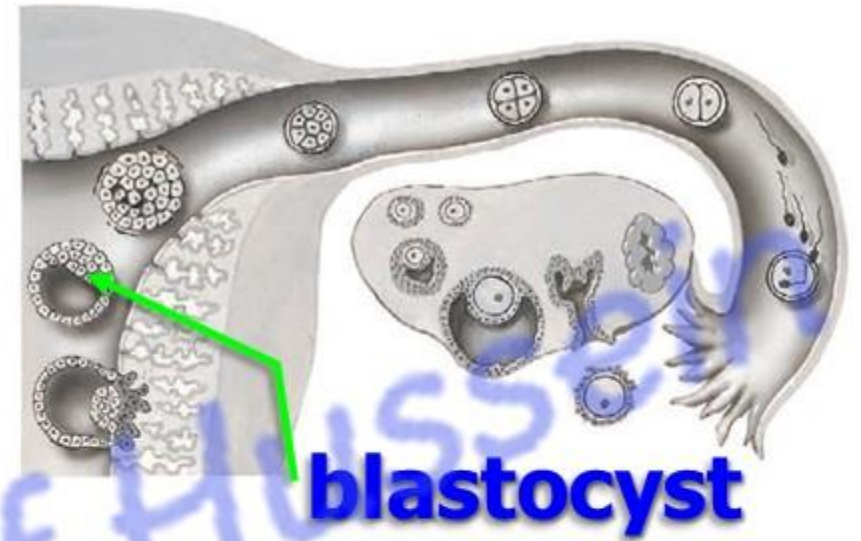
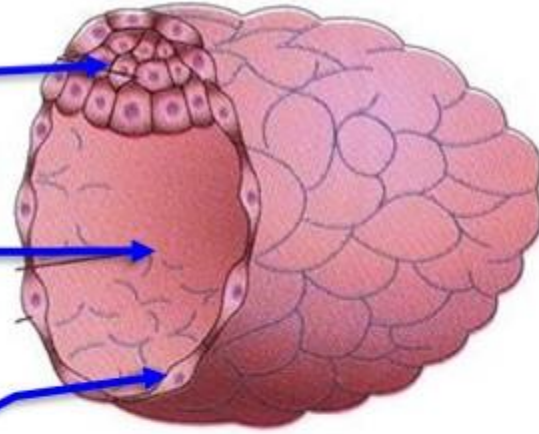
Formation of Blastocyst

[Prof. Dr. Youssef Hussein Anatomy - YouTube](#)

**Inner cell mass
(Embryoblast)**

Blastocele

**Outer cell mass
(Trophoblast)**



- **Formation of blastocyst**

- The **blastocyst** (cystic structure) is formed at the **5th days** after fertilization.
- The cells of the morula rapidly proliferate and forming a large number of cells.
- Fluid collects between the cells and form a single cavity called **blastocele**
- **Blastocyst** is surrounded by **zona pellucida** and divided by blastocele cavity into;
 - a- **Outer layer** of flat cells called **trophoblast** that forms the **placenta**.
 - b- **Inner** cell mass (**embryoblast**). This mass will form the **embryo**.

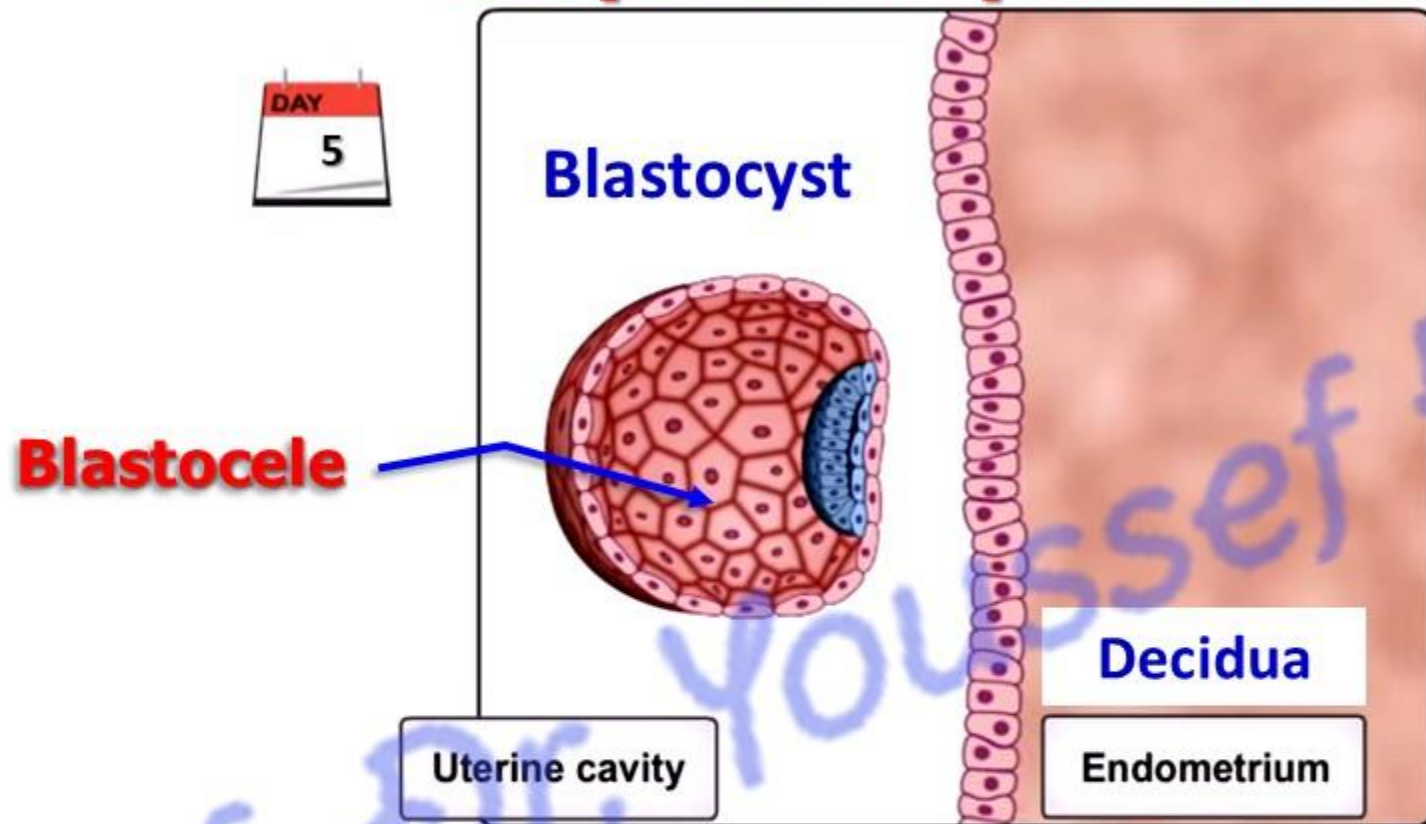
Implantation

Implanted blastocyst



- **Definition:** It is the entrance of the **blastocyst** into the thick endometrium of the uterus (**decidua**) .
- **Site of implantation:** into the middle of the upper part of the posterior wall of the uterus. [Prof. Dr. Youssef Hussein Anatomy - YouTube](#)
- **Timing:** Starts at **6th - 8th day** and completed around day 11–12.

Steps of implantation

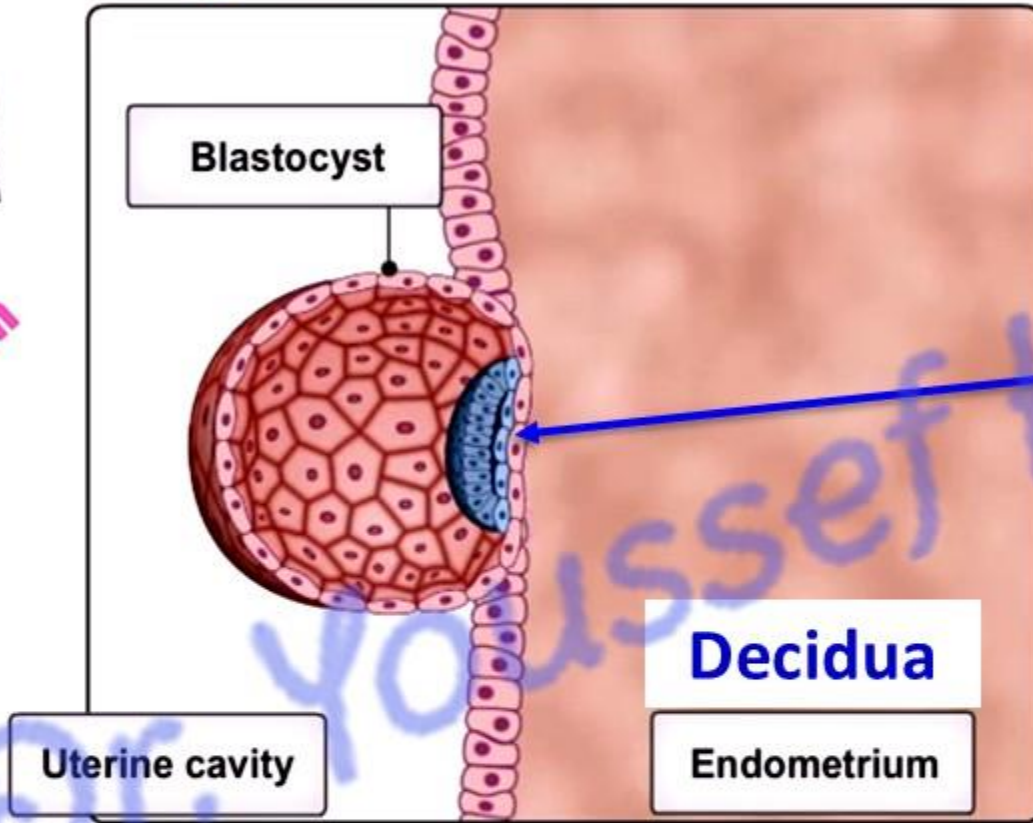


dr_youssefhussain@yahoo.com

1- Rupture of the **zona pellucida** around **blastocyst** due to increase amount of fluid in the blastocele cavity

Steps of implantation

DAY
6



Trophoblast

Decidua

Endometrium

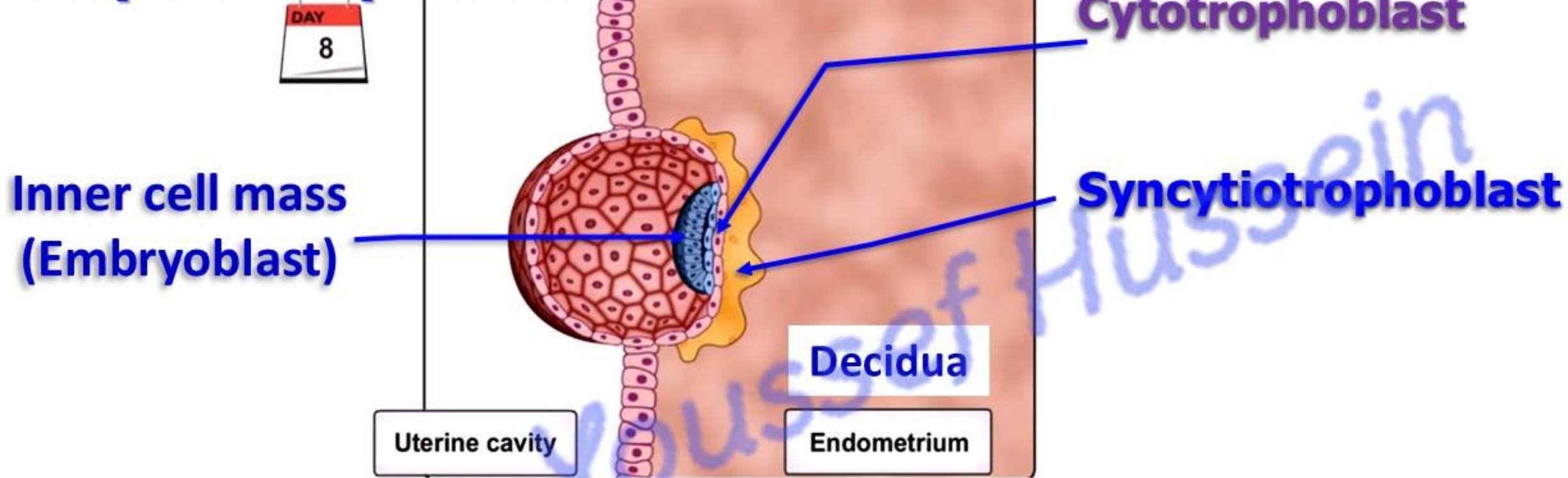
Uterine cavity

[Prof. Dr. Youssef Hussein Anatomy - YouTube](#)

2- The **trophoblast** (outer layer) of the blastocyst adherent to the endometrium (**decidua**) .

dr_youssefhusein@yahoo.com

Steps of implantation

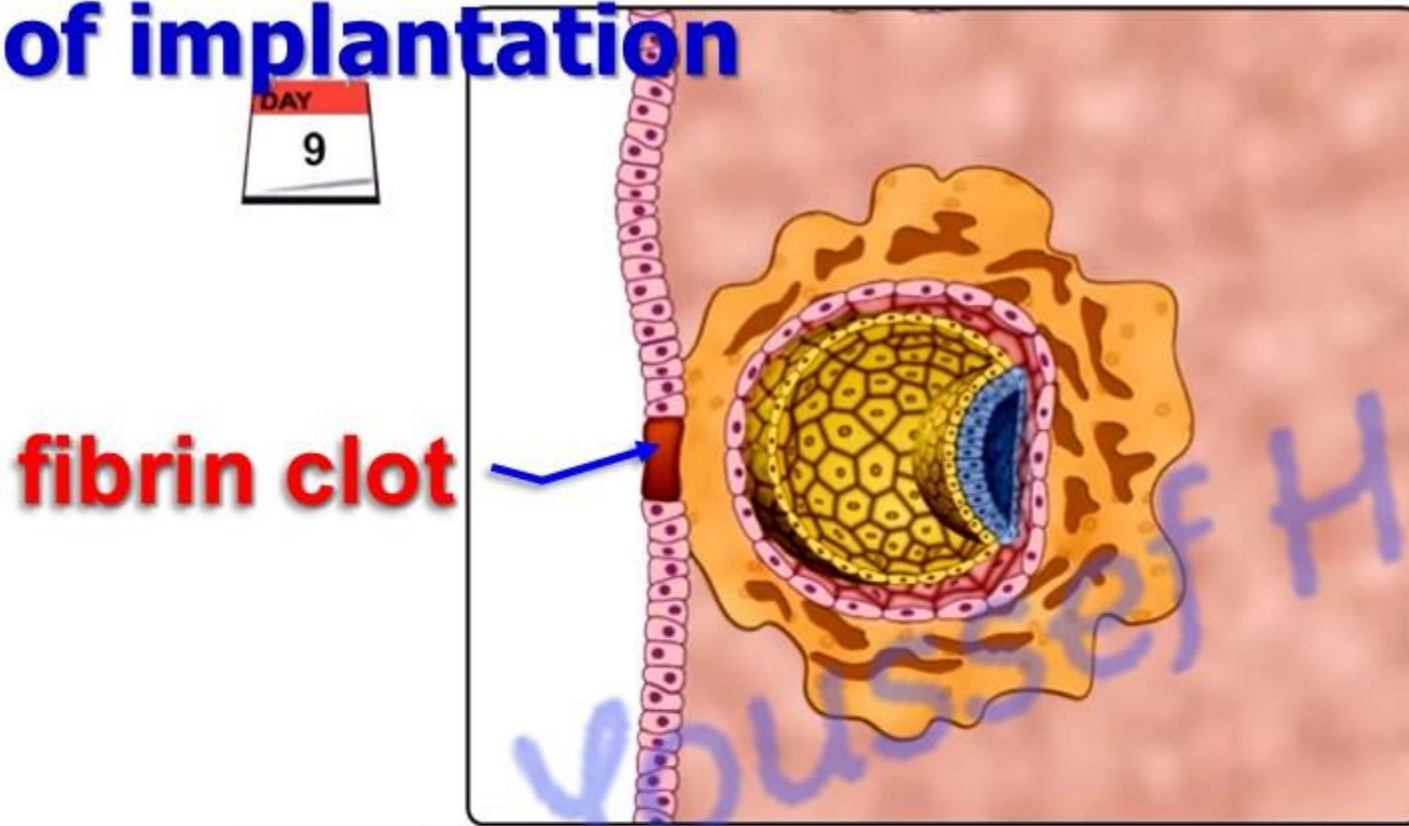


3- The trophoblast covering the inner cell mass **adherent** to the decidua and differentiates into **2 layers**: **1)** An inner layer called **cytotrophoblast**.

2) An outer layer called **syncytiotrophoblast**.

- The syncytiotrophoblasts have a **phagocytic** function.
- They **erode** the endometrium (**decidua**) and gradually **sink** into it at the side of embryoblast.

Steps of implantation



dr_youssefhussein@yahoo.com

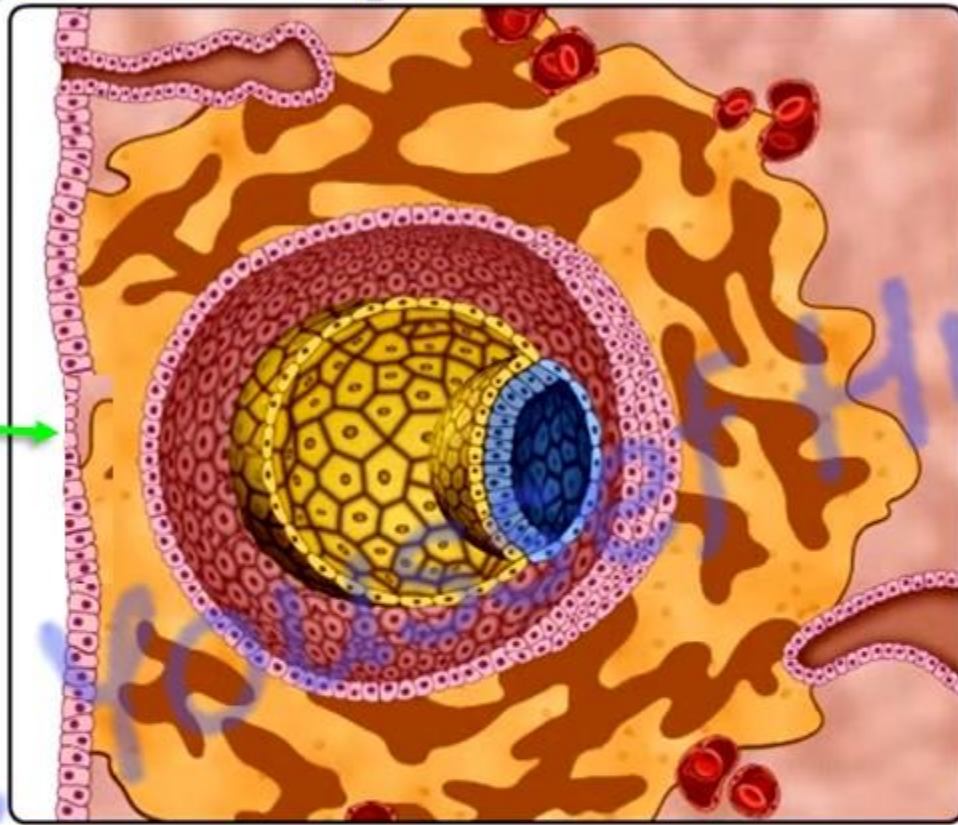
4- The **blastocyst** becomes embedded into the endometrium (**decidua**).

- The site of implantation is closed by a **fibrin clot**.

Steps of implantation



Surface epithelium covers the original defect



Prof. Dr. Youssef Hussein Anatomy - YouTube

5- By the 11th to the 12th day of development, the **blastocyst** is **completely embedded** in the endometrium (**decidua**) and the surface epithelium covers the original defect in the uterine wall

dr_youssefhusein@yahoo.com

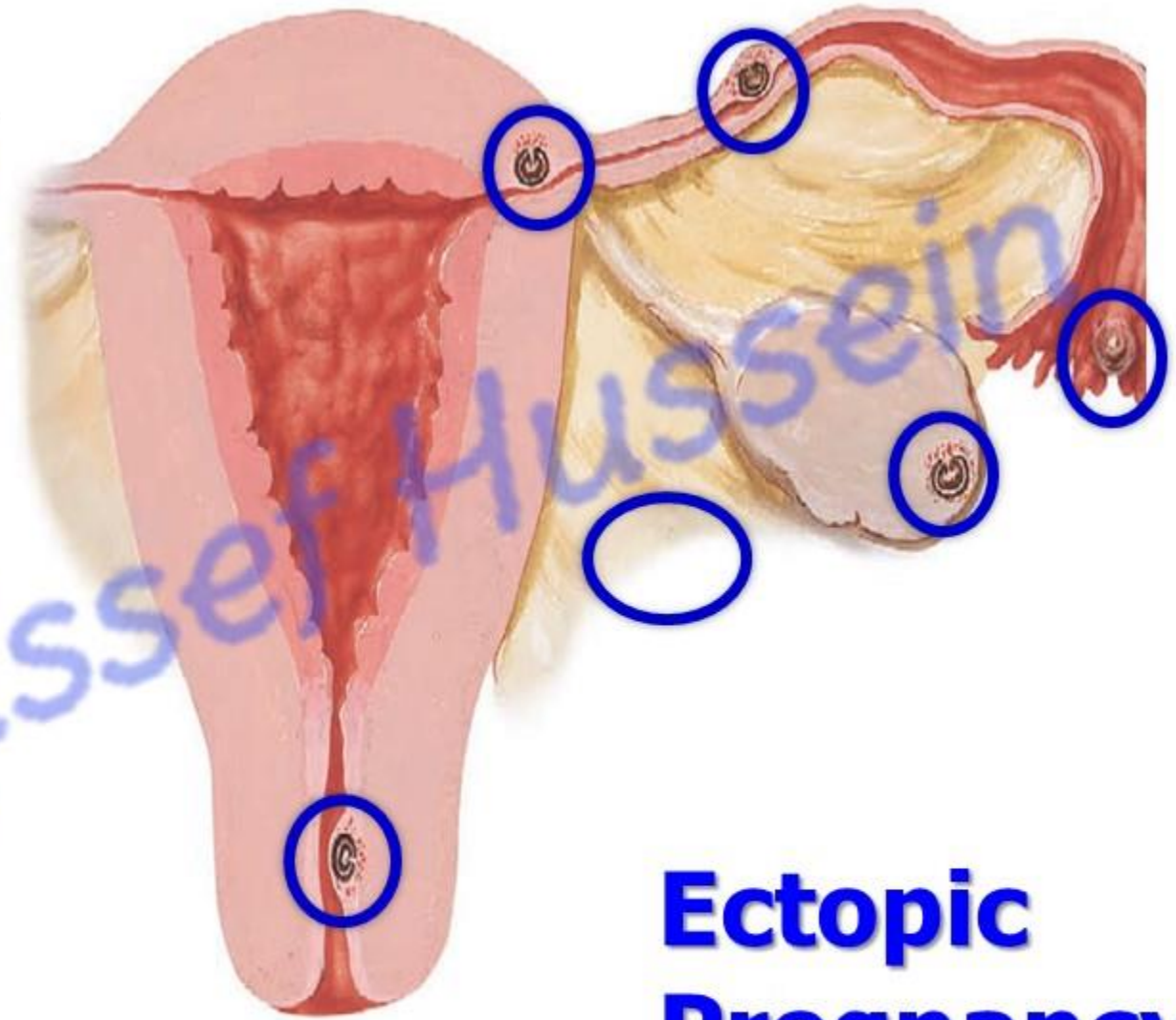
Abnormal implantation

(1) Intrauterine abnormal implantation:

- Implantation at any site rather than the normal site
- The placenta is called **placenta previa (see placenta)**.

(2) Extra uterine abnormal implantation (ectopic pregnancy):

- 1- Tubal pregnancy (uterine tube).
- 2- Ovarian pregnancy (in ovary).
- 3- Peritoneal cavity.




**Ectopic
Pregnancy**

https://www.youtube.com/channel/UCVSNqbibj9UWYaJdd_cn0PQ

يُمنع أخذ السلايدات بدون
إذن المحرر واي اجراء
يخالف ذلك يقع تحت
طائلة المسؤولية القانونية

اليوتيوب د. يوسف حسين



<https://www.youtube.com/@ProfDrYoussefHusseinAnatomy/playlists>