

وسهلا



أهلا

يُمنع أخذ السلايدات بدون
إذن المحرر واي اجراء
يخالف ذلك يقع تحت طائلة
المسؤولية القانونية
جميع المعلومات للاستخدام
التعليمي فقط

الأستاذ الدكتور يوسف حسين

كلية الطب - جامعة مؤتة - الأردن

دكتورة من جامعة كولونيا المانيا

Prof. Dr. Youssef Hussein Anatomy - YouTube

الواتس (أي استفسار)
00201224904207

Radioulnar Joints

Radioulnar Joints

Superior radio-ulnar joint

Annular ligament

Oblique cord

Ulna

Interosseous membrane

Radius

Inferior radio-ulnar joint

Articular disc



• Superior Radioulnar Joint

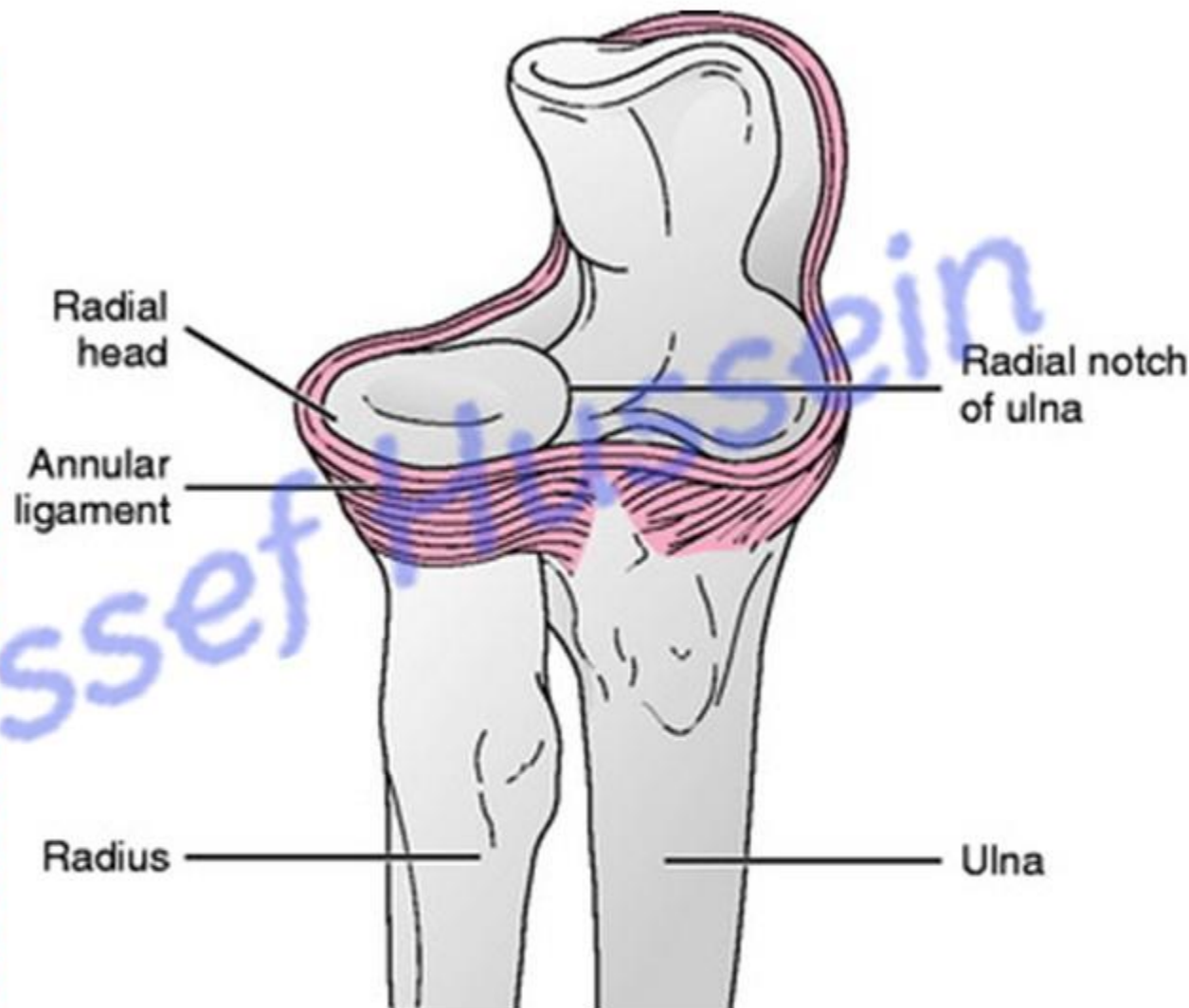
** **Type**; a pivot (uniaxial) synovial joint.

** **Articular surfaces**:

- 1- Articular circumference of the head of the radius.
- 2- Radial notch of the ulna and annular ligament.

• Annular ligament:

- It is a strong fibrous band surrounding the head of the radius.
- It is attached to the margins of radial notch of the ulna.



Synovial membrane: lines inner surface of capsule and Continuous with synovial membrane of elbow joint.

• Inferior Radioulnar Joint

** **Type**; a pivot (uniaxial) synovial joint.

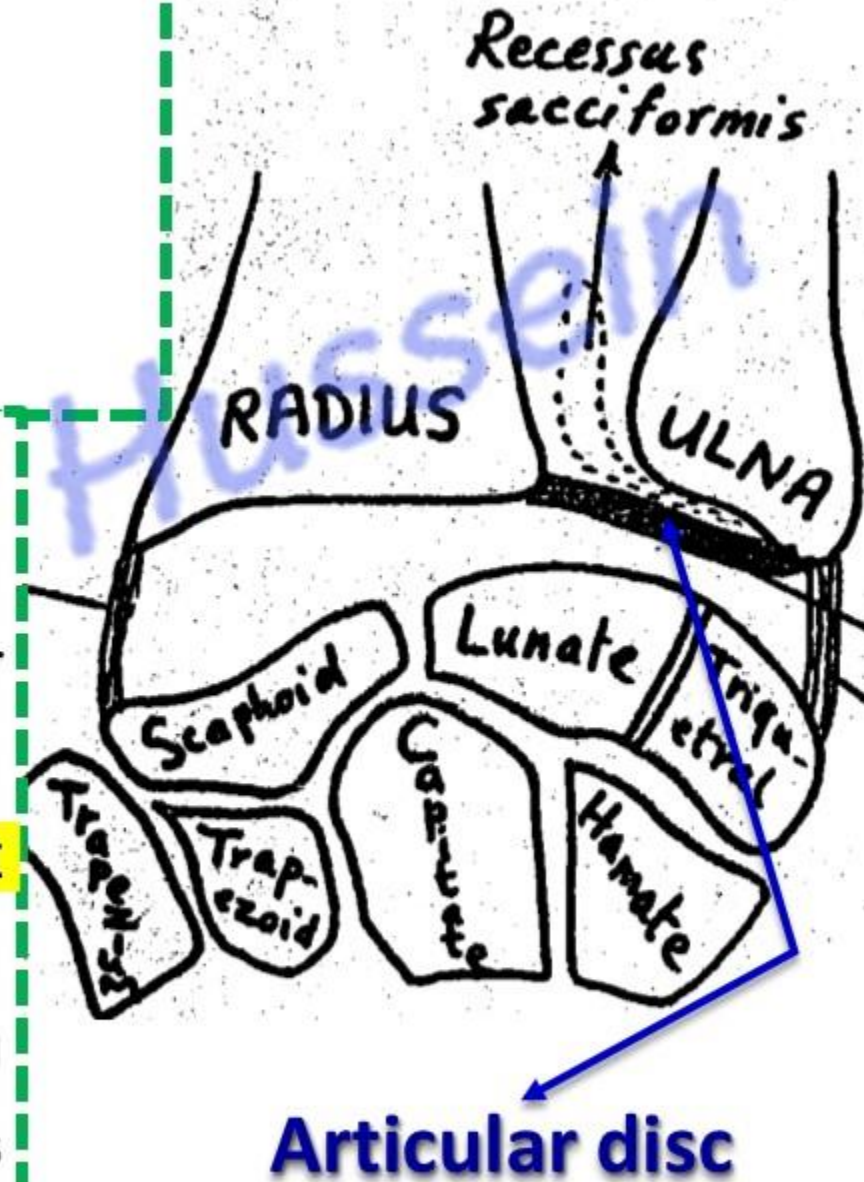
** **Articular surfaces**;

- Articular circumference of the head of ulna
- Ulnar notch of radius.

** **Articular disc**; is a triangular fibrocartilage.

- Its **apex** attached to base of styloid process of ulna.
- The **base** is attached the inferior margin of the ulnar notch of the radius.
- The disc separates the inferior radioulnar joint above from wrist joint below.

** **Synovial membrane**, projects upwards forming recessus sacciformis in front the interosseus membrane.



- **Movements of superior and inferior radioulnar joints**

Palm anterior

Palm posterior

- **Pronation and Supination**

- **Definition:**

- **Pronation:** **medial** rotation of the forearm and the palm of the hand faces **posteriorly**.

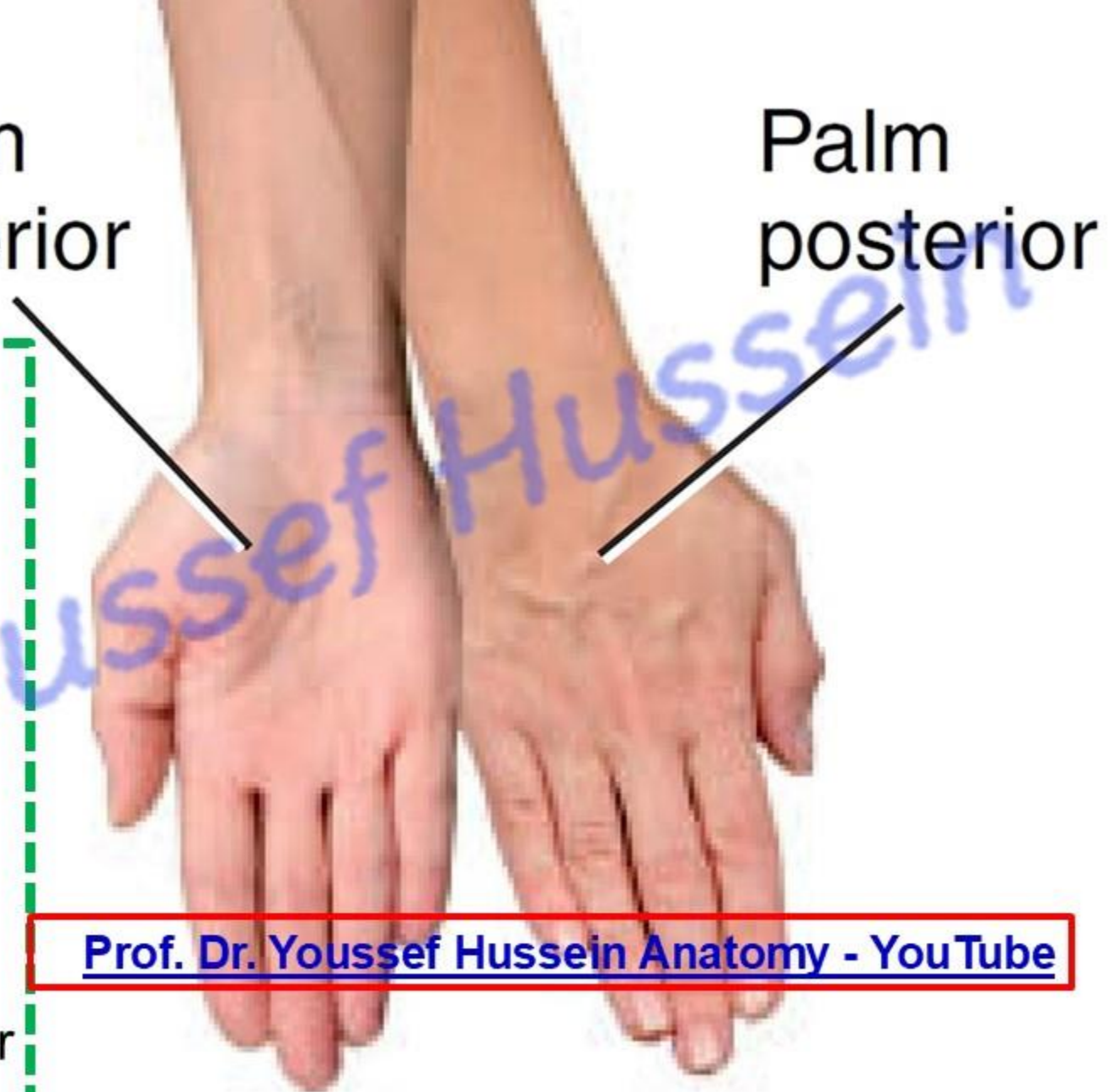- **Supination:** **lateral** rotation of the forearm and the palm of the hand faces **anteriorly**.

- **Joints:** superior and inferior radioulnar joints.

[Prof. Dr. Youssef Hussein Anatomy - YouTube](#)

Supination

Pronation



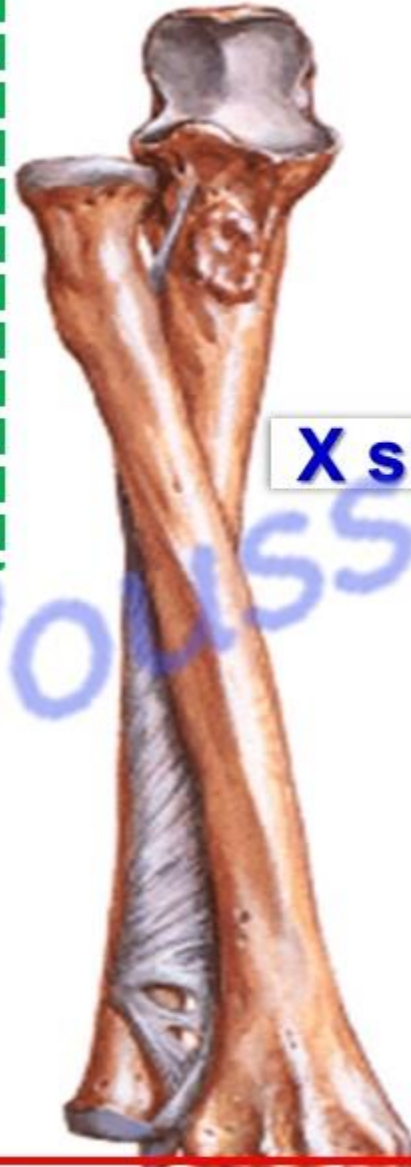- **Pronation**

a- It is initiated by **brachioradialis**.

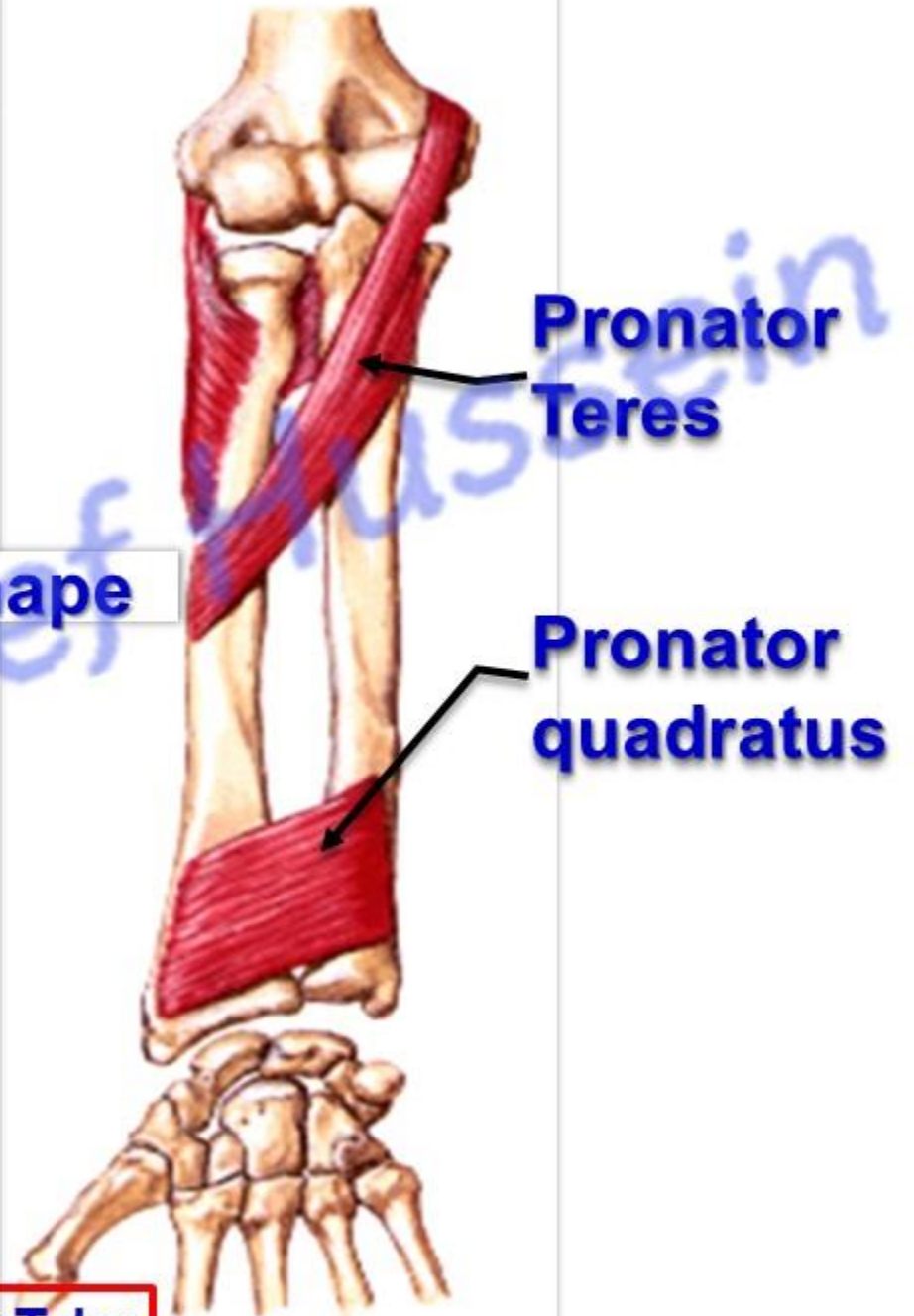
b- It is completed by:

- **Pronator teres** and **Pronator quadratus**.

Pronation



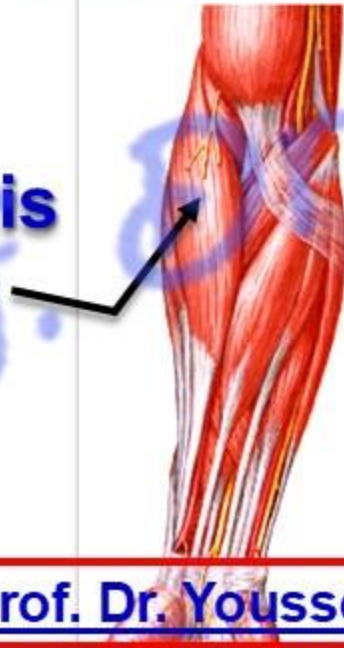
X shape



Pronator Teres

Pronator quadratus

Brachioradialis



Supination

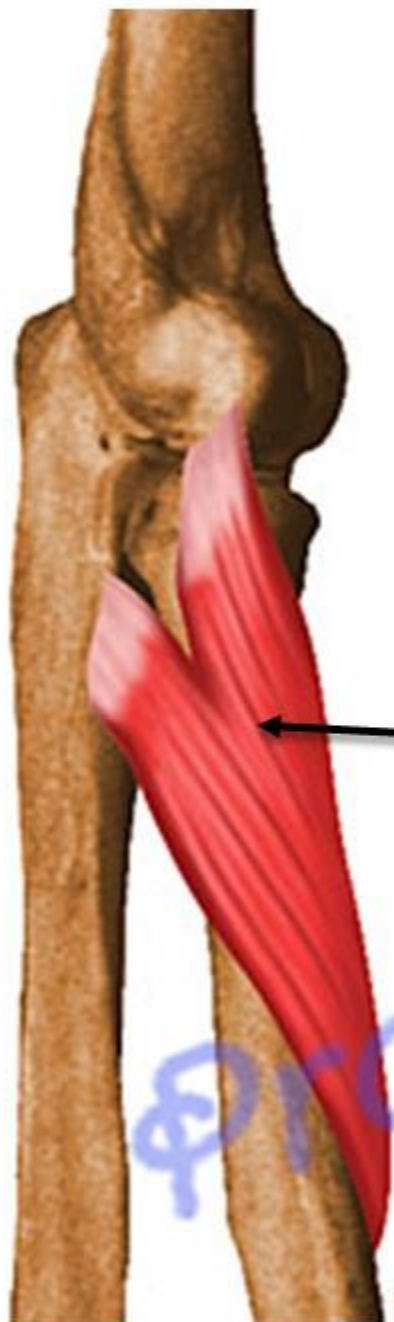- **Supination**

a- It is initiated by brachioradialis.

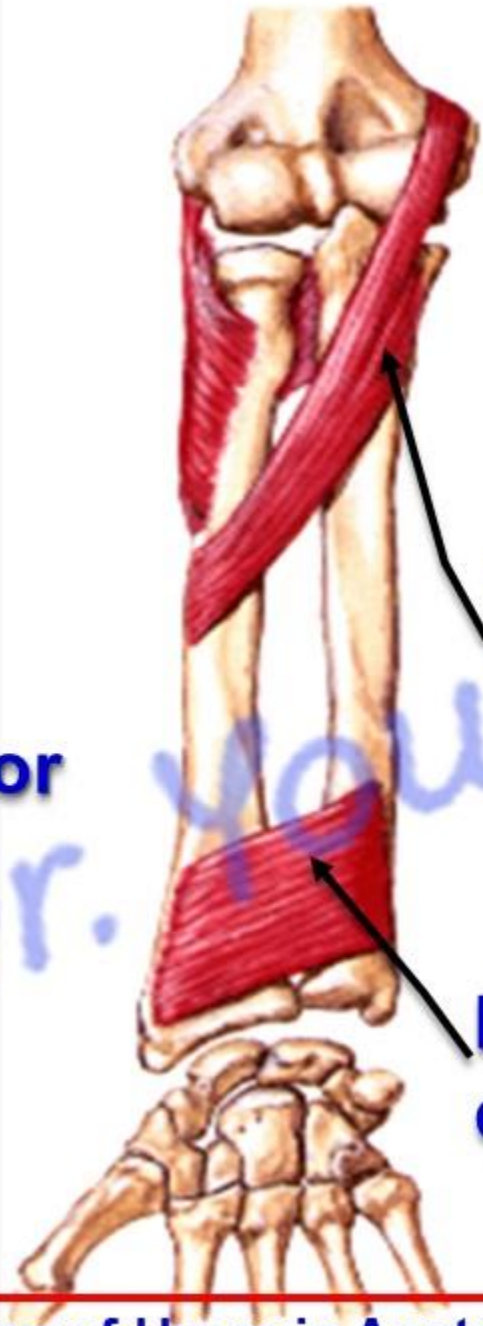
b- It is completed by

- **Supinator** during **extension** of elbow joint.
- **Biceps brachii** during **flexion** of elbow joint.
- Radius is parallel to ulna
- **N.B Supination** is more **powerful** than pronation. Because, in usual working position with elbow flexed (e.g. Turning screwdriver).
- In a semiflexed elbow: palm is turned upwards in supination and downward in pronation (**king pronates and beggar supinates**)



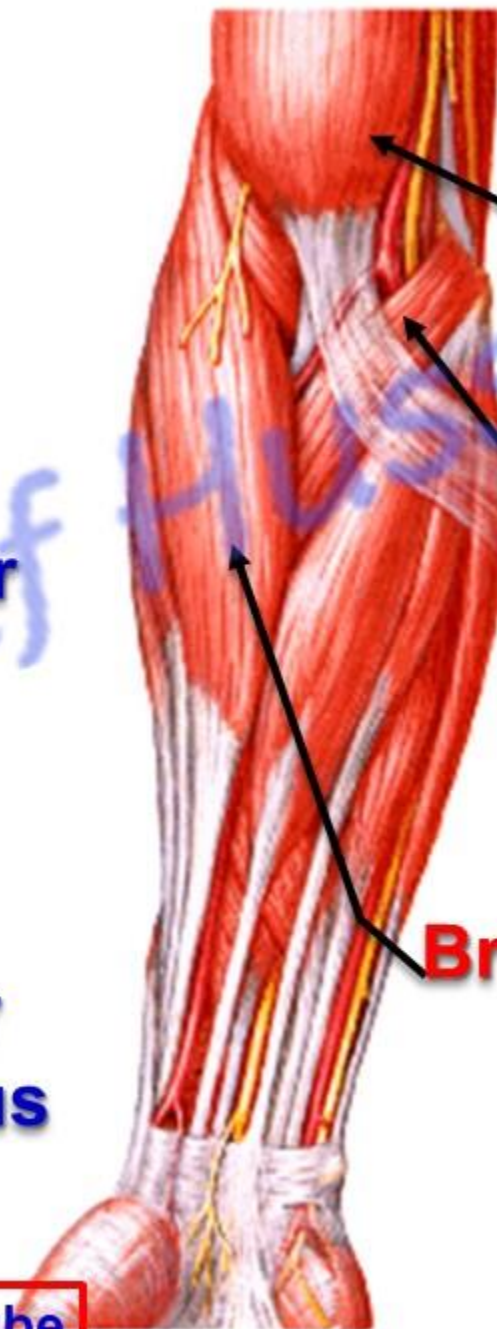


Supinator



**Pronator
Teres**

**Pronator
quadratus**



Biceps

**Pronator
Teres**

Brachioradialis

Radioulnar Joints

- **Middle Radioulnar Joint**

** **Type**; fibrous joint (No movements). It is formed by

1- **Oblique cord**: is a fibrous band extending from ulnar tuberosity to shaft of radius below the radial tuberosity.

2- **Interosseous membrane**: thin sheet of fibrous tissue between interosseous borders of the radius and ulna.

- **Directions of fibres**, obliquely downwards and medially from the radius to the ulna.

- **Functions of interosseous membrane**:

1- It binds radius and ulna.

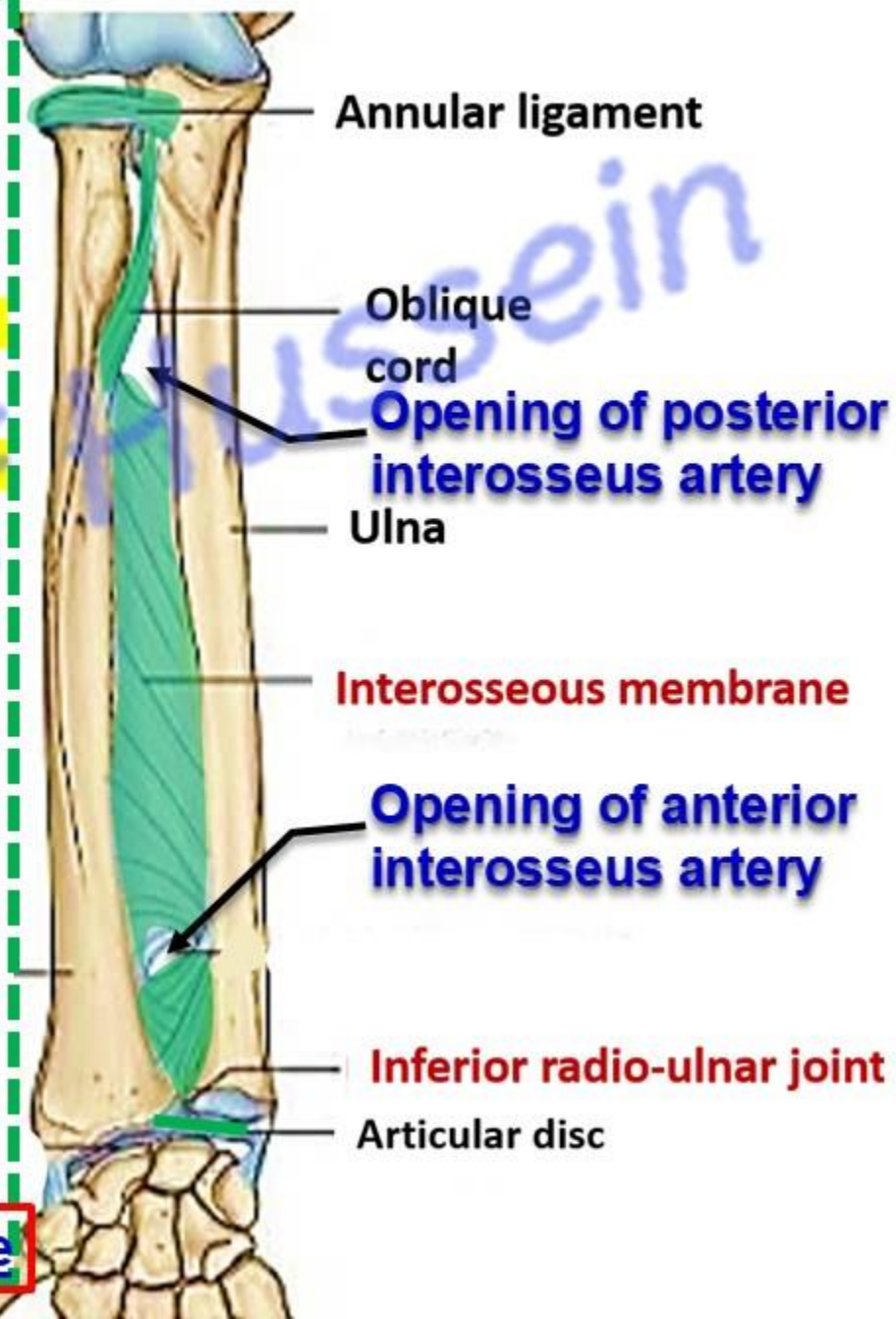
2- Breaks the shock transmitted from hand to radius.

3- It gives origin for the deep muscles of the forearm.

• **Openings**,

1- **Anterior interosseous artery** perforates membrane to the back of the forearm above the upper border of pronator quadratus.

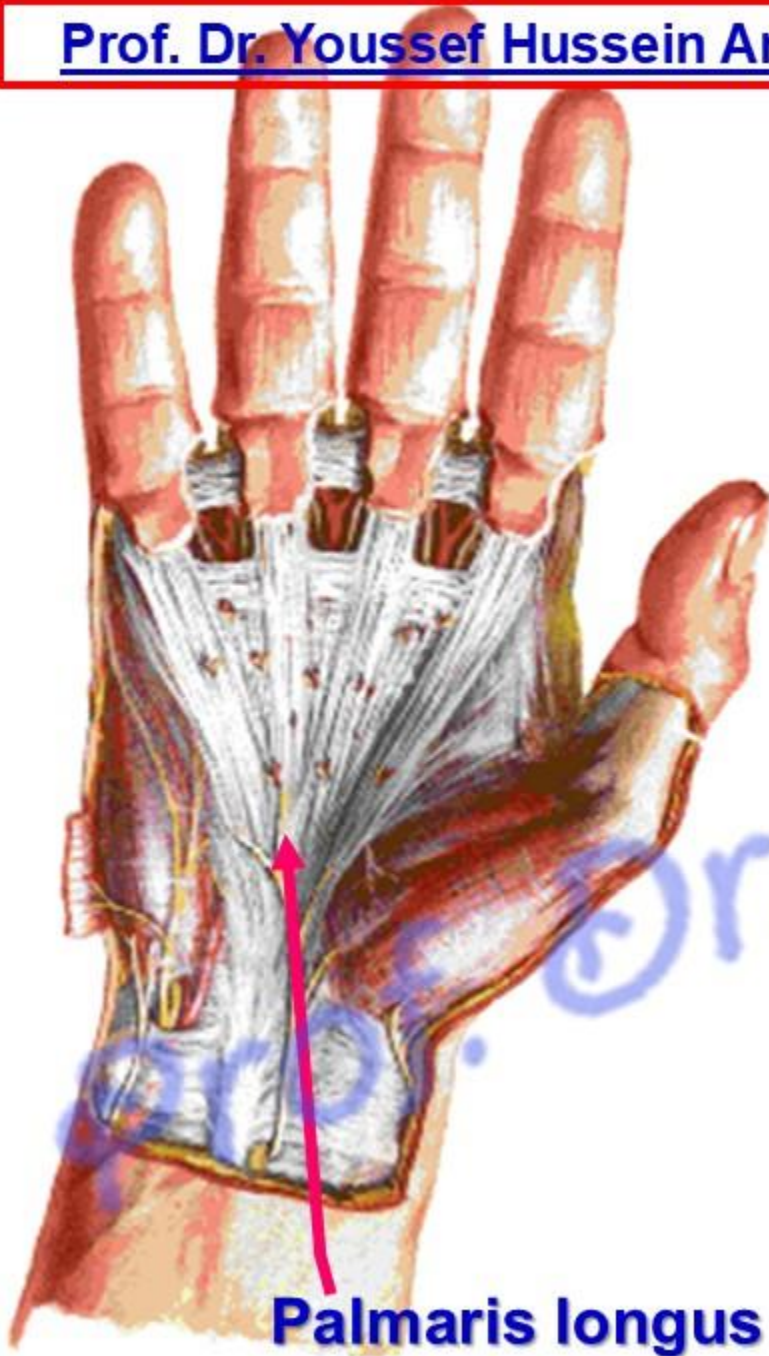
2- **Posterior interosseous artery** passes in gap between the oblique cord and interosseous membrane to the back of the forearm.





Palmar Aponeurosis

Palmar aponeurosis



Palmaris longus

- It is a **thickening of the deep fascia** in the middle of the palm
- It improve the hand grip
- It protects the underlying tendons, blood vessels and nerves

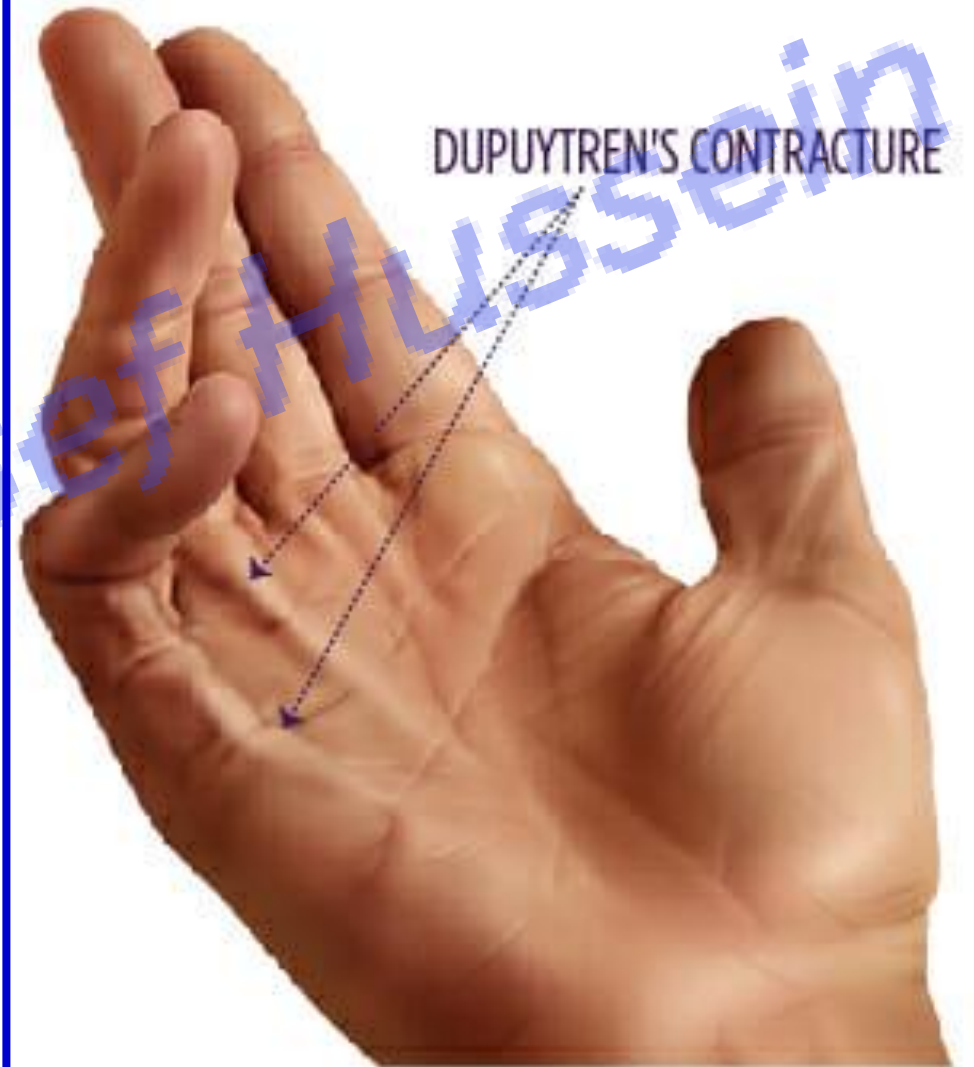**** Shape; - It is a triangular.**

The **apex** is adherent to the flexor retinaculum and gives insertion to the **tendon of palmaris longus**.

- **The base** divides into four slips, one for each of the medial four fingers.

- **** Dupuytren's contracture**

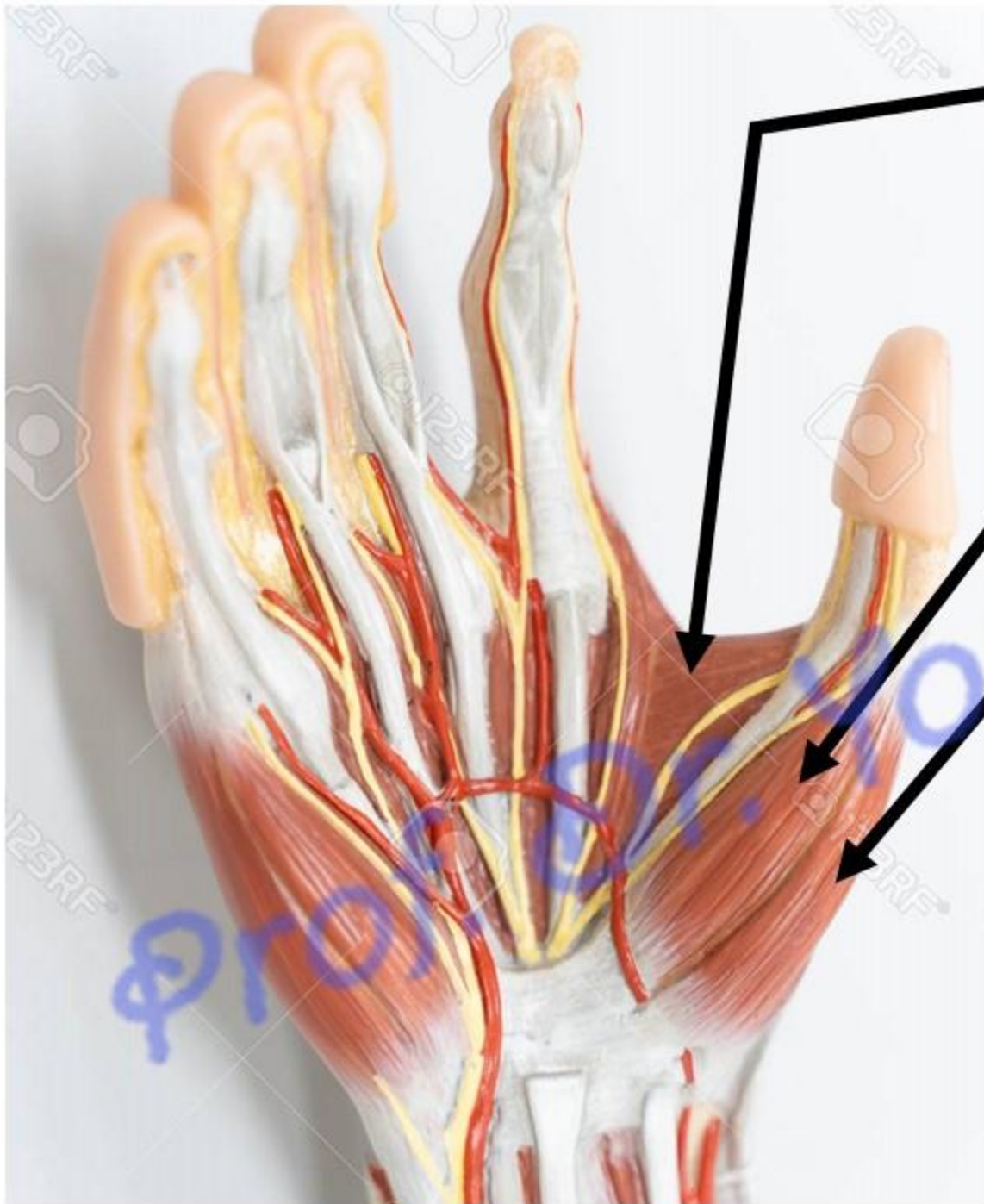- Thickening and fibrosis of the palmar aponeurosis due to its inflammation leading to **permanent flexion** of **metacarpophalangeal** and **proximal interphalangeal** joints of the 4th (ring) and 5th (little finger) because the fibrous tissue (fascia) thickening in the palm is more concentrated in those areas.
- It is painless condition
- the exact cause is unknown, it is largely genetic (hereditary)



Muscles of the Hand

Thenar muscles

Short muscles of thumb



4- Adductor pollicis

3- Opponens Pollicis
deep to abductor and
flexor pollicis brevis

2- Flexor pollicis brevis

1- Abductor pollicis brevis

- Nr. 1,2,&3 called thenar eminence
- **Nerve supply:** All thenar muscles supplied by lateral division of median nerve **except** adductor pollicis by deep branch of ulnar nerve.
- Thenar eminence has the same nerve & origin

1- Abductor Pollicis Brevis

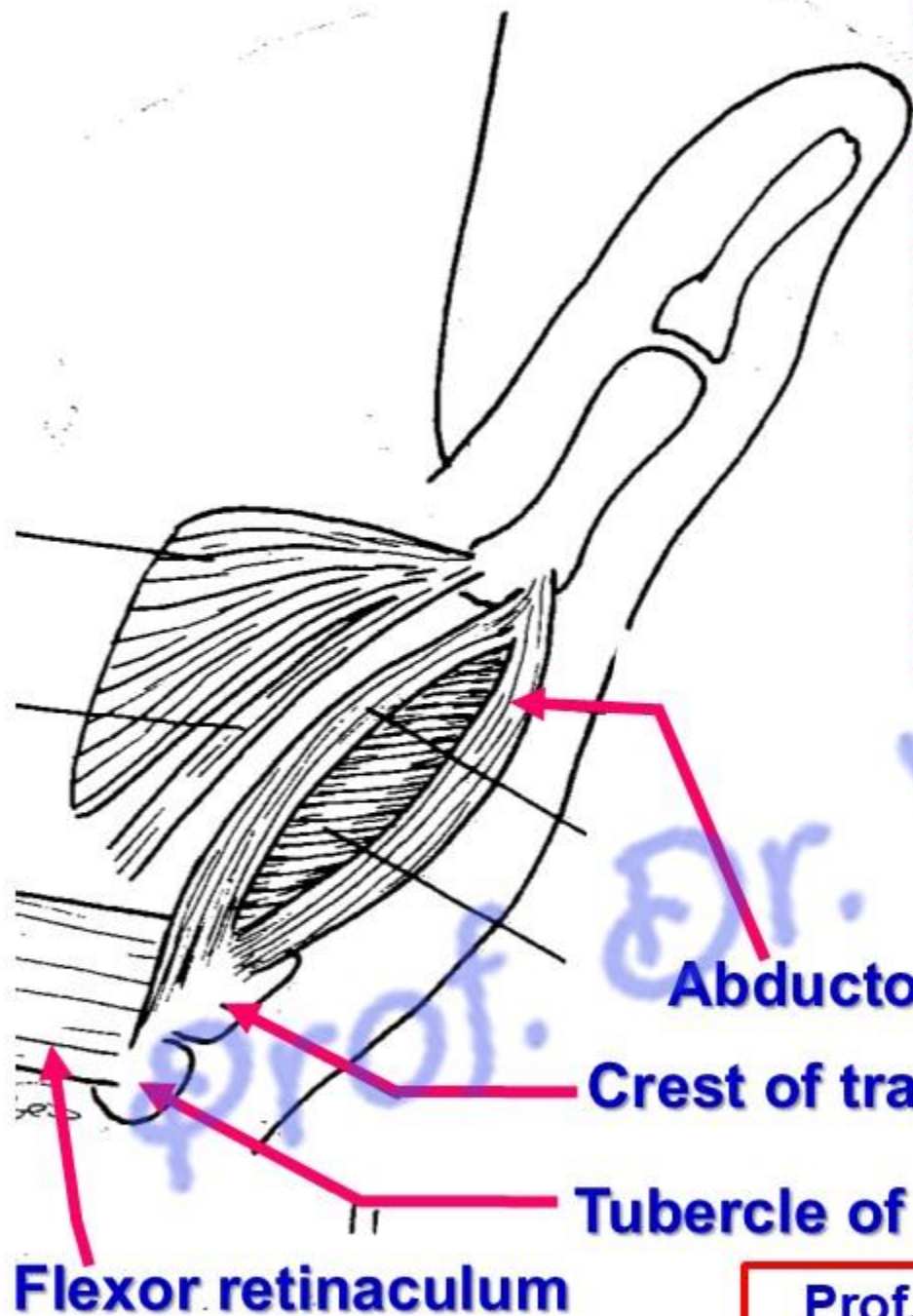
** **Site**; in the lateral part of the thenar eminence.

** **Origin**: a) lateral part of flexor retinaculum.

b) Tubercle of scaphoid. C) Crest of trapezium.

** **Insertion**; into the lateral side of the base of the proximal phalanx of the thumb.

** **Actions**: abduction of the thumb.



Abductor pollicis brevis

Crest of trapezium

Tubercle of scaphoid

Flexor retinaculum

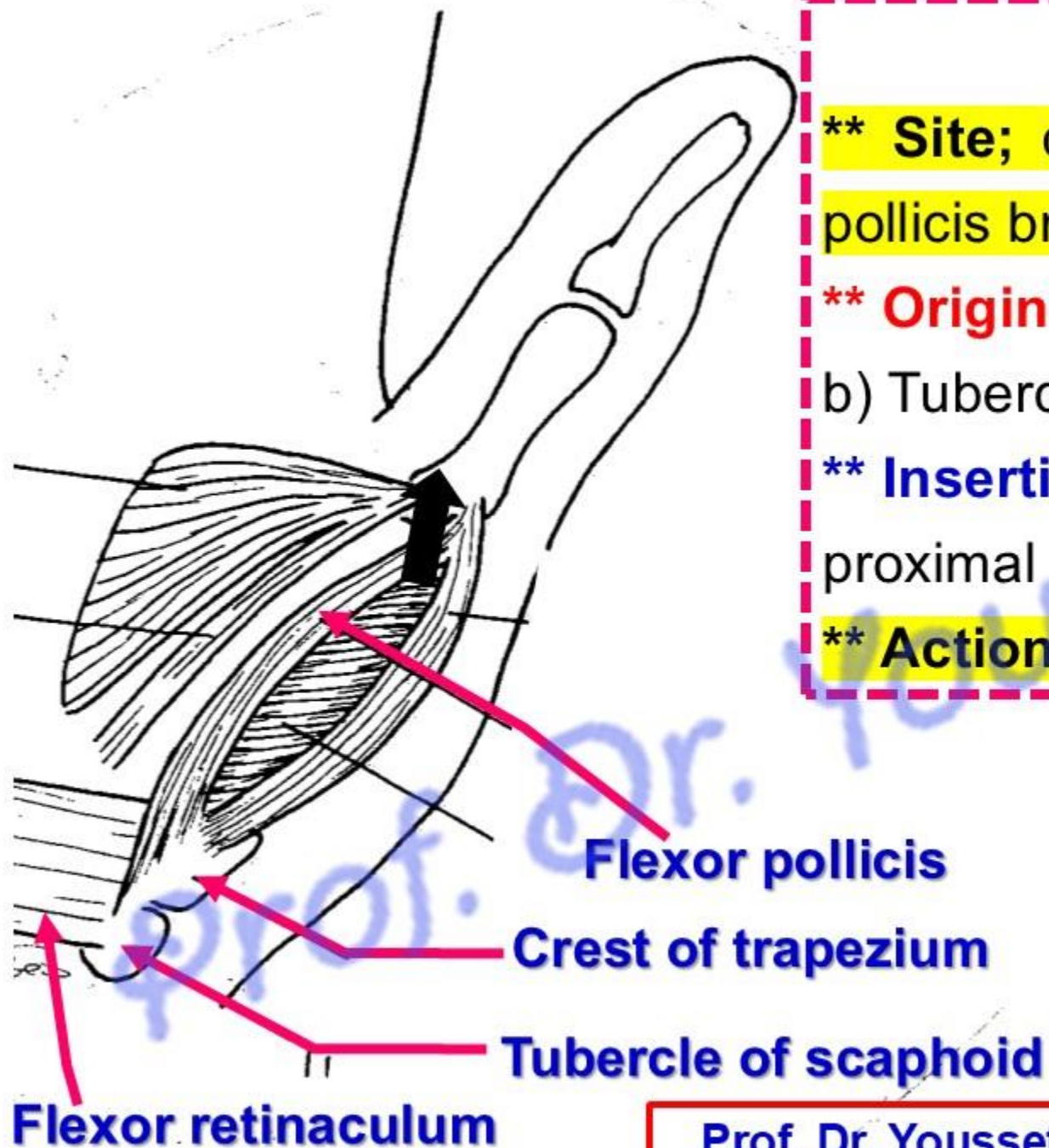
2- Flexor Pollicis

**** Site;** close to the medial side of the abductor pollicis brevis.

**** Origin:** a) lateral part of flexor retinaculum.
b) Tubercle of scaphoid. C) Crest of trapezium.

**** Insertion;** into the medial side of the base of the proximal phalanx of the thumb.

**** Actions:** flexion of the thumb.



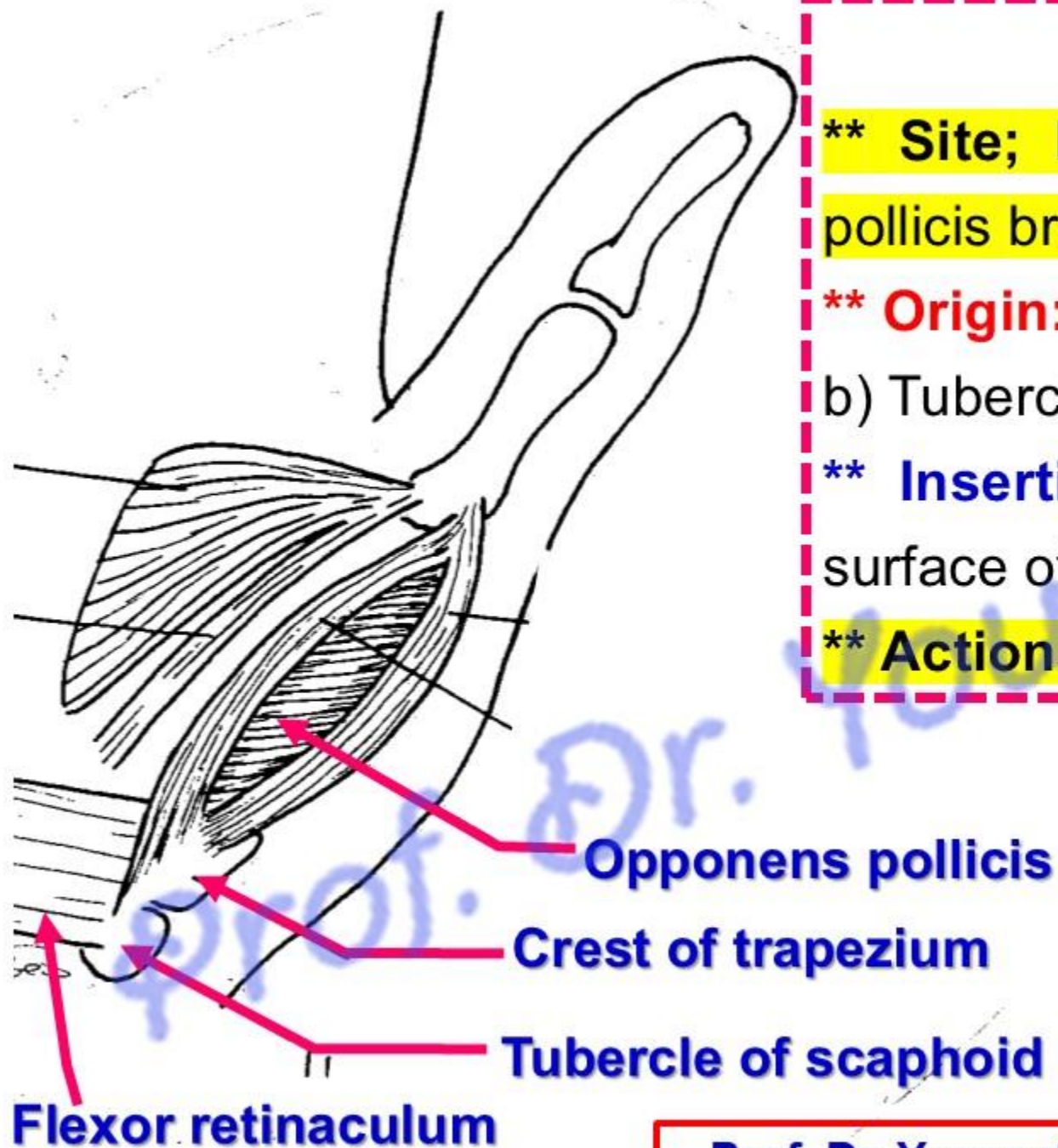
3- Opponens Pollicis

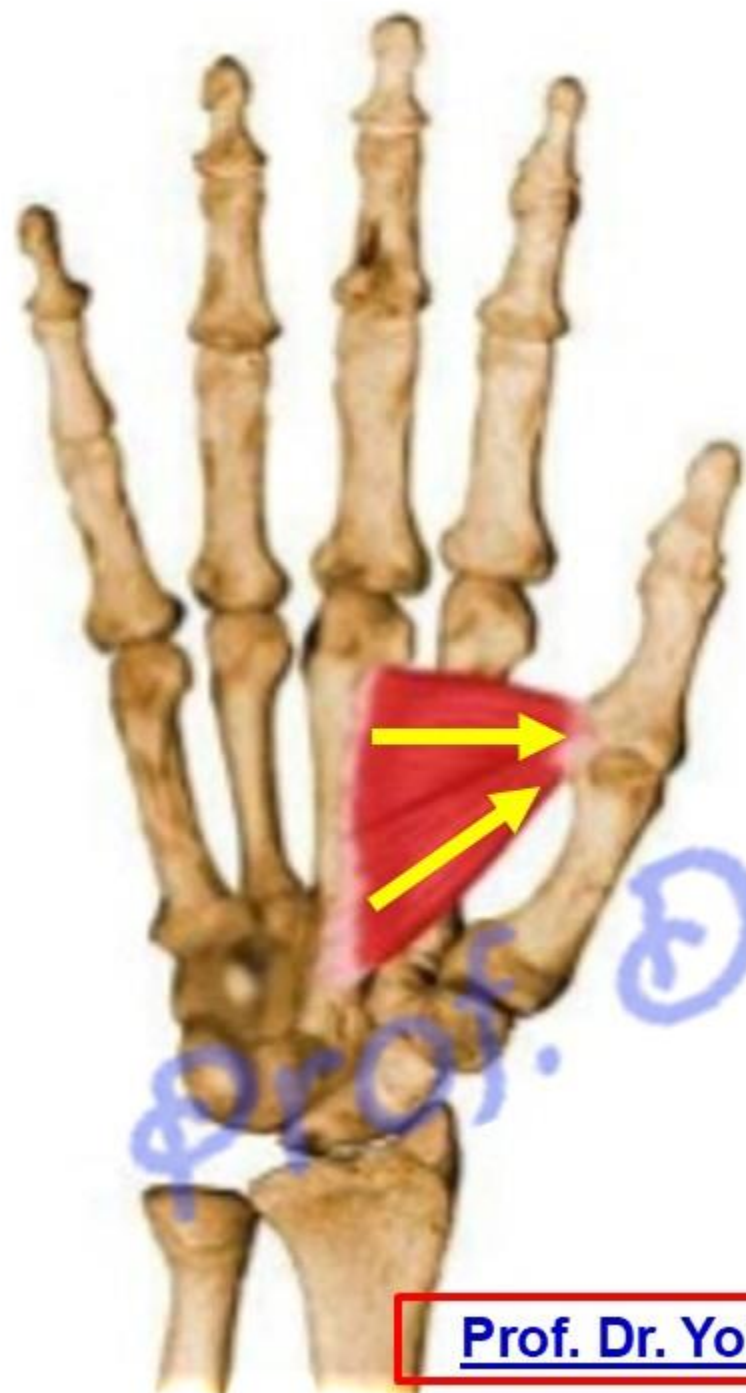
**** Site;** It lies deep to the abductor and flexor pollicis brevis.

**** Origin:** a) lateral part of flexor retinaculum.
b) Tubercle of scaphoid. C) Crest of trapezium.

**** Insertion;** into the lateral half of the palmar surface of the first metacarpal bone. .

**** Actions:** Opposition of the thumb.





4- Adductor Pollicis

**** Origin:** by two heads:

a- Oblique head: from the bases of the 2nd and 3rd metacarpal and carpal bones.

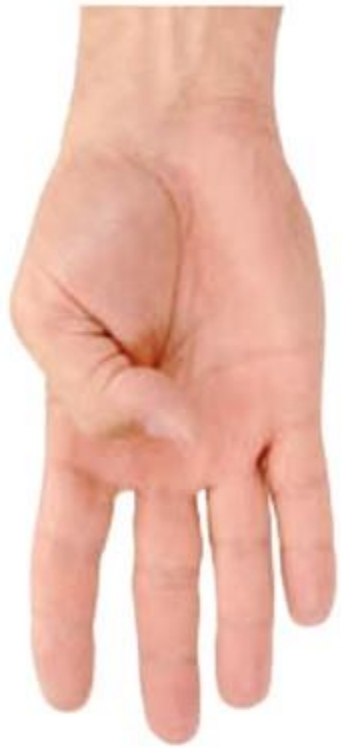b- Transverse head: from the palmar surface of the 3rd metacarpal bone.

*** Insertion:** into the medial side of the base of the proximal phalanx of the thumb.

*** Nerve supply:** deep branch of the ulnar nerve.

*** Actions:** adduction of the thumb.

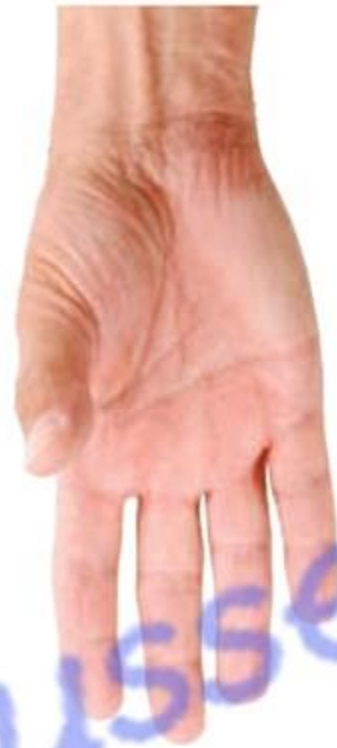N.B; A small **sesamoid** bone is developed in the tendon of adductor pollicis.



Flexion



Extension



Abduction



Adduction



Opposition

Movements of the thumb

Hypothenar muscles

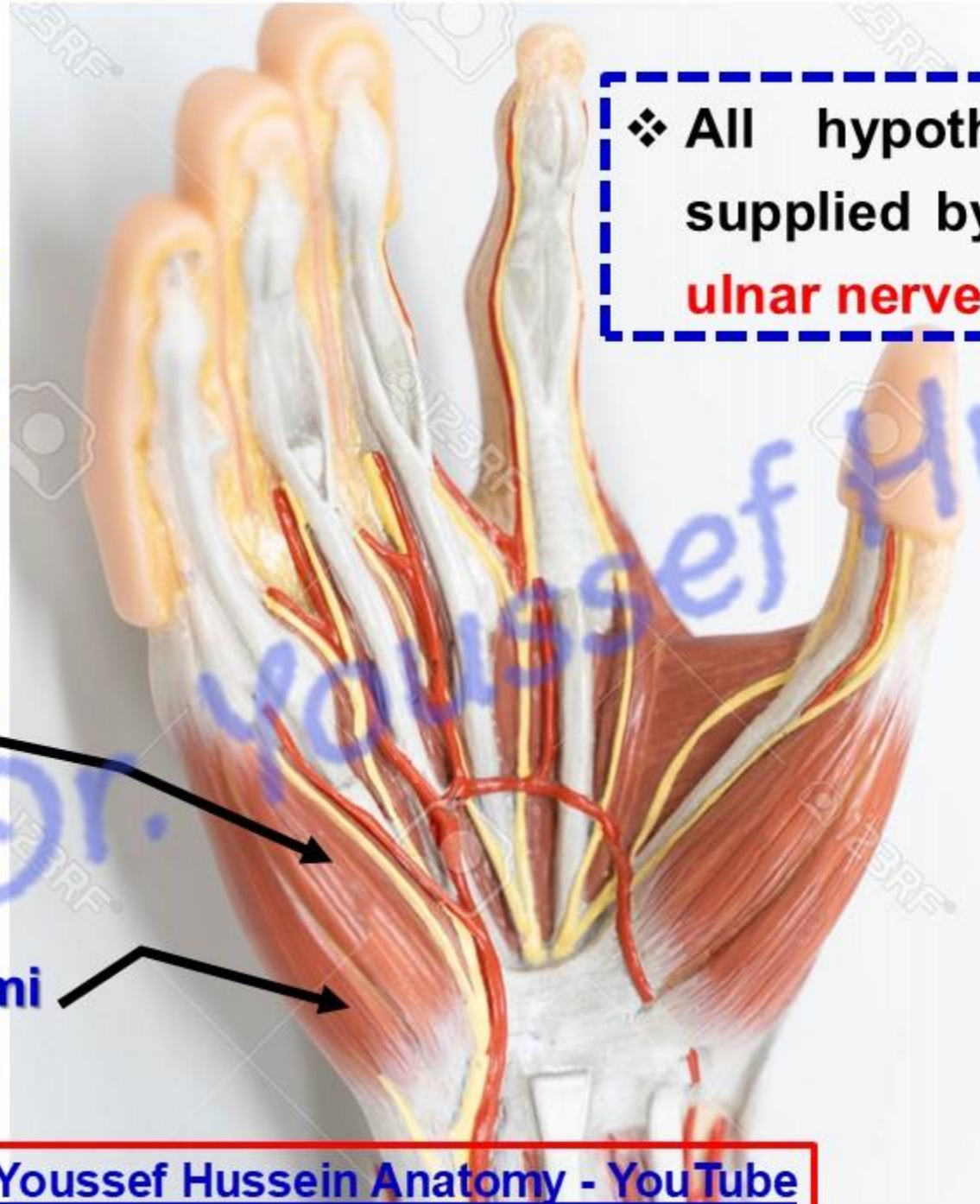
**Short muscles of
little finger**

3- Opponens digiti minimi deep to abductor and flexor digiti minimi

2- Flexor digiti minimi

1- Abductor digiti minimi

❖ All hypothenar muscles are supplied by **deep branch of the ulnar nerve**



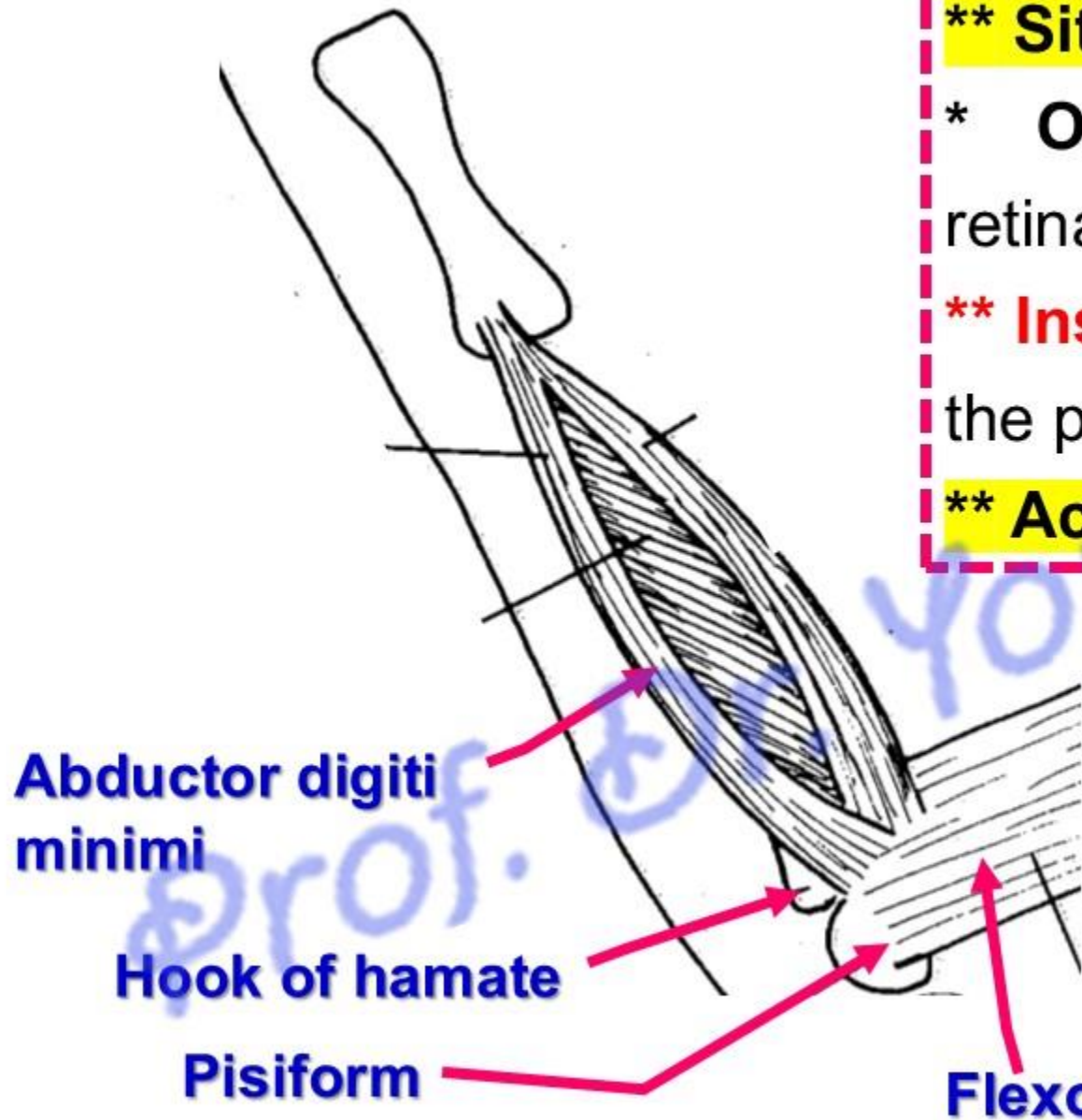
1- Abductor Digiti Minimi

**** Site;** in medial part of hypothenar eminence

*** Origin:** a) Medial part of the flexor retinaculum. b) Pisiform and hook of hamate.

**** Insertion:** into the medial side of the base of the proximal phalanx of the little finger.

**** Action:** abduction of the little finger.



[Prof. Dr. Youssef Hussein Anatomy - YouTube](#)

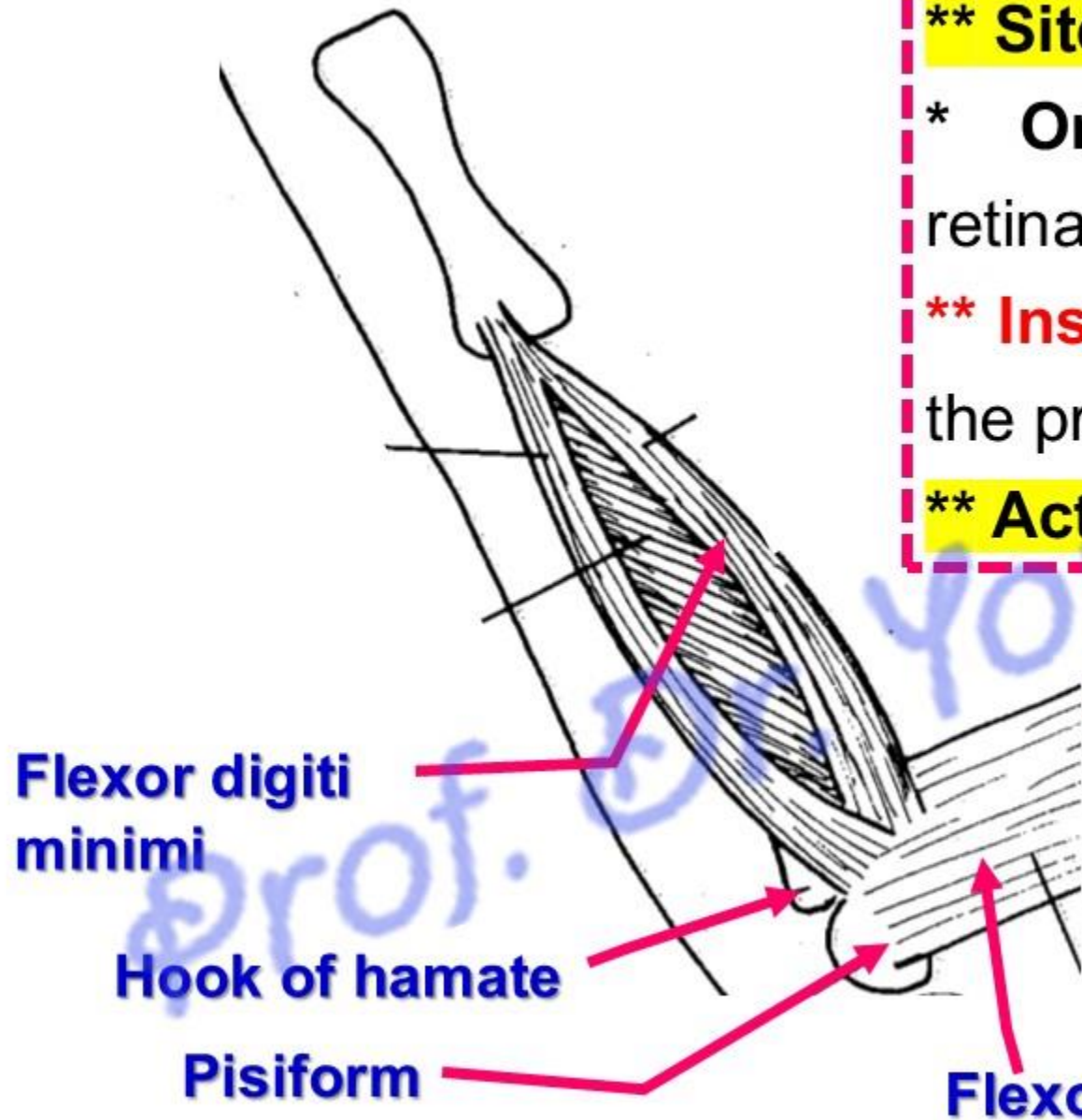
2- Flexor Digiti Minimi

**** Site;** lateral to abductor digiti minimi

* **Origin:** a) Medial part of the flexor retinaculum. b) Hook of hamate.

**** Insertion:** into the medial side of the base of the proximal phalanx of the little finger.

**** Action:** Flexion of the little finger.



[Prof. Dr. Youssef Hussein Anatomy - YouTube](#)

3- Opponens Digiti Minimi

**** Site;** deep to the flexor and abductor digiti minimi

**** Origin:** a) Medial part of the flexor retinaculum.
b) Hook of hamate.

**** Insertion:** Into the medial half of the palmar surface of the 5th metacarpal bone.

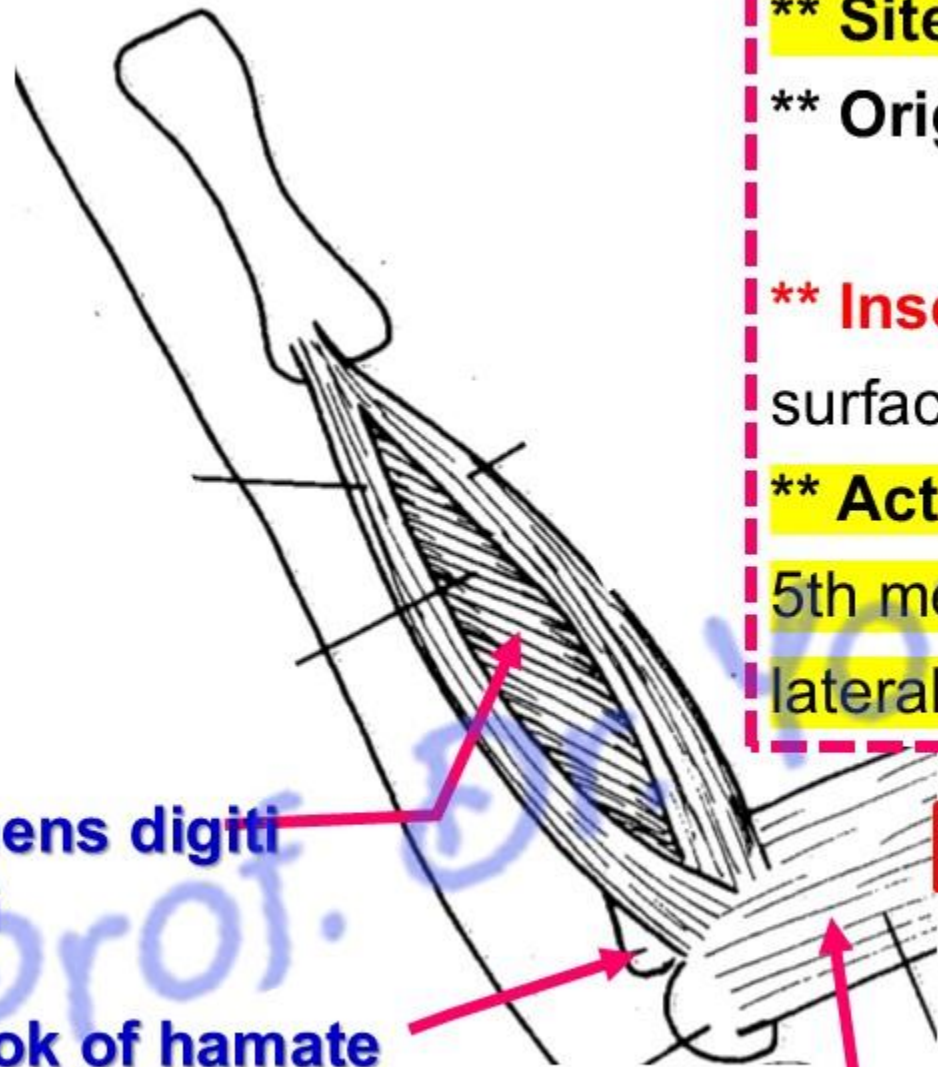
**** Action:** opposition of the little finger (It pulls the 5th metacarpal bone slightly forwards and rotates it laterally).

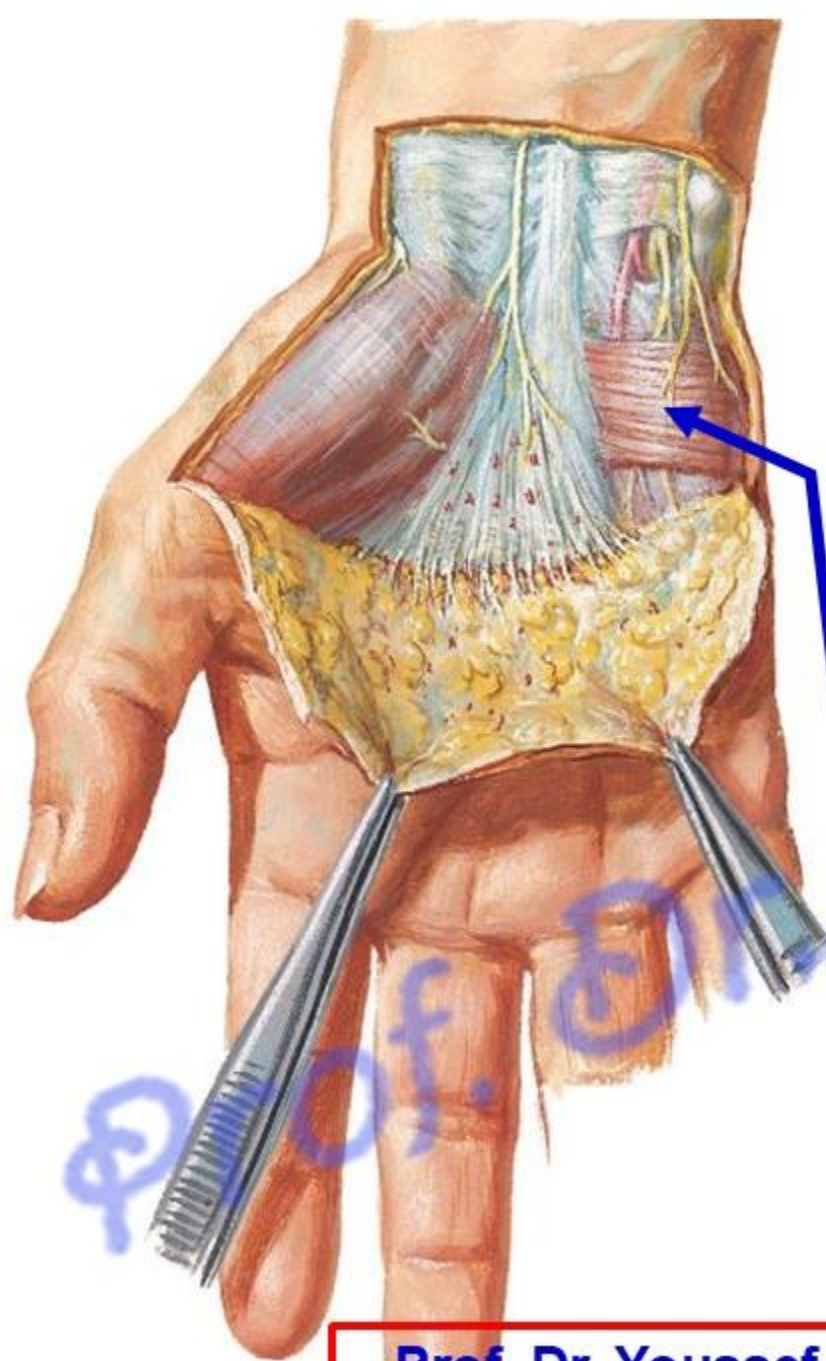
Opponens digiti
minimi

Hook of hamate

Flexor retinaculum

Prof. Dr. Youssef Hussein Anatomy - YouTube





Palmaris brevis

- **Palmaris Brevis**

- in superficial fascia covering hypothenar eminence.

- It may be **absent**.

- ** **Origin:** from the palmar aponeurosis

- ** **Insertion:** skin on the medial border of the hand.

- ** **Nerve supply:** superficial branch of ulnar nerve.

- ** **Action:** deepen the hollow of the palm.

Lumbricalis muscles

Interossei muscles

- ❖ All muscles are supplied by **deep branch of the ulnar nerve**
EXCEPT
 - The **1st lumbricalis** from **lateral division of median nerve**
 - The **2nd lumbricalis** from **medial division of median nerve**

Lumbricalis muscles

• Lumbrical Muscles

- They are **4 muscles** arranged from lateral to medial side.

** **Origins:** tendons of the flexor digitorum profundus

1- The 1st and 2nd are unipennate

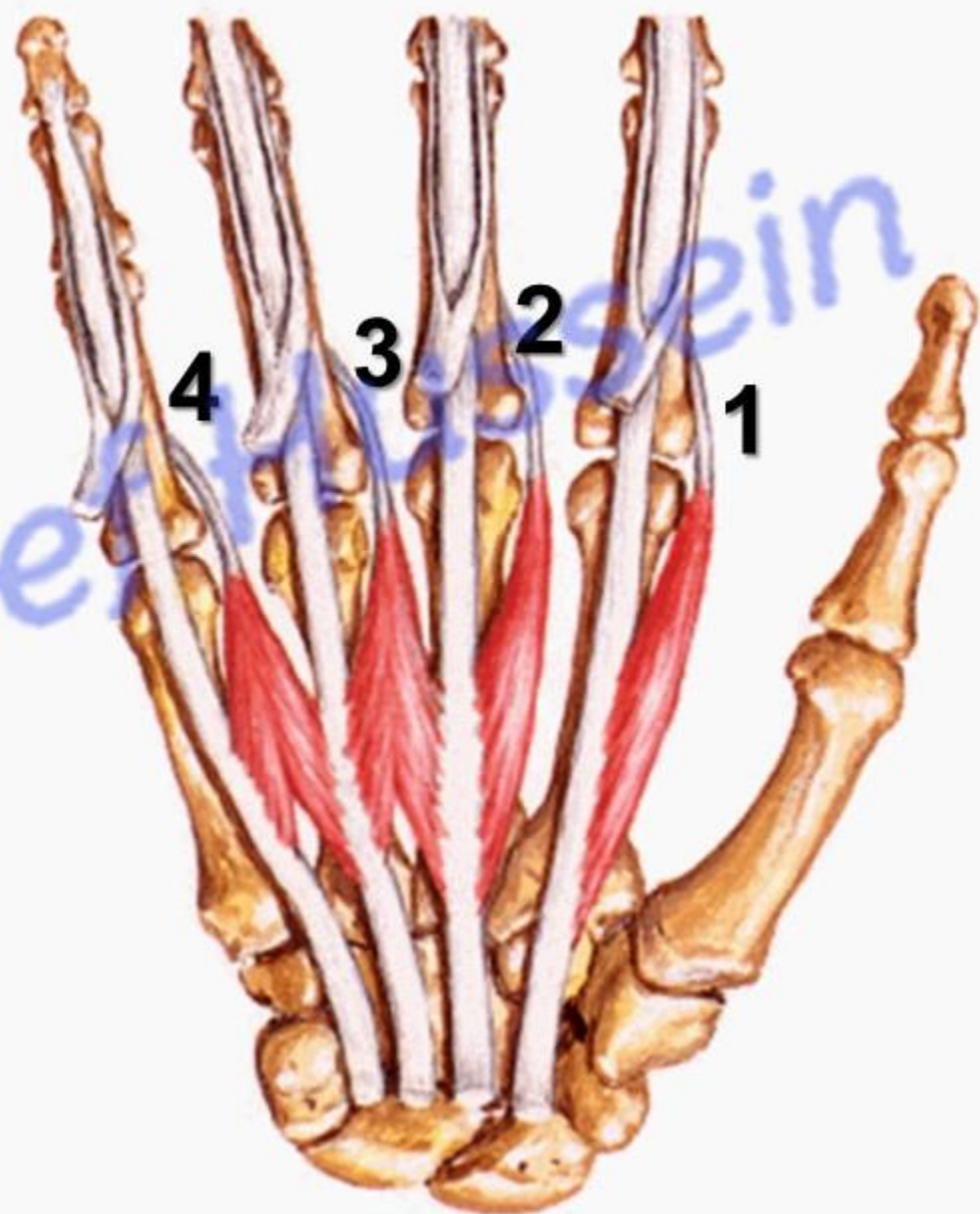
2- The 3rd and 4th are bipennate.

** **Insertions** extensor expansion of the corresponding finger.

** each tendon crosses the **lateral** side of the corresponding metacarpophalangeal joint.

** **Actions:**

Flexion of the metacarpophalangeal Joints and extension the interphalangeal joints of the medial 4 fingers (**writing position**).



Palmar interossei muscles

- **Palmar interossei**

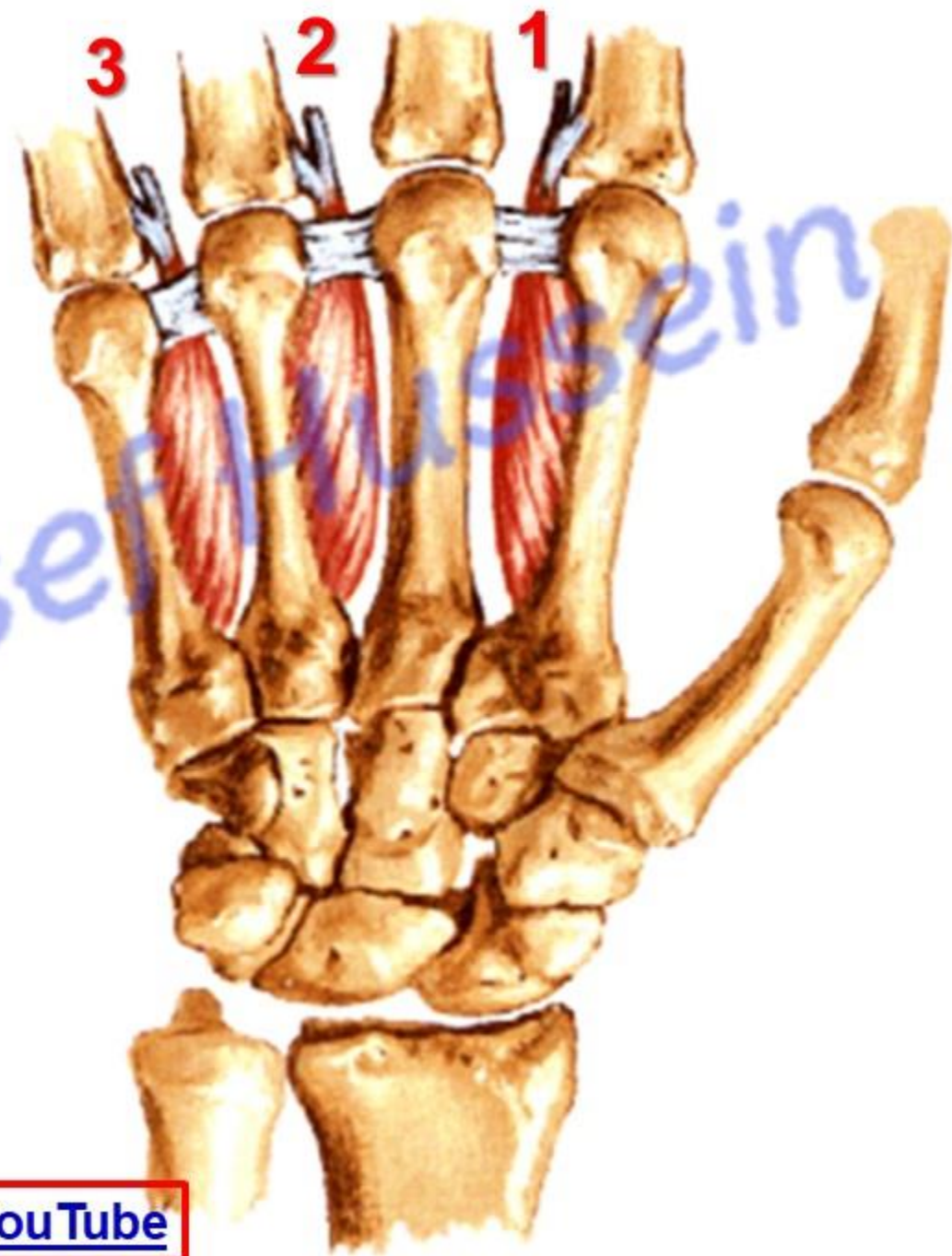
- They are smaller than the dorsal interossei.

**** Origin**

- **1st** from the **medial** side of the **2nd** metacarpal bone.

- **2nd** from the **lateral** side of the **4th** metacarpal bone.

- **3rd** from the **lateral** side of the **5th** metacarpal bone.



**Palmar interossei are
Unipennate**

- **Palmar interossei**

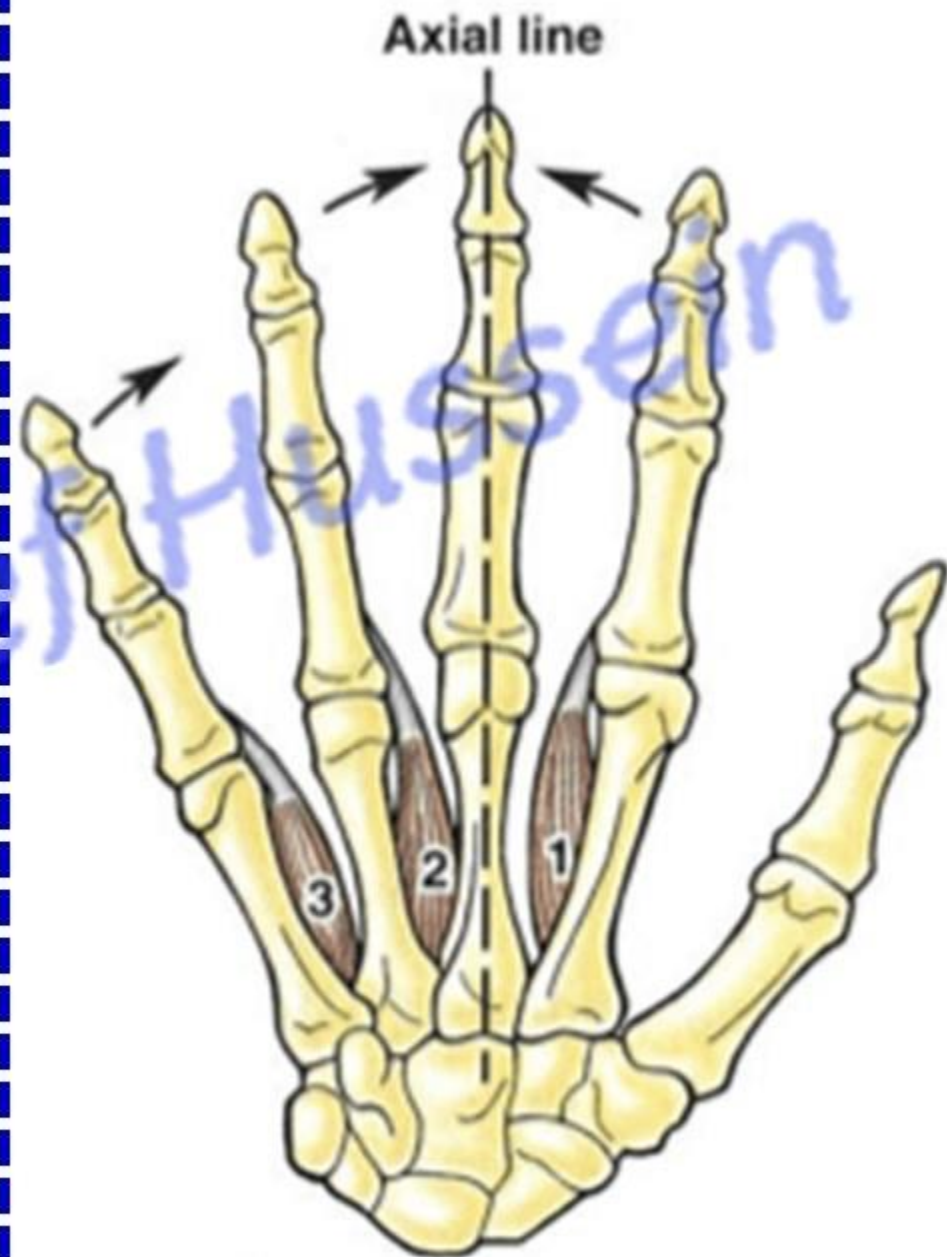
**** Insertion**

- **1st** to **medial** side of the proximal phalanx and extensor expansion of the **index**.
- **2nd** to **lateral** side of the proximal phalanx and the extensor expansion of the **ring**.
- **3rd** to **lateral** side of the proximal phalanx and the extensor expansion of the **little finger**.

**** Actions: adduct** the fingers towards the axis.

- They assist lumbricals in flexion of metacarpophalangeal Joints and extension interphalangeal joints (**writing positions**).

N.B: No palmar interossei to the middle finger (axis)



Dorsal interossei muscles

- **Dorsal interossei**
(4 in number)

** **Origin** from adjacent sides of the metacarpal bones.

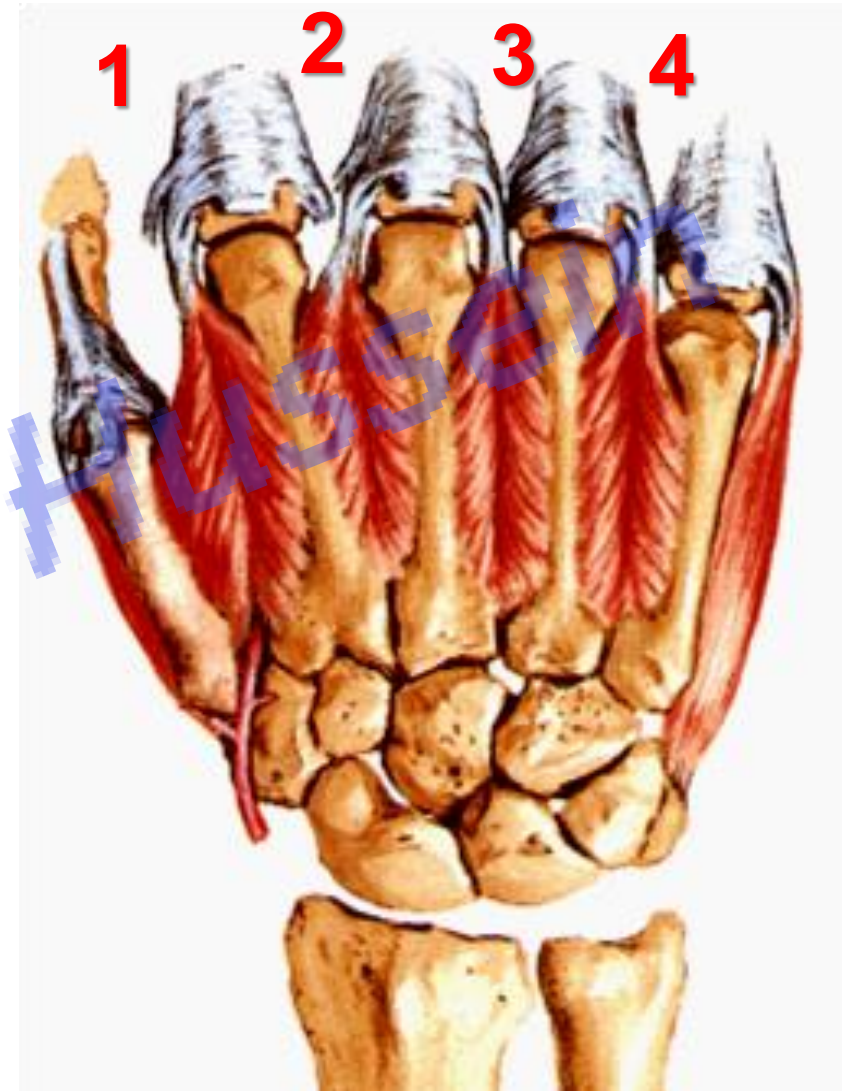
1- The 1st From the adjacent sides of the **1st and 2nd** metacarpal bones.

- (large) and sometimes called ***abductor indicis***.

2- The 2nd from the adjacent sides of the **2nd and 3rd** metacarpal bones.

3- The 3rd from the adjacent sides of the **3rd and 4th** metacarpal bones.

4- The 4th from the adjacent sides of the **4th and 5th** metacarpal bones.



**Dorsal interossei are
Bipennate**

Prof. Dr. Youssef Hussein Anatomy - YouTube

- **Dorsal interossei**

**** Insertion:**

[Prof. Dr. Youssef Hussein Anatomy YouTube](#)

1- **The 1st** into the **lateral** side base of the proximal phalanx and extensor expansion of the **index**.

2- **The 2nd** into the **lateral** side of the base of the proximal phalanx and extensor expansion of the **middle** finger.

3- **The 3rd** into the **medial** side of the base of the proximal phalanx and extensor expansion of the **middle** finger.

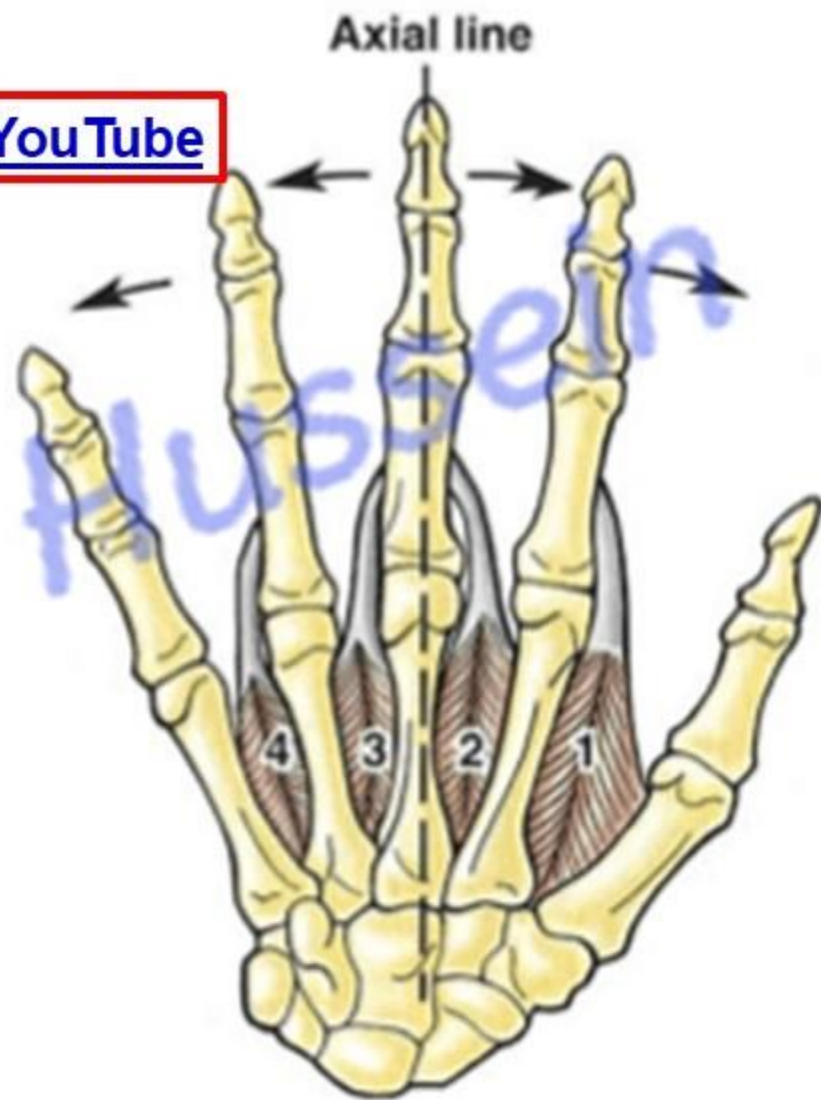
4- **The 4th** into the **medial** side of the base of the proximal phalanx and extensor expansion of the **ring** finger.

**** Actions:** **abduct** the fingers away from the axis of the middle finger.

- They assist lumbricals in flexion of metacarpophalangeal Joints and extension interphalangeal joints (**writing positions**).

N.B: No dorsal interossei to thumb and little fingers

- The axis receives two (2nd & 3rd) dorsal interossei



Fascial Spaces In the hand

- **Fascial Spaces In the hand**

Medial compartment
Hypothenar eminence

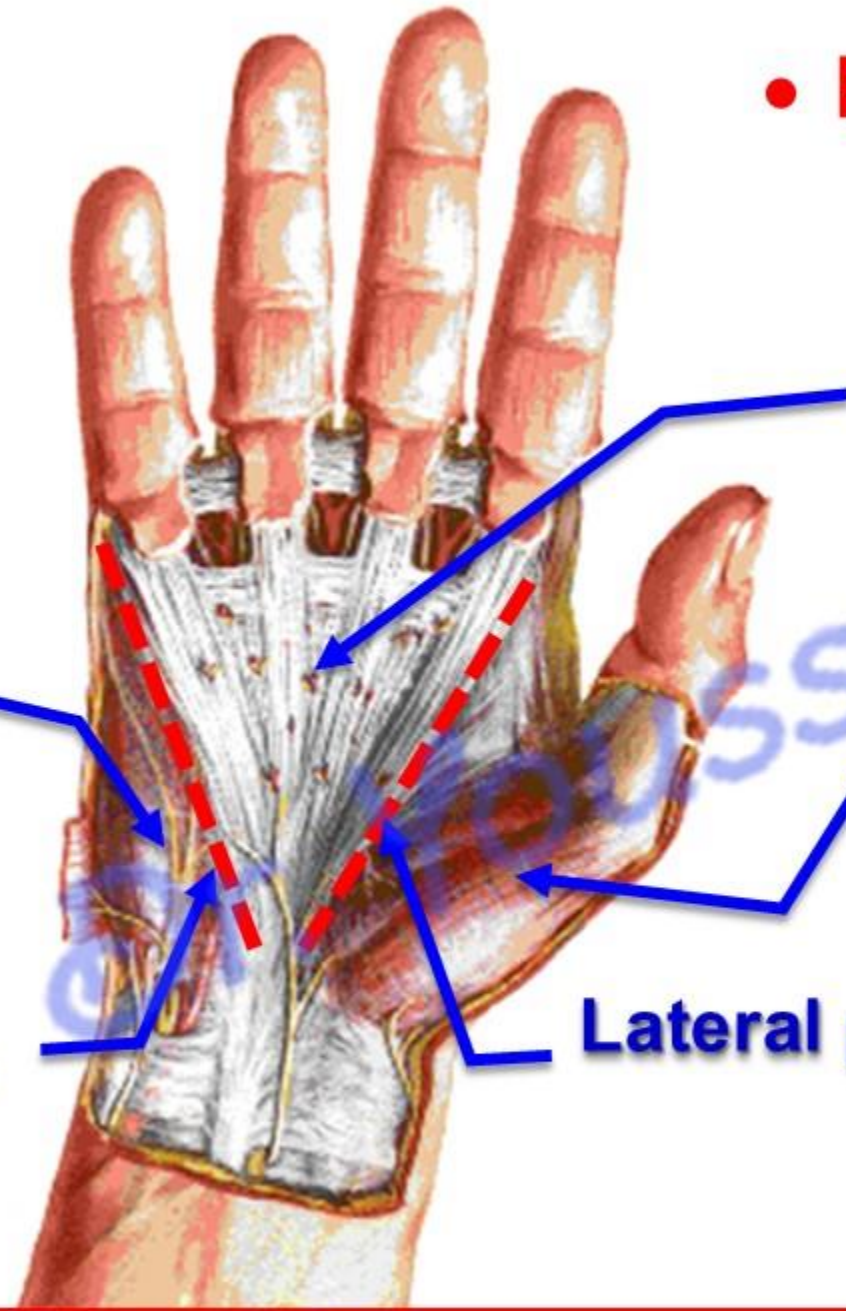
Palmar aponeurosis

Intermediate compartment

Lateral compartment
Thenar eminence

Medial palmar septum

Lateral palmar septum



• Fascial Spaces In the hand

- Two palmar septa (medial and lateral) From palmar aponeurosis divide palm into 3 main fascial compartments.

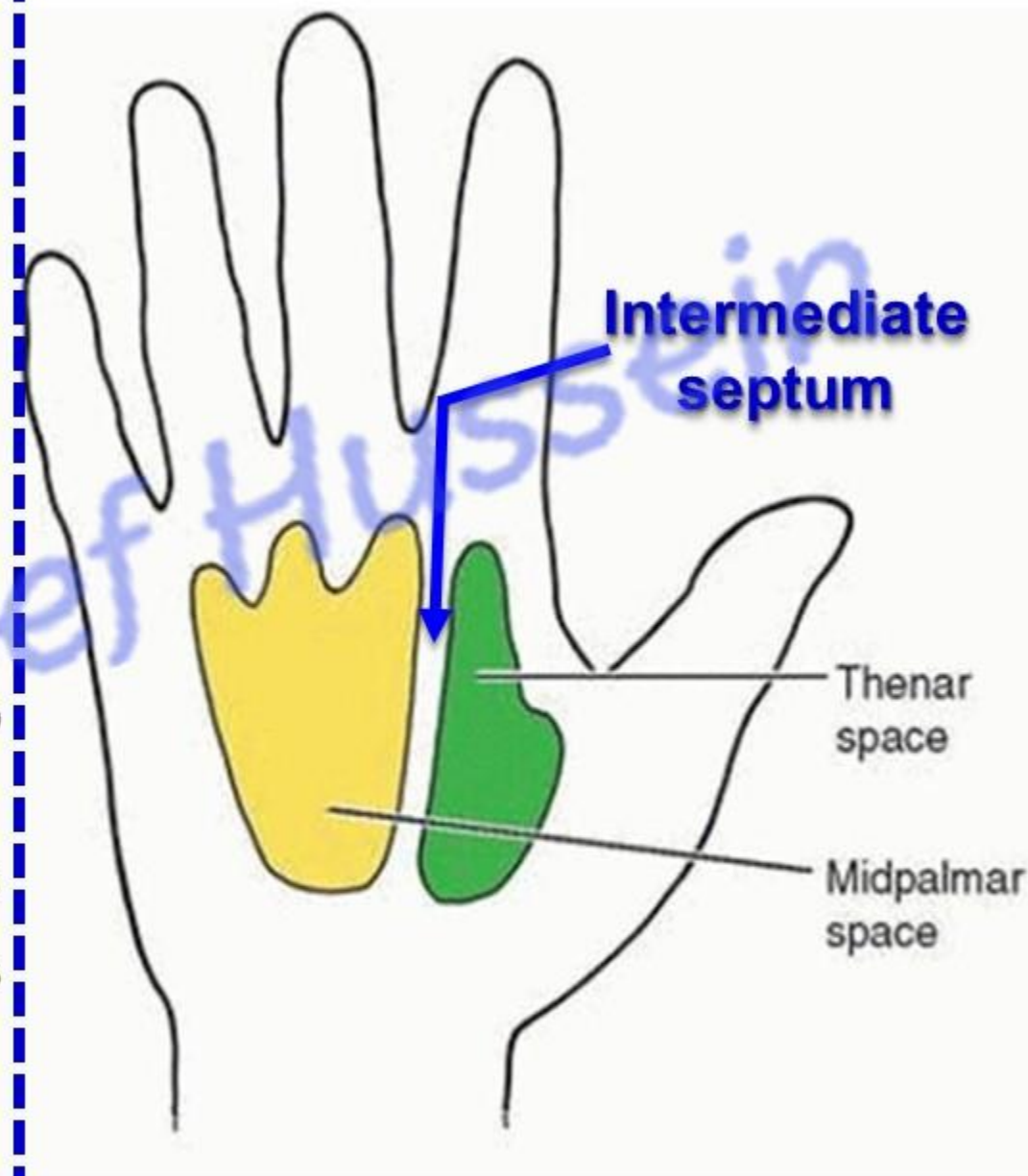
1- Lateral compartment: contains muscles of thenar eminence.

2- Medial compartment: contains muscles of hypothenar eminence.

3- Intermediate compartment: is the wide space deep to the palmar aponeurosis.

- **An intermediate septum** extends from the deep surface of palmar aponeurosis **between** flexor tendons of the index **laterally** and the 2nd lumbrical **medially**.

- It divides this compartment into **medial (midpalmar space)** and **lateral (thenar space)** parts.



a- Thenar space

** Contents;

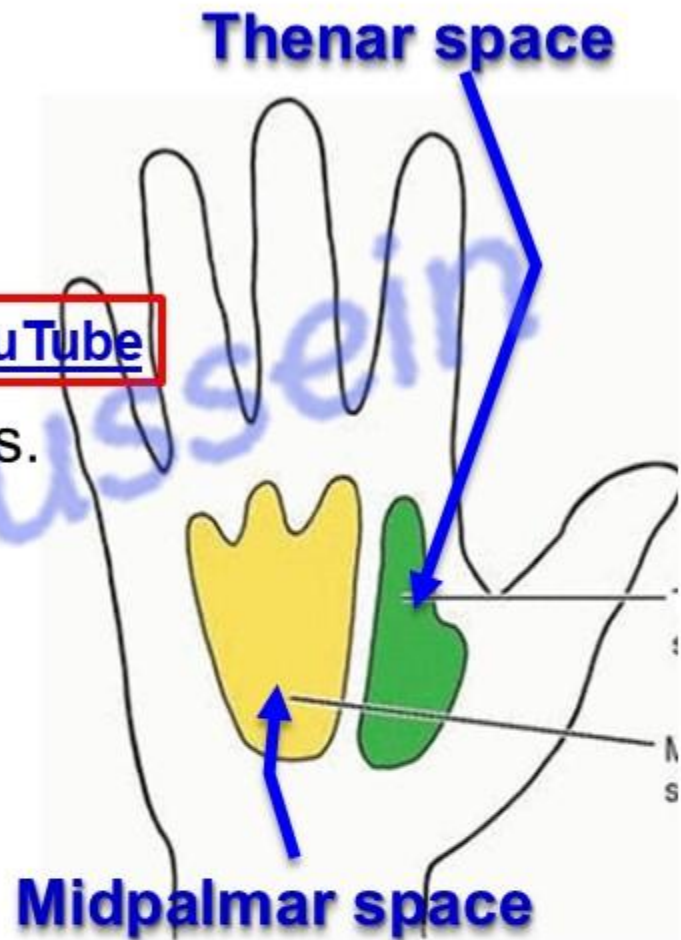
- a- Flexor tendons of the index.
- b- The first lumbricals. [Prof. Dr. Youssef Hussein Anatomy - YouTube](#)
- c- Digital vessels and nerves of the lateral one and half fingers.

N.B. surgical anatomy: It lies superficial to adductor pollicis forming a deep connection between radial and ulnar bursa leading to spread of infection in the palm of the hand

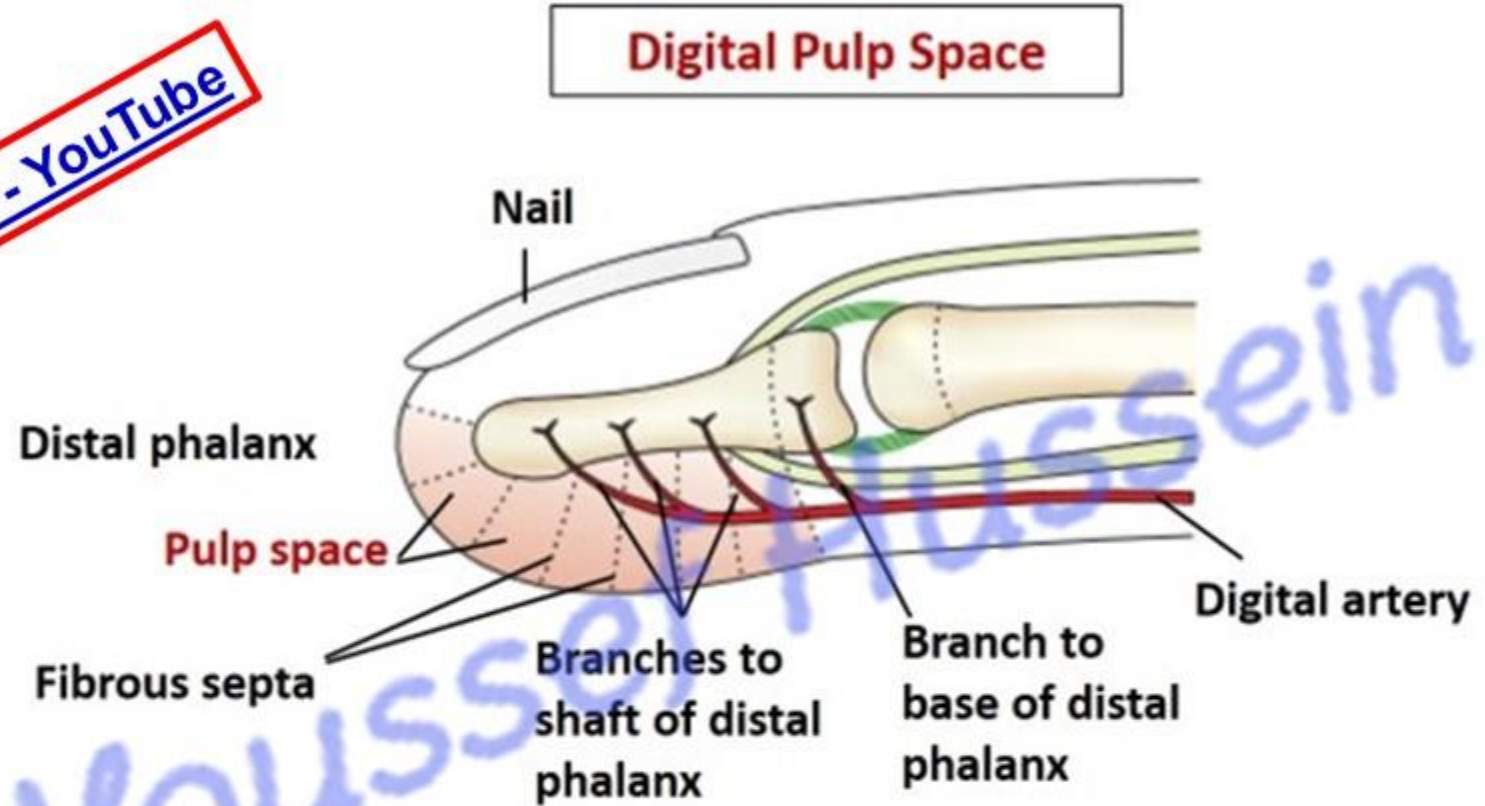
b- Midpalmar space

** Contents;

- a - Flexor tendons of the middle, ring and little fingers.
- b- The 2nd, 3rd and 4th lumbricals
- c- Digital vessels and nerves of the medial three and half fingers.
- D- Superficial and deep palmar arches and their branches



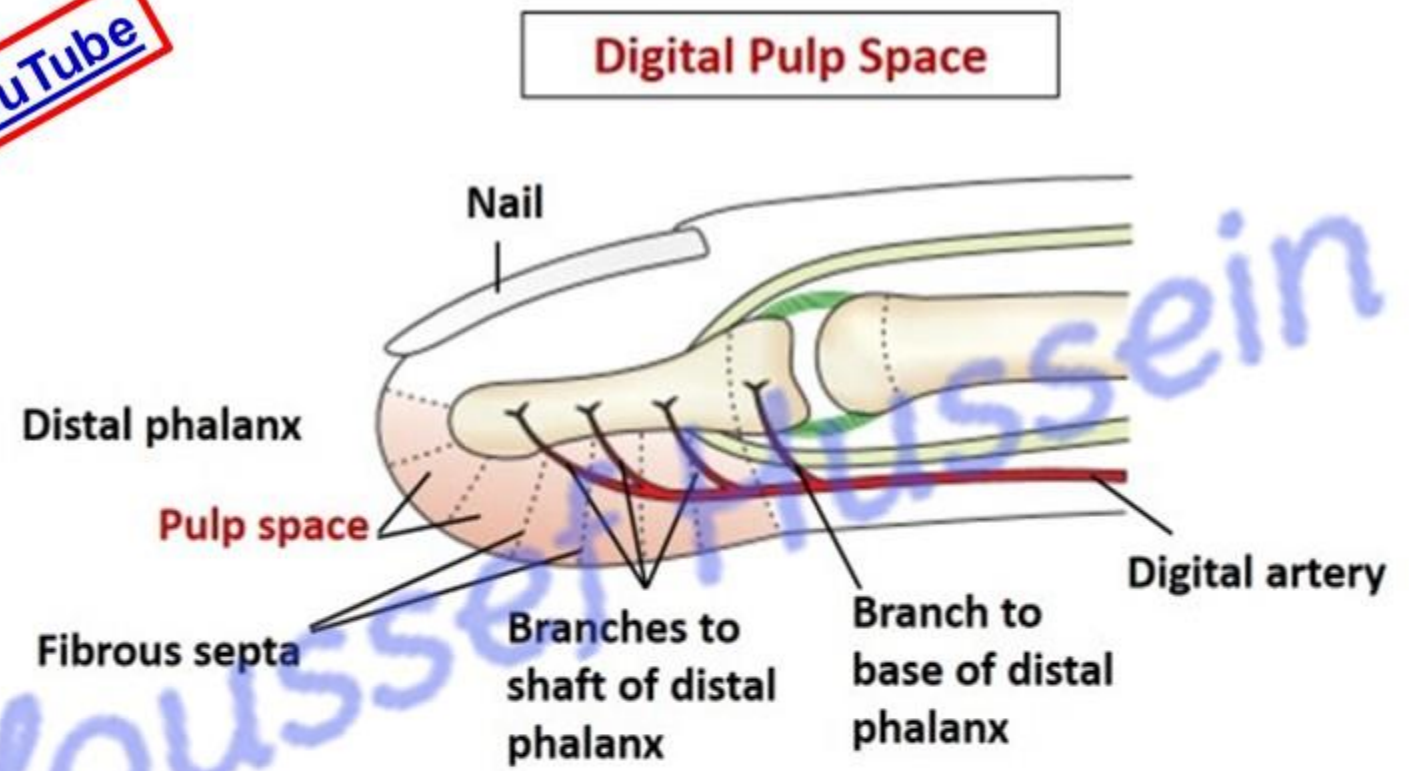
Prof. Dr. Youssef Hussein Anatomy - YouTube



Pulp space

- They are in the palmar surface of the tips of the fingers distal to the insertion of the flexor digitorum profundus.
- They contain fatty tissue, it is divided into numerous compartments by fibrous septa.
- The pulp contains terminal branches of digital arteries.
- It is closed proximally by the fusion of the deep fascia to the periosteum of the base of the distal phalanges.

Prof. Dr. Youssef Hussein Anatomy - YouTube



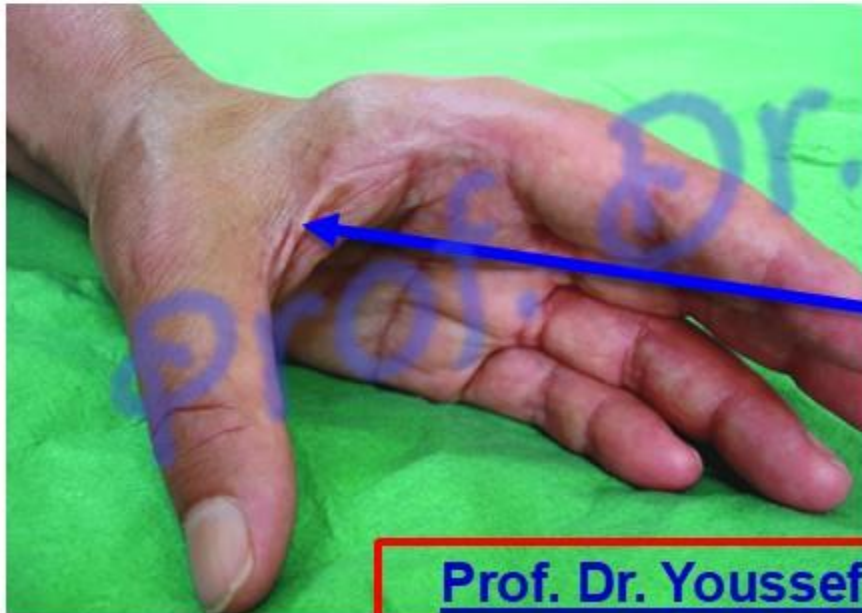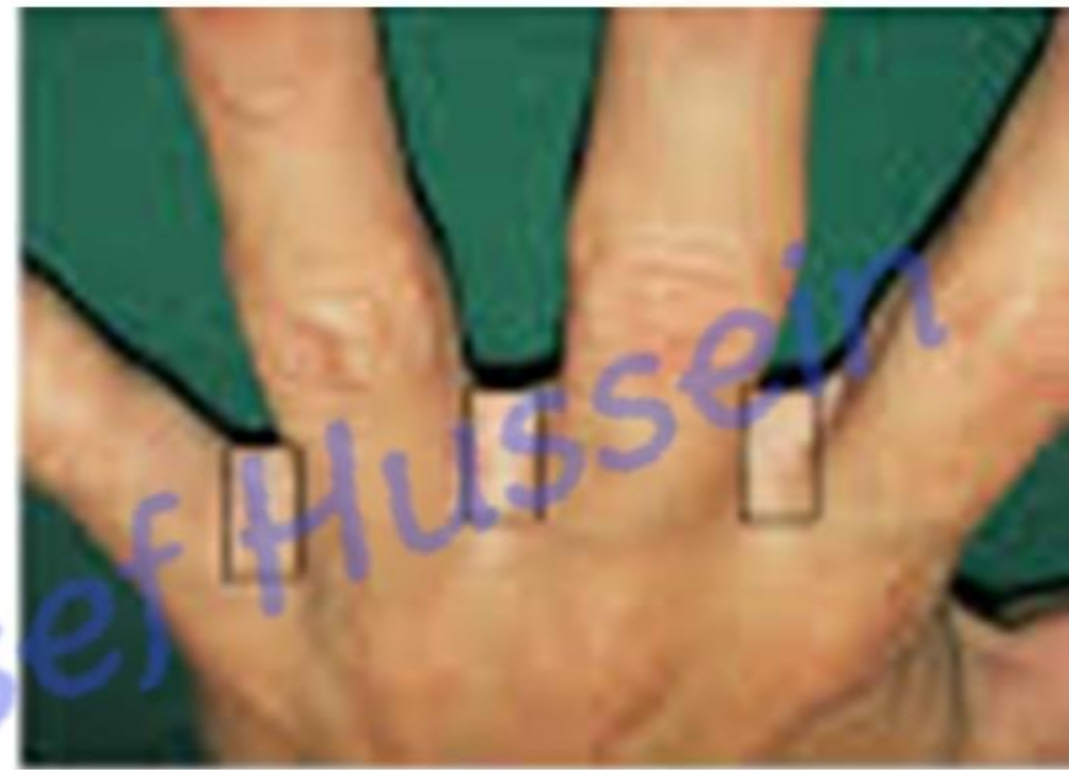Pulp space

* Clinical importance;

- 1- Pulp space infection (whitlow) produce severe throbbing pain due to closed space.
- 2- Treatment of infection often includes antibiotics and surgical decompression via a midlateral incision to prevent deep tissue damage
- 3- Severe infection of the pulp space may lead to occlude the digital arteries with consequent necrosis of the distal phalanx.

❖ Web spaces

- Spaces between the bases of the proximal phalanges of the fingers containing connective tissue and fat.
- These spaces, often sites of infection (fungal and bacterial) or contractures, require careful, often surgical management.



The 1st web space

Hand Grips



❖ **Power grip**

- ❖ **H**olding a **heavy object** firmly between the fingers and thumb.

❖ Precision grip

- ❖ Holding a **small object** lightly and precisely between the tip of the thumb and the tip of the index with partial support by the middle finger e.g. holding of the pencil in the writing position or surgical scalpel.



❖ Hook grip

- ❖ As for carrying a handle bag, done by the long flexor tendons.

Branches of radial artery

A- in the forearm

- 1- Radial recurrent artery
- 2- Palmar carpal branch
- 3- Superficial palmar branch

B- in the dorsum of the hand

- 1- Dorsal carpal branch
- 2- Dorsal digital branch
- 3- First dorsal metacarpal artery

C- in the palm of the hand

- 1- Princeps pollicis artery
- 2- Radialis indicis artery

D- End of the radial artery

Branches of ulnar artery

• A- in the forearm

- 1- Anterior ulnar recurrent artery
- 2- Posterior ulnar recurrent artery
- 3- Common interosseous artery
- 5- Palmer carpal branch
- 6- Dorsal carpal branch

B- in the palm of the hand

- 1- Superficial branch
- 2- Deep branch

Arch

Arch

Arch

Arch

Dorsal Carpal Arch

Dorsal carpal arch

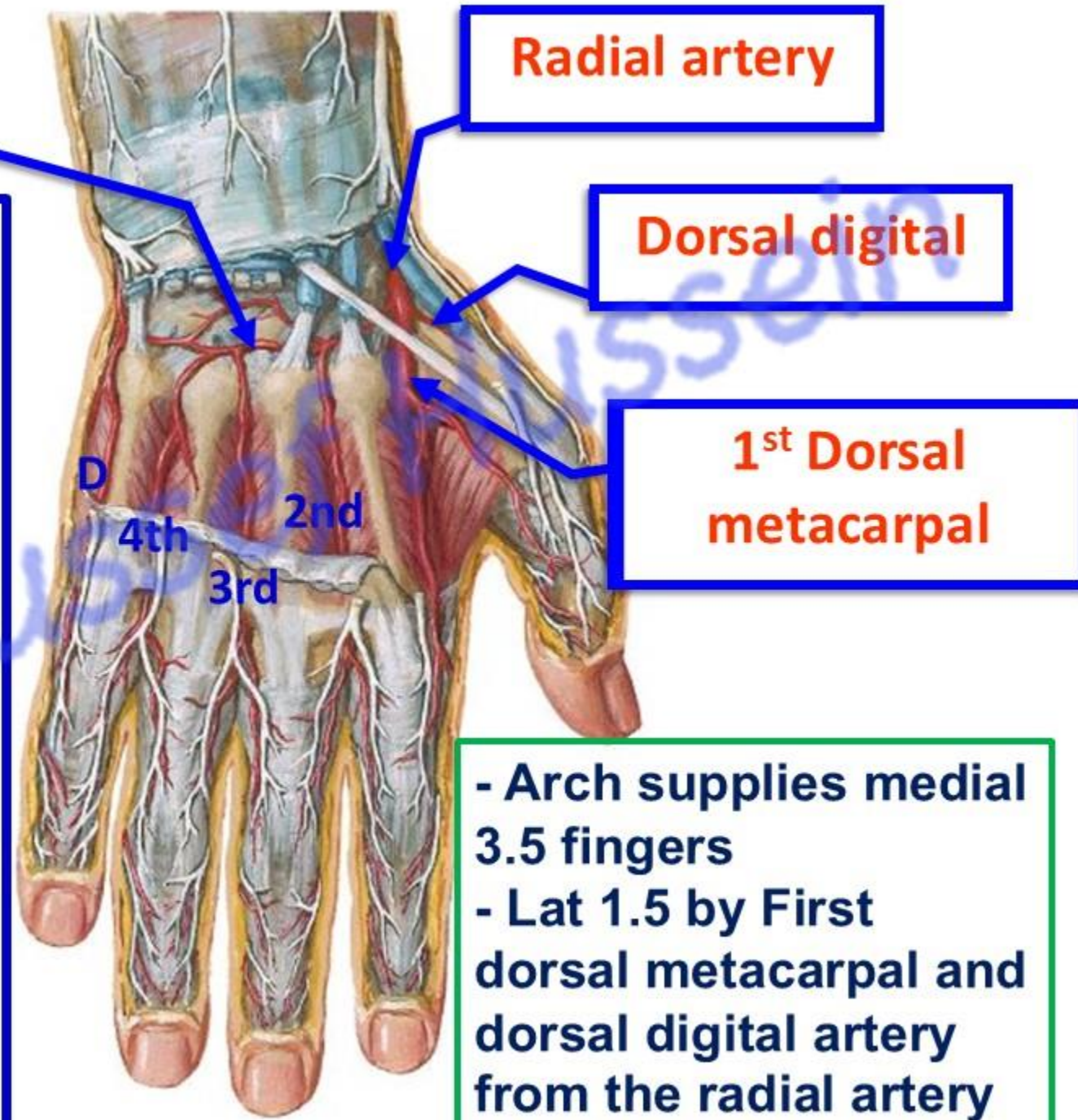
• Dorsal Carpal Arch

* **Formation**; union of:

- 1- Dorsal carpal branch of radial artery.
- 2- Dorsal carpal branch of ulnar artery.
- 3- Termination of anterior interosseous artery.

* **Branches**

- 1- **2nd, 3rd and 4th dorsal metacarpal arteries** to the adjacent sides of the medial 4 fingers.
- 2- **Dorsal digital artery** for the medial side of little finger.



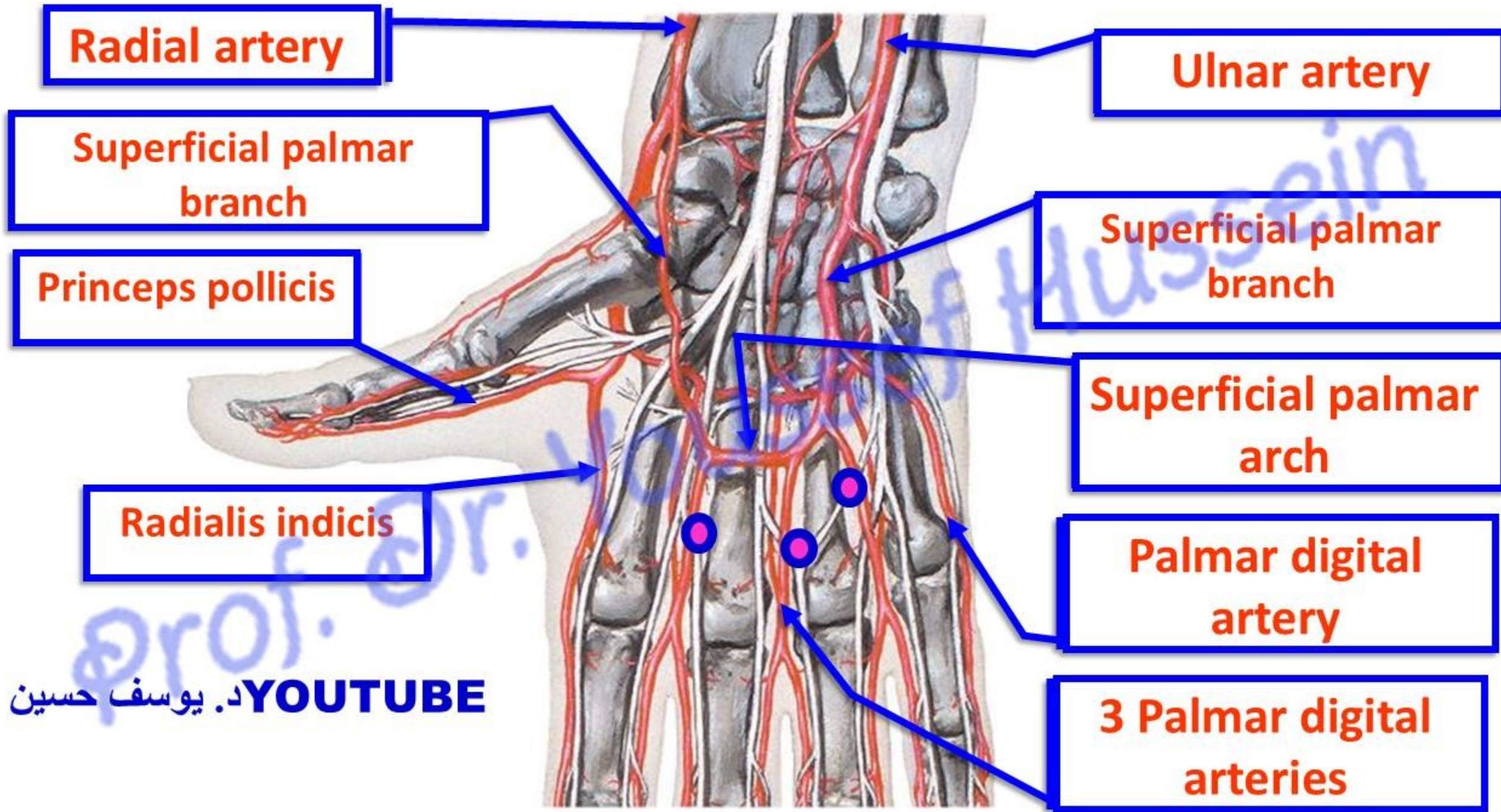
Radial artery

Dorsal digital

1st Dorsal metacarpal

- Arch supplies medial 3.5 fingers
- Lat 1.5 by First dorsal metacarpal and dorsal digital artery from the radial artery

Superficial Palmar Arch



- **Superficial palmar arch**

** **Site:** superficial to the flexor tendons.

- It is **distal** to the deep palmar arch.

** **Formation;**

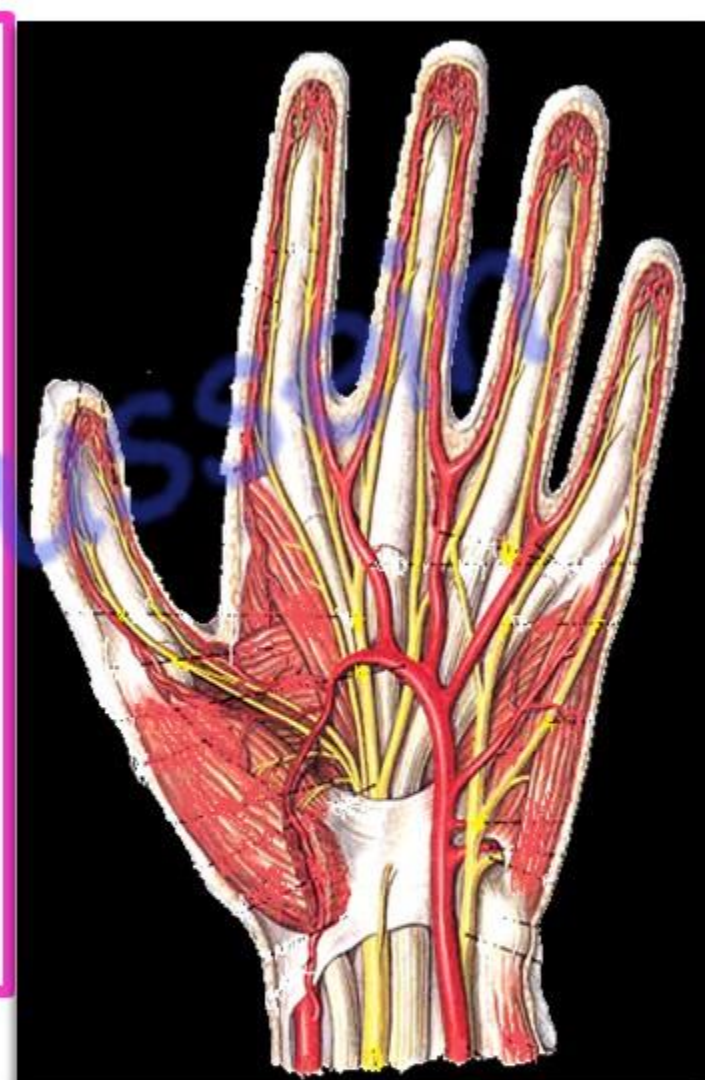1. Superficial terminal branch of the ulnar artery (**mainly**).

2. Superficial palmar branch of the radial artery.

** **Branches:**

1- 3 Palmar digital arteries for the adjacent sides of medial 4 fingers

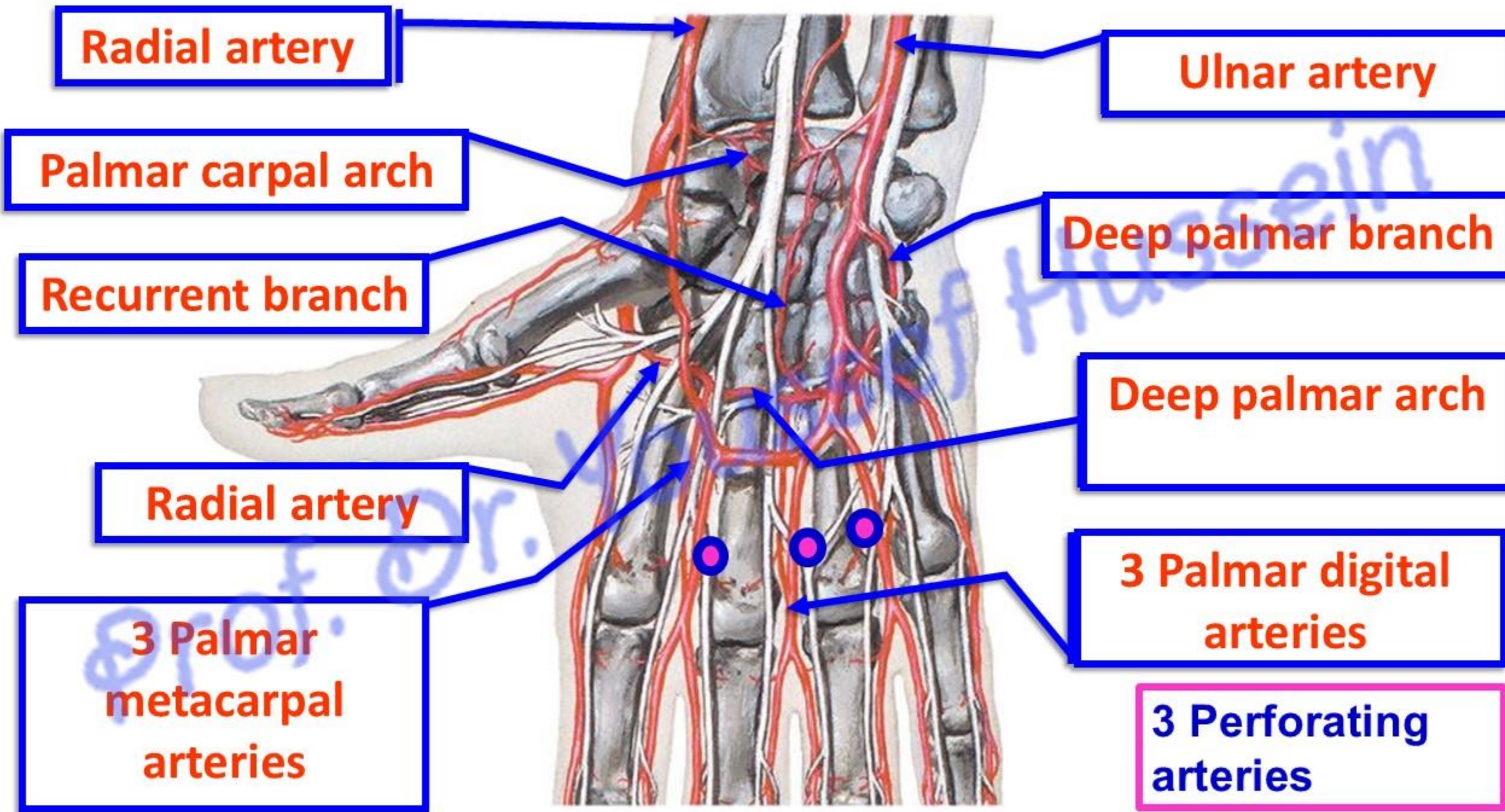
2- Palmar digital artery for the medial side of the little finger.



- Arch supplies palmar surface of medial 3.5 fingers

- Lat 1.5 by Princeps pollicis artery and Radialis indicis artery from the radial artery

Deep Palmar Arch



- **Deep palmar arch**

** **Site**; deep to the flexor tendons and lumbrical muscles.

** **Formation**;

1- The continuation of the radial artery (**mainly**).

2- The deep terminal branch of the ulnar artery.

** **Branches**

1- 3 palmar metacarpal arteries join palmar digital arteries of **superficial palmar arch**.

2- 3 Perforating branches: pass through the 2nd, 3rd and 4th interosseous spaces to join the 2nd, 3rd and 4th dorsal metacarpal arteries of **dorsal carpal arch**.

3- Recurrent branches to join **the palmar carpal arch**.

- In cases of **hemorrhage** of the hand press the radial artery against lower end of the radius to identify the source of bleeding;

a- If it becomes **weak**, the source of bleeding is the **deep** palmar arch.


b- If **not changed**, the source of bleeding is the **superficial** palmar arch.

د. يوسف حسين YOUTUBE

https://www.youtube.com/channel/UCVSNqbibj9UWYaJdd_cn0PQ

يُمنع أخذ السلايدات بدون
إذن المحرر واي اجراء
يخالف ذلك يقع تحت
طائلة المسؤولية القانونية

اليوتيوب د. يوسف حسين



Questions

<https://www.youtube.com/@ProfDrYoussefHusseinAnatomy/playlists>