



HISTOLOGY

Semester 2, Year 3 •

Dr . Amira Osman

Associate professor of Human histology & Cell Biology

Learning outcomes

At the end of this lecture, the student will be able to:

- 1- Describe the histological structure of tonsils
- 2- Describe the histological structure of thymus



Lymphatic system consists of

1- Lymph Vessels

2- Lymphatic organs:

1ry lymphatic organs

- Bone marrow
- Thymus

2ry lymphatic organs

- Lymph node
- Spleen
- Tonsils

Primary lymphoid organs

Secondary lymphoid organs

Thymus

Red bone marrow

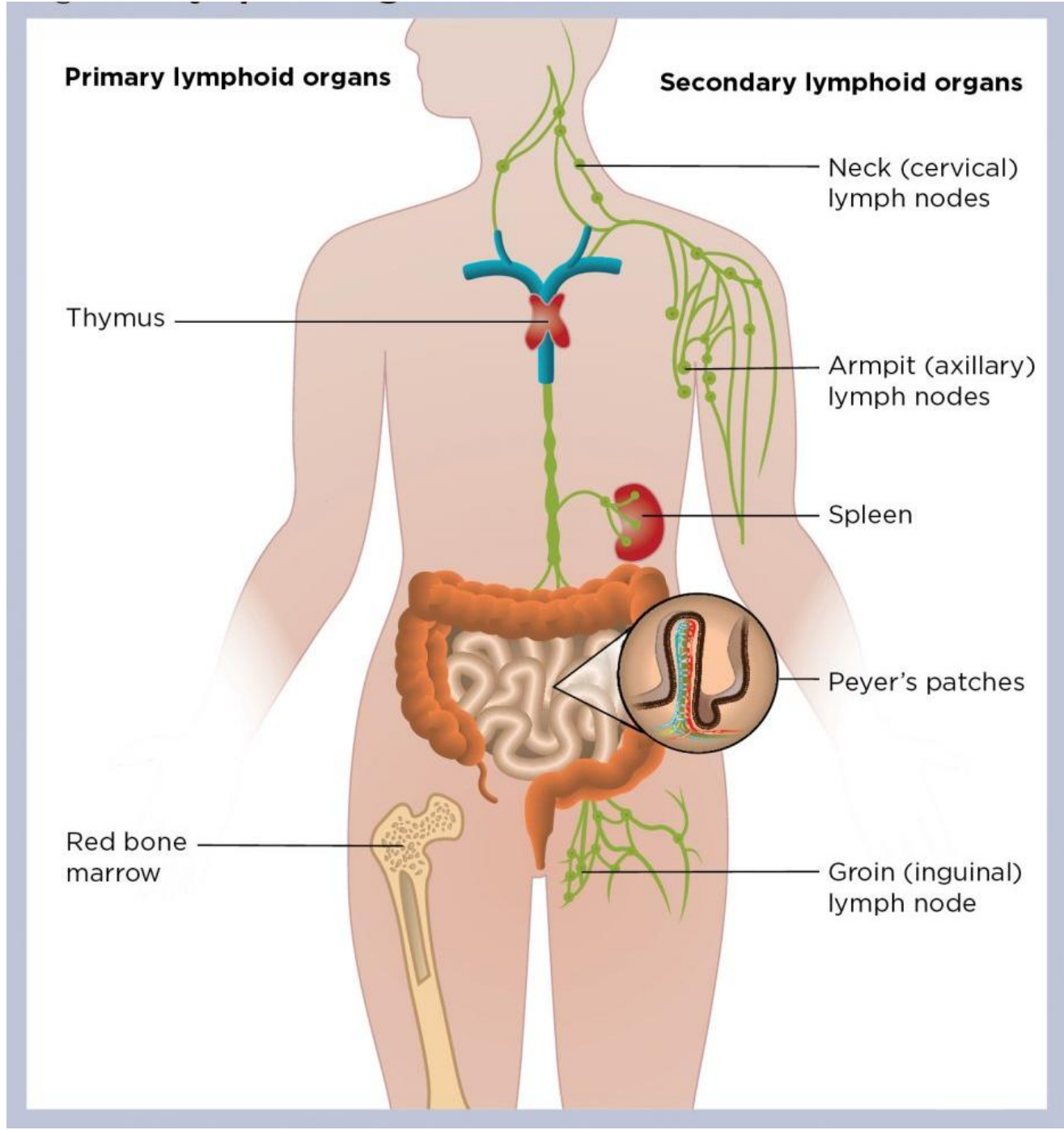
Neck (cervical) lymph nodes

Armpit (axillary) lymph nodes

Spleen

Peyer's patches

Groin (inguinal) lymph node



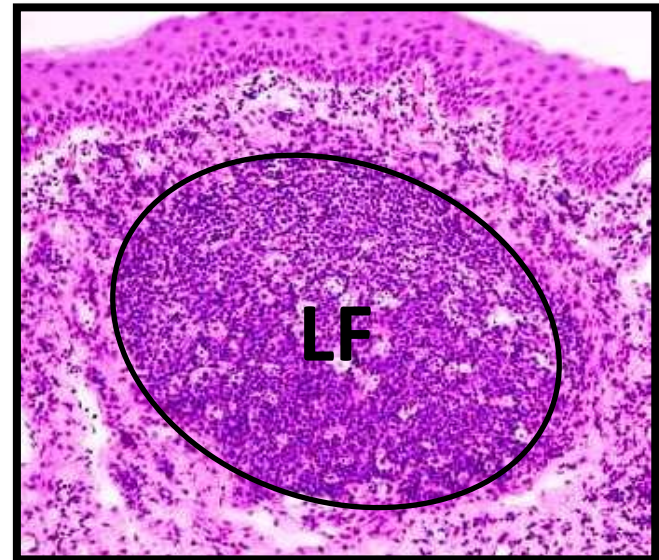
Lymphatic follicle

● **Structural & Functional unit of lymphatic tissue.**

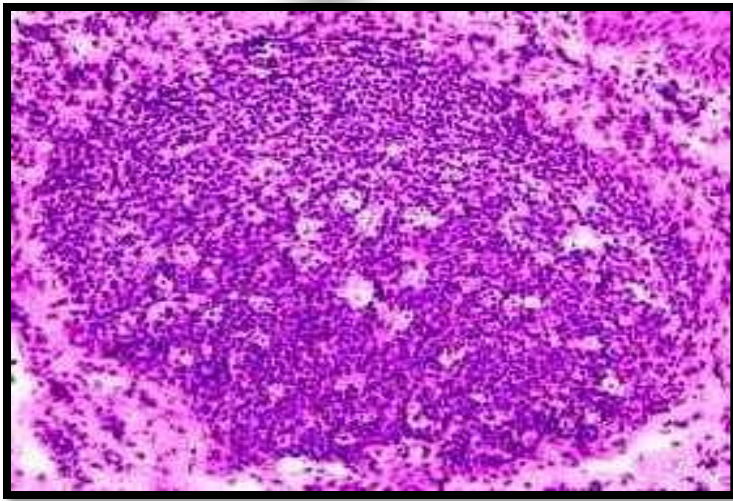

Rounded basophilic mass of lymphoid tissue not surrounded by capsule.

Structure:

- 1-Small lymphocytes
(mainly B lymphocytes &
few T lymphocytes)**
- 2- few macrophages**

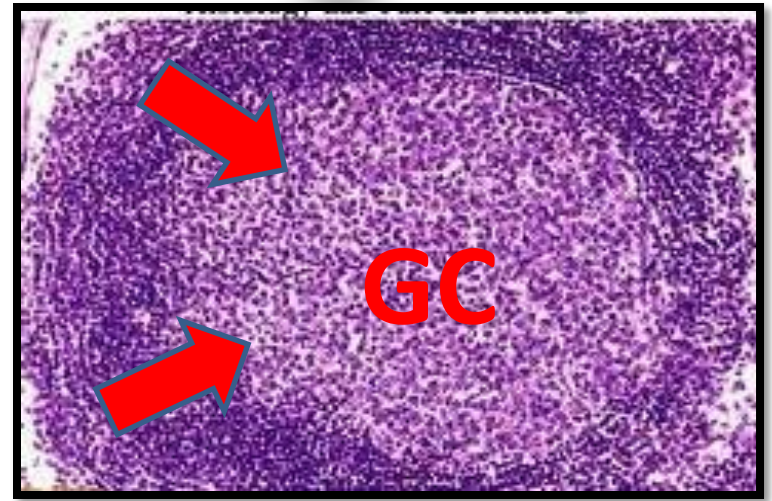



Types of lymphatic follicles



primary

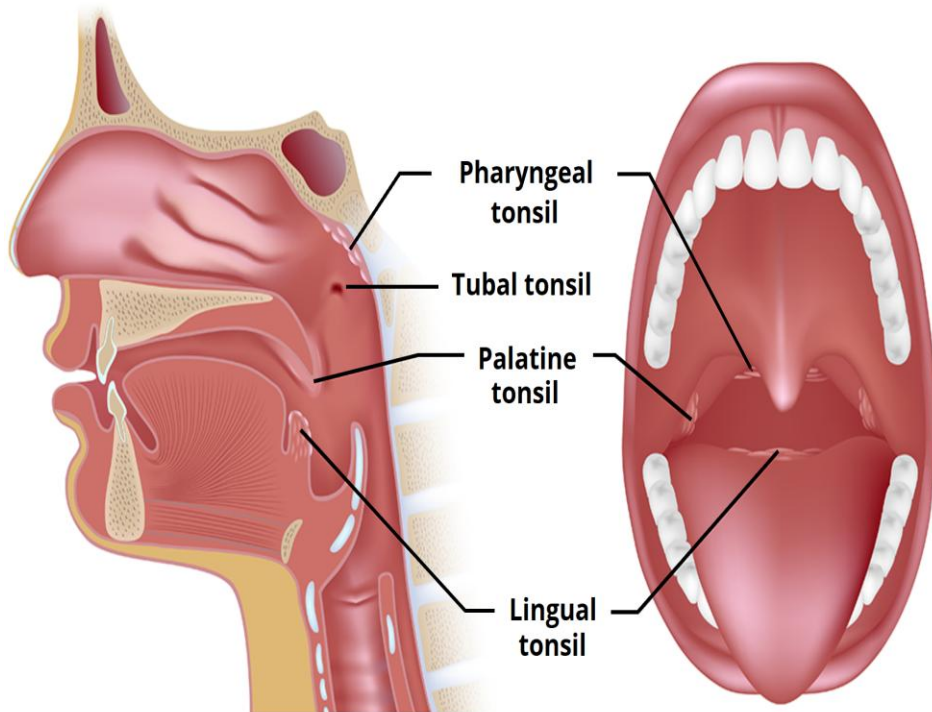
■ **without germinal center**



Secondary

■ **with germinal center**

3- Tonsils



- Masses of lymphatic tissue

- Found in the C.T of mucous membranes

- Types:

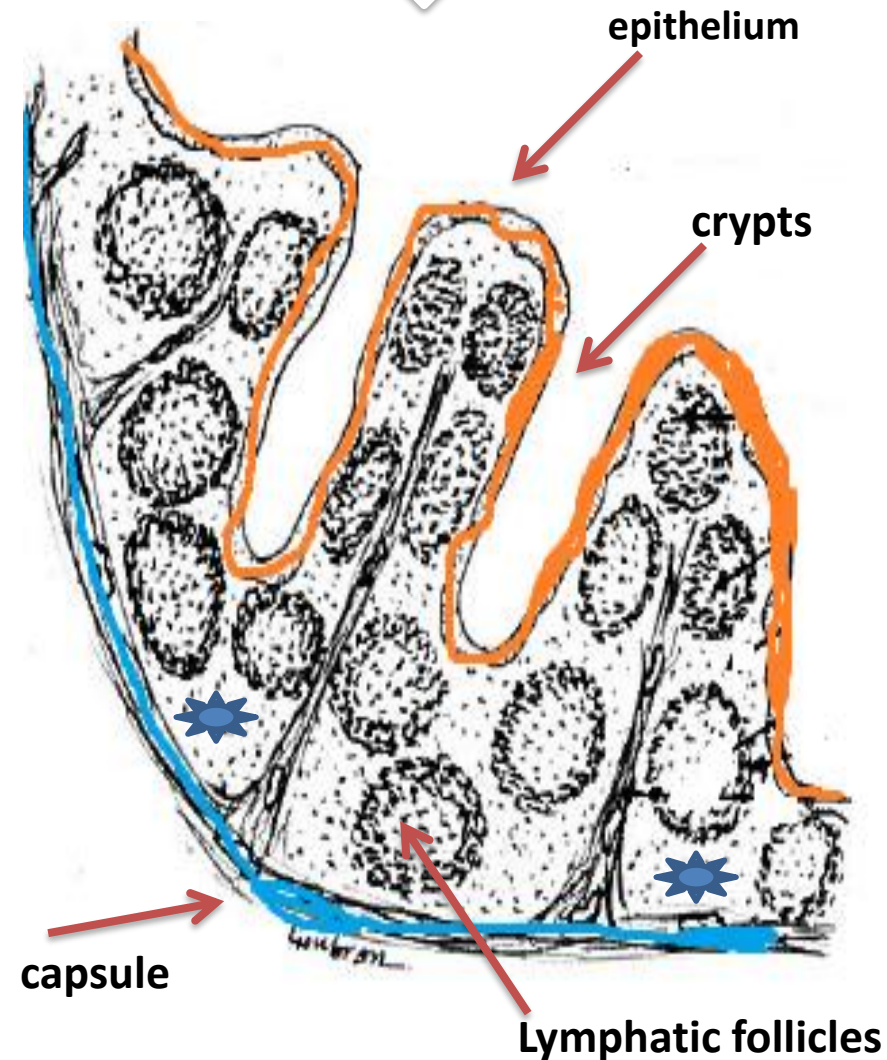
1- Palatine tonsil

2- Pharyngeal tonsil

3- lingual tonsil

4- Tubal tonsils

I- Palatine tonsil



Site: 2 masses in C.T under mucous membrane of oropharynx.

Structure:

1- Capsule dense C.T separate it from wall of pharynx

2- Stratified squamous non keratinized epithelium: →

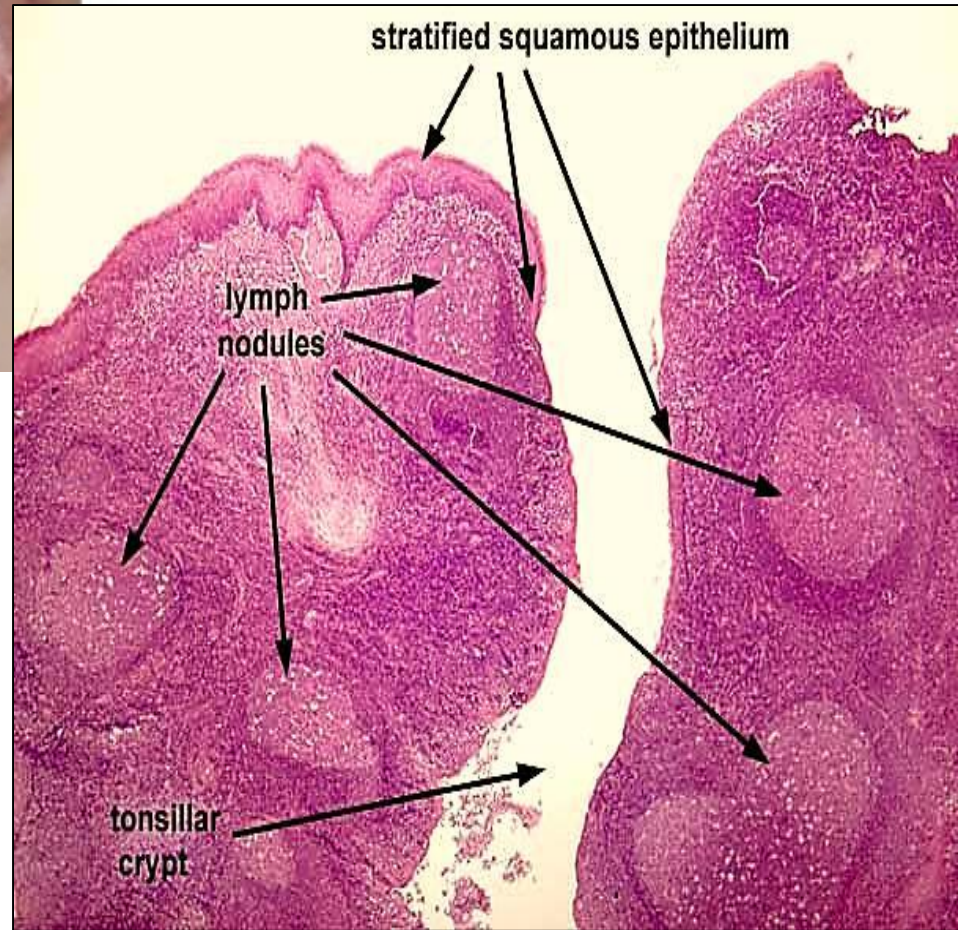
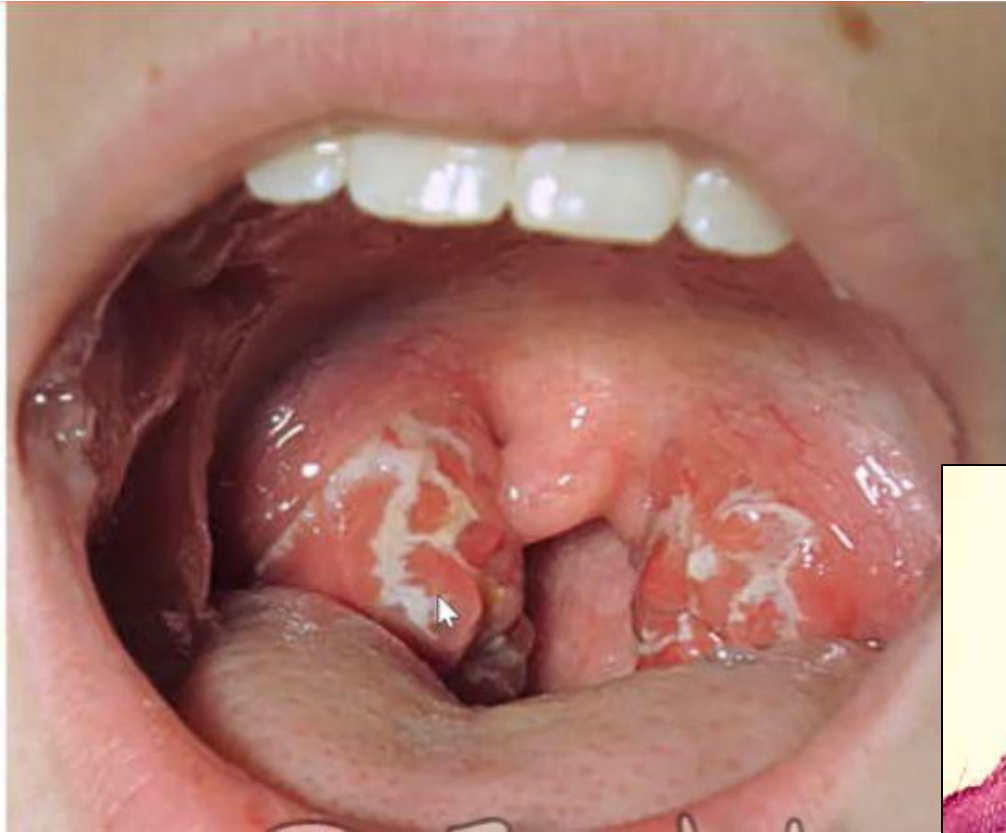-Epithelium dips

1ry & 2ry crypts

3- Lymphatic tissue:

A- lymphatic follicles

B-Diffuse lymphatic tissue



II- Pharyngeal tonsil

Site:

- Single mass in nasopharynx
- Chronic inflammation & enlargement of tonsil (adenoids)

Structure:

- 1-pseudostratified columnar ciliated epithelium
→ no crypts
- 2- diffuse lymphatic tissue

III- lingual tonsil

Site:

- Multiple small collections of lymphatic tissue at root of the tongue

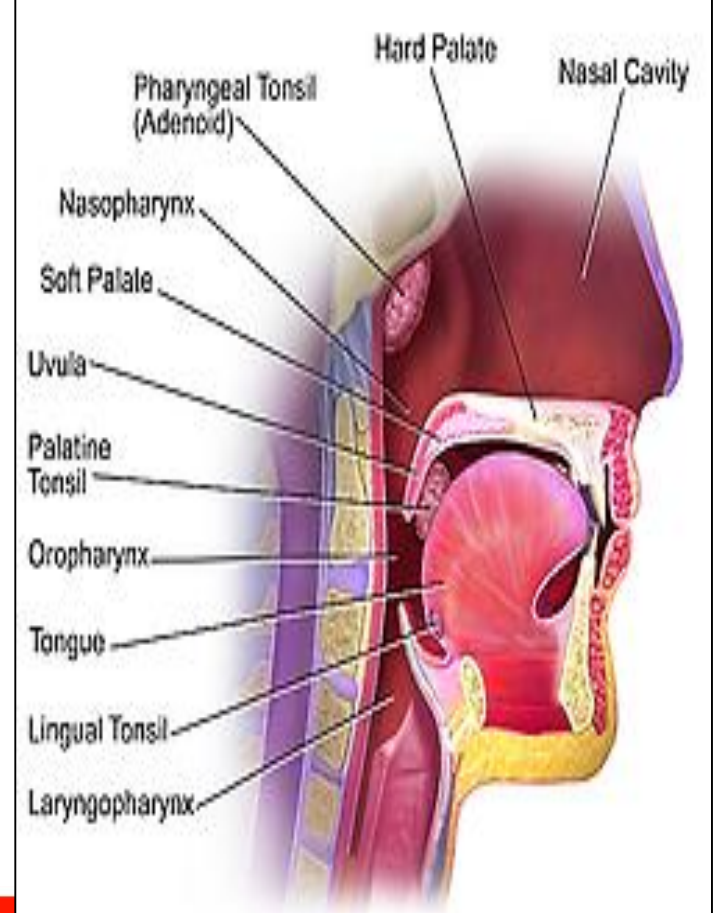
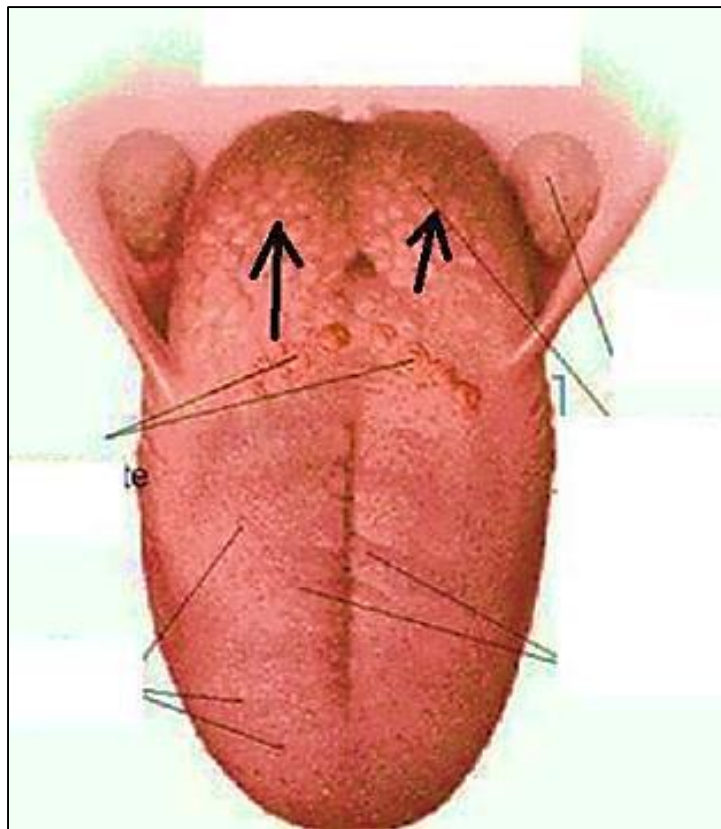
Structure:

- 1- Stratified squamous non keratinized epithelium form single crypts
- 2- lymphoid follicles

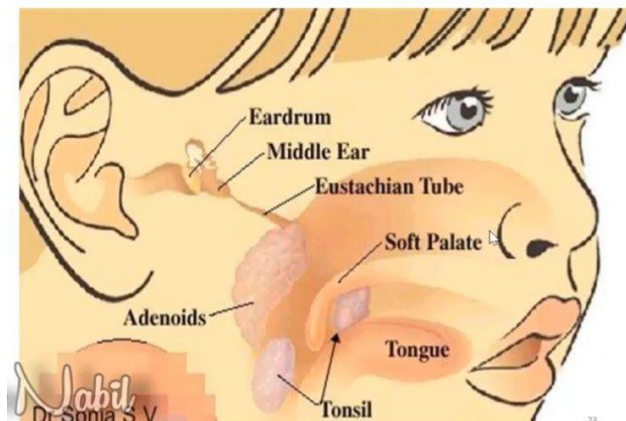
Function of tonsils: Quick defense mechanism →

Abs against Ags which may be swallowed with food or inhaled with air





Adenoids



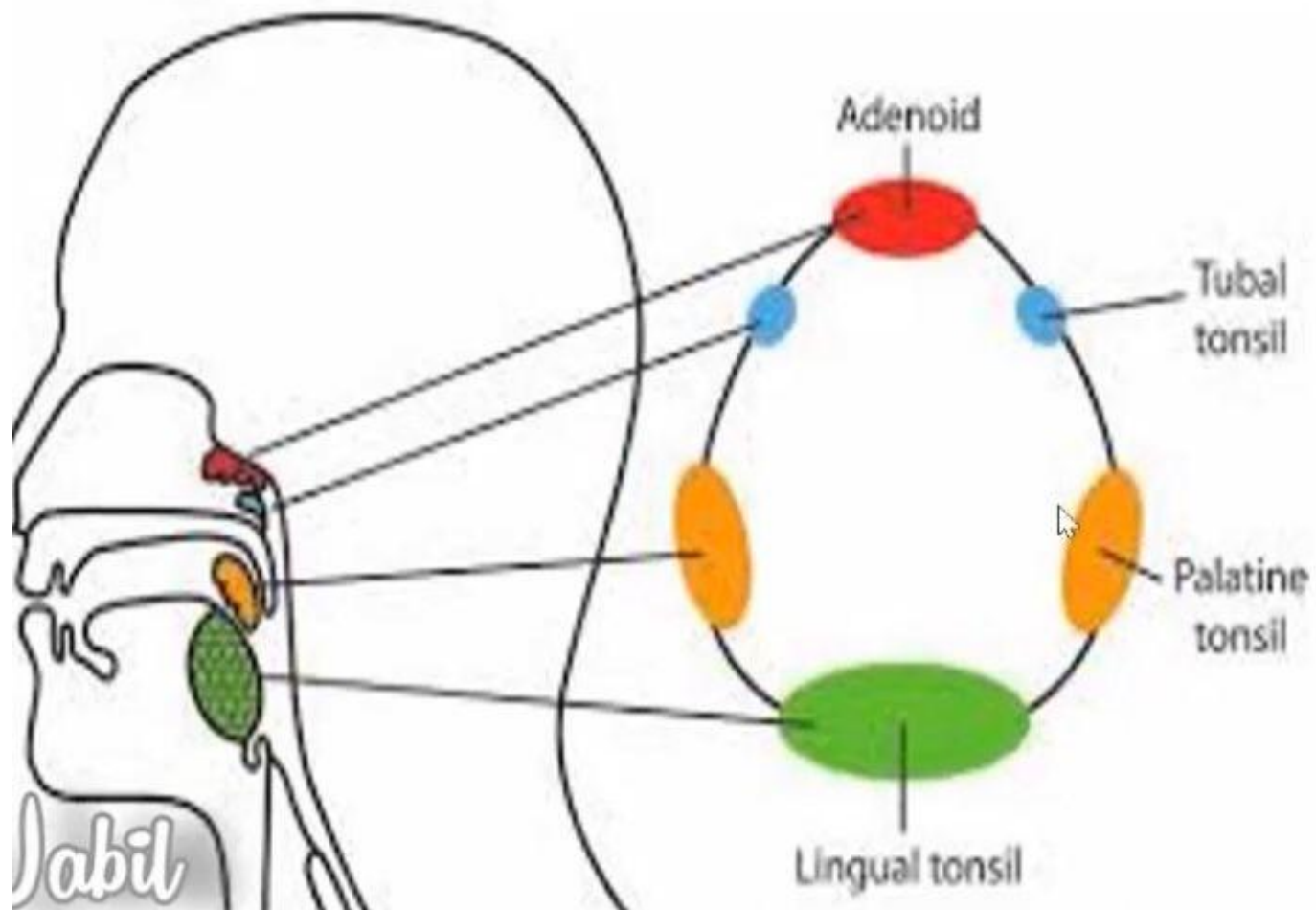
IV- Tubal tonsils

- **Site:** around the opening of the Eustachian tube in the lateral wall of the nasopharynx.
- **Number:** Two.
- **Structure:**
 - Lymphoid nodules.
 - Covered by *pseudostratified columnar ciliated epithelium*.
 - The epithelium dips inside the parenchyma to form few crypts.

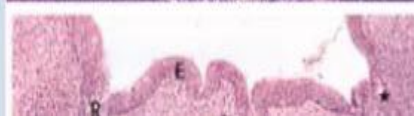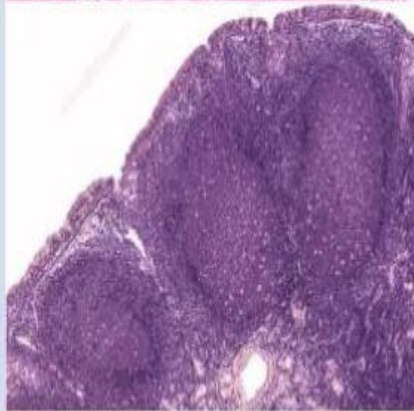
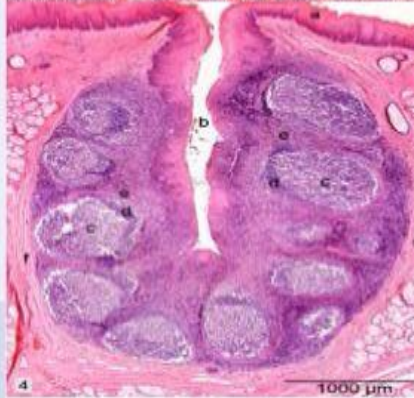
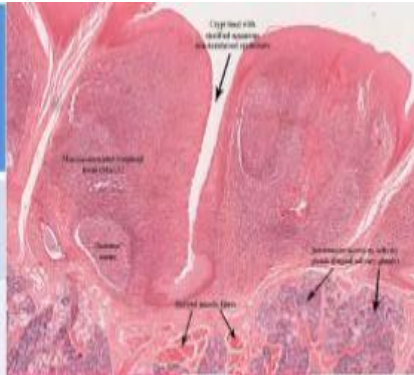


Tonsils

Waldeyer's ring



Types of tonsil	Palatine tonsils	Lingual tonsils	Pharyngeal tonsil	Tubal tonsils
1- Number	Two.	Multiple.	Single.	Two.
2- Site	In the lateral walls of the oropharynx.	On the dorsal surface of the posterior third of the tongue.	In the posterosuperior portion of the pharynx(nasopharynx).	Around the opening of the Eustachian tube in the lateral wall of the nasopharynx
3- Structure				
➤ Epithelium	Stratified squamous epithelium.	Stratified squamous epithelium.	Pseudostratified columnar ciliated epithelium.	Pseudostratified columnar ciliated epithelium.
➤ Crypts	Primary& secondary.	Each tonsil has a single crypt.	Absent.	Few.

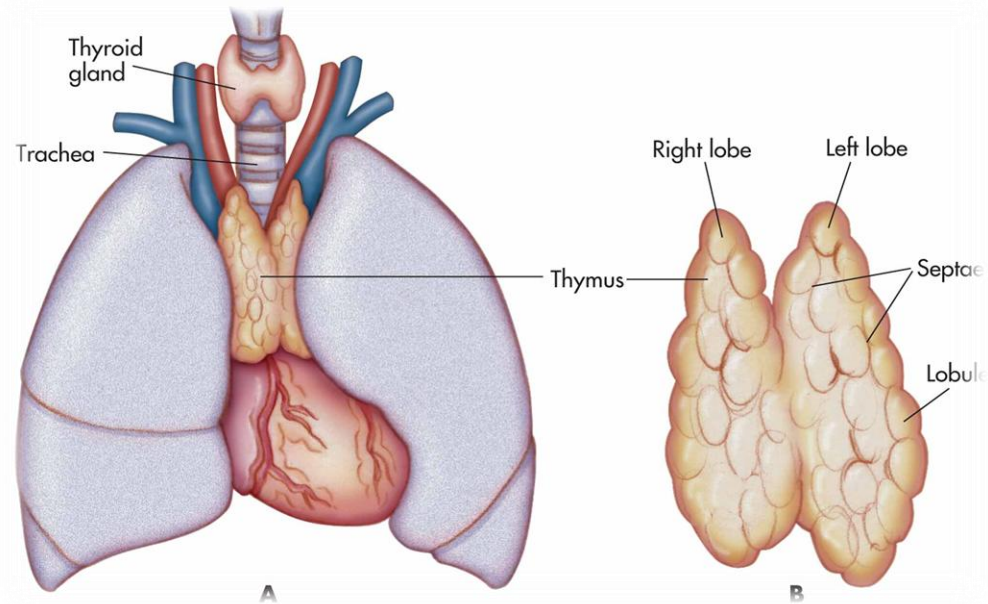


Thymus gland

- Flattened bilobed organ.

- Site:
behind the sternum

- Size:
in infants → large
at puberty → involute & decrease in size



Histological structure

Stroma:

1- Capsule thin loose C.T

2- Trabeculae

thin arise from capsule
divide thymus

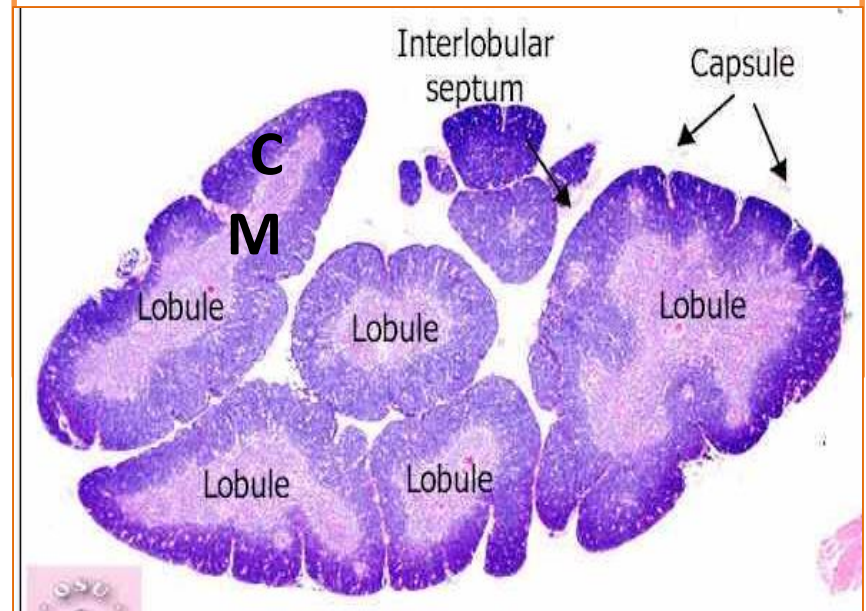
→ two lobes →
incomplete lobules

3- reticular network

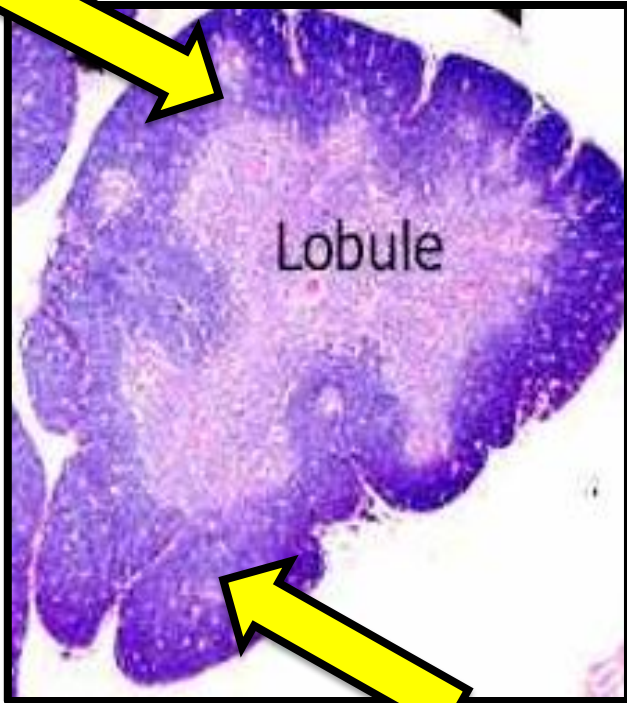
Parenchyma:

Thymic lobules

Each lobule consists of:
Outer cortex & inner
medulla



1-Cortex



Outer dark part of thymic lobules

Content:

1- T lymphoblasts:

Site: outer part of cortex

Development: UMC (bone marrow) →

CFU $\xrightarrow{\text{Migrate to thymus}}$ T lymphoblast

2- T lymphocytes:

Site: deep part of cortex (Numerous)

Development: T lymphoblast →

T lymphocyte

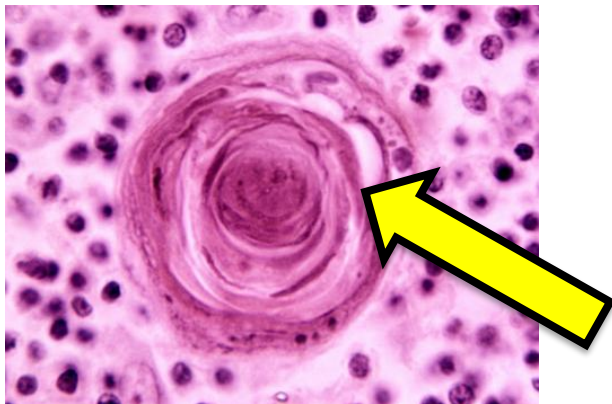
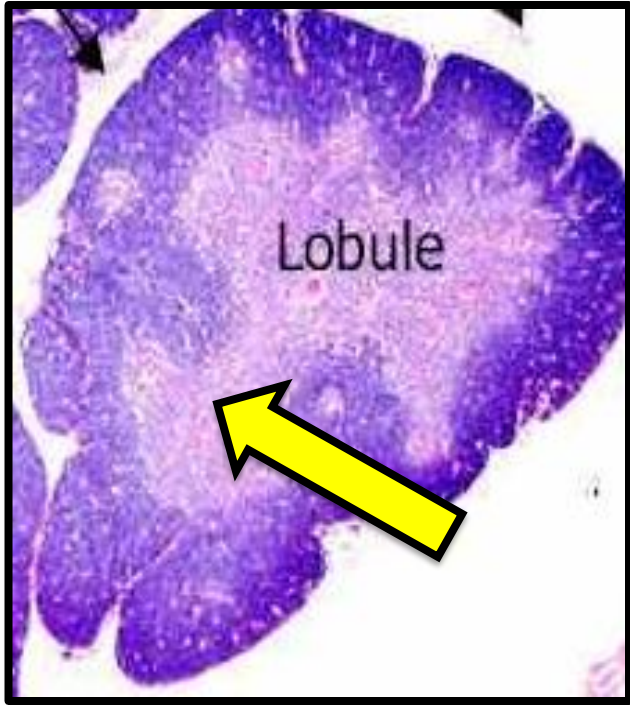
Migrate to medulla

3- Reticular epithelial cells:

Stellate shaped have pale nuclei

4- Few macrophages

2-Medulla






Inner pale part of thymic lobules

Content:

1- T lymphocytes:

Less in number than cortex

Developed in cortex  migrate to
medulla  post capillary venules  blood
thymus dependent zone

2- Reticular epithelial cells:

3- Few macrophages

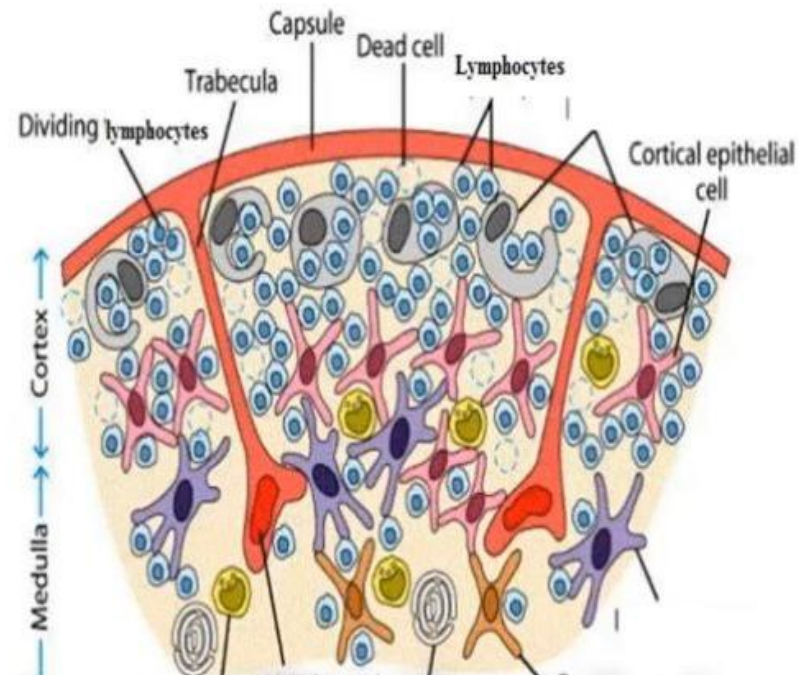
4- Hassall's corpuscles

Central hyaline acidophilic mass

Concentric layers of reticular epithelial cells

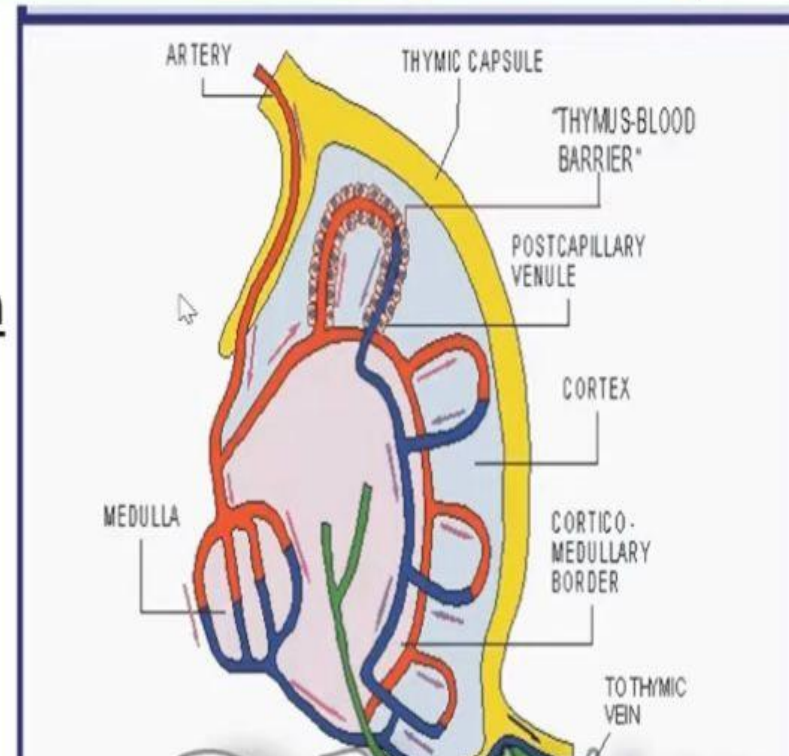
Functions of epithelial reticular cells

- 1- Form the cytoarchitecture of the cortex & medulla.
- 2- Form Hassall's corpuscles.
- 3- Form the blood thymic barrier.
- 4- Secrete several growth factors that stimulate T cell proliferation and differentiation e.g. thymopoietin.
- 5- Antigen presenting cells.



The blood-thymus barrier

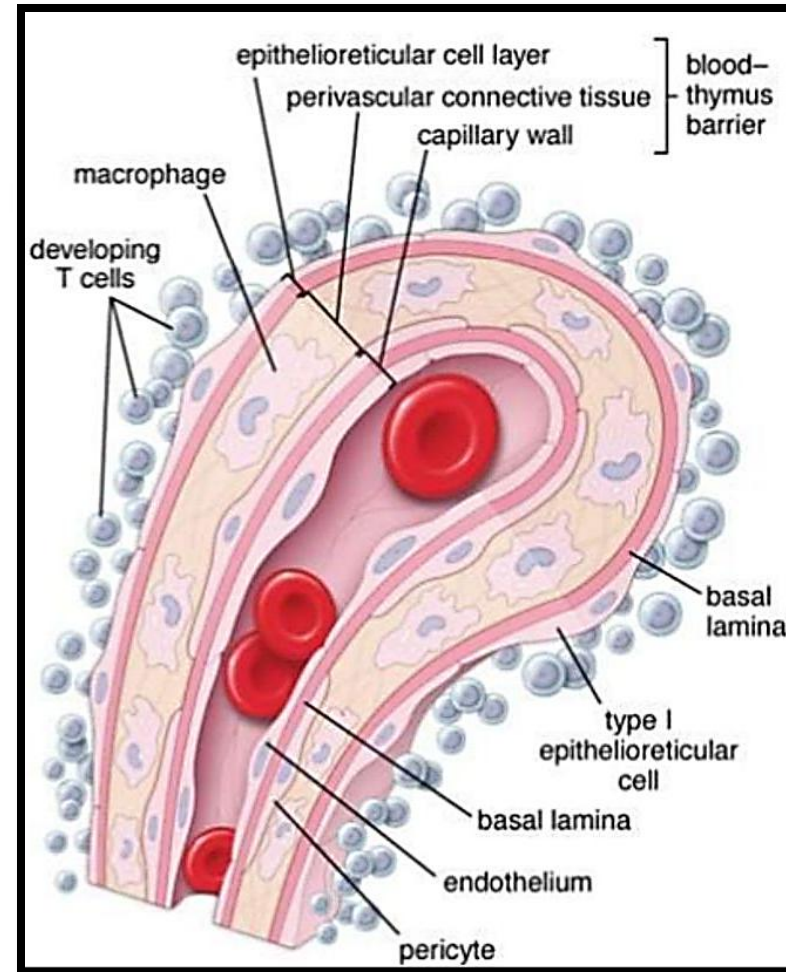
- **Definition:** It is a barrier between the developing T lymphocytes and the blood in the cortical capillaries.
- **Function:** this barrier prevents the foreign antigens from reaching the thymic cortex where T lymphocytes are still in state of maturation.



Blood thymic barrier

- **Components:**

- **Endothelial cells** of the blood capillaries (continuous; non fenestrated) joined together by occluding junctions.
- **Basal lamina** of the endothelial cells.
- The **pericytes** surrounding the capillary wall.
- **Macrophages** in the perivascular connective tissue.
- **Basal lamina** of the epithelial reticular cells.
- **Epithelial reticular cells** joined together by occluding junctions.



```
graph TD; A((Production of T lymphocytes)) --- B((Function of thymus gland)); B --- C((Development of lymphoid tissue in early life)); B --- D((Secretion of thymic hormones));
```

**Production
of T
lymphocytes**

**Function
of thymus
gland**

**Development
of lymphoid
tissue in
early life**

**Secretion of
thymic
hormones**

Self Assessment Quiz




The germinal centers of lymphatic follicles:

- 1- Formed in response to infection.
- 2- Found in primary follicles.
- 3- Contain many T lymphocytes.
- 4- The active site of macrophage proliferation.
- 5- deeply stained zone in their centers.



Lymph nodes receive afferent lymphatics at:

- 1- Near its hilum.
- 2- the cortico-medullary junction.
- 3- Its capsule.
- 4- The hilum.



The thymus dependent zone of lymph node is found in:

- 1- Medulla.
- 2- Deep part of cortex.
- 3- outer part of cortex.
- 4- under the capsule
- 5- Between trabeculae and follicles



The red pulp of the spleen consists of:

- 1- Elastic C.T.
- 2- B lymphocytes.
- 3- T lymphocytes.
- 4- Lymphatic nodules.
- 5- Splenic cords, blood sinuses & reticular fs.



Lymph follicles are not found in:

- 1- Spleen.
- 2- Cortex of lymph node.
- 3- PlatineTonsil.
- 4- Thymus.
- 5-MALT



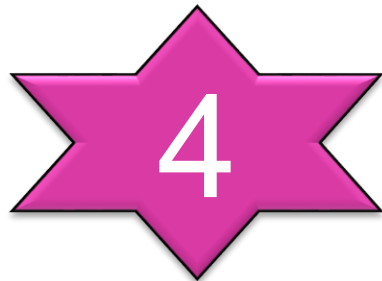Hassall's corpuscles are characteristics of:

- 1- Spleen.
- 2- lymph node.
- 3-Tonsils.
- 4- Bone marrow.
- 5- Thymus.



The epithelium of the palatine tonsil is:

- 1- Stratified squamous keratinized epithelium.
- 2- Stratified squamous non keratinized that form folds.
- 3- Pseudostratified columnar ciliated that form crypts.
- 4- Stratified squamous non keratinized that form crypts.



A vibrant red ribbon is tied into a large, elegant bow. A horizontal ribbon strip extends across the middle of the frame. A red tag is attached to the left side of the bow. The tag is rectangular with rounded corners and features the words "THANK YOU" in a white, serif font. The text is centered on the tag and has a subtle reflection effect below it. The entire scene is set against a plain white background.

THANK
YOU