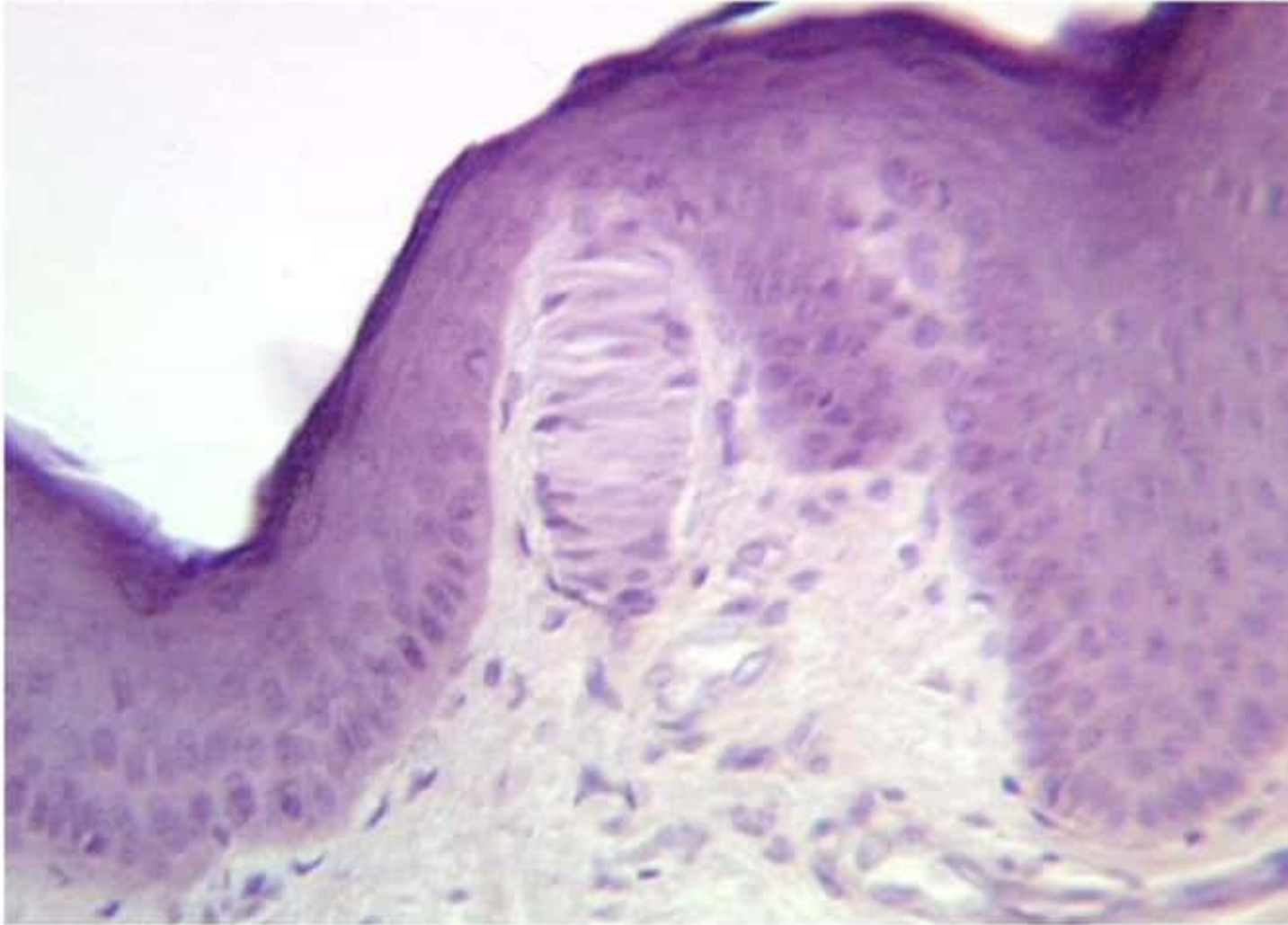
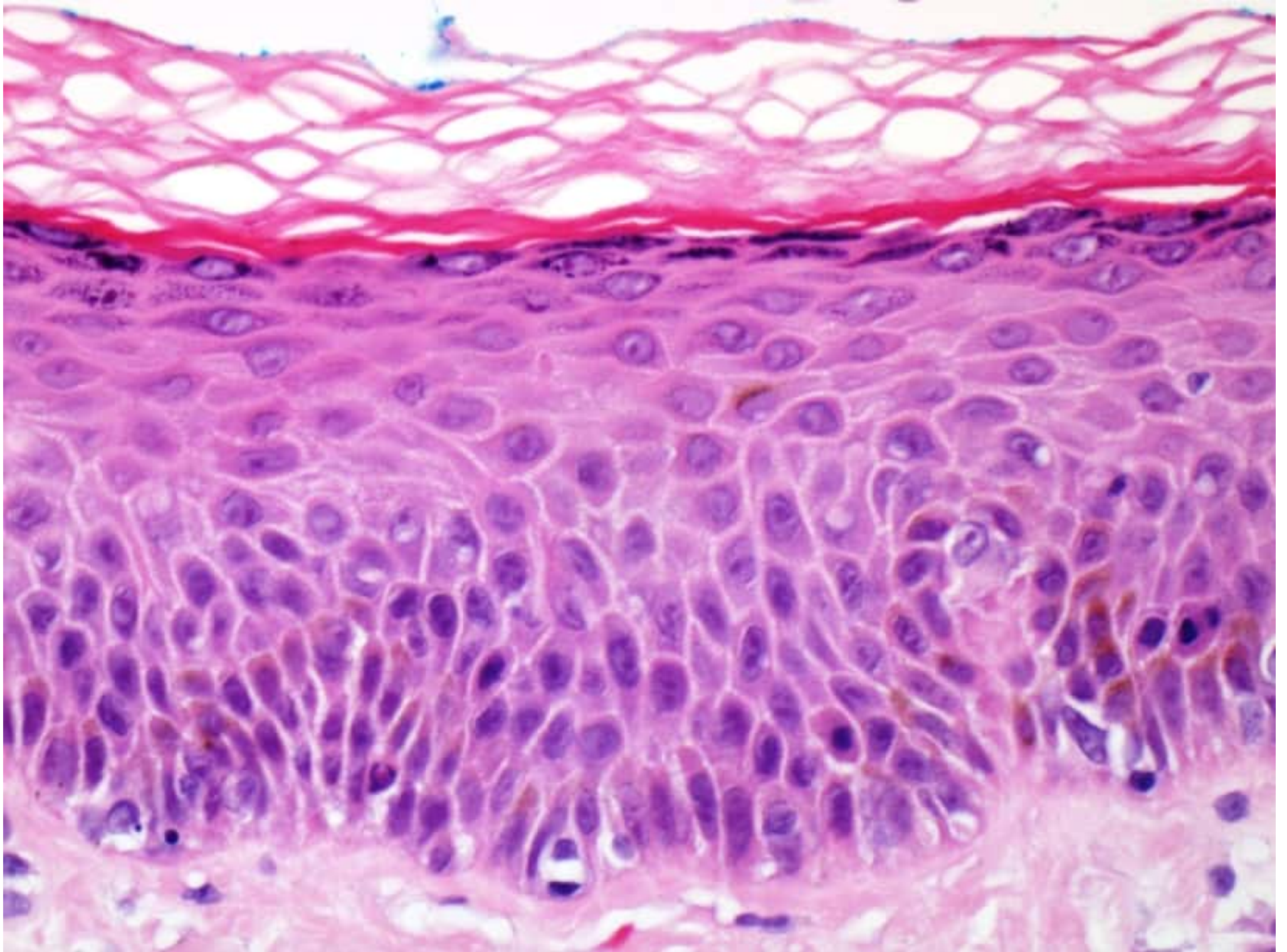
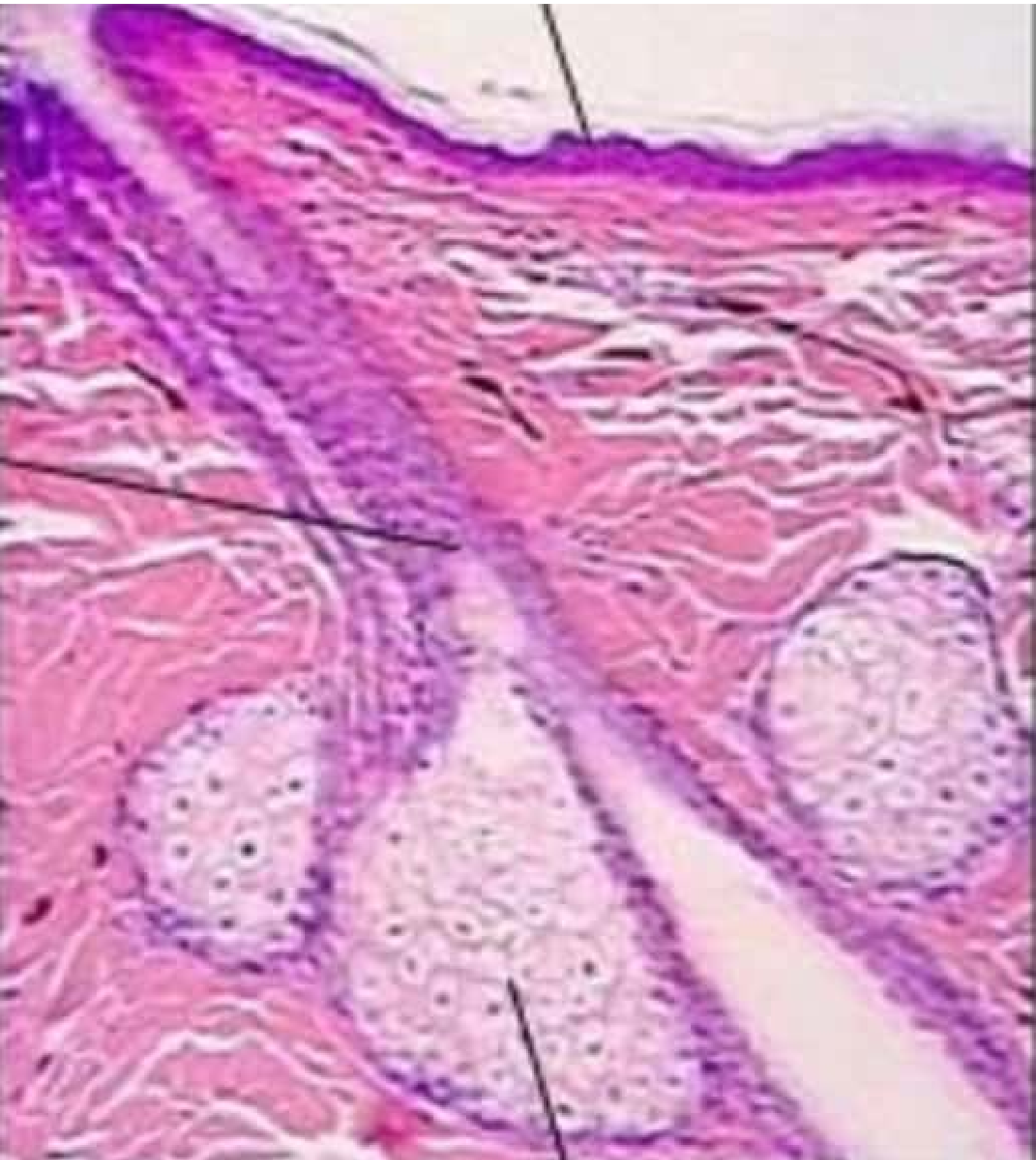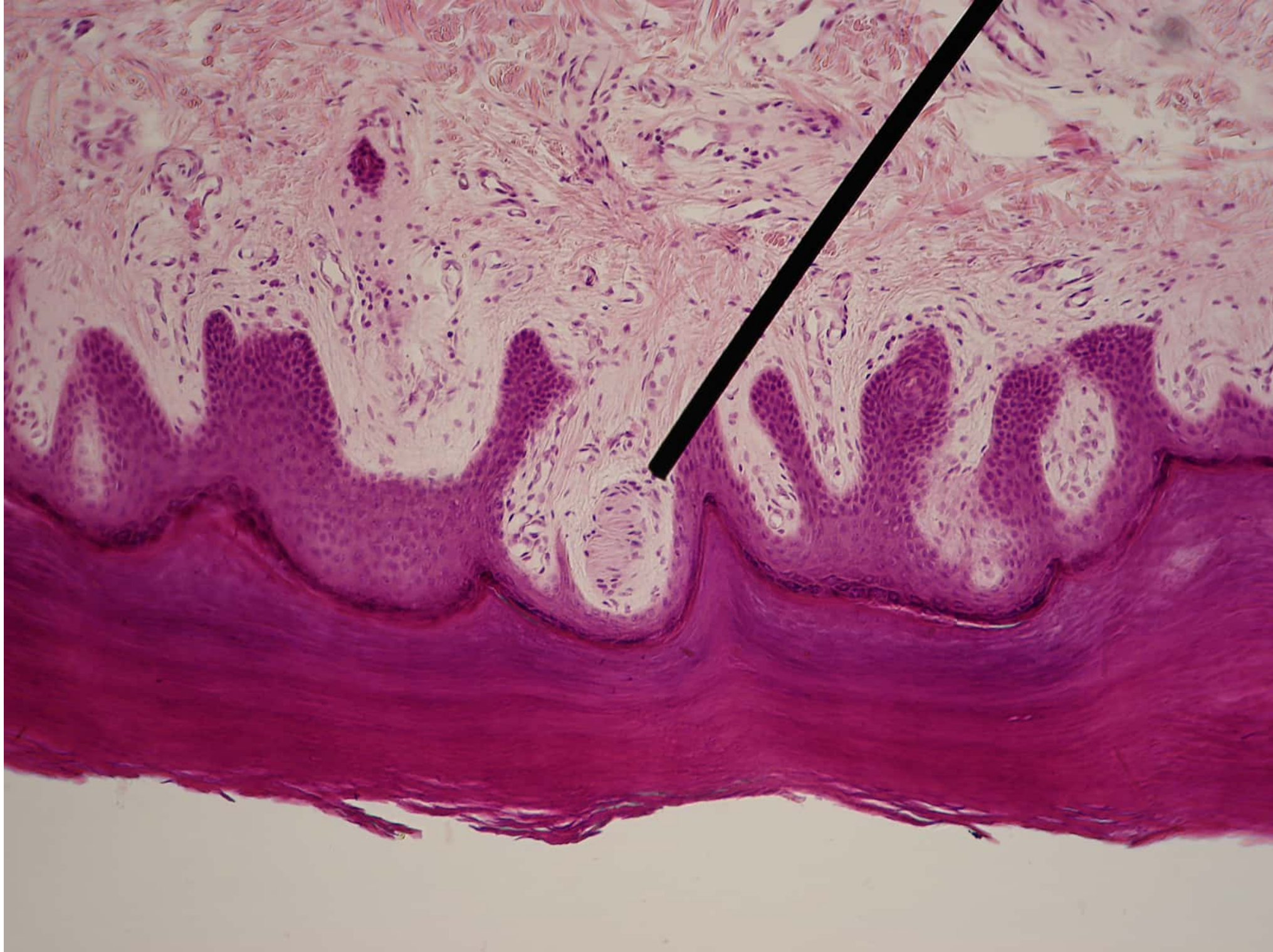


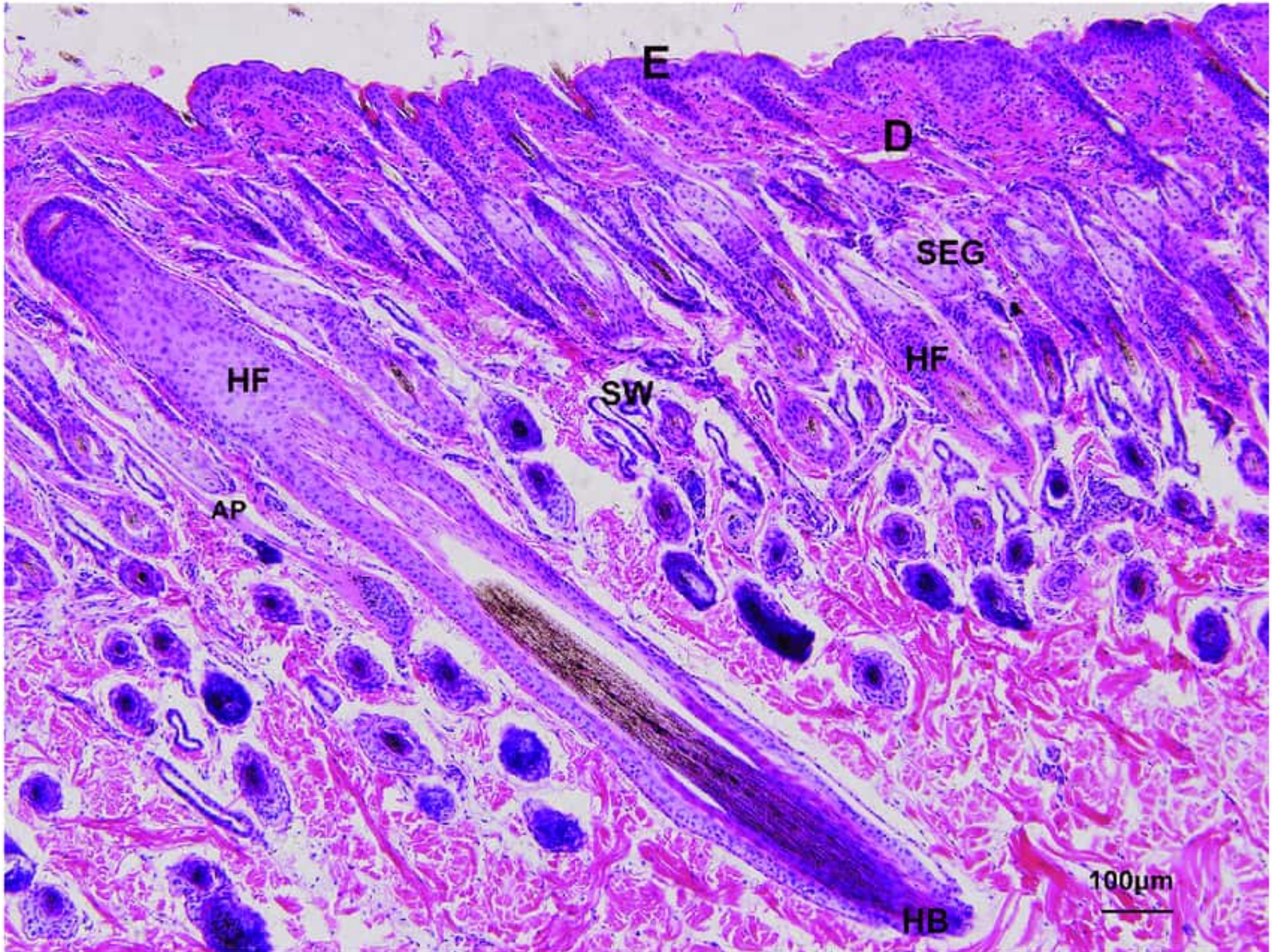
# Meissner's Corpuscle

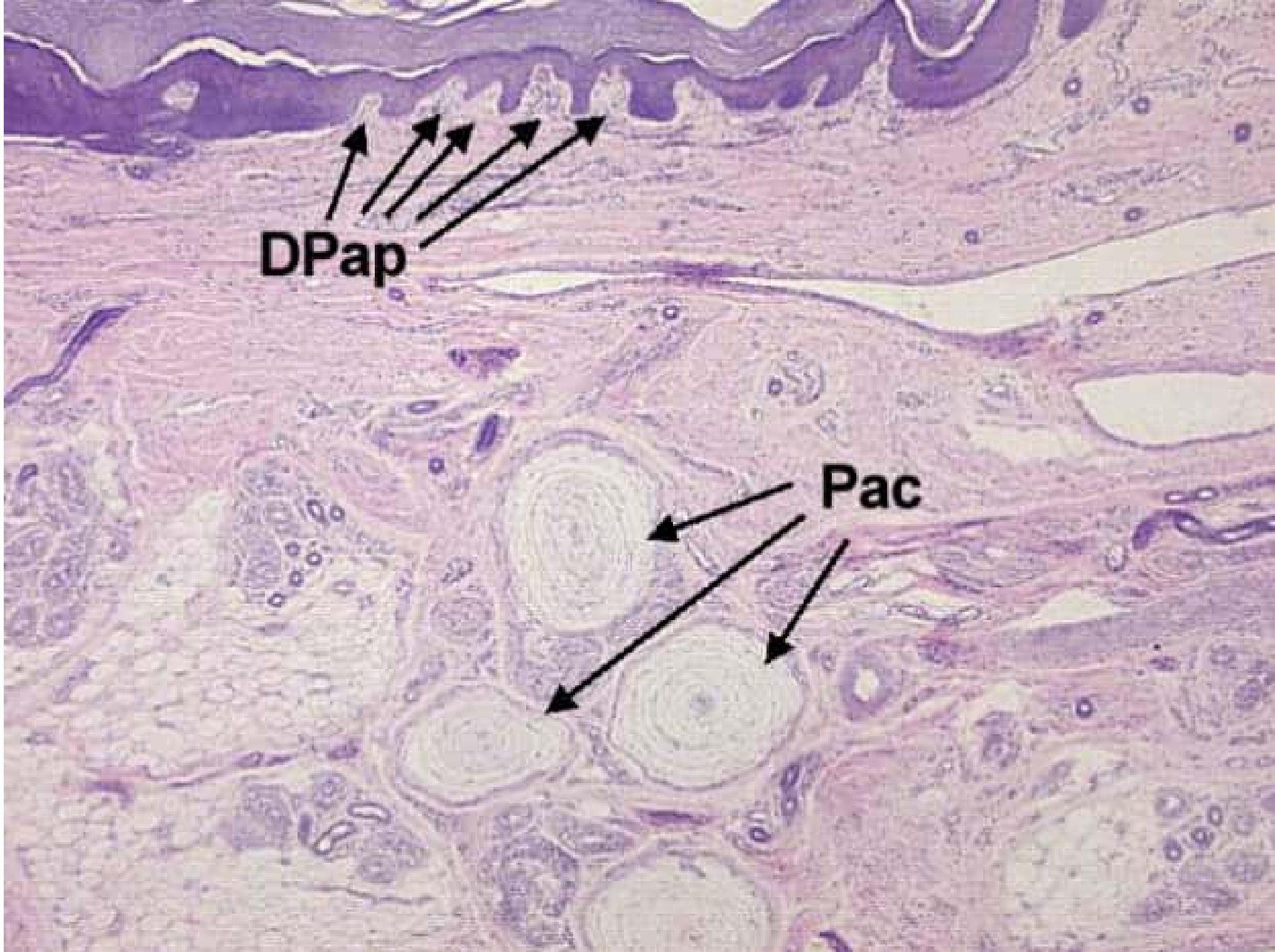






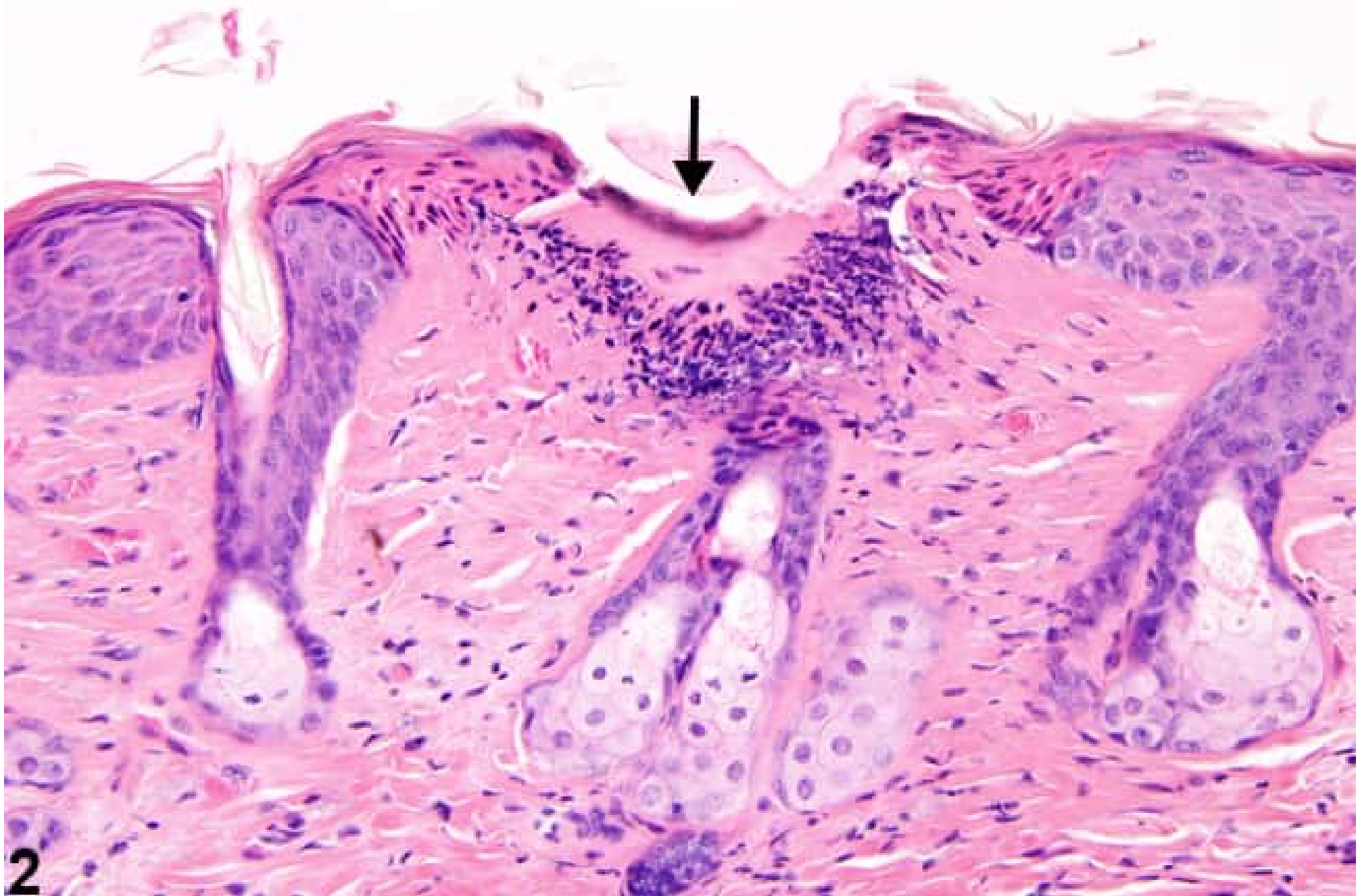




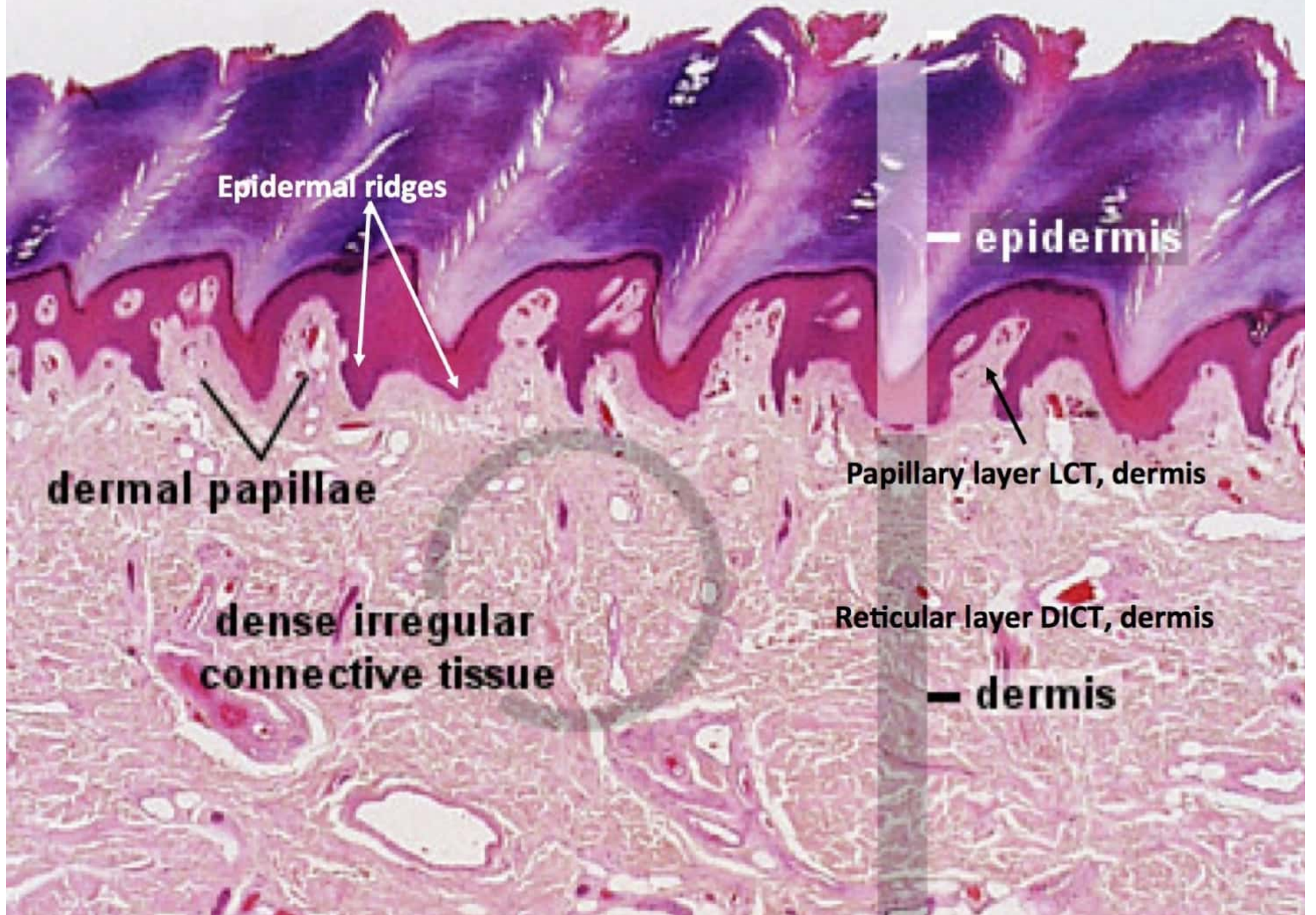


**DPap**

**Pac**

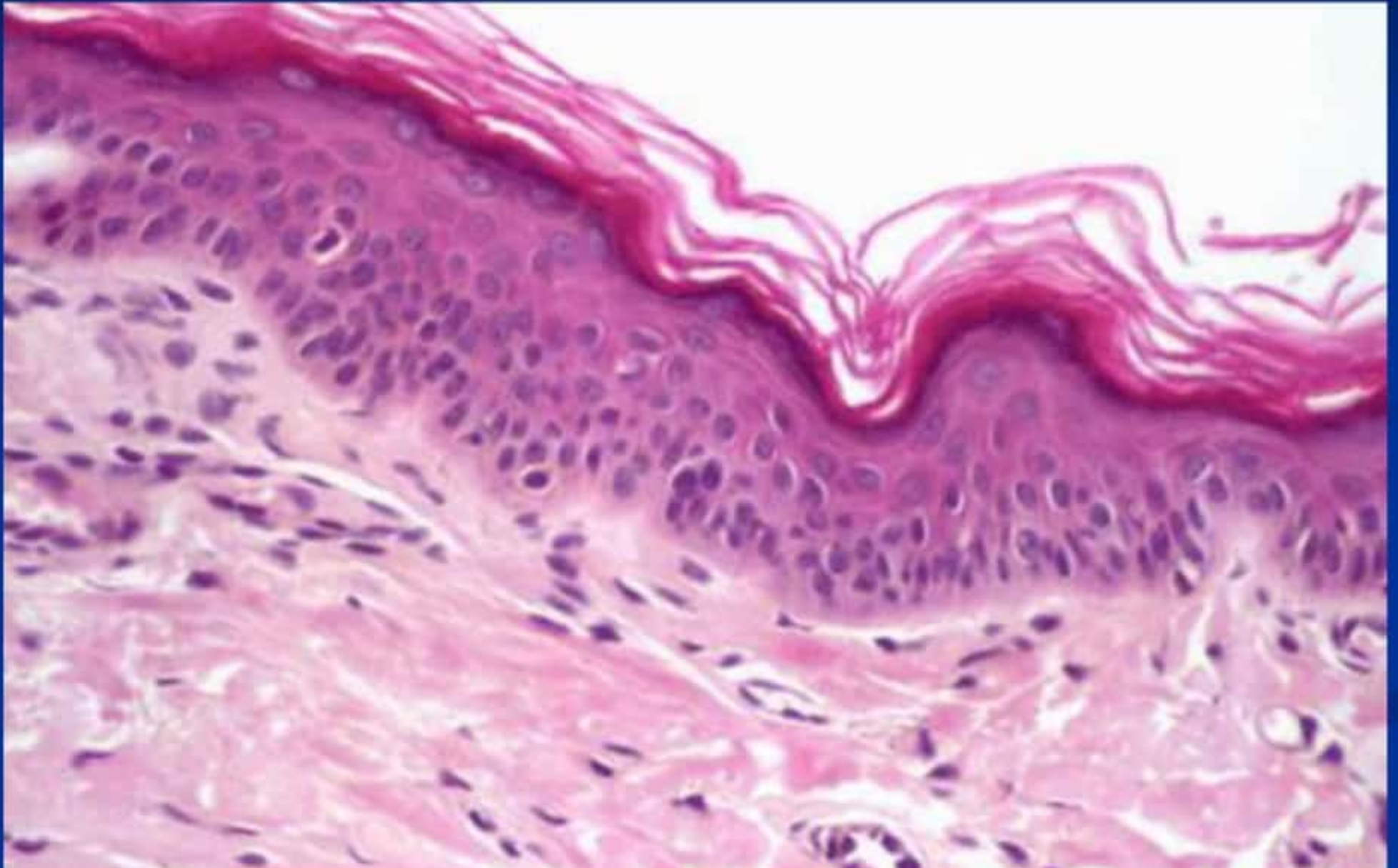


2

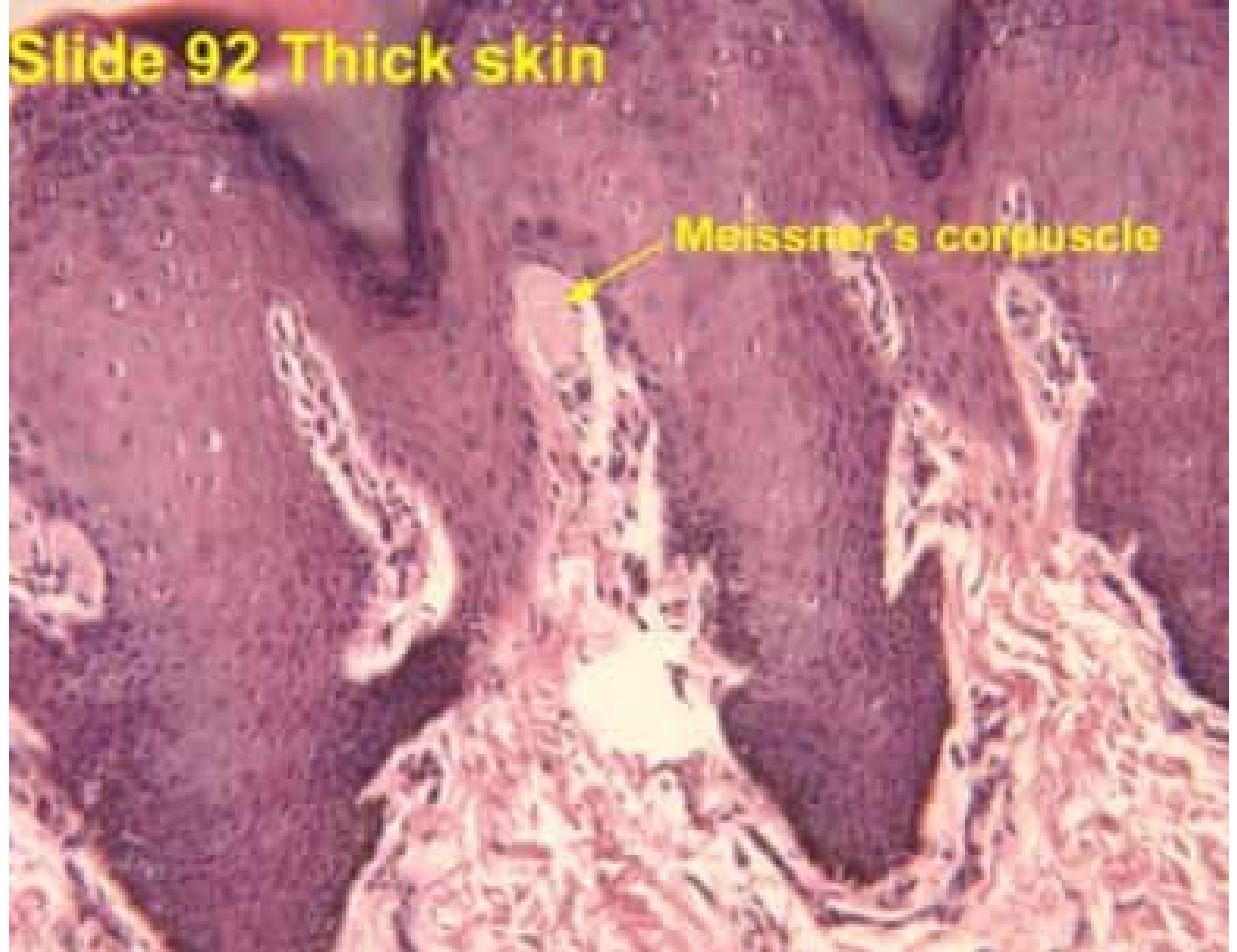

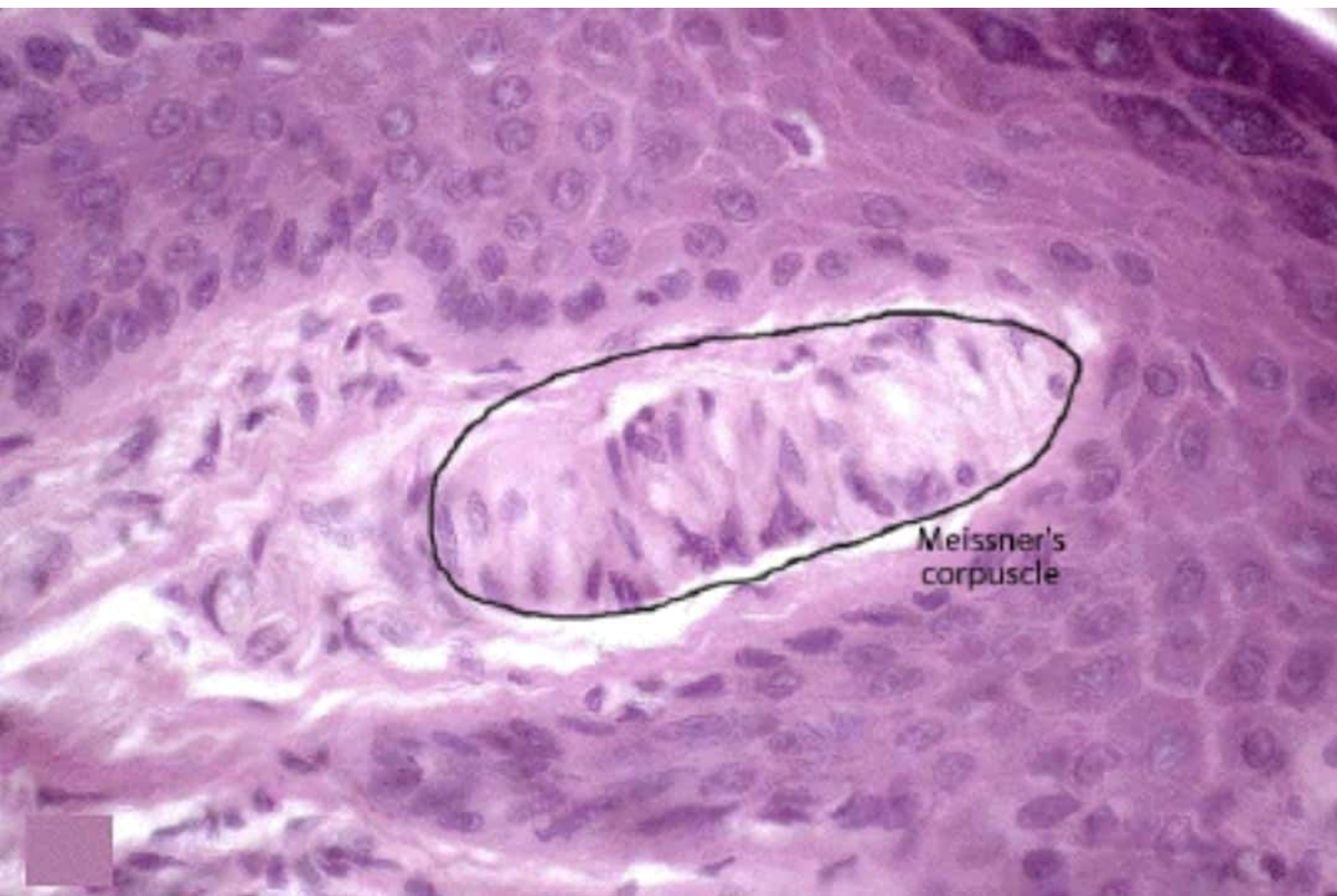


# F. Stratum Corneum – Thin Skin

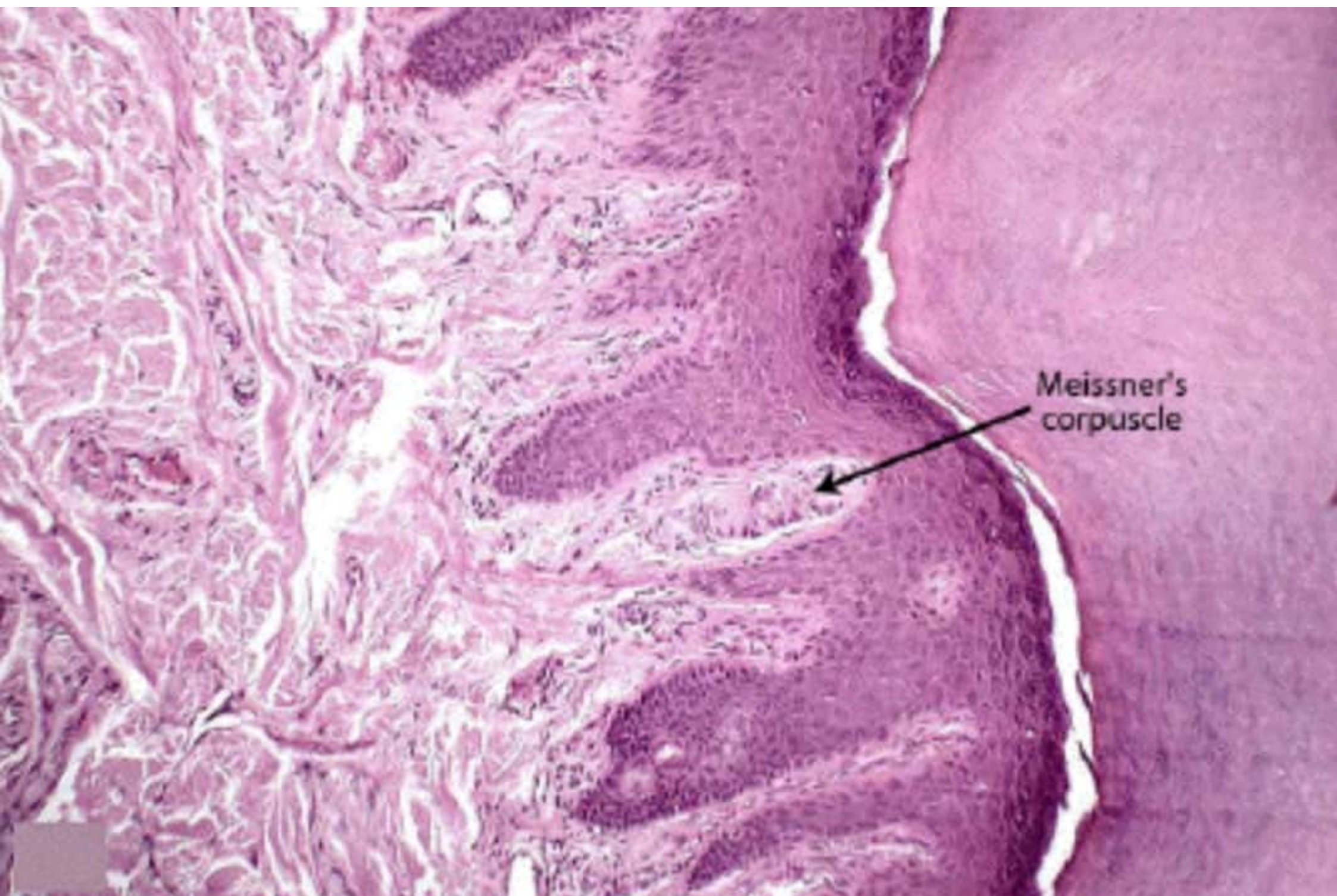

# Slide 92 Thick skin



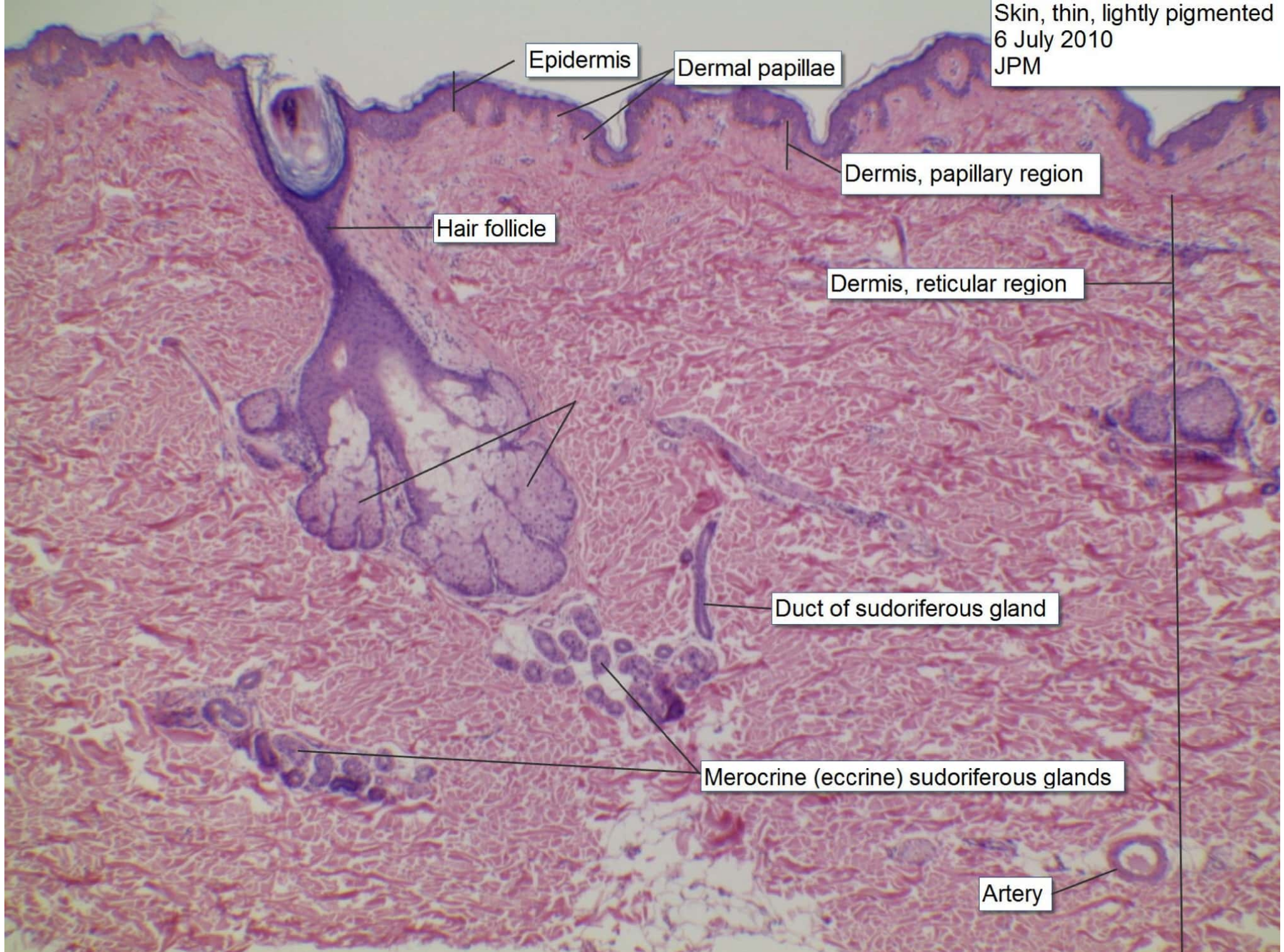


Meissner's  
corpuscle



Meissner's  
corpuscle

Skin, thin, lightly pigmented  
6 July 2010  
JPM



Epidermis

Dermal papillae

Dermis, papillary region

Hair follicle

Dermis, reticular region

Duct of sudoriferous gland

Merocrine (eccrine) sudoriferous glands

Artery

