

وسهلا

أهلا



الأستاذ الدكتور يوسف حسين

أستاذ التشريح وعلم الأجنة - كلية الطب - جامعة الزقازيق - مصر

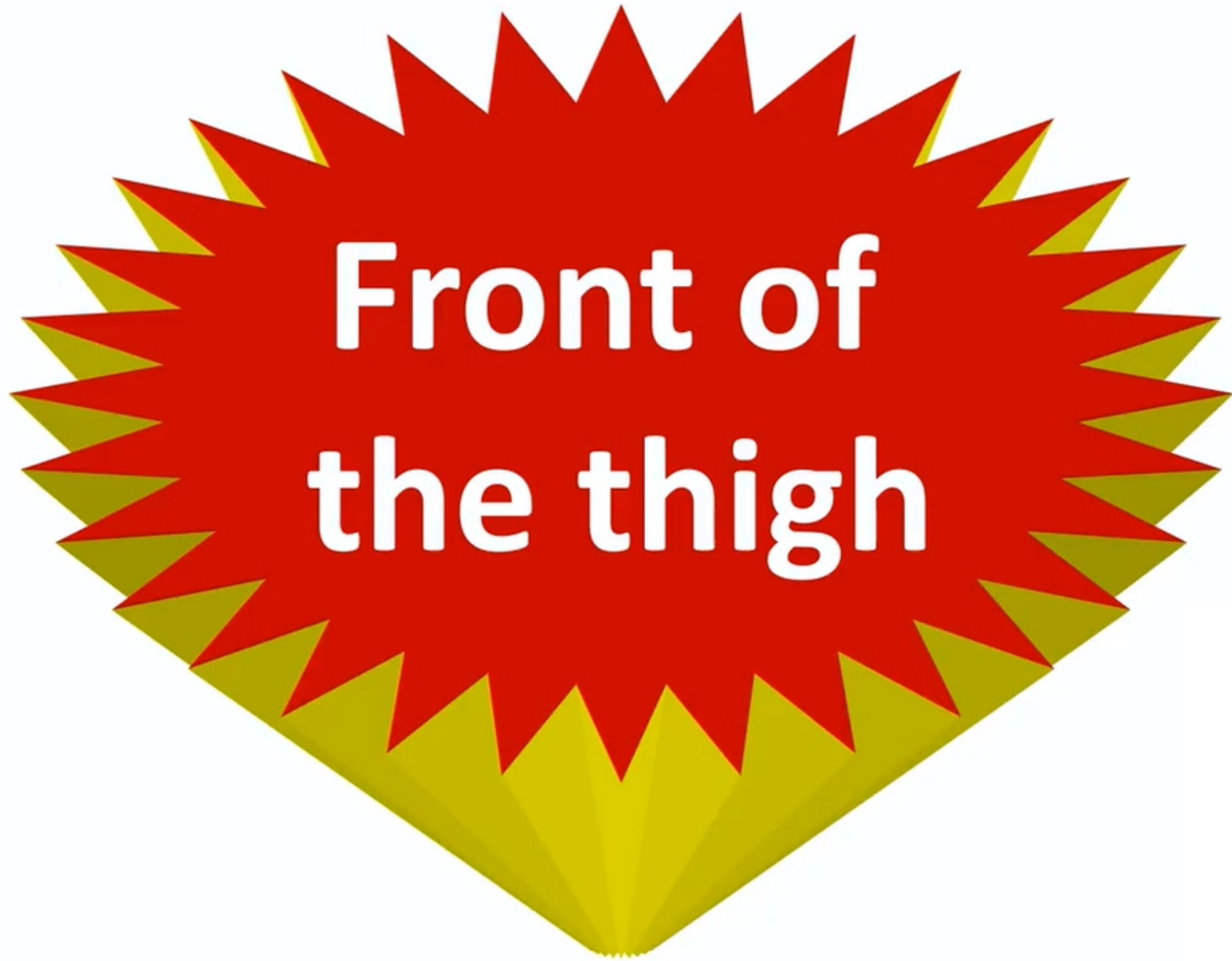رئيس قسم التشريح و الأنسجة و الأجنة - كلية الطب - جامعة مؤتة - الأردن

مساعد العميد لشؤون الطلاب والامتحانات - كلية الطب - جامعة مؤتة - الأردن

دكتورة من جامعة كولونيا المانيا

Dr. Youssef Hussein Anatomy اليوتيوب

جروب الفيس د. يوسف حسين (استاذ التشريح)



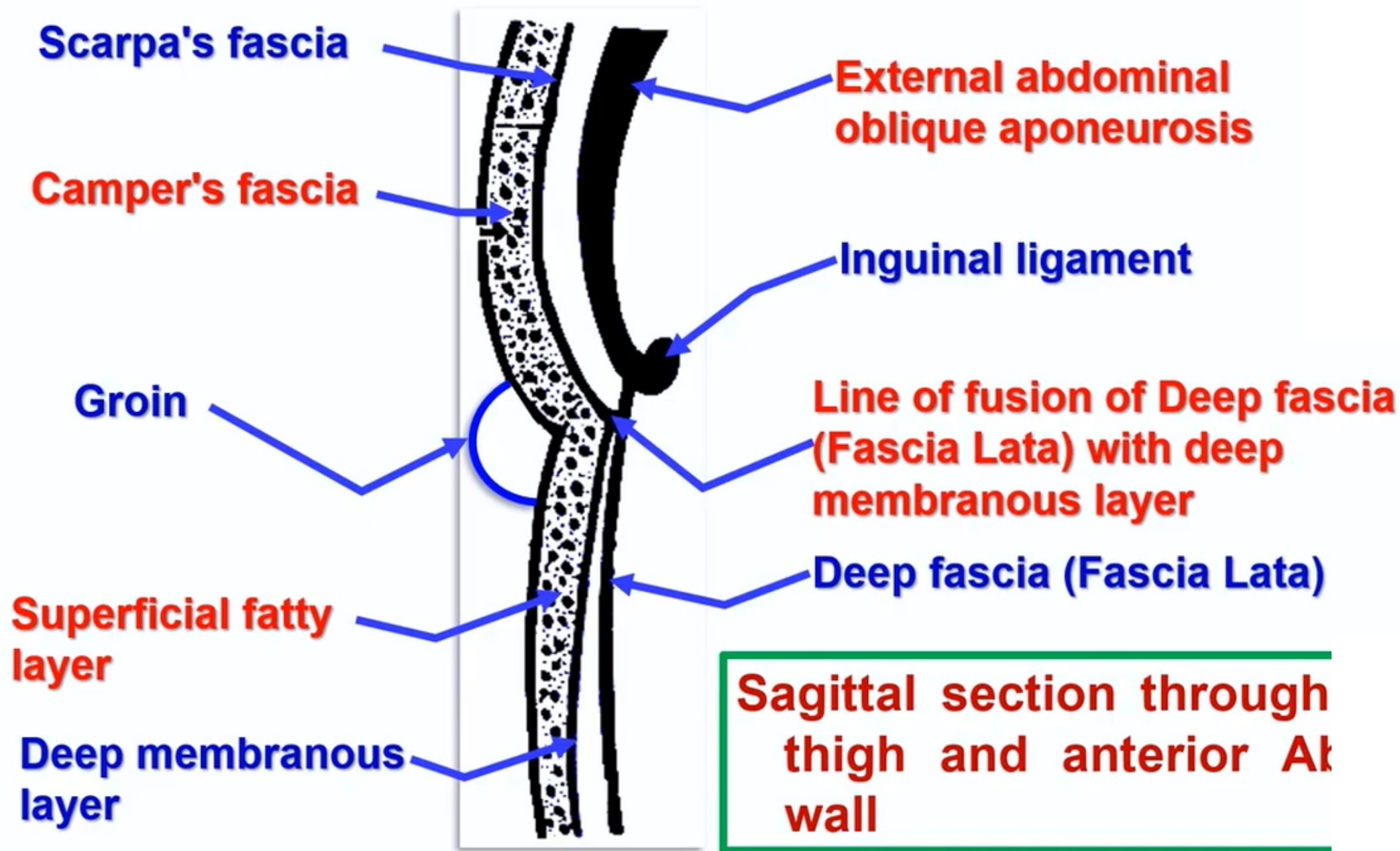
**Front of
the thigh**

A stylized graphic consisting of a central red starburst shape with multiple points. The starburst is set against a background that transitions from a light yellow-green at the bottom to a darker green at the top. The text is centered within the red starburst.

**Superficial
Fascia
Cutaneous
nerve supply**



**Sagittal section through
thigh and anterior wall
wall**



• Superficial Fascia of front of Thigh

▪ It is differentiated into:

- a. **Superficial fatty layer:** thick especially in the medial side of the thigh.
- It continuous with Superficial fatty layer of anterior abdominal wall (**Camper's fascia**)
- a. **Deep membranous layer:** continuous with Deep membranous layer of anterior abdominal wall (**Scarpa's fascia**)
- **It is** firmly attached to the deep fascia of the thigh just below the inguinal ligament.
- **** Groin** (Inguinal groove); junction of the anterior abdomi front of thigh.

❖ Superficial cutaneous nerves

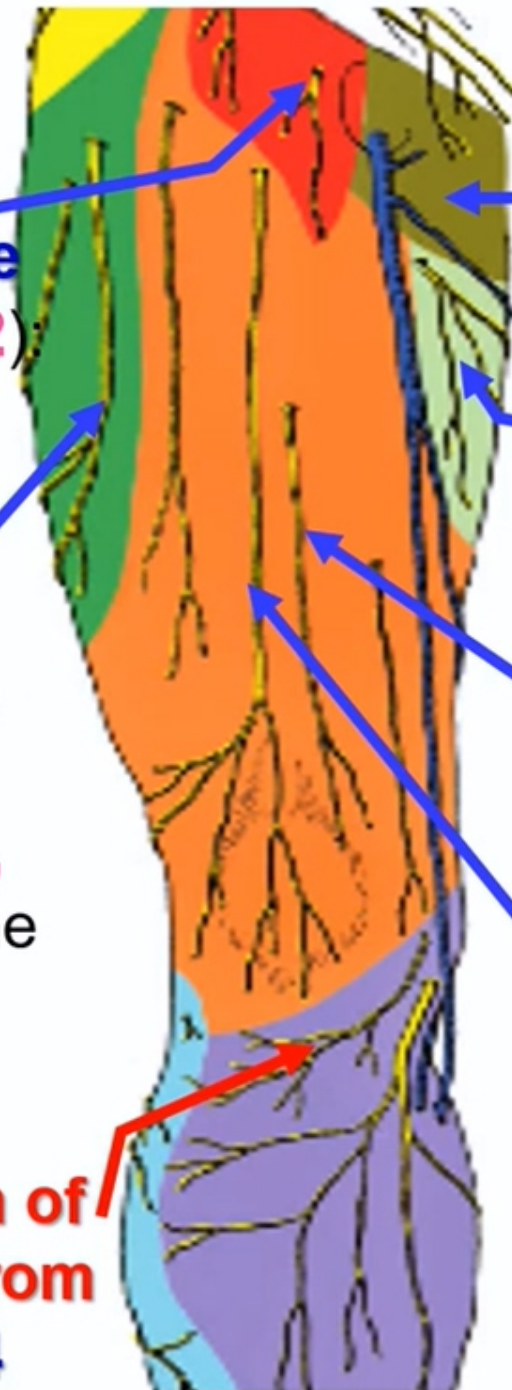
Femoral branch of genitofemoral nerve (lumbar plexus L1, 2)

skin overlying the femoral triangle

Lateral cutaneous nerve of thigh (lumbar plexus L 2, 3)

Lateral part of the front of the thigh

Infrapatellar branch of saphenous nerve from femoral nerve L3&4



Ilioinguinal nerve (lumbar plexus L1, upper part of the medial side of the thigh)

Obturator nerve (lumbar plexus L1, 2, 3, middle 1/3 of the medial side of thigh)

Medial cutaneous nerve of thigh (femoral nerve L 2, 3), Front and lower 1/3 of the medial side of the thigh

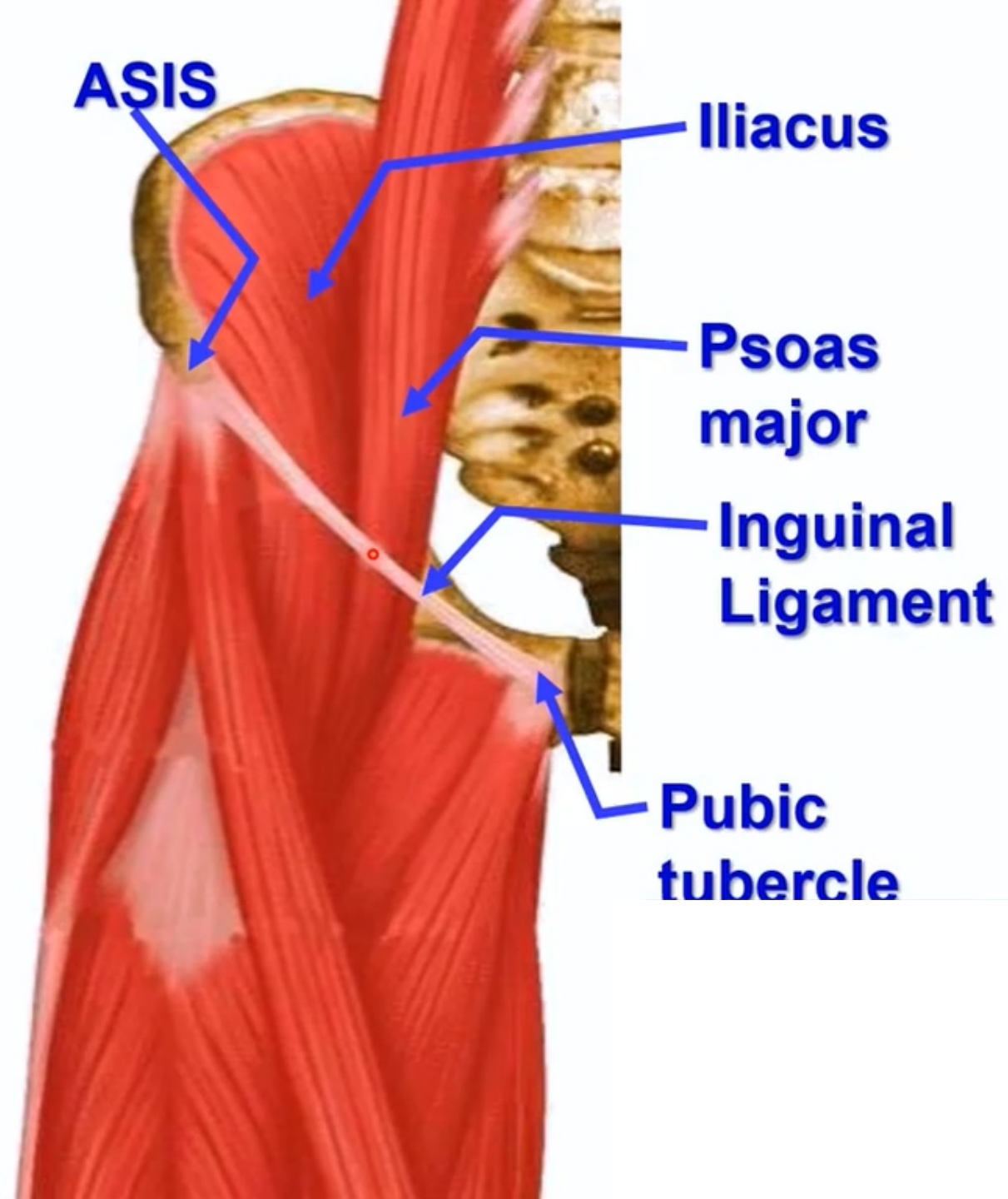
Intermediate cutaneous nerve of thigh (femoral nerve L 2, 3), Front of the thigh



**Inguinal
Ligament**

- **Inguinal (Poupart's) Ligament**

- This is the lower border of the external abdominal oblique aponeurosis.
- The muscle folded upward backwards upon itself.
- It is convex downward due to traction by the deep fascia.
- **Attachments,**
 - **Medially:** pubic tubercle.
 - **Laterally:** anterior superior iliac spine.



**** Midpoint of inguinal ligament:** midway between anterior superior iliac spine and pubic tubercle.

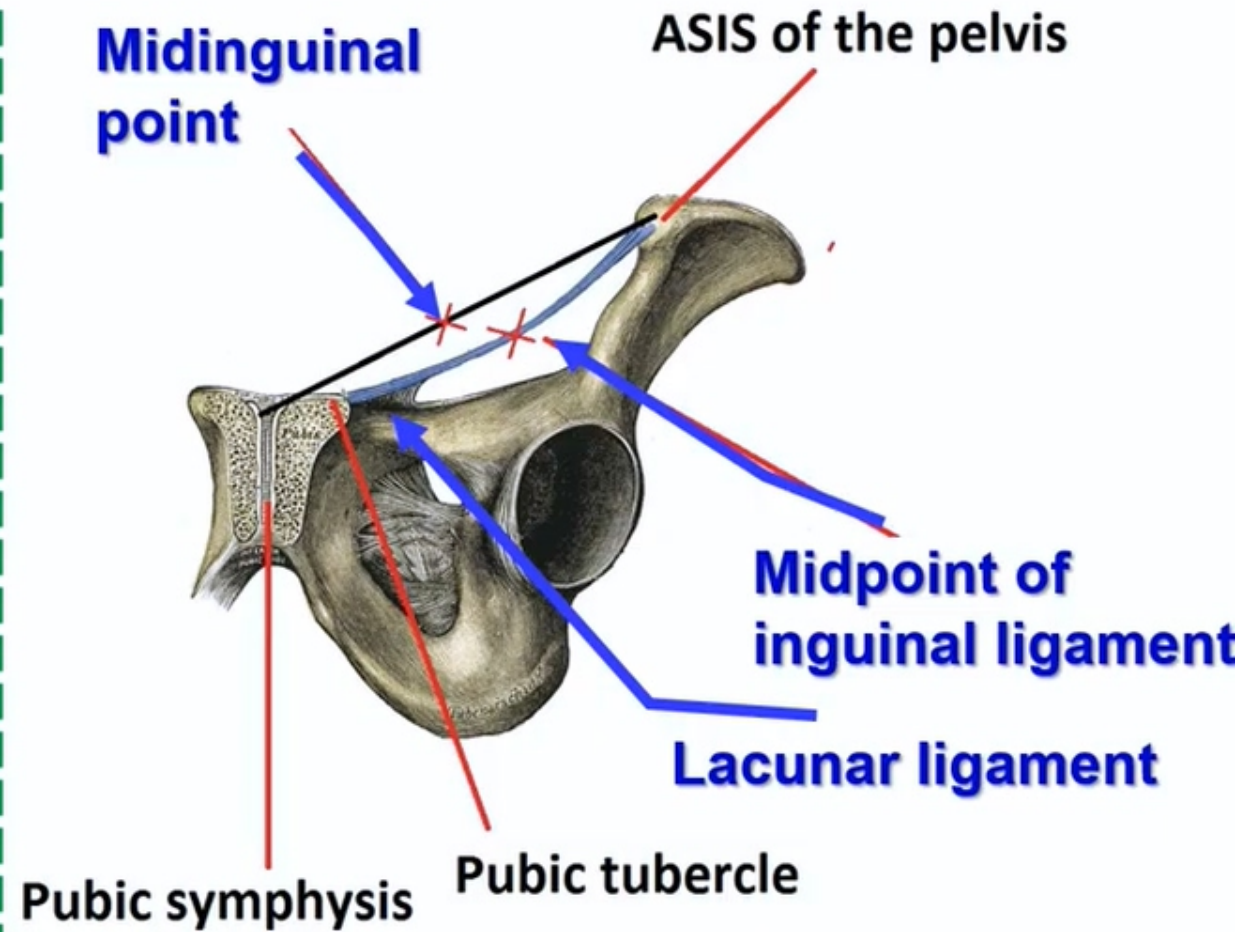
N.B: we detect **pubic tubercle** by adducting the thigh against resistance and follow tendon of adductor longus muscle.

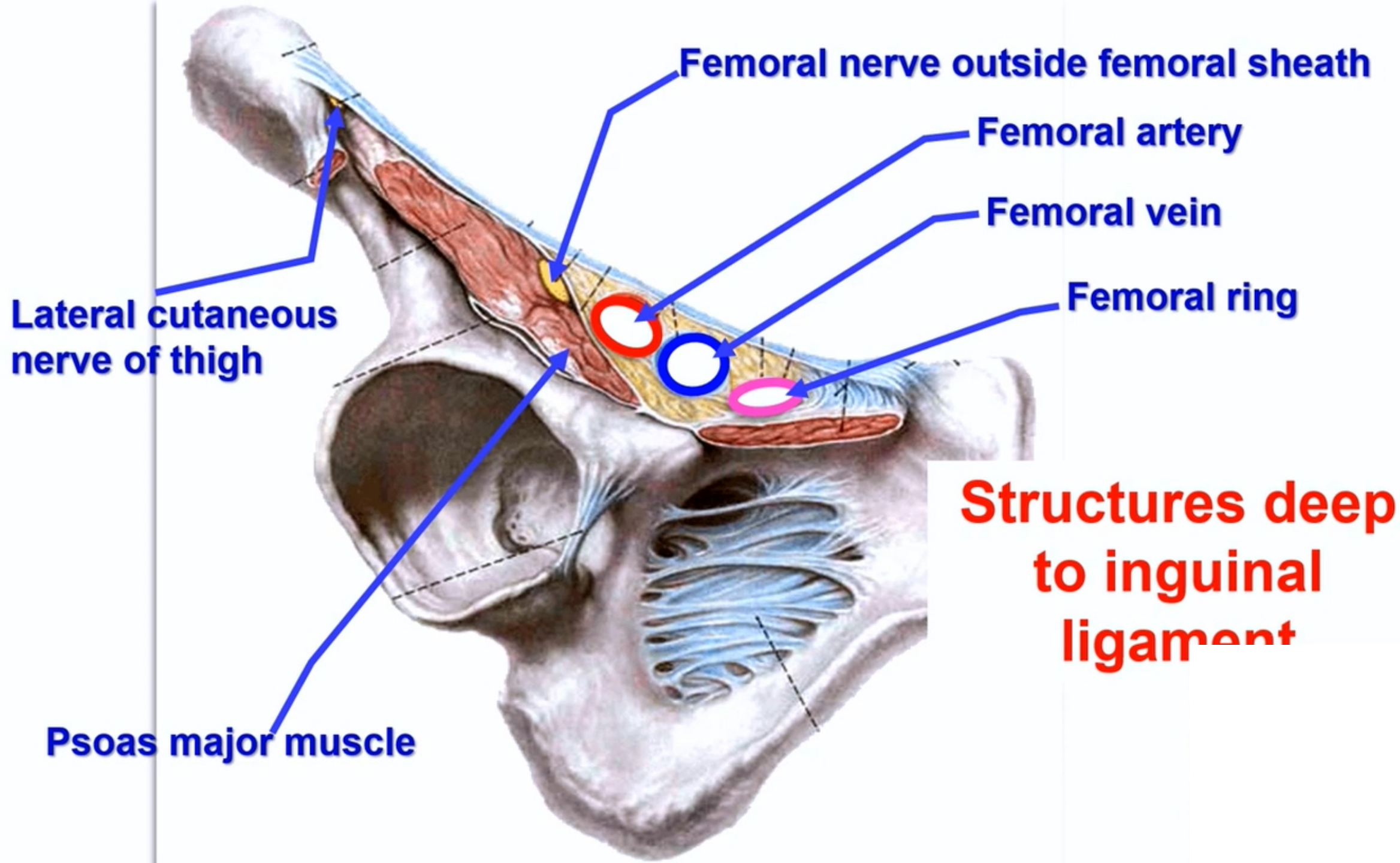
**** Midinguinal point:** midway between anterior superior iliac spine and symphysis pubis.

- **Lacunar ligament**, triangular medial part of the inguinal ligament.

a- **Apex** attached to the pubic tubercle.

b- **Base** is a sharp free end and forms medial boundary of the femoral ring





Superficial inguinal lymph nodes

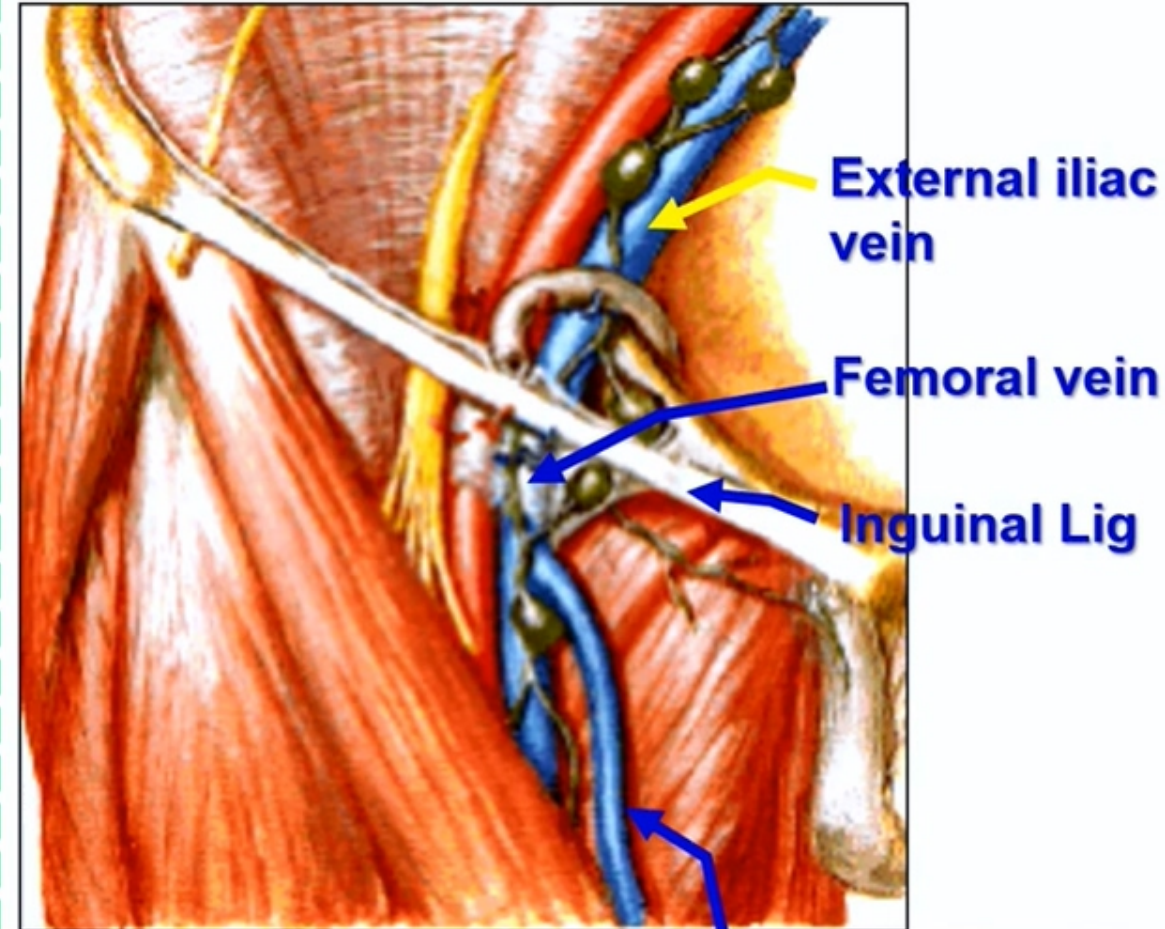
A- Upper (Horizontal) group: below the inguinal ligament.

B- Lower (Vertical) group; around the upper part of the great saphenous vein.

** Afferent:

- 1- From whole of the lower limb.
- 2- Anterior abdominal wall below the level of umbilicus.
- 3- External genital organs.
- 4- Perineum and Lower part of the anal canal.
- 5- Fundus of the uterus related to the opening of the uterine tubes **along the round ligament of the uterus.**

**** Efferent:** to **deep inguinal lymph nodes close to femoral vein** then to **external iliac lymph nodes** close to external iliac vein



Great saphenous

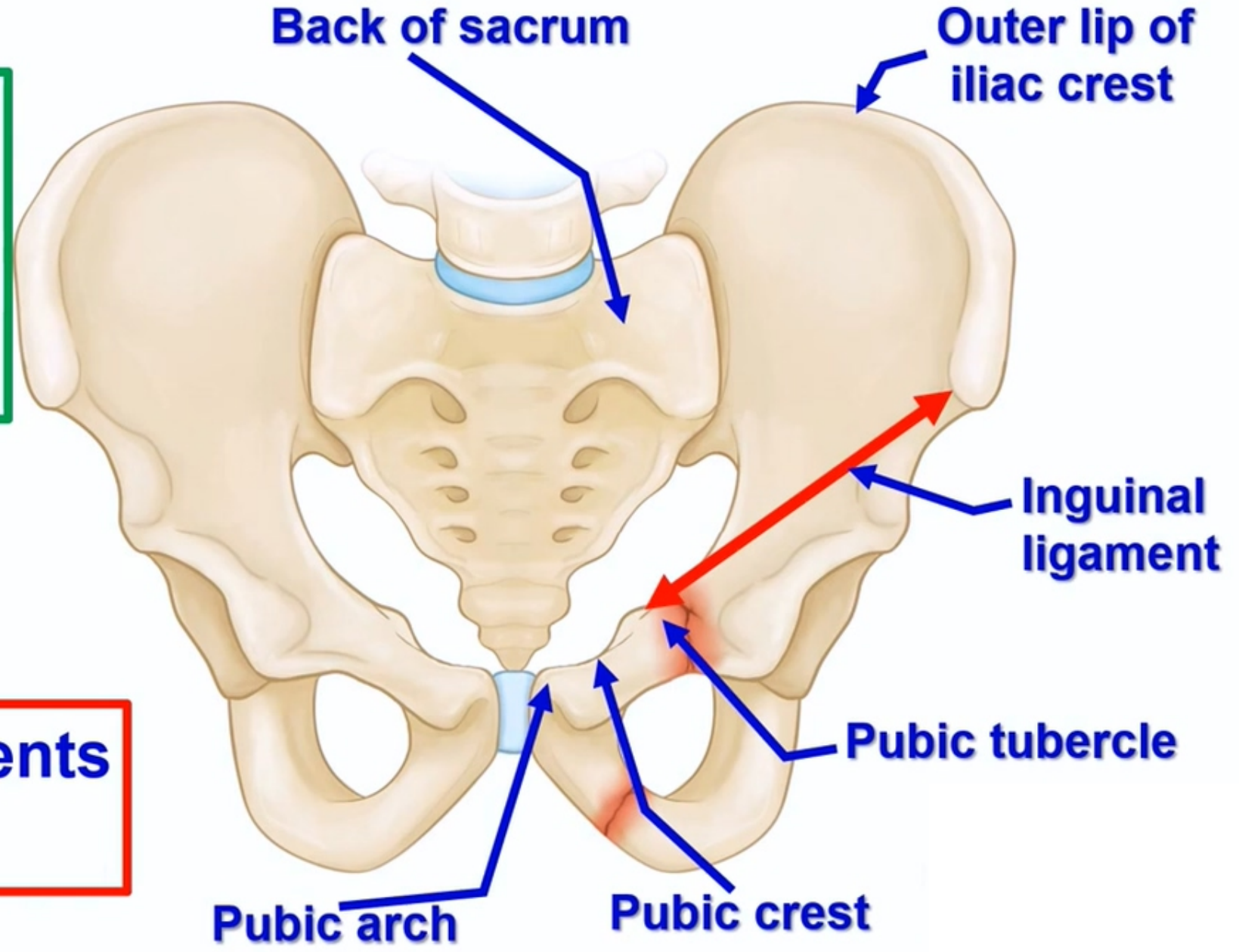


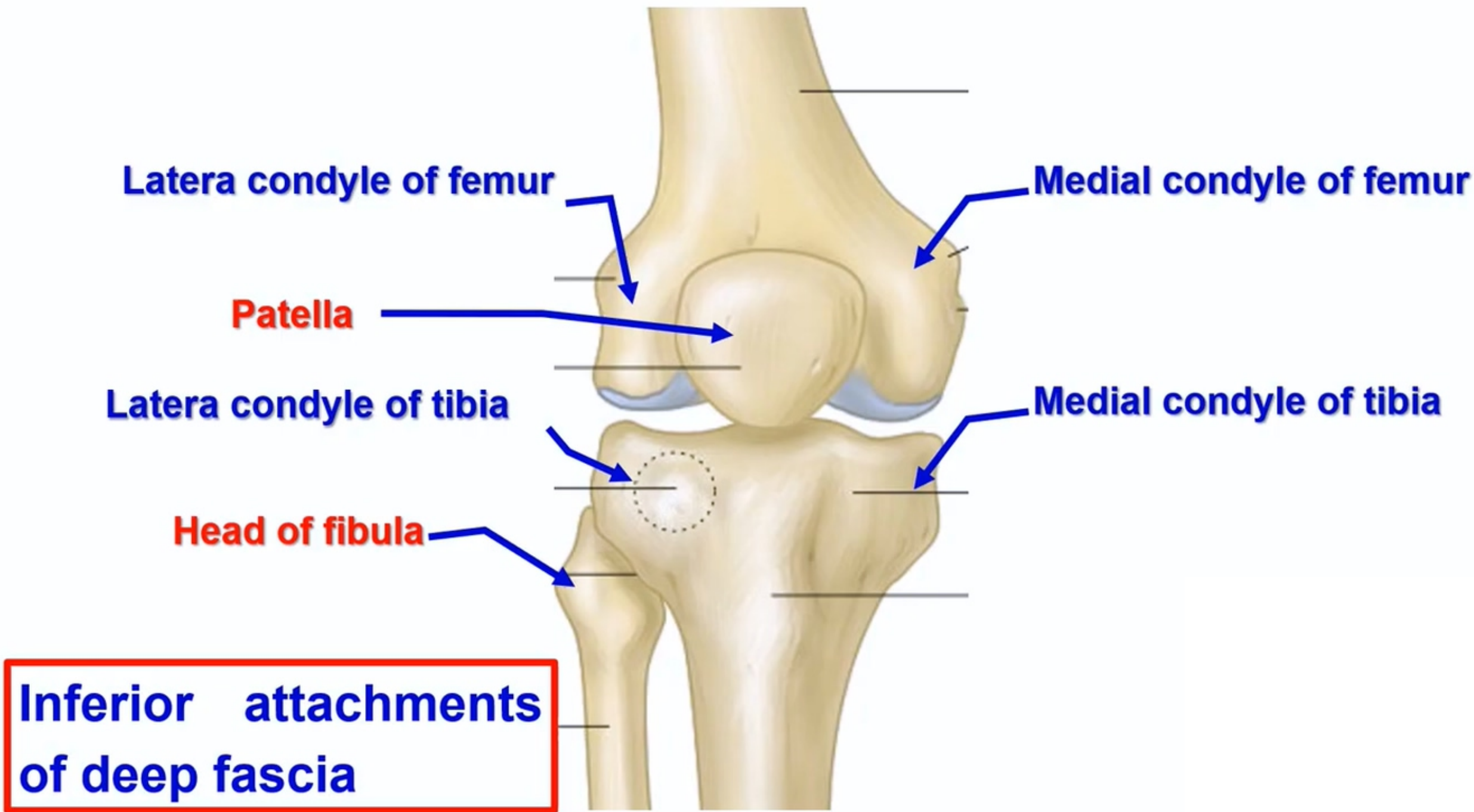
**Deep
fascia**

- **Deep Fascia of the Thigh (Fascia lata)**

- It is very strong fascia surrounding the thigh.

Superior attachments of deep fascia





- **Iliotibial Tract**

- It is the thickened lateral part of the deep fascia of the thigh.

- **Attachment**

- a. **Superiorly**: outer lip of iliac crest

- b. **Inferiorly**, lateral condyle of Tibia.

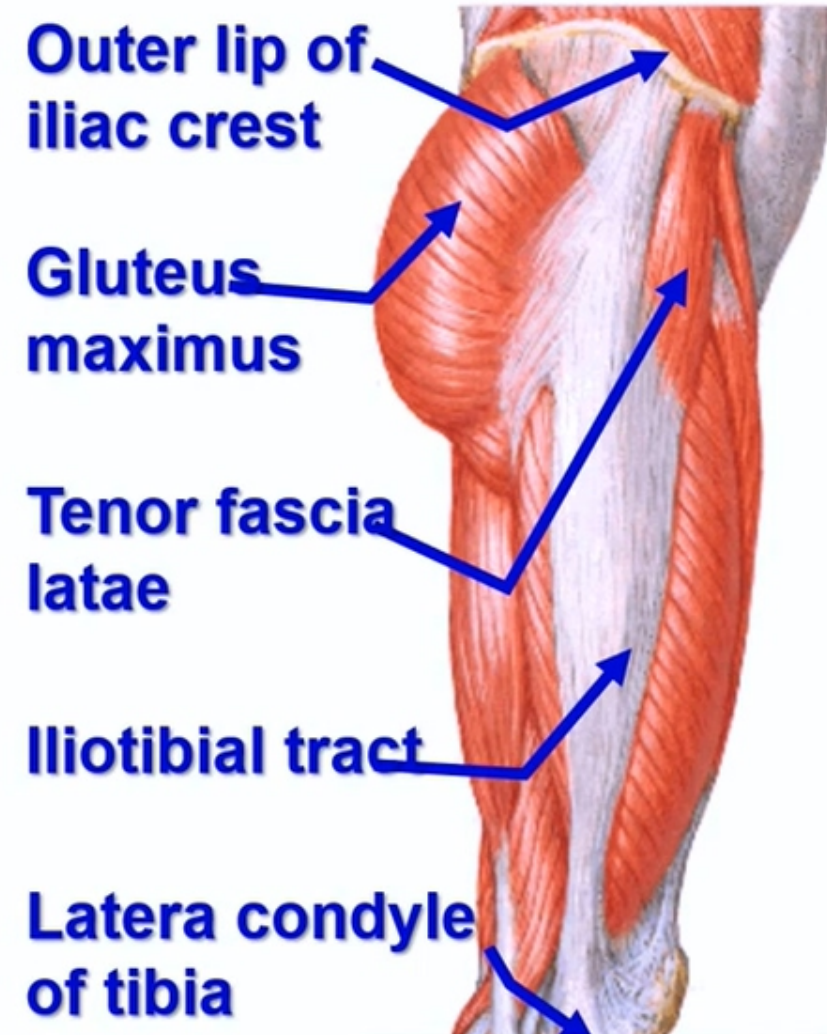
- **Nerve supply**, lateral cutaneous nerve of the thigh.

- **Functions,**

- 1- Receives **insertion** of superficial 3/4 of gluteus maximus and tensor fasciae latae.

- 2- Maintains extension of the knee joint.

- 3- Steady pelvis on the femur during standing.

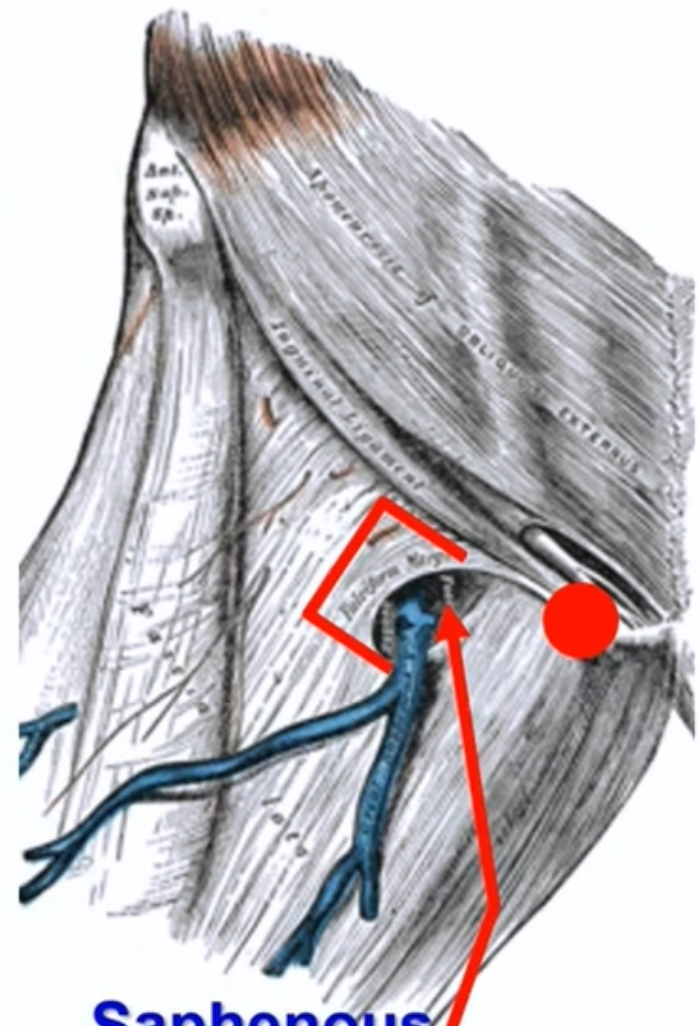




**Saphenous
opening**

• Saphenous Opening

- ** **Shape**, an oval opening in deep fascia of thigh.
- ** **Site**, 1.5 inches below and lateral to the pubic tubercle.
- ** **Margins**, superiorly, laterally and inferiorly are sharp and called **falciform margin**. medially, the margin is smooth.
- ** it is closed by a **cribriform fascia**.
- ** **Structures passing through the opening**
 - a- Great saphenous vein.
 - b- Lymph vessels from superficial to deep lymph nodes.
 - c- Superficial inguinal arteries from femoral artery**
 - 1- Superficial epigastric.
 - 2- Superficial external pudendal.
 - 3- Superficial circumflex iliac.
- ** **Deep relations**, femoral canal.
- ** **Surgical importance**, gives passage for femoral hernia.



**Saphenous
opening**



Thank you

Questions