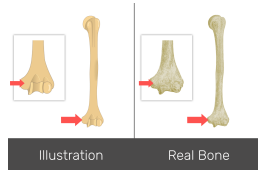


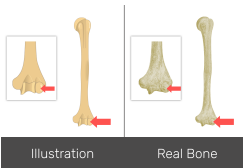
**1-) Name the bone marking :**



- A- Lesser tubercle
- B- Lateral epicondyle
- C- Medial epicondyle

Answer: Medial epicondyle

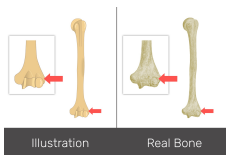
**2-) Name the bone marking :**



- A- Medial epicondyle
- B- Capitulum
- C- Lateral epicondyle

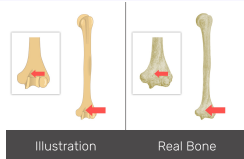
Answer: Capitulum

**3-) Name the bone marking:**



- A- Lateral epicondyle (Answer)
- B- coronoid fossa
- C- Lateral supracondylar ridge

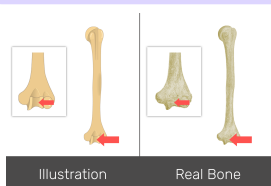
**4- Name the bone marking:**



- A- Capitulum (capitulum humeri)
- B- coronoid fossa
- C- Lesser tubercle

Answer: Coronoid fossa

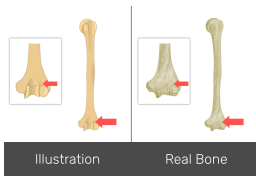
**5-) Name the bone marking:**



- A-) Lesser tubercle
- B-) Trochlea (trochlea humeri)
- C-) Capitulum

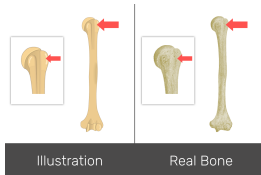
Answer: Trochlea

**6-)Name the bone marking:**



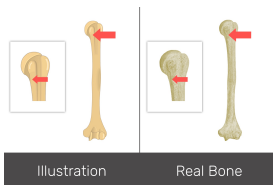
- A-)Radial fossa
  - B-)Deltoid tuberosity
  - C-)Greater tubercle
- Answer:Radial fossa

**7-)Name the bone marking:**



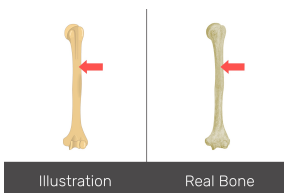
- A-)Shaft or body
  - B-)Greater tubercle
  - C-)Lateral epicondyle
- Answer:Greater tubercle

**8-)Name the bone marking:**



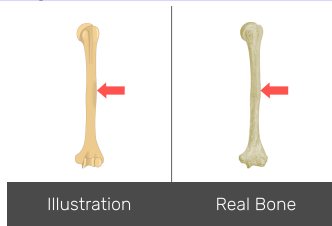
- A-Surgical neck
  - B-Capitulum
  - C-Lateral supracondylar ridge
- Answer:Surgical neck

**9-)Name the bone marking:**



- A-Shaft or body
  - B-Surgical neck
  - C-Intertubercular (bicipital) groove
- Answer:Shaft or body

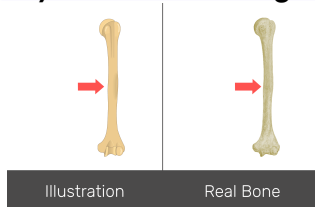
**10-)Name the bone marking:**



- A-Surgical neck
- B-Deltoid tuberosity
- C-Anatomical Neck

Answer:Deltoid tuberosity

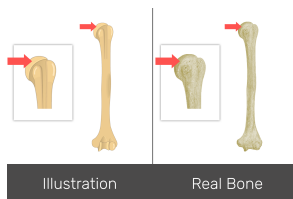
**11-)Is this a left or right humerus?**



- A-Left
- B-Right

Answer:Left

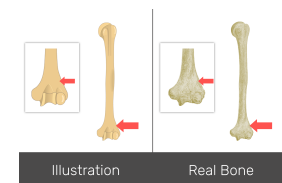
**12-)Name the bone marking:**



- A-Head of humerus
- B-Medial epicondyle
- C-Intertubercular (bicipital) groove

Answer:Head of humerus

**13-)Name the bone marking:**



- A-Anatomical Neck
- B-Trochlea
- C-Lateral supracondylar ridge

Answer:Lateral supracondylar ridge

