

INGUINAL REGION

Dr. Aiman Qais Afar
Surgical Anatomist

College of Medicine / University of Mutah

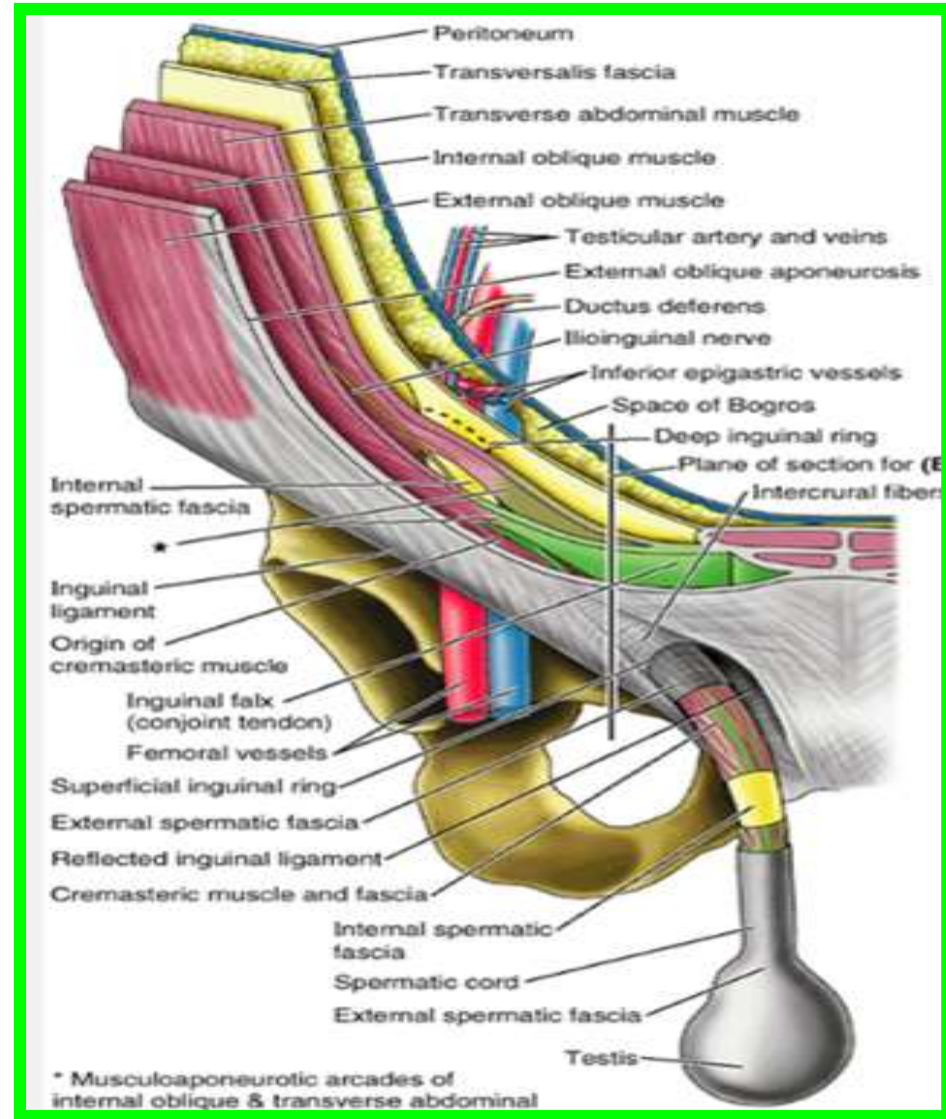
2021-2022

Thursday 17 March 2022

Inguinal Region

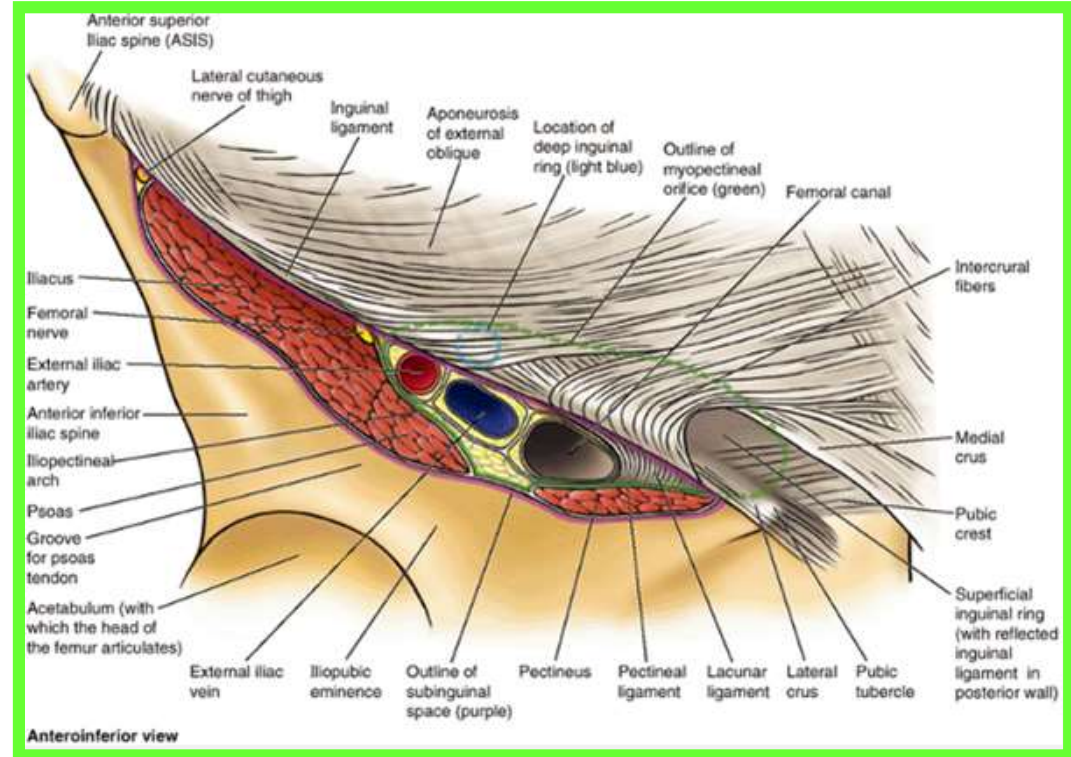
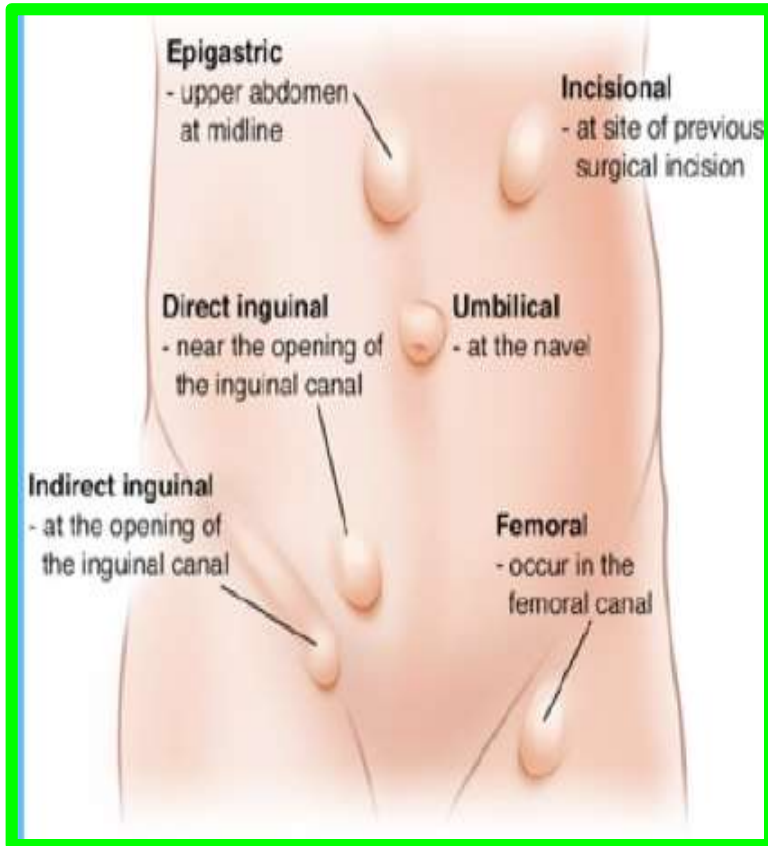
The inguinal region (groin) extending between the ASIS and pubic tubercle, is an important area anatomically and clinically.

- ❖ **Anatomically** because it is a region where structures exit and enter the abdominal cavity and
- ❖ **Clinically** because the pathways of exit and entrance are potential sites of herniation.



Inguinal Region

In fact, the majority of **abdominal hernias** occur in this region, with inguinal hernias in particular accounting for **75% of all abdominal hernias**, (approximately 86%) occur in males because of the passage of the spermatic cord through **the inguinal canal**.

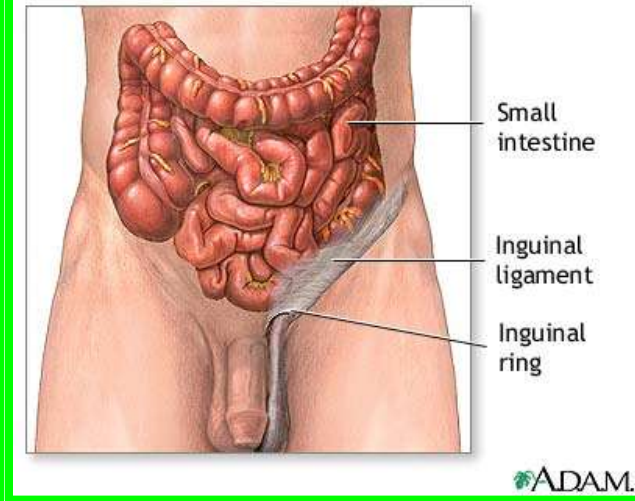
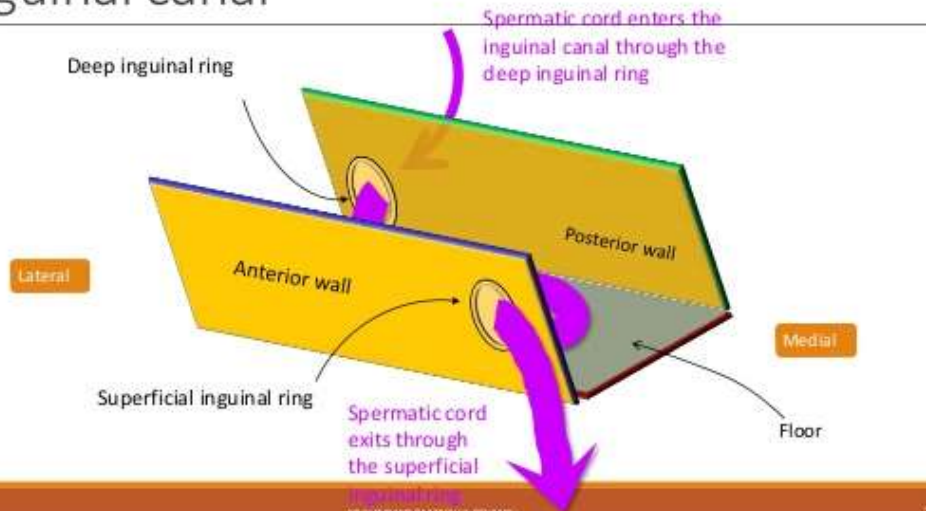


Inguinal Canal

❖ The inguinal canal is an oblique passage through the lower part of the anterior abdominal wall. **In the males**, it allows structures to pass to and from the testis to the abdomen.

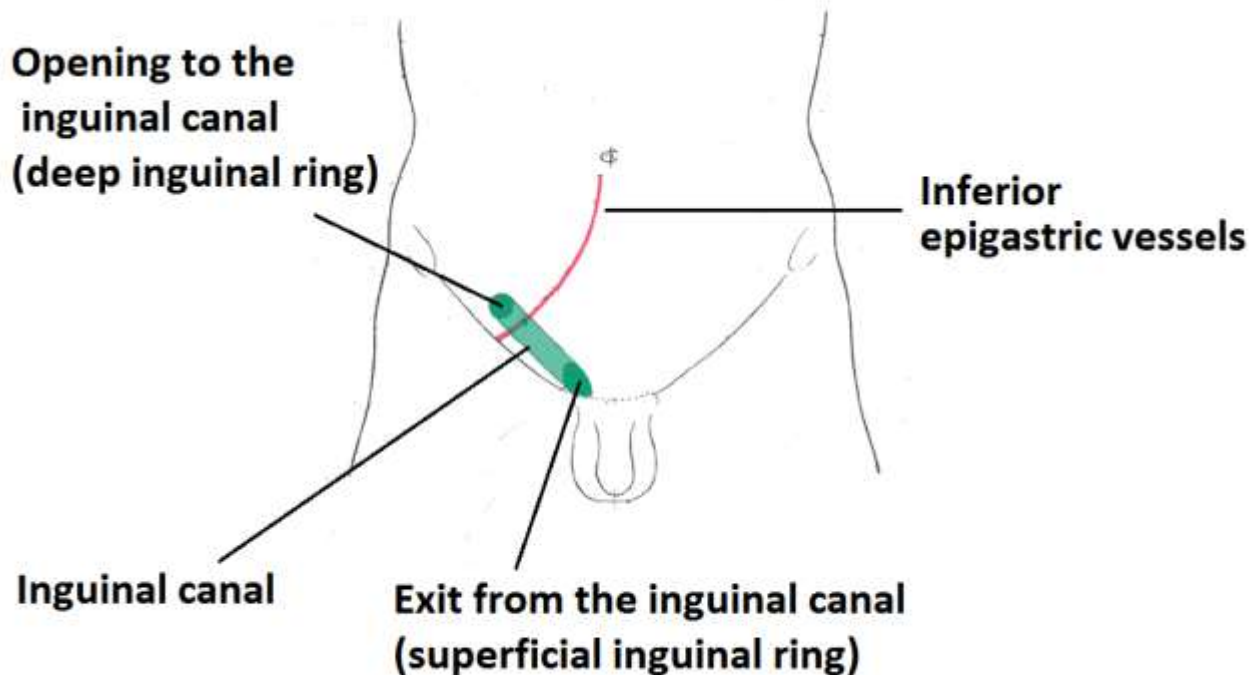
❖ **In females** it allows the round ligament of the uterus to pass from the uterus to the labium majus.

Inguinal canal



Inguinal Canal

The canal is about **1.5 in. (4 cm)** long in the adult and extends from the **deep inguinal ring**, a hole in the **fascia transversalis** downward and medially to the **superficial inguinal ring**, a hole in the aponeurosis of the **external oblique muscle**

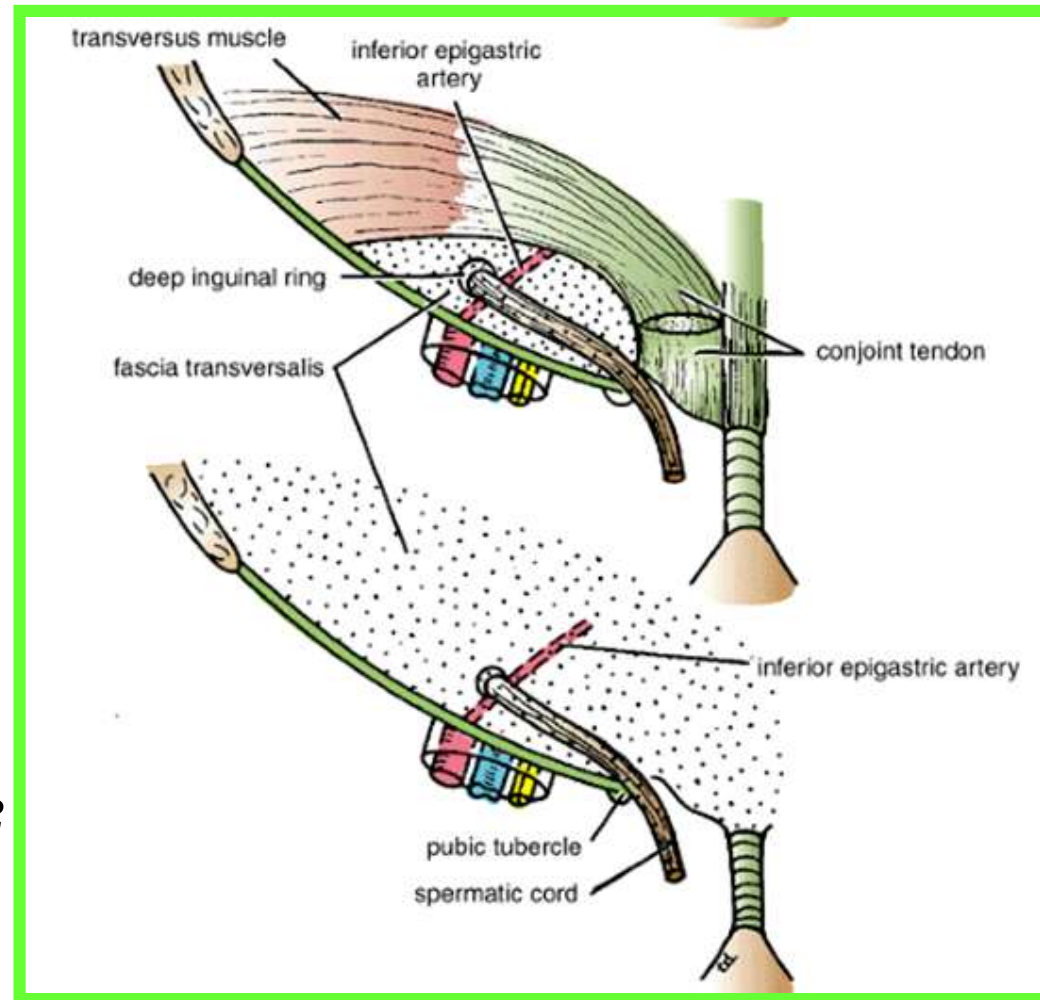


Inguinal Canal

❑ The deep inguinal ring, an oval opening in the fascia transversalis, lies about 0.5 in. (1.3 cm) above the inguinal ligament midway between the anterior superior iliac spine and the symphysis pubis

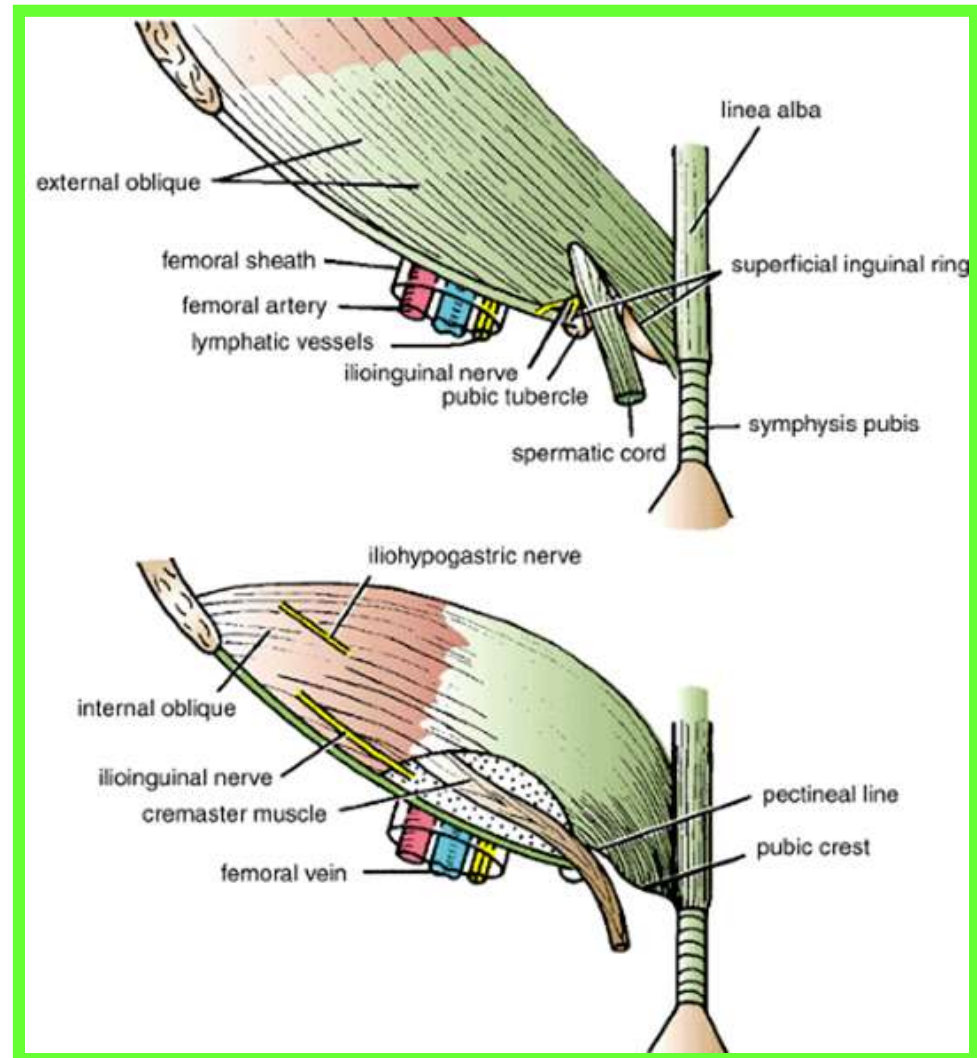
❖ Related to it medially are the inferior epigastric vessels, which pass upward from the external iliac vessels

❖ The margins of the ring give attachment to the internal spermatic fascia



Inguinal Canal

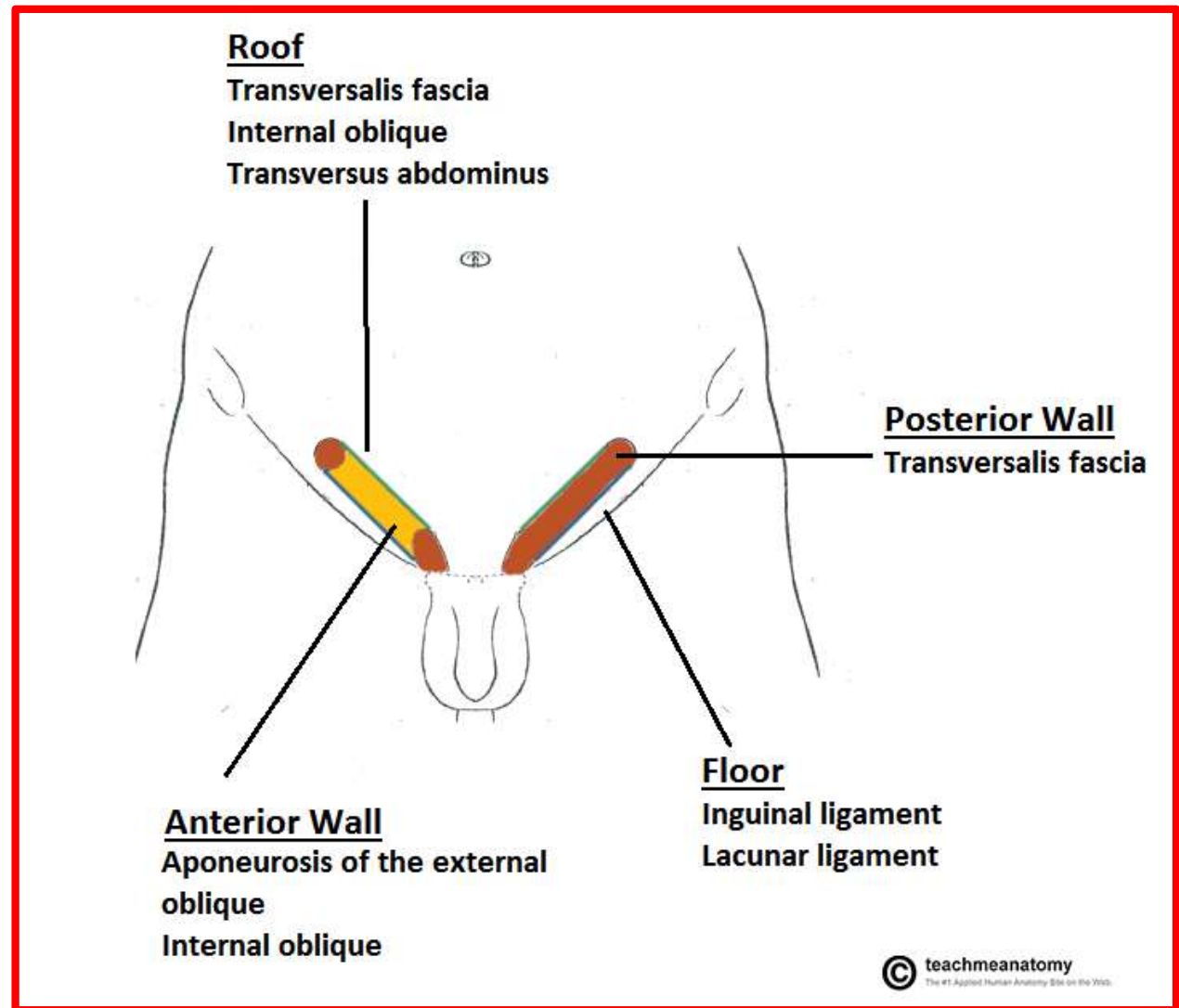
❑ **The superficial inguinal ring** is a triangular-shaped defect in the **aponeurosis of the external oblique muscle** and lies immediately above and medial to the **pubic tubercle**



❖ **The margins of the ring, sometimes called the crura, give attachment to *the external spermatic fascia***

Walls of the Inguinal Canal

- ✓ Anterior wall
- ✓ Posterior wall
- ✓ Roof
- ✓ Floor



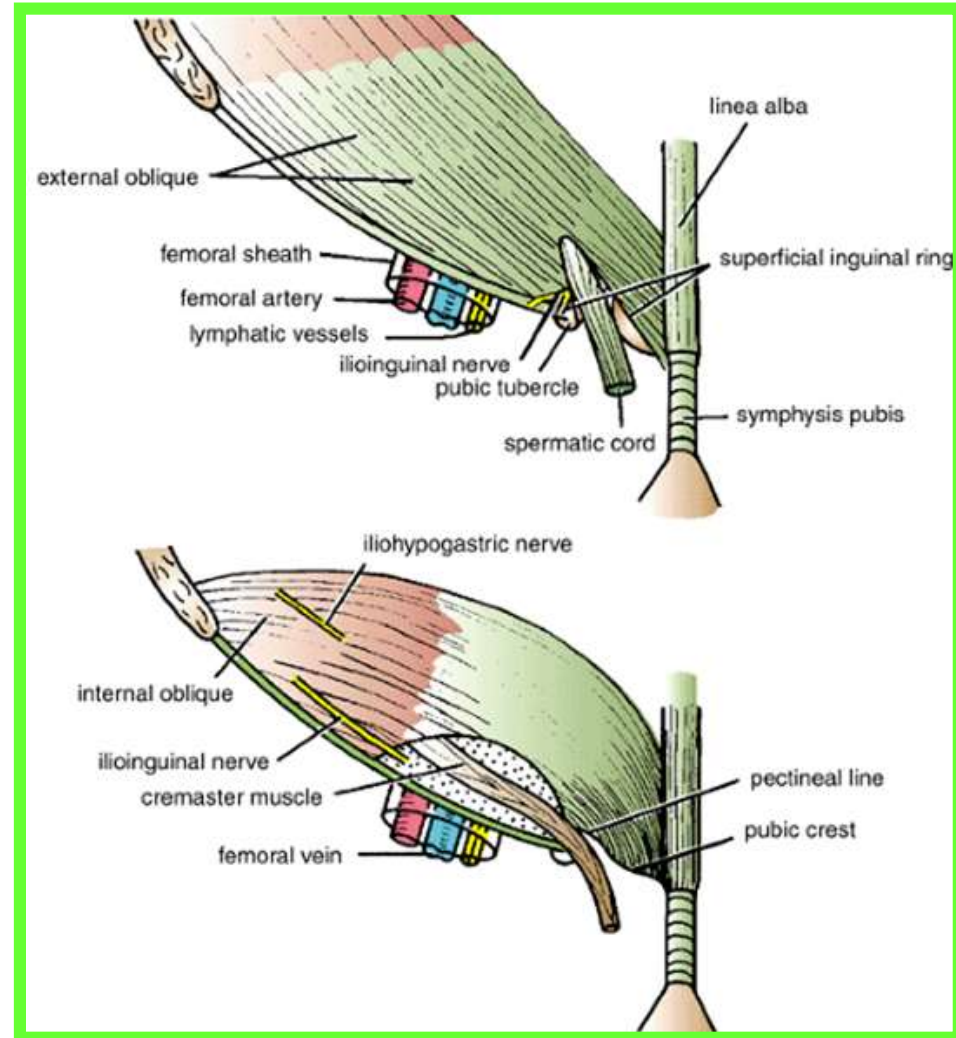
Walls of the Inguinal Canal

Anterior wall: External oblique aponeurosis, reinforced laterally by the origin of the internal oblique from the inguinal ligament

Posterior wall: Conjoint tendon medially, fascia transversalis laterally.

Roof or superior wall: Arching lowest fibers of the internal oblique and transversus abdominis muscles

Floor or inferior wall: Uprturned lower edge of the inguinal ligament and, at its medial end, the lacunar ligament

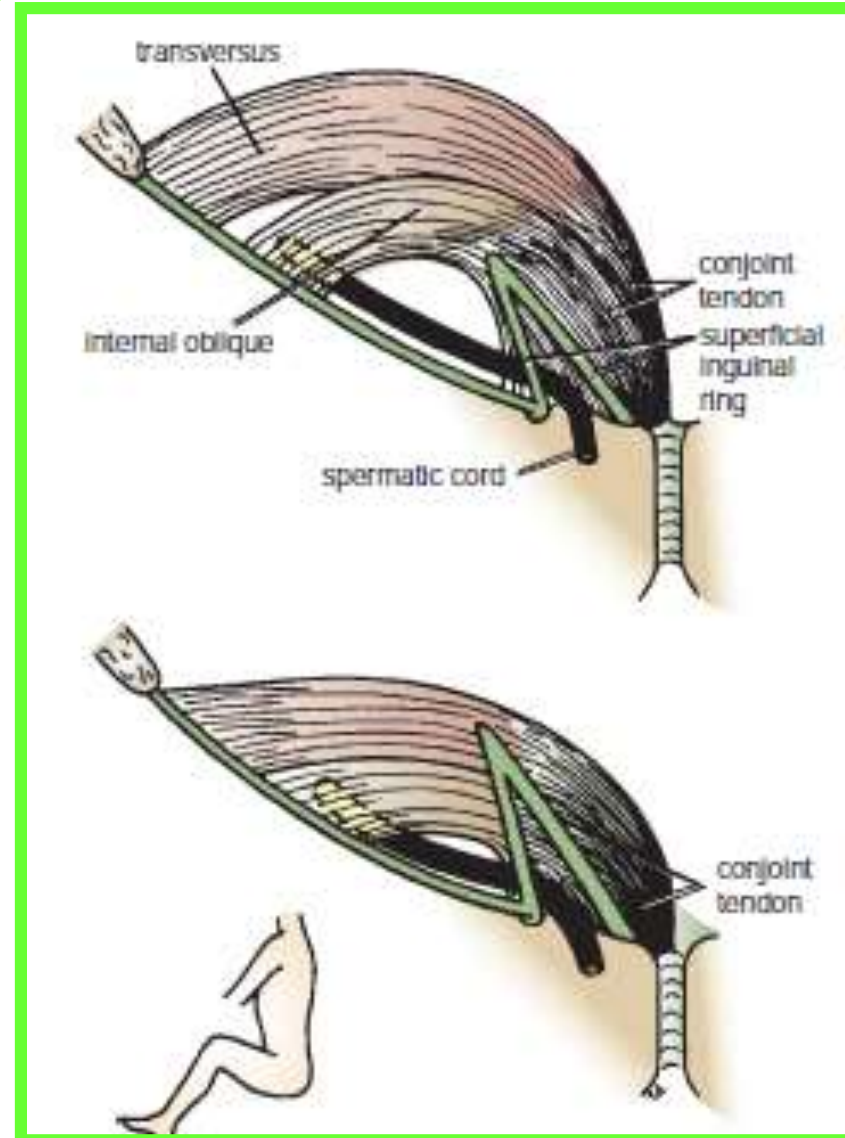
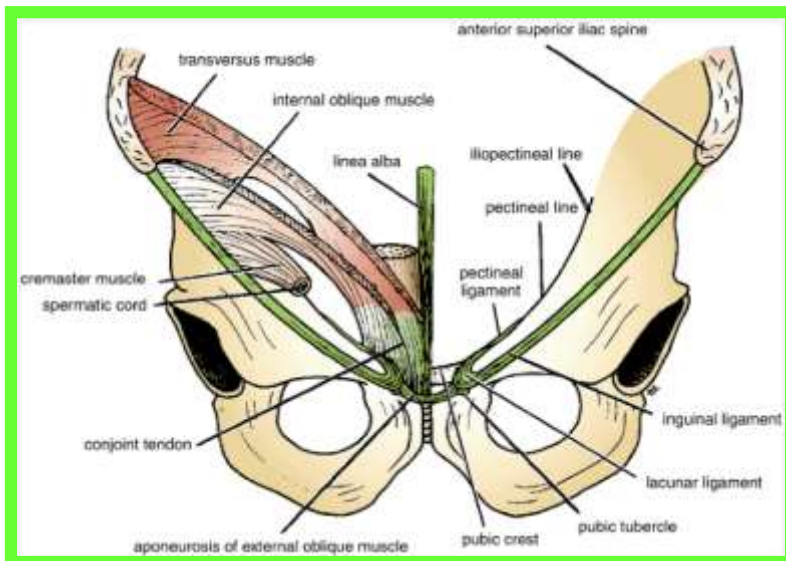


Walls of the Inguinal Canal

Dr. Aiman Qais Afar
Thursday 17 March 2022

✓ Anterior wall is therefore strongest where it lies opposite the weakest part of the posterior wall, namely, **the deep inguinal ring**.

✓ Posterior wall is therefore strongest where it lies opposite the weakest part of the anterior wall, namely, **the superficial inguinal ring**

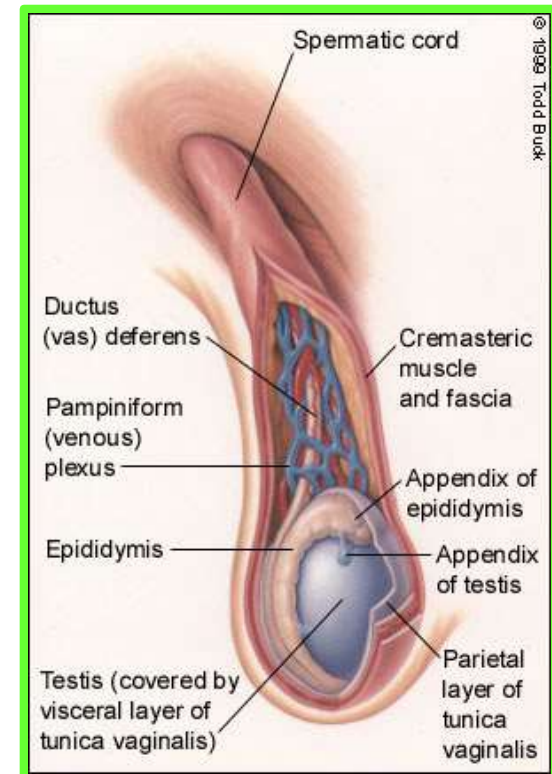
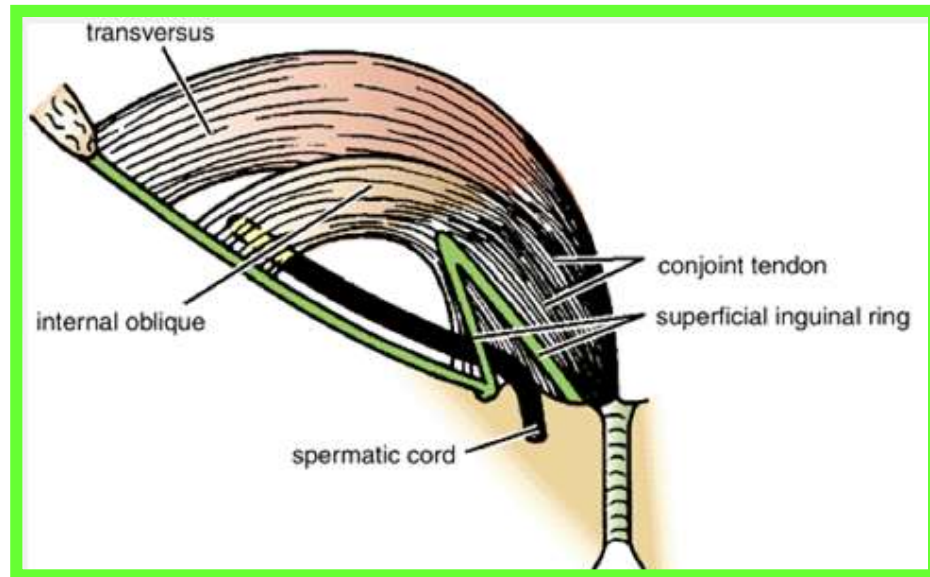


Spermatic Cord

Is a collection of structures that pass through the inguinal canal to and from the testis. It begins at **the deep inguinal ring lateral to the inferior epigastric artery** and **ends at the testis**.

Structures of the Spermatic Cord

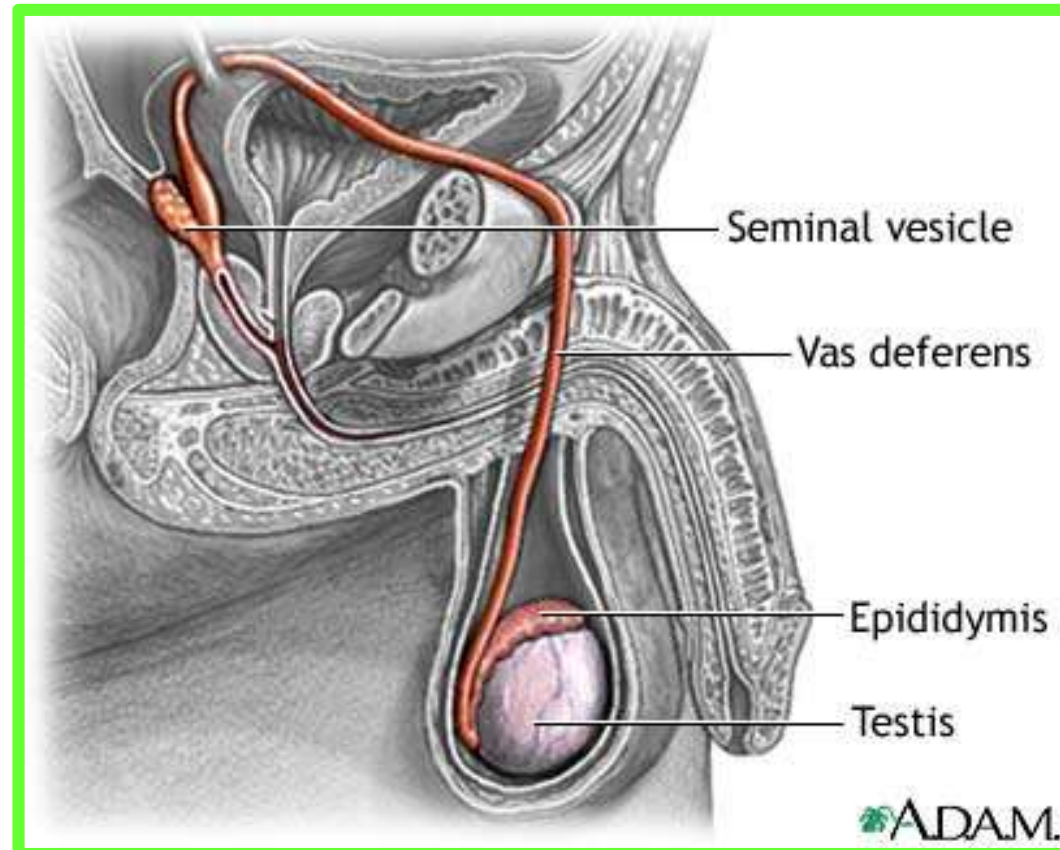
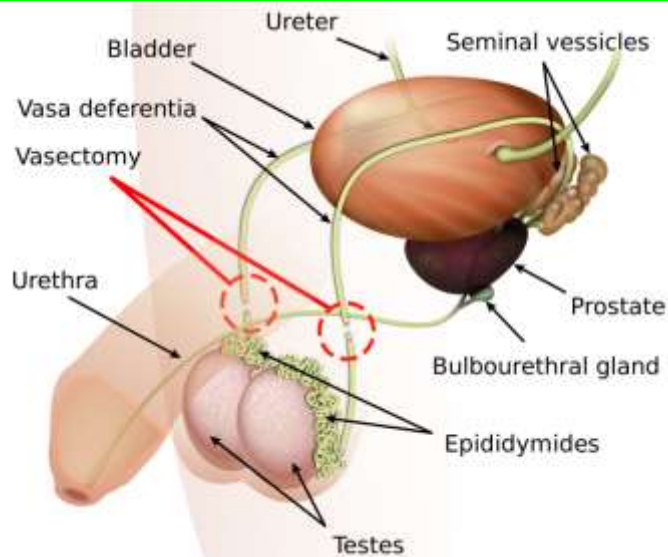
- ❖ Vas deferens
- ❖ Testicular artery
- ❖ Testicular veins (pampiniform plexus)
- ❖ Testicular lymph vessels
- ❖ Autonomic nerves
- ❖ Remains of the processus vaginalis
- ❖ Genital branch of the genitofemoral nerve, which supplies the cremaster muscle



❖ Vas Deferens (Ductus Deferens)

Dr. Aiman Qais Afar
Thursday 17 March 2022

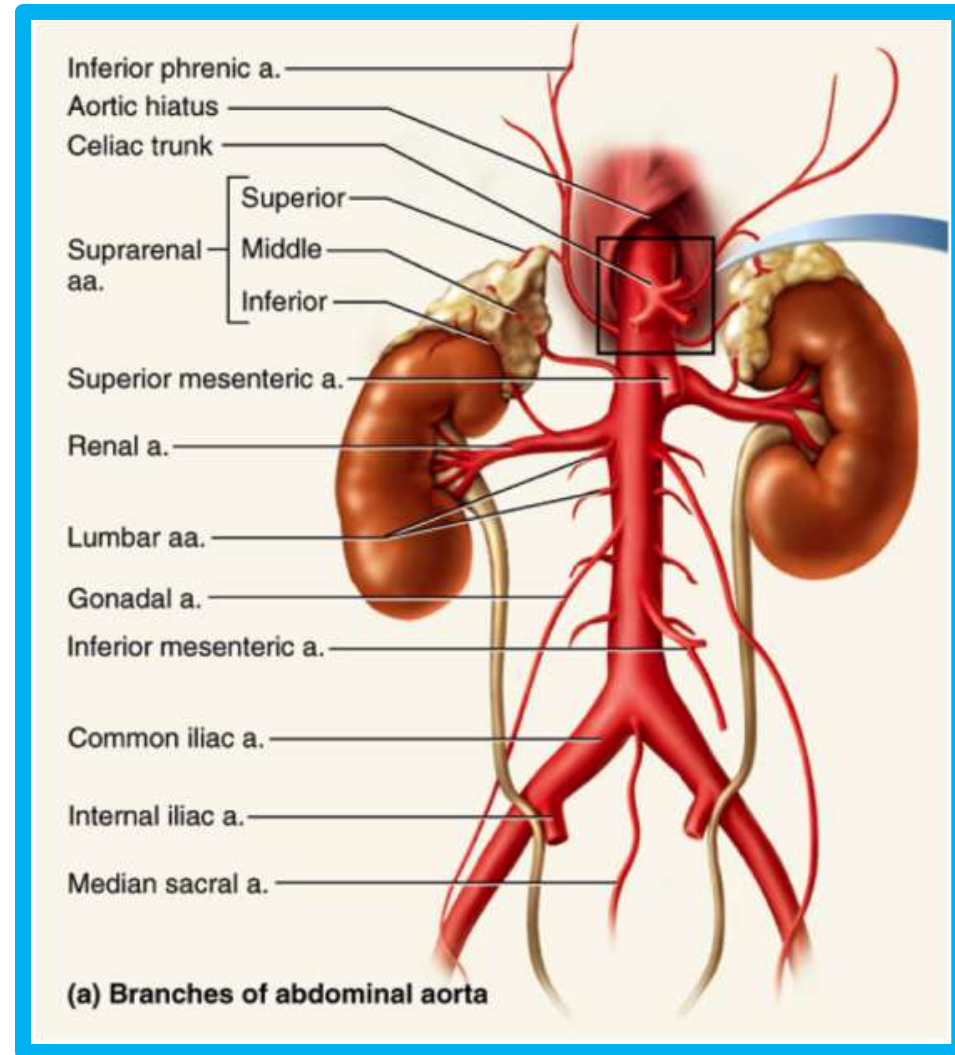
- ✓ Is a **cordlike structure** that can be palpated between finger and thumb in the upper part of the scrotum.
- ✓ It is a **thick-walled muscular duct** that **transports spermatozoa from the epididymis to the urethra**



❖ Testicular Artery

❑ A branch of **the abdominal aorta** (at the level of the **second lumbar vertebra**), **the testicular artery** is long and slender and descends on the posterior abdominal wall.

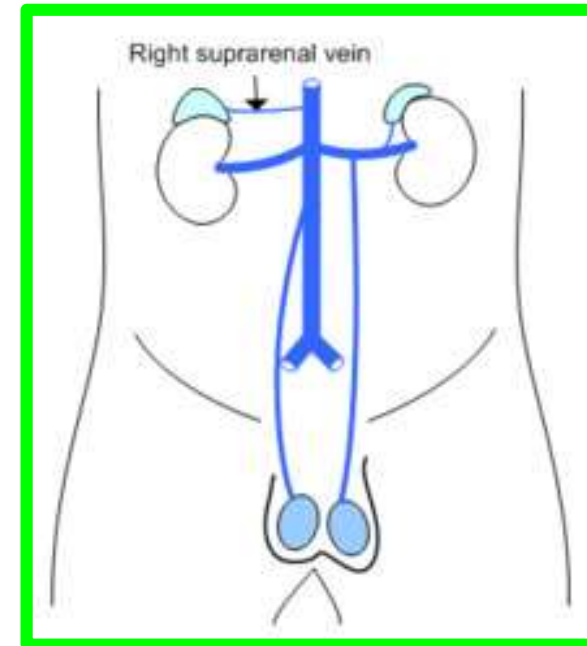
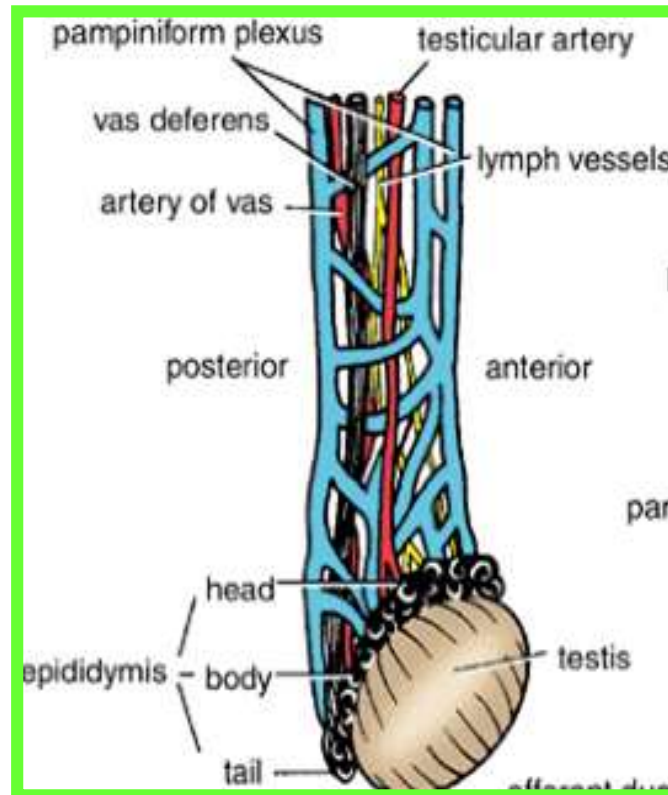
❑ It traverses the inguinal canal and supplies the testis and the epididymis



❖ Testicular Veins

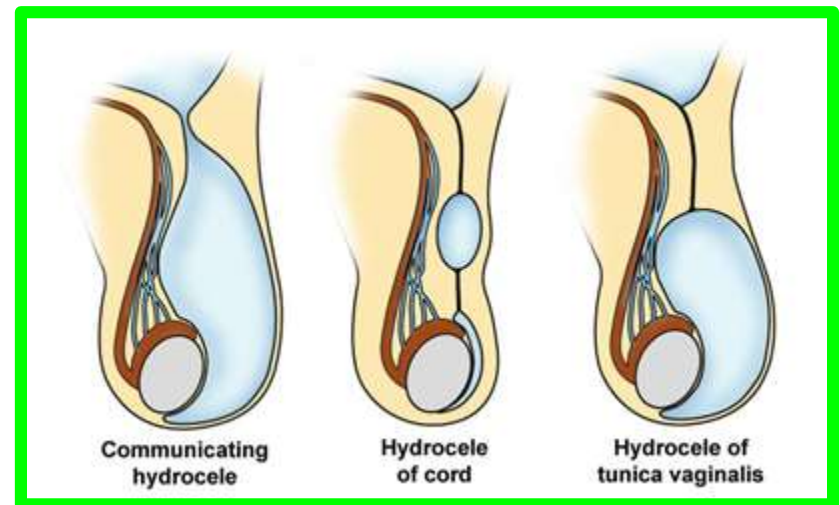
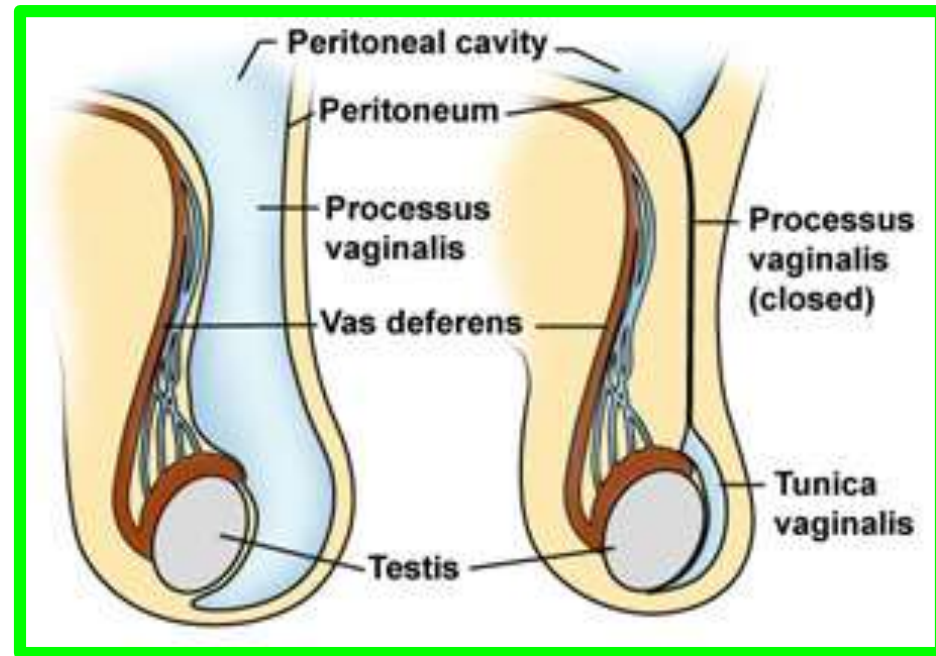
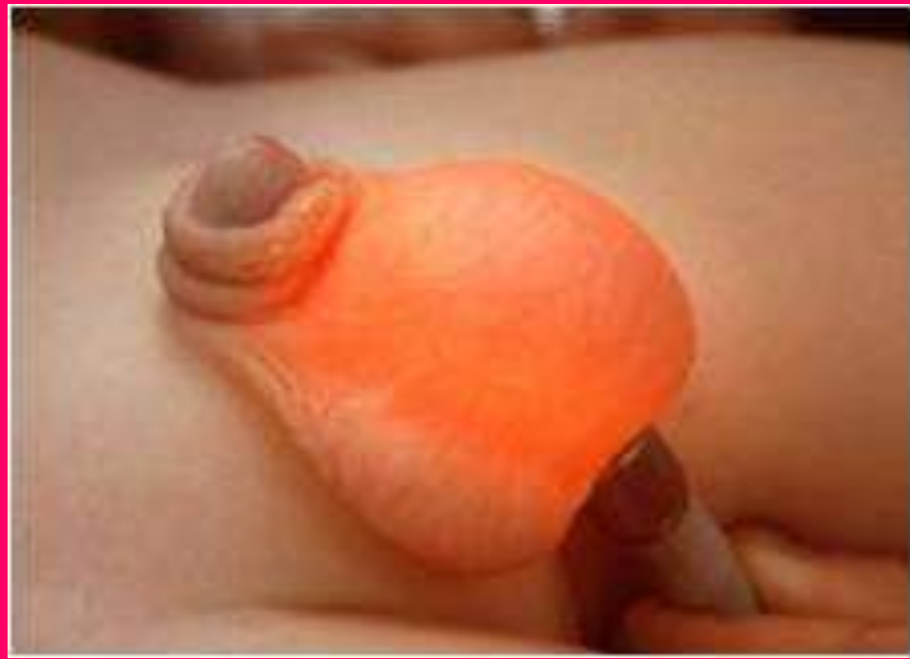❑ An extensive venous plexus, the **pampiniform plexus**, leaves the posterior border of the testis as the plexus ascends, it becomes reduced in size so that at about the level of the deep inguinal ring, a **single testicular vein** is formed.

❑ This runs up on the posterior abdominal wall and drains into the **left renal vein** on the left side and into the **inferior vena cava** on the right side



❖ *Processus Vaginalis*

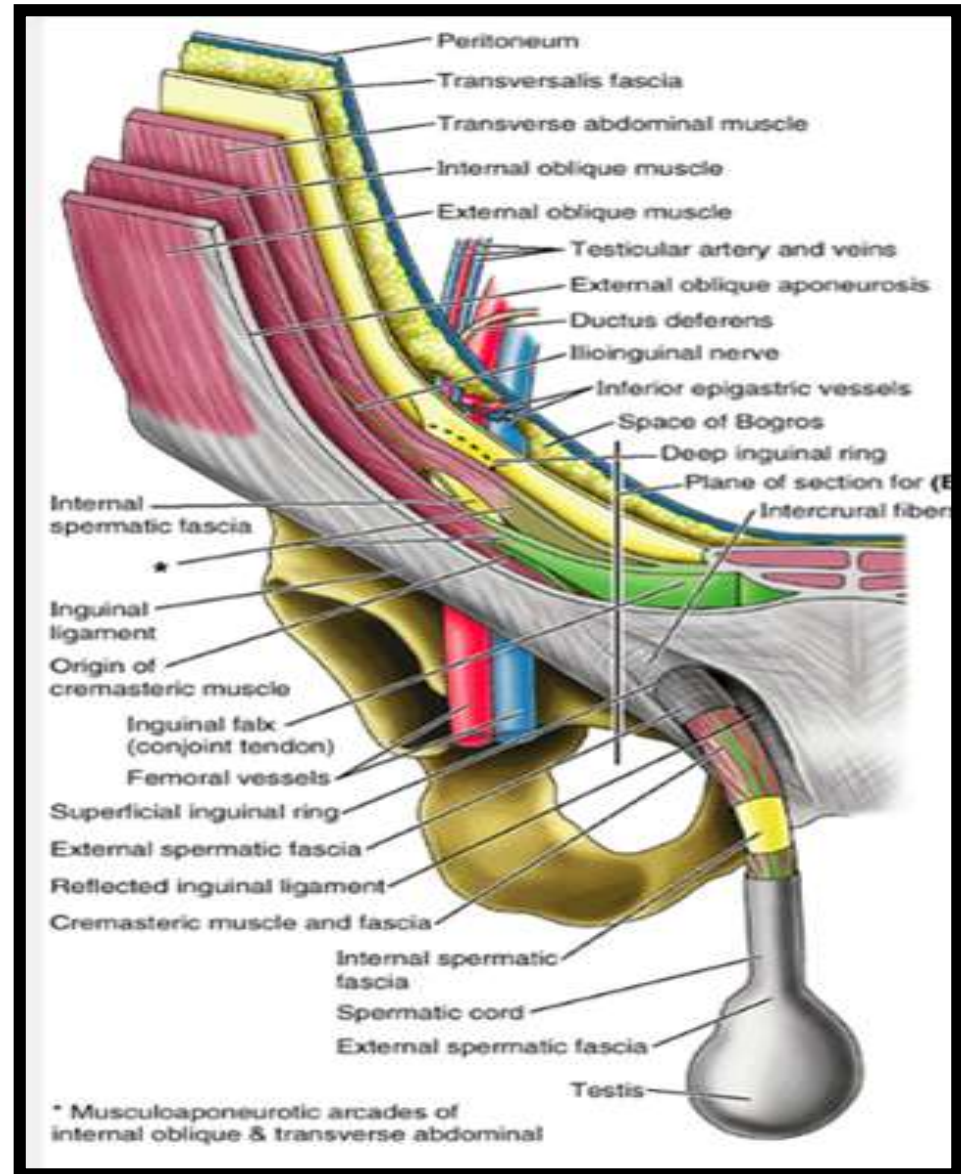
The remains of the *processus Vaginalis* are present within the cord



Hydrocele of Spermatic Cord and/or Testis ????

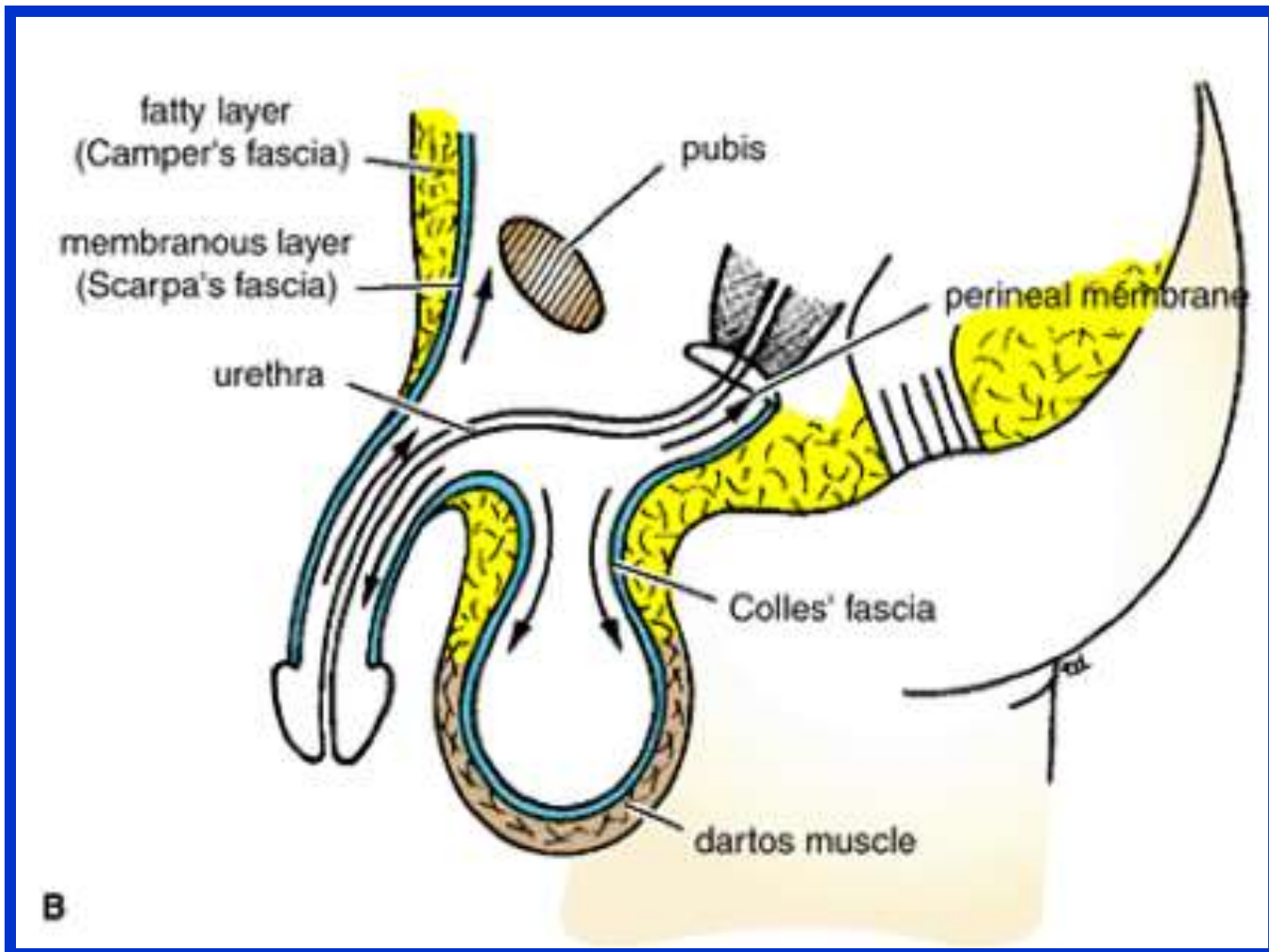
Coverings of the Spermatic Cord (the Spermatic Fasciae)

- ✓ **External spermatic fascia** derived from the external oblique aponeurosis and attached to the margins of the **superficial inguinal ring**
- ✓ **Cremasteric fascia** derived from **the internal oblique muscle**
- ✓ **Internal spermatic fascia** derived from **the fascia transversalis** and attached to the margins of the **deep inguinal ring**



Scrotum

The scrotum is an outpouching of the lower part of the anterior abdominal wall and contains the **testes**, the **epididymides**, and the **lower ends of the spermatic cords**.



Scrotum

The wall of the scrotum has the following layers:

❖ **Skin**

❖ **Superficial fascia;**

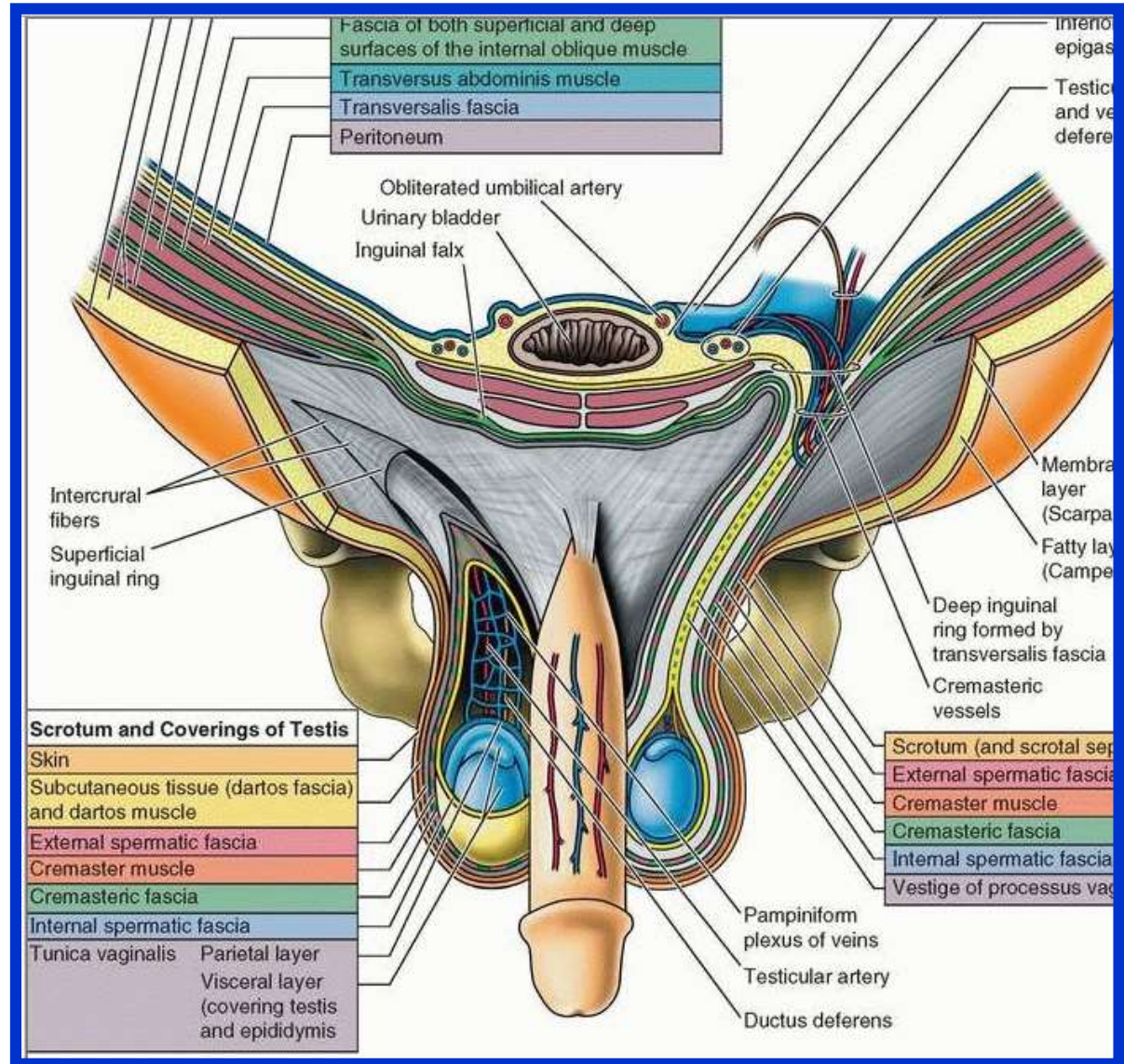
✓ The **dartos muscle**, replaces the **fatty (camper fascia)**, and
✓ The **membranous layer (Scarpa's fascia)** is now called **Colles' fascia**.

❖ **External spermatic fascia** derived from

the **external oblique**

❖ **Cremasteric fascia**

derived from the **internal oblique**

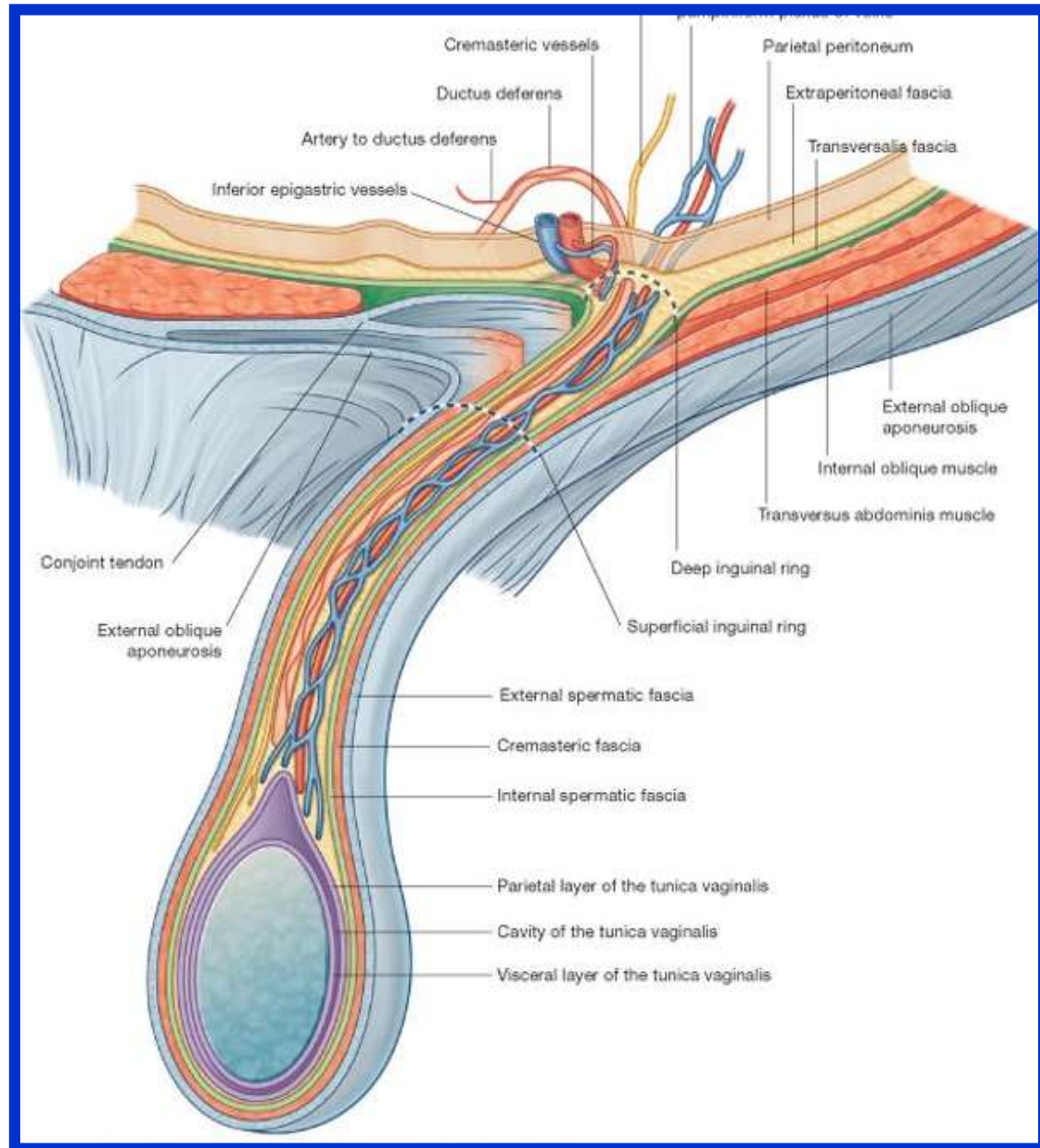


Scrotum

The wall of the scrotum:

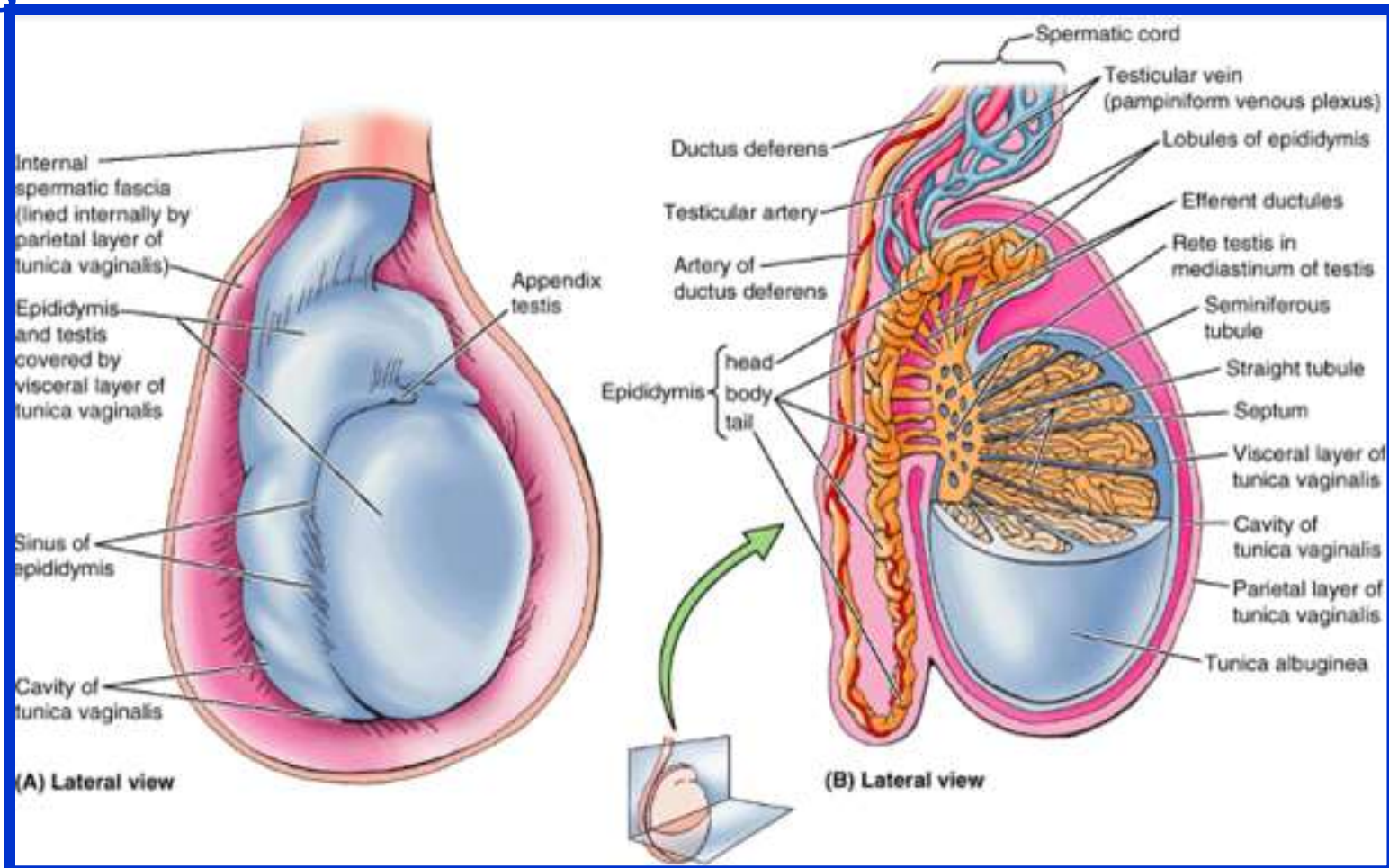
❖ **Internal spermatic fascia** derived from the **fascia transversalis**

❖ **Tunica vaginalis**, which is a **closed sac** that covers the anterior, medial, and lateral surfaces of each testis



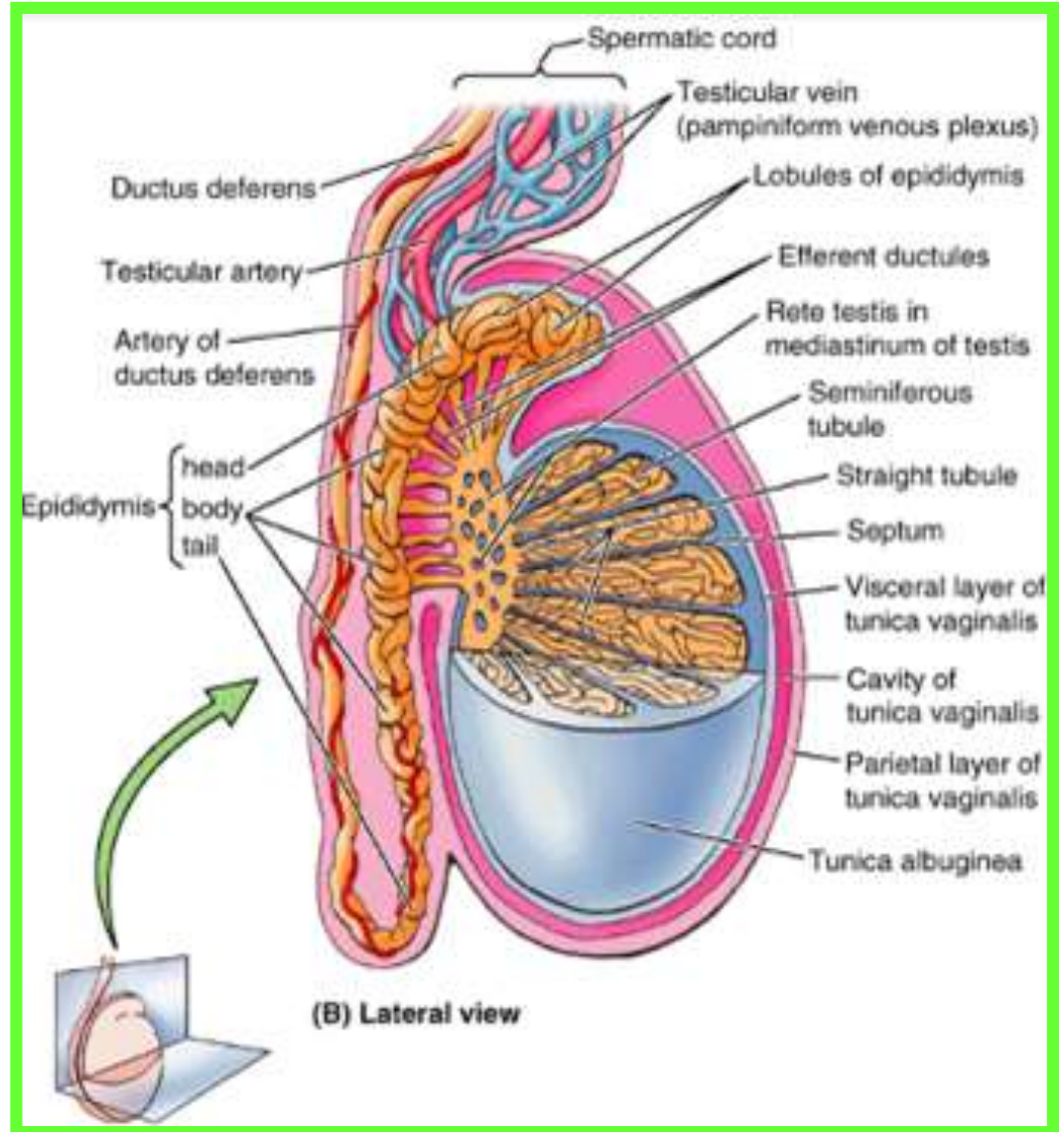
Testis

- The testis is a **firm, mobile organ** lying within the **scrotum**.
- The **left testis usually lies at a lower level than the right**.
- Each testis is surrounded by a **tough fibrous capsule, the tunica albuginea**



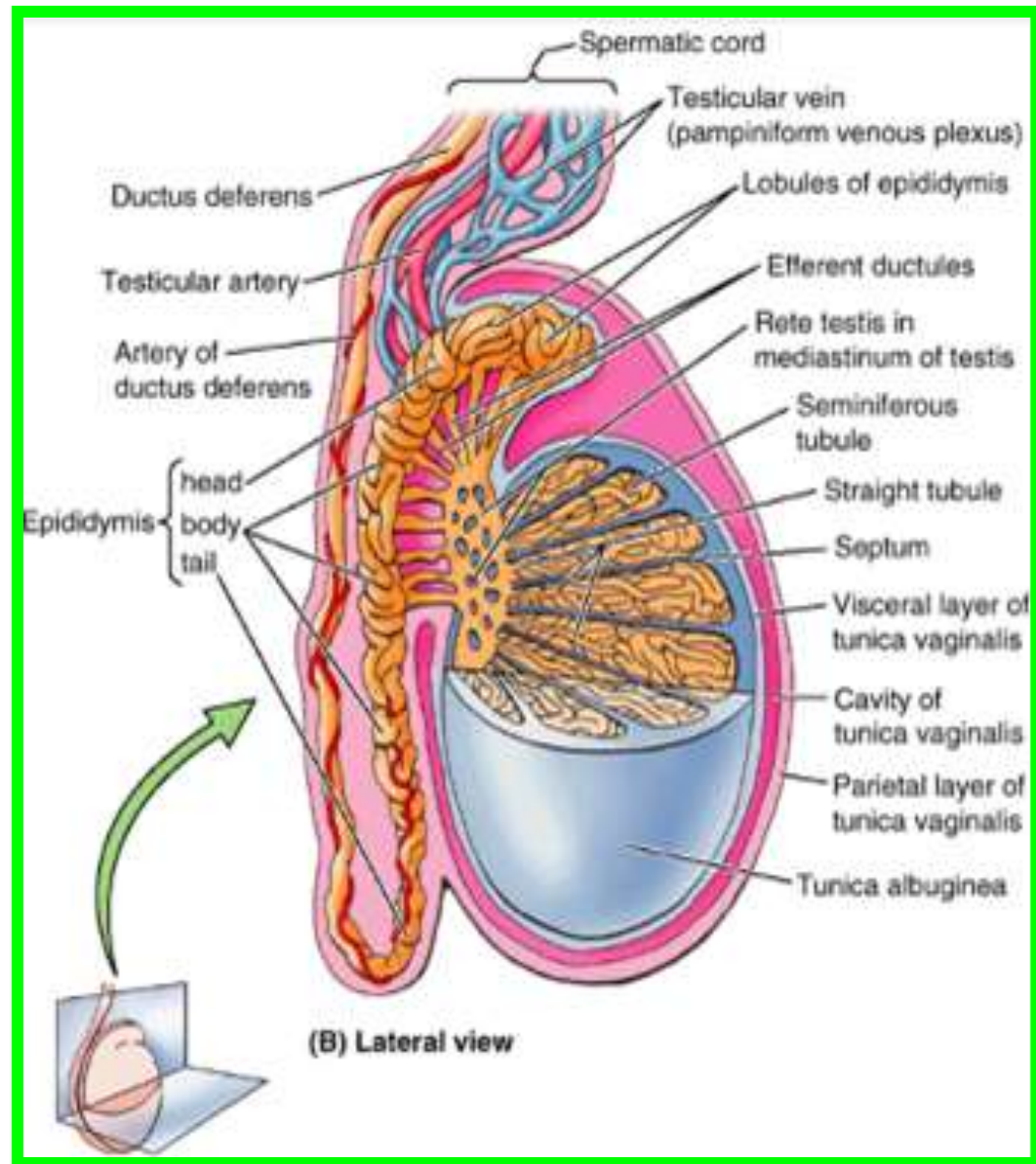
Testis

- ✓ Extending from the inner surface of the capsule is a series of fibrous septa that divide the interior of the organ into **lobules**.
- ✓ Lying within each lobule are one to three coiled **seminiferous tubules**.
- ✓ The tubules open into a network of channels called the **rete testis**.
- ✓ Small **efferent ductules** connect the rete testis to the upper end of the **epididymis**



Epididymis

- ❑ The epididymis is a firm structure lying posterior to the testis, with the vas deferens lying on its medial side.
- ❑ It has an expanded upper end, **the head**, a **body**, and a pointed **tail** inferiorly.
- ❑ Laterally, a distinct groove lies between the testis and the epididymis, which is lined with the inner visceral layer of the tunica vaginalis and is called the **sinus of the epididymis**.

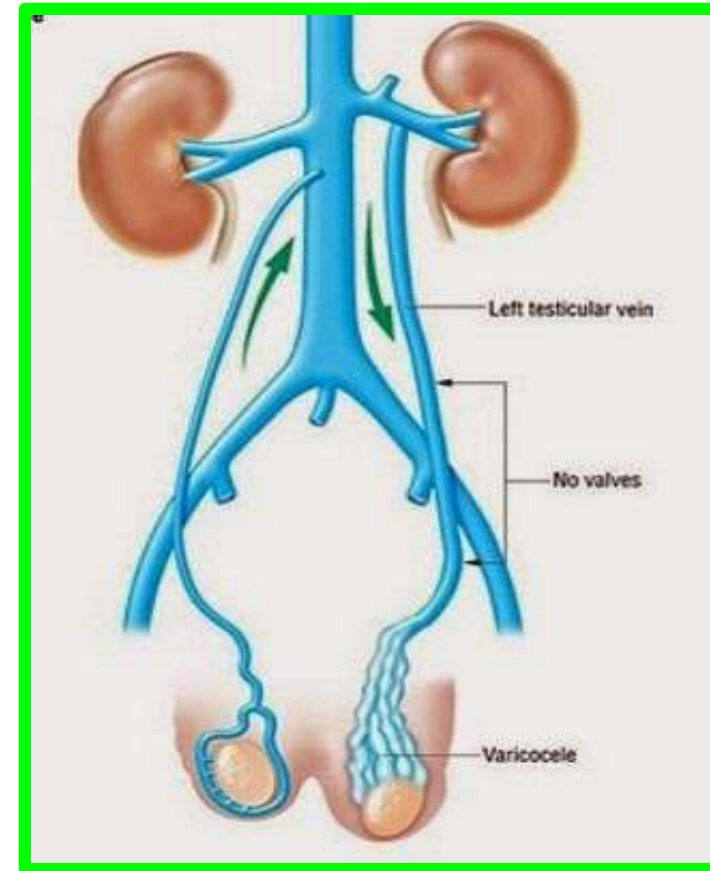
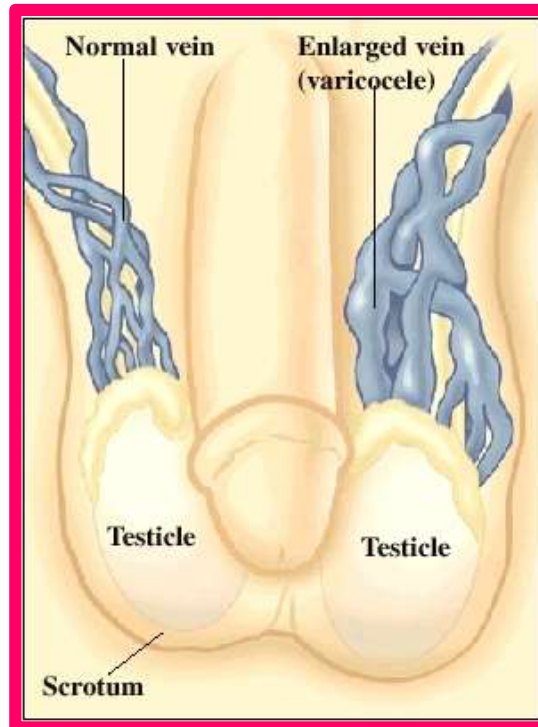


Blood Supply of the Testis and Epididymis

- ✓ The **testicular artery** is a branch of the **abdominal aorta**.
- ✓ The **testicular veins** emerge from the testis and the epididymis as a venous network, the **pampiniform plexus**.

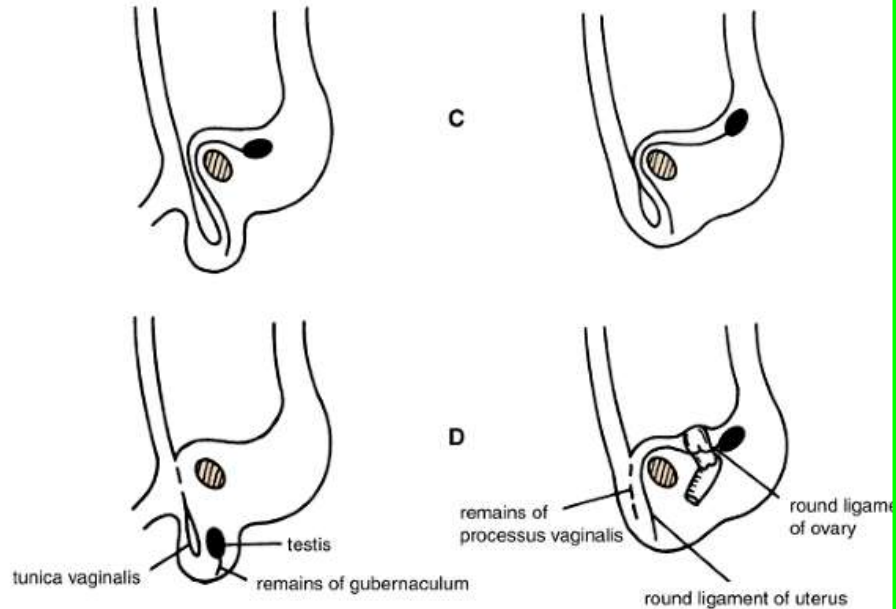
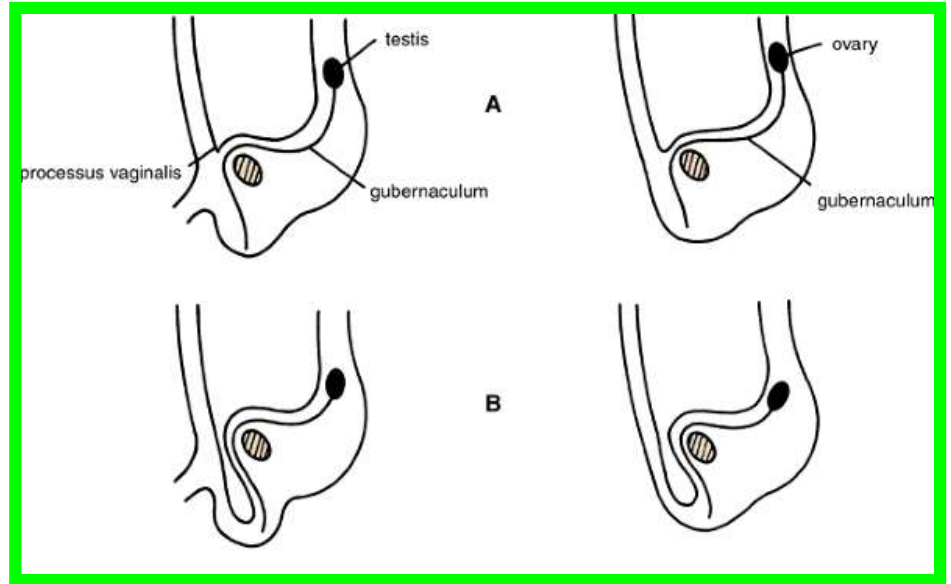
✓ This becomes reduced to a **single vein** as it ascends through the **inguinal canal**.

✓ The **right testicular vein** drains into the **inferior vena cava**, and the **left vein** joins the **left renal vein**.



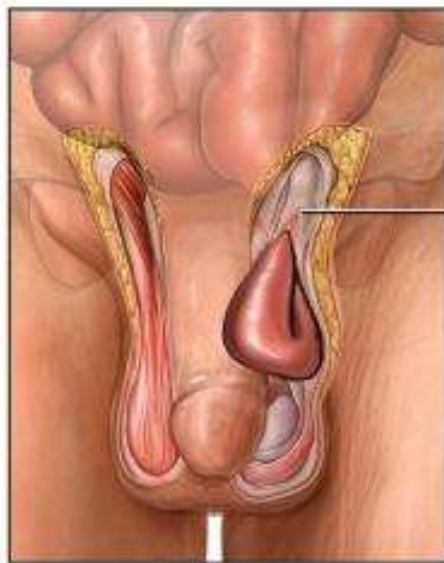
Varicocele ????

Formation of the inguinal canals and descent of testes



❑ A hernia is the protrusion of part of the abdominal contents beyond the normal confines of the abdominal wall.

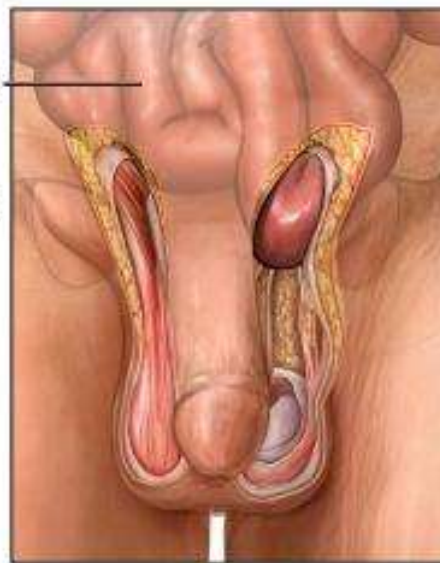
- ❖ **Indirect Inguinal Hernia** : The sac enters the inguinal canal through the deep inguinal ring lateral to **the inferior epigastric vessels**. (the most common 85%)
- ❖ **Direct Inguinal Hernia** : The sac of a direct hernia bulges directly anteriorly through the posterior wall of the inguinal canal medial to **the inferior epigastric vessels** (about 15%)



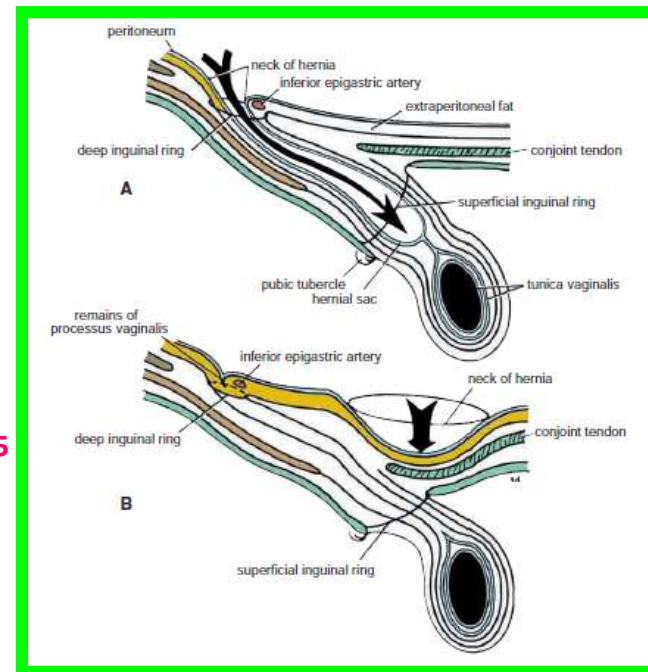
Indirect inguinal hernia

Small intestine

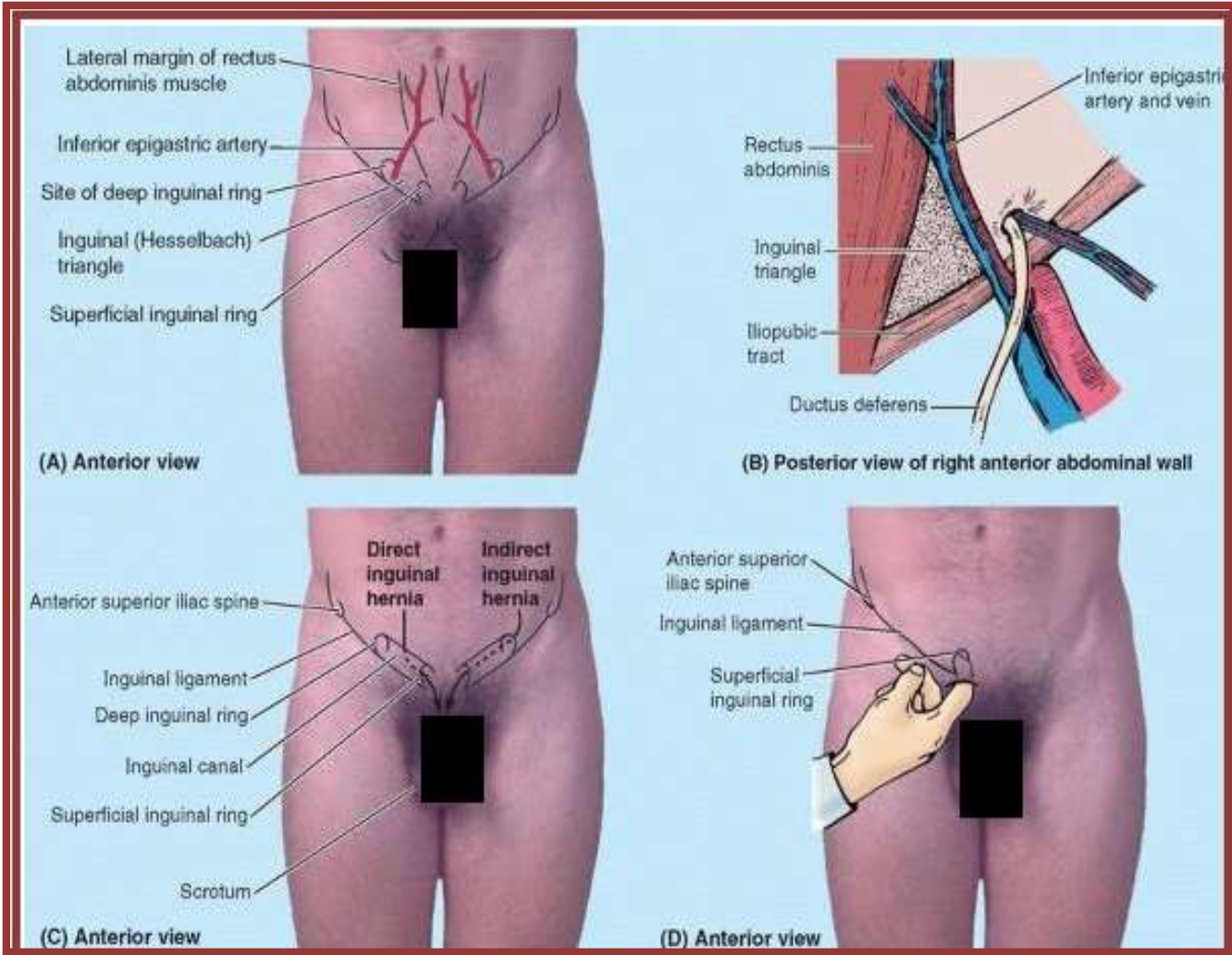
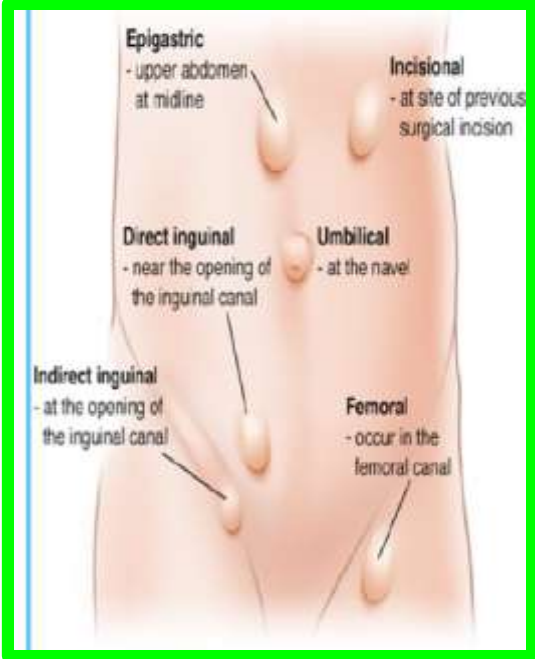
Inguinal canal



Direct inguinal hernia



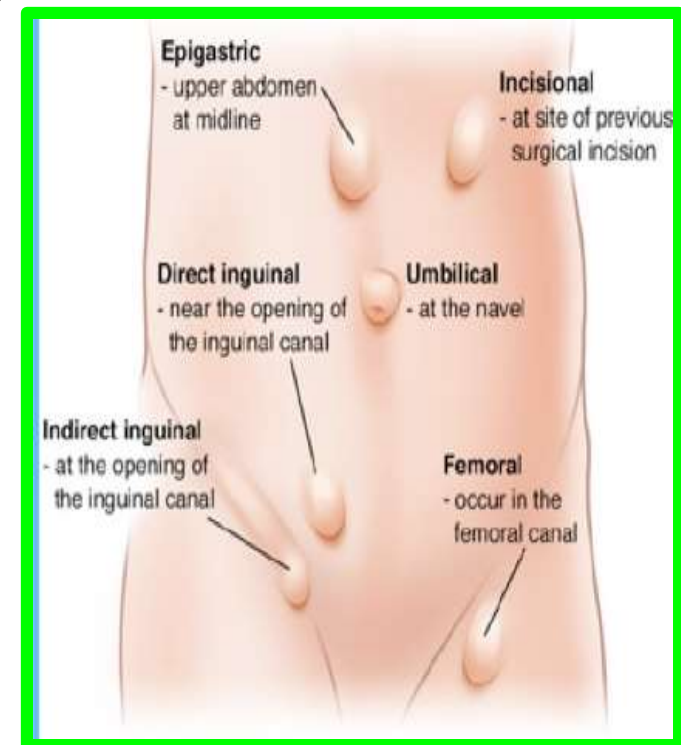
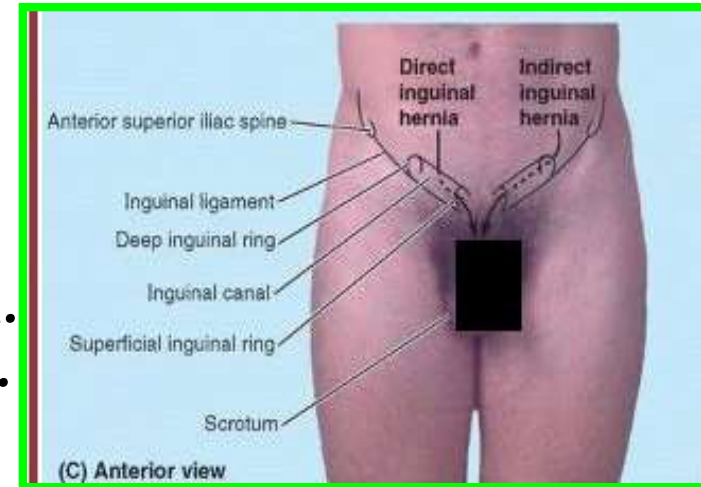
25



The inguinal hernia form about 75% of all abdominal wall hernias(Femoral, Umbilical, Incisional ,Epigastric... etc.)

Indirect Inguinal Hernia

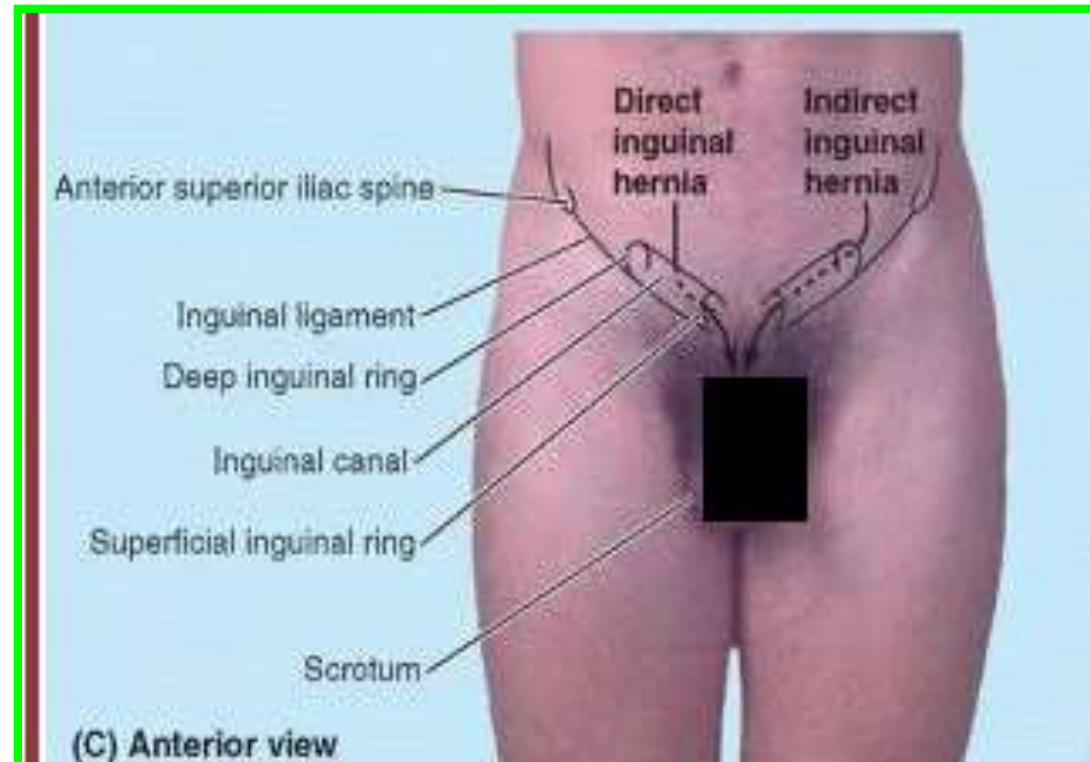
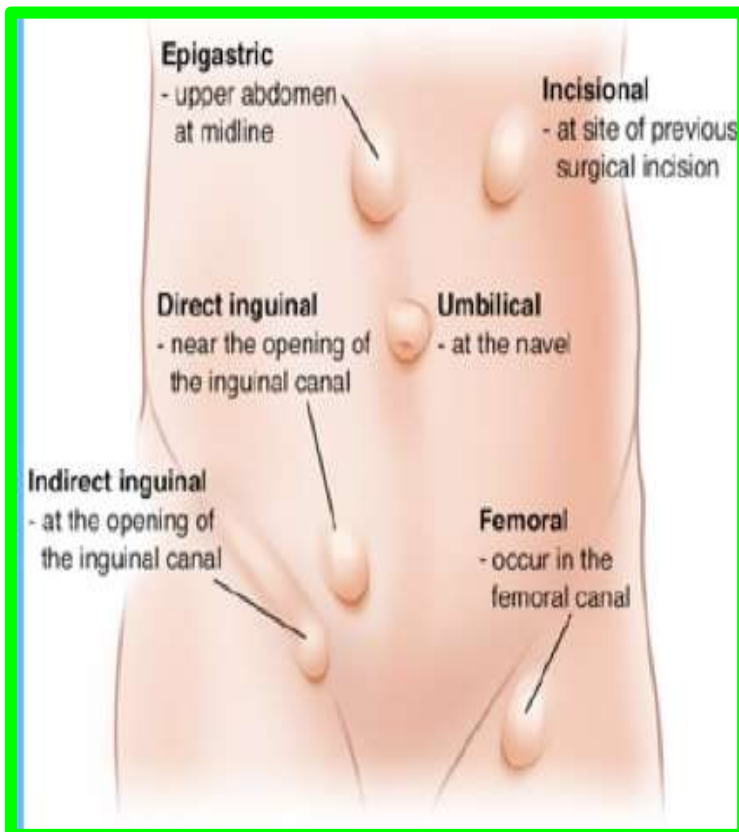
- ■ It is the remains of **the processus vaginalis** and therefore is congenital in origin.
- ■ It is more common than a direct inguinal hernia.
- ■ It is much more common in males than females.
- ■ It is more common on the right side.
- ■ It is most common in children and young adults.
- ■ The hernial sac enters the inguinal canal through the deep inguinal ring and lateral to the inferior epigastric vessels. The neck of the sac is narrow.
- ■ The hernial sac may extend through the **superficial inguinal ring** above and medial to the pubic tubercle. (**Femoral hernia** is located below and lateral to the pubic tubercle)
- ■ The hernial sac may extend down into the **scrotum or labium majus**

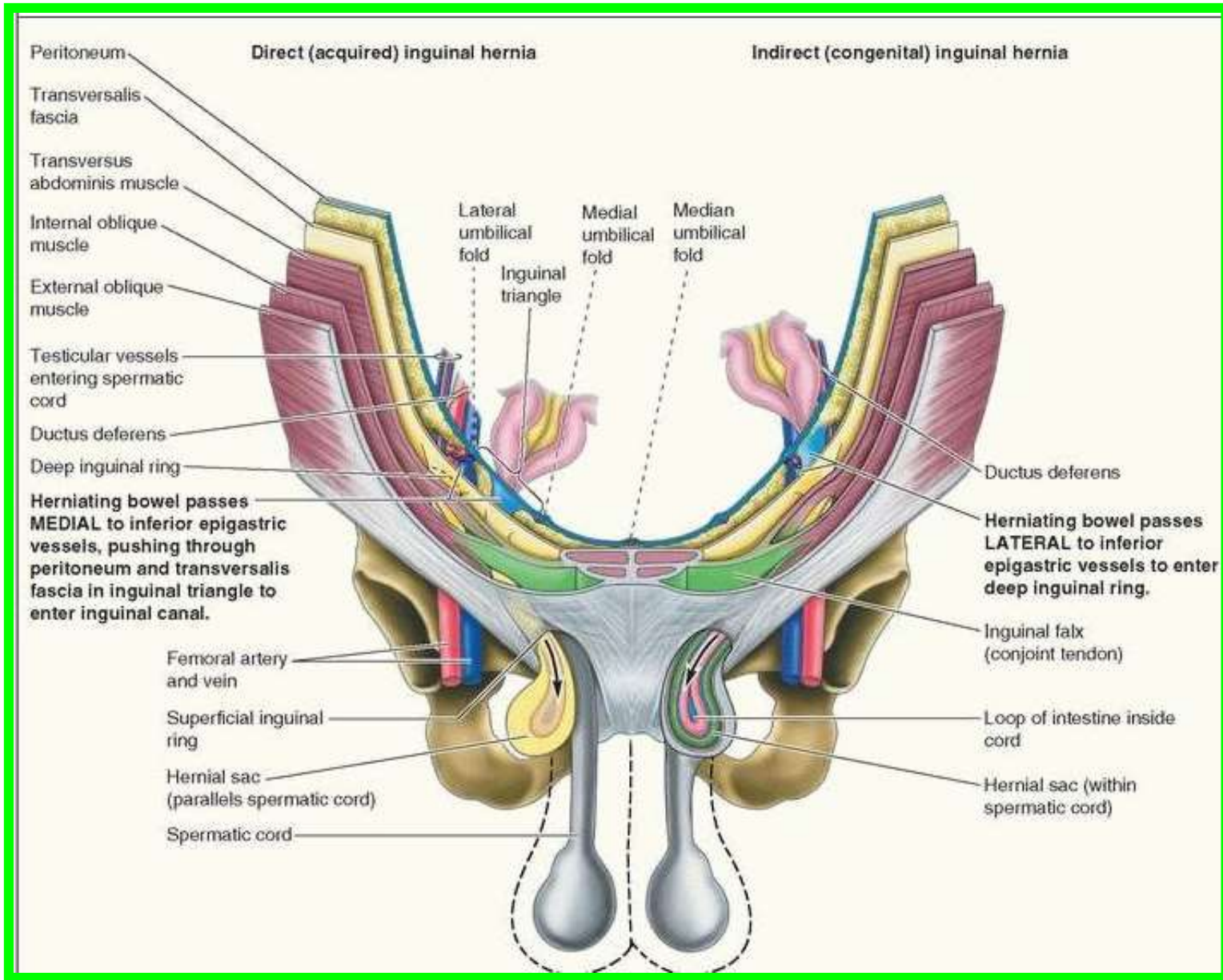


Direct Inguinal Hernia

A direct inguinal hernia can be summarized as follows:

- It is common in old men with weak abdominal muscles and is rare in women.
- The hernial sac bulges forward through the posterior wall of the inguinal canal medial to the inferior epigastric vessels.
- The neck of the hernial sac is wide.





A scenic view of a pine forest with a body of water in the background under a cloudy sky. The foreground is a grassy field with some small bushes. The trees are dense and green, with some taller, thinner trees in the distance. The water is visible on the right side, and the sky is overcast.

Dr. Aiman Qais Afar
Thursday 17 March 2022