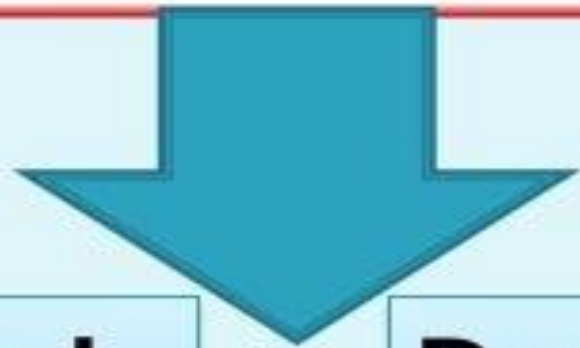

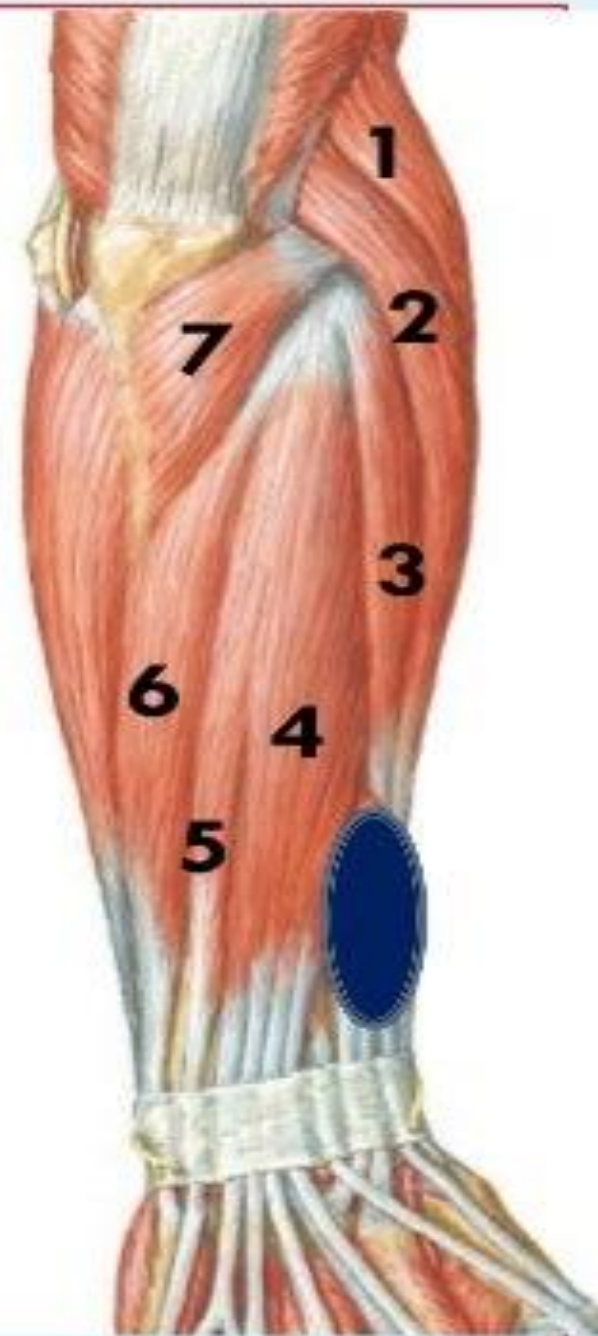
Muscles of back of forearm



Superficial group (7)

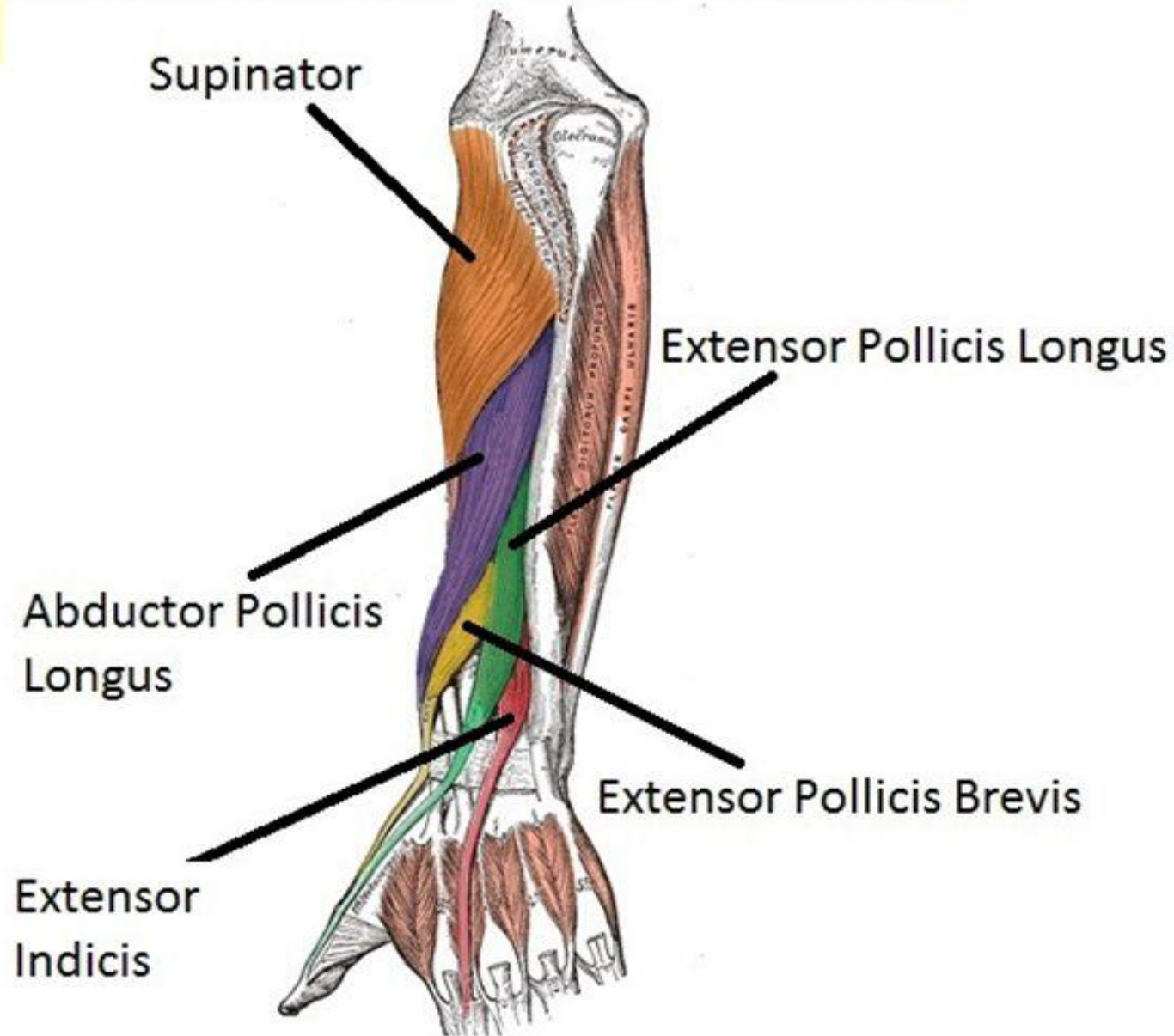
Deep group (5)

1. Brachioradialis
2. Extensor carpi radialis longus
3. Extensor carpi radialis brevis
4. Extensor digitorum
5. Extensor digiti minimi
6. Extensor carpi ulnaris
7. anconeus



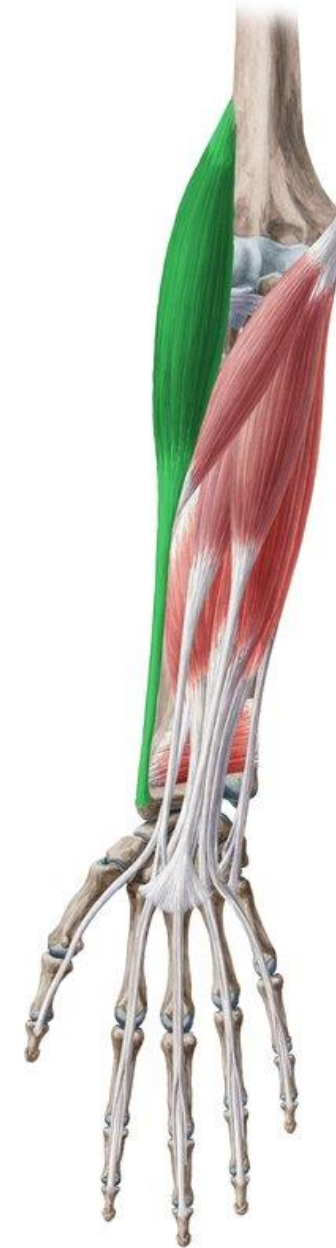Deep Group

- Supinator
- Abductor pollicis longus
- Extensor pollicis brevis
- Extensor pollicis Longus
- Extensor indicis
- Except for the supinator muscle, all these deep layer muscles originate from the posterior surfaces of the radius, ulna, and interosseous membrane and pass into the thumb and fingers.



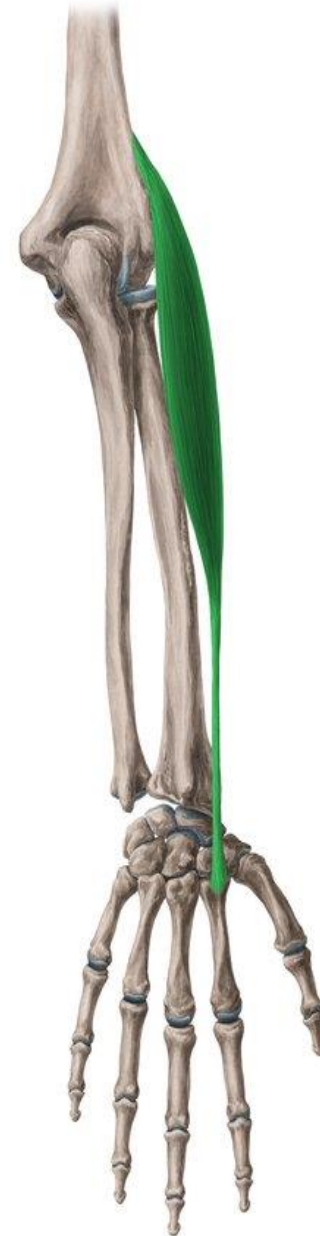1- Brachioradialis

- **Origin:**
- Upper 2/3 of lateral supracondylar ridge of the humerus.
- **Insertion:**
- Base of styloid process of radius.
- **Nerve supply:**
- Radial nerve.
- **Action:**
- Flexion of elbow at midprone position.



2- Extensor carpi radialis longus

- **Origin:**
 - Lower 1/3 of lateral supracondylar ridge of the humerus.
- **Insertion:**
 - Posterior surface of base of 2nd metacarpal bone.
- **Nerve supply:**
 - Radial nerve.
- **Action:**
 - Extension and abduction of wrist.



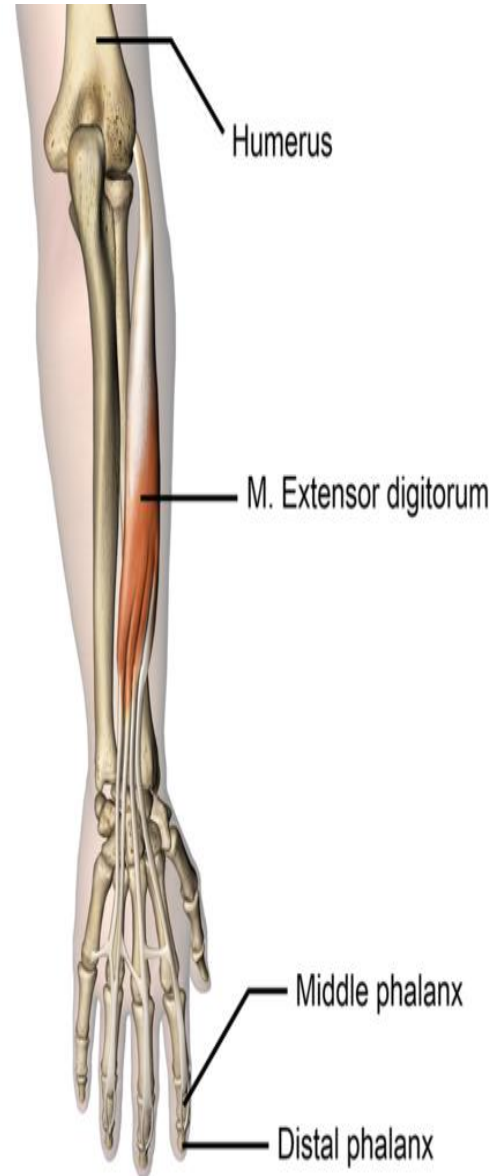3- Extensor carpi radialis brevis

- **Origin:**
- Common extensor origin (**front** of lateral epicondyle of the humerus).
- **Insertion:**
- Posterior surface of base of 3rd metacarpal bone.
- **Nerve supply:**
- Posterior interosseous nerve.
- **Actions:**
- Extension and abduction of wrist.



4- Extensor digitorum

- **Origin:** Common extensor origin.
- **Insertion:**
 - The tendons expands on the posterior surface of proximal phalanges of the medial 4 fingers forming the **extensor expansion**. Each extensor expansion splits into 3 slips: a central slip inserted into the base of the middle phalanx, and 2 lateral slips which are inserted into the base of distal phalanx. The extensor expansion receives also the insertion of the corresponding lumbrical and interossei muscles
- **Nerve supply:** Posterior interosseous nerve.
- **Actions:**
 - Extension of all joints of the medial 4 fingers.
 - It helps in extension of the wrist.



5- Extensor digiti minimi

Origin:

- Common extensor origin.

Insertion:

- Extensor expansion of the little finger.

Nerve supply:

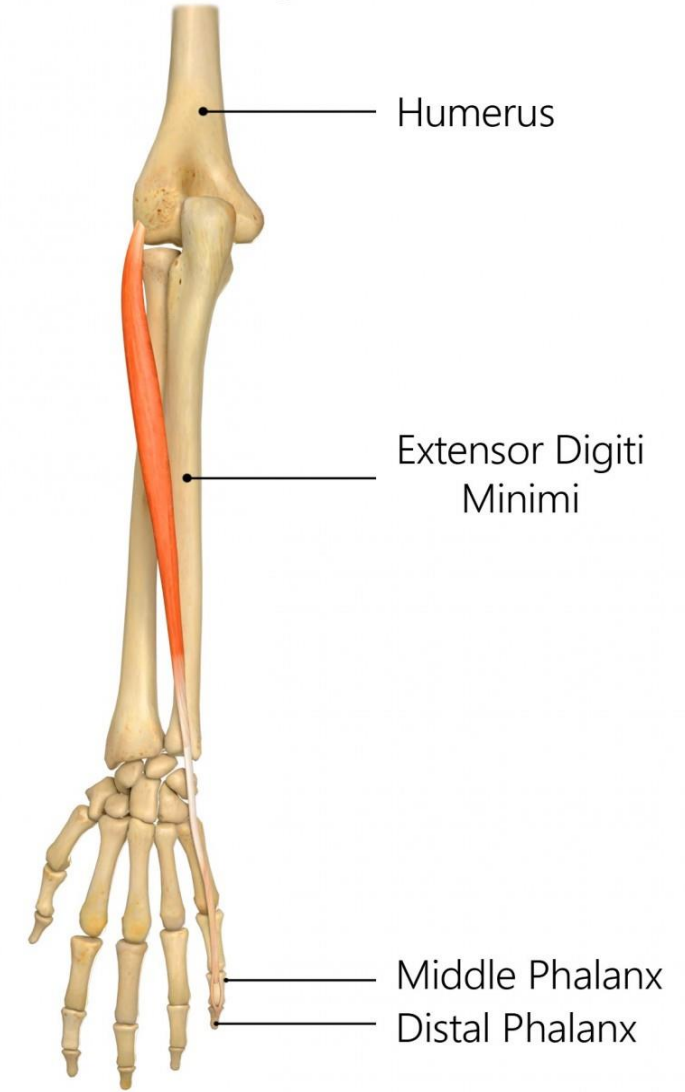
- Posterior interosseous nerve.

Actions:

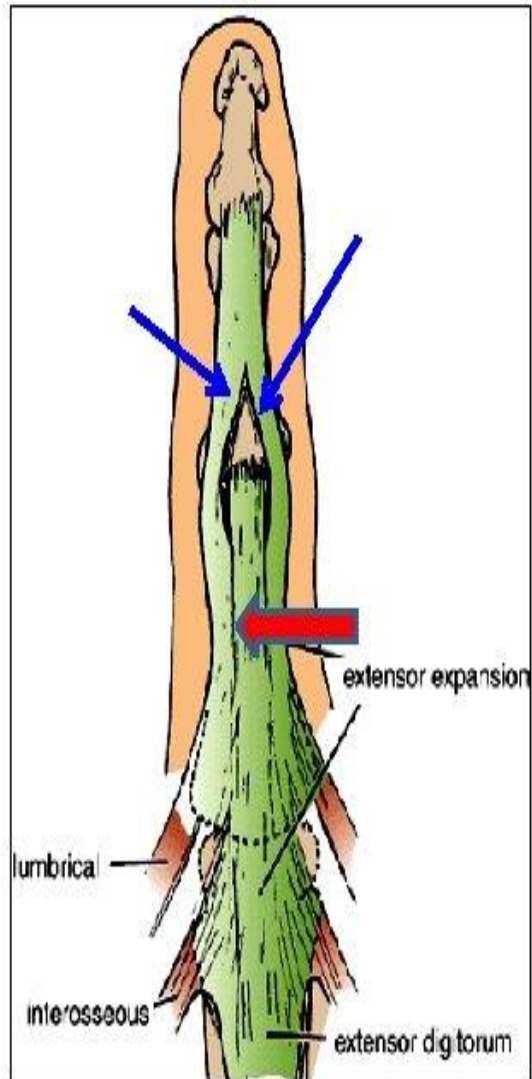
- Extension of all joints of little finger + Extension of wrist.

REHAB
My Patient.com

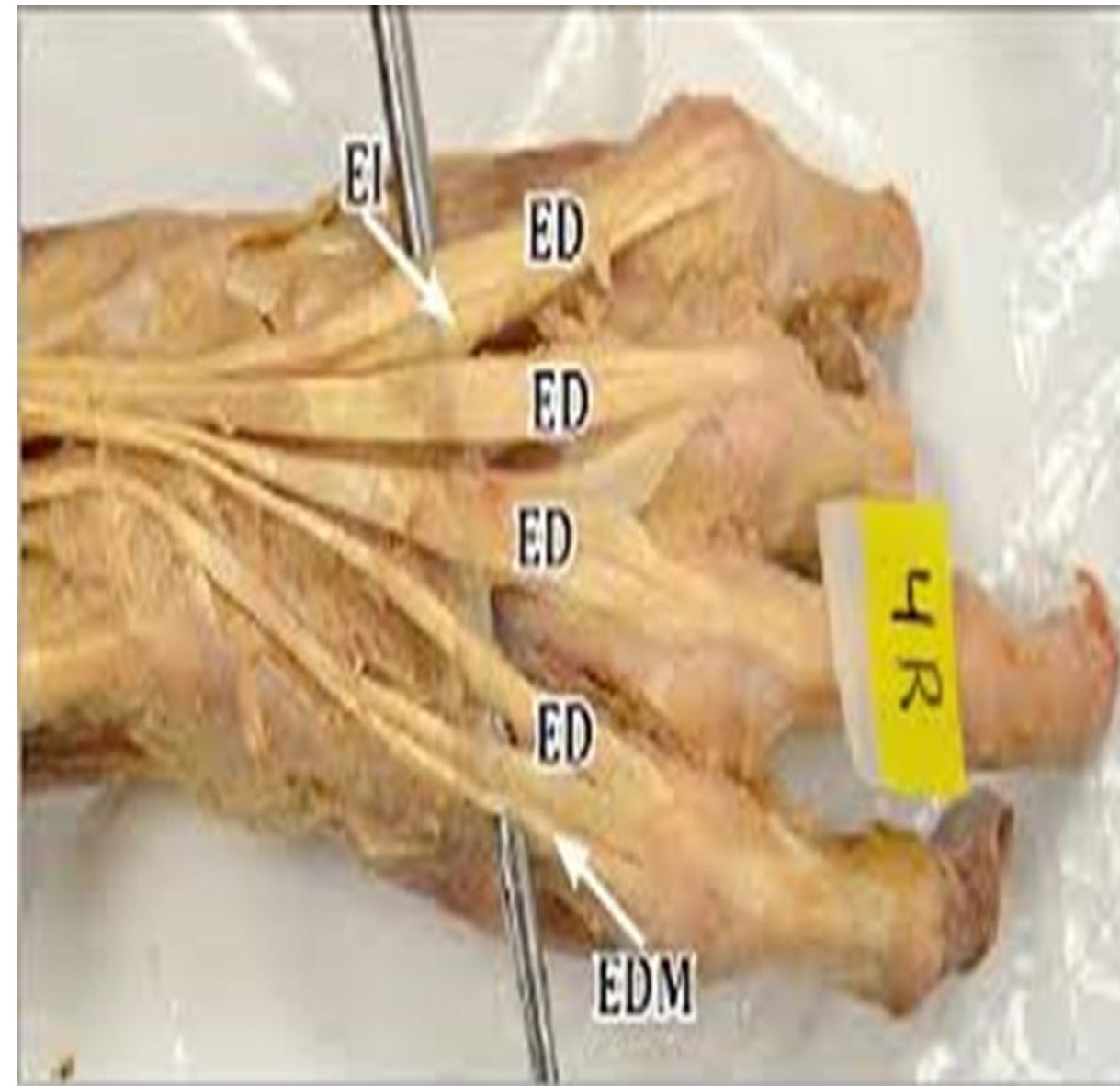
Extensor Digiti Minimi

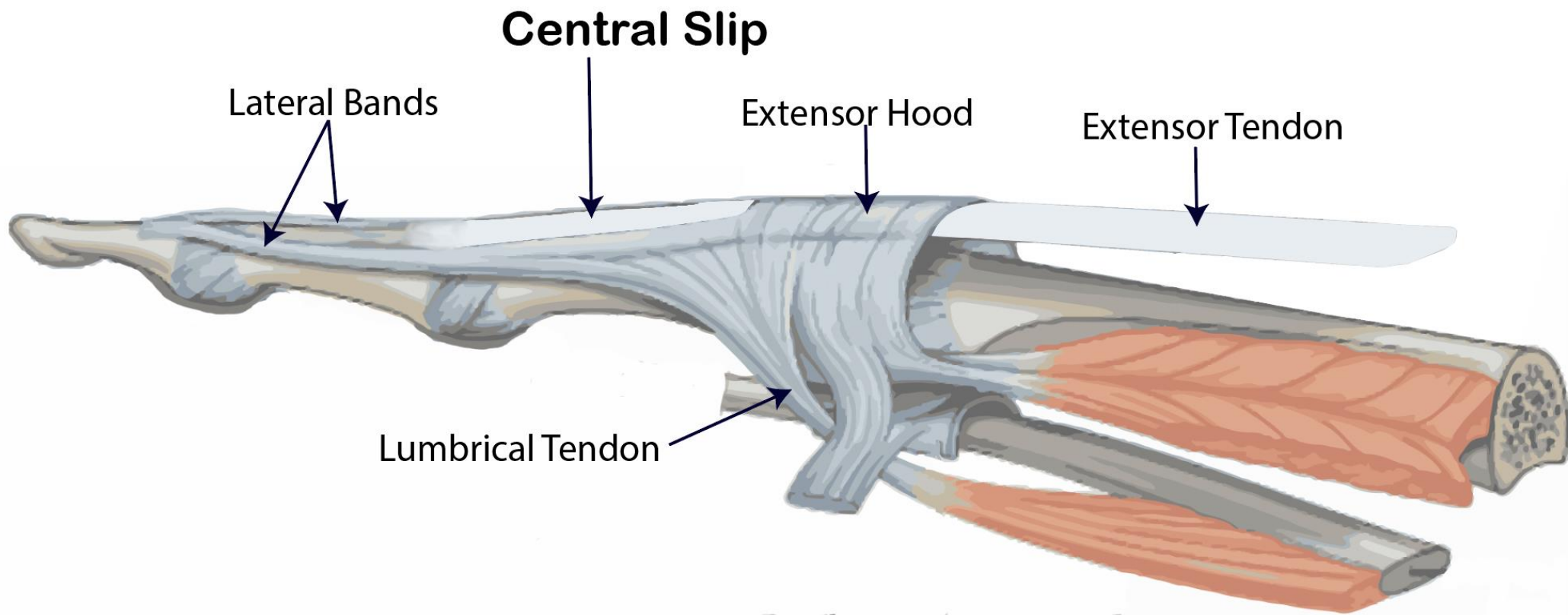


Extensor Expansion



- Formed from the expansion of extensor digitorum tendons
- At the **PIJ**, the expansion splits into **3 parts**
 - **One Central** inserted into the base of Middle phalanx.
 - **Two laterals** inserted into the base of the Distal phalanx.
- The Expansion Receives the insertions of:
 - **Corresponding Interosseous muscle (on each side).**
 - **Lumbrical muscle (on the lateral side).**





6- Extensor carpi ulnaris:

Origin:

- Common extensor origin.
- Posterior border of ulna.

Insertion:

- Posterior surface of the base of 5th metacarpal bone.

Nerve supply:

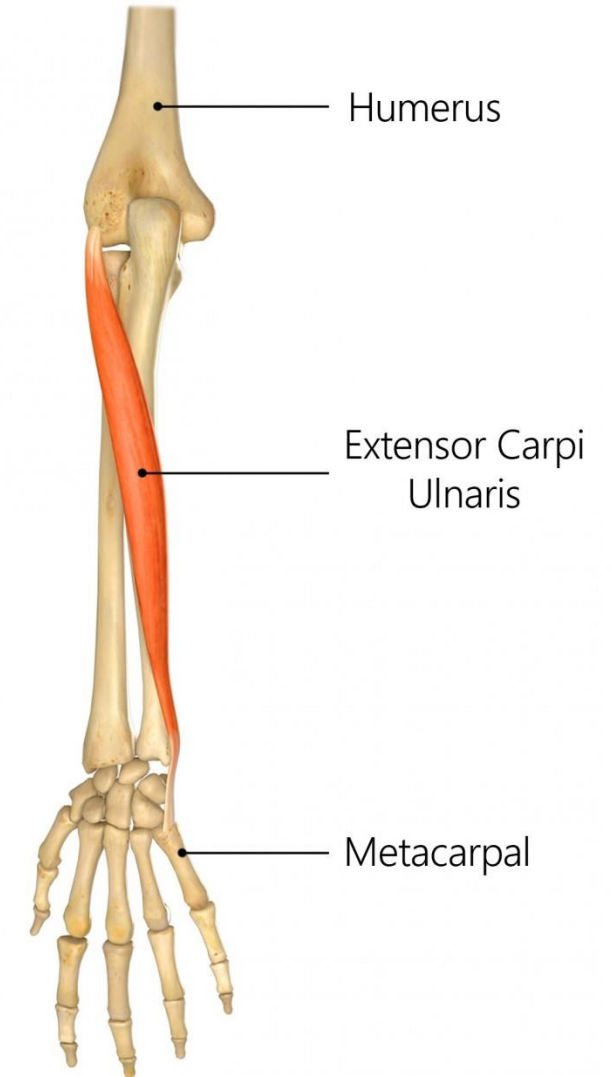
- Posterior interosseous nerve.

Actions:

- Extension and adduction of the wrist.

REHAB
My Patient.com

Extensor Carpi Ulnaris



7- Anconeus

Origin:

- Posterior aspect of lateral epicondyle of humerus.

Insertion:

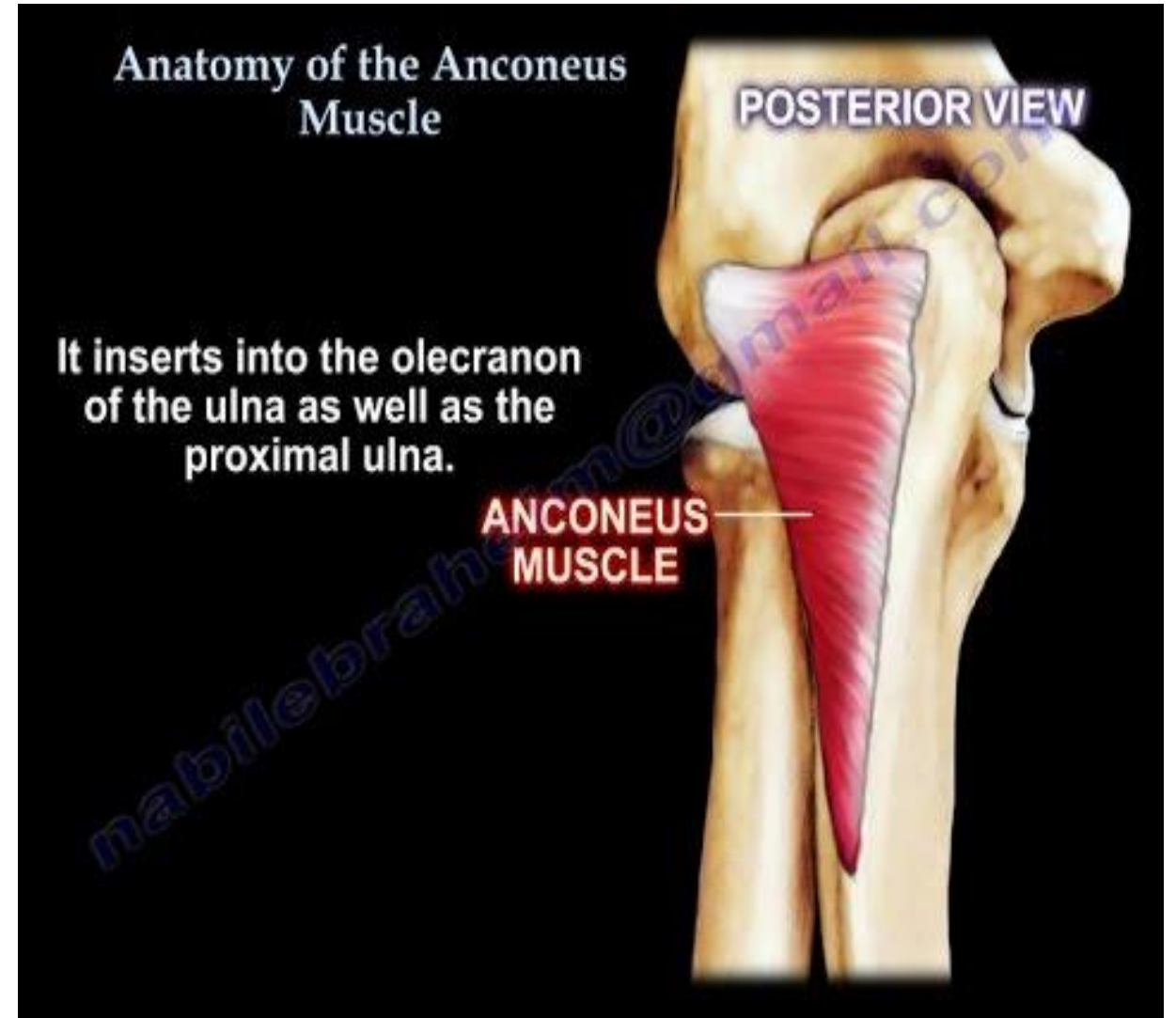
- Lateral surface of olecranon process of ulna

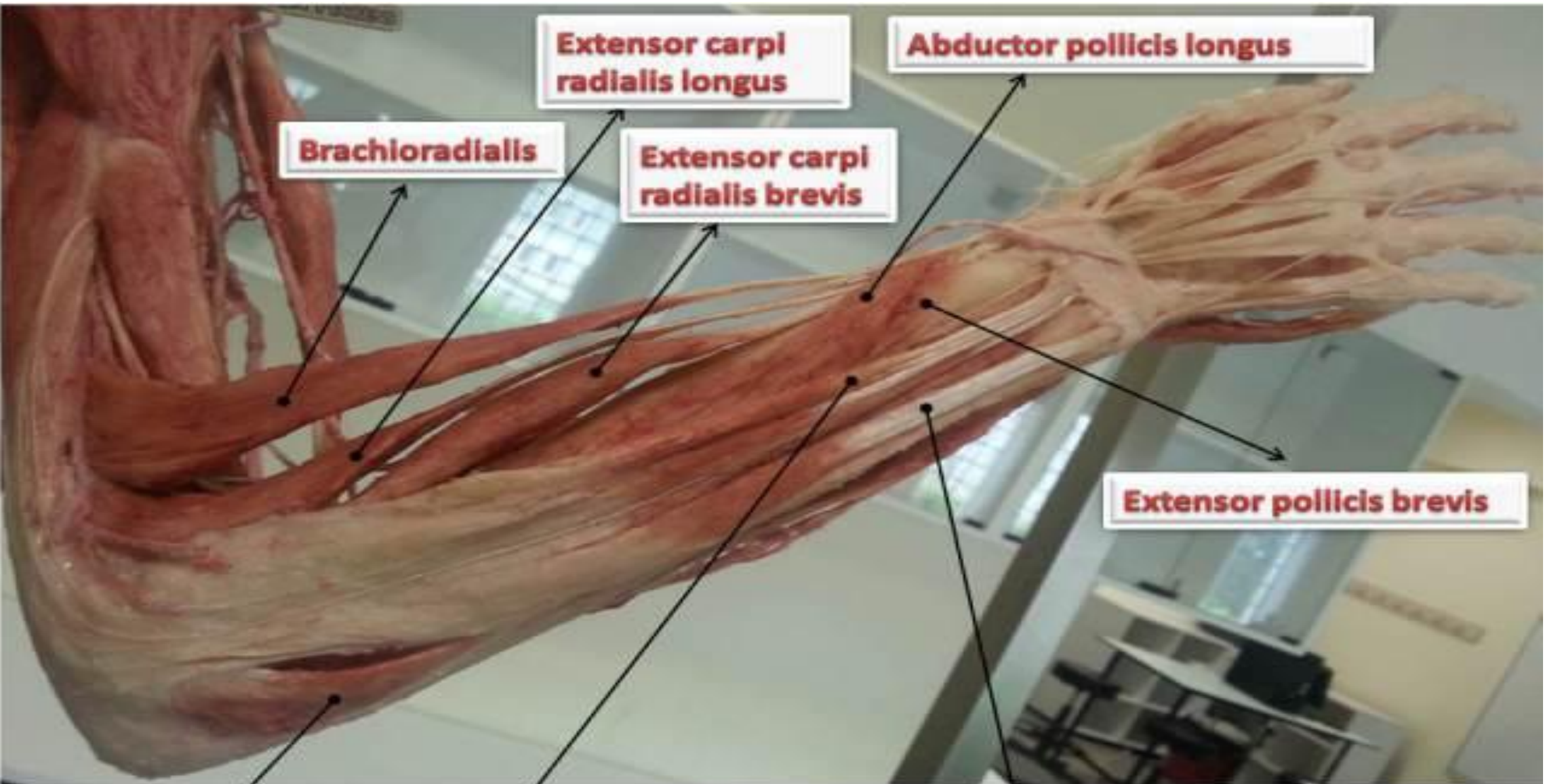
Nerve supply:

- Radial nerve.

Action:

- It helps in extension of elbow.





Extensor carpi radialis longus

Abductor pollicis longus

Brachioradialis

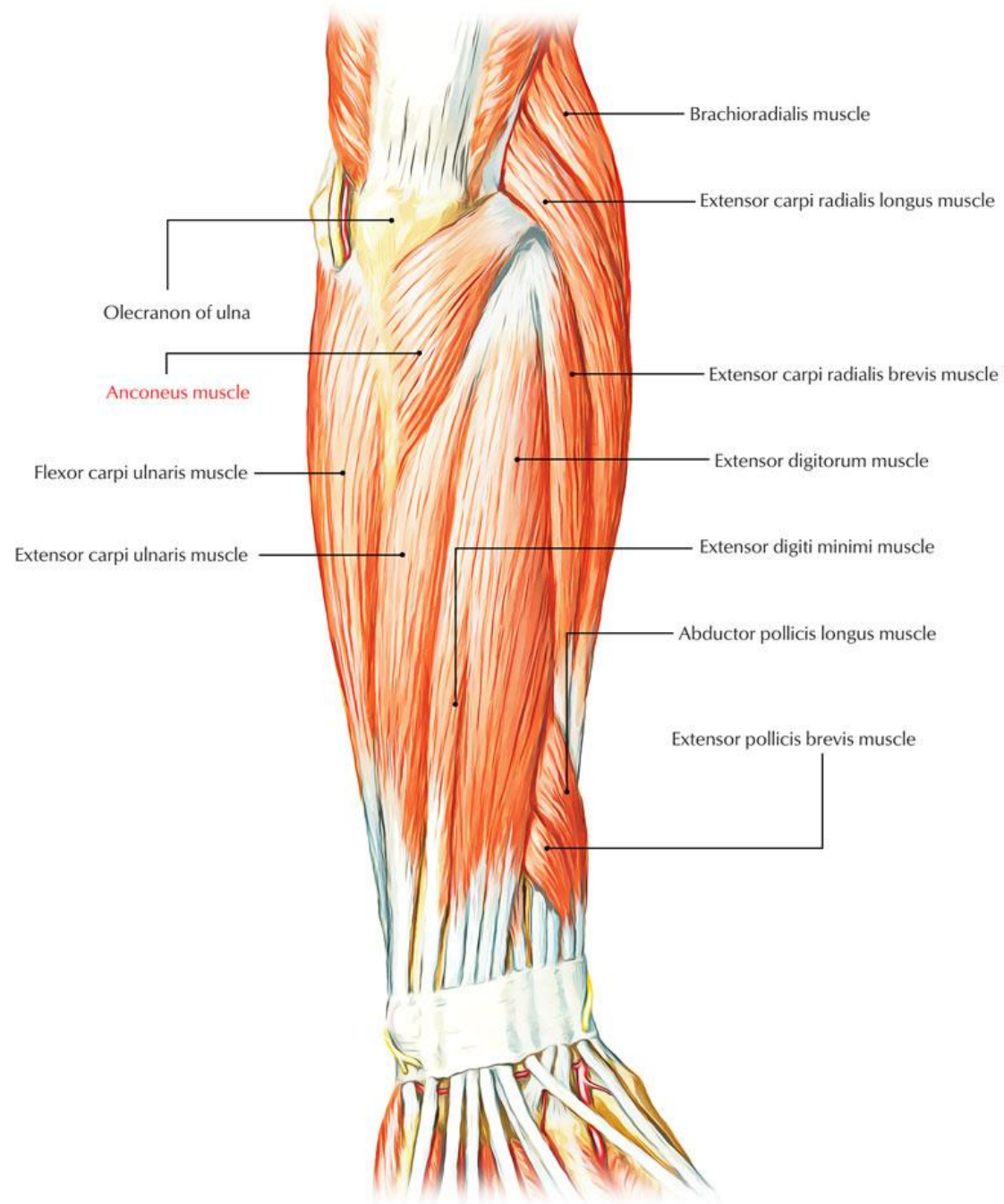
Extensor carpi radialis brevis

Extensor pollicis brevis

Extensor digitorum

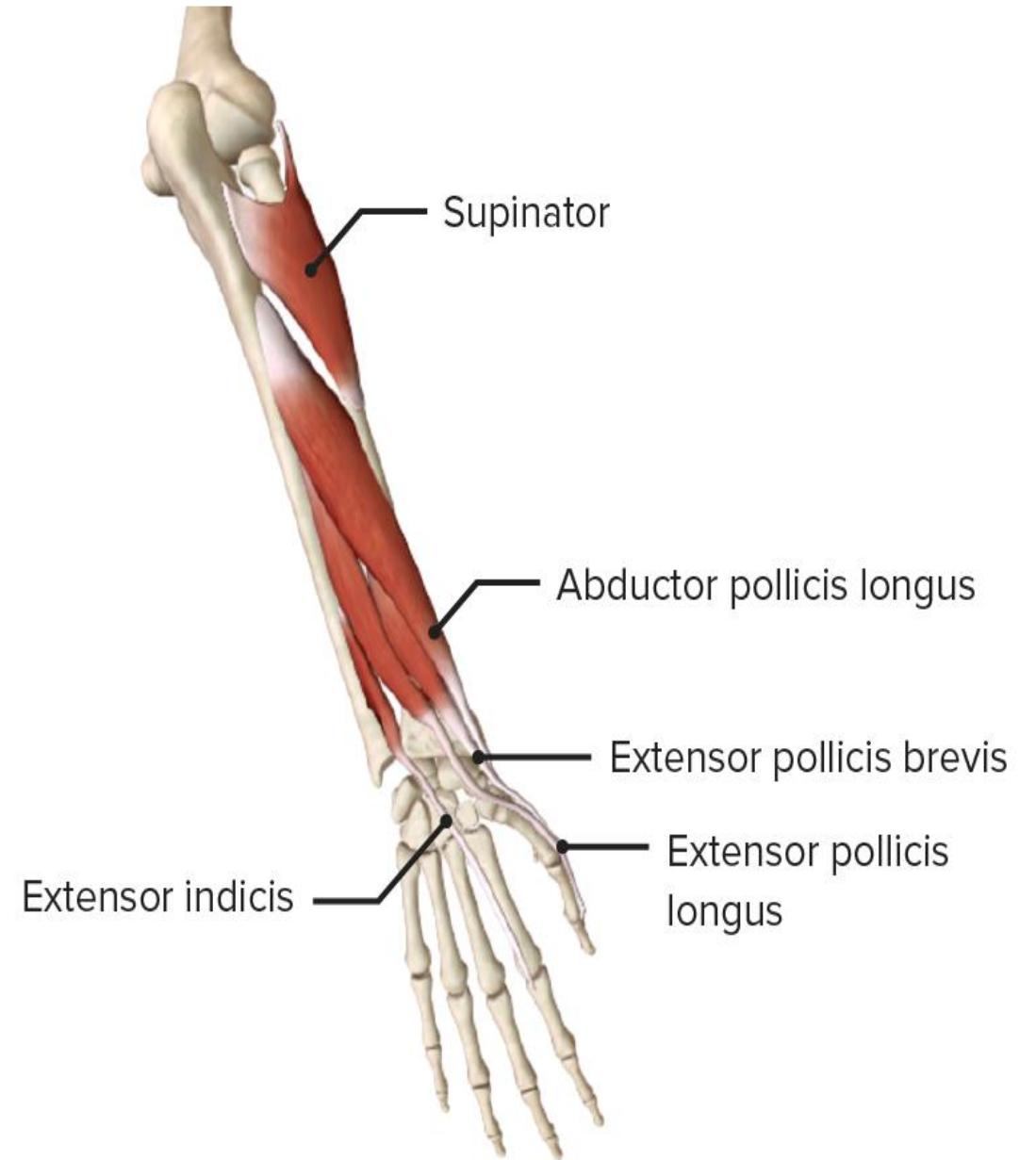
Extensor carpi ulnaris

Anconeus

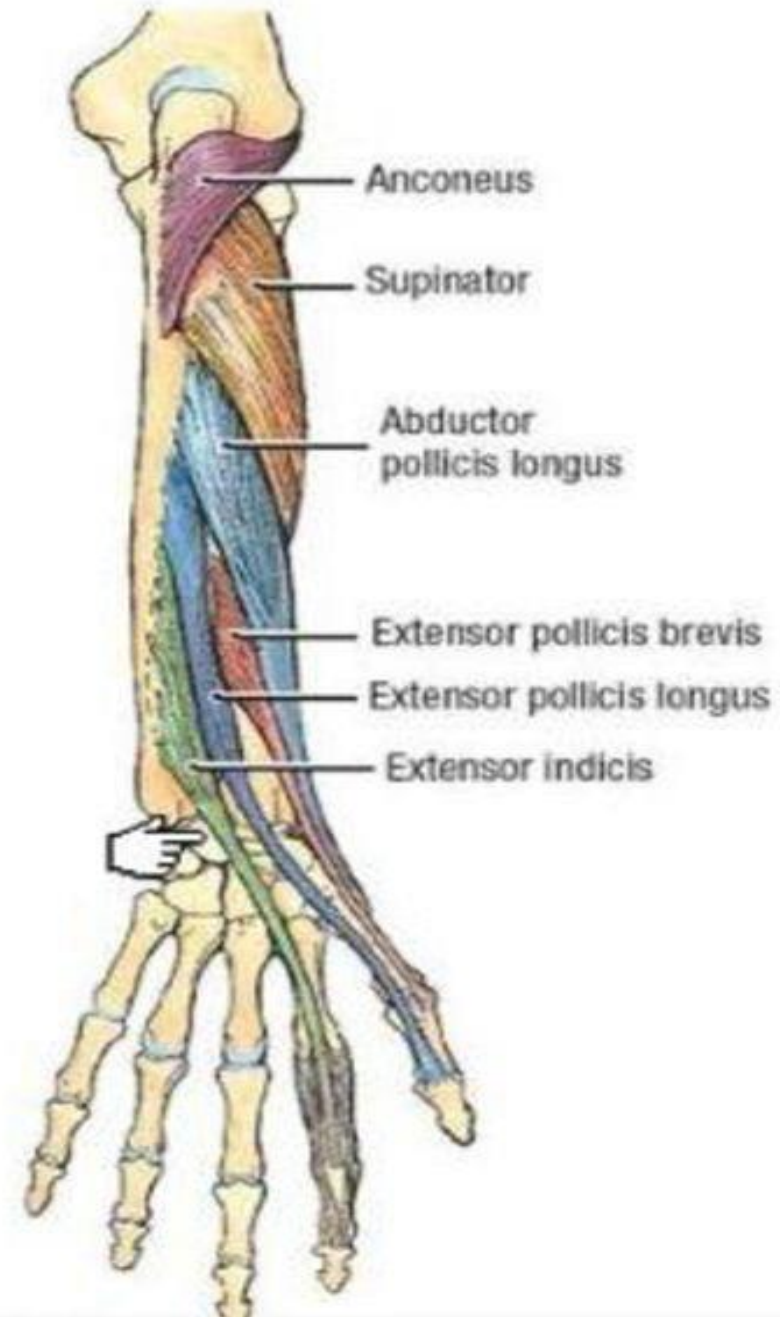


• **II- Deep group of extensor muscles:**

- 1. Supinator.**
- 2. Abductor pollicis longus.**
- 3. Extensor pollicis brevis.**
- 4. Extensor pollicis longus.**
- 5. Extensor indicis.**



- Except for the supinator muscle, all these deep layer muscles originate from the posterior surfaces of the radius, ulna, and interosseous membrane and pass into the thumb and fingers.
- All muscles of the deep layer are innervated by the posterior interosseous nerve, the continuation of the deep branch of the radial nerve.



1- Supinator:

Origin:

- Supinator crest and fossa in ulna.
- Lateral epicondyle of humerus.
- Lateral ligament of elbow joint.
- Annular ligament.

Insertion:

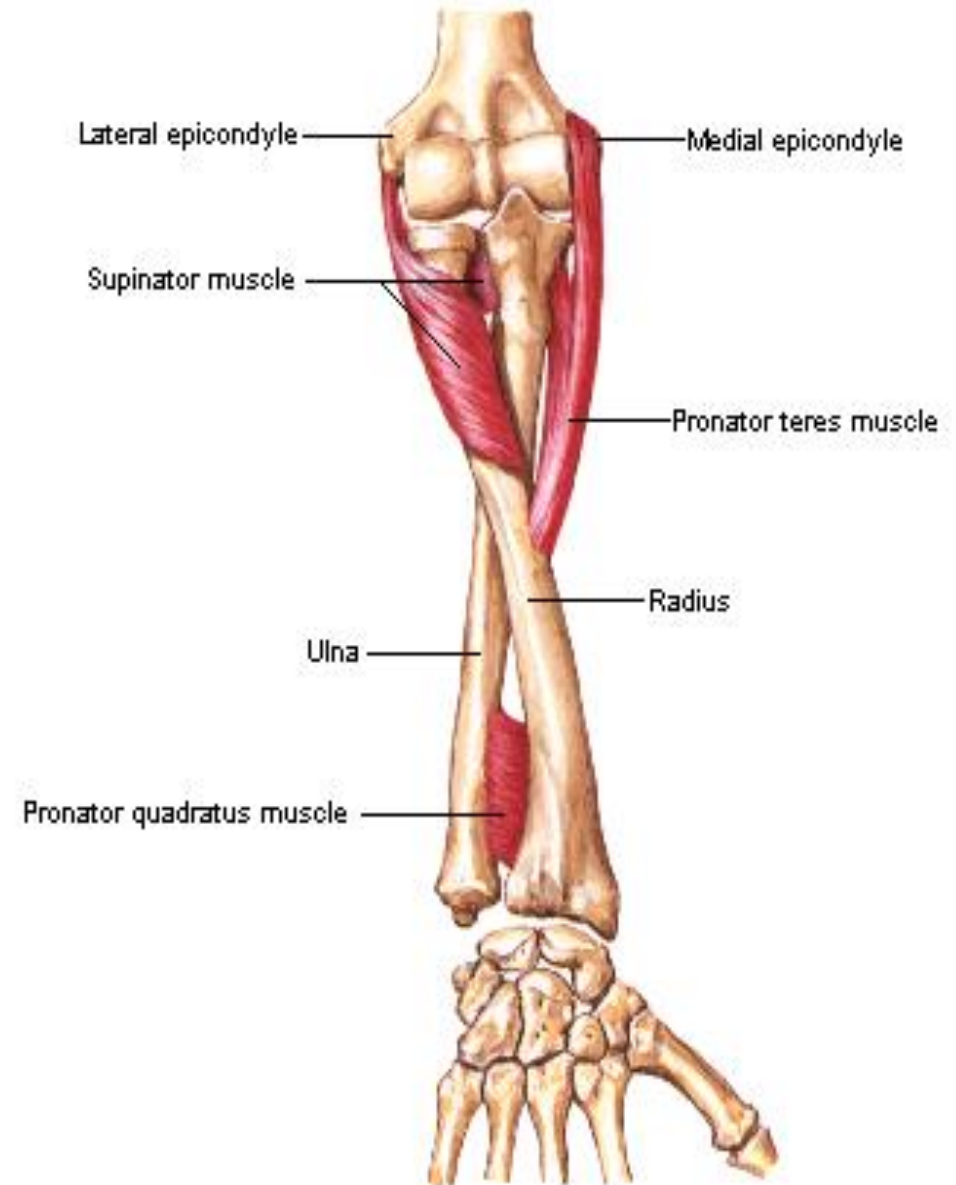
- Upper 1/3 of shaft of radius.

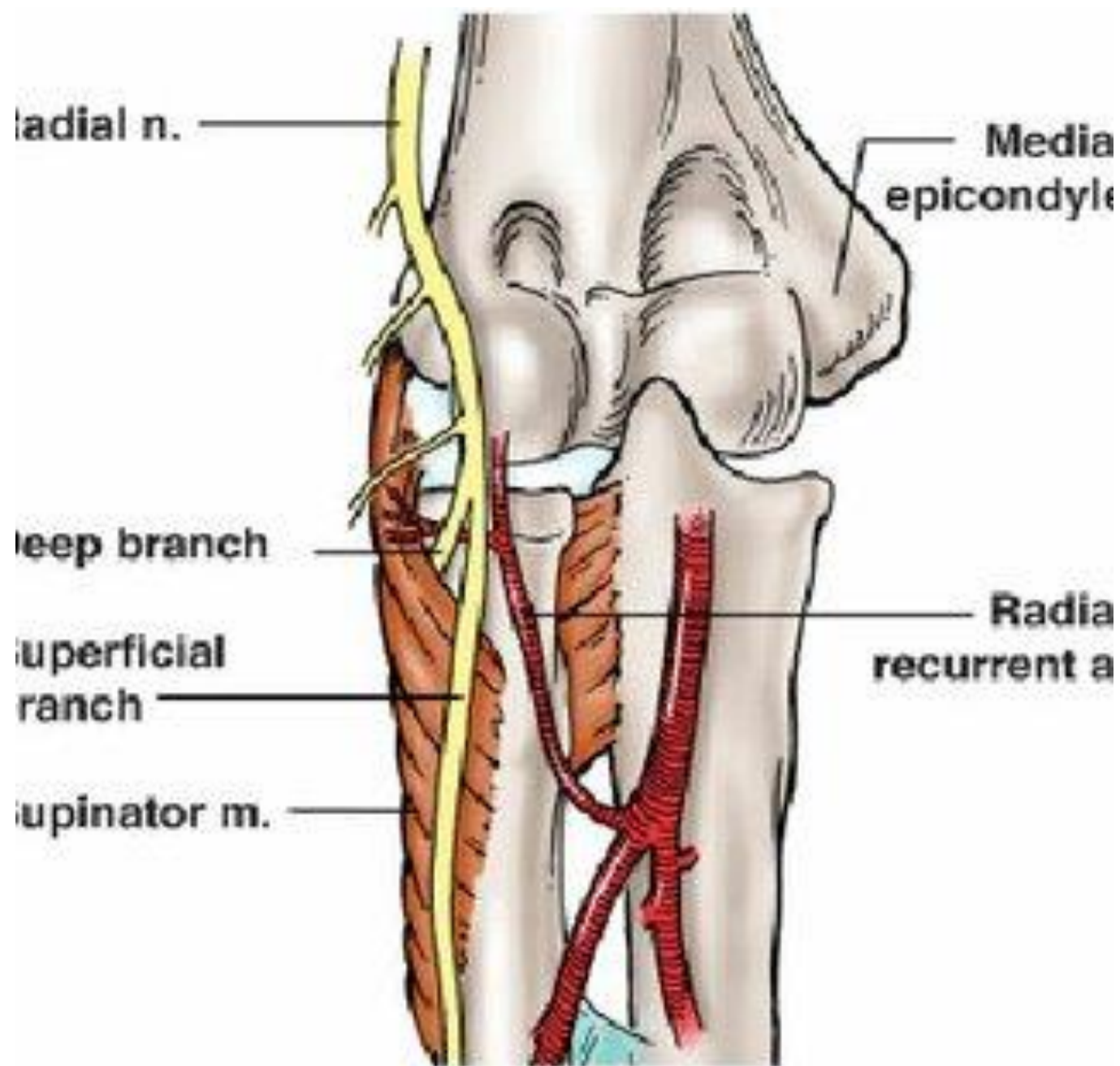
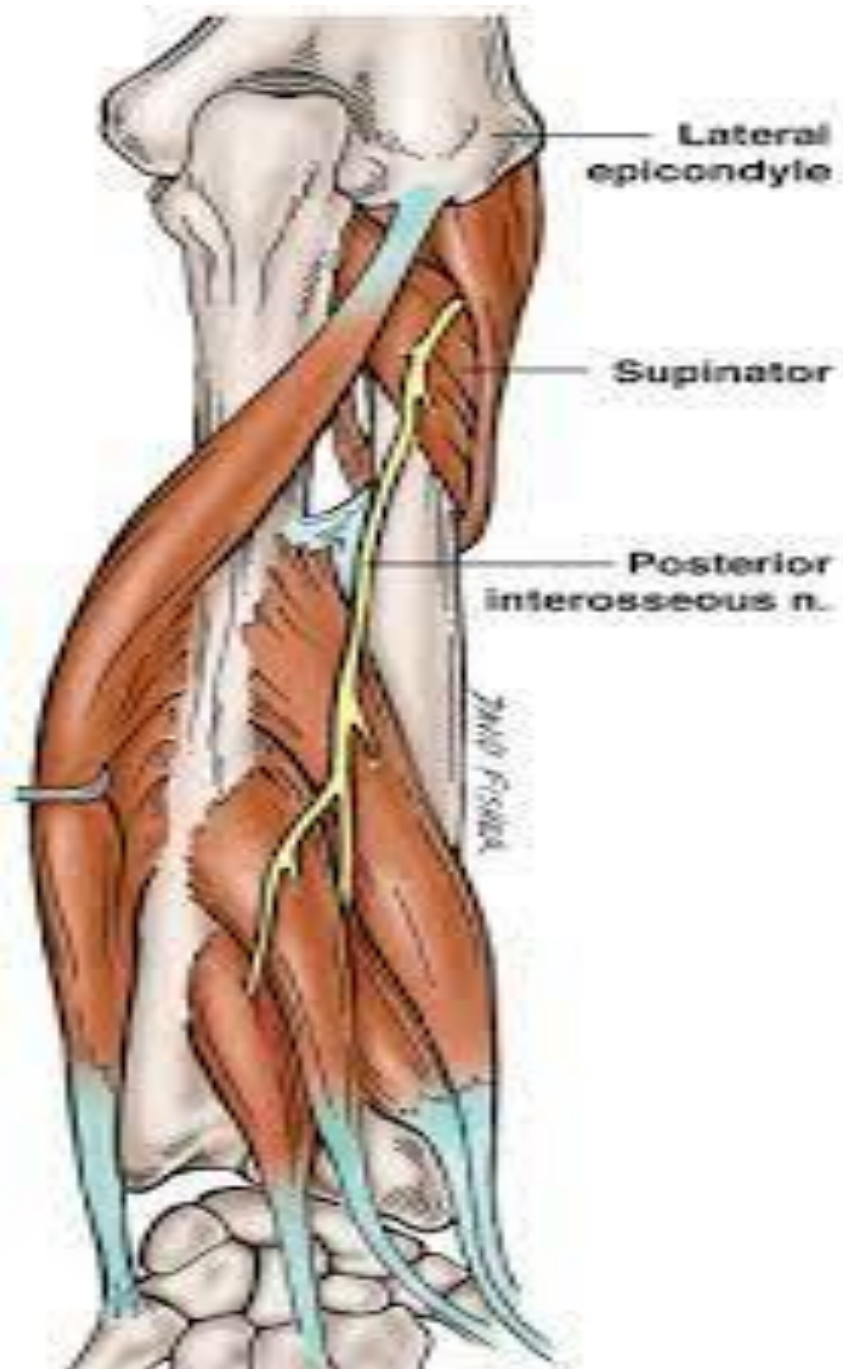
Nerve supply:

- Posterior interosseous nerve.

Action:

- Supination of the forearm.





2- Abductor pollicis longus

Origin:

- Posterior surface of ulna.
- Posterior surface of radius.
- Interosseous membrane.

Insertion:

- Posterior surface of the base of 1st metacarpal bone.

Nerve supply:

- Posterior interosseous nerve.

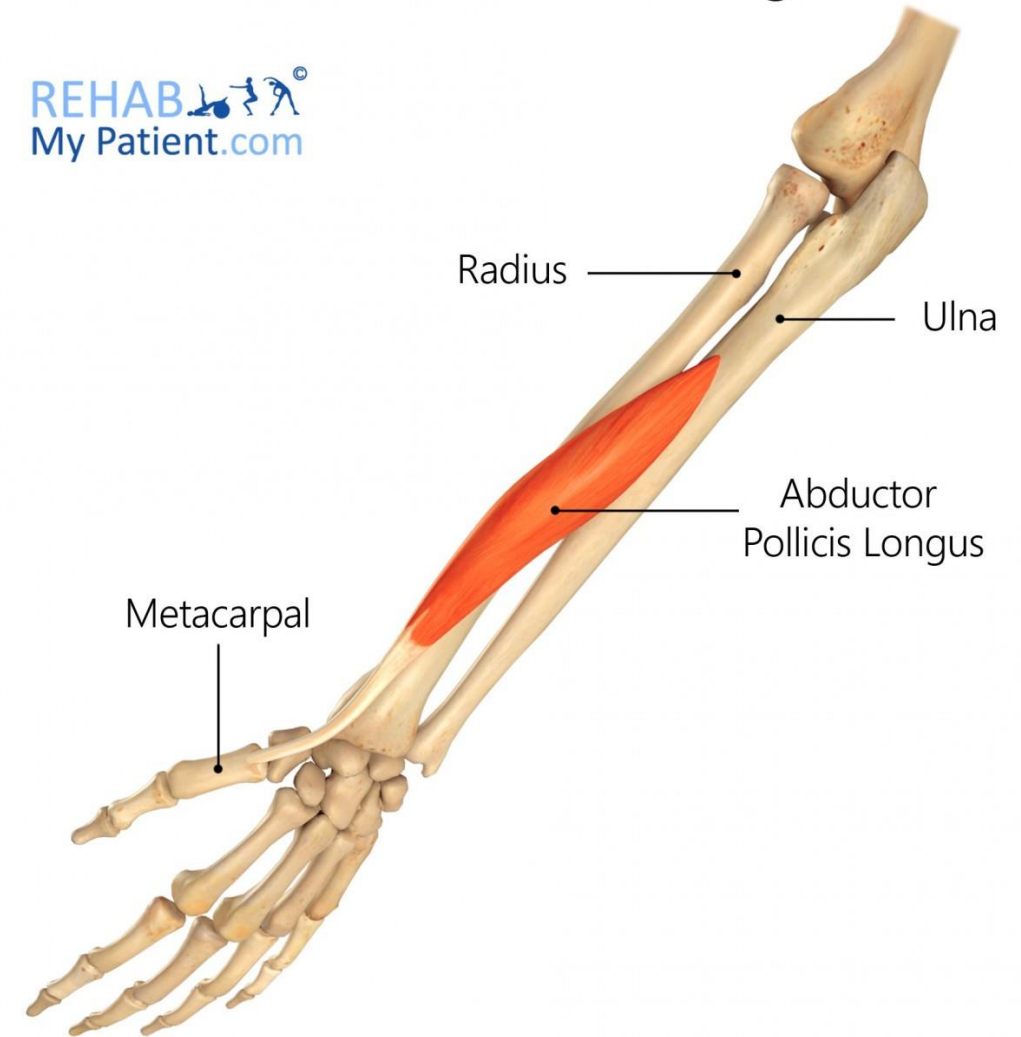Action:

- Abduction of the thumb.

Helps in Extension of the thumb at the carpometacarpal joint.

Abductor Pollicis Longus

REHAB
My Patient.com



3- Extensor pollicis brevis

Origin:

- Posterior surface of radius
- Interosseous membrane.

Insertion:

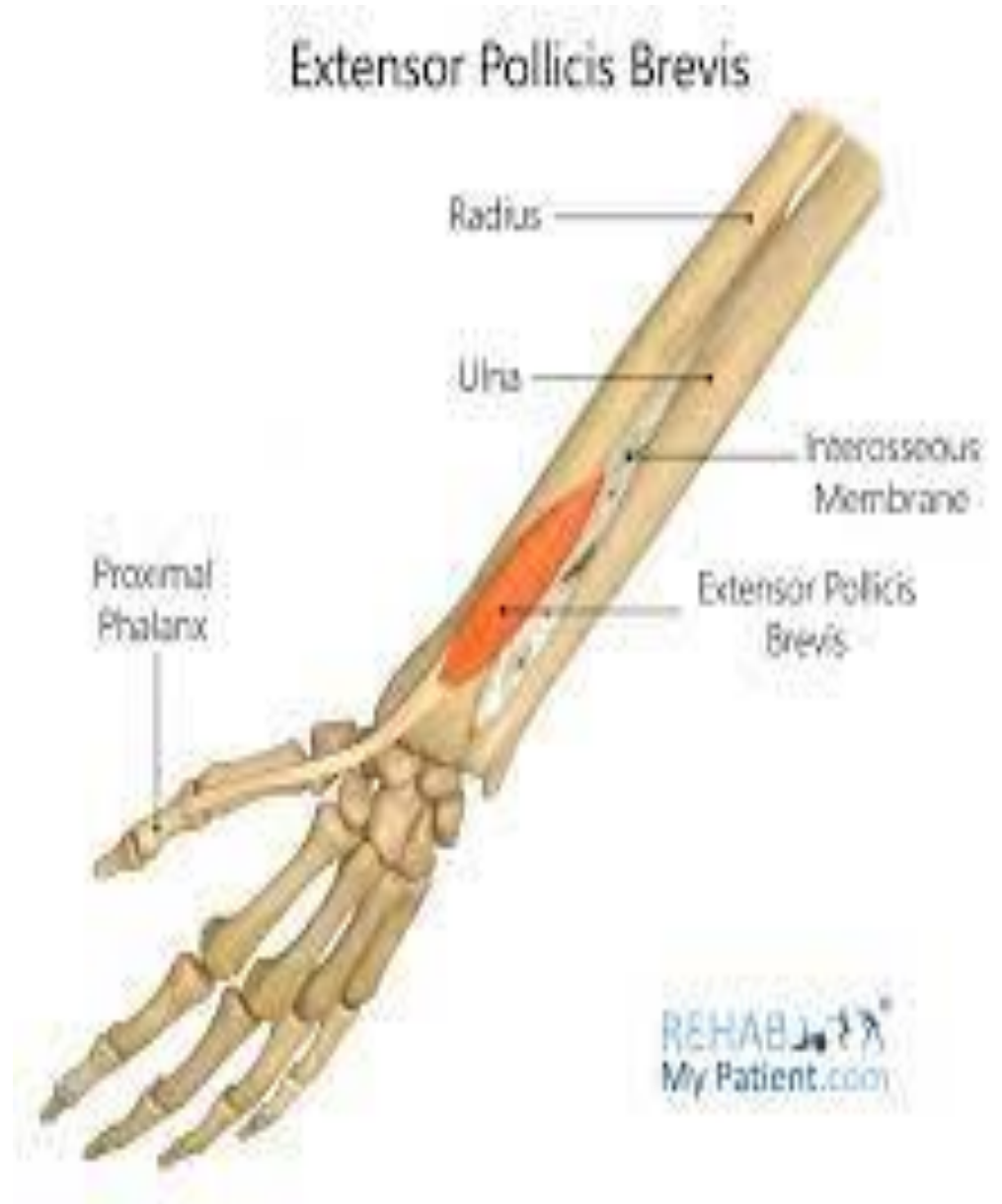
- Proximal phalanx of the thumb.

Nerve supply:

- Posterior interosseous nerve.

Action:

- Extension of metacarpophalangeal and carpometacarpal joints of the thumb



4- Extensor pollicis longus:

Origin:

- Posterior surface of ulna
- Interosseous membrane.

Insertion:

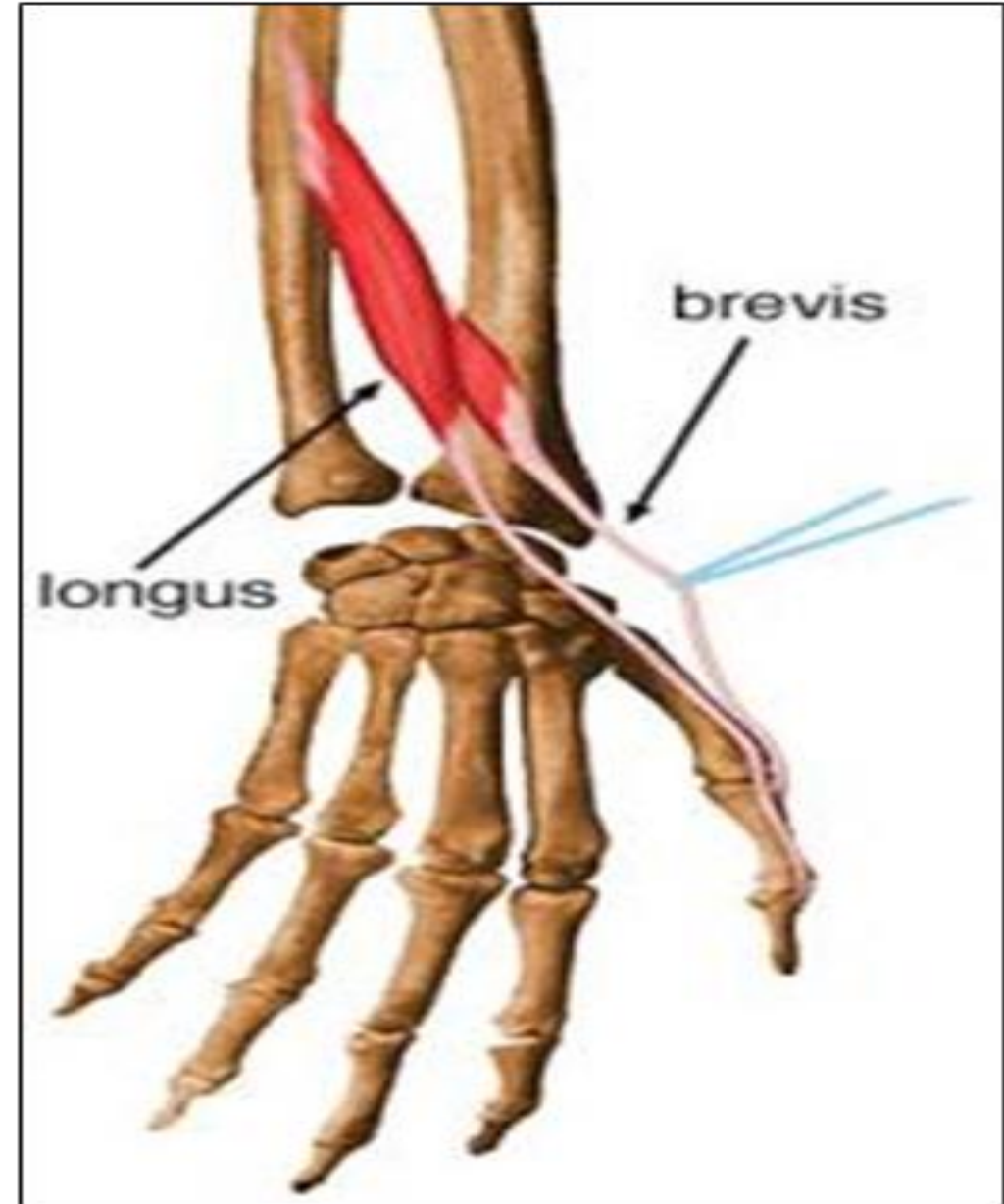
- Distal phalanx of the thumb.

Nerve supply:

- Posterior interosseous nerve.

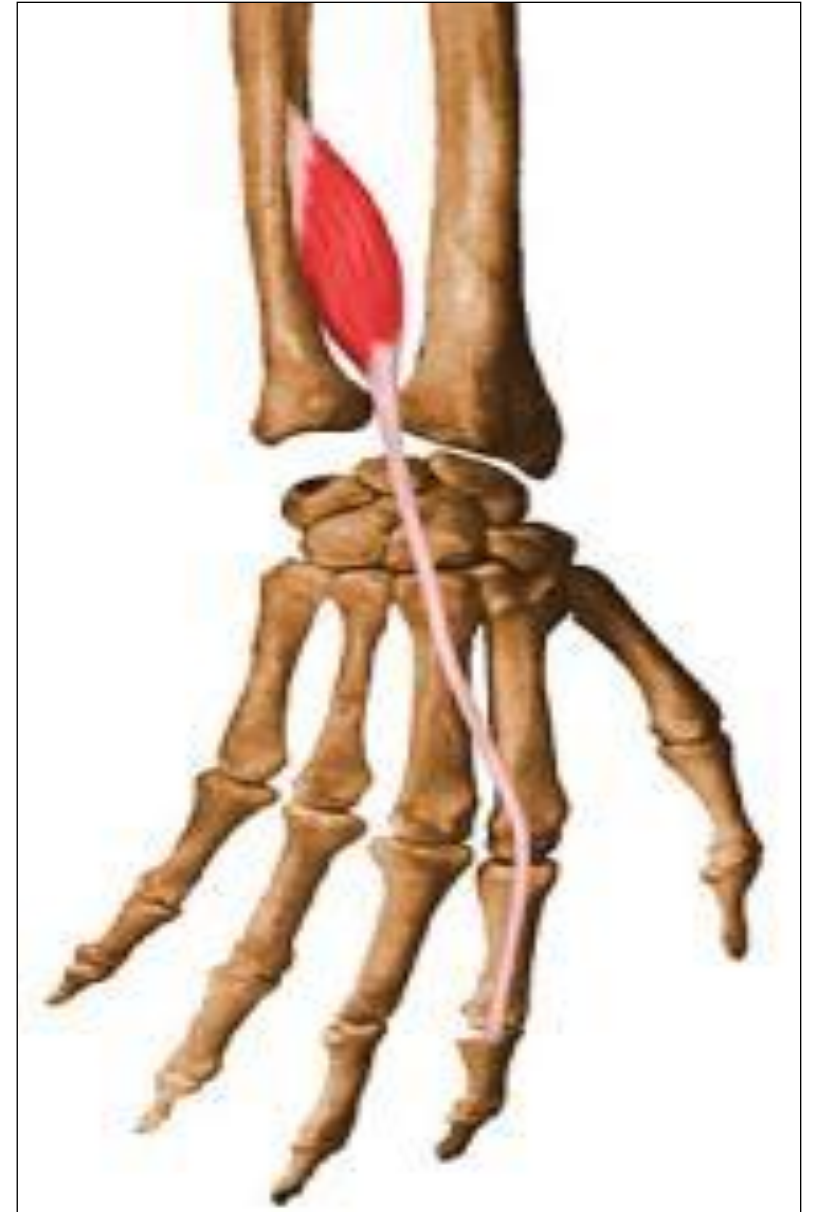
Action:

- Extension of all joints of the thumb.



5- Extensor indicis

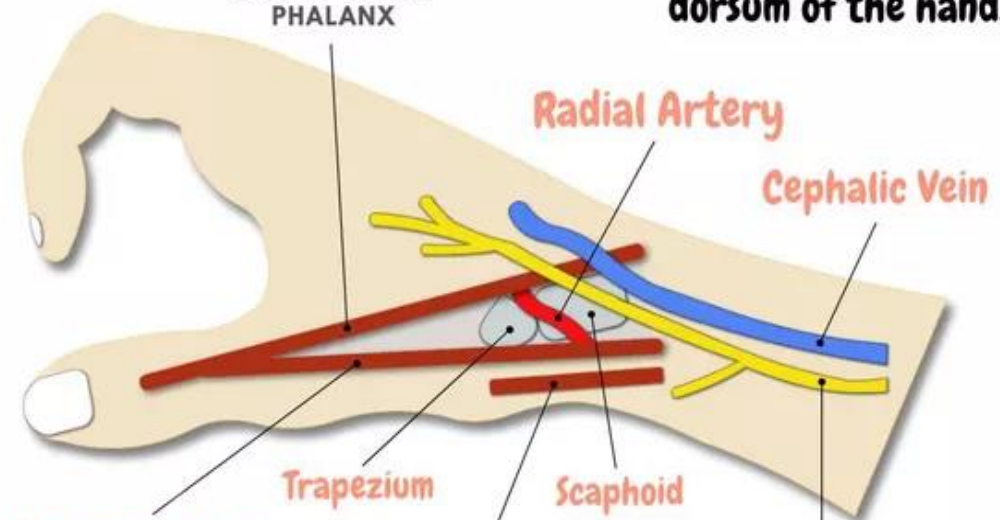
- **Origin:**
 - Posterior surface of ulna
 - Interosseous membrane.
- **Insertion:**
 - Extensor expansion of the index finger.
- **Nerve supply:**
 - Posterior interosseous nerve.
- **Action:**
 - Extension of all joints of index finger.



SNUFF BOX

Extensor pollicis longus muscle
BASE OF DISTAL PHALANX

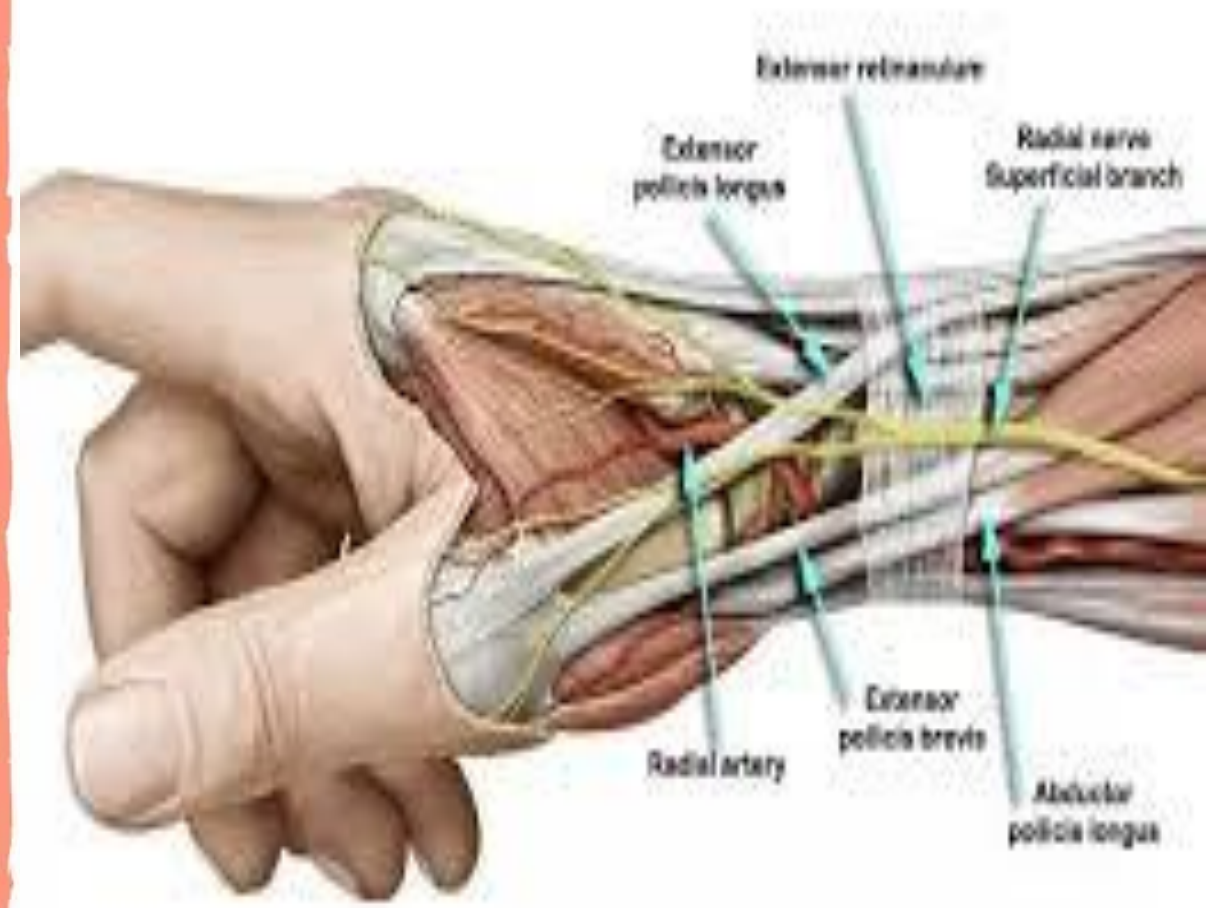
Triangular depression found on the lateral aspect of the dorsum of the hand.

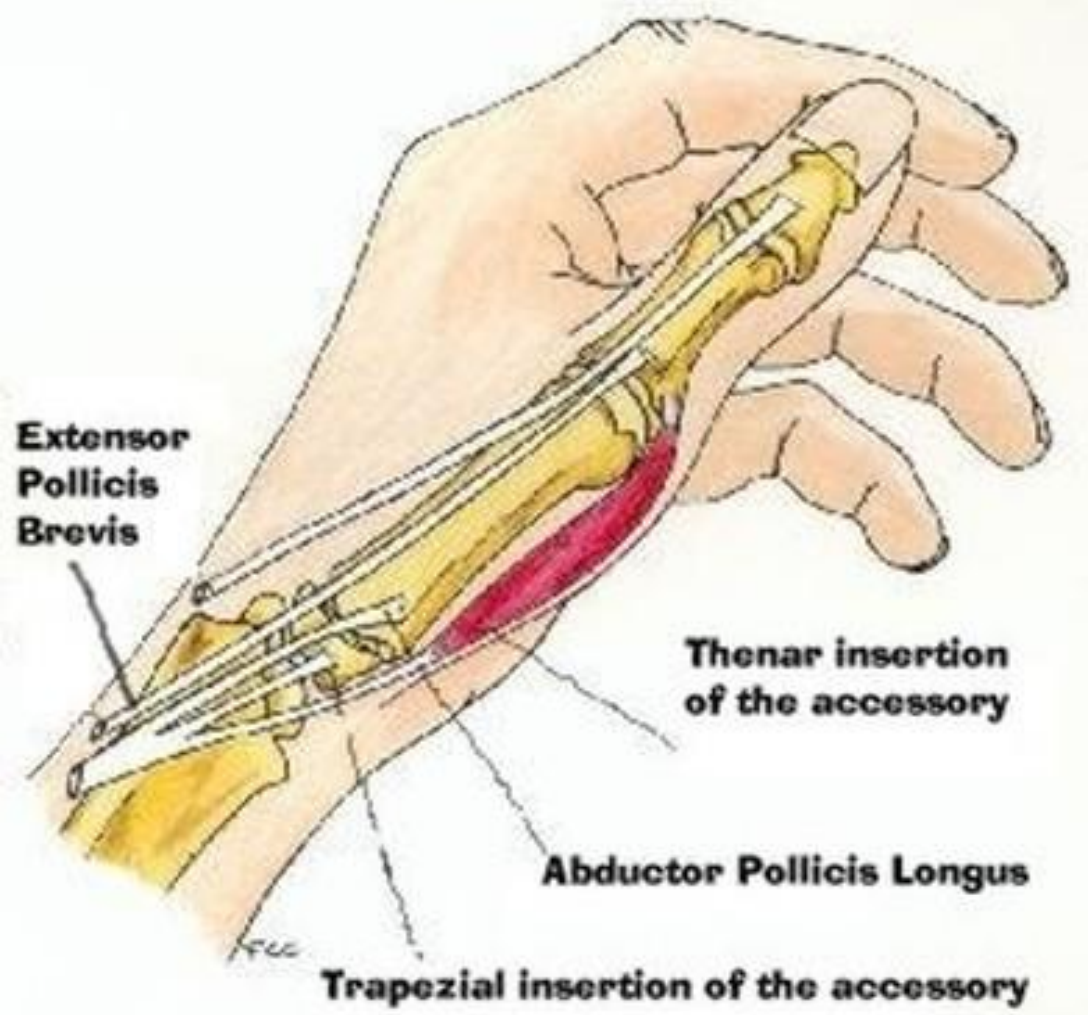
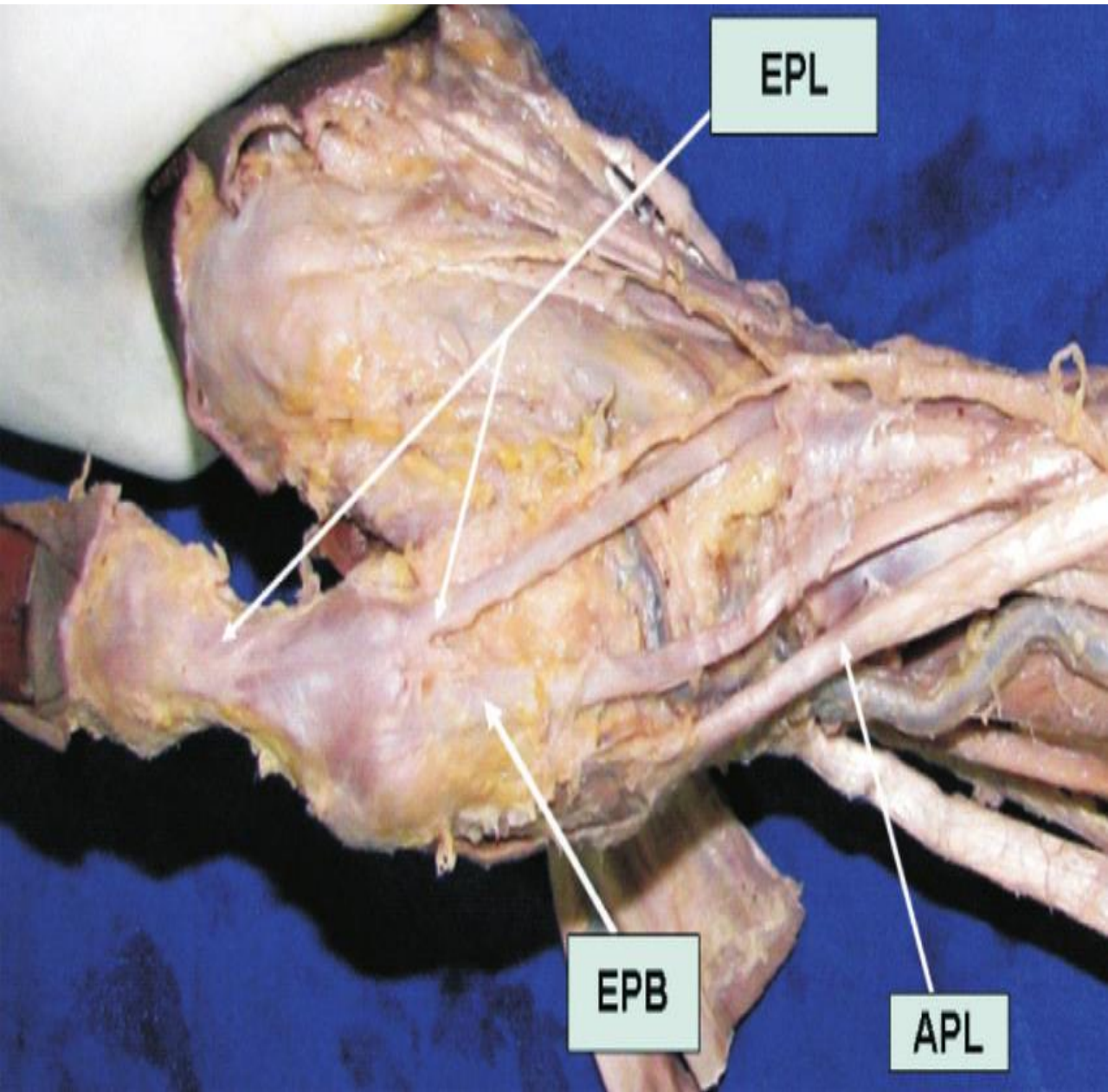


Extensor pollicis brevis muscle
BASE OF PROXIMAL PHALANX

Abductor pollicis longus muscle
BASE OF 1ST METACARPAL

Superficial branch of Radial nerve





Extensor retinaculum

- Thickened band of fascia
- Runs across the back of wrist

Attachment-

- laterally to lower part of anterior border of radius
- Medially it is attached to triquetral & pisiform

