

***Insertion:**

- Pectoralis major muscle → Lateral lip of the bicipital groove.
- Latissimus Dors. → Floor of the bicipital groove.
- Teres major. → Medial lip of the bicipital groove.

***Rotator cuff muscle:**

- subscapularis
- supraspinatus
- Infraspinatus
- Teres minor

***Insertion:**

- subscapularis. → Lesser tubercle of humerus
- supraspinatus → Highest impression of greater tubercle of humerus
- Infraspinatus. → middle impression of greater tubercle of humerus
- Teres minor. → lowest impression of greater tubercle of humerus

***Nerve supply (double):** PTL. وحدة مدنية يتحكمي لواحد (يطل).

- Pectoralis major. → Lateral and medial pectoral nerves.
- Trapezius. → N.motor. ,N.sensory
- Levator scapulae. → Dorsal scapular n c5 + n from cervical plexus c3&c4

Note : pectoral major muscle is the only muscle of the upper limb supplied by 5 segments from brachial plexus.:

- lateral pectoral nerve. → C5,C6,C7
- medial pectoral nerve. → C8,T1

وحدة مصرة انه وادي رم الها فيتحكمي : رم رم لي

Note: Dorsalscapular n c5 → Rhomboideus Minor+Rhomboideus Major+Levator Scapulae

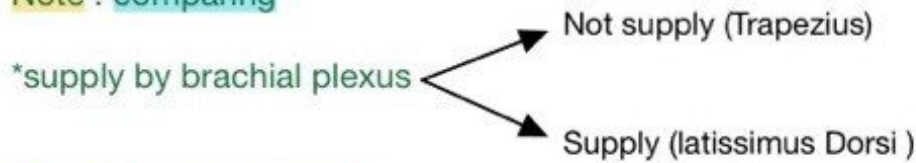
***The structures pierced the Clavipectoral Fascia:**

- Cephalic Vein.
 - Lymphatics vessels.
 - Thoraco-acromial Artery.
 - Lateral pectoral Nerve.
- وحدة مضيعة الفيزا تبعتها بتحكمي : فين الفيزا أنتي (aunty) نيرمين

Note:Action

- protraction of the scapula. → Serratus Anterior + Pectoralis Minor
- Elevates the ribs during deep inspiration. → Pectoralis major+Pectoralis Minor

Note : comparing



Note : Latissimus Dorsi

The only muscles of upper limb has pelvic attachment.

Accessory muscle of expiration

It has triple relations to teres major (it lies behind, below and finally in front).

Note :

*Deep relations of pectoralis major:

- Pectoralis minor
- Clavipectoral fascia.
- Axilla and its contents

Note:

*Abduction of the arm :

0-15 → Supraspinatus

15-90 → Middle fiber of deltoid muscle

>90 → Middle and lower fibres of Trapezius + lower 5 digitations of the Serratus anterior

Note

-Fixation of the scapula during movement of the upper limb. → Serratus Anterior

-Fixation of the clavicle during movements of the shoulder girdle → Subclavius

Note: Action

*Retraction the scapula :

- middle fibres of Trapezius
- Rhomboides Minor and Rhomboides major

Note Adduction

- Pectoralis major muscle
- Latissimus Dorsi
- subscapularis
- Infraspinatus
- Teres minor
- Teres major

Note Abduction

- Serratus Anterior
- Trapezius
- middle fibres of Deltoid muscle
- supraspinatus

🥺 miss you ساره ترا : ساره ترا : ساره ترا