Malaria

protozoal infection of RBCs

- caused by plasmodium
- subtypes:
  1- p. falciparum → Malignant tertian malaria
  2- p. vivax → Benign tertian malaria
  3- p. ovale → Ovale tertian malaria
  4- p. malariae → Quartan malaria
- parasite morphology → trophozoite, schizont, gametocyte (on RBCs)
- diagnosis:
  1. Travel history (of endemic areas)
  2. symptoms
  3. Blood smear (RBCs تشوفها داخل الـ)
- Treatment → Quinine derivatives
  - can be used as prophylaxis
  - p. falciparum → often drug resistant
    أخطر وحده
- Control →
  1. Control mosquito population
  2. mosquito netting

asexual reproduction (in human)
- Sporozoit → merozoit → on liver
- Gametogony → on RBCs

Sporogony (sexual reproduction) → mosquito

Malarial symptoms

type	organ Involved	symptoms
tertian (vivax and ovale)	spleen, liver, erythrocytes systemic	headache, lassitude, vague aching of bones and joints, chills and high fever (103-106 F), nausea and vomiting, convulsion, euphoria, profuse sweating. Symptoms every other day and last 8-12 hours. Spontaneous recovery
falciparum (malignant tertian)		same as above but no tertian pattern: there may be daily spiking; no spontaneous recovery and ultimately fatal. Renal & CNS involvement
quartan (malariae)		same as tertian, but paroxysm occurs every three days (2 clear days)

life cycle

mosquito

Sporozoits on salivary gland of mosquito

bite (human) → Sporozoits on Blood stream → infect liver cells → may: ① remain dormant (hypnozoites) → like p. vivax & p. ovale
or: ② asexual multiplication (sporozoites → merozoites)
like p. falciparum & p. malariae

Extraerythrocytic cycle

liver cell rupture and goes to blood stream

each merozoite infect one RBC → starts asexual reproduction (كيف)

merozoite → trophozoite → schizont (contains abt of merozoites) → rupture of RBCs and release of merozoites to Blood stream → enters RBC again

- others → asexual reproduction (Erythrocytic cycle) (merozoites زيادة مرزال)
- some → Gametogony → male & female gametocytes (تتحول)

female mosquito bite on her gut → male & female gametocytes → zygote (due to fuse of male & female gametocytes)

1. zygote → 2. ookinetic → 3. oocyst → sporozoites (salivary gland of mosquitos وبتروح لل)

1. 2. 3. → on the gut

Babesia

protozoal infection of RBCs

- caused by Babesia microti
- Zoonotic infection (Deer is primary reservoir)
- cases reported in northen-estern part of the US & Europe
- parasite morphology →
  1. Similar to malaria parasite but no schizonts or gametocytes
  2. up to 4 trophozoite per RBC →

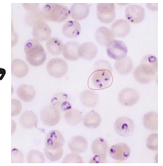

- Symptoms:
  1. mild chills & fever
  2. Hemolytic anemia
  3. Jaundice
  4. Hepatomegally

  No malariae paroxysm fever
- diagnosis →
  1. symptoms
  2. history of tick bite
  3. no paroxysm fever
  4. characteristic organism in blood (4 trophozoite/RBC)
- Treatment: clindamycin + Quinin
- prevention:
  1. Avoid tick bites
  2. Recovery may be spontaneous
     - p. vivax & p. ovale (مثل الـ)
     - p. falciparum (أما الـ)
       - no spontaneous recovery
       - ultimatly fatal