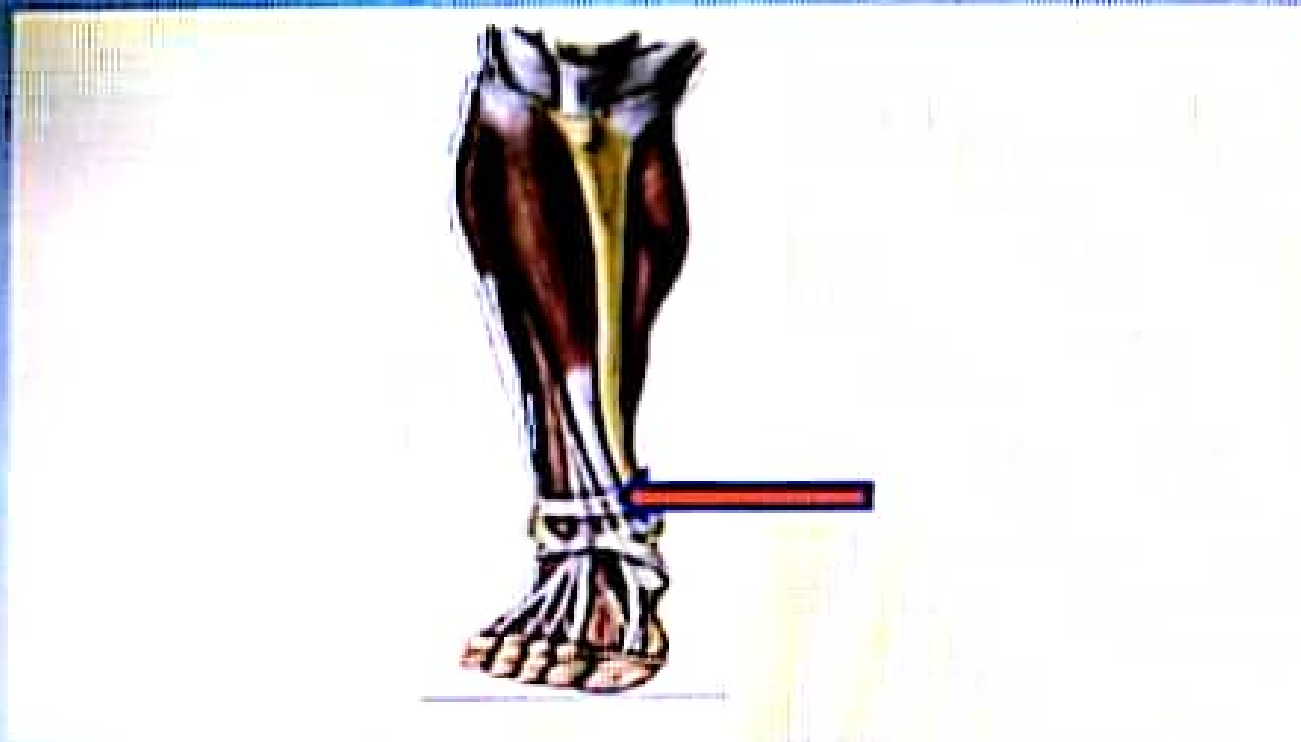


What is the labeled structure?



Select one

- a Superior external retinaculum
- b Inferior flexor retinaculum
- c Superior flexor retinaculum
- d Peroneal retinaculum
- e Inferior external retinaculum

What is the labeled structure?

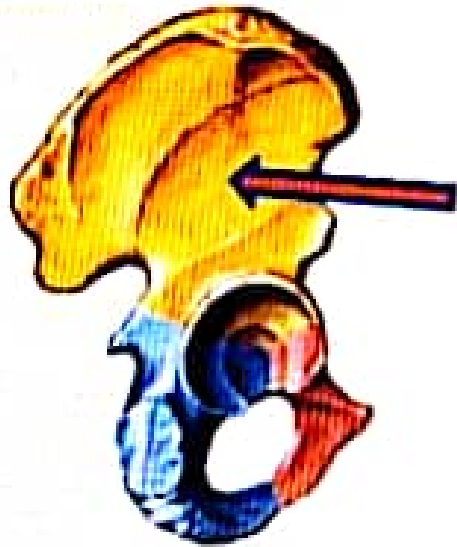


Select one



- a. Adductor magnus
- b. Rectus femoris
- c. Vastus medialis
- d. Obturator externus
- e. Adductor longus

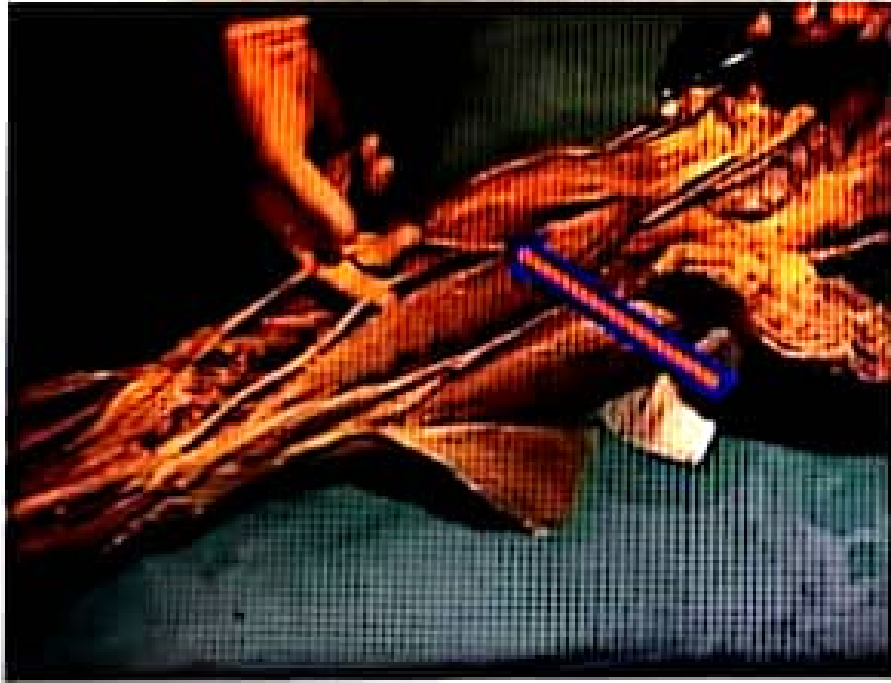What is the labeled structure?



Select one

- a. Origin of gluteus maximus
- b. Origin of Biceps Muscle
- c. Origin of gluteus medius
- d. Origin of rectus femoris
- e. Origin of gluteus minimus

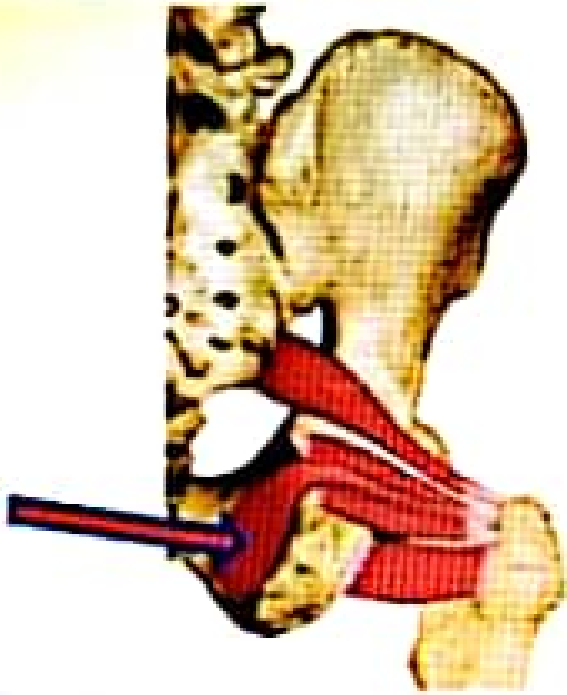
What is the labeled structure?



Select one:

- a. Femoral nerve
- b. Sciatic nerve
- c. Tibial nerve
- d. Sural nerve
- e. Common peroneal nerve

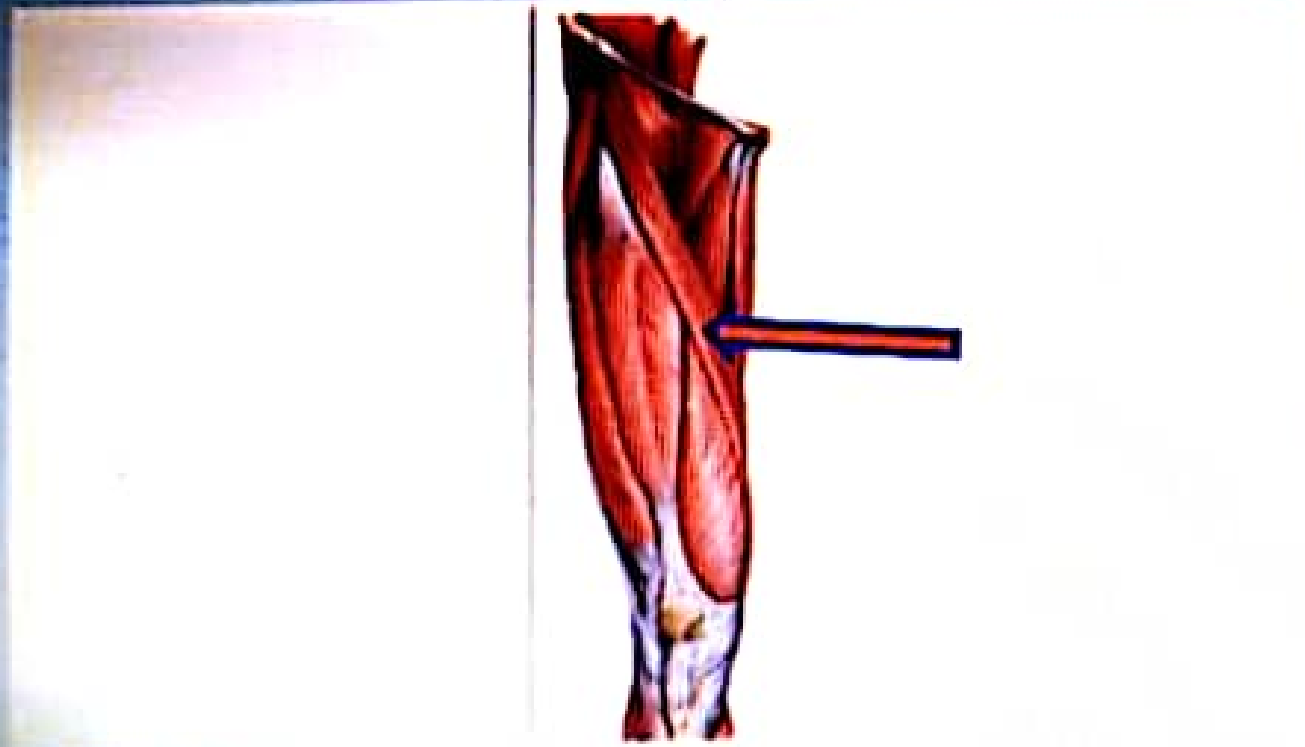
What is the labeled structure?



Select one:

- a. Obturator externus muscle
- b. Obturator internus muscle
- c. Superior gemellus muscle
- d. Inferior gemellus muscle
- e. Piriform muscle

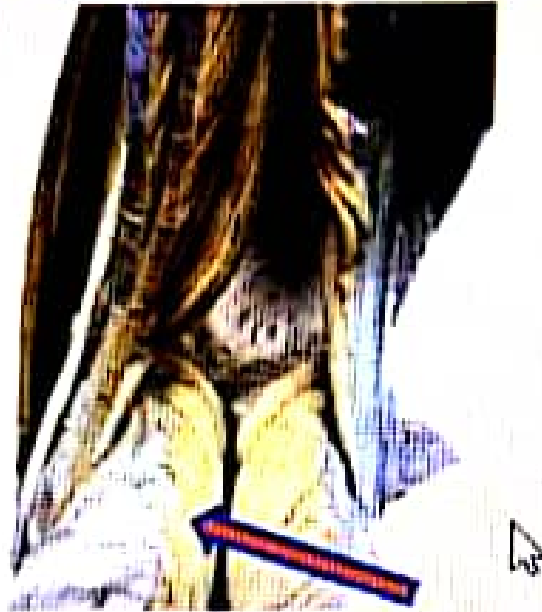What is the labeled structure?



Select one:

- a Vastus lateralis
- b Vastus intermedius
- c Sartorius
- d Rectus femoris
- e Vastus medialis

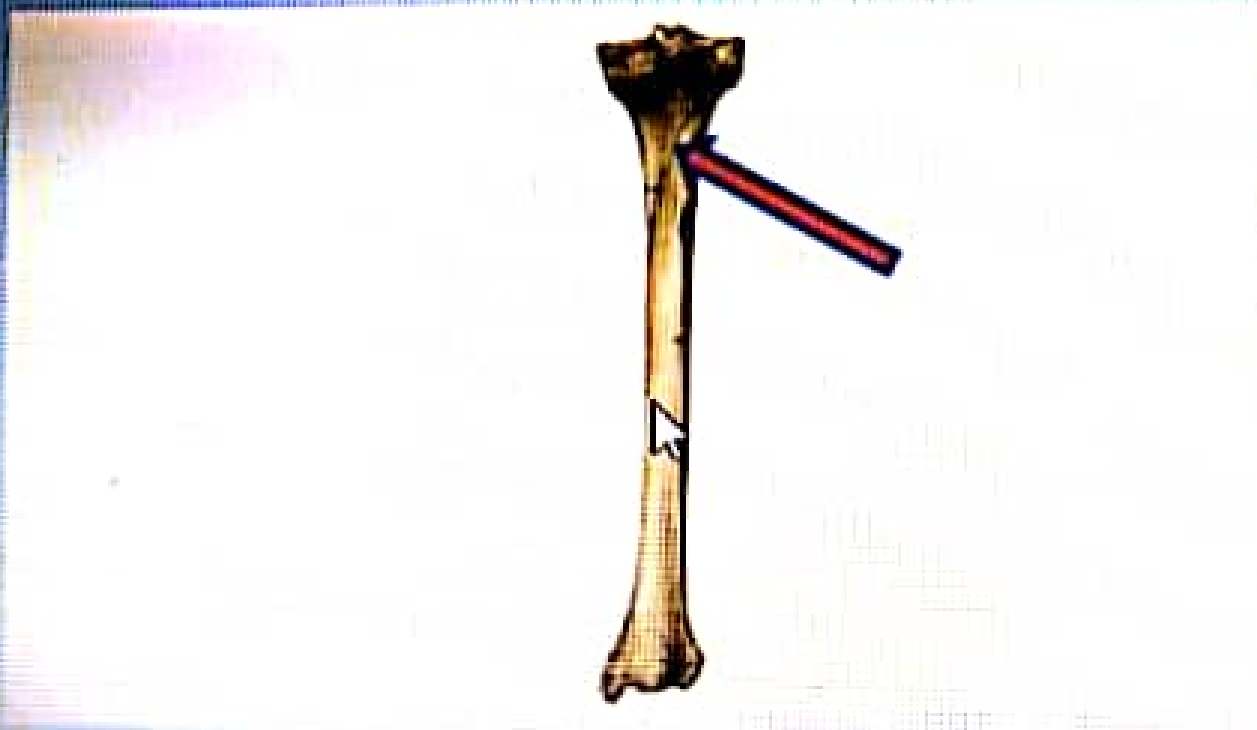What is the labeled structure?



Select one:

- a. Biceps muscle
- b. Lateral head of gastrocnemius muscles
- c. Semitendinosus muscle
- d. Medial head of gastrocnemius muscles
- e. Semimembranosus muscle


What is the labeled structure?



Select one:

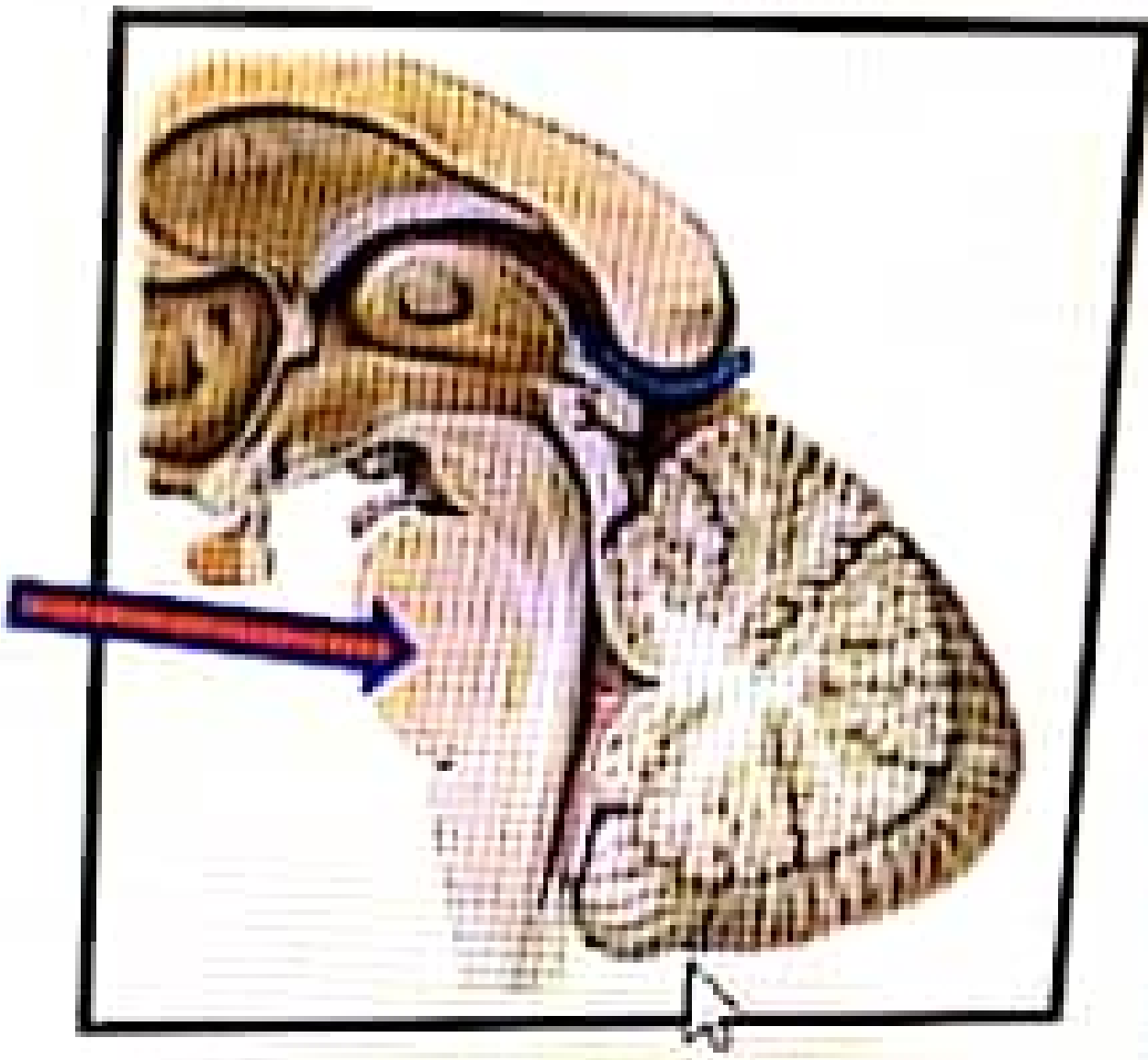
- a. Right popliteus
- b. Left soleus
- c. Right tibialis posterior
- d. Left popliteus
- e. Right soleus

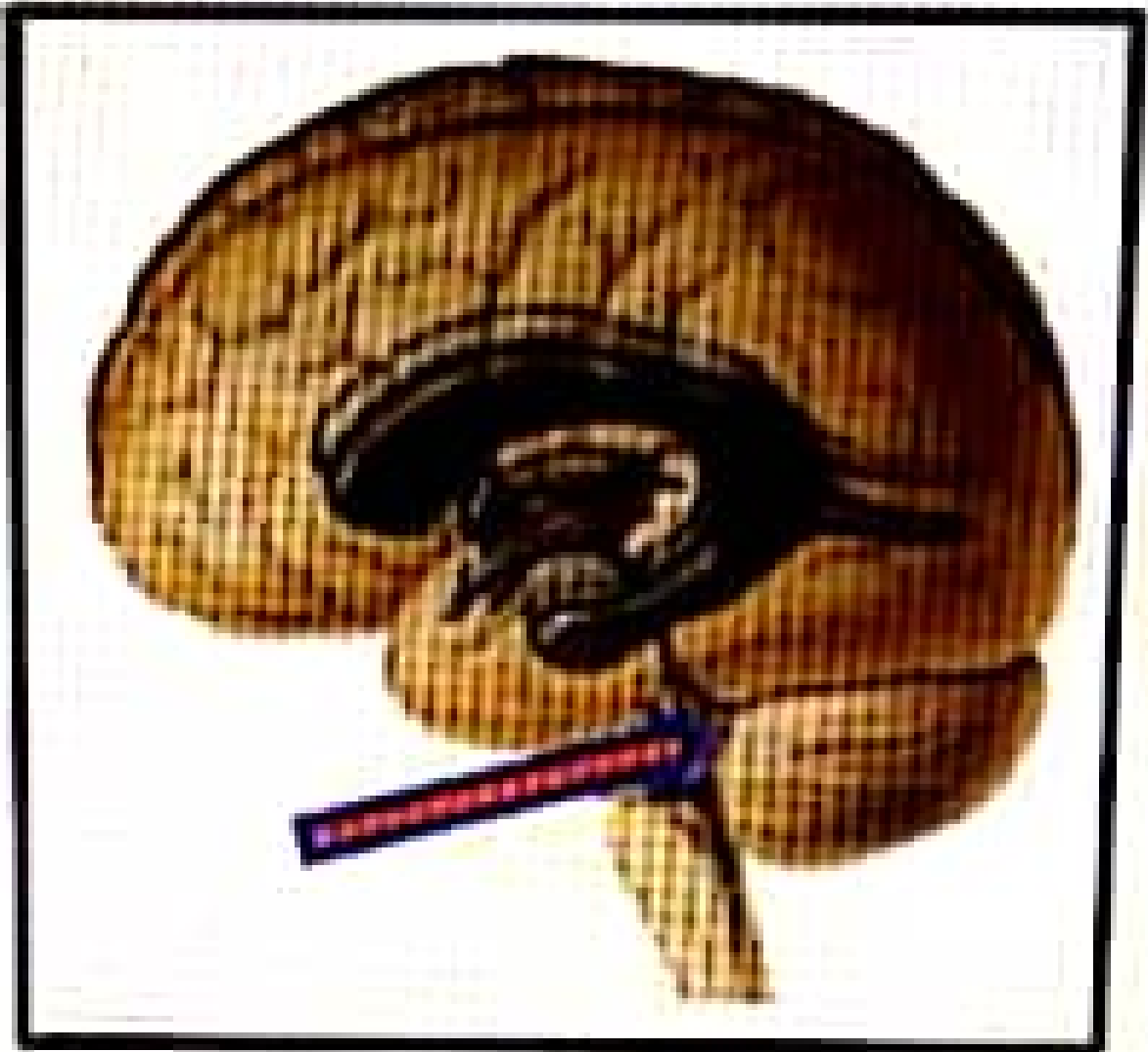
What is the labeled structure?



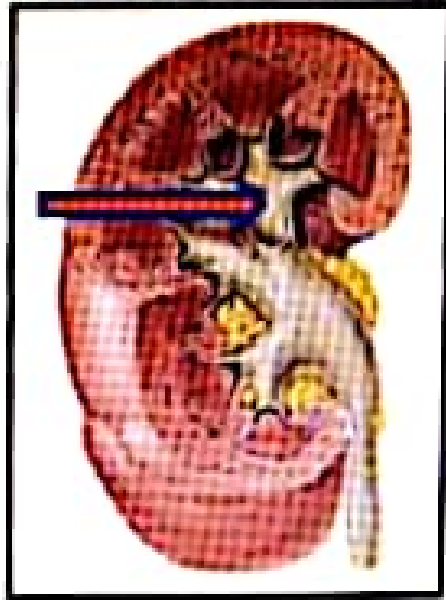
Select one:

- a. Spiral line
- b. Linea aspera
- c. Lesser trochanter
- d. Neck of the femur
- e. Greater trochanter





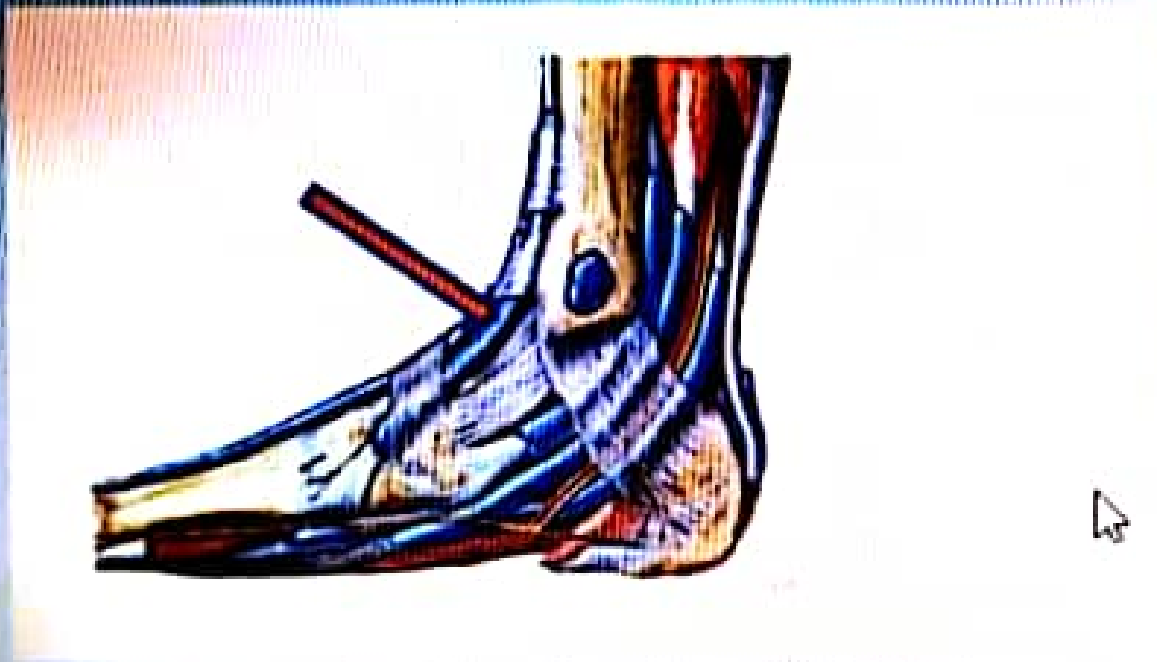What is the labeled structure?



Select one

- a Ureter
- b Pelvis of the ureter
- c Major calyx
- d Minor calyx
- e The renal papilla

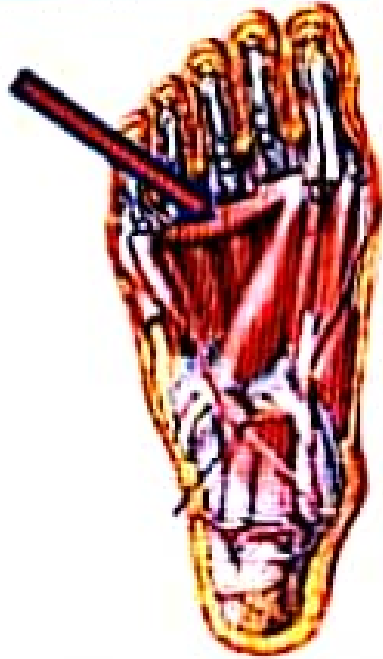What is the labeled structure?



Select one.

- a. Tibialis posterior muscle
- b. Tibia bone
- c. Extensor digitorum longus muscle
- d. Tibialis anterior muscle
- e. Flexor digitorum longus muscle

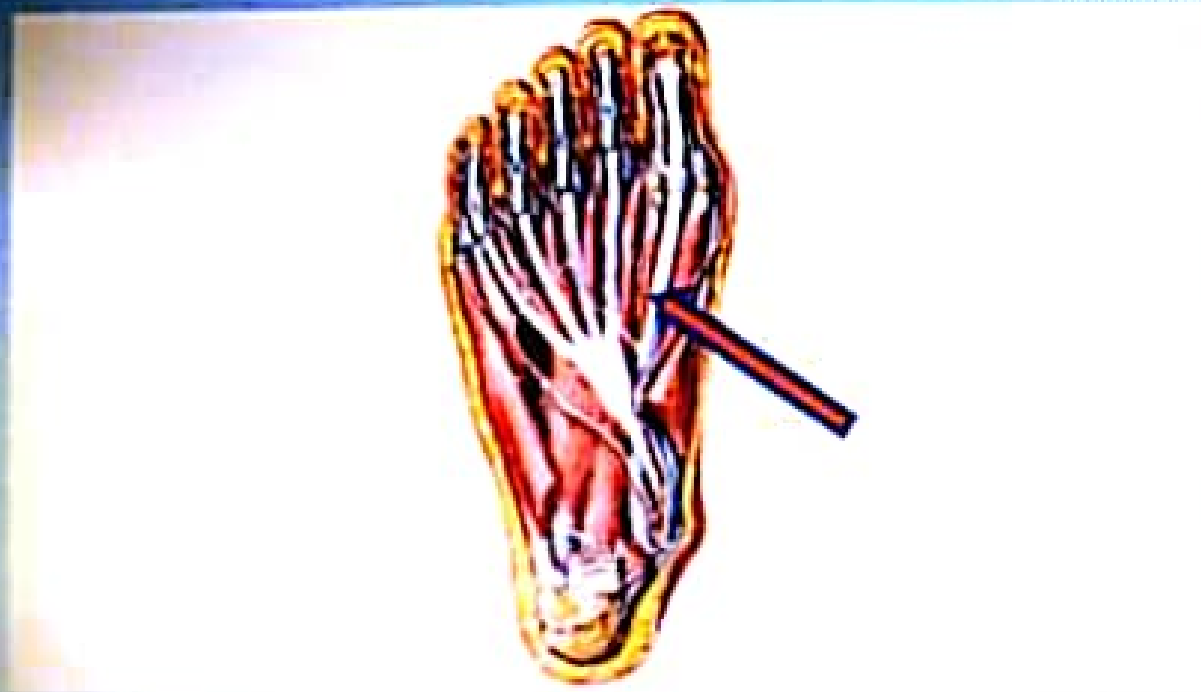What is the labeled structure?



Select one

- a. Transverse head of adductor hallucis
- b. Oblique head of adductor hallucis
- c. Flexor hallucis brevis
- d. Oblique head of abductor hallucis
- e. Transverse head of abductor hallucis

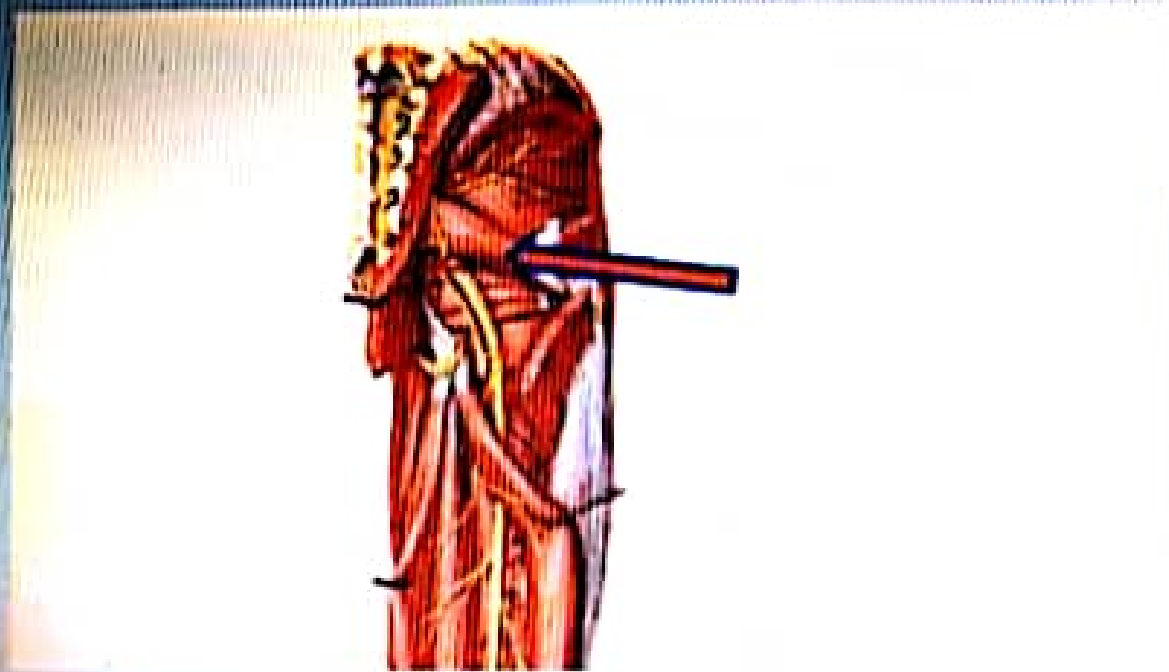What is the labeled structure?



Select one

- a. Peroneus longus
- b. Flexor digitorum longus
- c. Peroneus brevis
- d. Flexor accessorius
- e. Flexor hallucis longus

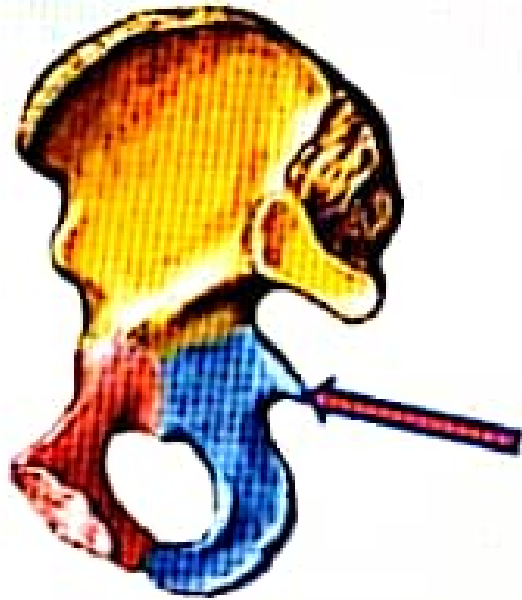What is the labeled structure?



Select one:

- a. Obturator externus
- b. Posterior cutaneous nerve of the thigh
- c. Pudendal nerve
- d. Piriformis
- e. Sciatic nerve

What is the labeled structure?

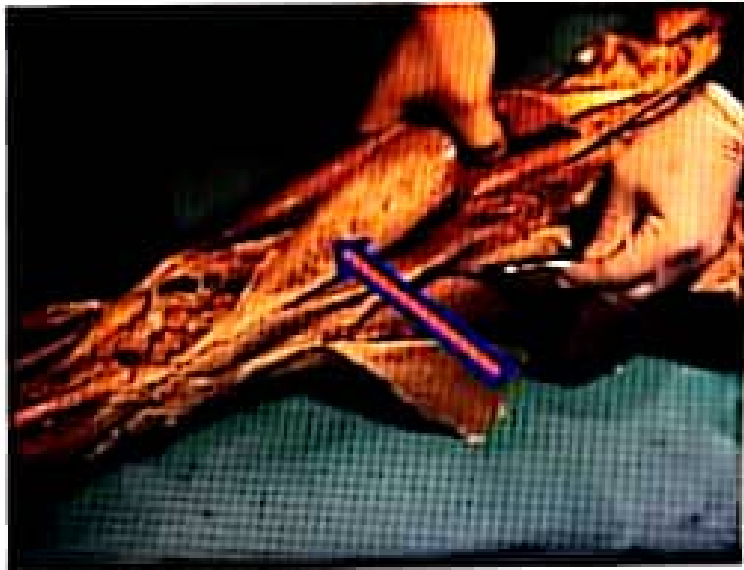

Select one

- a Posterior inferior iliac spine
- b Ischial spine
- c Iliopectineal eminence
- d Ischial tuberosity
- e Posterior superior iliac spine

What is the labeled structure?

What is the labeled structure?

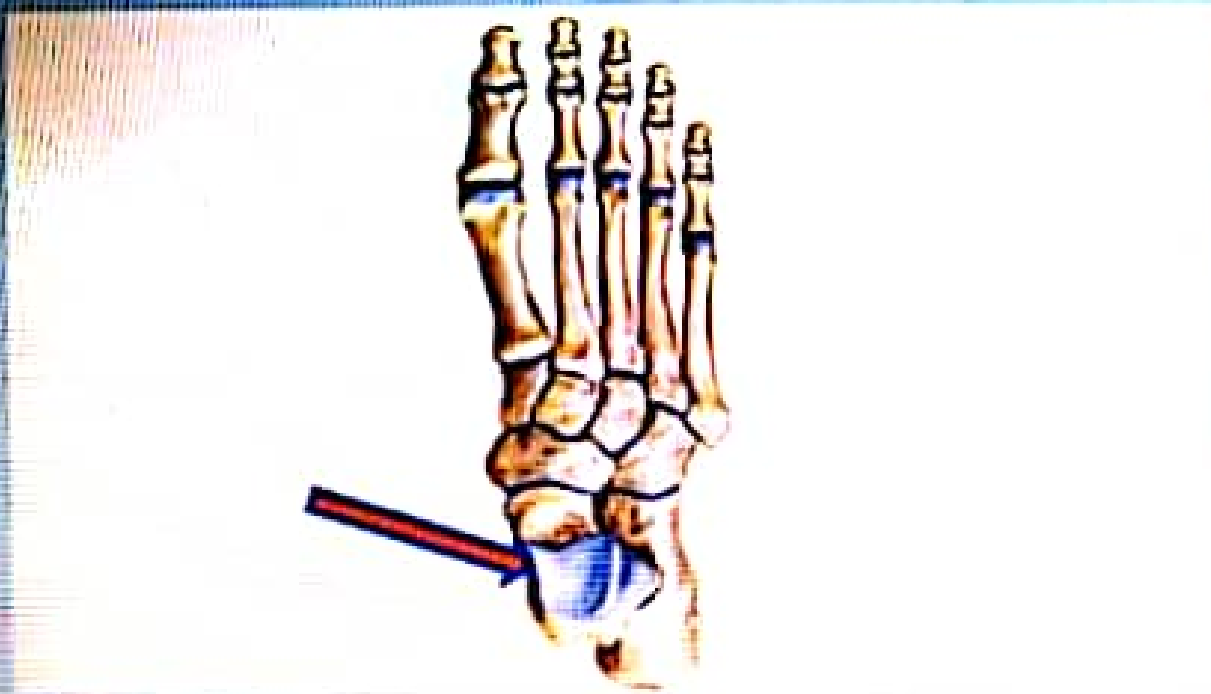

Select one.

- a Upper medial border of popliteal fossa
- b Lower lateral border of popliteal fossa
- c Lower medial border of popliteal fossa
- d Upper lateral border of popliteal fossa
- e Root of popliteal fossa

Next page

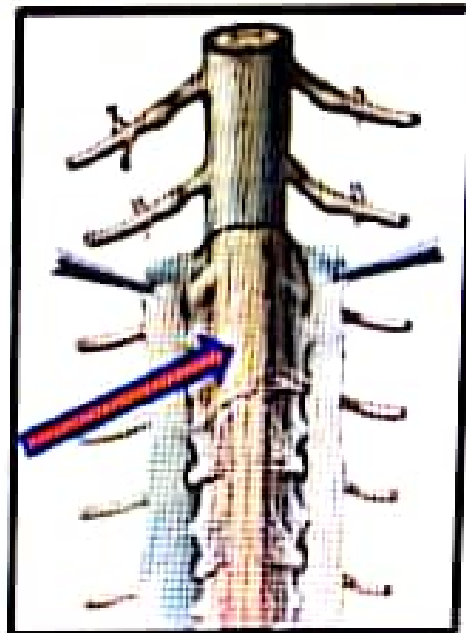
What is the labeled structure?



Select one:

- a. Cuboid bone
- b. Talus bone
- c. Calcaneus bone
- d. Navicular bone
- e. Metatarsal bone

What is the labeled structure?



Select one:

- a. The pia mater of spinal cord
- b. The subarachnoid space
- c. The arachnoid mater of spinal cord
- d. Denticulate ligament
- e. The dura mater of spinal cord

Data Mode ?

Go to Text Only

← اناتومي فاينل (كورونا) جلسة ٢

May 30, 2020 · 🧑

امتحان سهل جدا



1



Like



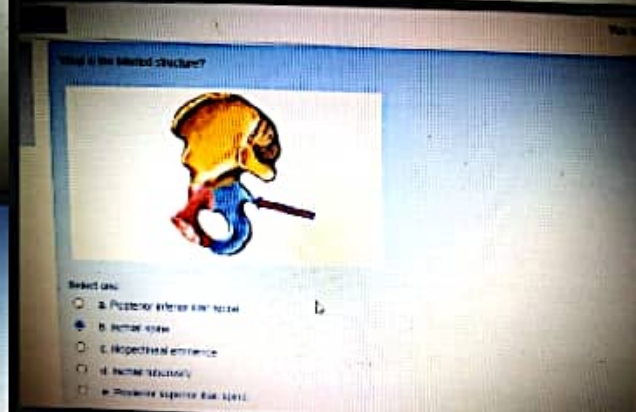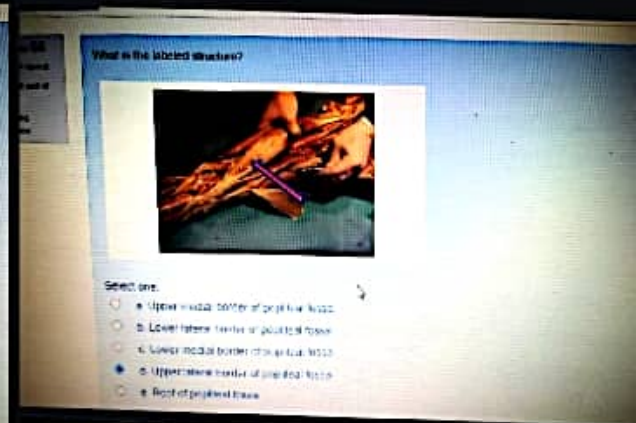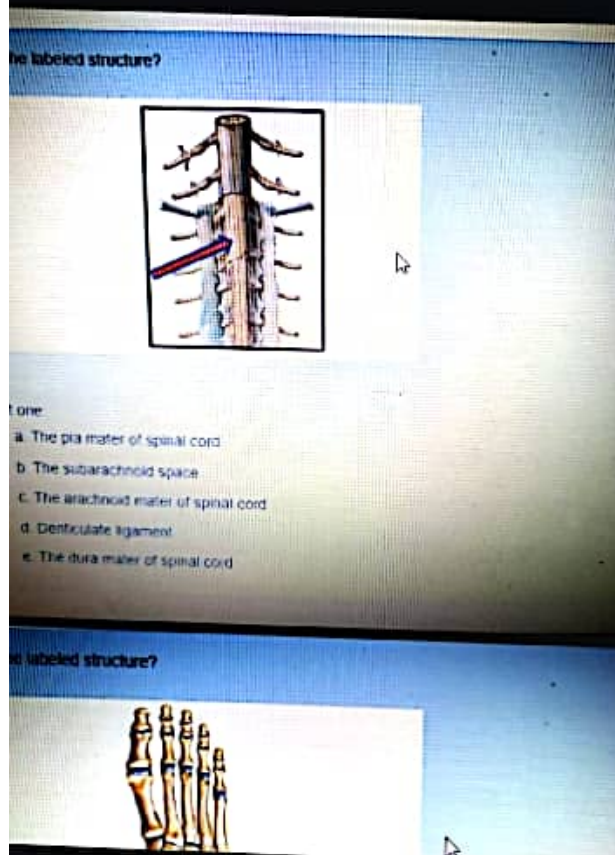
Comment



... اناتومي فاينل (كورونا) عكرمة هياجنة
٢ جلسة

May 30, 2020 · 🧑


بالتوفيق



Data Mode ?

Go to Text Only

← اناتومي فاينل (كورونا) جلسة ٢



Like



Comment



Jumana Khreisat ▶ اناتومي

٢ فاينل (كورونا) جلسة

May 30, 2020 · 🌐



Muscle prevent tilting of the pelvis to unsupported side = gluteus medius



1



Like



Comment



Rama ShAmyleh ▶ اناتومي

٢ فاينل (كورونا) جلسة

May 30, 2020 · 🌐



-Which of the following muscle inverted the foot ?

Tibialis anterior ✓

حسب السلايد المذكور اجابتين بشكل عام
بس في الشرح التفصيلي للعضلات مش المذكور الا للـ

Tibialis anterior



Naba Jehad and 1 other

Respond ▾



Data Mode ?

Go to Text Only

← اناتومي فاينل (كورونا) جلسة ٢

Danyah Tarawneh and 3 others



Like



Comment

Jumana Khreisat ▶ اناتومي
٢ فاينل (كورونا) جلسة

May 30, 2020 · 🌐

Correct about cerebellum =
Vermis is the name given to that part joining
the cerebellar hemisphere together.



Danyah Tarawneh and 4 others



Like



Comment


Jumana Khreisat ▶ اناتومي
٢ فاينل (كورونا) جلسة

May 30, 2020 · 🌐

Intermediate part of foot supplied by =
superficial peroneal nerve.



Naba Jehad and 2 others



Respond ▾



Data Mode ?

Go to Text Only

← اناتومي فاينل (كورونا) جلسة ٢


اناتومي ▶
٢ فاينل (كورونا) جلسة

May 30, 2020 · 🌐

False number of spinal nerve =
7 cervical.



Danyah Tarawneh and 5 others



Like



Comment


اناتومي ▶
٢ فاينل (كورونا) جلسة

May 30, 2020 · 🌐

Boundaries of popliteal fossa except =
Ischial part of adductor magnus.



Danyah Tarawneh and 3 others



Like



Comment



اناتومي ▶




Respond ▼



Data Mode ?

Go to Text Only

← اناتومي فاينل (كورونا) جلسة ٢

  Danyah Tarawneh and Naba Jehad

Like



Comment





Jumana Khreisat ▶ اناتومي

٢ فاينل (كورونا) جلسة

May 30, 2020 · 🌐

Urinary bladder wrong statement =
Base of bladder faces inferiorly.

  Danyah Tarawneh and 4 others

Like



Comment



Jumana Khreisat ▶ اناتومي

٢ فاينل (كورونا) جلسة

May 30, 2020 · 🌐

Cross section of spinal nerve false =
Thin white commissure.

  Danyah Tarawneh and 1 other

11 comments



Like



Comment

Respond ▼

...



Data Mode ?

Go to Text Only

← اناتومي فاينل (كورونا) جلسة ٢



Like



Comment




Jumana Khreisat ▶ اناتومي

٢ فاينل (كورونا) جلسة

May 30, 2020 · 🌐

Sural nerve branch from=
Tibial nerve.

👍 Naba Jehad and 1 other



Like



Comment




Jumana Khreisat ▶ اناتومي

٢ فاينل (كورونا) جلسة

May 30, 2020 · 🌐

Muscle inserted upper part of medial surface=
Sartorius muscle.

👍👤 Danyah Tarawneh and Naba Jehad



Like



Comment

Respond ▾



Data Mode ?

Go to Text Only

← اناتومي فاينل (كورونا) جلسة ٢

RECENT ACTIVITY



Jumana Khreisat ▶ اناتومي

٢ فاينل (كورونا) جلسة

May 30, 2020 · 🌐



Muscle arises from both tibia and fibula =
Tibialis posterior.

Naba Jehad



Like



Comment



Jumana Khreisat ▶ اناتومي

٢ فاينل (كورونا) جلسة

May 30, 2020 · 🌐



Brainstem wrong =
Totally from the hindbrain.

Naba Jehad and 1 other



Like



Comment



Jumana Khreisat ▶ اناتومي



Respond ▾

