

Which is wrong for the adductor canal?

Select one:

- a. Named sub sartorial canal
- b. Named Hunter's canal
- c. It is a tunnel in the middle third of the thigh
- d. Begins at apex of femoral triangle
- e. Contains the sural nerve

Which is wrong of the following regarding the cerebellum?

Select one:

- a. The cerebellar cortex is composed of white matter
- b. Lies posterior to the pons and the medulla oblongata
- c. The cerebellar cortex is thrown into folds (folia)
- d. The median portion is the vermis
- e. Lies within the posterior cranial fossa

Which of the following's muscle protects of the lateral meniscus?

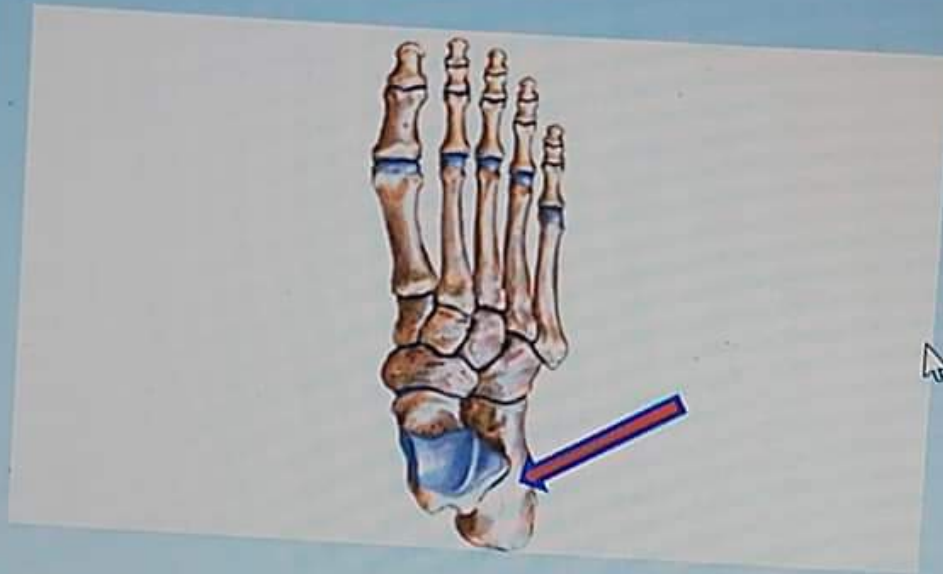
tion 59

er saved

ed out of

g
on

What is the labeled structure?



Select one:

- a. Cuboid bone
- b. Talus bone
- c. Calcaneus bone
- d. Navicular bone
- e. Metatarsal bone

60

What is the labeled structure?

102-1: Gener...



General Anatomy...

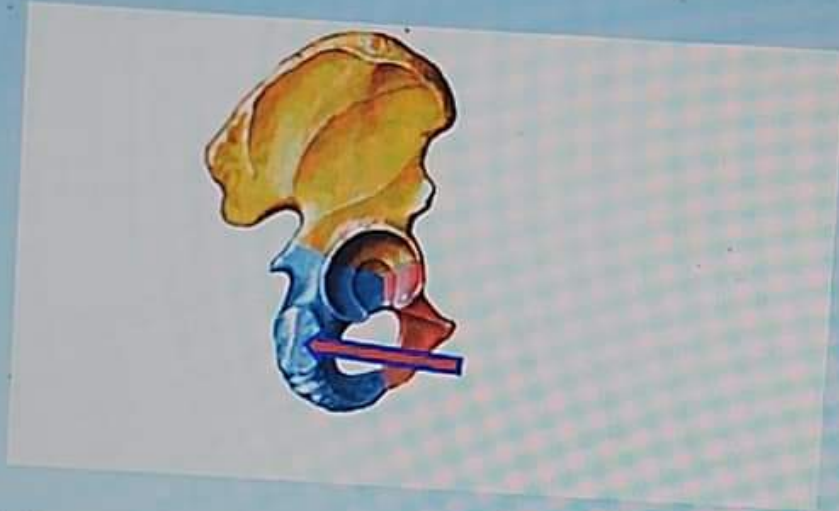

on 60

saved

out of

What is the labeled structure?



Select one:

- a. Origin of Semimembranosus muscle
- b. Origin of Biceps muscle
- c. Origin of adductor magnus muscle
- d. Origin of Semitendinosus muscle
- e. Origin of quadratus femoris muscle

02-1: Gener...



General Anatomy...



Question 51

Answer saved

Marked out of 1.00

Flag question

Which of the following muscles arises from the lateral surface of the epicondyle?

Select one:

- a. Lateral head of gastrocnemius
- b. Soleus
- c. Medial head of gastrocnemius
- d. Popliteus
- e. Plantaris

Question 52

Answer saved

Marked out of 1.00

Flag question

One is wrong about adductor longus?


Select one:

- a. Adducts the thigh
- b. Inserted in the linea alba
- c. Anterior branch of obturator nerve supplies it
- d. Flexes the thigh
- e. Partly supplied by the sciatic

1501102-1: Gener...



General Anatomy...



علم التشريح العام

Which of the followings muscles arises from the lateral surface of the lateral condyle of the femur above the lateral epicondyle?

Select one:

- a. Lateral head of gastrocnemius
- b. Soleus
- c. Medial head of gastrocnemius
- d. Popliteus
- e. Plantaris

One is wrong about adductor longus?

Select one:

- a. Adducts the thigh
- b. Inserted in the linea alba
- c. Anterior branch of obturator nerve supplies it
- d. Flexes the thigh
- e. Partly supplied by the sciatic



General Anatomy...



All of the followings forms the medial longitudinal arch except?

Select one:

- a. Calcaneus
- b. Cuboid
- c. Navicular
- d. Talus
- e. Cuneiform

All of the followings are lateral rotator the of hip joint except?

Select one:

- a. Piriformis
- b. Obturator externus
- c. Adductor magnus
- d. Obturator Internus
- e. Quadratus Femoris



- b. Obturator externus
- c. Adductor magnus
- d. Obturator Internus
- e. Quadratus Femoris

15

ed
of

All of the following's muscles are deep to gluteus maximus except?


Select one:

- a. Gluteus medius
- b. Piriformis
- c. Quadratus femoris
- d. Tensor fascia lata
- e. Gluteus minimus

s page

102-1: Gener...

General Anatomy...



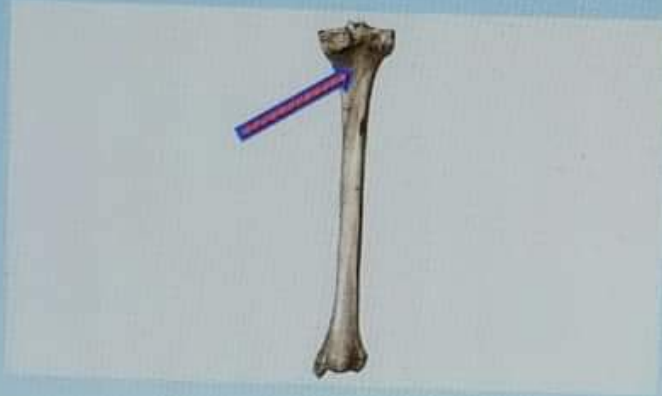Question 1

Answer saved

Marked out of 1.00


Flag question

What is the labeled structure?



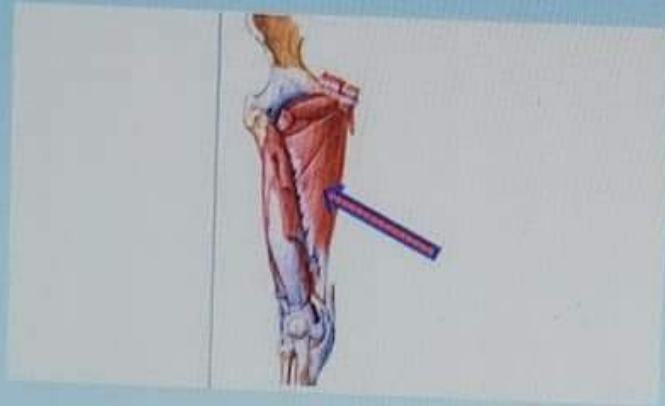
Select one:

- a. Right popliteus
- b. Left soleus
- c. Right tibialis posterior
- d. Left popliteus
- e. Right soleus



Question 2
Answer saved
Marked out of
1.00
Flag
question

What is the labeled structure?




Select one:

- a. Adductor magnus
- b. Obturator internus
- c. Adductor brevis
- d. Obturator externus
- e. Adductor longus

Question 3
Answer saved
Marked out of
1.00

All the following located in the medulla of the kidney Except?

Select one:



Question 3

Answer saved

Marked out of 1.00

Flag question

All the following located in the medulla of the kidney Except?

Select one:

- a. The renal papilla
- b. The renal columns
- c. The medullary rays
- d. The renal pyramids
- e. Interlobar arteries

Question 4

Answer saved

Marked out of 1.00

Flag question

The sural nerve is branch of?



Select one:

- a. Common peroneal nerve
- b. Tibial nerve
- c. Deep peroneal nerve
- d. Sciatic nerve
- e. Superficial peroneal nerve

Question 5

Answer saved

What is the labeled structure?



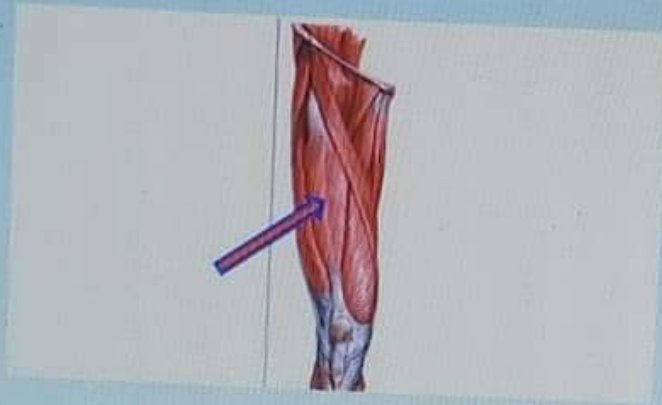
Question 5

Answer saved

Marked out of 1.00


Flag question

What is the labeled structure?



Select one:

- a. Vastus lateralis
- b. Vastus intermedius
- c. Sartorius
- d. Rectus femoris
- e. Vastus medialis



1501102-3: Gener...



General Anatomy...



علم التشريح العام/الدفعة 1

Question 6

Not saved

1 out of 1

g
on

Which of the following muscles is inserted at the groove on the back of the medial condyle of the tibia?

Select one:

- a. Semimembranosus
- b. Biceps femoris
- c. Ischial part of adductor magnus
- d. Semitendinosus
- e. Quadratus femoris

Question 7

Not saved

1 out of 1

g
on

Inversion and eversion are movements of?


Select one:

- a. Calcaneo-navicular joint
- b. Ankle joint
- c. Intertarsal joint
- d. Talo-calcaneo-navicular joint
- e. Talo-navicular joint

501102-1: Gener...



General Anatomy...



Which of the following's muscles acted like the top gear of car?

Select one:

- a. Tibialis posterior
- b. Soleus
- c. Flexor hallucis longus
- d. Gastrocnemius
- e. Flexor digitorum longus

Choose the correct of the following statements concern the peripheral nervous system?

Select one:

- a. There are 10 pairs of cranial nerves
- b. There are 8 pairs of cervical spinal nerves.
- c. The posterior root of a spinal nerve contains many efferent motor nerve fibers.
- d. A spinal nerve is formed by the union of an anterior and a posterior ramus in an intervertebral foramen
- e. A posterior root ganglion contains the cell bodies of autonomic nerve fibers leaving the spinal cord

What is the labeled structure?

2-3: Gener...

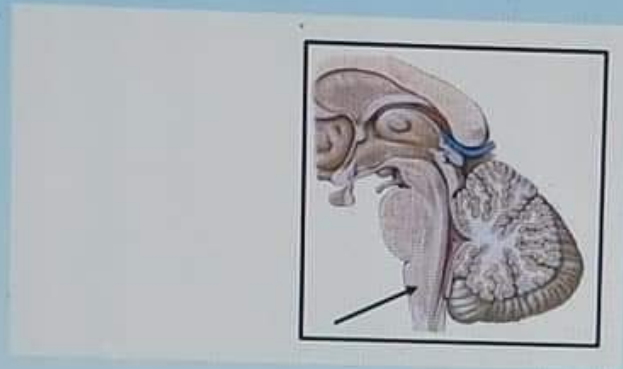
General Anatomy...



- e. A posterior root ganglion contains the cell bodies of autonomic nerve fibers leaving the spinal cord

0
ed
of

What is the labeled structure?



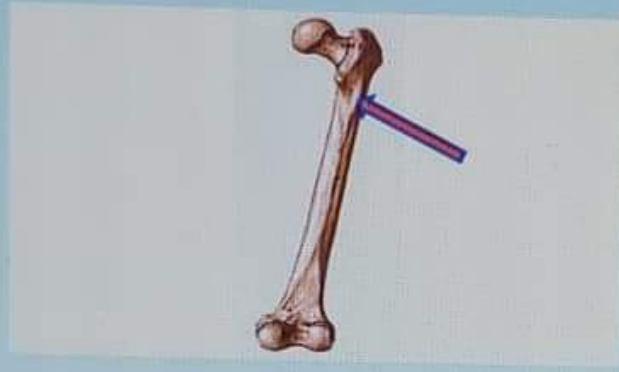Select one:

- a. The medulla oblongata
- b. The spinal cord
- c. The pons
- d. The midbrain
- e. The vermis



Question 11
Not saved
1 out of 10
100%

What is the labeled structure?




Select one:

- a. Spiral line
- b. Lateral lip of the linea aspera
- c. Gluteal tuberosity
- d. Linea aspera
- e. Medial lip of the linea aspera

1501102-1: Gener...

General Anatomy...



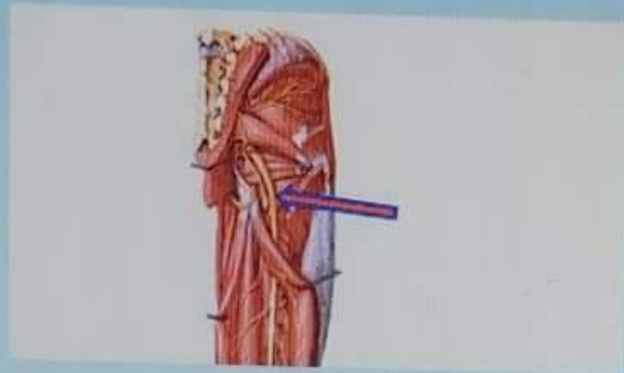
Question 12

Answer saved

Marked out of 1.00

Flag question

What is the labeled structure?



Select one:

- a. Superior gluteal nerve
- b. Posterior cutaneous nerve of the thigh
- c. Pudendal nerve
- d. Sciatic nerve
- e. Inferior gluteal nerve


Question 13

Answer saved

Marked out of 1.00

The forebrain includes the following Except?

Select one:



Question 13

Answer saved

Marked out of 10

Flag question

The forebrain includes the following Except?

Select one:

- a. The cerebrum
- b. Thalamus
- c. Hypothalamus
- d. Cerebellum
- e. The diencephalon is almost completely hidden from the surface of the brain

Question 14

Answer saved

Marked out of 10

Flag question

The following are parts of uterine tube Except?

Select one:

- a. The cervix
- b. The ampulla
- c. The infundibulum
- d. The isthmus
- e. The intramural part

Question 15

Answer saved

All of the followings pass deep to the extensor retinaculum except?

1501102-1: Gener...

General Anatomy...



Flag question

- b. The ampulla
- c. The infundibulum
- d. The isthmus
- e. The intramural part

Question 15

Answer saved

Marked out of 10


Flag question

All of the followings pass deep to the extensor retinaculum except?

Select one:

- a. Tibialis anterior muscle
- b. Extensor digitorum longus muscle
- c. Peroneus tertius muscle
- d. Extensor hallucis longus- muscle
- e. Extensor digitorum brevis muscle

Previous page



علم التشريح العام/الدفعة الاولى

Question 16

Answer saved

Marked out of 1.00

Flag question

Which of the following's muscles inserted in the top of the greater trochanter?

Select one:

- a. Gluteus medius
- b. Piriformis
- c. Quadratus femoris
- d. Obturator internus
- e. Gluteus minimus

Question 17

Answer saved



Marked out of 1.00

Flag question

Which of the following's muscles attached to the 5th metatarsal bone?

Select one:

- a. Peroneus tertius and longusB. Tibialis anterior and extensor digitorum brevis
- b. Extensor digitorum longus and brevis
- c. Peroneus tertius and brevis
- d. Tibialis anterior and extensor hallucis brevis



Question 18

Answer saved

Marked out of 1.00

Flag question

What are the meaning of lateral deviation of the big toe?

Select one:

- a. Talipes Calcaneus
- b. Hallux Valgus
- c. Flat Foot
- d. Talipes Equinus
- e. Pes Cavus

Question 19

Answer saved

Marked out of 1.00

Flag question

All the hamstring muscles are supplied by sciatic nerve except?

Select one:

- a. Semimembranosus
- b. Long head of biceps femoris
- c. Ischial part of adductor magnus
- d. Semitendinosus
- e. Short head of biceps femoris



Question 20

Answer saved

Marked out of

The medial part of the foot is supplied by?

Select one:



Answer saved

Marked out of 1.00

Flag question

All the remaining muscles are supplied by sciatic nerve except

Select one:

- a. Semimembranosus
- b. Long head of biceps femoris
- c. Ischial part of adductor magnus
- d. Semitendinosus
- e. Short head of biceps femoris

Question 20

Answer saved

Marked out of 1.00



Remove flag

The medial part of the foot is supplied by?

Select one:

- a. Sural nerve
- b. Deep peroneal nerve
- c. Saphenous nerve
- d. Tibial nerve
- e. Superficial peroneal nerve

Previous page



علم التشريح العام/الدفعة الاولى

Question 21

Answer saved

Marked out of 1.00

Flag question

Which is not true for the femoral triangle?

Select one:

- a. It lies just below the inguinal ligament
- b. The Sartorius is its lateral boundary
- c. The adductor longus muscle is its medial boundary
- d. it contains the femoral artery and its branches
- e. It contains adductor magnus in its floor

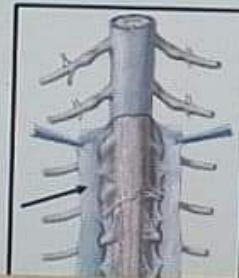Question 22

Answer saved


Marked out of 1.00

Flag question

What is the labeled structure?



Taskbar showing browser tabs: 1501102-1: Gener..., General Anatomy... and various application icons (Chrome, Firefox, Edge, etc.).



- e. It contains adductor magnus in its floor


Question 22

Answer saved

Marked out of 1.00


Flag question

What is the labeled structure?



Select one:

- a. The pia mater of spinal cord
- b. The subarachnoid space
- c. The arachnoid mater of spinal cord
- d. Denticulate ligament
- e. The dura mater of spinal cord



- c. The arachnoid mater of spinal cord
- d. Denticulate ligament
- e. The dura mater of spinal cord

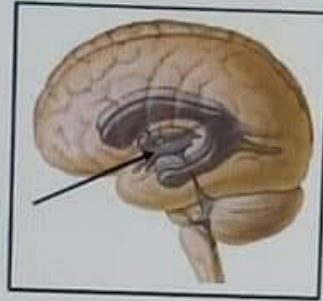
Question 23

Answer saved

Marked out of 1.00


Remove flag

What is the labeled structure?



Select one:

- a. Cerebral aqueduct
- b. The third ventricle
- c. The cerebellum
- d. The fourth ventricle
- e. The lateral ventricle



Question 24

Answer saved

Marked out of 1.00

Flag question

How many lumbricals muscles?

Select one:

- a. 3
- b. 14
- c. 4
- d. 7
- e. 8

Question 25

Answer saved


Marked out of 1.00

Flag question

The obturator externus muscle is inserted on?

Select one:

- a. The greater trochanter
- b. The lesser trochanter
- c. The trochanteric fossa
- d. The head of femur
- e. The shaft of the femur



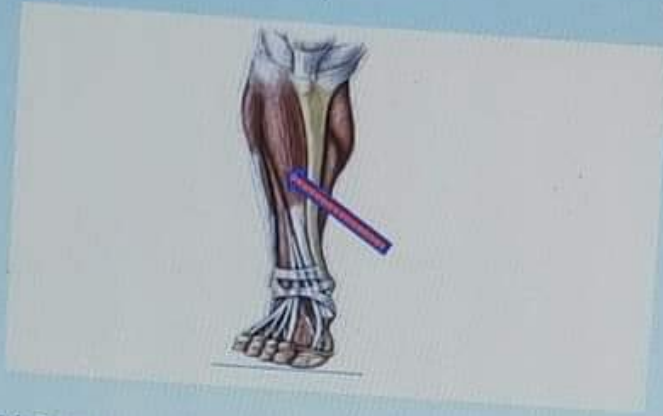Question 26

Answer saved

Marked out of 100

Flag question

What is the labeled structure?



Select one:

- a. Tibialis posterior muscle
- b. Tibia bone
- c. Extensor digitorum longus muscle
- d. Tibialis anterior muscle
- e. Flexor digitorum longus muscle

1501102-1: Gener...



General Anatomy...



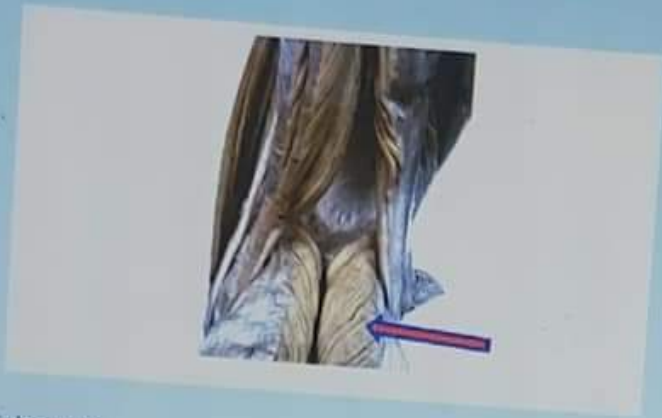Question 27

Answer saved

Marked out of 1.00

Flag question

What is the labeled structure?



Select one:

- a. Biceps muscle
- b. Lateral head of gastrocnemius muscles
- c. Semitendinosus muscle
- d. Medial head of gastrocnemius muscles
- e. Semimembranosus muscle

Question 28

Answer saved

Marked out of 1.00

All of the following are sciatic nerve bed except?

Select one:

01102-1: Gener...

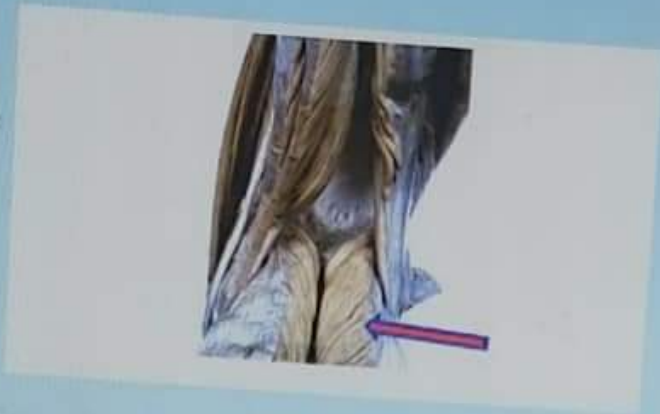

General Anatomy...



Question 27
Answer saved
Marked out of
1.00
Flag
Question

What is the labeled structure?



Select one:


- a. Biceps muscle
- b. Lateral head of gastrocnemius muscles
- c. Semitendinosus muscle
- d. Medial head of gastrocnemius muscles
- e. Semimembranosus muscle

Question 28
Answer saved
Marked out of

All of the followings are sciatic nerve bed except?

Select one:

1501102-1: Gener... General Anatomy... [Internet Explorer icon] [YouTube icon] [Windows Store icon] [Edge icon] [File Explorer icon]



Question 28

Not saved
0 out of 1

All of the following are sciatic nerve bed except?

Select one:

- a. Adductor magnus muscle
- b. Inferior gemellus muscle
- c. Quadratus femoris muscle
- d. Obturator externus muscle
- e. Superior gemellus muscle

Question 29

Not saved
0 out of 1

Select the correct of the following statements concern the cerebrum?

Select one:

- a. The cerebral hemispheres are separated by a fibrous septum called the tentorium cerebelli
- b. Each hemisphere extends from the frontal to the occipital bones in the skull
- c. The corpus callosum is a mass of gray matter lying within each cerebral hemisphere
- d. The basal nuclei masses of white matter within each cerebral hemisphere
- e. The cavity present within each cerebral hemisphere is called the cerebral ventricle

Question 30

Not saved

What is the labeled structure?

01102-1: Gener...

General Anatomy...



- e. The cavity present within each cerebral hemisphere is called the cerebral ventricle

Question 30

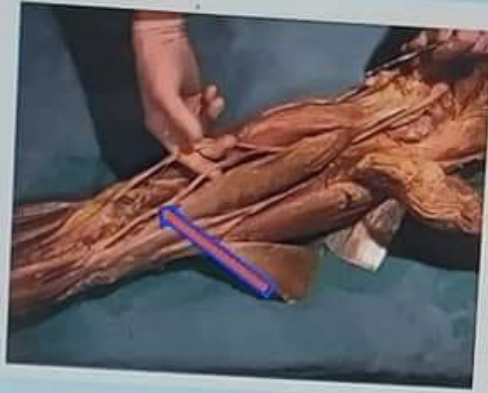
Never saved

Marked out of

1.00

0.00

What is the labeled structure?



Select one:

- a. Femoral nerve
- b. Sciatic nerve
- c. Tibial nerve
- d. Sural nerve
- e. Common peroneal nerve

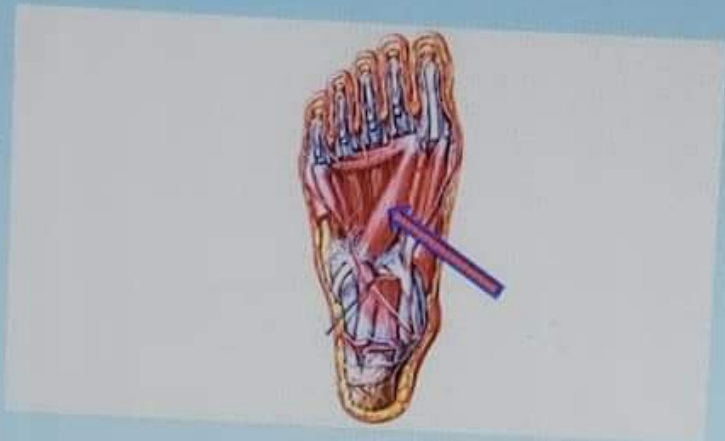001102-1: Gener...

General Anatomy...



Question 31
Answer saved
Marked out of 1.00
Flag question

What is the labeled structure?





Select one:

- a. Transverse head of adductor hallucis
- b. Oblique head of adductor hallucis
- c. Flexor hallucis brevis
- d. Oblique head of abductor hallucis
- e. Transverse head of abductor hallucis

Question 32
Answer saved
Marked out of

Select the false statement regarding the spinal cord?

Select one:



Select one:

- a. Transverse head of adductor hallucis
- b. Oblique head of adductor hallucis
- c. Flexor hallucis brevis
- d. Oblique head of abductor hallucis
- e. Transverse head of abductor hallucis

Question 32

Answer saved

Marked out of 0

Flag question

Select the false statement regarding the spinal cord?

Select one:

- a. It is continuous with the medulla oblongata of the brain
- b. It tapers off below into the conus medullaris
- c. Begins superiorly at the foramen magnum
- d. Roughly cylindrical in shape
- e. It terminates inferiorly in the sacral region

Question 33

Answer saved

Marked out of 0

What is the main extensor of the hip joint?

Select one:

- a. Gluteus minimus

1501102-1: Gener...

General Anatomy...



Question 33

Answer saved

Marked out of 1.00

Flag question

What is the main extensor of the hip joint?

Select one:

- a. Gluteus minimus
- b. Quadratus Femoris
- c. Gluteus maximus
- d. Tensor fascia lata
- e. Gluteus medius

Question 34

Answer saved

Marked out of 1.00

Flag question

All of the followings are muscles of the anterior compartment of the leg except?

Select one:

- a. Extensor hallucis longus- muscle
- b. Extensor digitorum longus muscle
- c. Peroneus tertius muscle
- d. Tibialis anterior muscle
- e. Extensor digitorum brevis muscle


Question 35

Answer saved

Marked out of 1.00

Flag question

Which tendon presents in the fourth layer of sole of foot?



Answer saved

Marked out of 1.00

Flag question

All of the followings are muscles of the anterior compartment of the leg except:

Select one:

- a. Extensor hallucis longus- muscle
- b. Extensor digitorum longus muscle
- c. Peroneus tertius muscle
- d. Tibialis anterior muscle
- e. Extensor digitorum brevis muscle

Question 35

Answer saved

Marked out of 1.00

Flag question

Which tendon presents in the fourth lay of sole of foot?

Select one:

- a. Tendons of tibialis posterior
- b. Tendons of flexor digitorum longus
- c. Tendons of tibialis anterior
- d. Tendons of flexor hallucis longus
- e. Tendons of extensor digitorum longus

Previous page

1501102-1: Gener...

General Anatomy...



علم التشريح العام/الدفعة الاولى

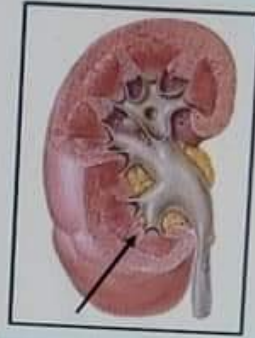
Question 36

Answer saved

Marked out of 1.00

Flag question

What is the labeled structure?



Select one:

- a. The cortex
- b. The renal pyramids
- c. The renal columns
- d. The medullary rays
- e. The renal papilla



1501102-1: Gener...



General Anatomy...



Power



Question 37

Answer saved

Marked out of 1.00

Flag question

Main knee movements are?

Select one:

- a. Dorsiflexion and Plantar flexion
- b. Gliding
- c. Circumduction
- d. Flexion and extension
- e. Abduction and adduction

Question 38

Answer saved

Marked out of 1.00

Flag question

Which of the following's muscles inserted in the plantar surface of base of the first metatarsal bo

Select one:

- a. Tibialis posterior
- b. Peroneus longus
- c. Flexor digitorum longus
- d. Peroneus brevis
- e. Flexor hallucis longus

Question 39

Answer saved

The action of the pectineus includes?

1501102-1: Gener...

General Anatomy...



Question 39

Answer saved

Marked out of 1.00

Flag question

The action of the pectineus includes?

Select one:

- a. Hip flexion
- b. Hip abduction
- c. Hip extension
- d. Knee flexion
- e. Knee extension

Question 40

Answer saved




Marked out of 1.00

Flag question

All of the followings support the longitudinal arch except?

Select one:

- a. Tendons of flexor digitorum longus
- b. Tendons of peroneus longus
- c. Flexor digitorum brevis
- d. Long plantar ligament
- e. Tendons of tibialis posterior



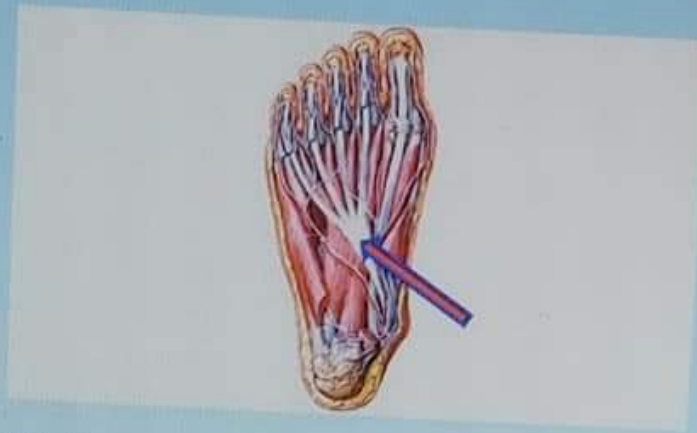
Question 41

Answer saved

Marked out of 1.00

Flag question

What is the labeled structure?



Select one:

- a. Peroneus longus
- b. Flexor digitorum longus
- c. Peroneus brevis
- d. Flexor accessories
- e. Lumbricals

Question 42


Answer saved

Marked out of

Paralysis of all muscles of the leg and foot due to injury of?

Select one:

Taskbar showing icons for Google Chrome, Microsoft Edge, and various applications. The taskbar also displays the text '1501102-1: Gener...' and 'General Anatomy...'.



Question 42

Answer saved

Marked out of 1.00

Flag question

Paralysis of all muscles of the leg and foot due to injury of?

Select one:

- a. Common peroneal nerve
- b. Tibial nerve
- c. Deep peroneal nerve
- d. Sciatic nerve
- e. Superficial peroneal nerve

Question 43

Answer saved

Marked out of 1.00

Flag question


All of the followings are supplied by lateral plantar nerve except?

Select one:

- a. Adductor hallucis muscle
- b. Flexor digitorum accessories muscle
- c. Abductor hallucis muscle
- d. The second lumbricals muscle
- e. Abductor digiti minimi muscle

Question 44

All of the followings are contents of the second layer of the sole of foot except?



- e. Abductor digiti minimi muscle

Question 44

Answer saved

Marked out of 1.00

Flag question

All of the followings are contents of the second layer of the sole of foot except?

Select one:

- a. Tendon of flexor digitorum longus
- b. The first Lumbrical muscle
- c. Flexor digitorum accessories
- d. Tendon of flexor digitorum brevis
- e. Tendon of flexor hallucis longus

Question 45

Answer saved

Marked out of 1.00

Flag question

The tendocalcaneus receives the insertion of?

Select one:

- a. Soleus and gastrocnemius
- b. Flexor hallucis longus and flexor digitorum longus
- c. Soleus and popliteus
- d. Flexor digitorum longus and plantaris
- e. Gastrocnemius and flexor digitorum longus



1501102 -1: Gener...



General Anatomy...



علم التشريح العام/الدفعة الاولى

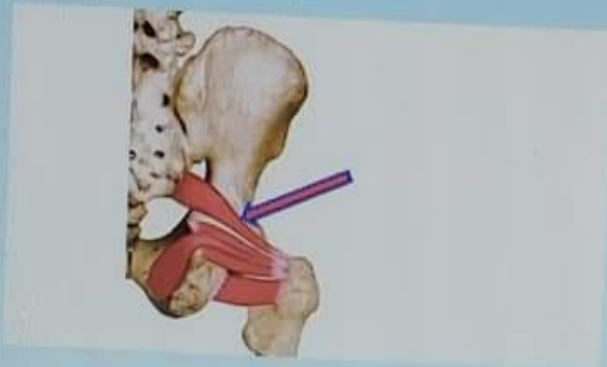
Question 46

Answer saved

Marked out of 1.00

Flag question


What is the labeled structure?



Select one:

- a. Obturator externus muscle
- b. Obturator internus muscle
- c. Superior gemellus muscle
- d. Inferior gemellus muscle
- e. Piriform muscle

Waiting for med-elearn.mutah.edu.jo...



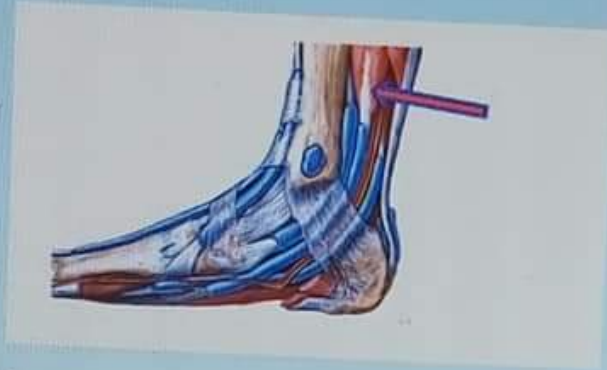
Question 47

Answer saved

Marked out of 1.00

Flag question

What is the labeled structure?



Select one:



- a. Tibialis posterior muscle
- b. Tibia bone
- c. Extensor digitorum longus muscle
- d. Tibialis anterior muscle
- e. Flexor digitorum longus muscle

Question 48

Answer saved

Marked out of 1.00

What is the labeled structure?



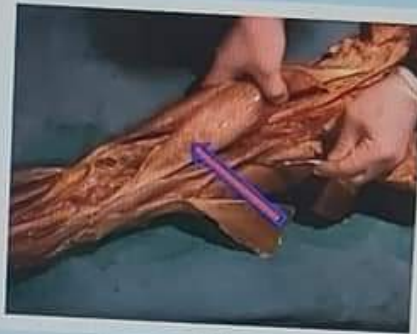Question 48

Answer saved

Marked out of 1.00

Flag question

What is the labeled structure?



Select one:

- a. Semitendinosus muscle
- b. Lateral head of gastrocnemius muscle
- c. Medial head of gastrocnemius muscle
- d. Biceps muscle
- e. Semimembranosus muscle

Question 49

Answer saved

Marked out of

The ureter has the following except?

Select one:



Question 49

Answer saved

Marked out of 1.00

Flag question

The ureter has the following except?

Select one:

- a. Is a muscular tube
- b. 25 cm in length
- c. Enters the pelvis in front of the sacroiliac joint
- d. Possesses five constrictions
- e. Is crossed near its termination by the vas deferens in male


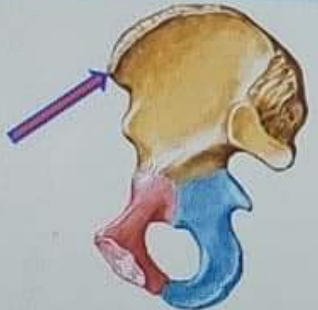
Question 50

Answer saved

Marked out of 1.00

Flag question

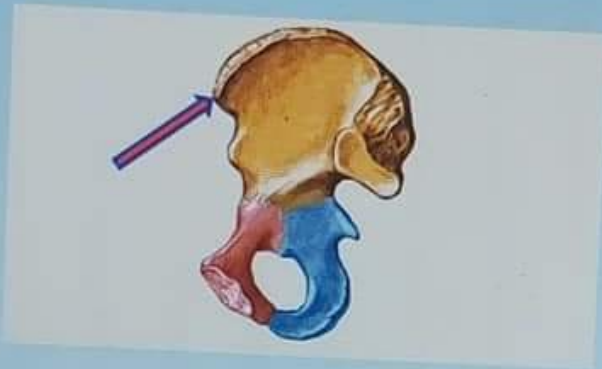
What is the labeled structure?



Medicine College

Question 50
Answer saved
Marked out of 1.00
Flag question


What is the labeled structure?



Select one:

- a. Posterior inferior iliac spine
- b. Anterior superior iliac spine
- c. Iliopectineal eminence
- d. Anterior inferior iliac spine
- e. Posterior superior iliac spine

Previous page



علم التشريح العام/الدفعة

1

ed

of

Which of the followings muscles arises from the lateral surface of the lateral condyle of the femur above the lateral epicondyle?

Select one:

- a. Lateral head of gastrocnemius
- b. Soleus
- c. Medial head of gastrocnemius
- d. Popliteus
- e. Plantaris

2

ed

of

One is wrong about adductor longus?

Select one:

- a. Adducts the thigh
- b. Inserted in the linea alba
- c. Anterior branch of obturator nerve supplies it
- d. Flexes the thigh
- e. Partly supplied by the sciatic

02-1: Gener...

General Anatomy...



علم التشريح العام/الدفعة الاولى

Question 56

Answer saved

Marked out of 1.00

Flag question

Which is wrong for the adductor canal?

Select one:

- a. Named sub sartorial canal
- b. Named Hunter's canal
- c. It is a tunnel in the middle third of the thigh
- d. Begins at apex of femoral triangle
- e. Contains the sural nerve

Question 57

Answer saved


Marked out of 1.00

Flag question

Which is wrong of the following regarding the cerebellum?

Select one:

- a. The cerebellar cortex is composed of white matter
- b. Lies posterior to the pons and the medulla oblongata
- c. The cerebellar cortex is thrown into folds (folia)
- d. The median portion is the vermis
- e. Lies within the posterior cranial fossa



- c. Obturator Magnus
- d. Obturator Internus
- e. Quadratus Femoris

55

ved
ut of
ve


All of the following's muscles are deep to gluteus maximus except?

Select one:

- a. Gluteus medius
- b. Piriformis
- c. Quadratus femoris
- d. Tensor fascia lata
- e. Gluteus minimus

as page

Next pa



53

red
t of

All of the followings forms the medial longitudinal arch except?

Select one:

- a. Calcaneus
- b. Cuboid
- c. Navicular
- d. Talus
- e. Cuneiform

54

red
t of

All of the followings are lateral rotator the of hip joint except?

Select one:

- a. Piriformis
- b. Obturator externus
- c. Adductor magnus
- d. Obturator Internus
- e. Quadratus Femoris

55

102-1: Gener...

General Anatomy...



Medicine College

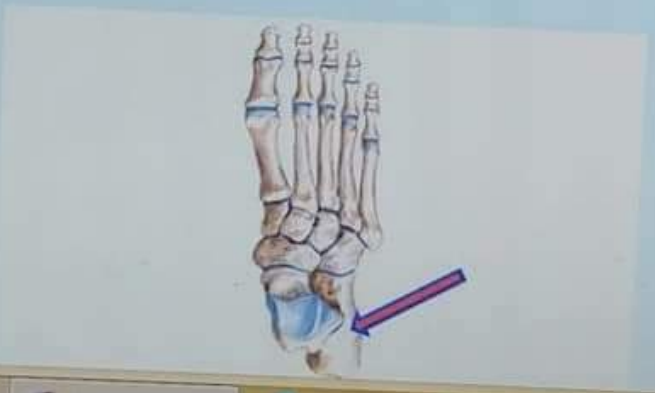Question 58
Answer saved
Marked out of 1.00
Flag question

Which of the following's muscle protects of the lateral meniscus?


- Select one:
- a. Lateral head of gastrocnemius
 - b. Soleus
 - c. Medial head of gastrocnemius
 - d. Popliteus
 - e. Plantaris

Question 59
Answer saved
Marked out of 1.00
Flag question

What is the labeled structure?



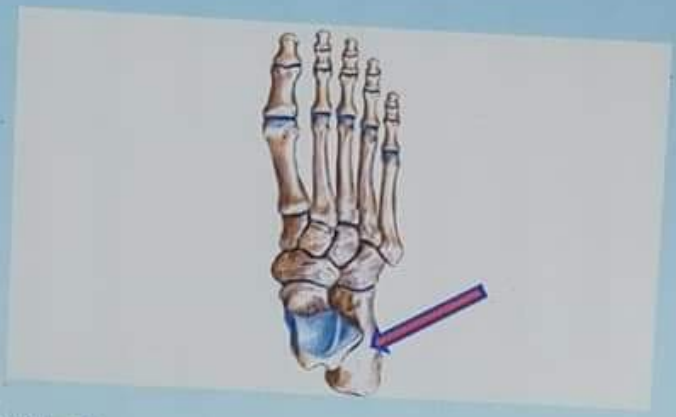Windows taskbar showing icons for Google Chrome, Microsoft Edge, and various applications. The taskbar includes the Start button, a search bar, and several pinned application icons.



Medicine College

Question 59
Answer saved
Marked out of 1.00
Flag question


What is the labeled structure?



- Select one:
- a. Cuboid bone
 - b. Talus bone
 - c. Calcaneus bone
 - d. Navicular bone
 - e. Metatarsal bone

Question 60
Answer saved
Marked out of

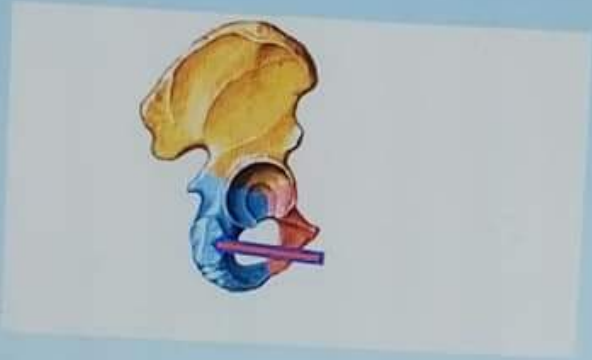
What is the labeled structure?



Medicine College

Question 60
Answer saved
Marked out of 1.00
Flag question

What is the labeled structure?



- Select one:
- a. Origin of Semimembranosus muscle
 - b. Origin of Biceps muscle
 - c. Origin of adductor magnus muscle
 - d. Origin of Semitendinosus muscle
 - e. Origin of quadratus femoris muscle

Previous page

Windows taskbar showing icons for Google Chrome, Microsoft Edge, and various applications. The taskbar includes a search icon, a task view icon, and several application icons.

