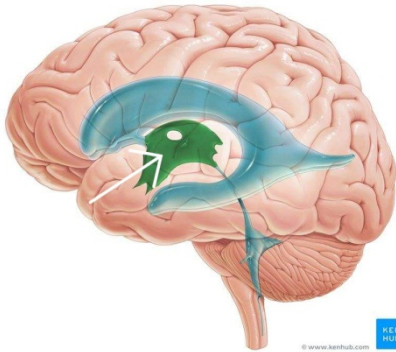




Archive Of Anatomy

1-What is the labeled structure?



- a-cerebral aqueduct
- b- the third ventricle
- c- the cerebellum
- d-the fourth ventricle
- e- the lateral ventricle

2-all of the following are sciatic nerve bed except:

- a-adductor magnus muscle
- b- inferior gemellus muscle
- c- obturator externus muscle
- d- quadratus femoris muscle
- e- superior gemellus muscle

3-select the correct of the following statements concern the cerebrum

- a- the cerebral hemispheres are separated by a fibrous septum called the tentorium cerebelli
- b- each hemisphere extends from the frontal to the occipital bones in the skull
- c- the corpus callosum is a mass of gray matter lying within each cerebral hemisphere

d- the basal nuclei masses of white matter within each cerebral hemisphere

e- the cavity present within each cerebral hemisphere is called cerebral ventricle

4- select the false statement regarding the spinal cord :

a- it is continuous with the medulla oblongata of the brain

b- it is taper off below into the conus medullaris

c- begins superiorly at the foramen magnum

d- roughly cylindrical in shape

e- it terminates inferiorly in the sacral region

5- what is the main extensor of hip joint ?

a- gluteus minimus

b- quadratus femoris

c- gluteus maximus

d tensor fascia lata

e-gluteus medius

6-all of the following are muscle of the anterior compartment of the leg except :

a- extensor hallucis longus muscle

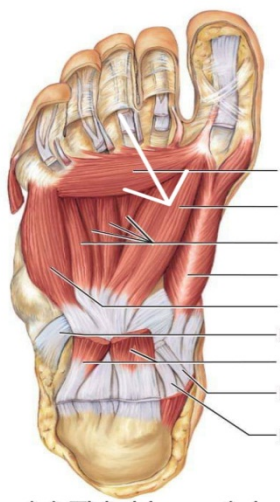
b-extensor digitorum longus muscle

c- peroneus tertius muscle

d- tibialis anterior muscle

e- extensor digitorum brevis muscle

7- what is the labeled structure ?



- a- transverse head of adductor hallucis
- b- oblique head of adductor hallucis
- c- flexor hallucis brevis
- d- oblique head of abductor hallucis
- e- transverse head of abductor hallucis

8- which tendon presents in the fourth layer of sole of foot ?

- a- tendon of tibialis posterior
- b- tendons of flexor digitorum longus
- c- tendons of tibialis anterior
- d- tendons of flexor hallucis longus
- e- tendons of extensor digitorum longus

9- main knee movements are?

- a- dorsiflexion and plantar flexion
- b- gliding
- c- circumduction
- d- flexion and extension
- e- abduction and adduction

10- which of the following muscles are inserted in the plantar surface of the first metatarsal bone :

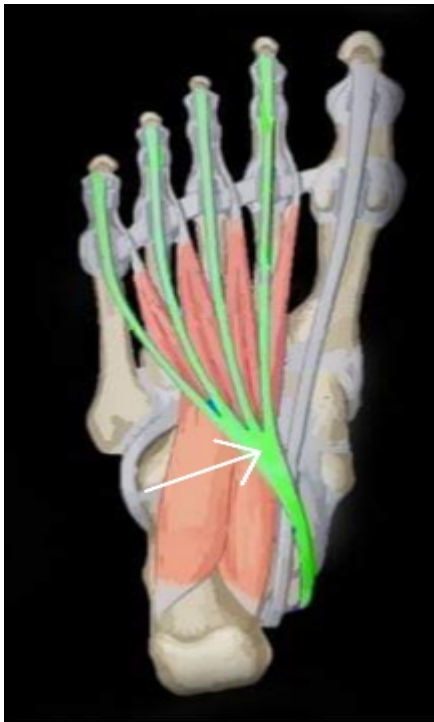
- a- tibialis posterior
- b- peroneus longus
- c- flexor digitorum longus
- d- peroneus brevis
- e- flexor hallucis longus

11- the action of the pectineus includes ?

- a- hip flexion
- b- hip abduction
- c- hip extension
- d- knee flexion
- e- knee extension

12-all of the followings support the longitudinal arch except ?

- a- tendons of flexor digitorum longus
- b- tendons of peroneus longus
- c- flexor digitorum brevis
- d- long plantar ligament
- e- tendons of tibialis posterior



13- what is the labeled structure ?

- a-peroneus longus
- b- flexor digitorum longus
- c- peroneus brevis
- d- flexor accessories
- e- lumbricals

14-paralysis of all muscle of the leg and foot due to injury of ?

a- common peroneal nerve

b- tibial nerve

c- deep peroneal nerve

d- sciatic nerve

e- superficial peroneal nerve

15- all of the followings are supplied by lateral plantar nerve except:

a- adductor hallucis muscle


b- flexor digitorum accessories muscle

c- abductor hallucis muscle

d- the second lumbricals muscle

e- abductor digiti minimi muscle

16-what is the labeled structure?



- a- semitendinosus muscle
- b- lateral head of gastrocnemius muscle
- c- medial head of gastrocnemius muscle
- d- biceps muscle
- e- semimembranosus muscle

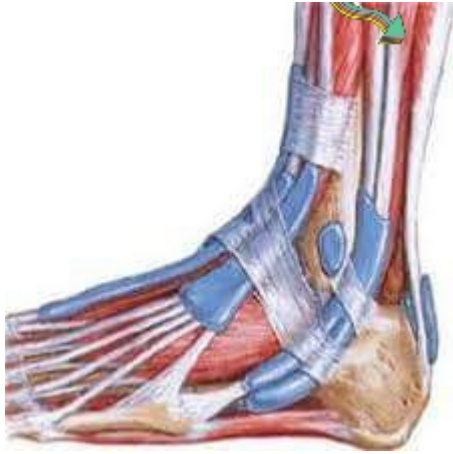17- all of the following are contents of the second layer of the sole of foot except :

- a- tendon of flexor digitorum longus
- b- the first lumbrical muscle
- c- flexor digitorum accessories
- d- tendon of flexor digitorum brevis
- e- tendon of flexor hallucis longus

18- the tendocalcaneus receives the insertion of :

- a- soleus and gastrocnemius
- b- flexor hallucis longus and flexor digitorum longus
- c- soleus and popliteus
- d- flexor digitorum longus and plantaris
- e- gastrocnemius and flexor digitorum longus

19 – what is the labeled structure ?



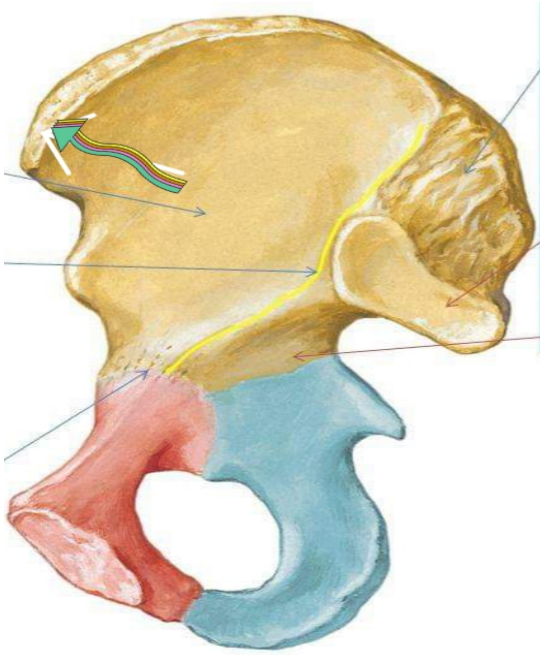
- a- tibialis posterior muscle
- b- tibia bone
- c- extensor digitorum longus muscle
- d- tibialis anterior muscle
- e- flexor digitorum longus muscle

20-the ureter has the following except :

- a- is a muscular tube
- b- 25 cm in length
- c- enters the pelvis in front of the sacroiliac joint
- d- possesses five constrictions
- e- is crossed near its termination by the vas deferens in male

21-what is the labeled structure?





- a- posterior inferior iliac spine
- b- anterior superior iliac spine
- c- iliopectineal eminence
- d- anterior inferior iliac spine
- e- posterior superior iliac spine

22-which of the following muscles arises from the lateral surface of the lateral condyle of the femur above the lateral cpicondyle?

- a- lateral head of gastrocnemius
- b-soleus
- c- medial head of gastrocnemius
- d- popliteus
- e-plantaris

23- one is wrong about adductor longus?

a- adducts the thigh

b- inserted in the linea alba

c- anterior branch of obturator nerve supplies it

d- flexes the thigh

e- partly supplied by the sciatic

24- which is wrong for the adductor canal ?

a- named sub sartorial canal

b- named hunter's canal

c- it is a tunnel in the middle third of the thigh

d- begins at apex of femoral triangle

e- contains the sural nerve

25- what is the labeled structure?

- a-obturator externus muscle
- b- obturator internus muscle
- c-superior gemellus muscle
- d- inferior gemellus muscle
- e- piriform muscle

26-which of the following's muscle protects of the lateral meniscus?

- a- lateral head of gastrocnemius
- b- soleus
- c- medial head of gastrocnemius
- d-popliteus
- e- plantaris

27-all of the followings are lateral rotator of hip joint except?

- a- piriformis
- b- obturator externus
- c- adductor magnus

d- obturator internus

e- quadratus femoris

28 all of the followings forms the medial longitudinal arch except :

a- calcaneus

b-cuboid

c-navicular

d-talus

e-cuneiform

29- all of the followings are lateral rotator of the hip joint except:

a- piriformis

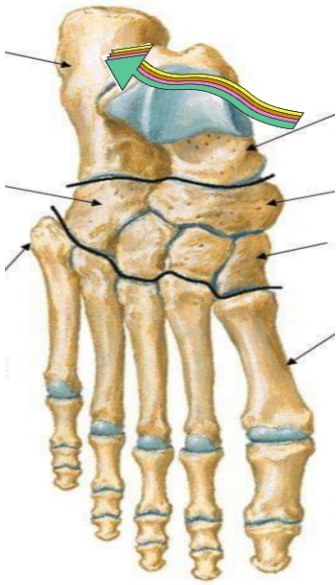
b- obturator externus

c-adductor magnus

d-obturator internus

e-quadratus femoris

30- what is the labeled structure?



a- cuboid bone

b-talus bone

c- calcaneus bone

d- navicular bone

e- metatarsal bone

31- which of the followings muscle protects of the lateral meniscus?

a- lateral head of gastronemius

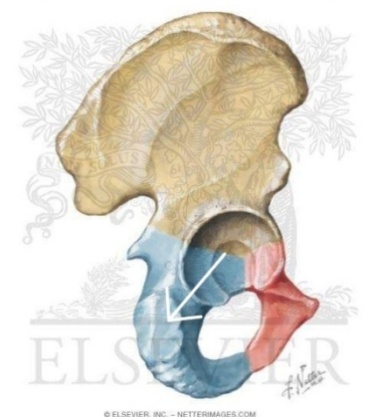
b- soleus

c- medial head of gastronemius

d- popliteus

e- plantaris

32-what is the labeled structure?



a- origin of semimembranosus muscle

b- origin of biceps muscle

c- origin of adductor magnus muscle

d- origin of semitendinosus

e- origin of quadratus femoris muscle

33- which is wrong of the following regarding the cerebellum?

a- the cerebellar cortex is composed of white matter

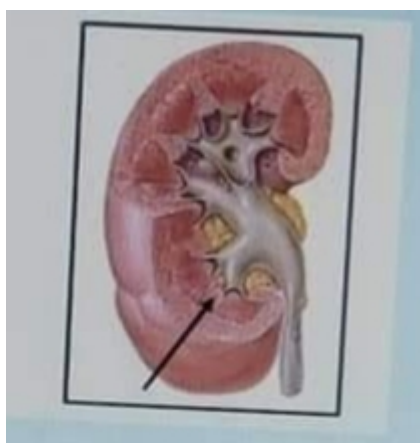
b- lies posterior to the pons and the medulla oblongata

c- the cerebellar cortex is thrown into folds(folia)

d- the median portion is the vermis

e- lies within the posterior cranial fossa

34- what is the labeled structure?



a- the cortex

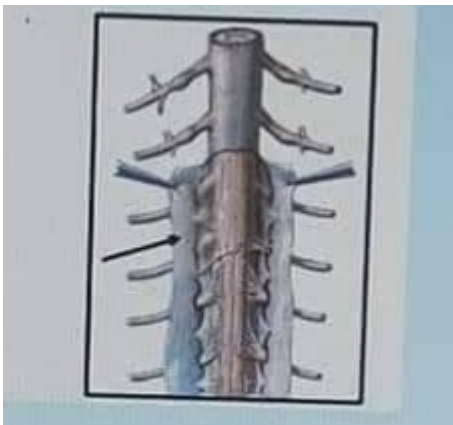
b-the renal columns

c- the renal pyramids

d- the medullary rays

e- the renal papilla

35-what is the labeled structure ?



a-the pia mater of spinal cord

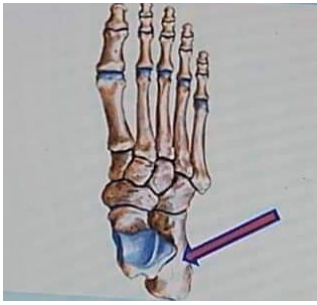b- the subarachnoid space

c- the arachnoid mater of spinal cord

d- denticulate ligament

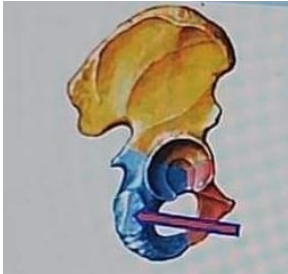
e- the dura mater of spinal cord

36- What is the labeled structure ?



- a. cuboid bone
- b. Talus bone
- c. Navicular bone
- d. metatarsal bone
- e. Calcaneus bone

37-What is the labeled structure ?



- a. origin of semimembranosus muscle
- b. origin of biceps muscle
- c. origin of adductor magnus muscle
- d. origin of semitendinosus muscle
- e. origin of quadratus femoris muscle

38- One is wrong about the adductor longus .



- a. adducts the thigh
- b. inserted in the linea alba
- c. Anterior branch of obturator nerve supplies it
- d. flexes the thigh
- e. partly supplied by the sciatic

39- Which is wrong about the adductor canal ?

- a. named sub sartorial canal
- b. named hunters canal
- c. it is a tunnel in the middle third of the thigh
- d. begins at apex of femoral triangle
- e. contains the sural nerve

40- Which is wrong regarding the cerebellum ?

- a. the cerebellar cortex is composed of white matter
- b. lies posterior pones and medulla oblongata
- c. the cerebellar cortex is thrown into folds
- d. the median portion is the vermis
- e. lies within the posterior cranial fossa

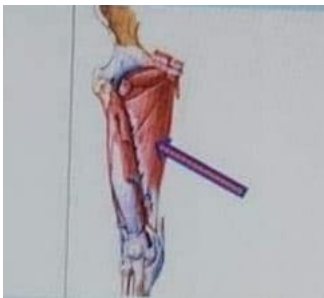41-All of the following is located in the medulla of the kidney except ?

- a. the renal papilla
- b. the renal columns
- c. the medullary rays
- d. the renal pyramids
- e. interlobular arteries

42-The sural nerve is branch of ?

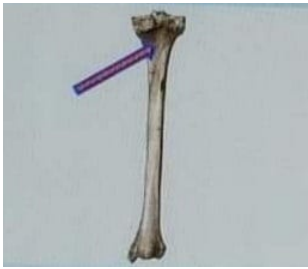- a. common peroneal nerve
- b. tibial nerve
- c. deep peroneal nerve
- d. sciatic nerve
- e. superficial peroneal nerve

43- What is labeled structure ?



- a. adductor magnus
- b. obturator internus
- c. adductor brevis
- d. obturator externus
- e. adductor longus

44-What is labeled structure ?



- a. right popliteus
- b. left soleus
- c. left popliteus
- d. right soleus

45-All of the following muscles are deep to gluteus maximus except ?

- a. gluteus medius
- b. piriformis
- c. quadratus femoris
- d. tensor of fascia lata
- e. gluteus minimus

46-All of the following forms the medial longitudinal arch except ?

- a. calcaneus
- b. cuboid
- c. navicular
- d. talus

e. cuneiform

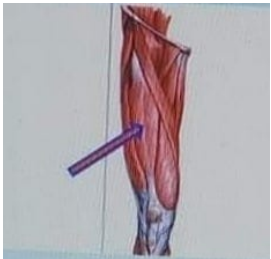
47- All of the following are lateral rotator of the hip joint except

- a. piriformis
- b. obturator externus
- c. adductor magnus
- d. obturator internus
- e. quadratus femoris

48- Which of the following muscles arises from the lateral condyle of the femur above the lateral epicondyle ?

- a. lateral head of gastrocnemius
- b. soleus
- c. medial head of gastrocnemius
- d. popliteus
- e. plantaris

49- What is labeled structure ?



- a. vastus lateralis
- b. vastus intermedius

- c. sartorius
- d. rectus femoris
- e. vastus medialis

50-Which of the following muscles inserted in the groove on the back of the medial condyle of the tibia ?

- a. semimembranosus muscle
- b. biceps femoris
- c. ischial part of adductor magnus muscle
- d. semitendinosus
- e. quadratus femoris

51- inversion and eversion is movement of ?

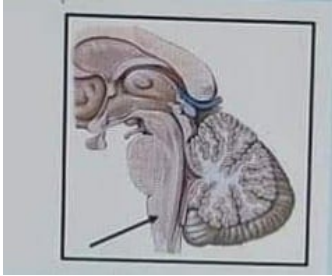
- a. calcaneo-navicular joint
- b. ankle joint
- c. intertarsal joints
- d. talo- calcaneo-navicular joint
- e. talo-navicular joint

52-Which of the following muscles acts like the top gear of the car ?

- a. tibialis posterior
- b. soleus

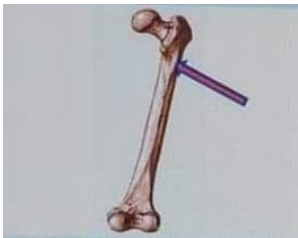- c. flexor hallucis longus
- d. gastrocnemius
- e. flexor digitorum longus

53-What is the labeled structure ?



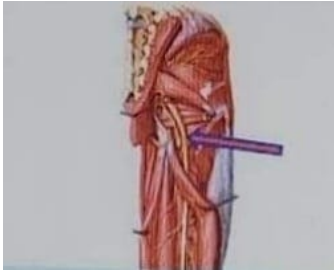- a. the medulla oblongata
- b. the spinal cord
- c. the pons
- d. the midbrain
- e. the vermis

54- What is the labeled structure ?



- a. spiral line
- b. lateral lip of linea aspera
- c. gluteal tuberosity
- d. linea aspera
- e. medial lip of linea aspera

55- What is the labeled structure ?



- a. superior gluteal nerve
- b. posterior cutaneous nerve of thigh
- c. pudendal nerve
- d. sciatic nerve
- e. inferior gluteal nerve

56- Which is not true for femoral triangle ?

- a. it lies just below the inguinal ligament
- b. the sartorius is its lateral boundary
- c. the adductor longus muscle is its medial boundary
- d. it contains the femoral artery and its branches
- e. it contains the adductor magnus in its floor

57- the medial part of the foot is supplied by ?

- a. sural nerve
- b. deep peroneal nerve
- c. saphenous nerve

- d. tibial nerve
- e. superficial peroneal nerve

58- What is the meaning of lateral deviation of the big toe ?

- a. talpes calcaeus
- b. hallux valgus
- c. flat foot
- d. talpes equinus
- e. pes cavus

59-All the hamstring muscles are supplied by the sciatic nerve except ?

- a. semimembranous
- b. long head of biceps femoris
- c. ischial part of the adductor magnus
- d. short head of biceps femoris
- e. semitendinosus

60-Which of the following muscles is inserted in the top of the greater trochanter ?

- a. gluteus medius
- b. piriformis
- c. quadratus femoris



- d. obturator internus
- e. gluteus minimus

61- All of the following pass deep to the extensor retinaculum except ?

- a. tibialis anterior muscle
- b. extensor digitorum longus muscle
- c. peroneus tertius muscle
- d. extensor hallucis longus muscle
- e. extensor digitorum brevis muscle

62- The forebrain includes all of the following except ?

- a. cerebellum
- b. thalamus
- c. hypothalamus
- d. cerebrum
- e. the diencephalon is almost completely hidden from the surface of the brain

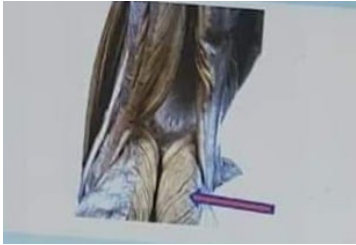63- the following are parts of uterine tube except ?

- a. the cervix
- b. the ampulla
- c. infundibulum

d. isthmus

e intramural part

64-What is the labeled structure?



a. biceps muscle

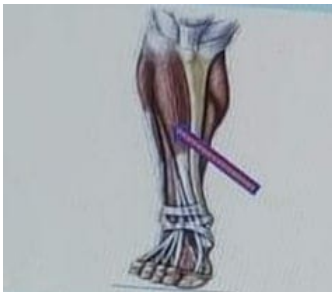b. lateral head of gastrocnemius

c. semitendinosus muscle

d. medial head of gastrocnemius

e. semimembranosus muscle

65- What is the labeled structure?



a. tibialis posterior muscle

b. tibia bone

c. extensor digitorum longus muscle

d. tibialis anterior muscle

e. flexor digitorum longus muscle

66- How many lumbricalis muscles ?

- a. 3
- b. 14
- c. 4
- d. 7
- e. 8

67- The obturator externus muscle is inserted in ?

- a. the greater trochanter
- b. the inner trochanter
- c. the trochanteric fossa
- d. the head of femur
- e. the shaft of the femur

