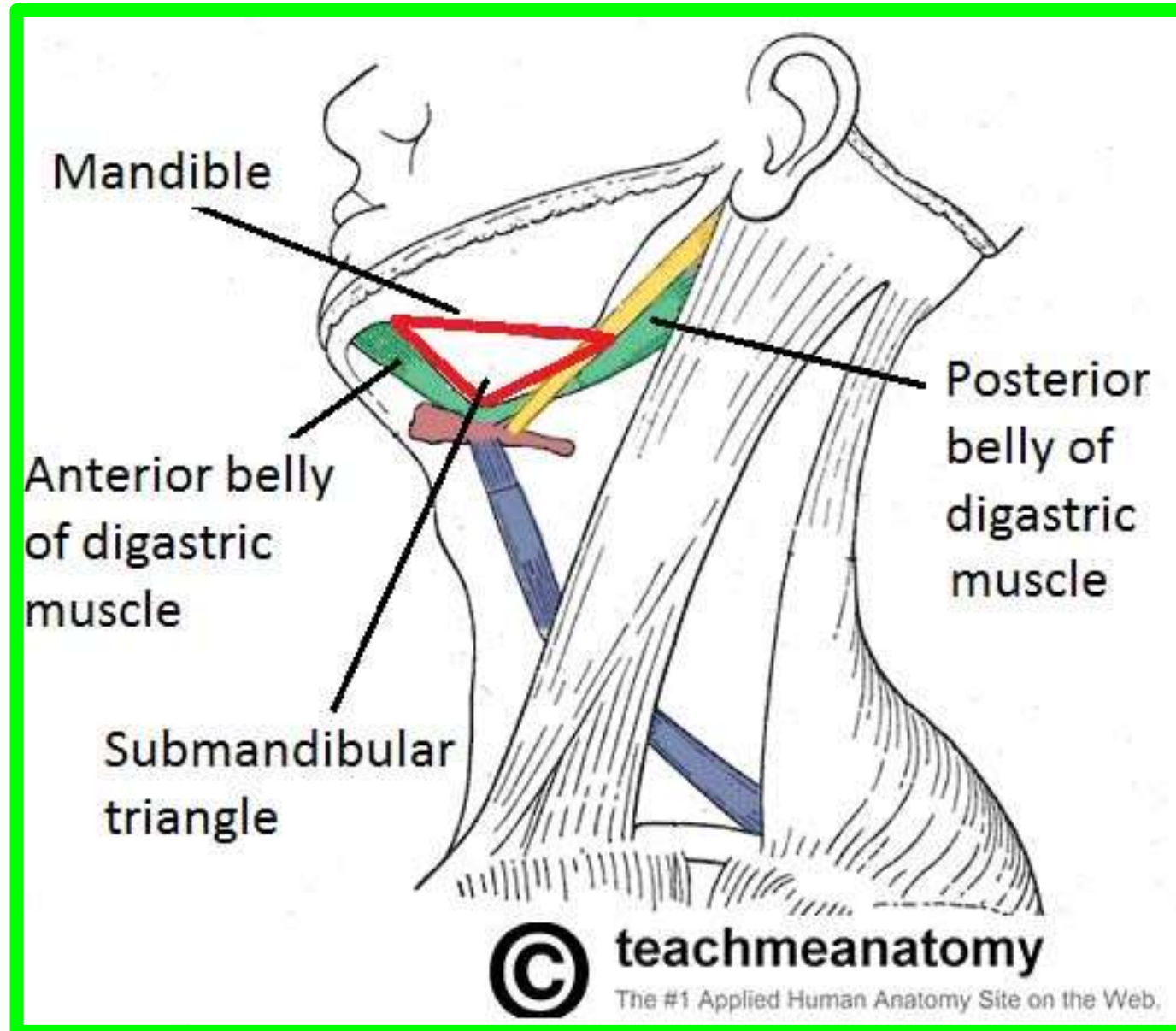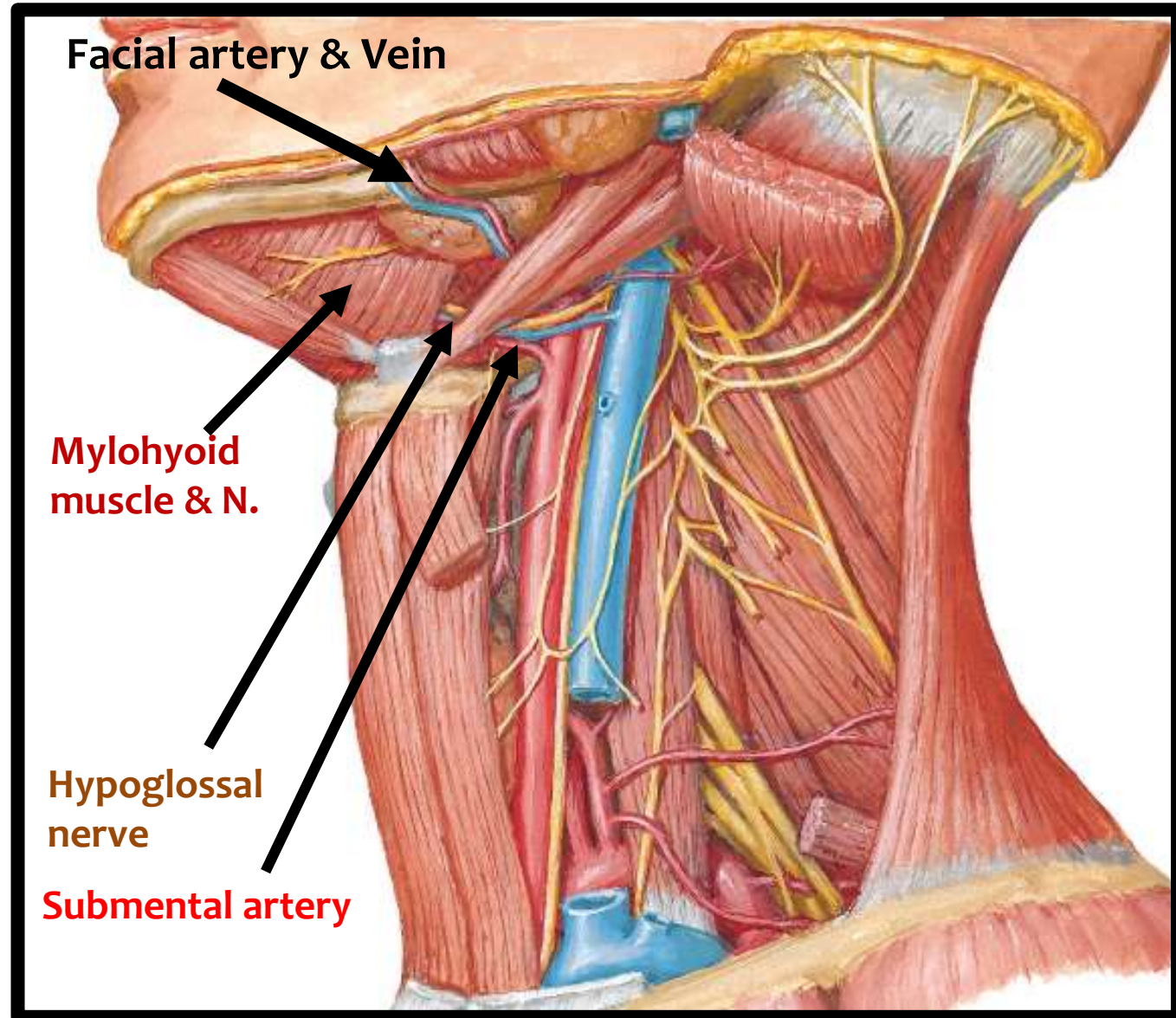
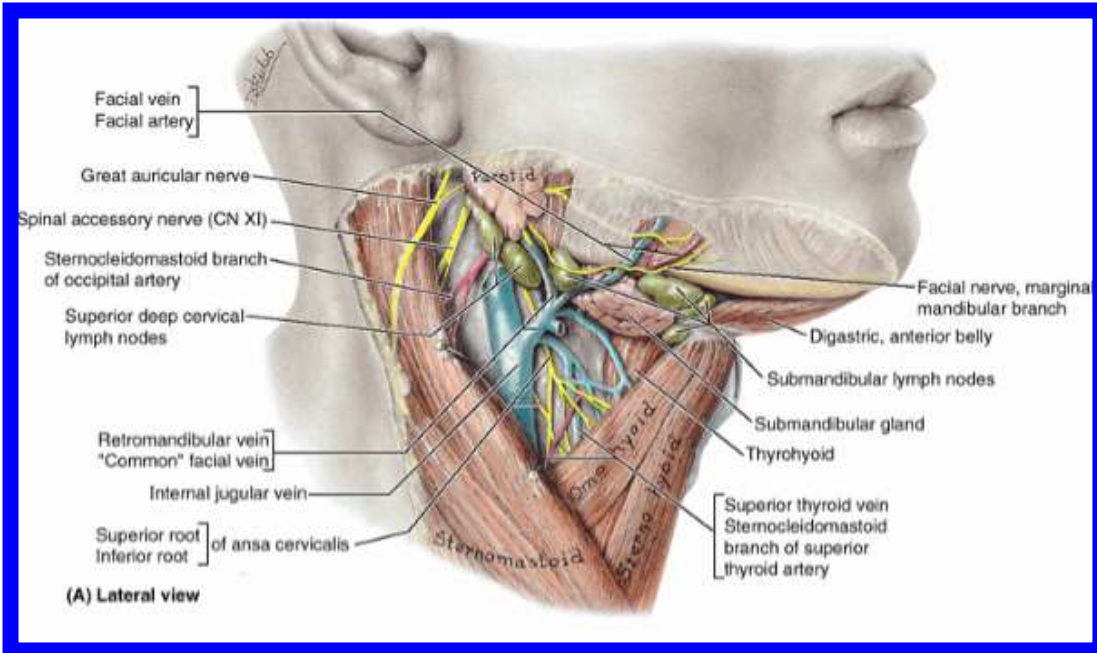


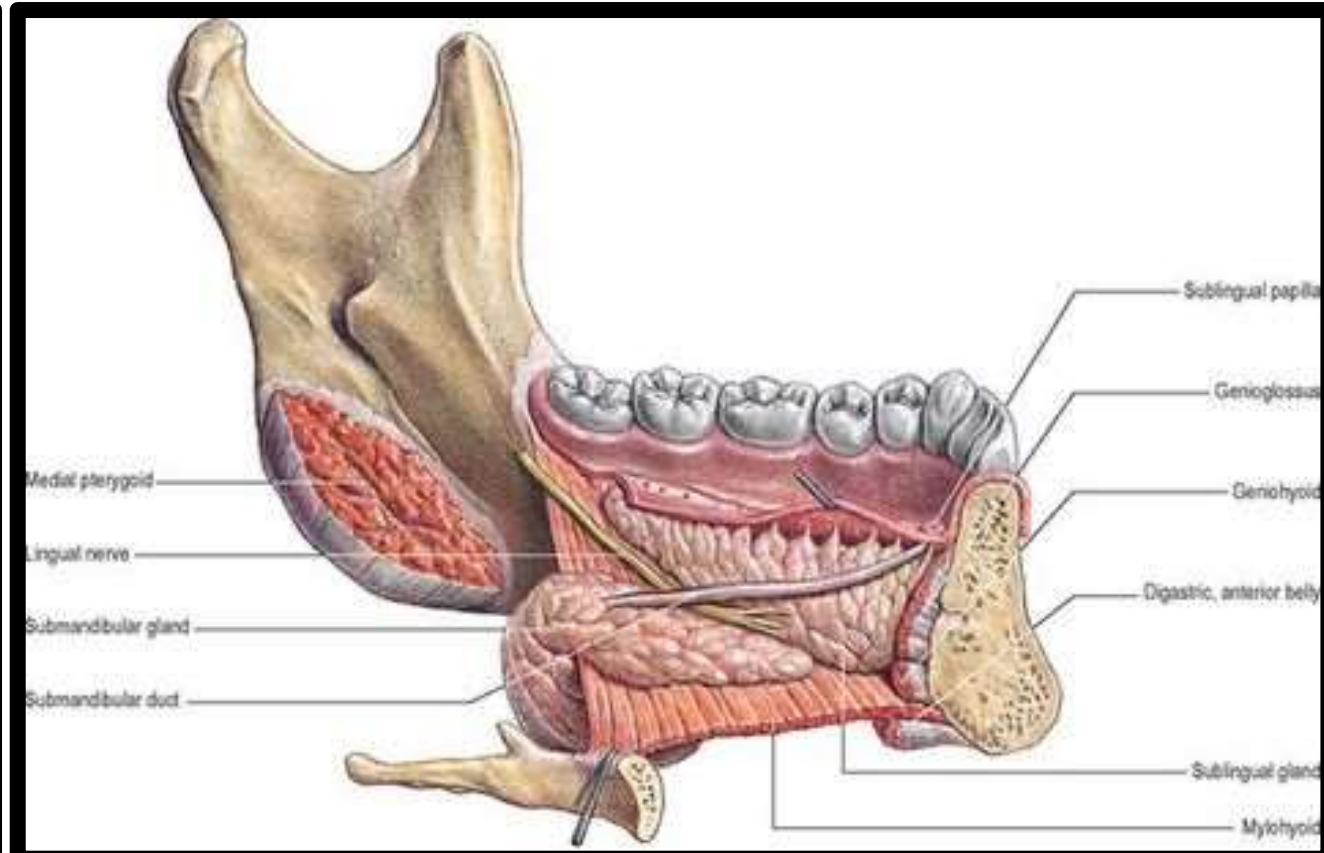
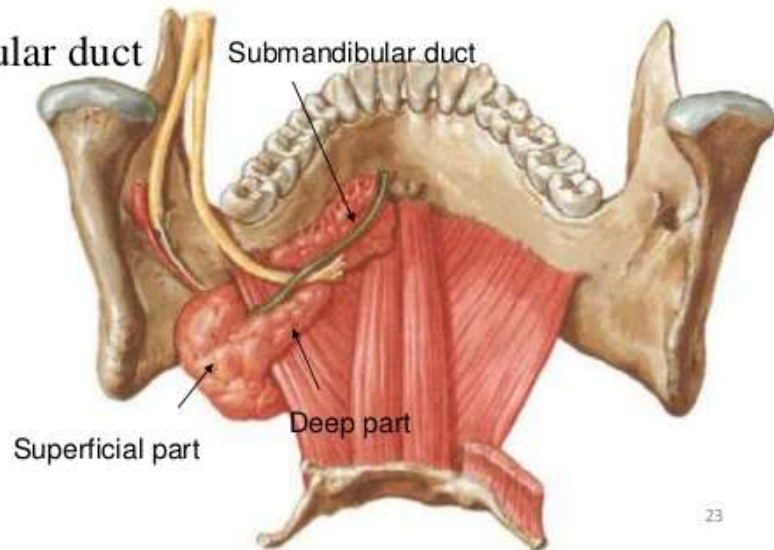
The submandibular triangle Anterior Cervical Region



Submandibular gland

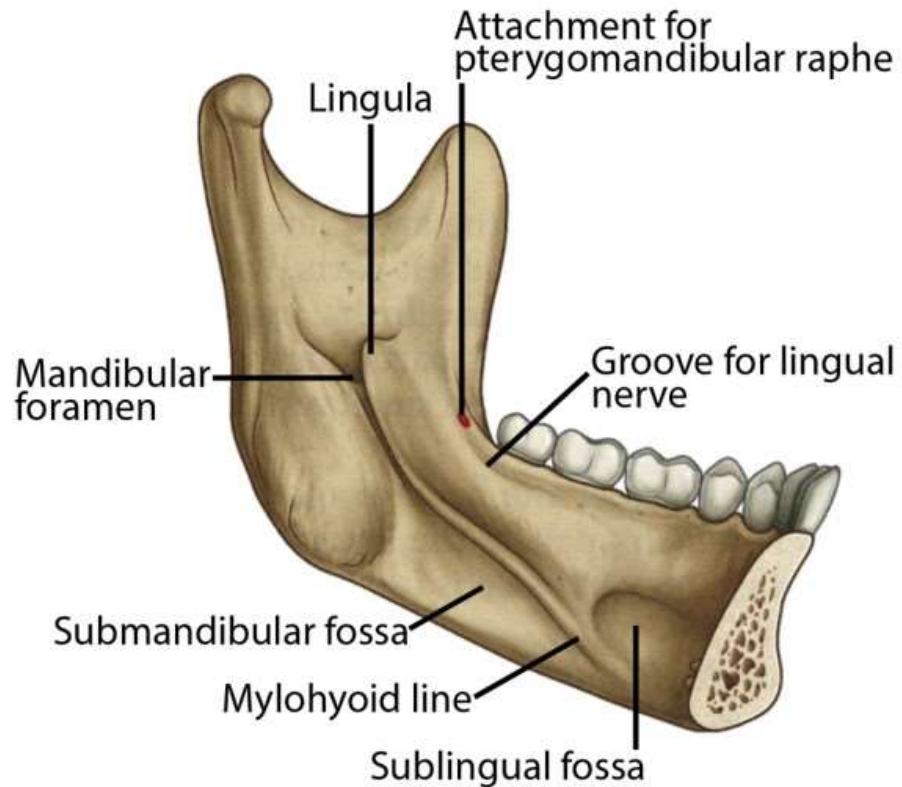
PARTS

1. Superficial part
2. Deep part
3. Submandibular duct



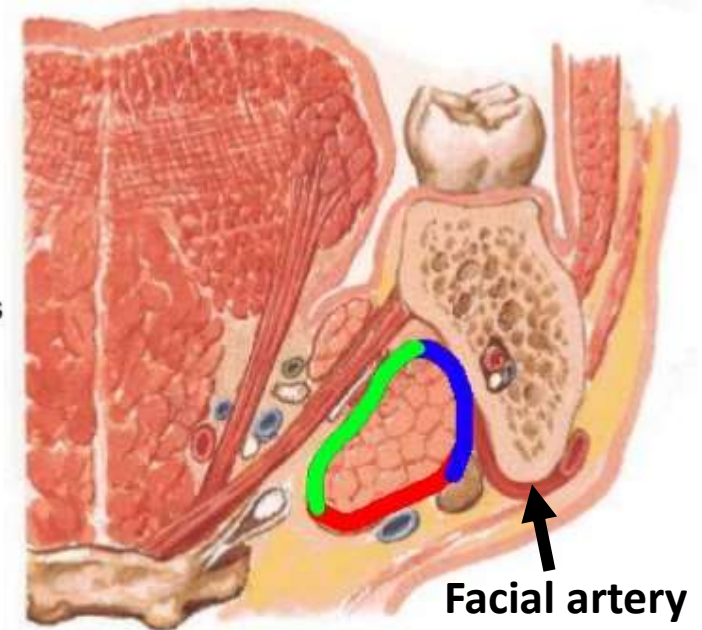
Submandibular gland

Dr. Aiman Qais Afar
Sunday 3 April 2022

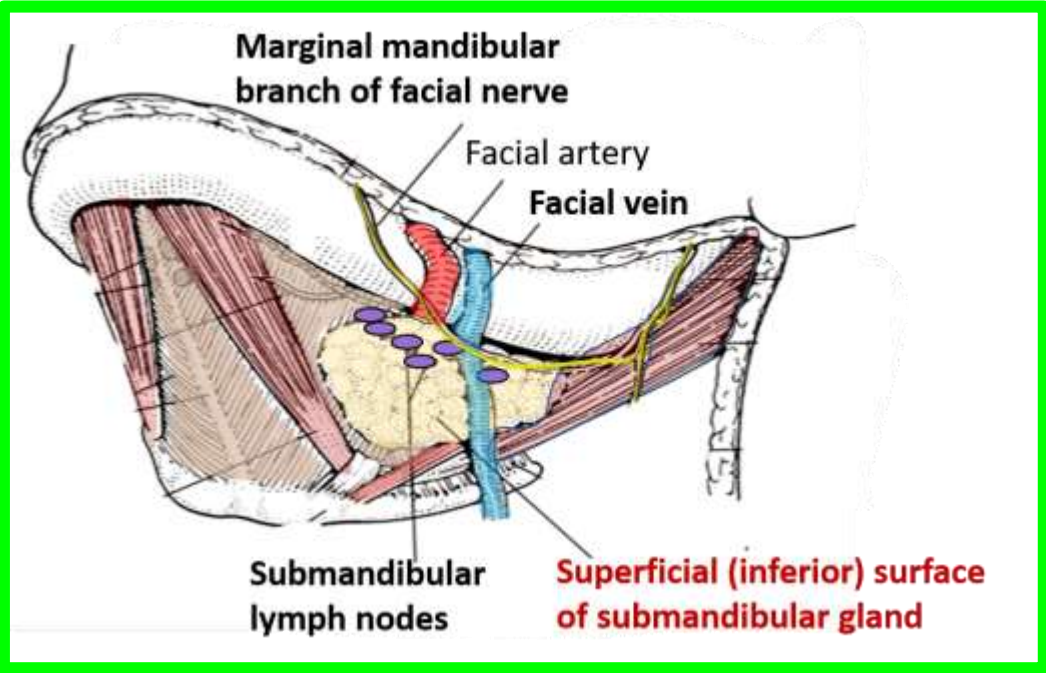
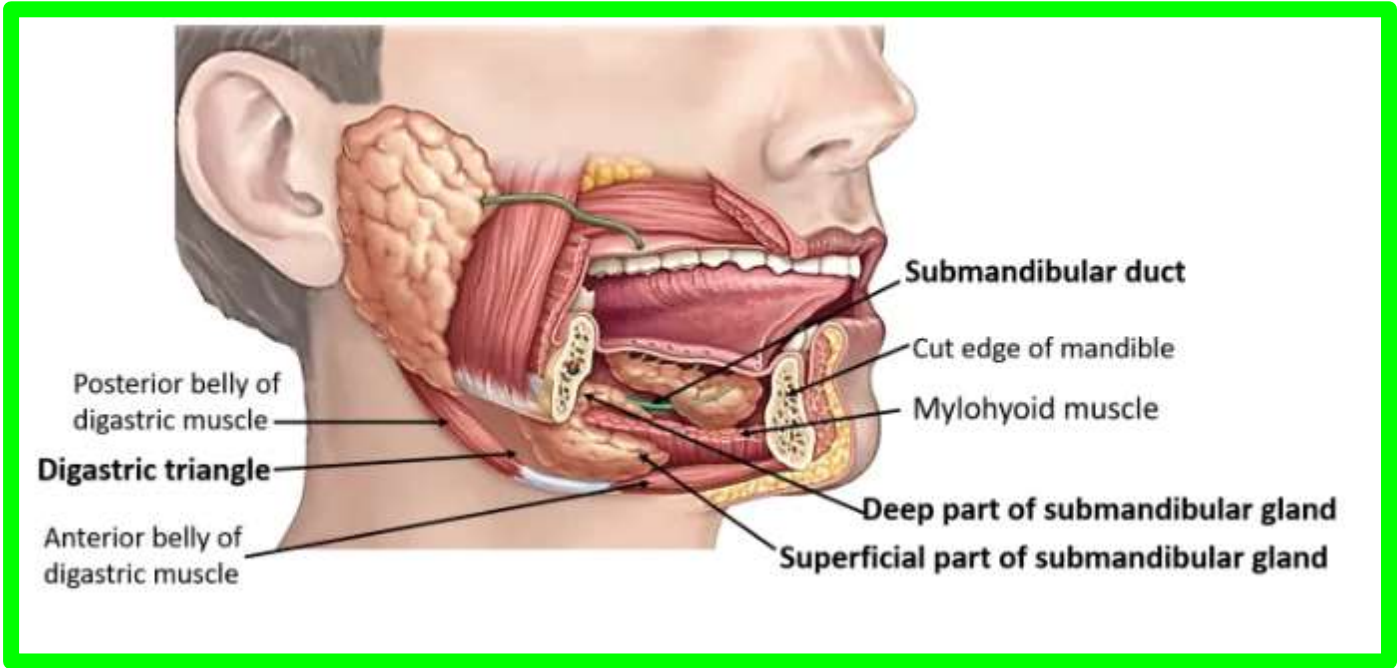


Relations

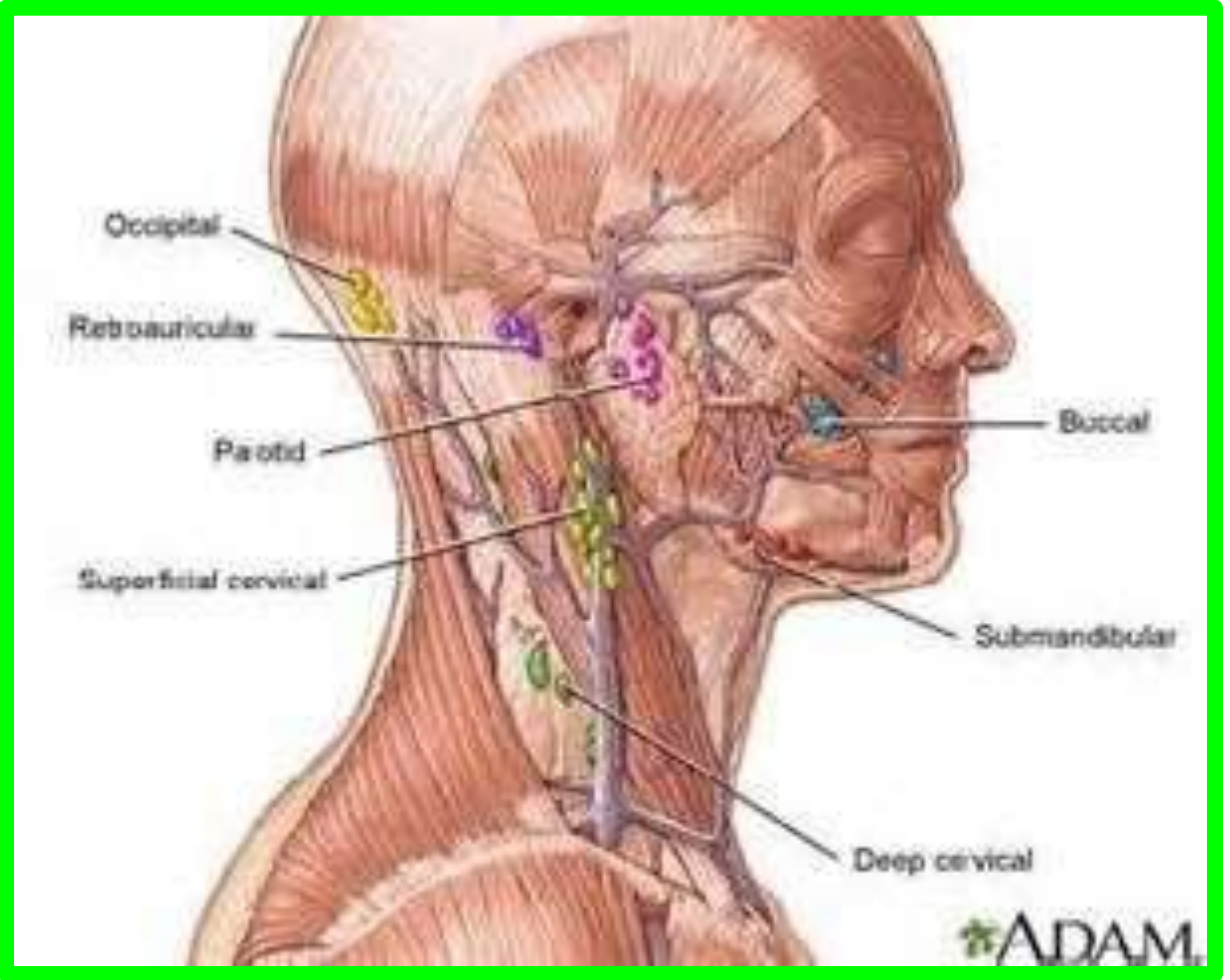
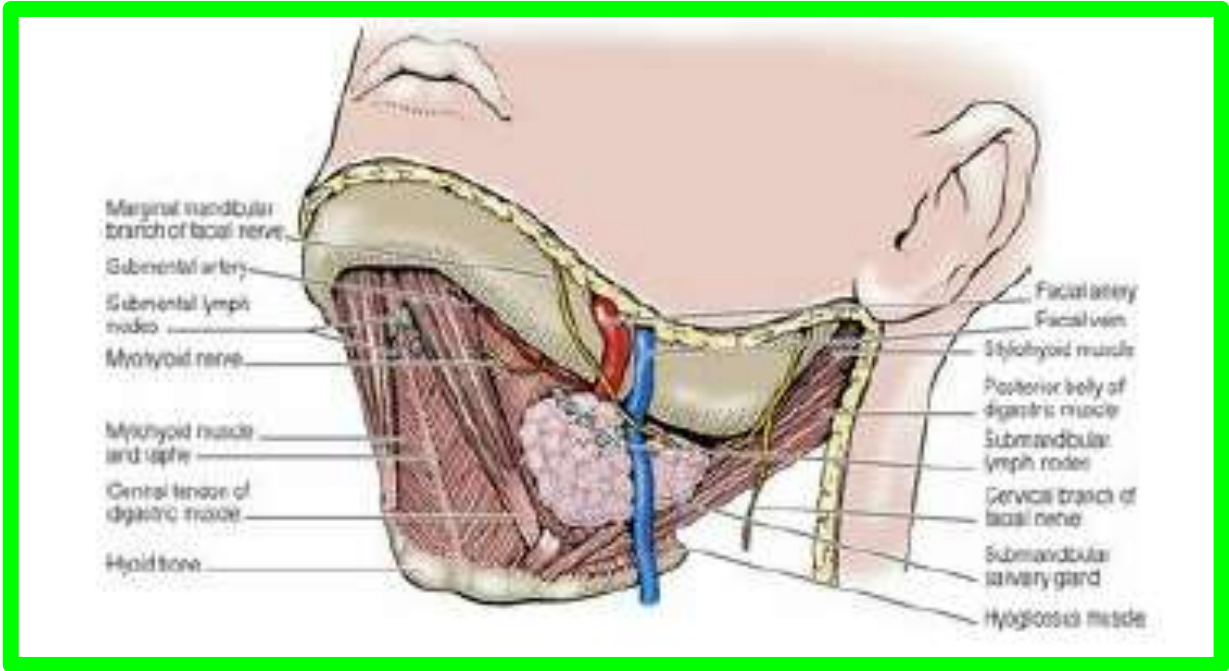
- 1. Inferolateral surface:** related to skin, superficial fascia (containing platysma, cervical branch of facial n., ant. facial v., LNs) & deep fascia.
- 2. Lateral surface:** related to body of mandible, facial a., mylohyoid n. & a.
- 3. Medial surface:** related to 2 muscles (mylohyoid & hyoglossus) & 2 nerves (lingual & hypoglossal).



Submandibular gland



Submandibular gland

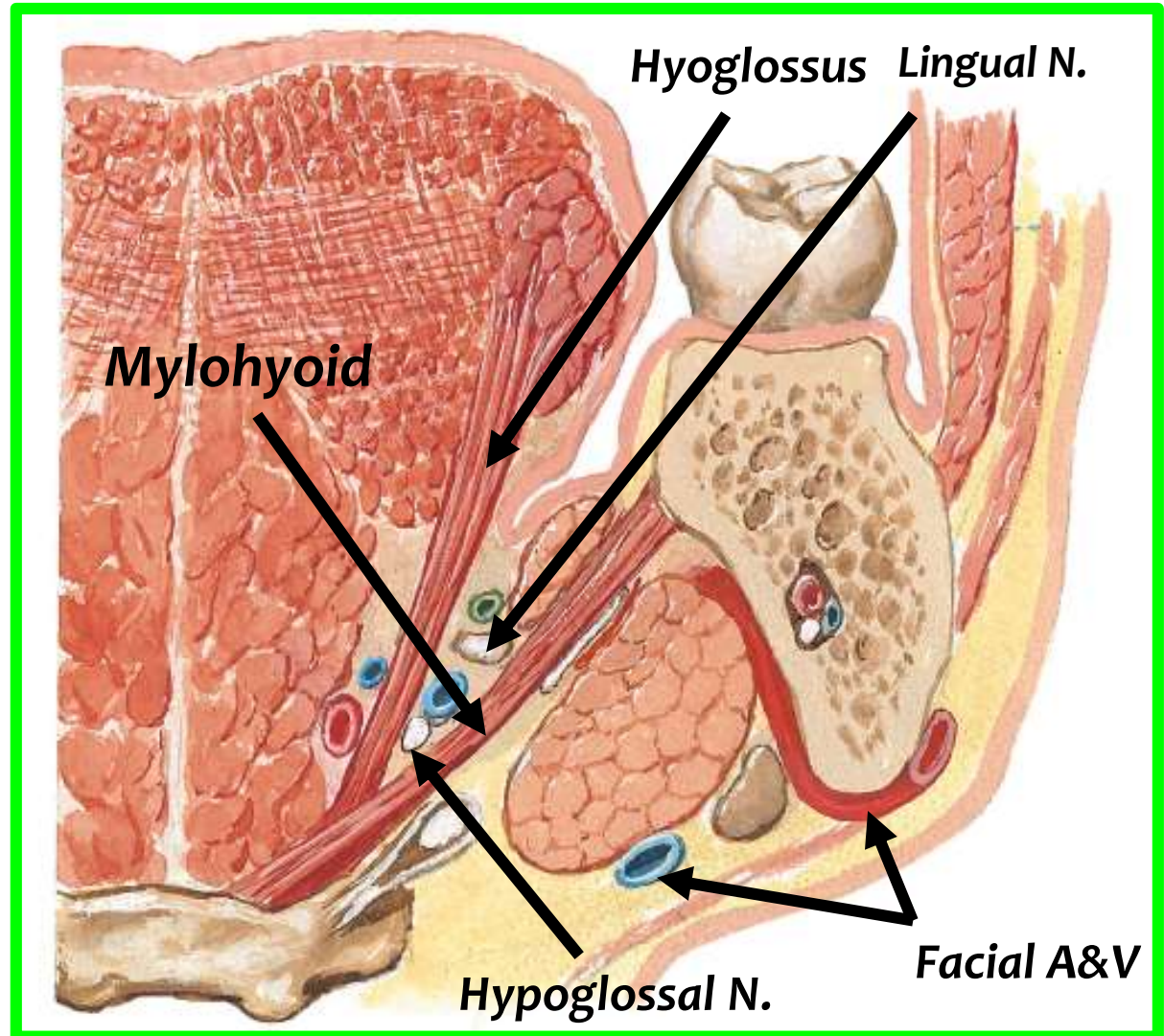
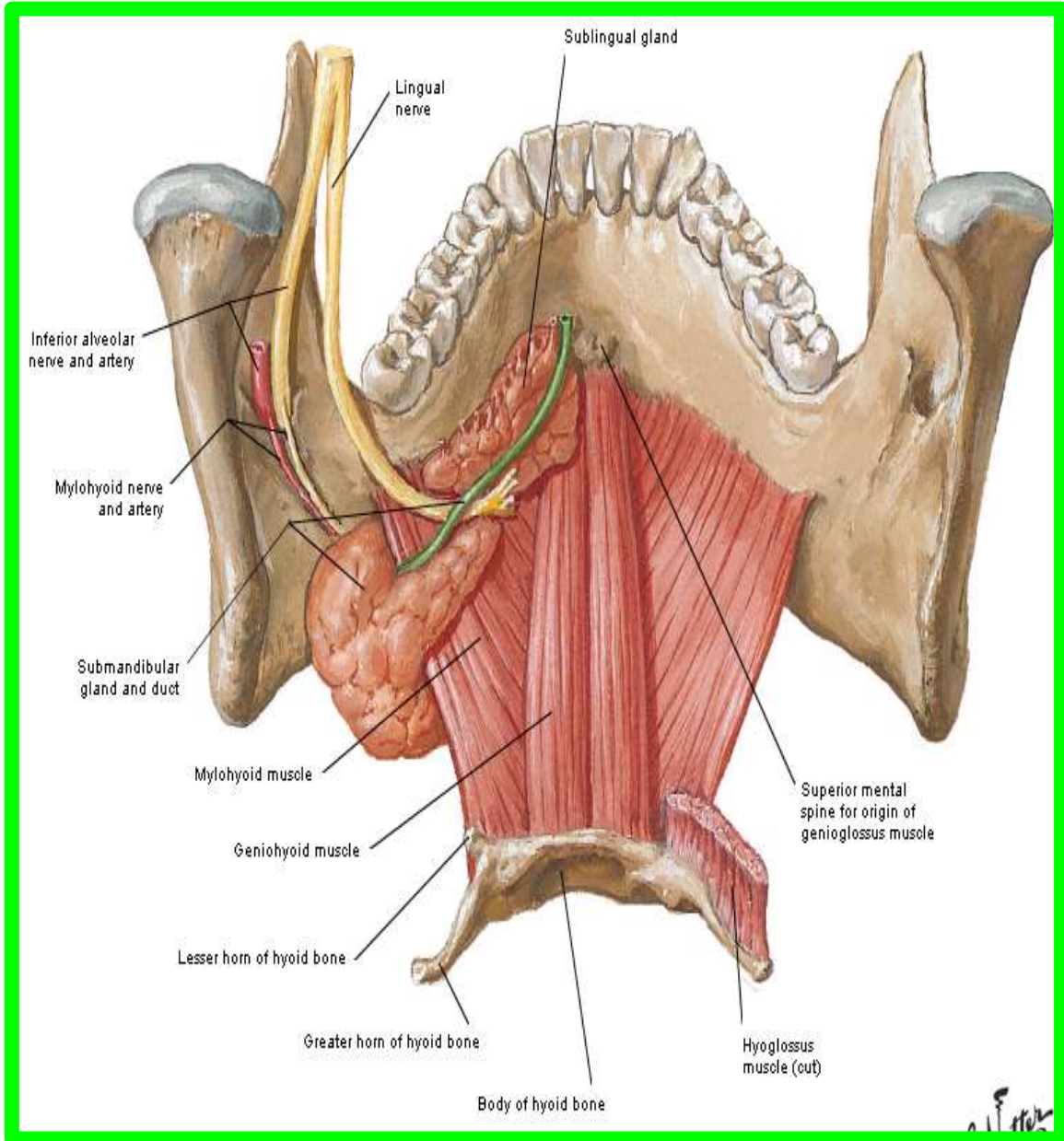


Submandibular gland

Sunday 3 April 2022

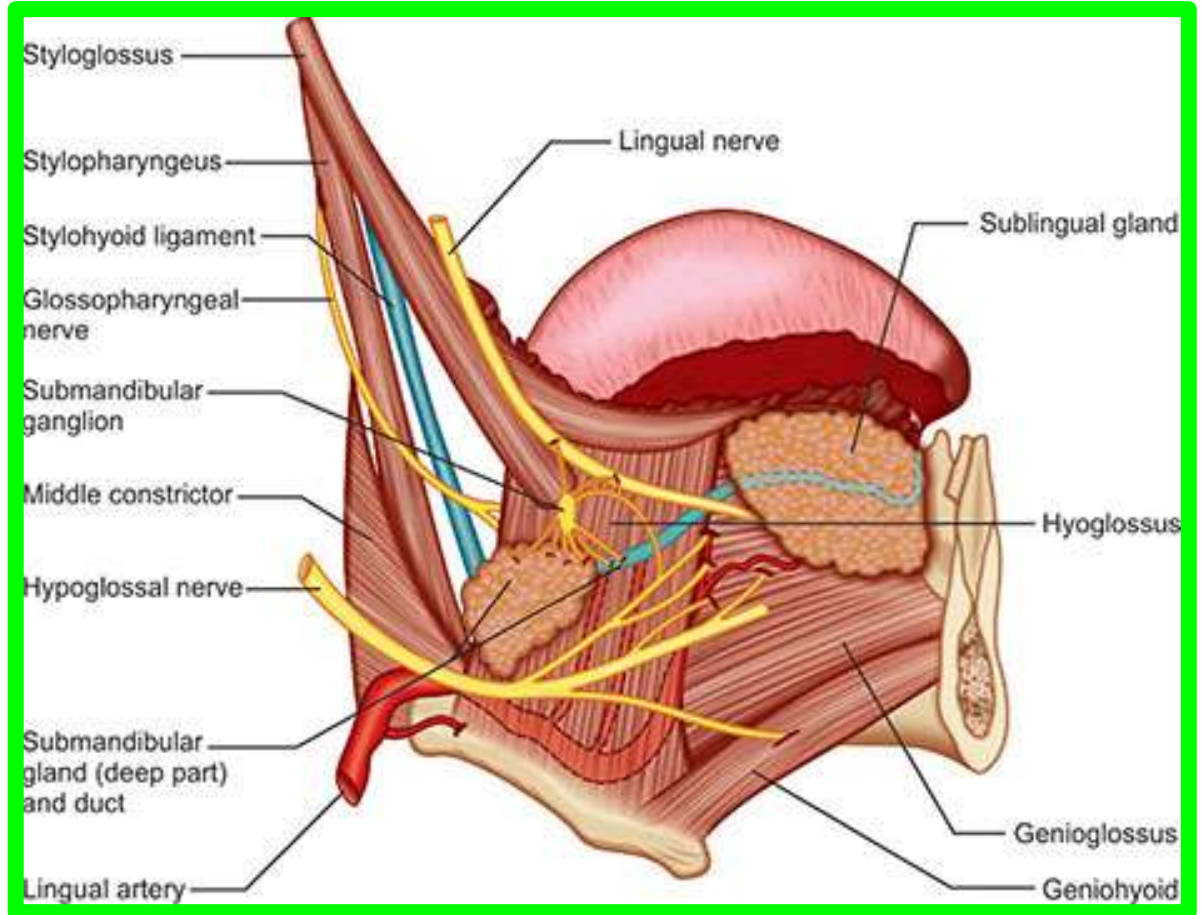
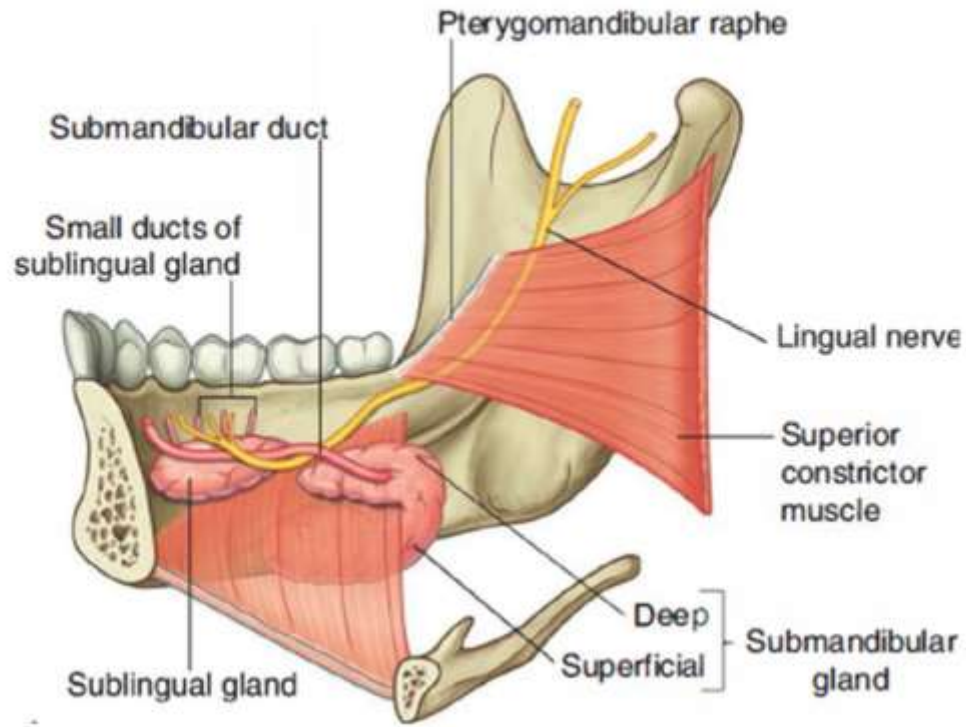
Dr. Aiman Qais Afar

7

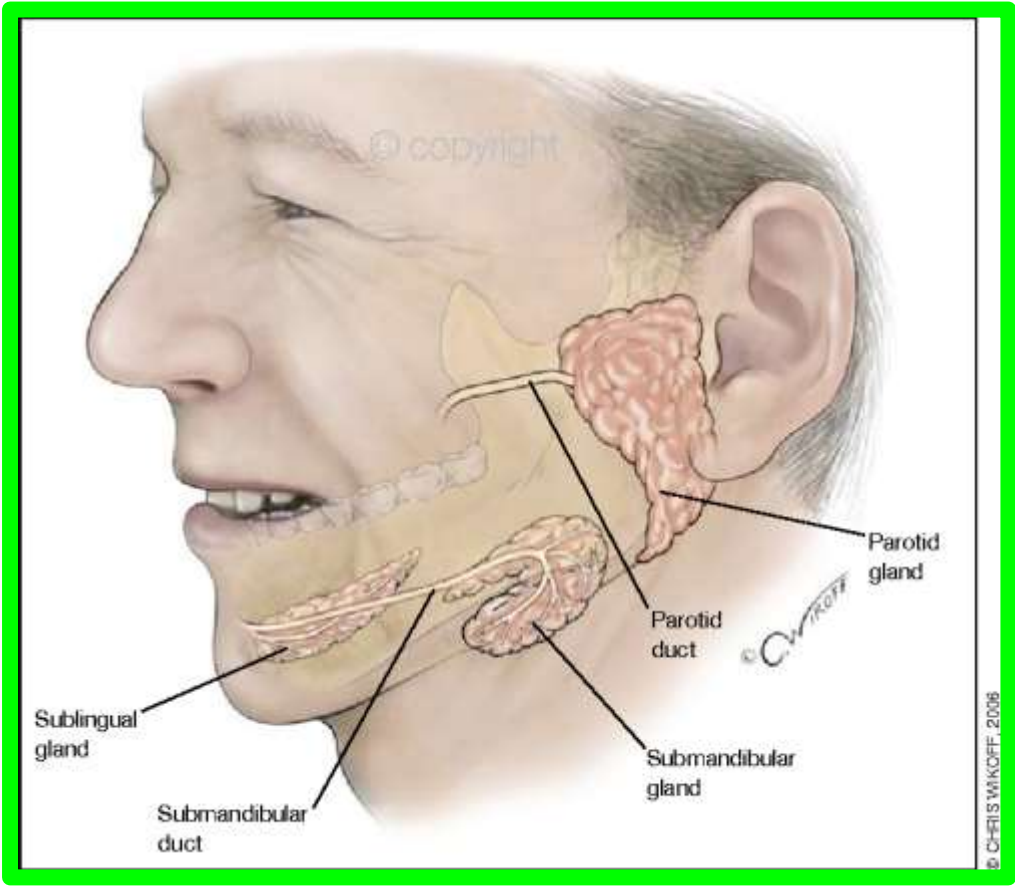


Submandibular gland

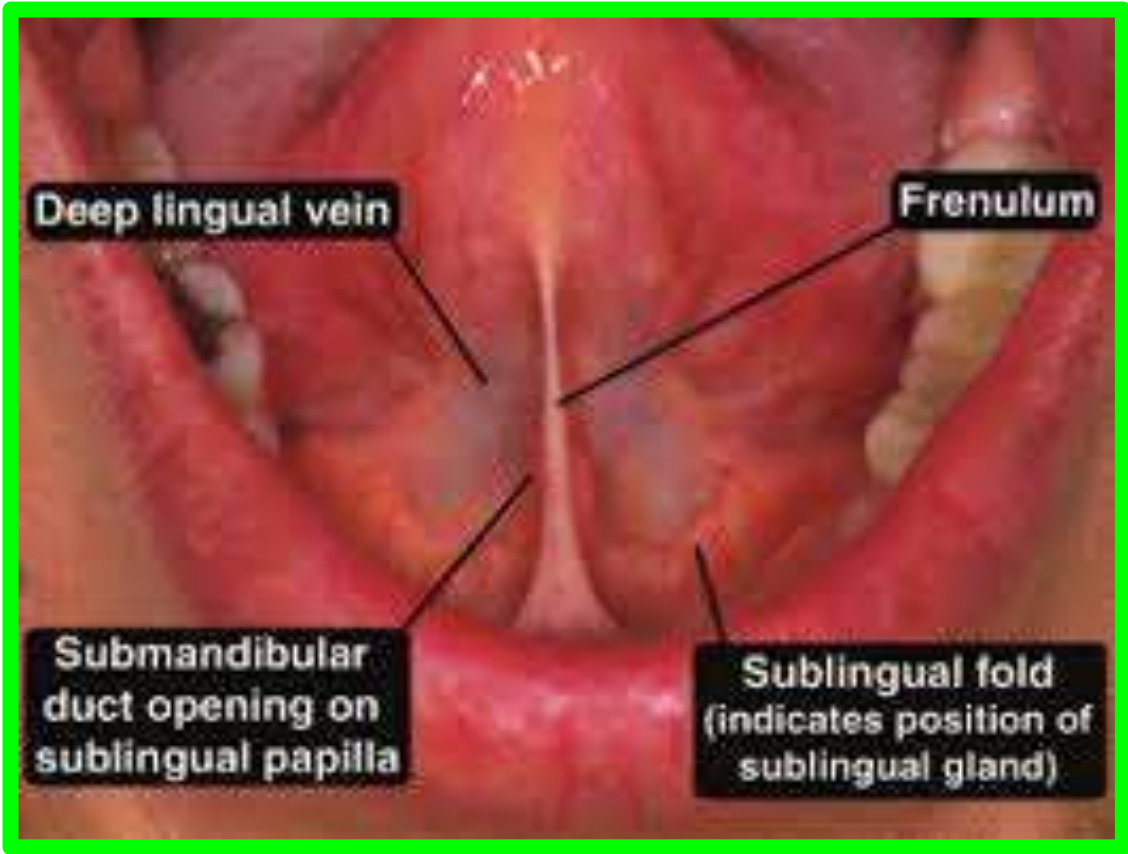
Submandibular and sublingual glands:



Submandibular gland

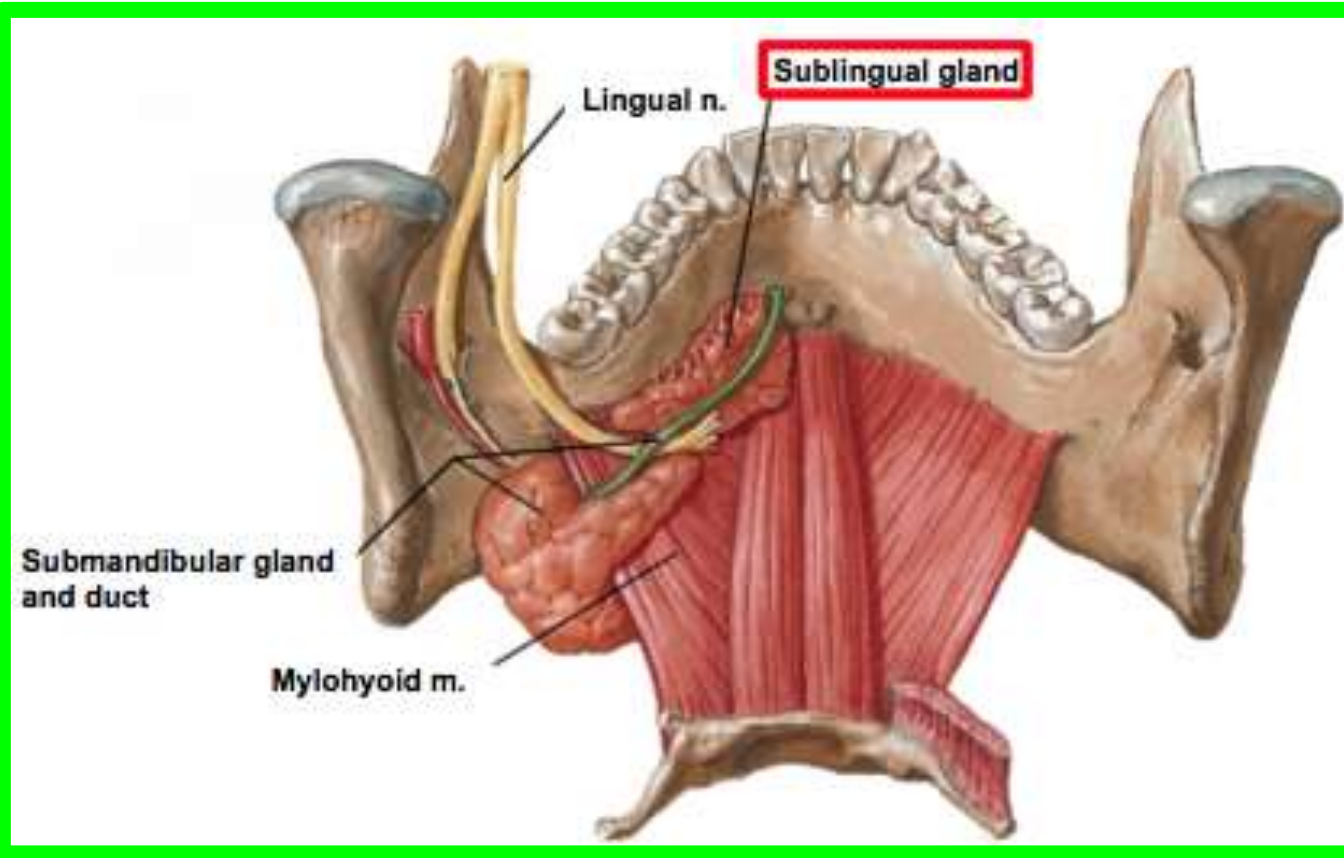
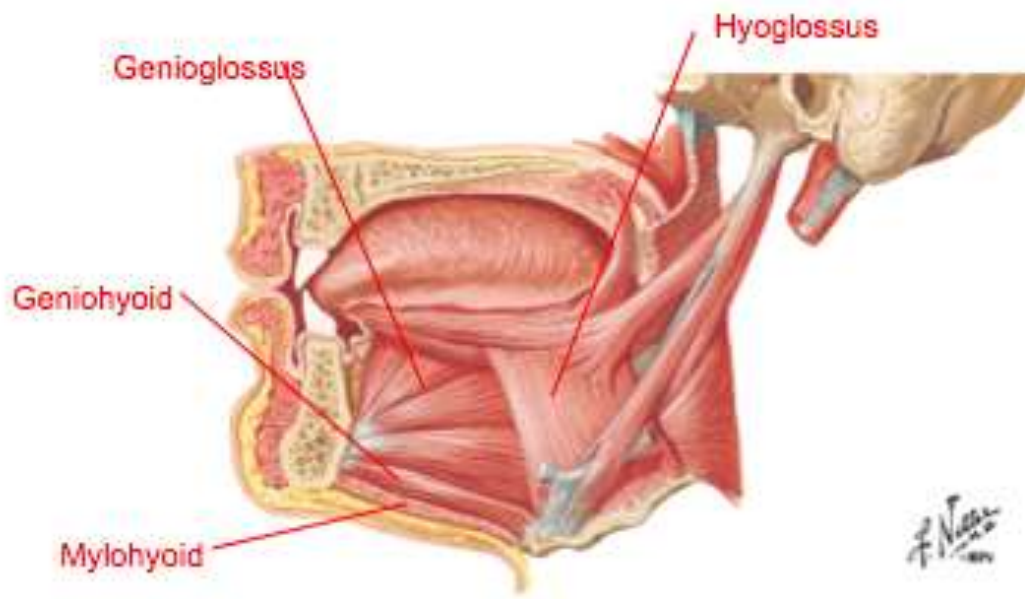


Sunday 3 April 2022

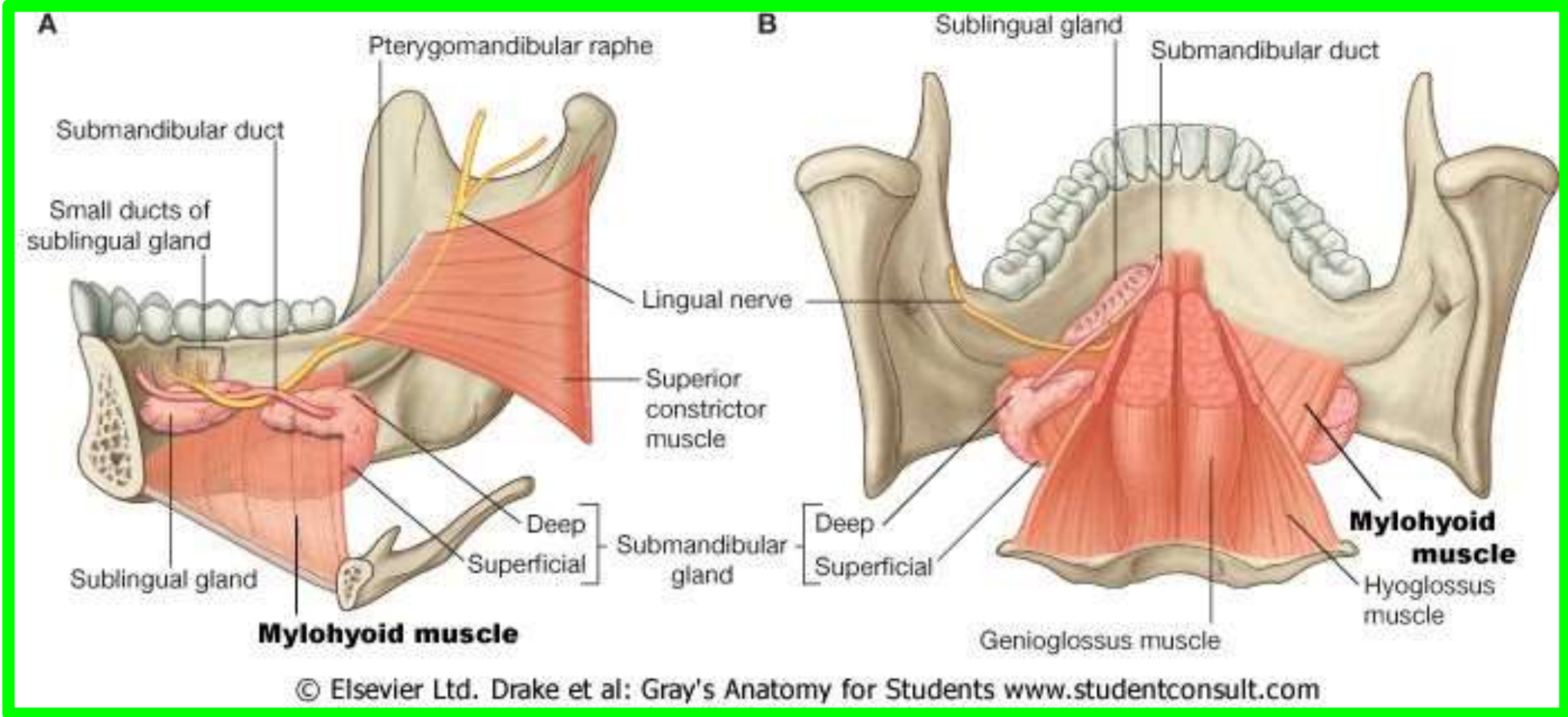


Dr. Aiman Qais Afar

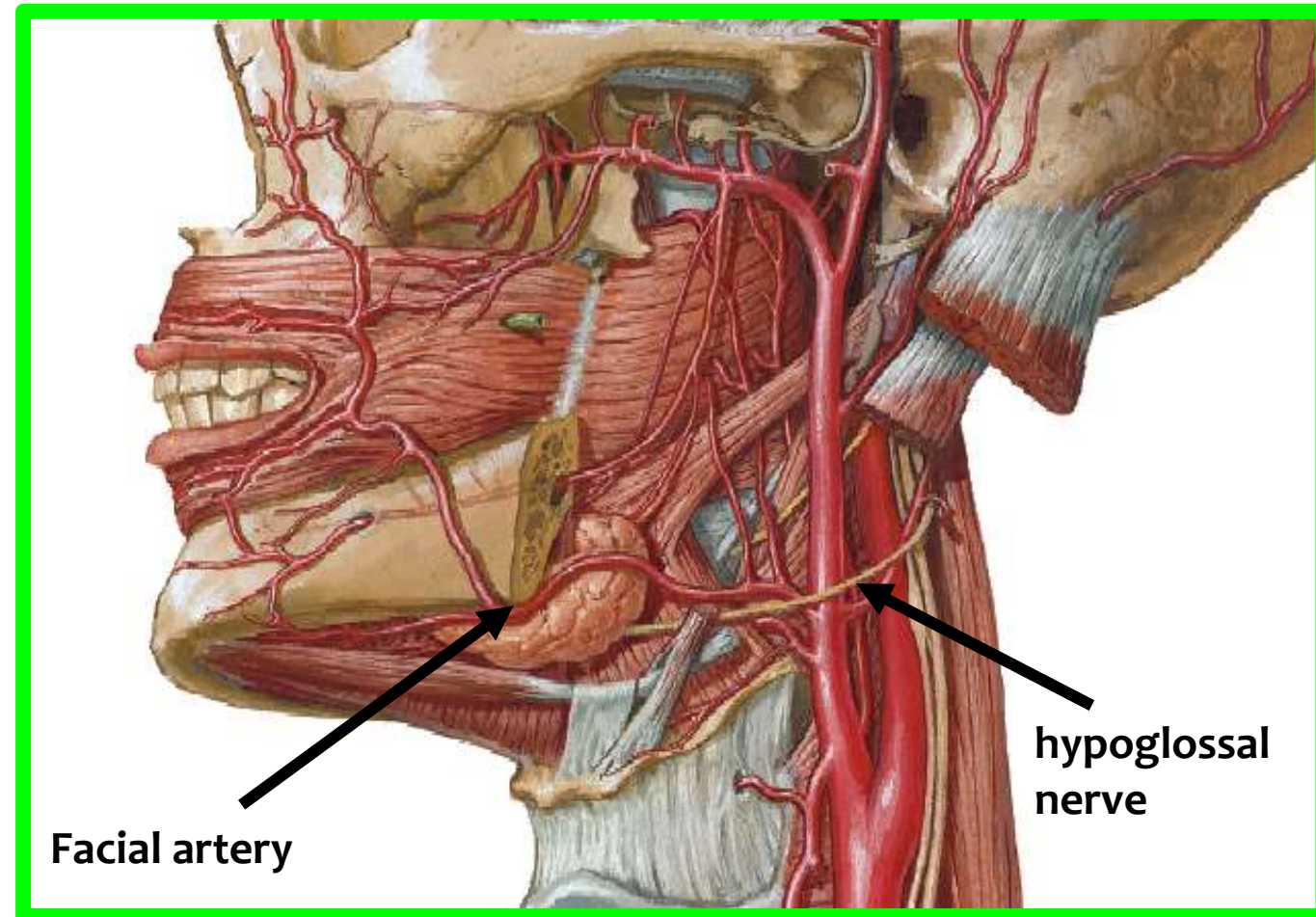
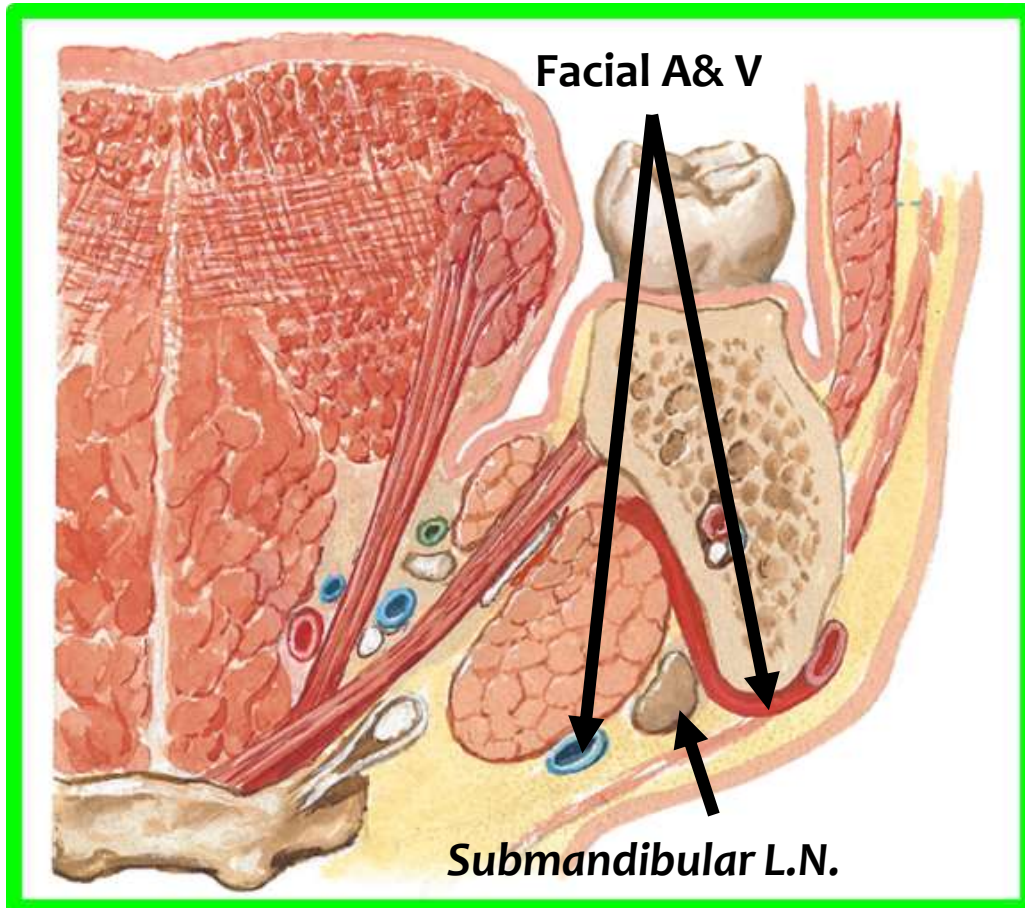
Submandibular gland



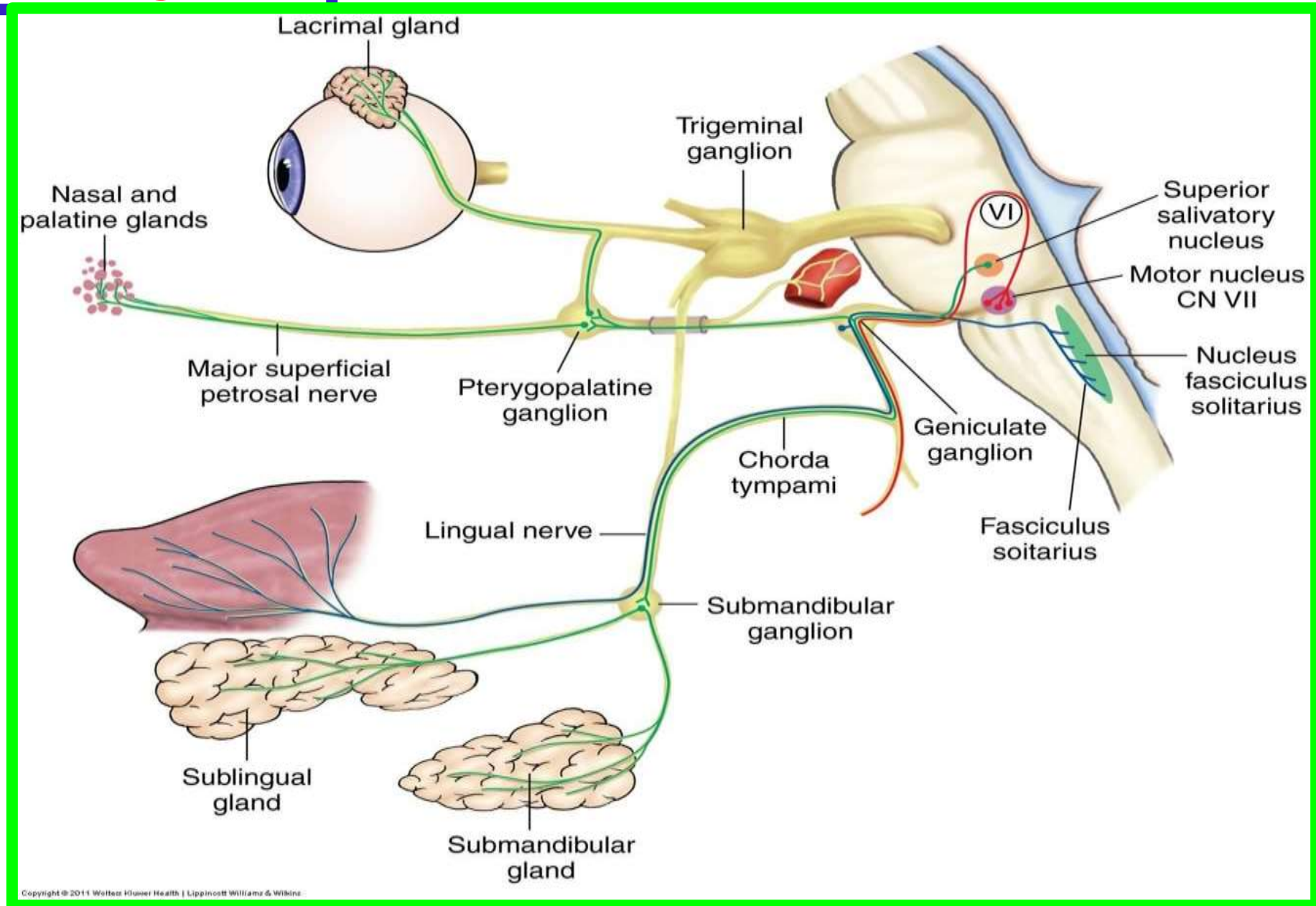
Submandibular gland



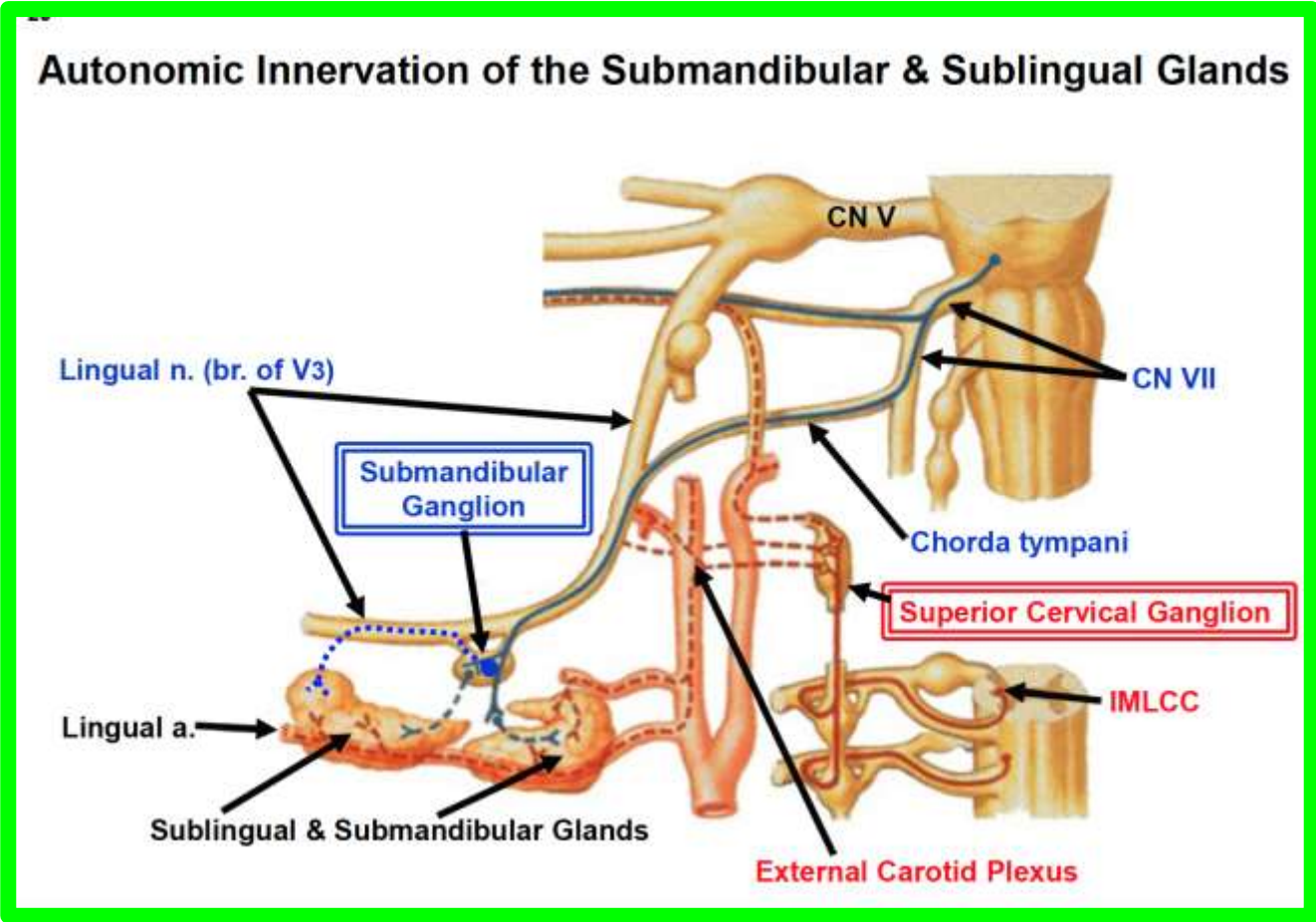
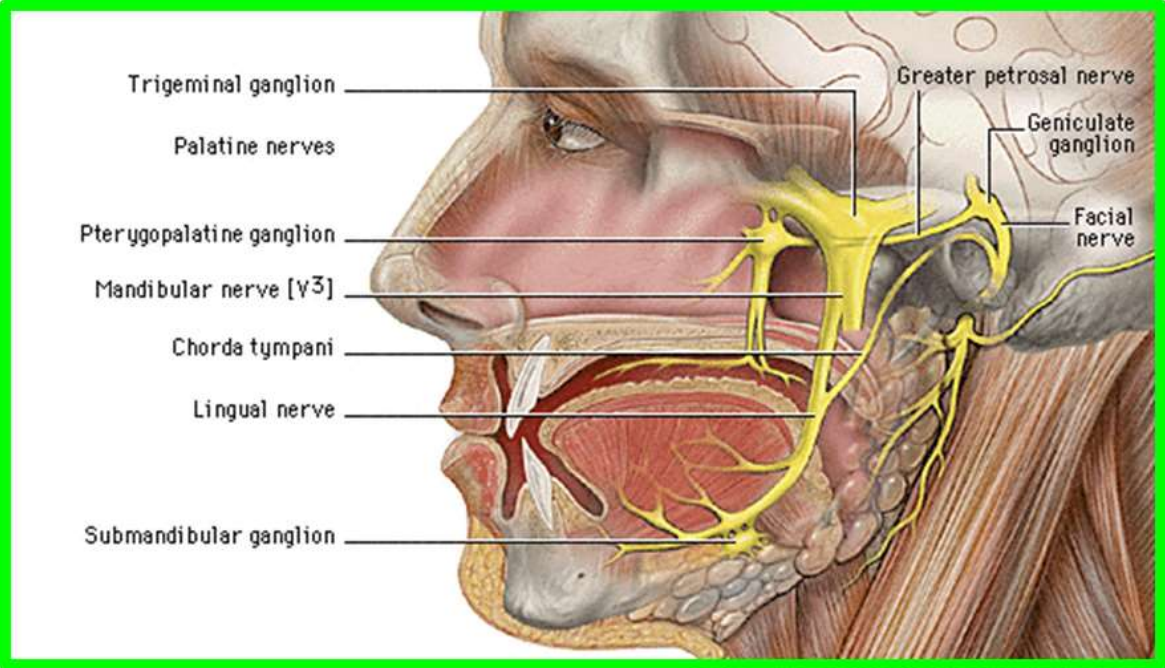
Submandibular gland



Submandibular gland



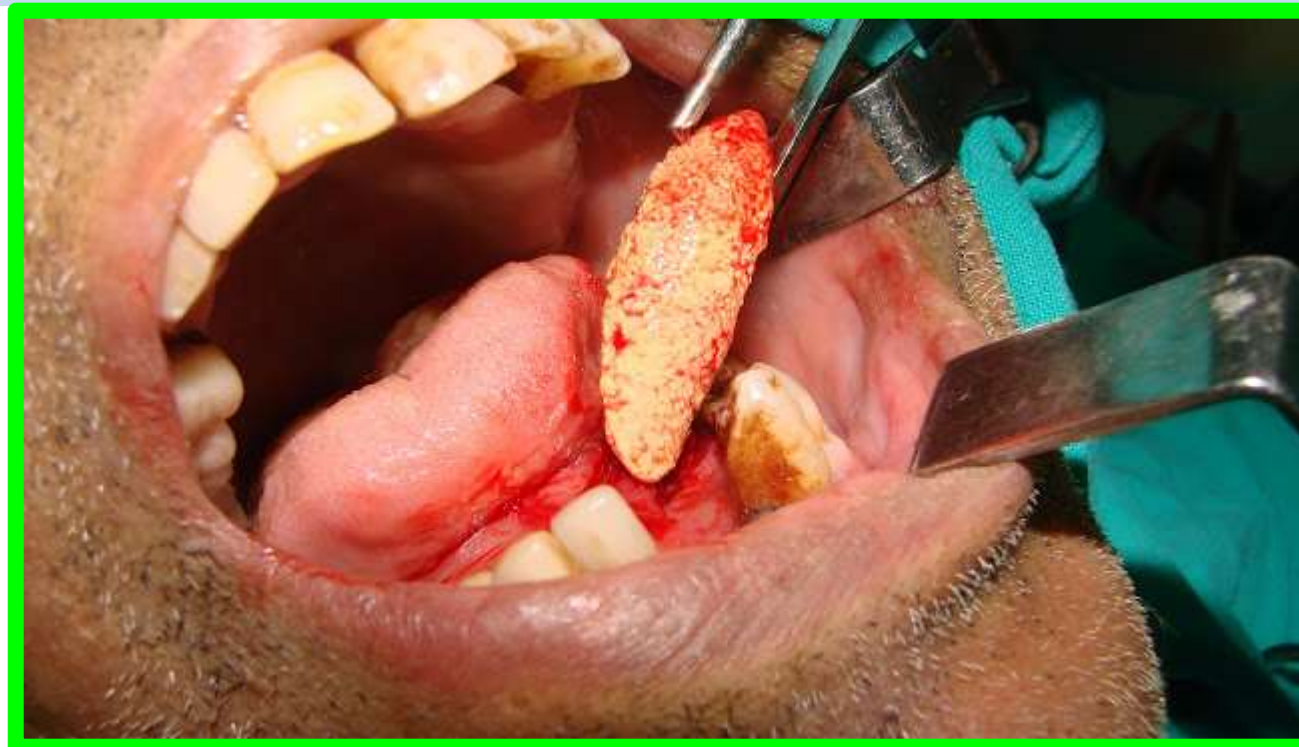Submandibular gland



Submandibular gland

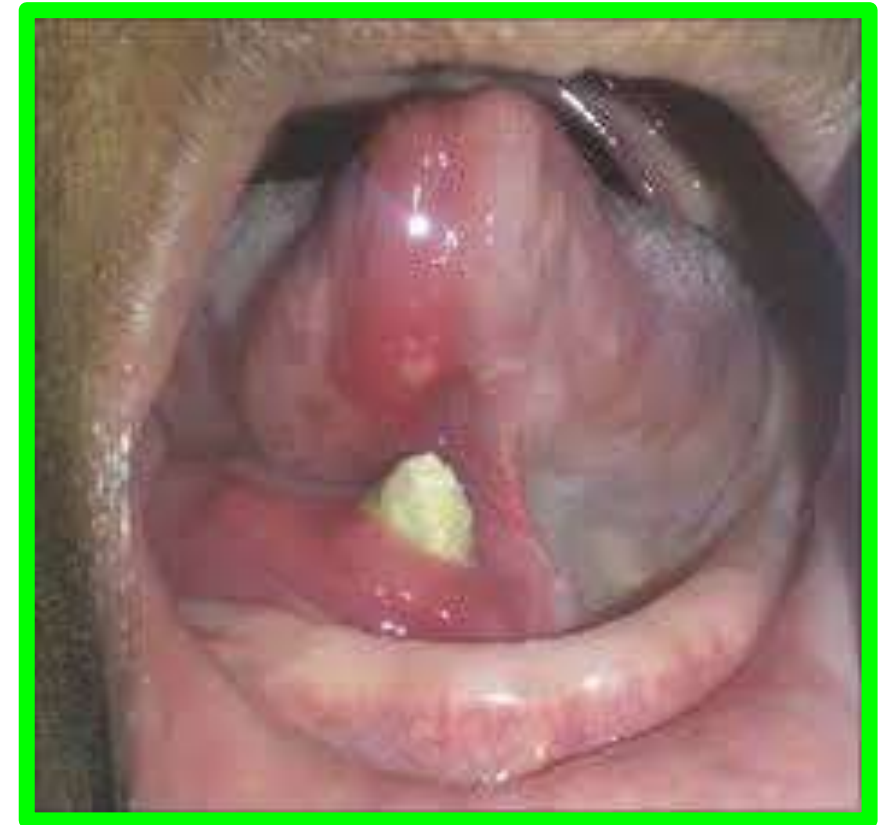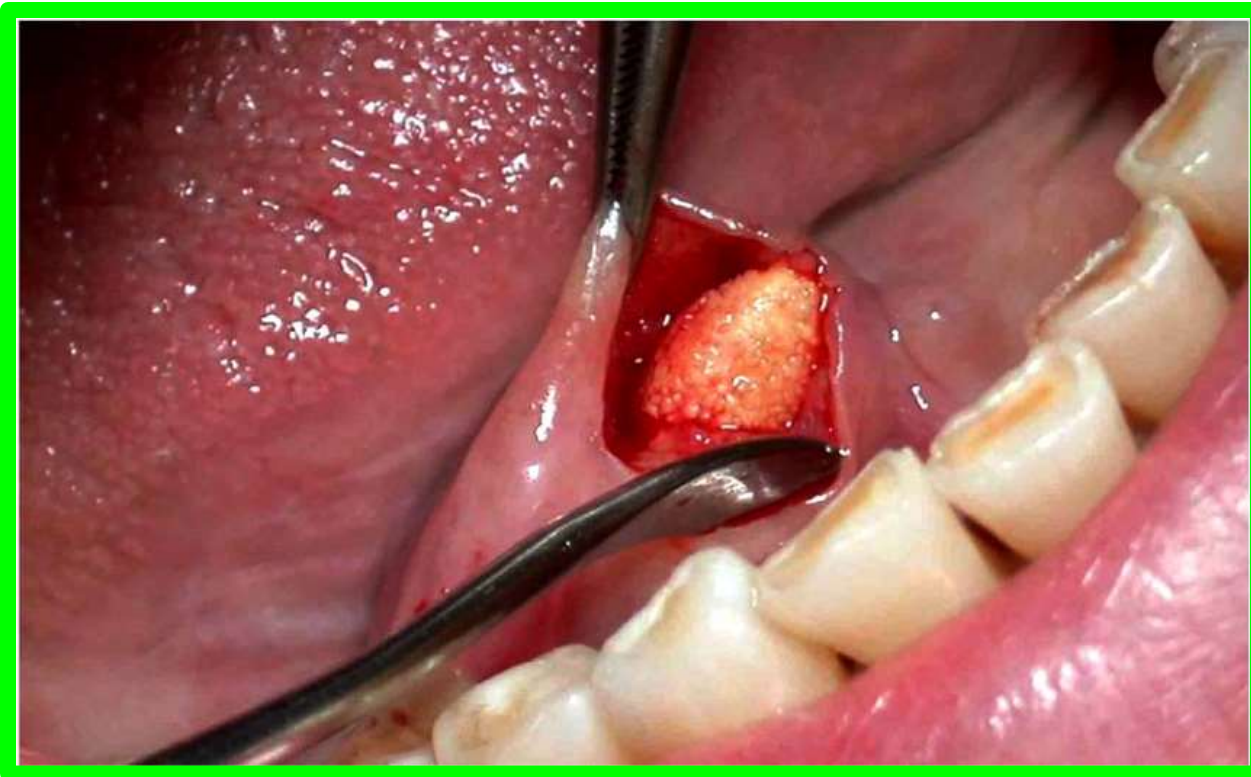
Submandibular Salivary Gland: Calculus Formation

- ✓ The submandibular salivary gland is **a common site of calculus formation**.
- ✓ This condition is rare in the other salivary glands.
- ✓ The presence of **a tense swelling below the body of the mandible**, which is greatest **before or during a meal** and is **reduced in size or absent between meals**, is diagnostic of the condition.



Submandibular gland

- ✓ Examination of the floor of the mouth will reveal **absence of ejection of saliva** from the orifice of the **duct of the affected gland**.
- ✓ Frequently, **the stone can be palpated in the duct**, which lies below the mucous membrane of the floor of the mouth.

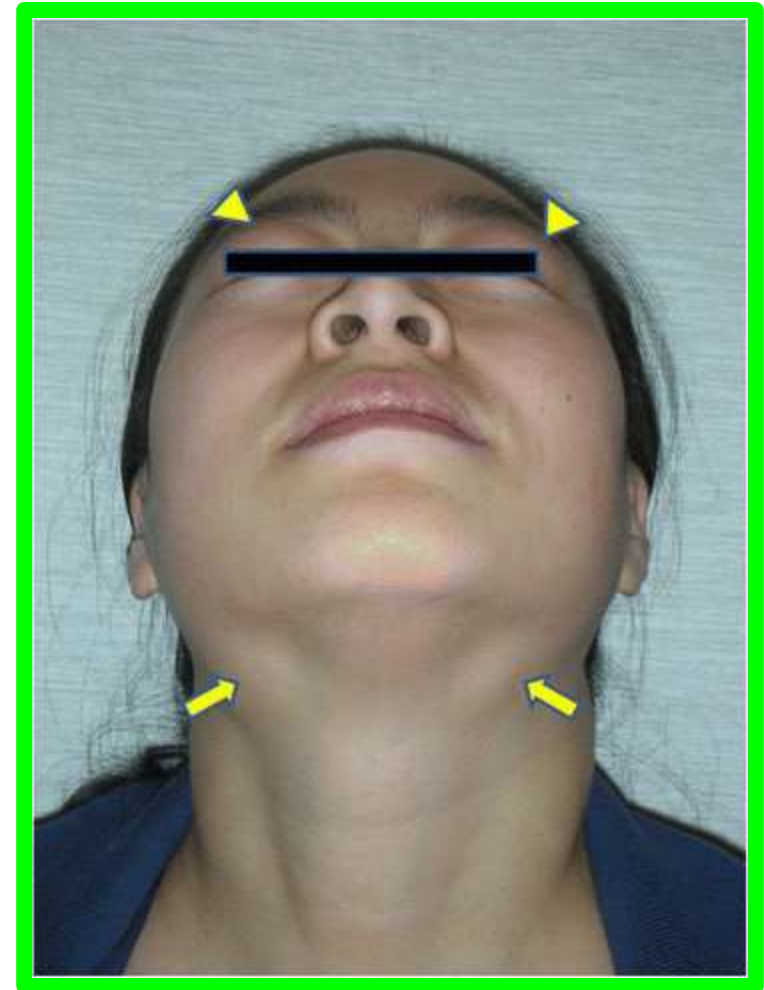


Enlargement of the Submandibular Lymph Nodes and Swelling of the Submandibular Salivary Gland

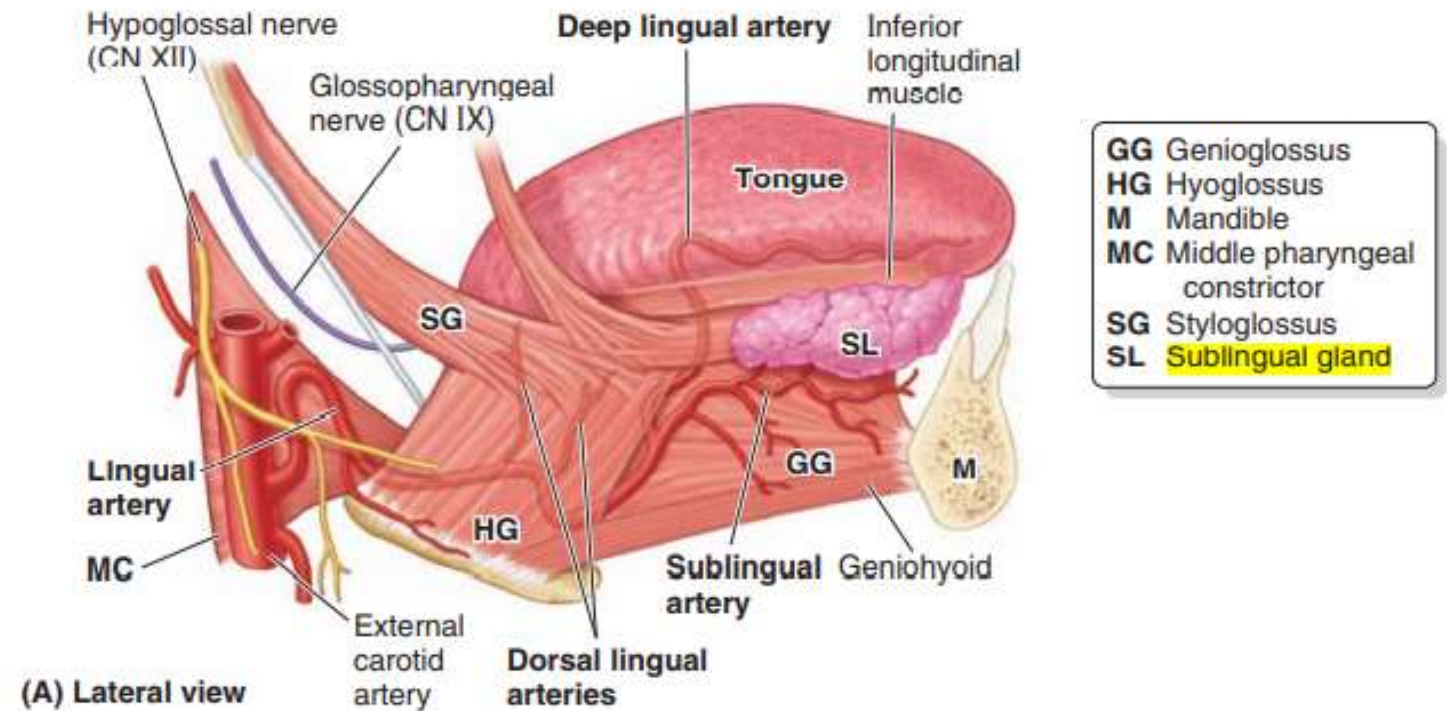
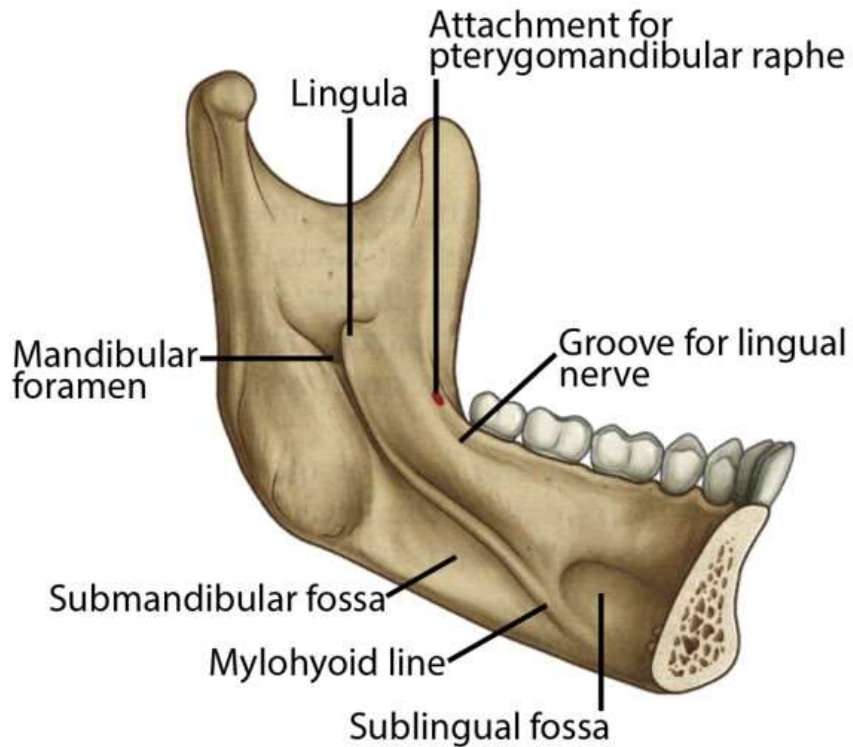
❖ The submandibular lymph nodes are commonly enlarged as a result of a pathologic condition of the scalp, face, maxillary sinus, or mouth cavity

❖ One of the most common causes of painful enlargement of these nodes is **acute infection of the teeth**.

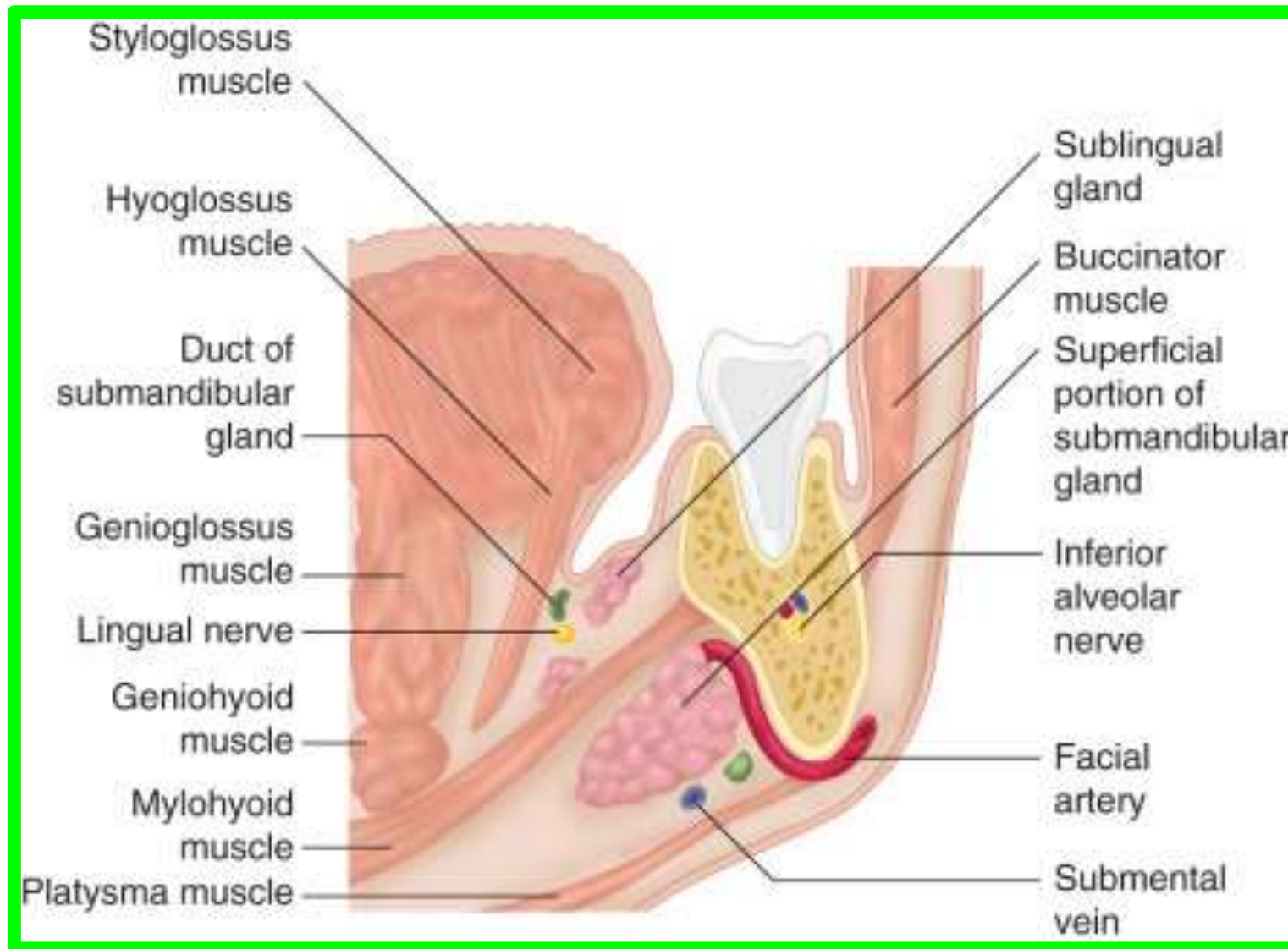
❖ Enlargement of these nodes should not be confused with pathologic swelling of the submandibular salivary gland.



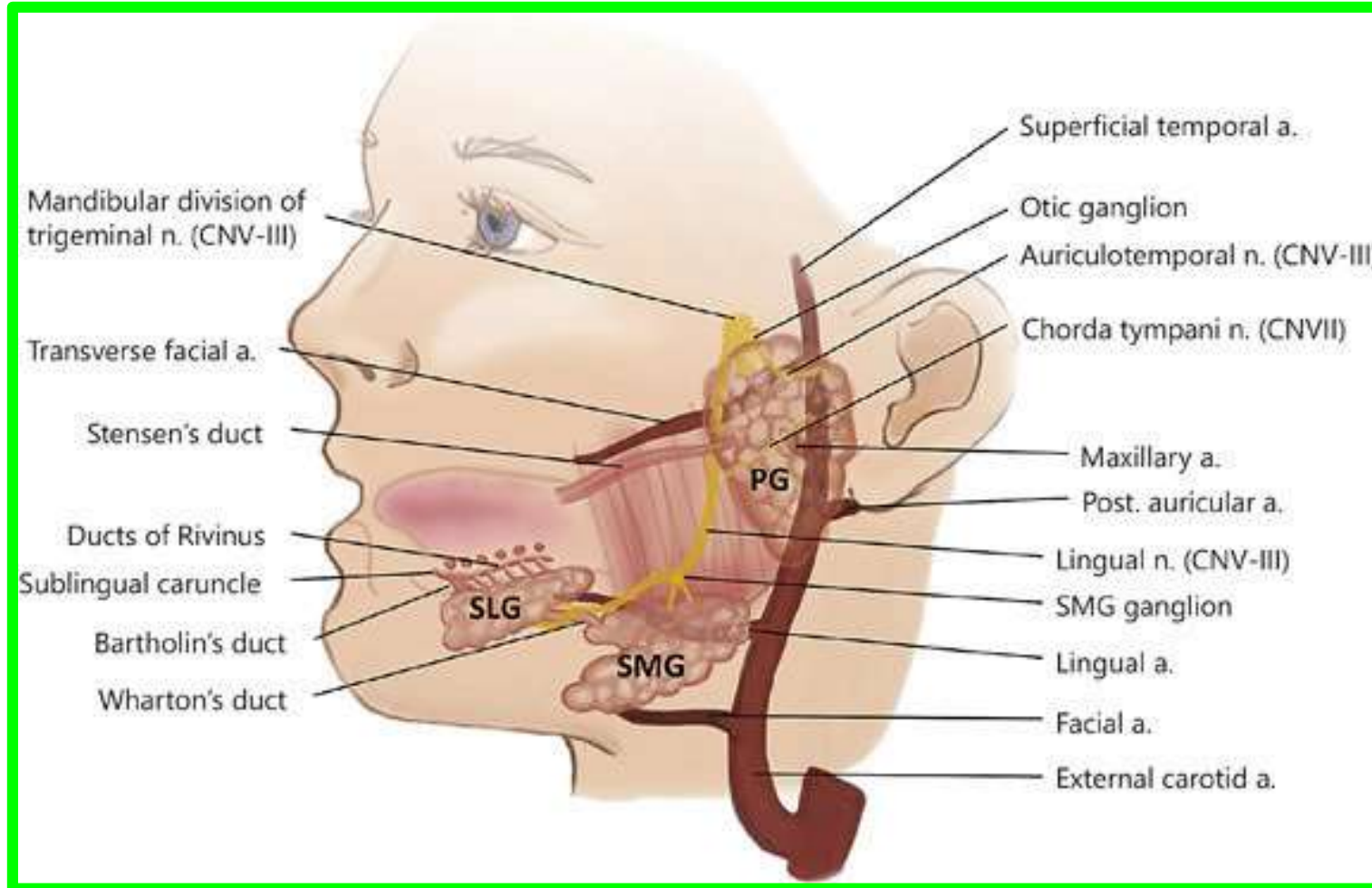
SUBLINGUAL SALIVARY GLAND



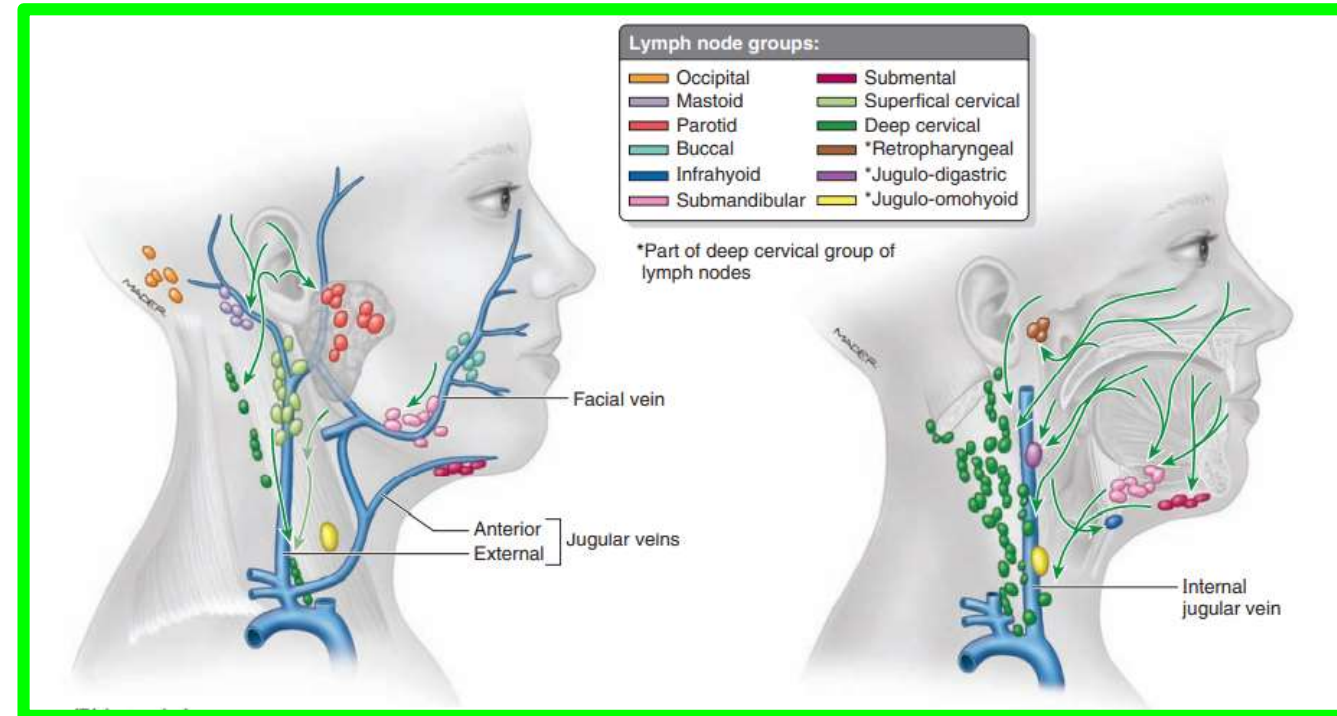
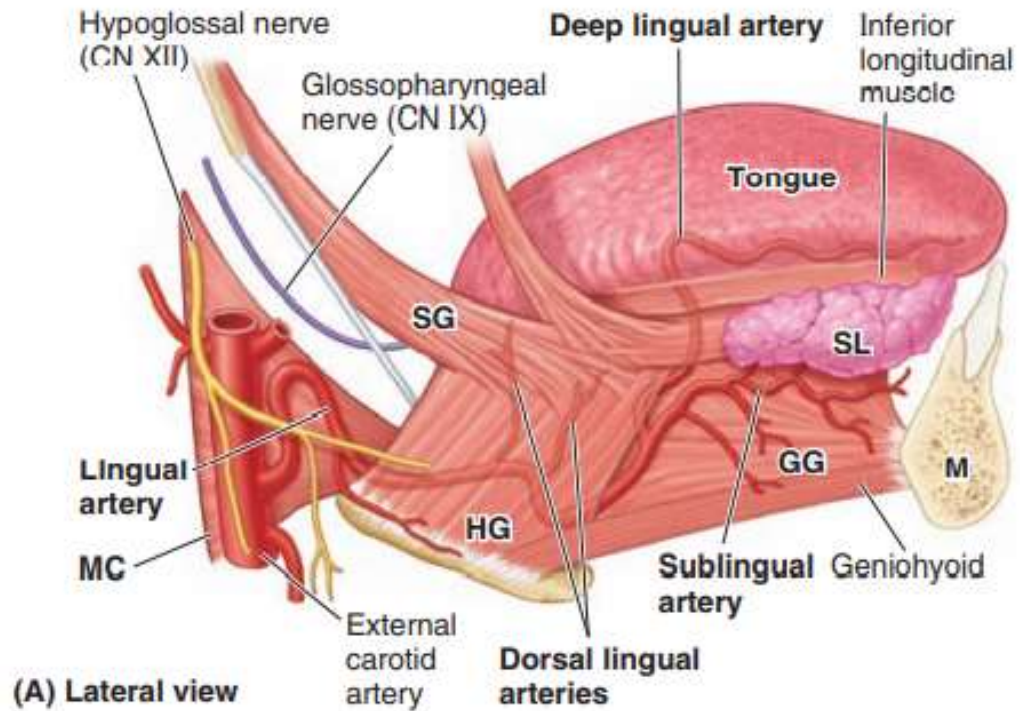
SUBLINGUAL SALIVARY GLAND



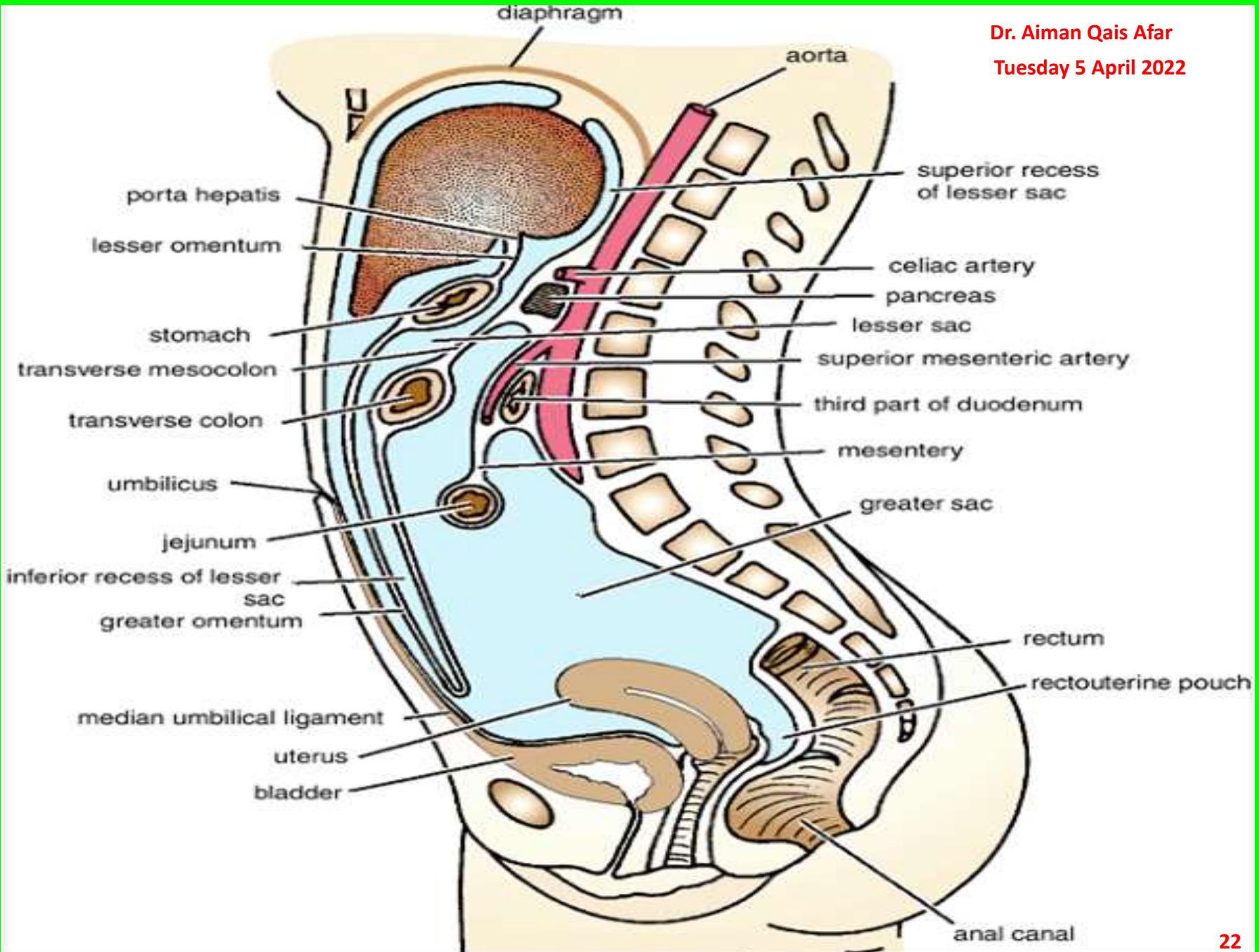
SUBLINGUAL SALIVARY GLAND

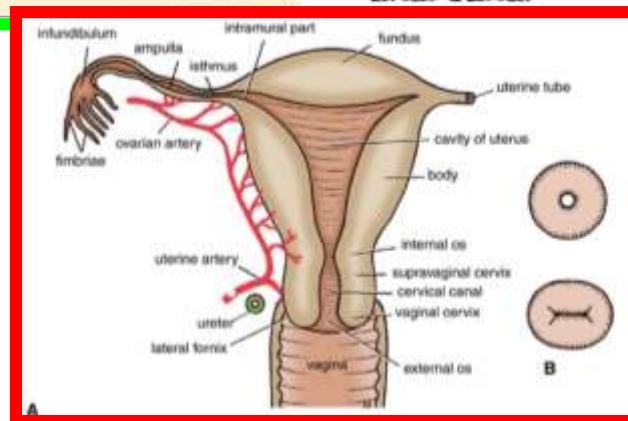
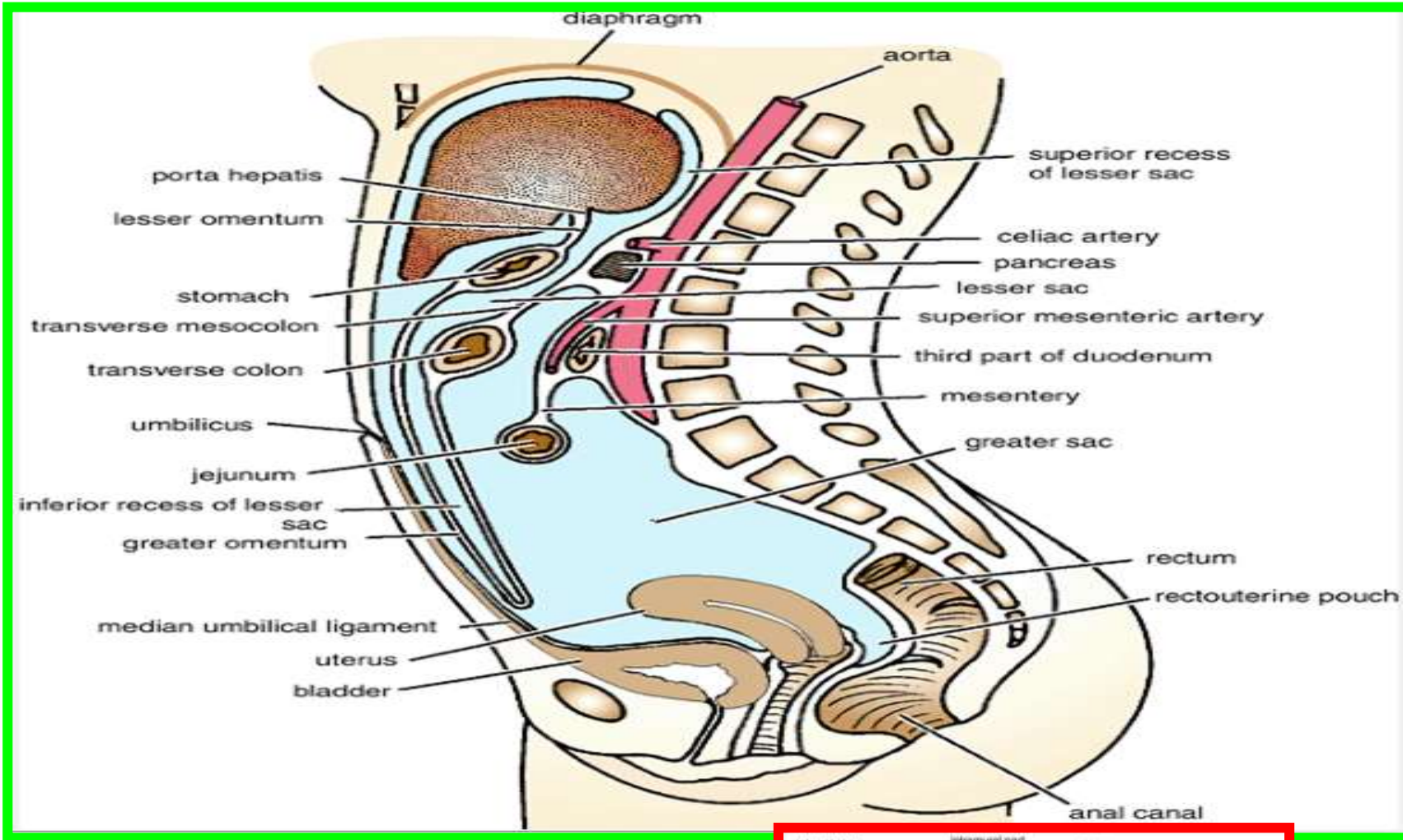


SUBLINGUAL SALIVARY GLAND



Dr. Aiman Qais Afar
Tuesday 5 April 2022





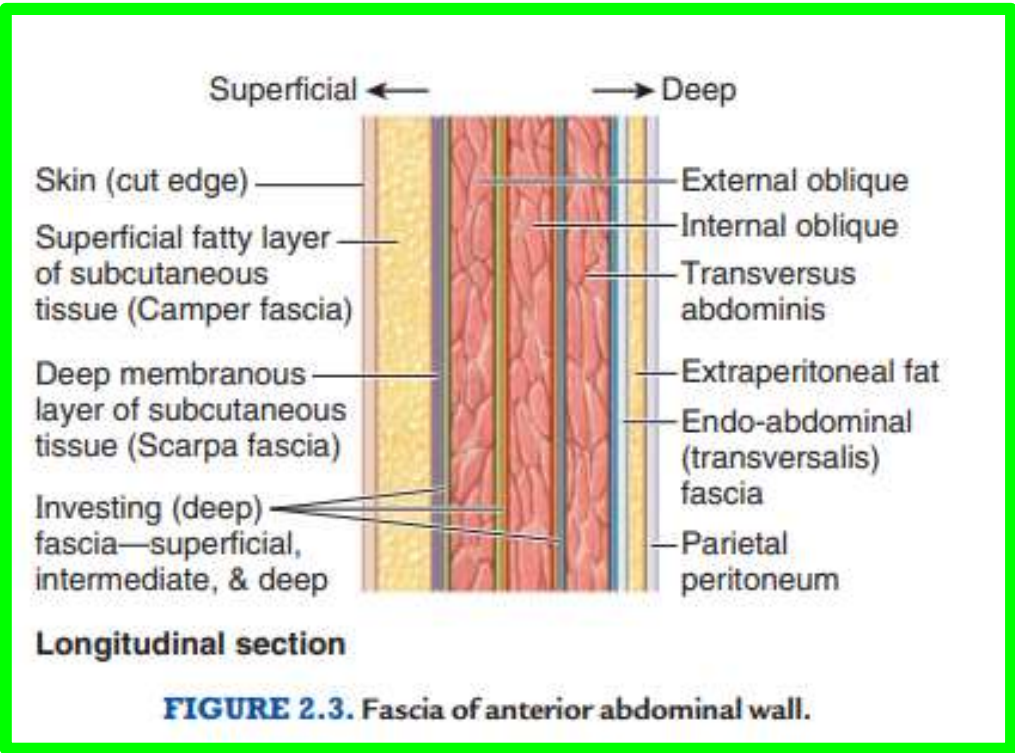
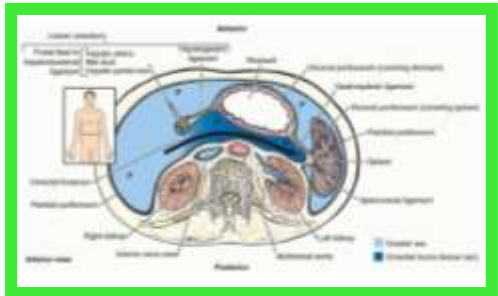
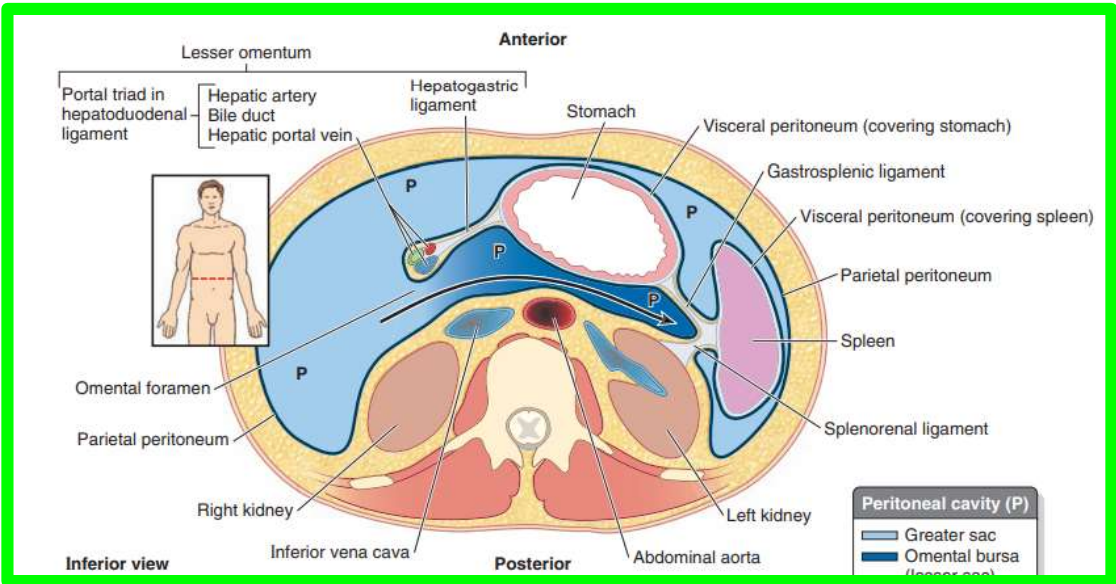
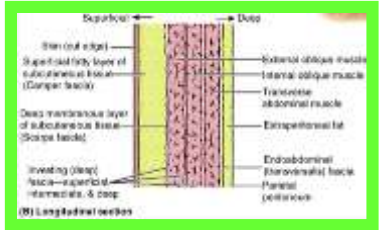
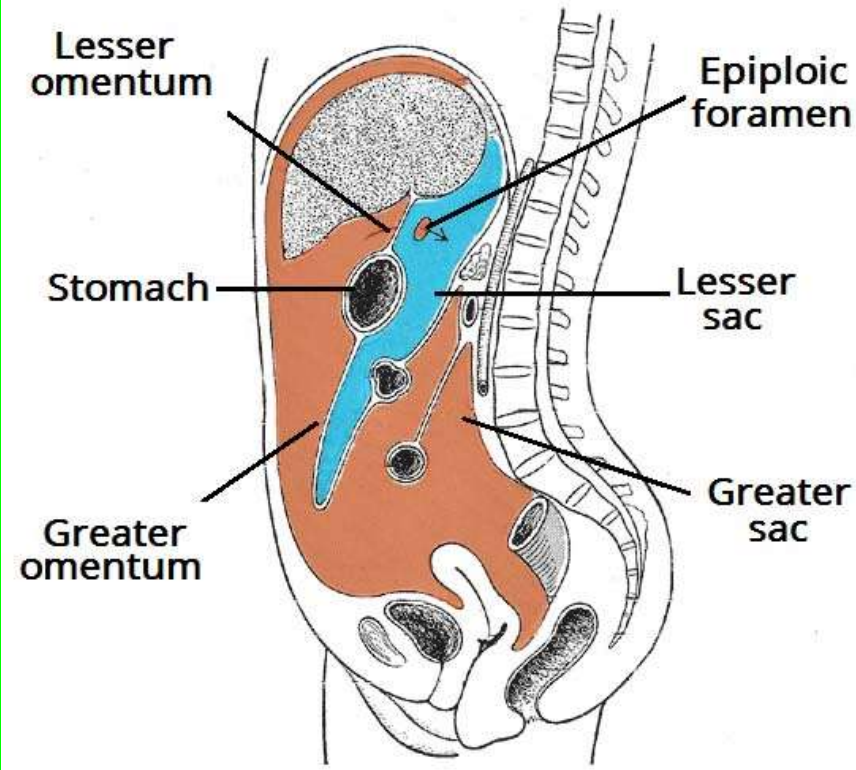
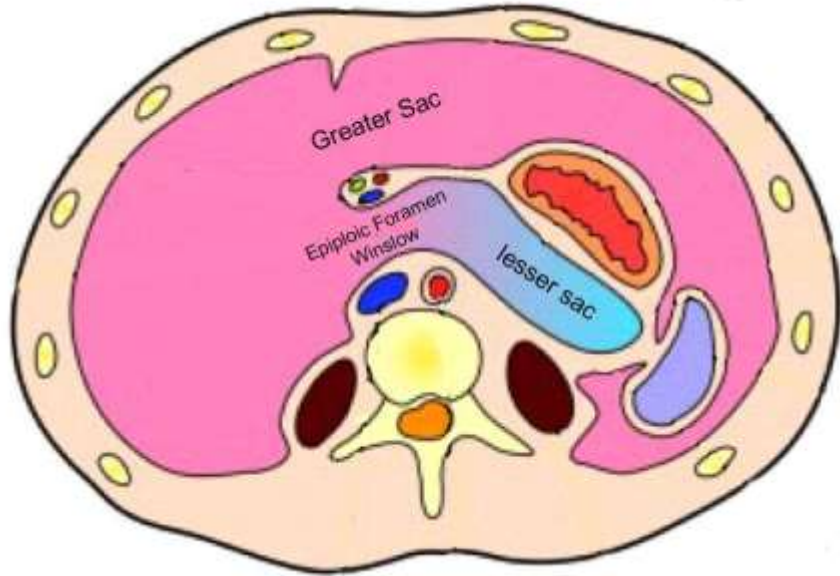


FIGURE 2.3. Fascia of anterior abdominal wall.

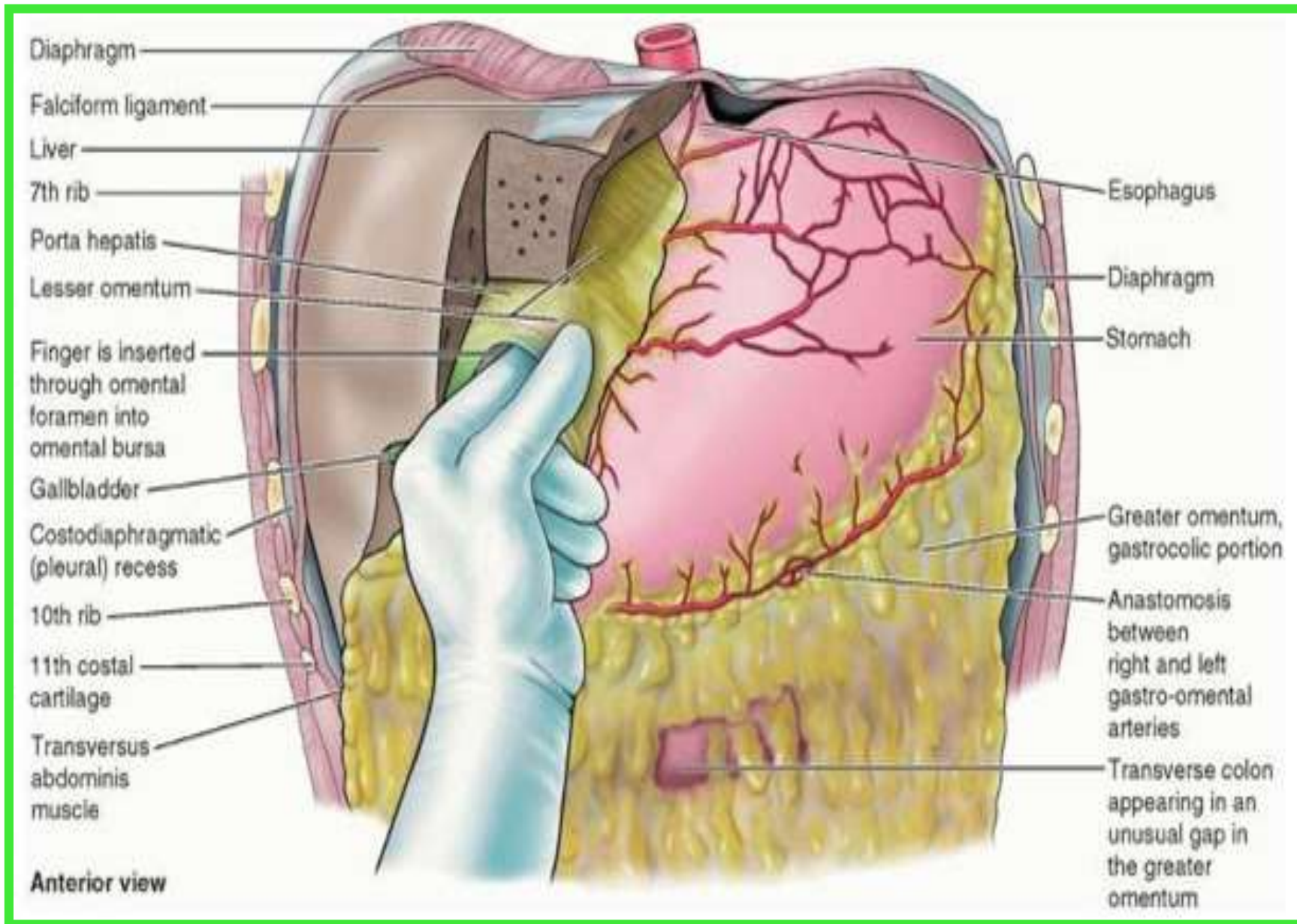


PERITONEUM

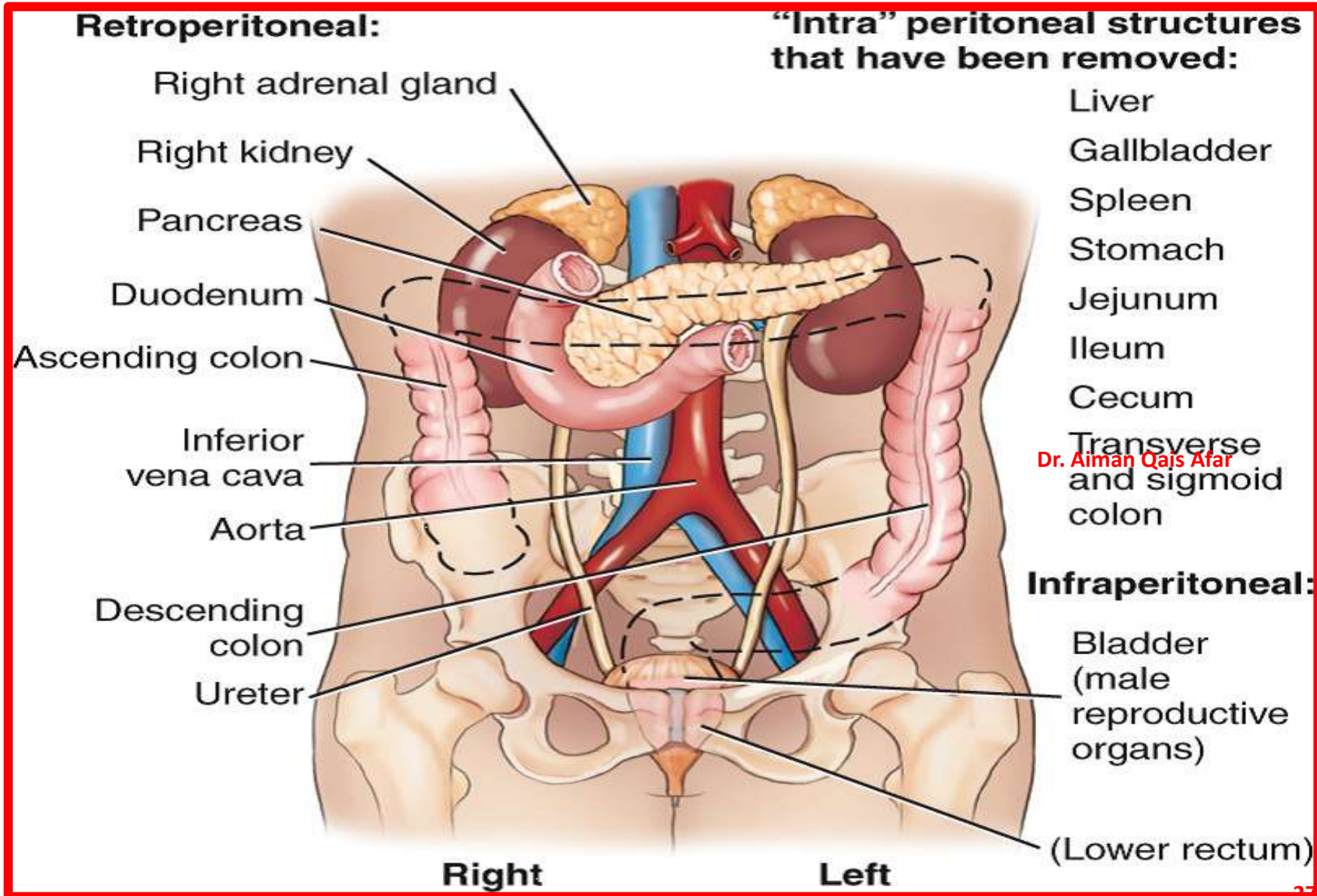
General Arrangement



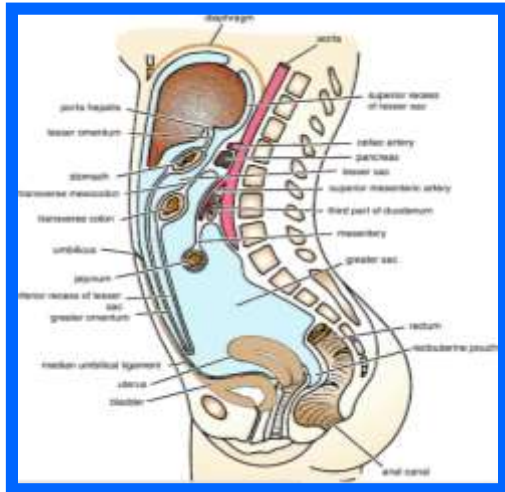
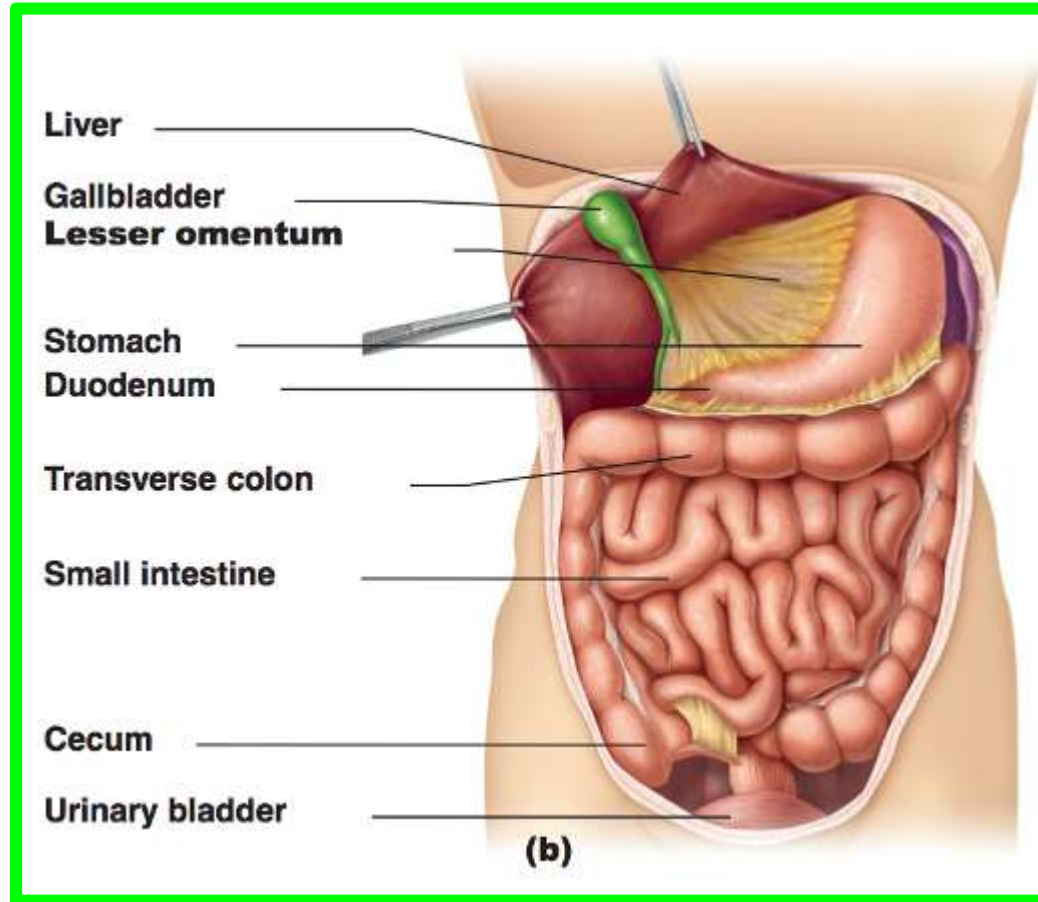
© teachmeanatomy
The #1 Applied Human Anatomy Site on the Web.



Intraperitoneal and Retroperitoneal Relationships



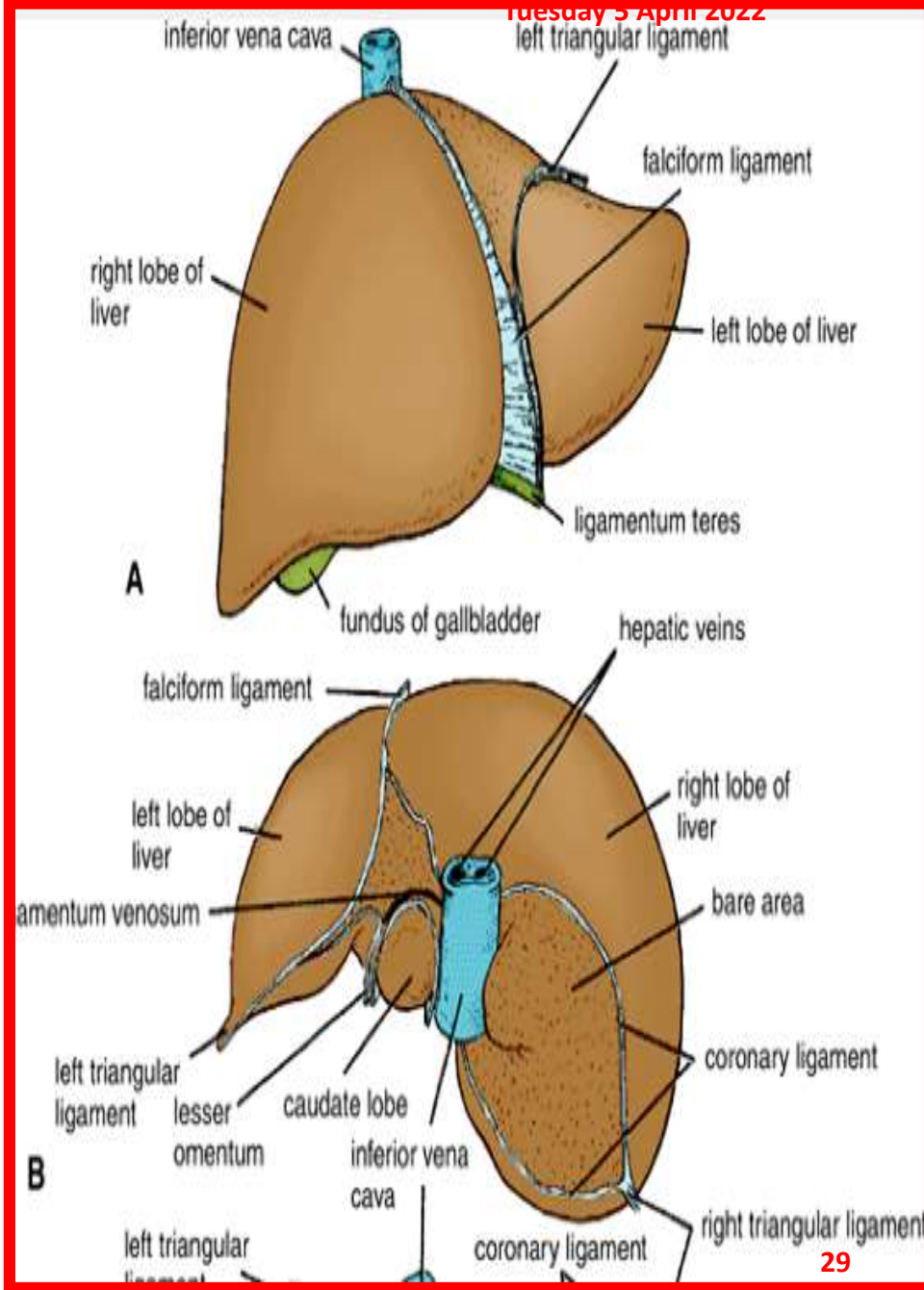
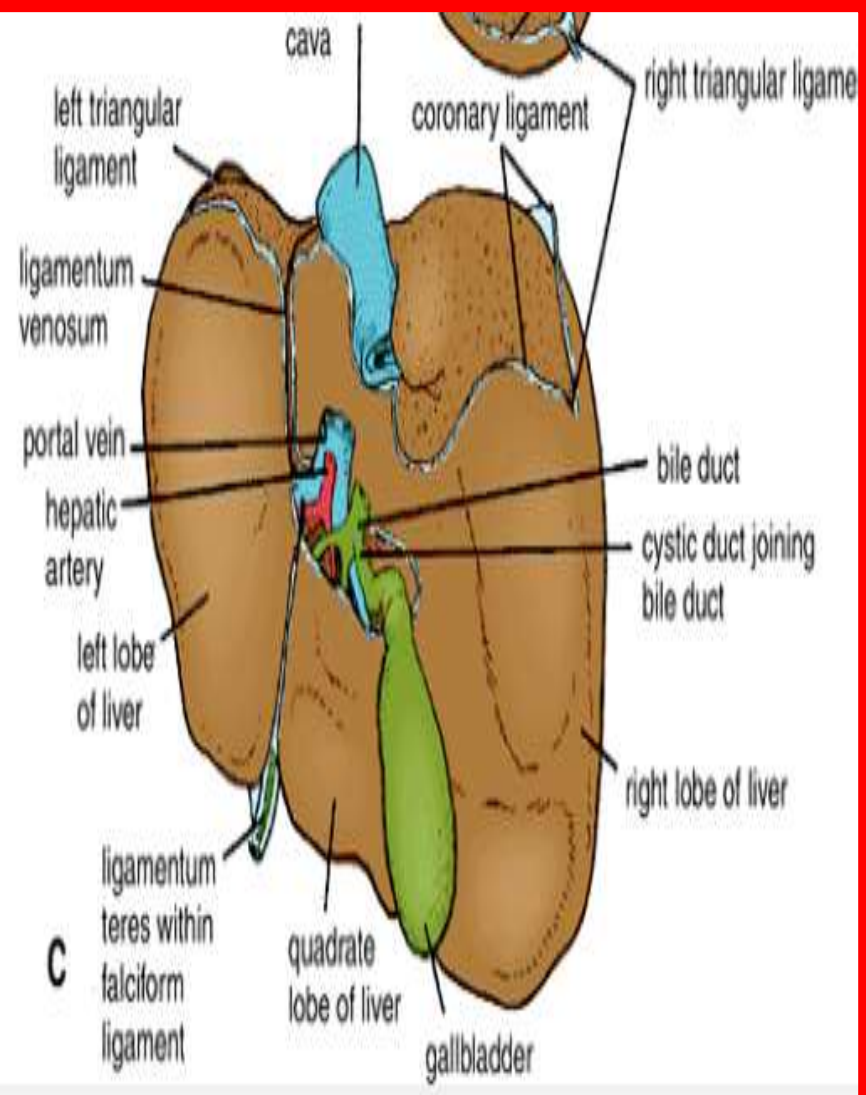
Intraperitoneal and Retroperitoneal Relationships



Peritoneal Ligaments

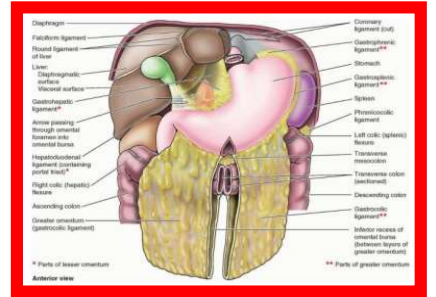
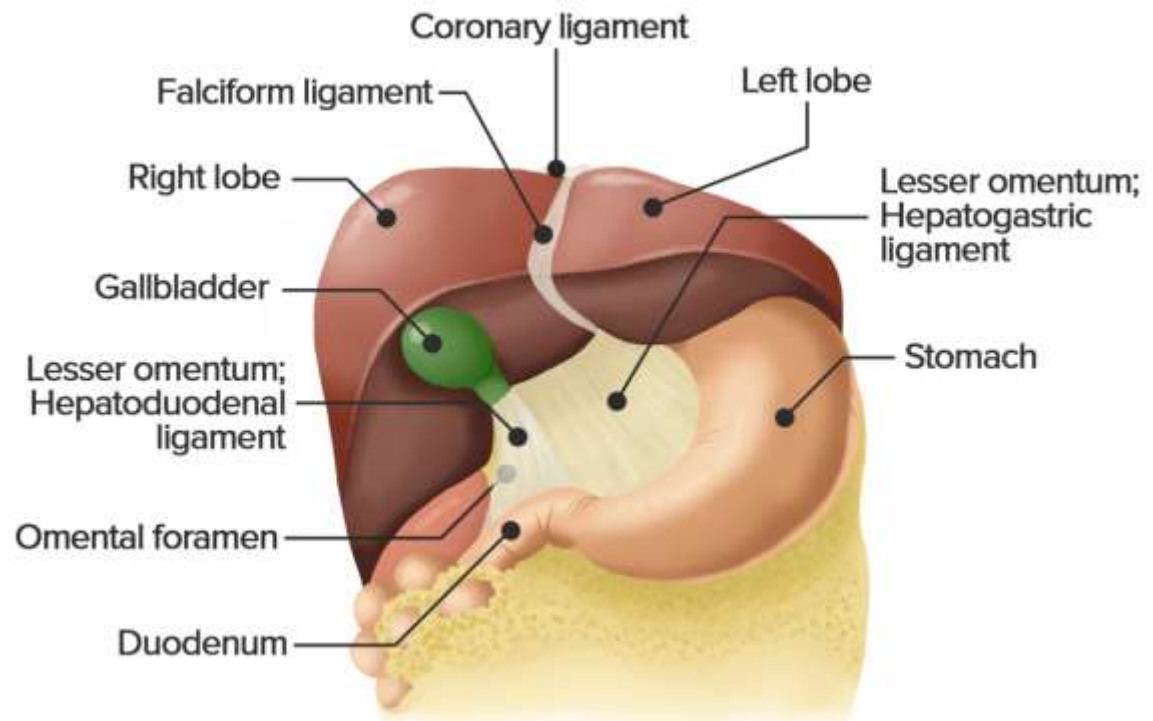
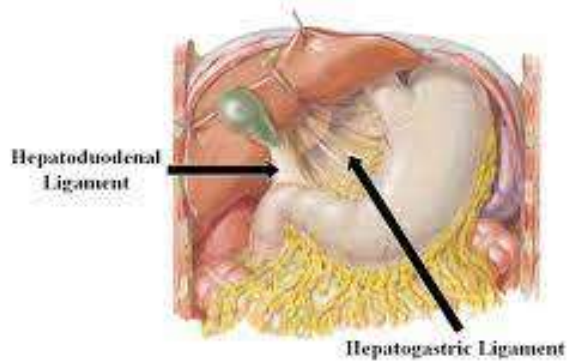
Dr. Aiman Oais Afar

Tuesday 5 April 2022



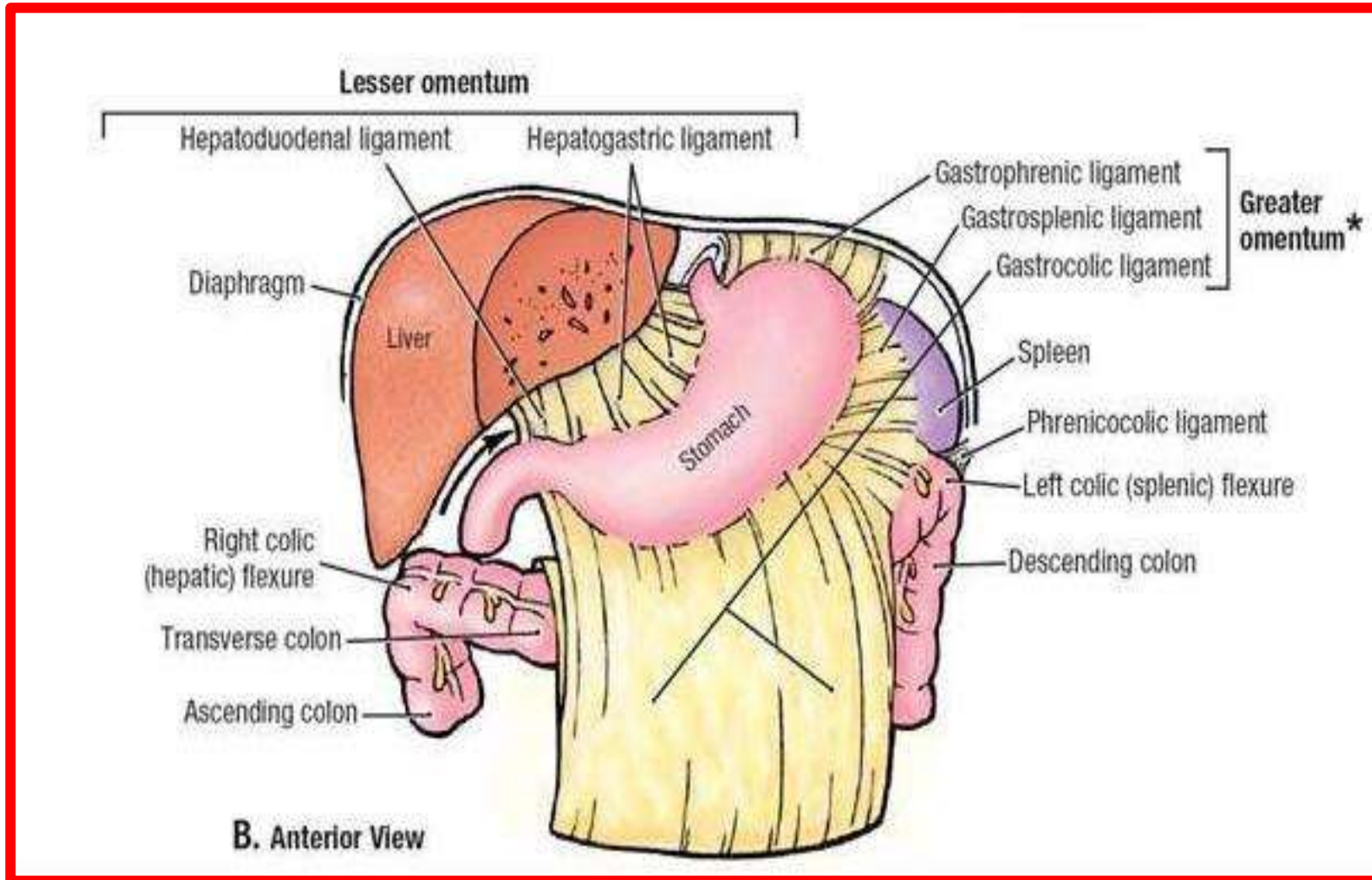
Peritoneal Ligaments

SUPRACOLIC REGION - LIVER
Portal Triad

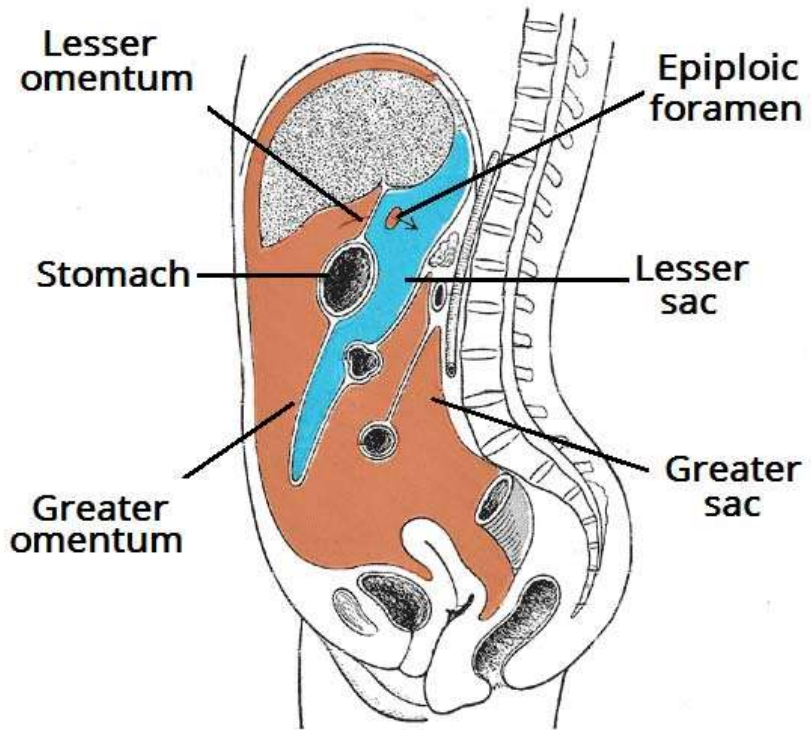


Peritoneal Ligaments

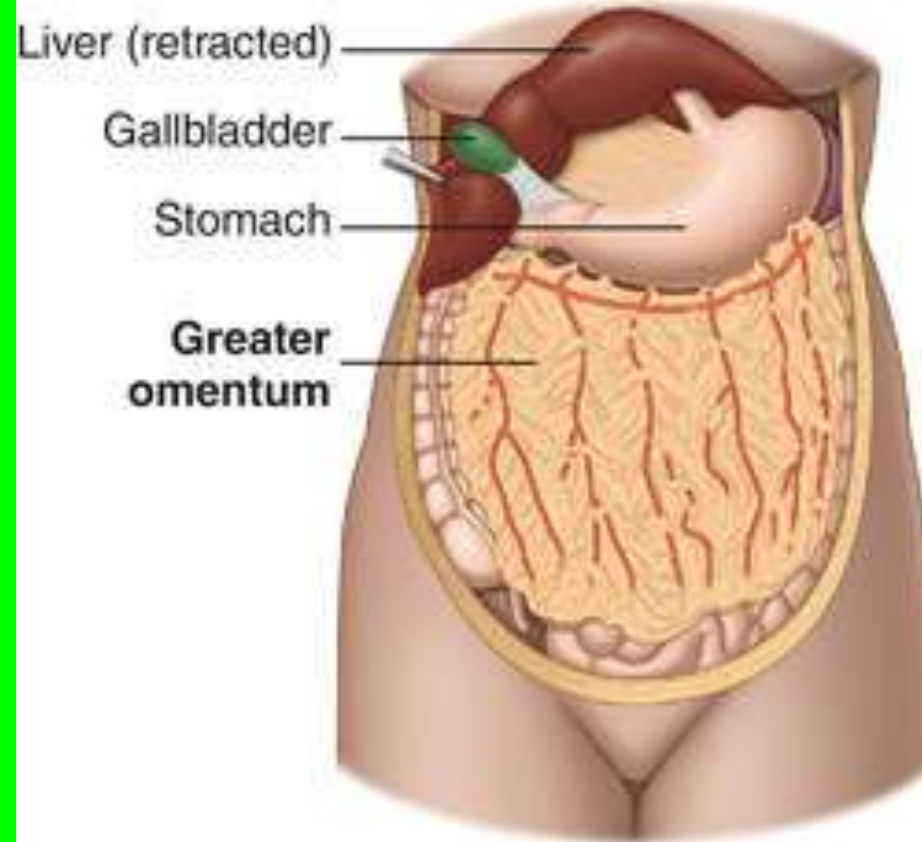
Dr. Aiman Qais Afar
Tuesday 5 April 2022

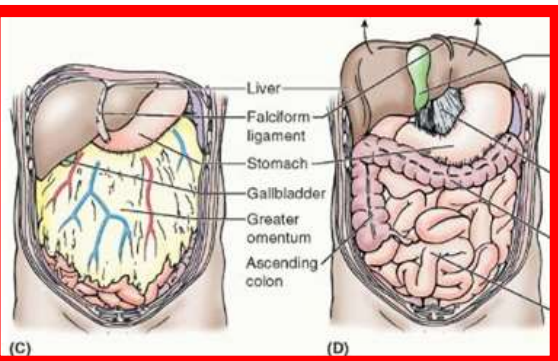
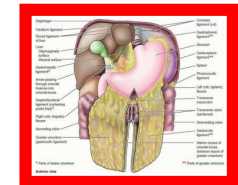
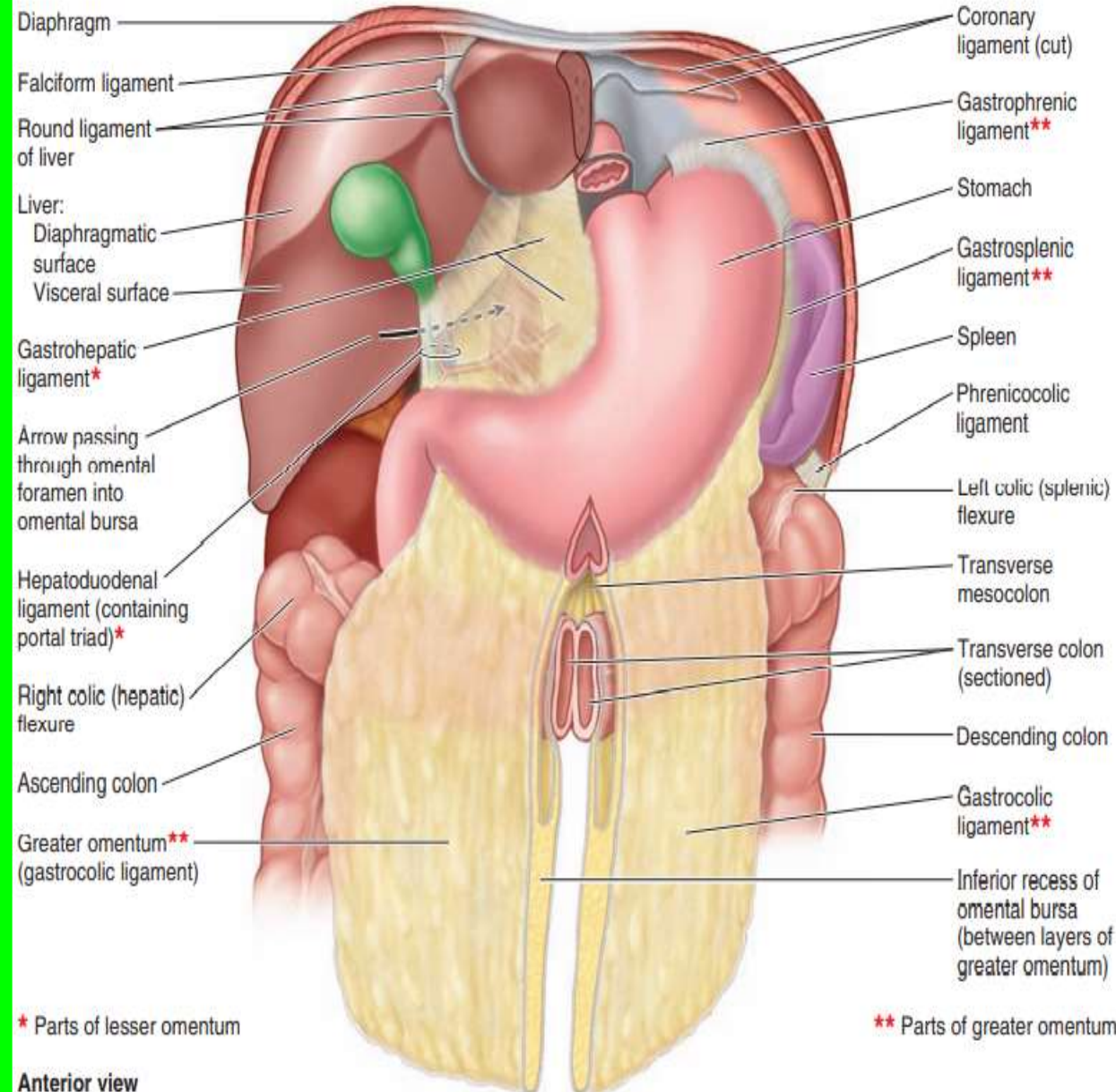


Omenta



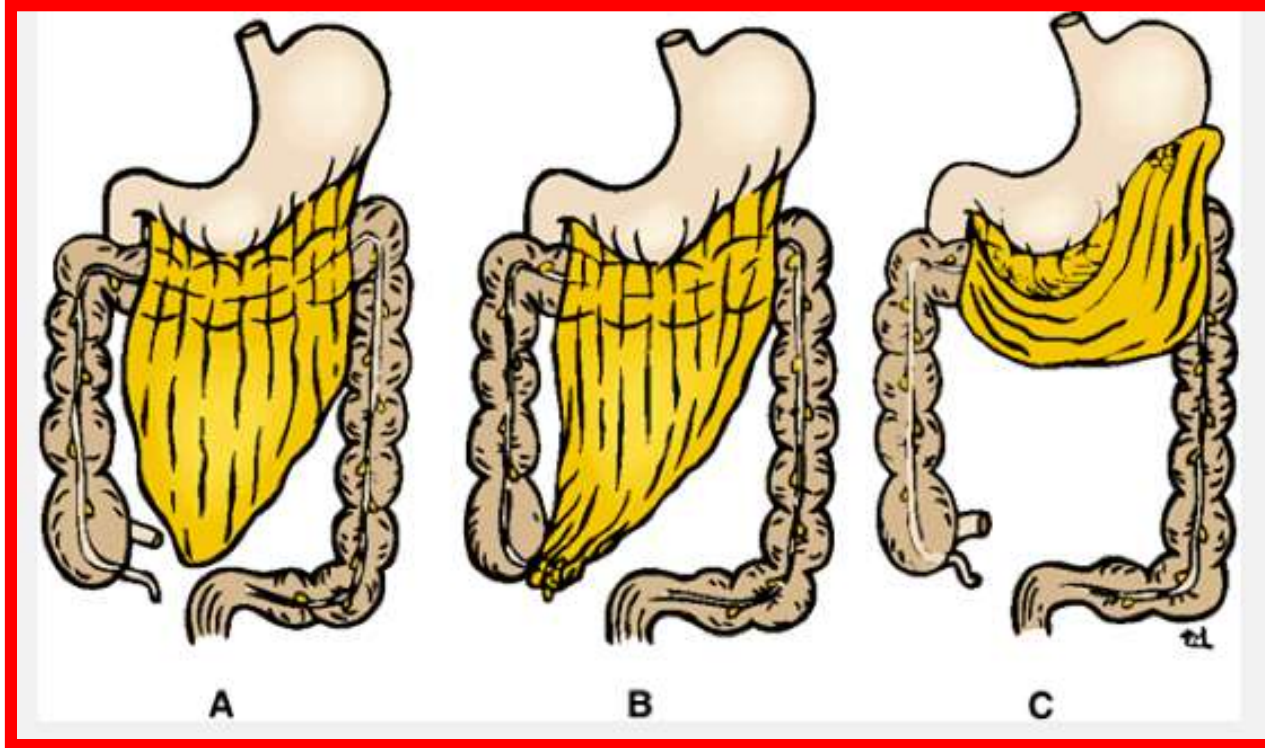
© teachmeanatomy
The #1 Applied Human Anatomy Site on the Web.



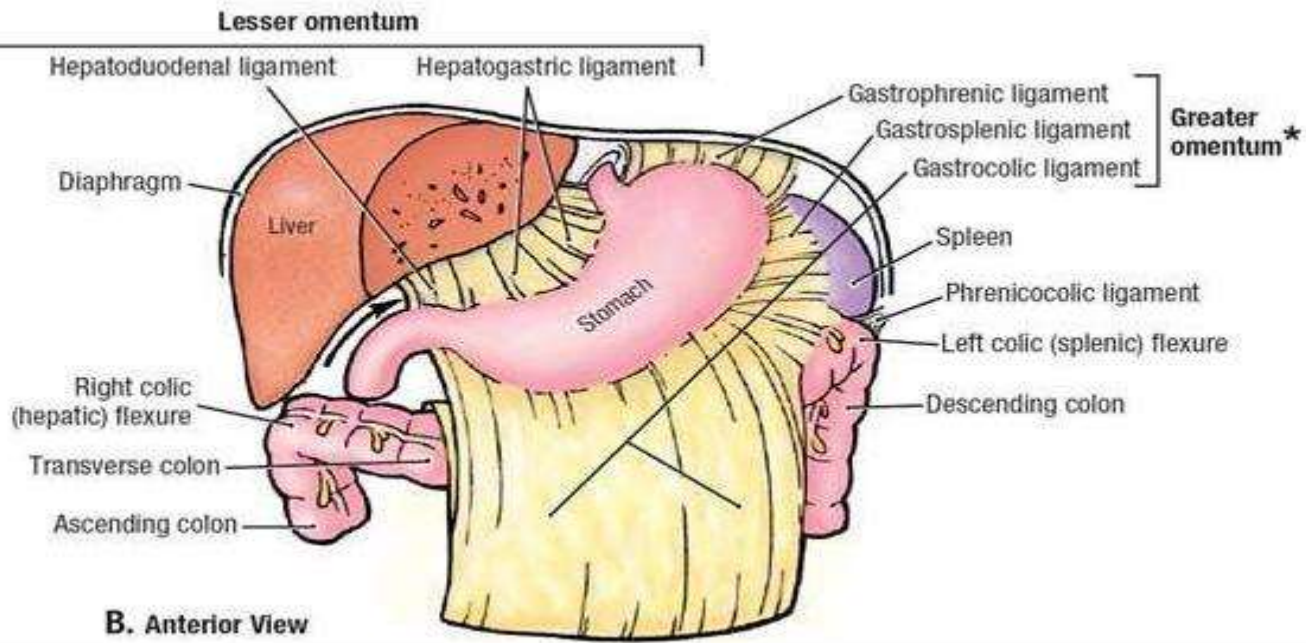


Omenta

The greater omentum



Omenta

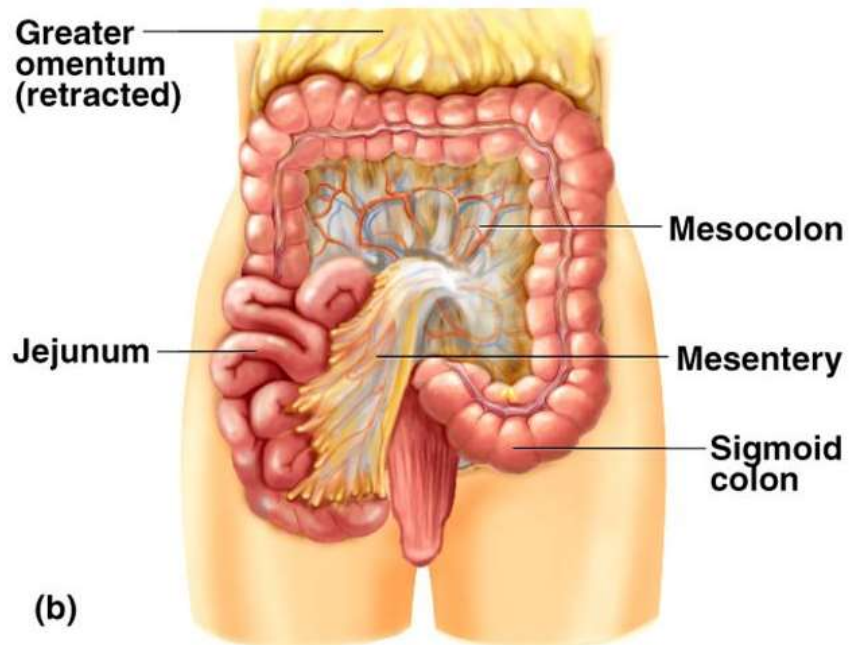


Dr. Aiman Qais Afar
Tuesday 5 April 2022

Mesenteries

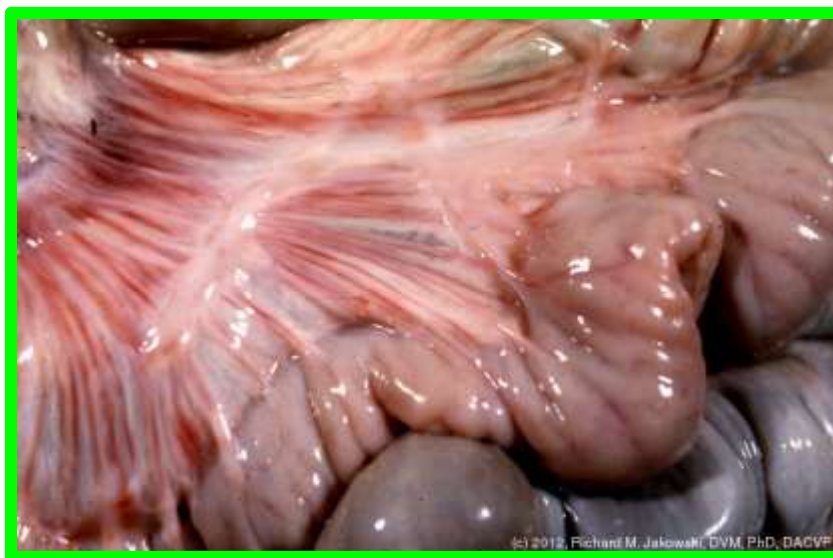Dr. Aiman Qais Afar

Mesentery and Mesocolon



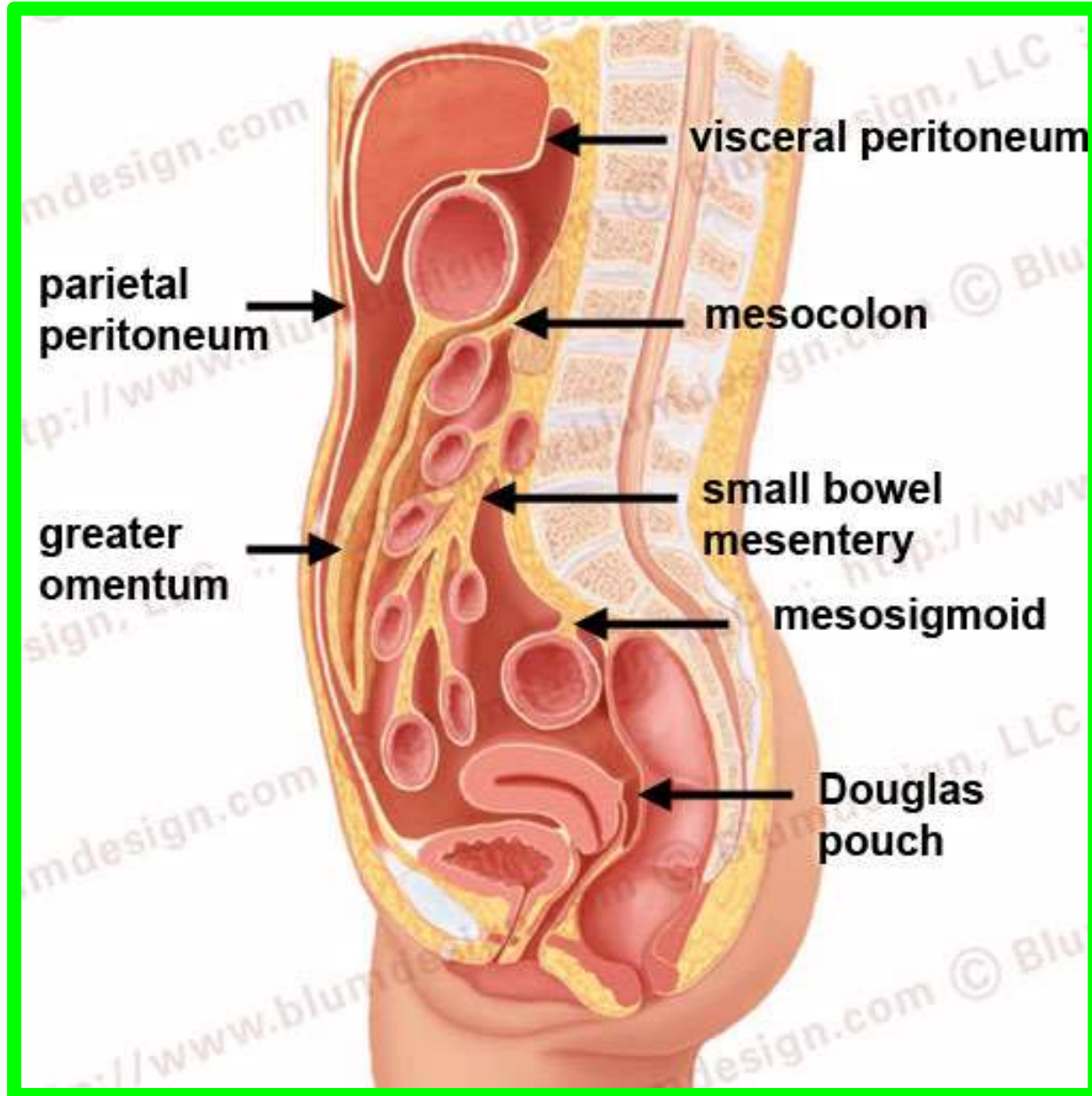
36

Tuesday 5 April 2022

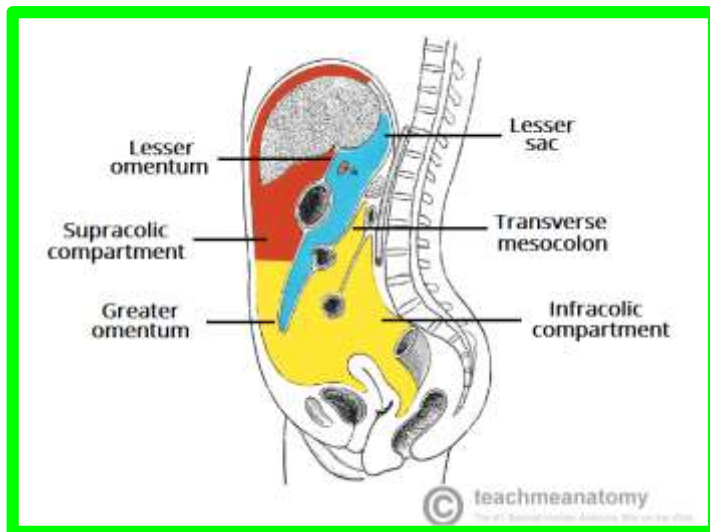
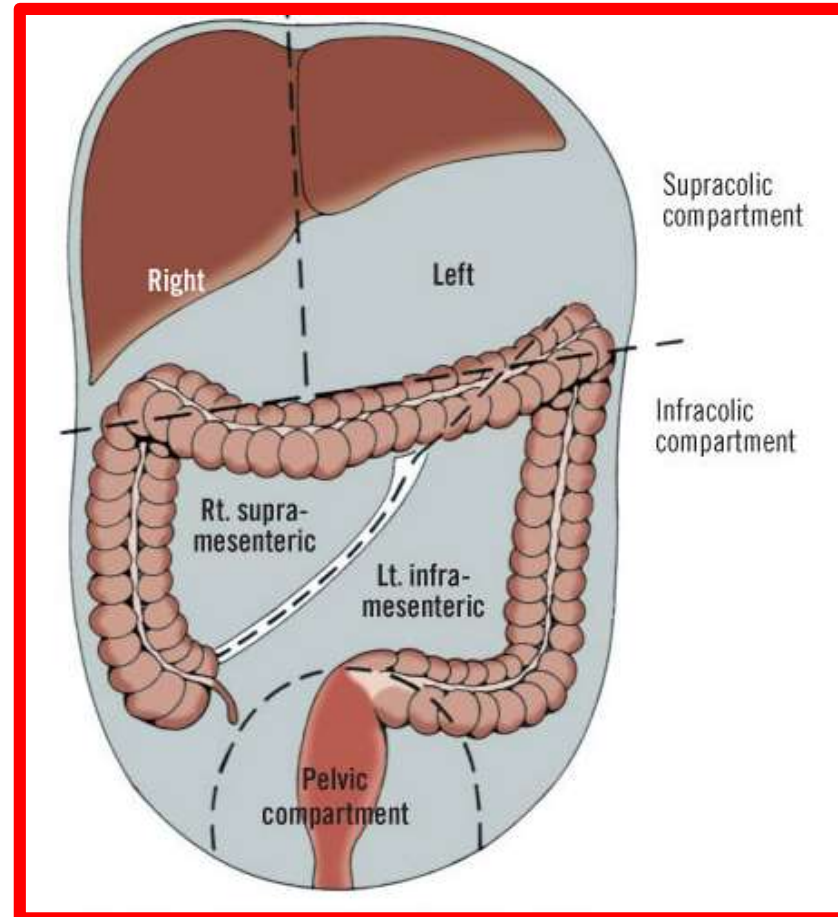


Mesenteries

Dr. Aiman Qais Afar

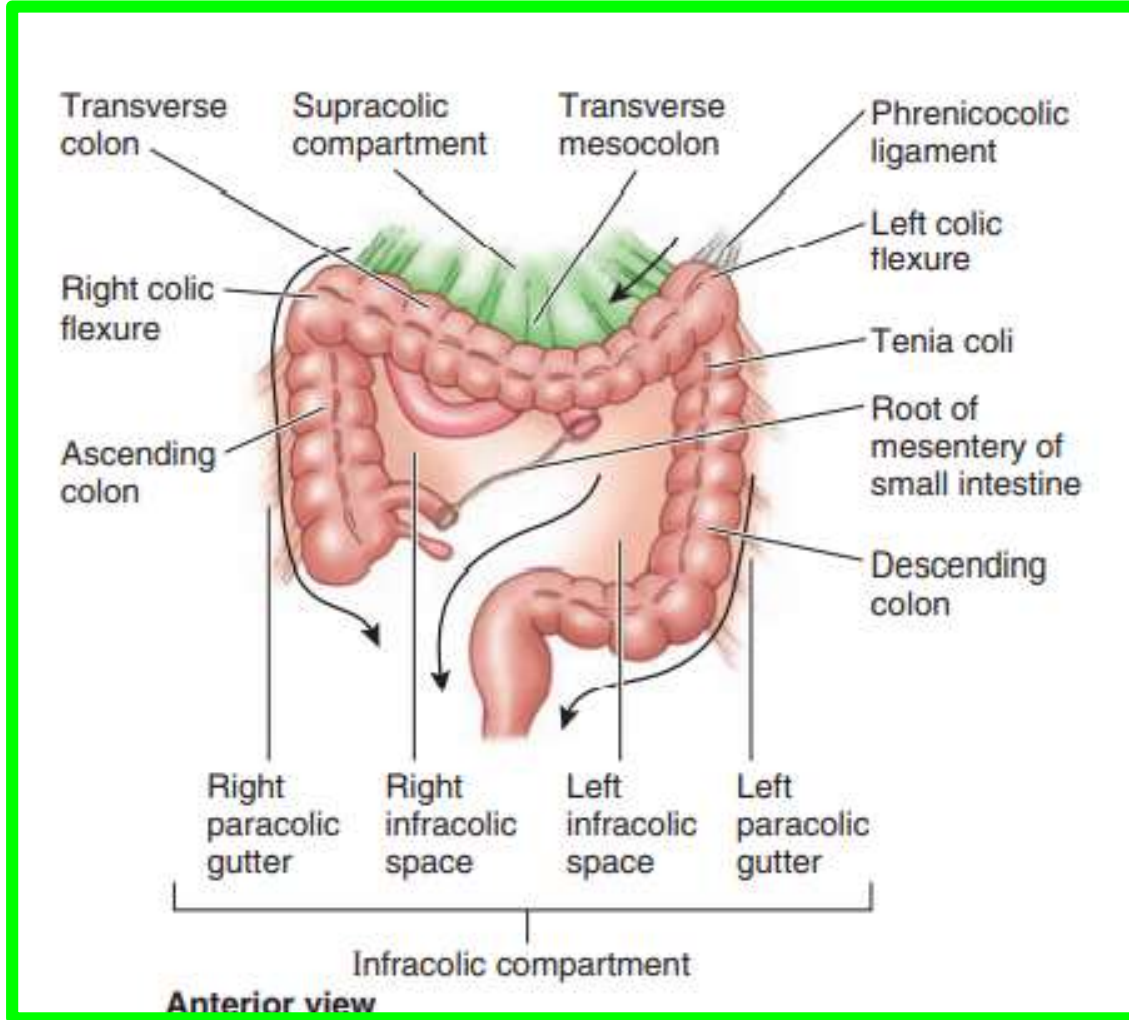


Subdivisions of Peritoneal Cavity



Dr. Aiman Qais Afar
Tuesday 5 April 2022

Subdivisions of Peritoneal Cavity

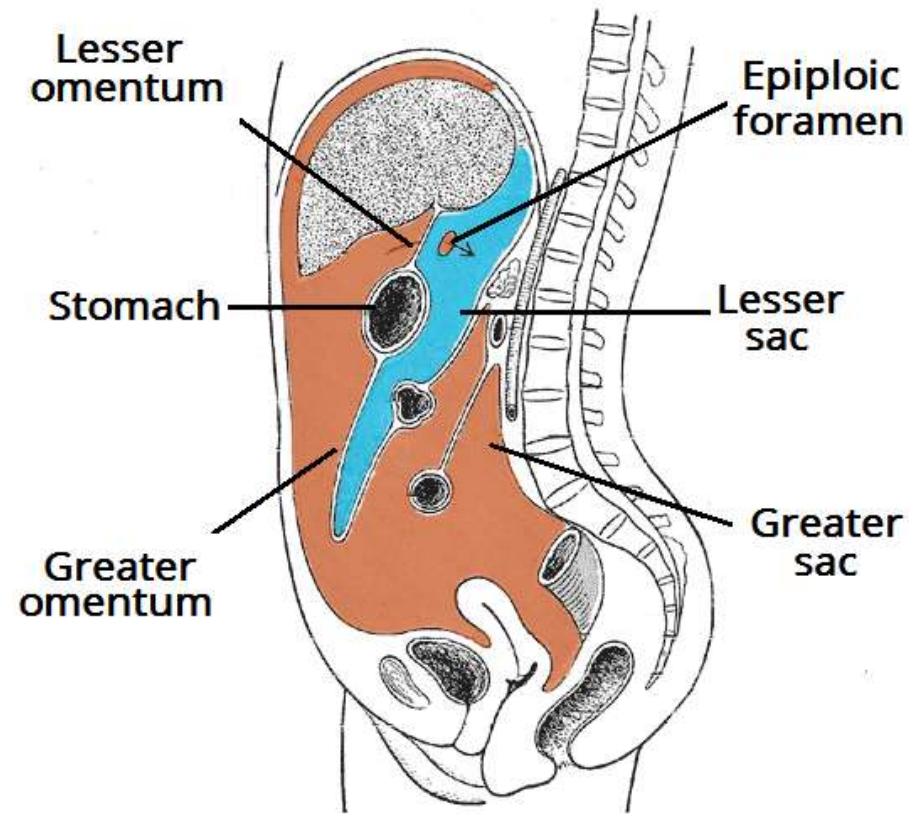
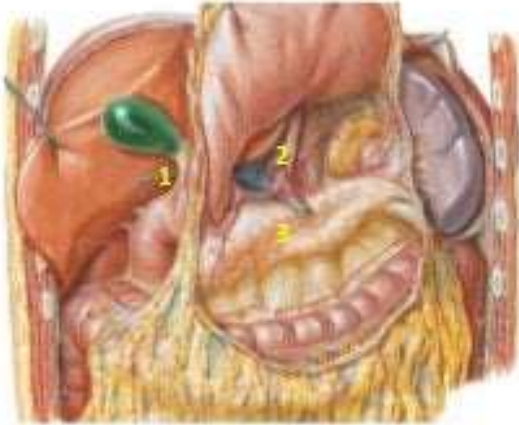

Peritoneal Pouches, Recesses, Spaces, and Gutters

Lesser Sac

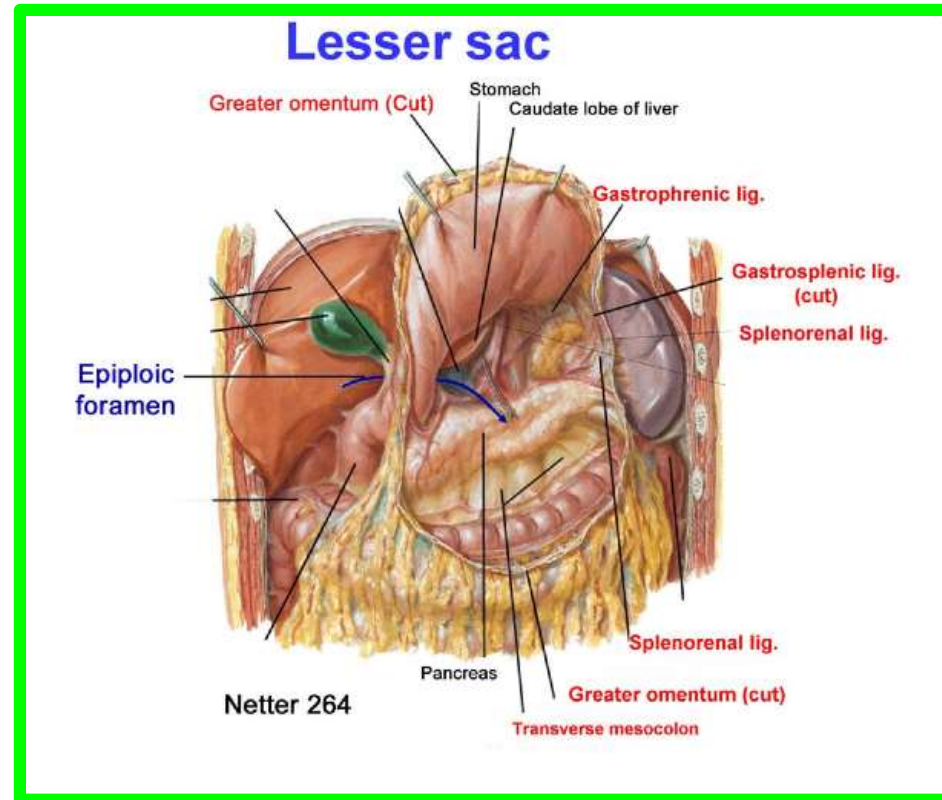
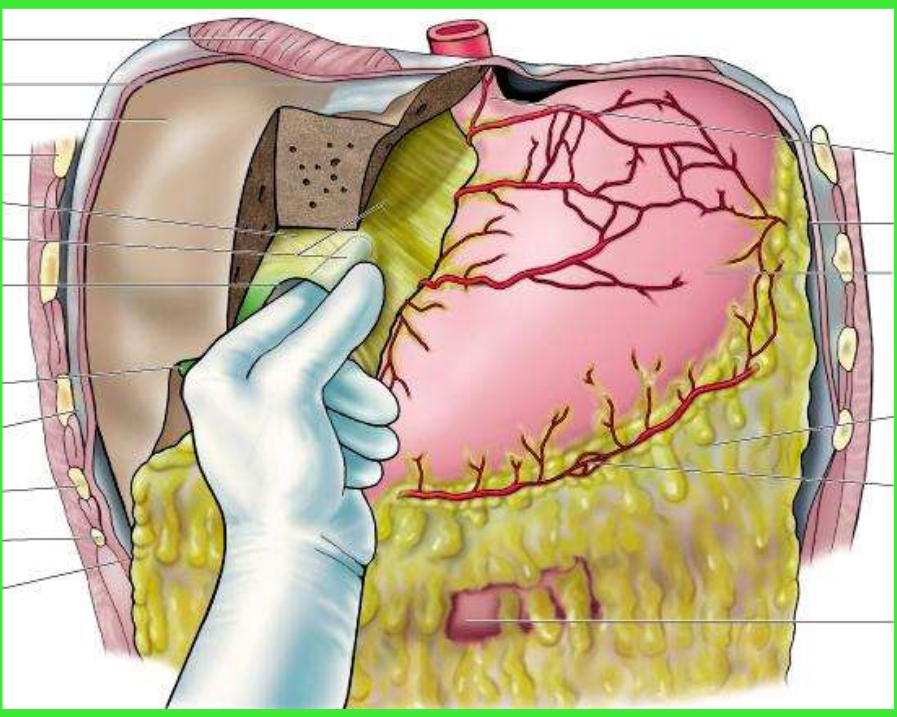
Epiploic foramen location "important" !!

1. Epiploic foramen
2. To superior recess of lesser omental bursa
3. Pancreas (retroperitoneal)



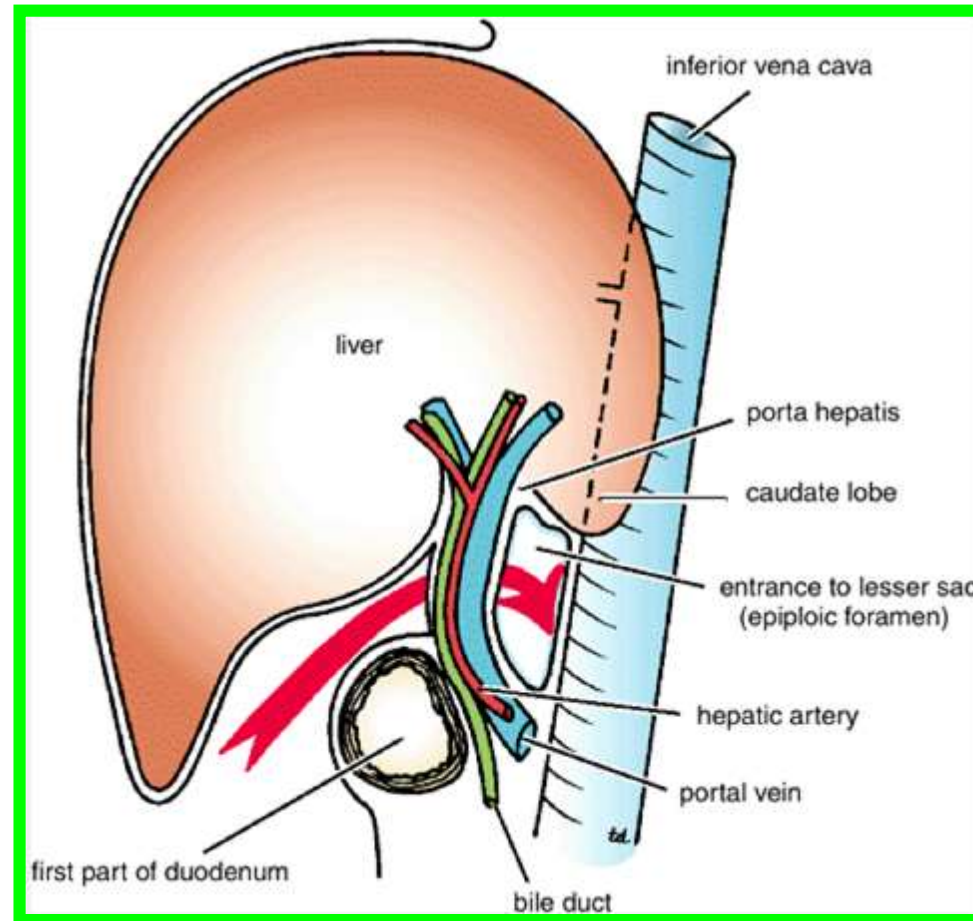
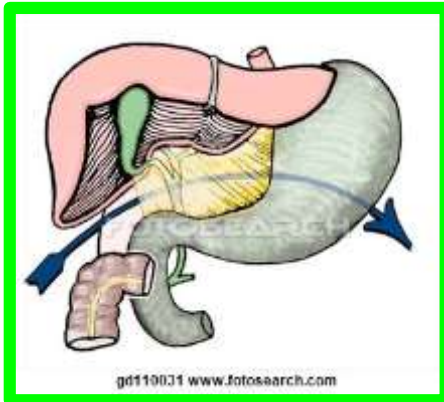
Peritoneal Pouches, Recesses, Spaces, and Gutters

Lesser Sac



Peritoneal Pouches, Recesses, Spaces, and Gutters

Lesser Sac

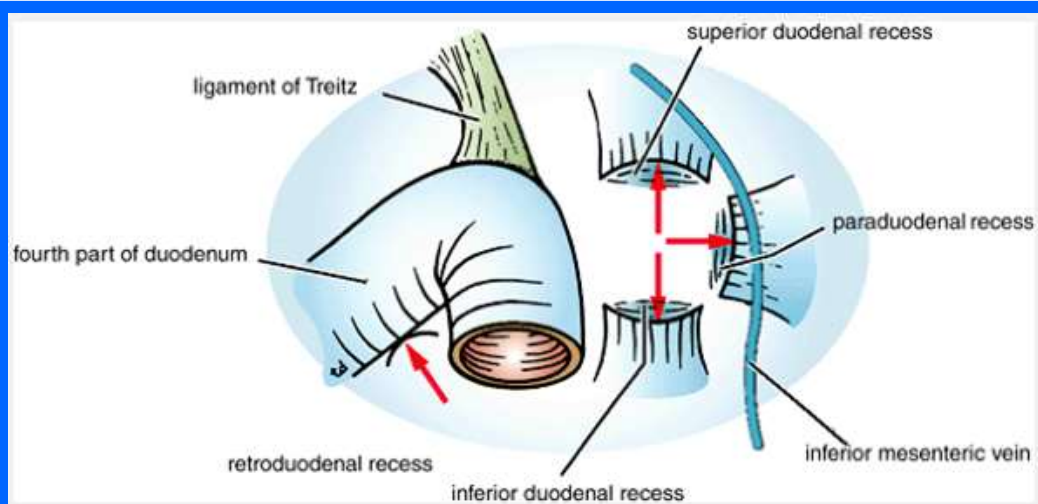
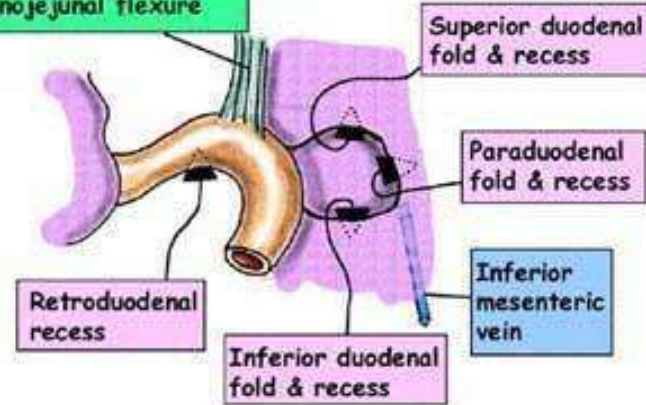


Duodenal Recesses

PERITONEAL RECESSES

There are a number of small recesses, as shown below, that are potential areas for internal herniation of bowel or other structures

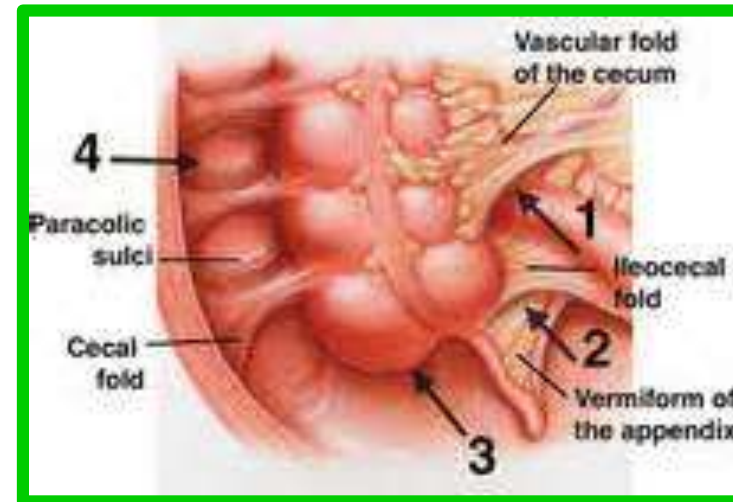
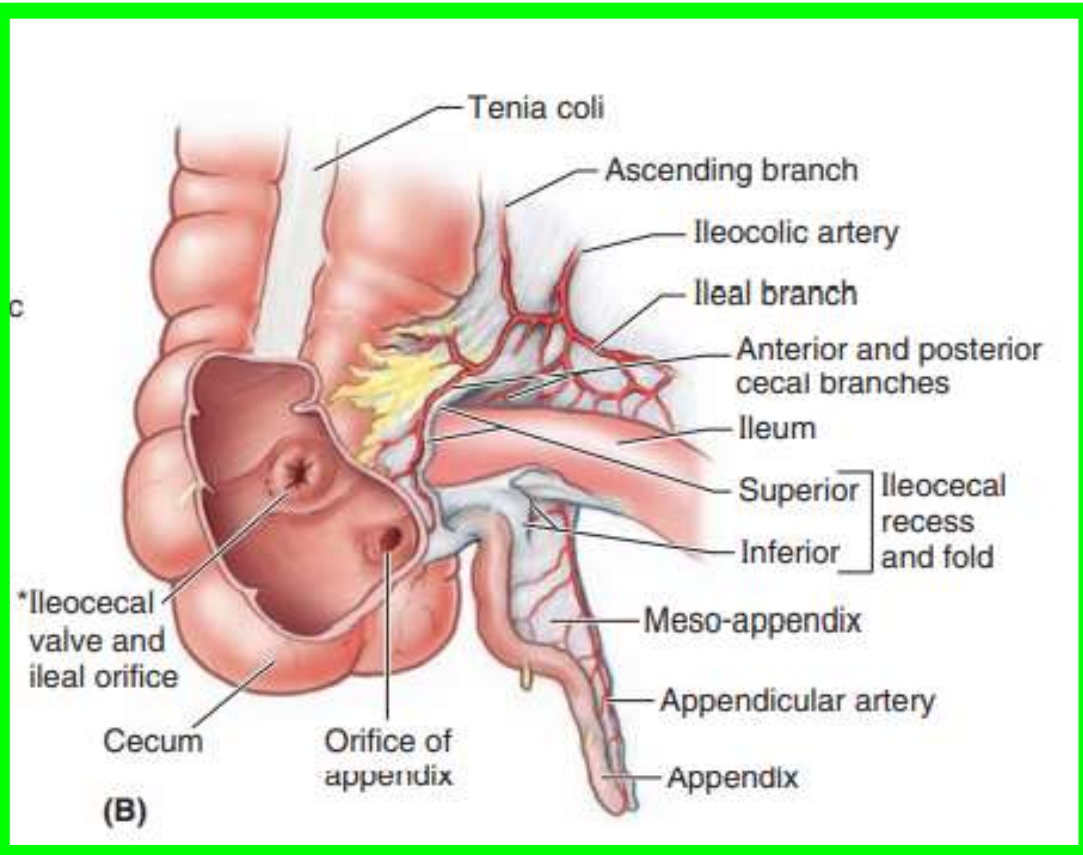
Ligament of Treitz
Thin band of smooth muscle from right crus, passing anterior to aorta/renal vessels but behind pancreas, to blend with outer coat of duodenojejunal flexure



Dr. Aiman Qais Afar
Tuesday 5 April 2022

Peritoneal Pouches, Recesses, Spaces, and Gutters

Cecal Recesses

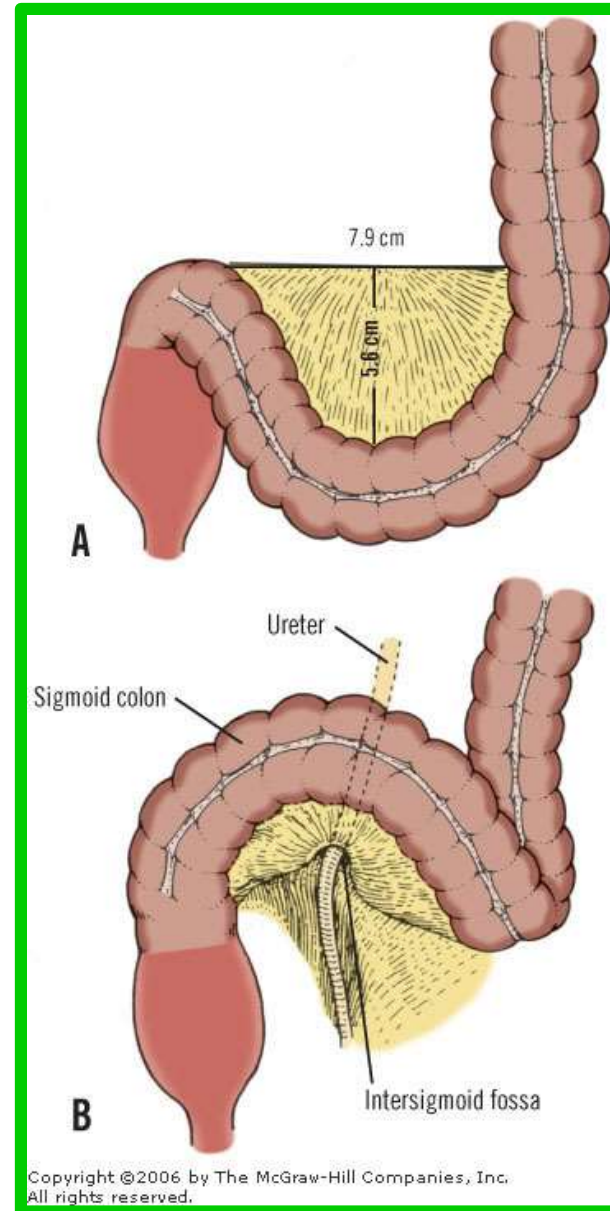
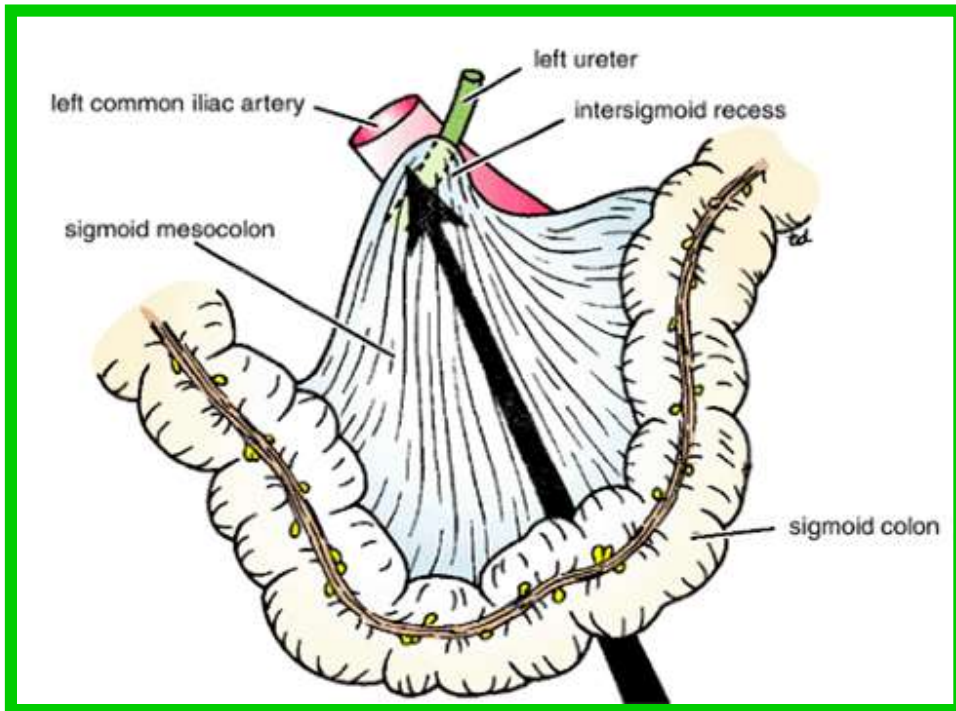


Dr. Aiman Qais Afar

Tuesday 5 April 2022

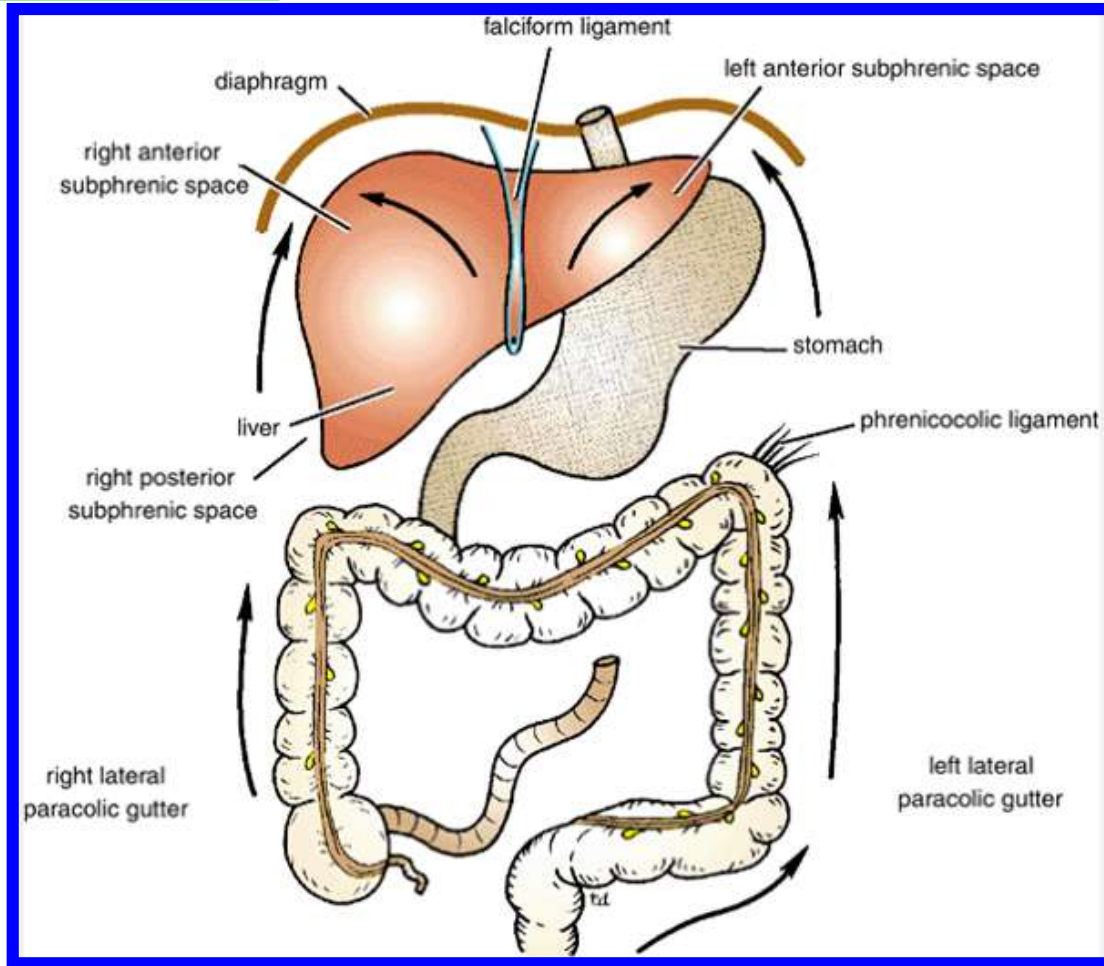
Peritoneal Pouches, Recesses, Spaces, and Gutters

Intersigmoid Recess



Peritoneal Pouches, Recesses, Spaces, and Gutters

Subphrenic Spaces

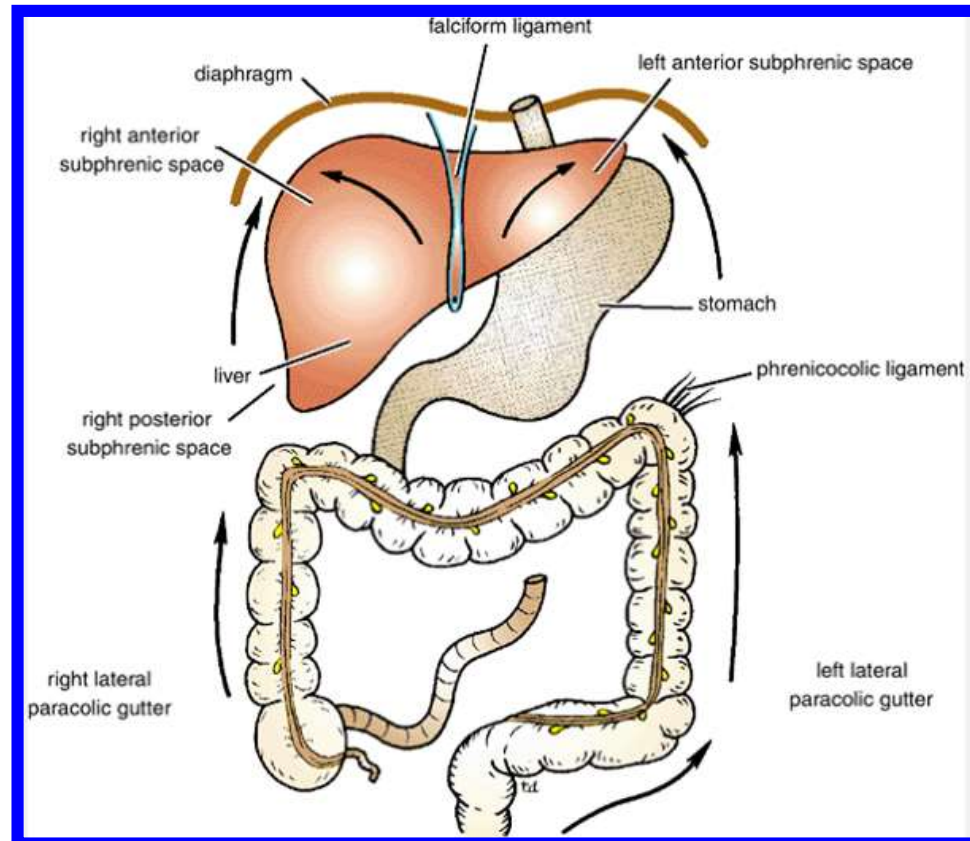


Peritoneal Pouches, Recesses, Spaces, and Gutters

Subphrenic Spaces

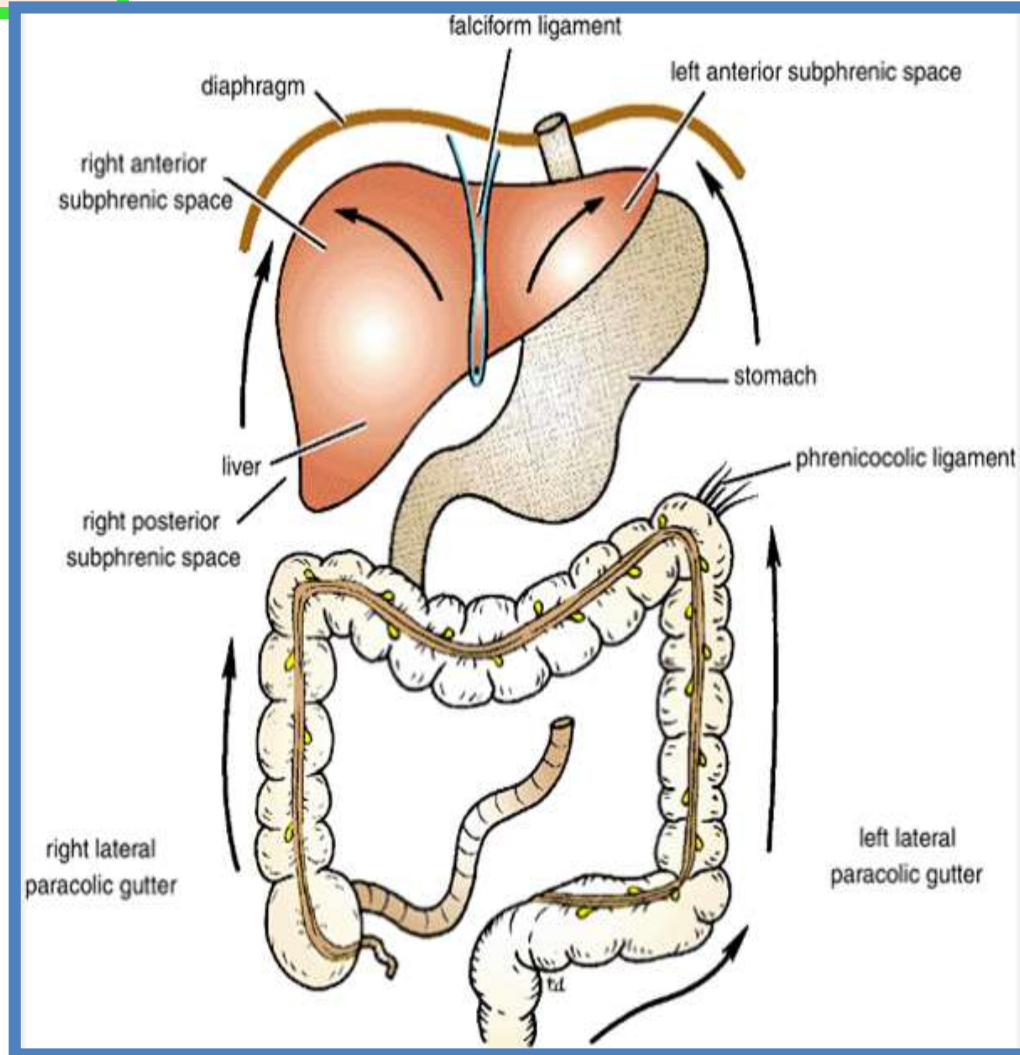
Dr. Aiman Qais Afar

Tuesday 5 April 2022



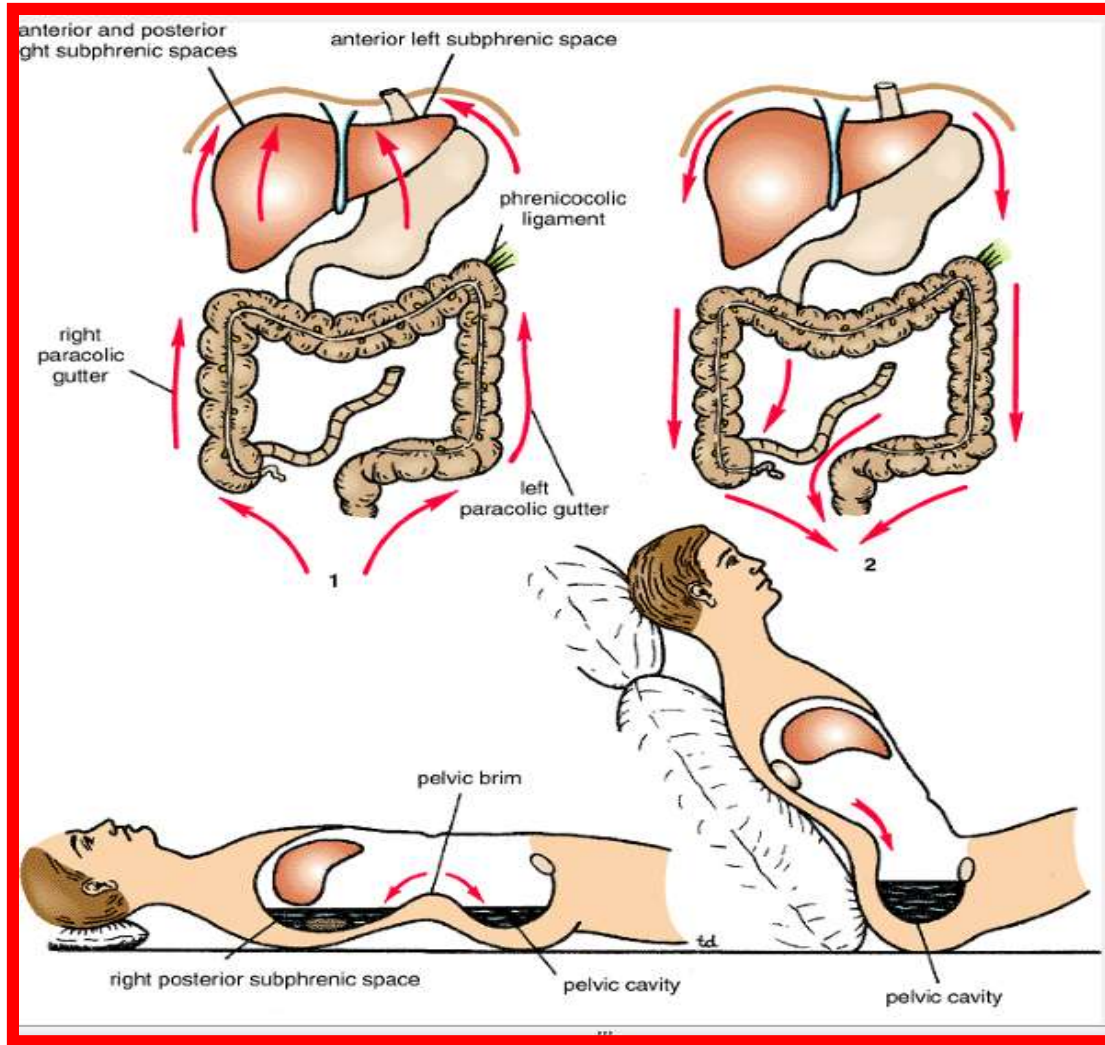
Peritoneal Pouches, Recesses, Spaces, and Gutters

Paracolic Gutters



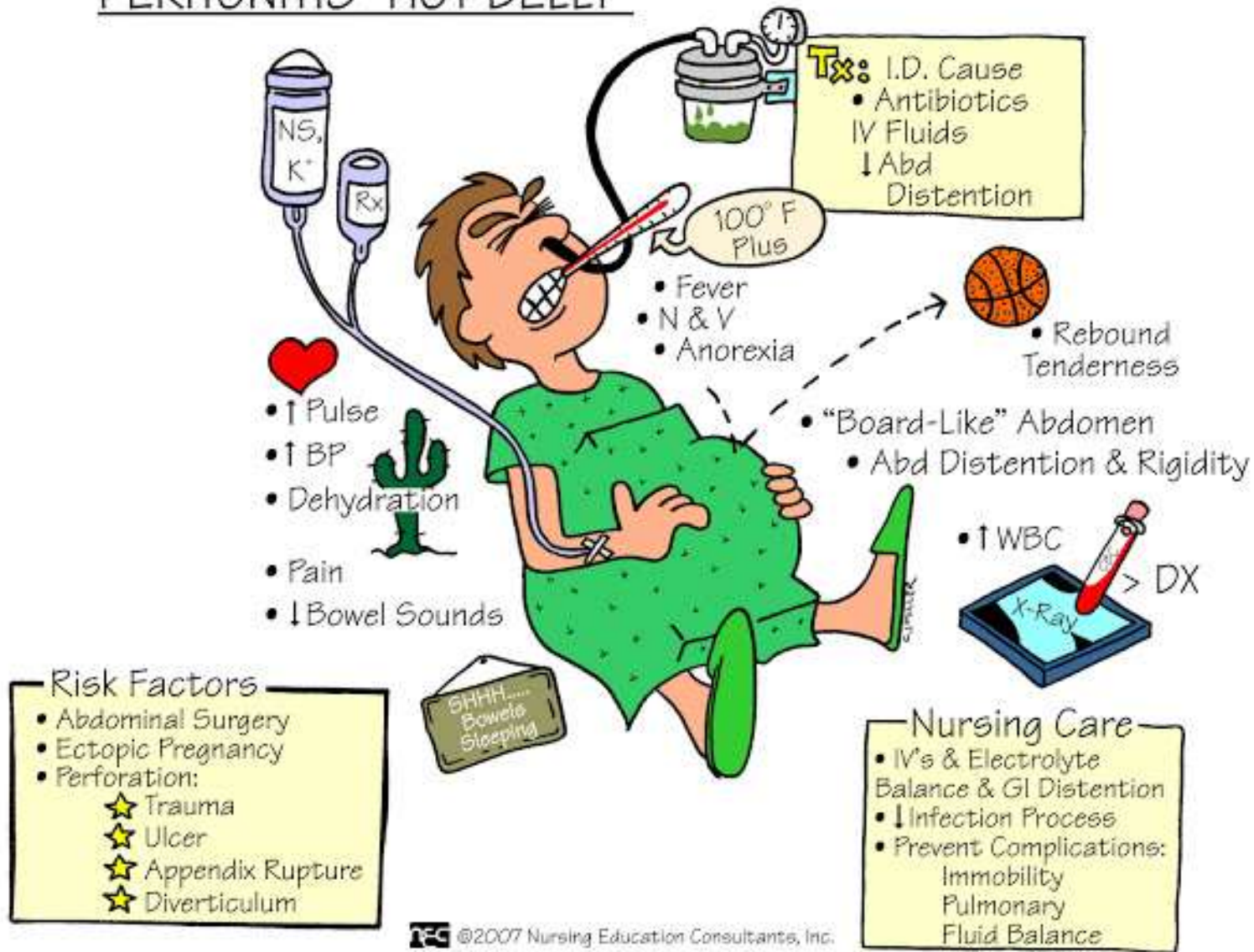
Peritonitis and Ascites ???

Fluid in Omental Bursa ???



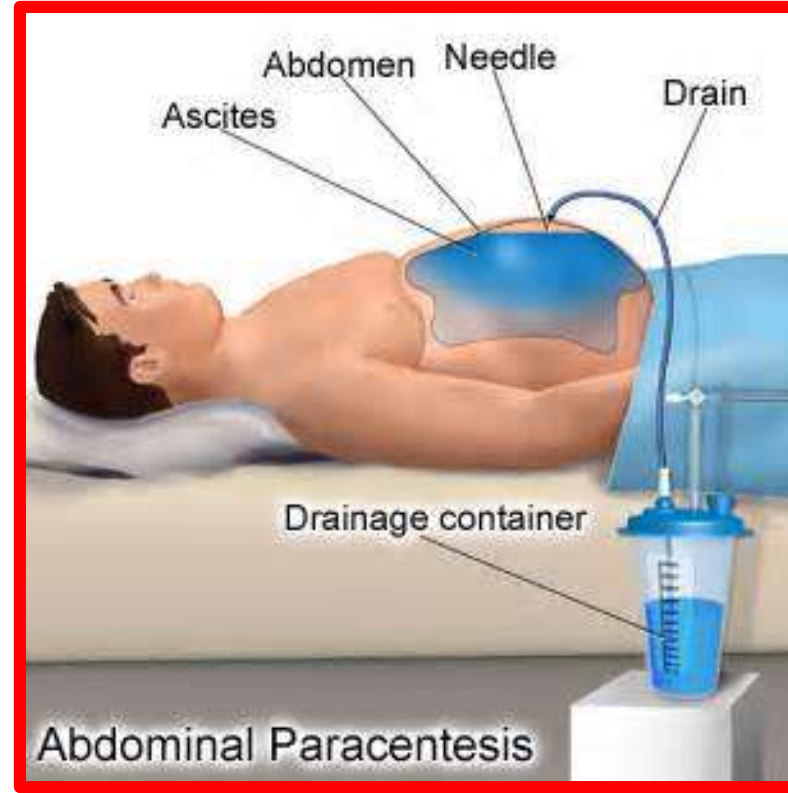
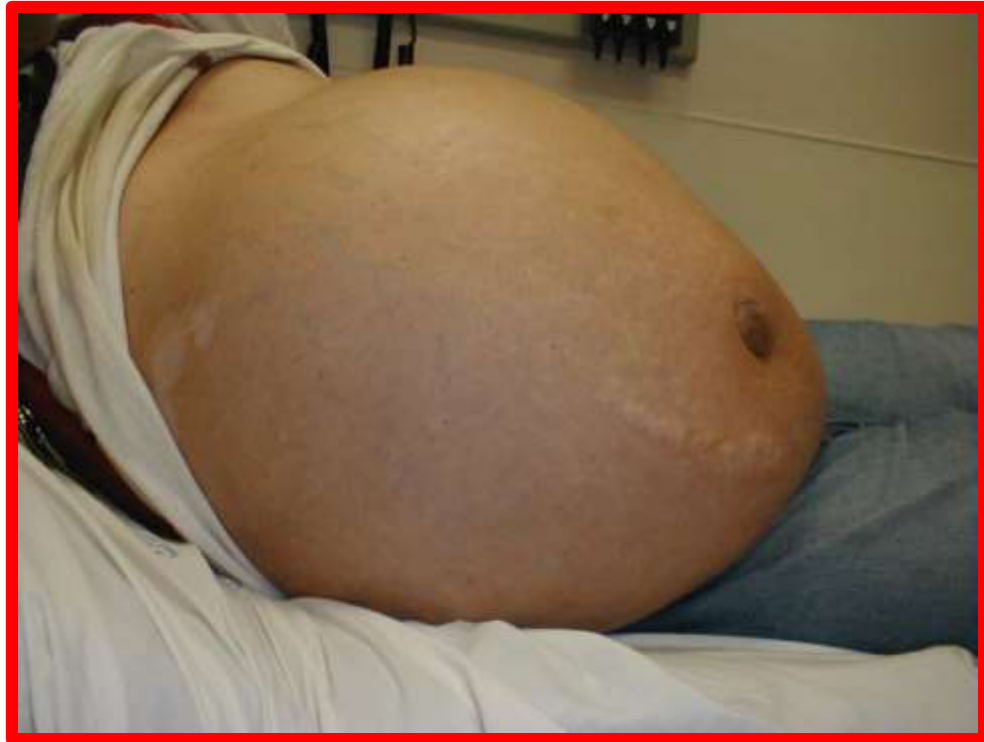Abdominal Paracentesis ???

PERITONITIS "HOT BELLY"



Peritonitis and Ascites ???

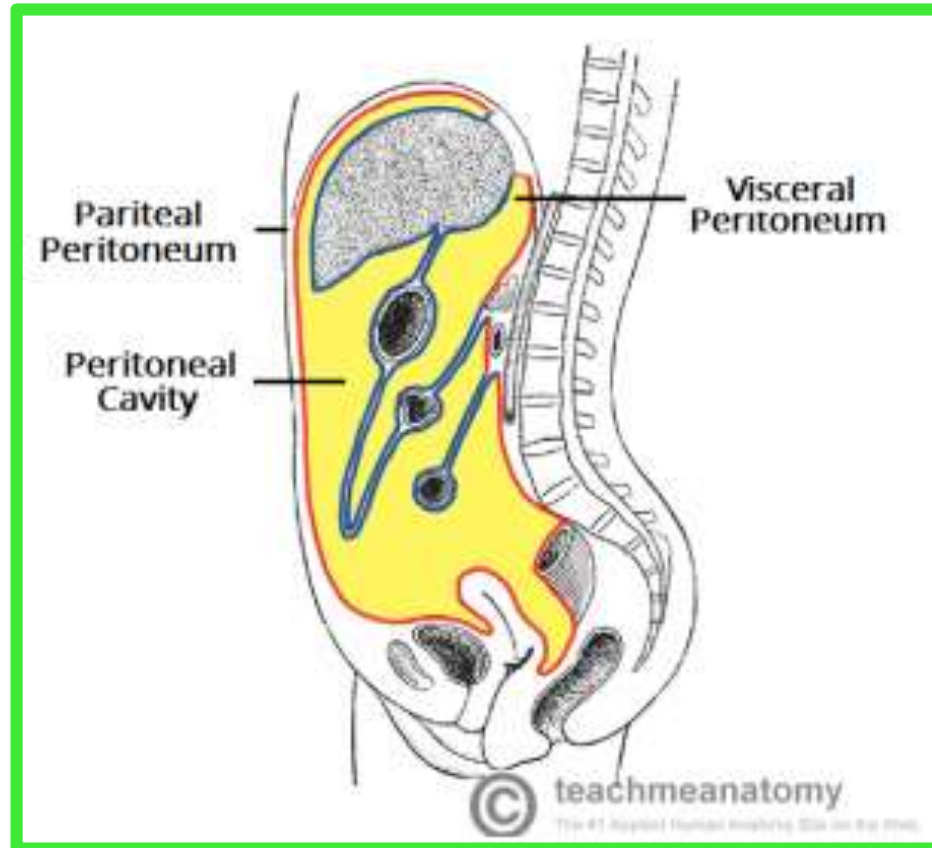
Abdominal Paracentesis ???



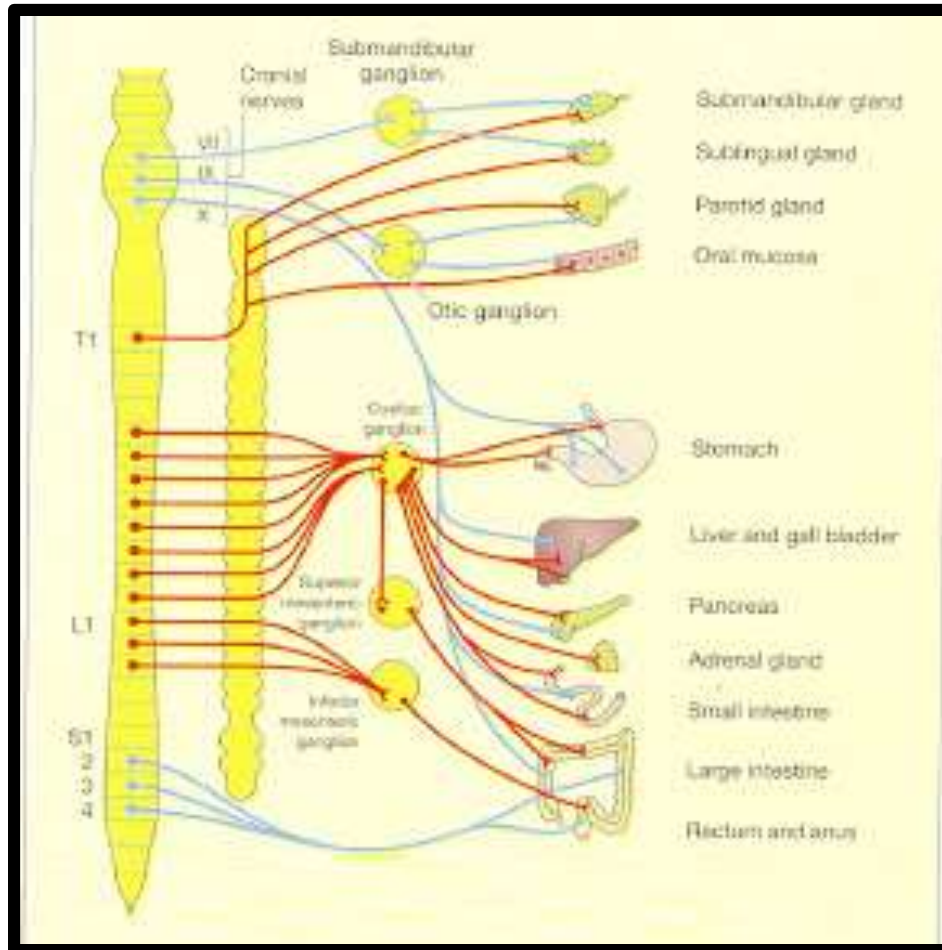
Nerve Supply of the Peritoneum

Dr. Aiman Qais Afar
Tuesday 5 April 2022

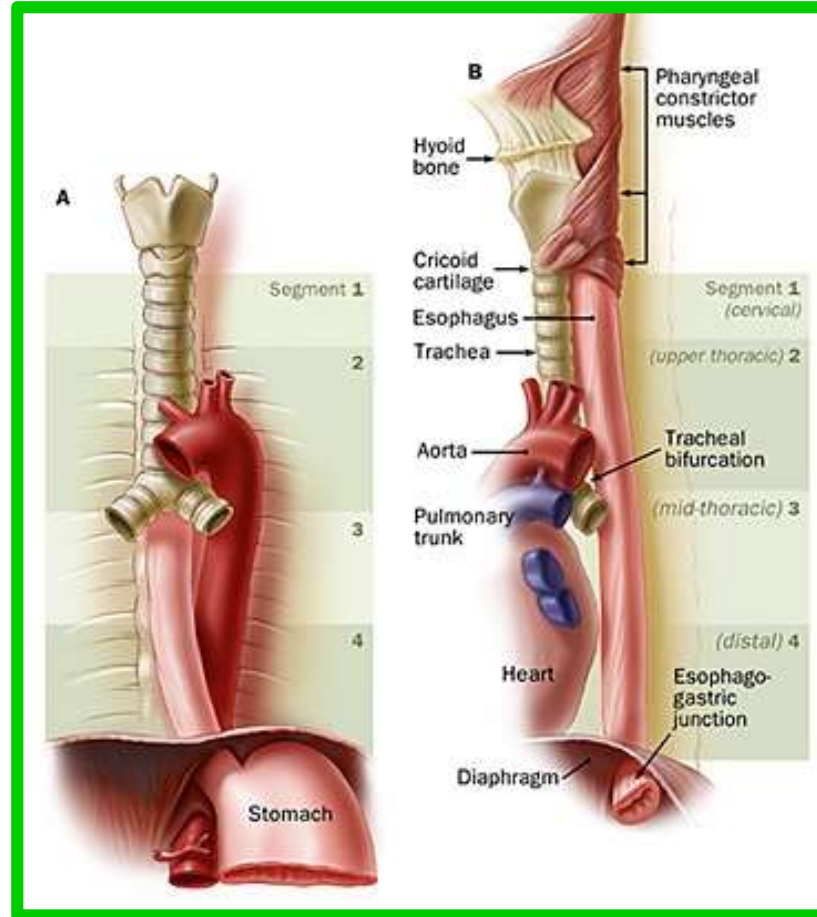
52



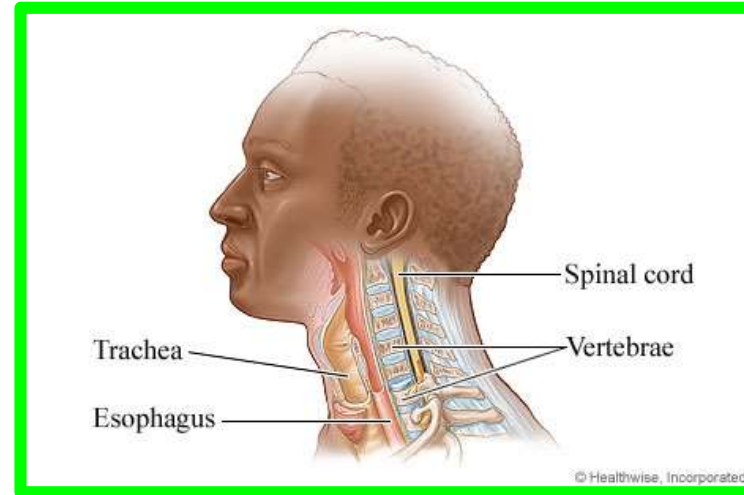
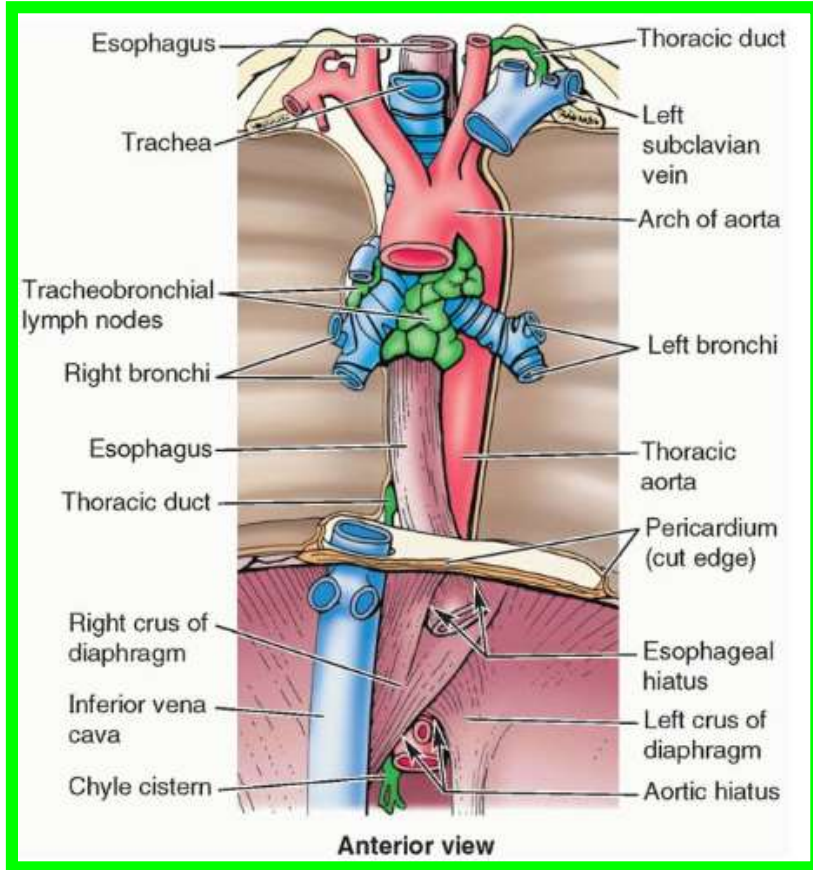
Nerve Supply of the Peritoneum



The Esophagus

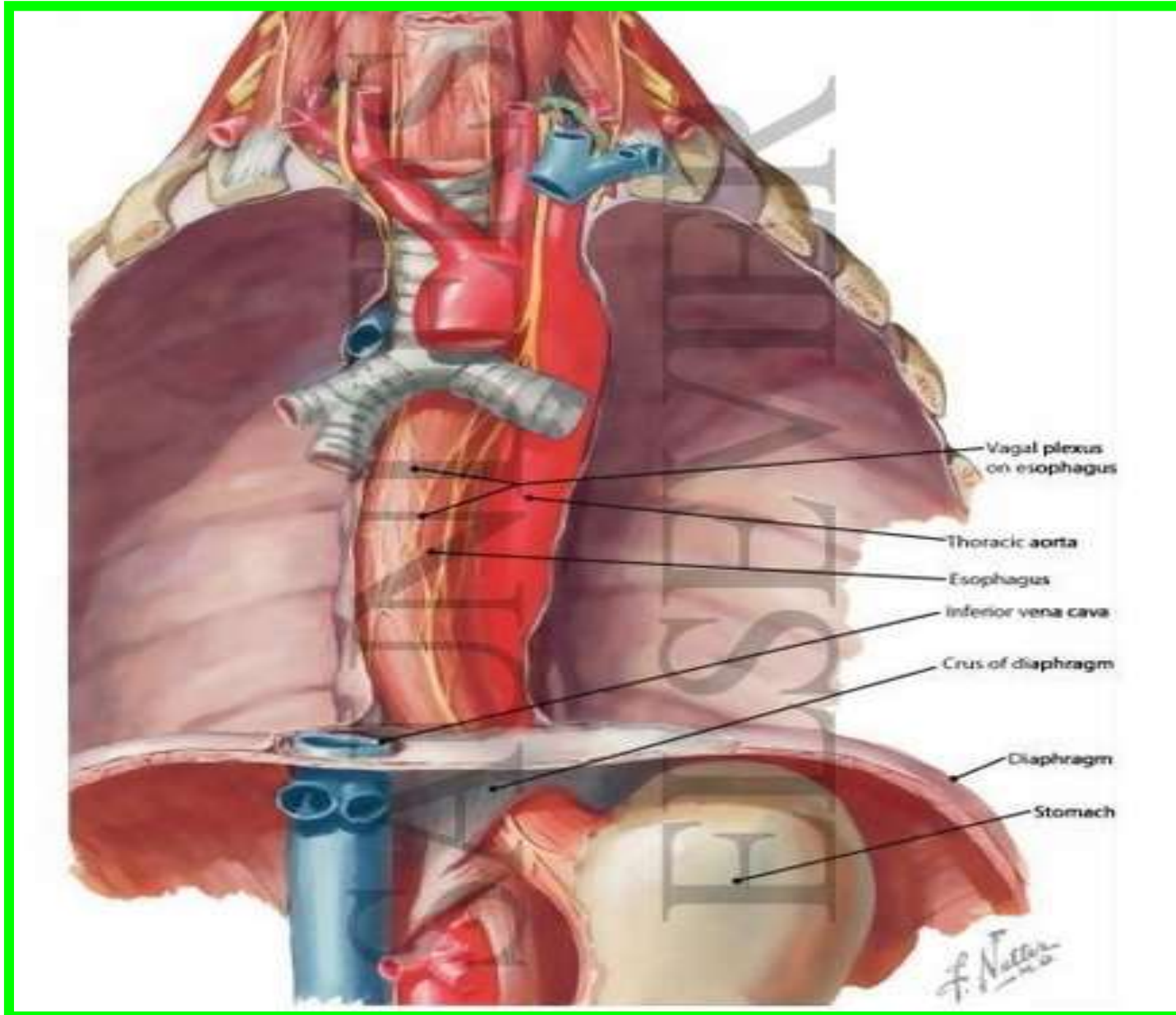


The Esophagus

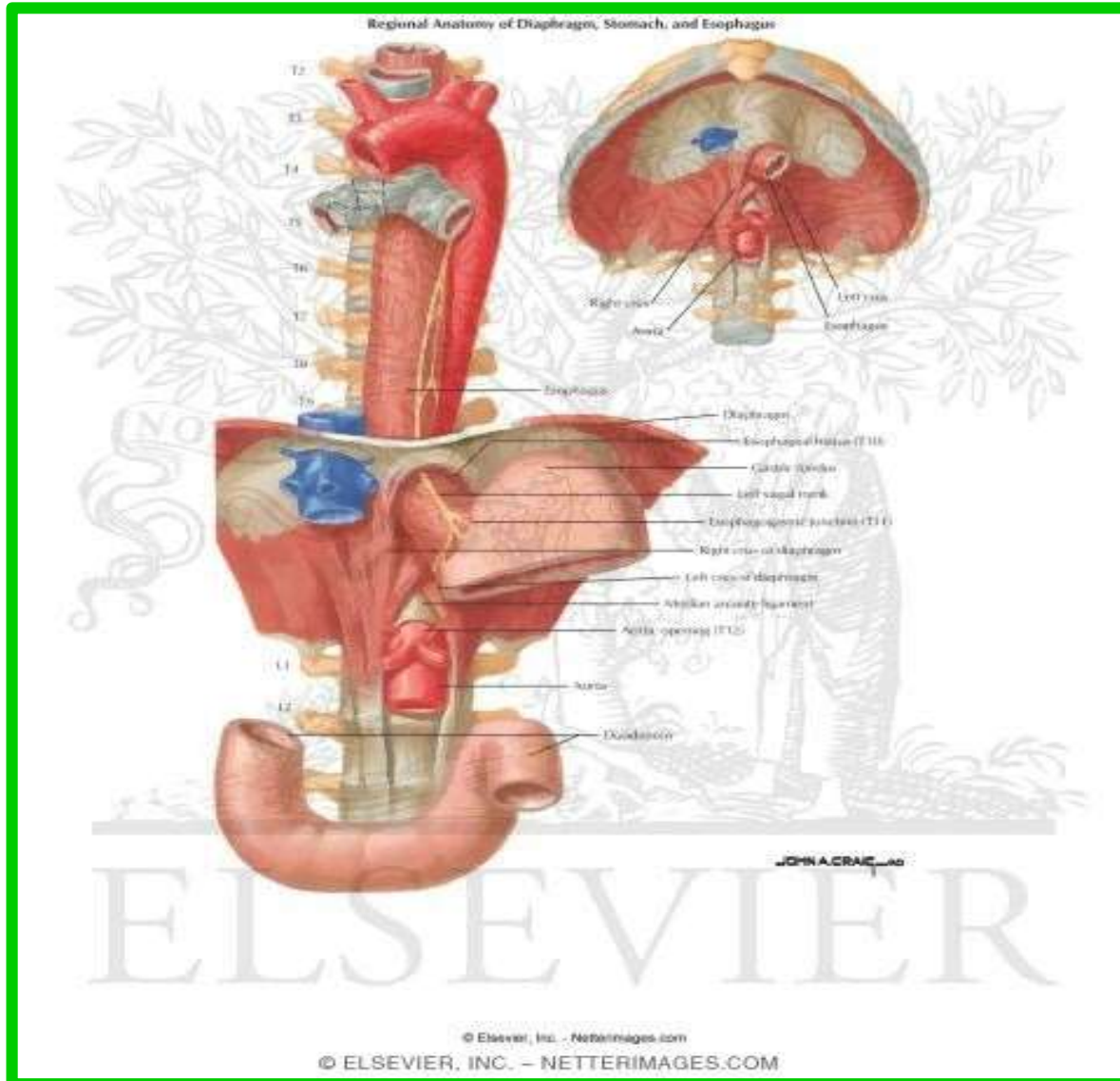


The Esophagus

Dr. Aiman Qais Maathidy
Tuesday 5 April 2022

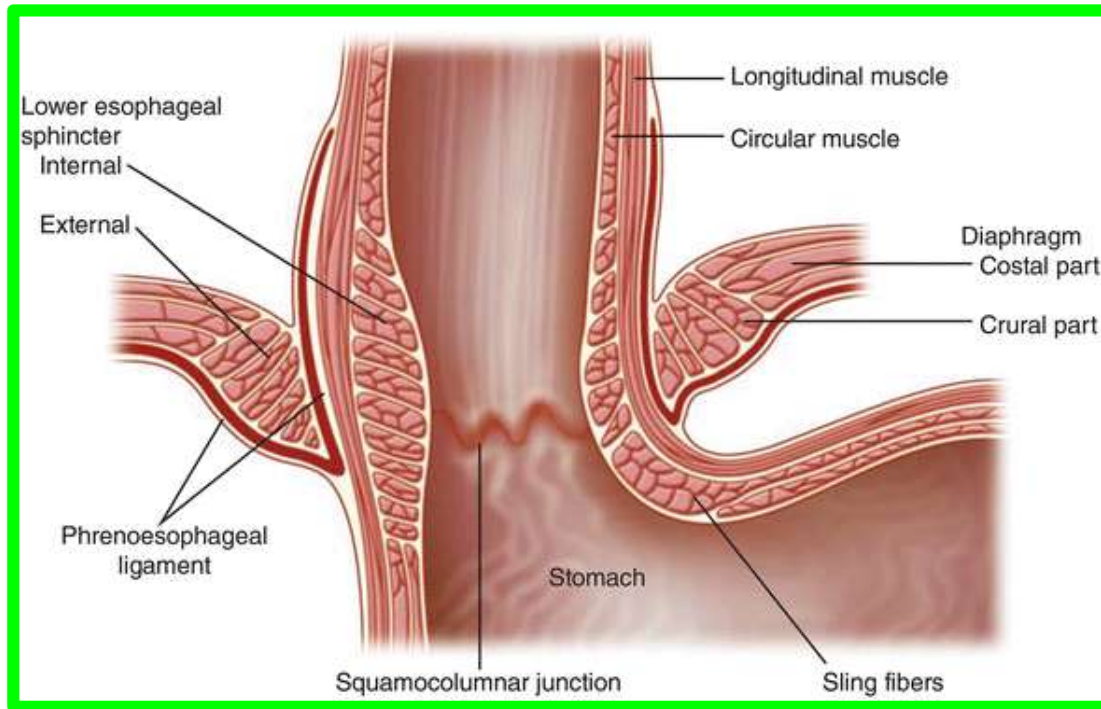


The Esophagus

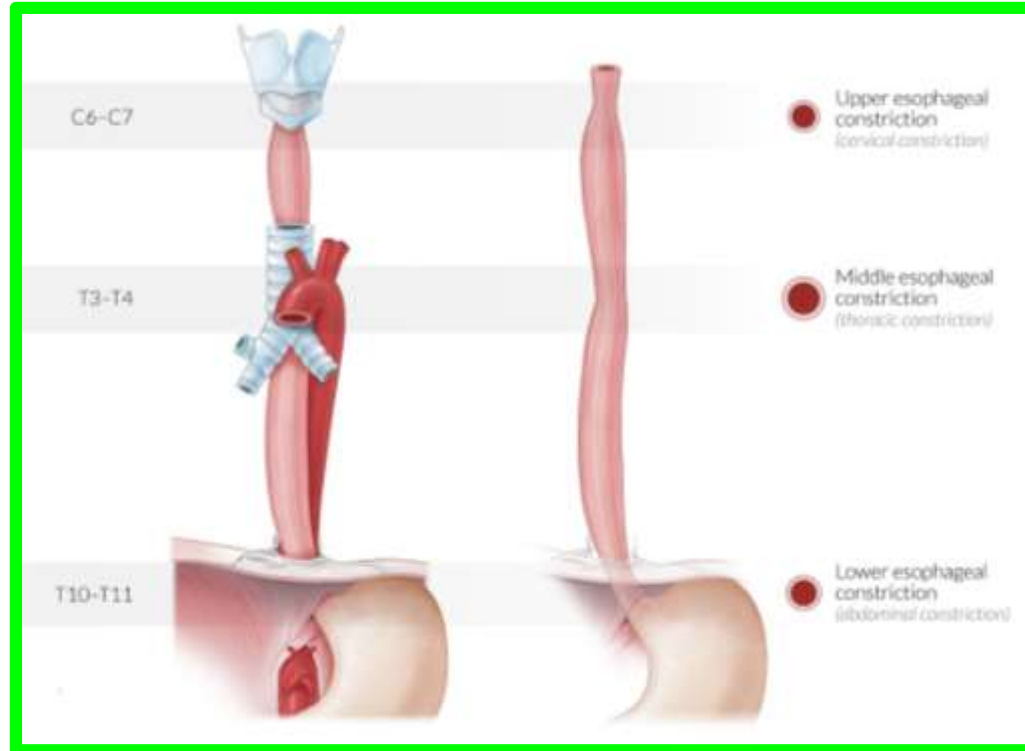


The Esophagus

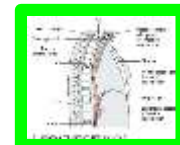Dr. Aiman Qais Maathidy
Tuesday 5 April 2022



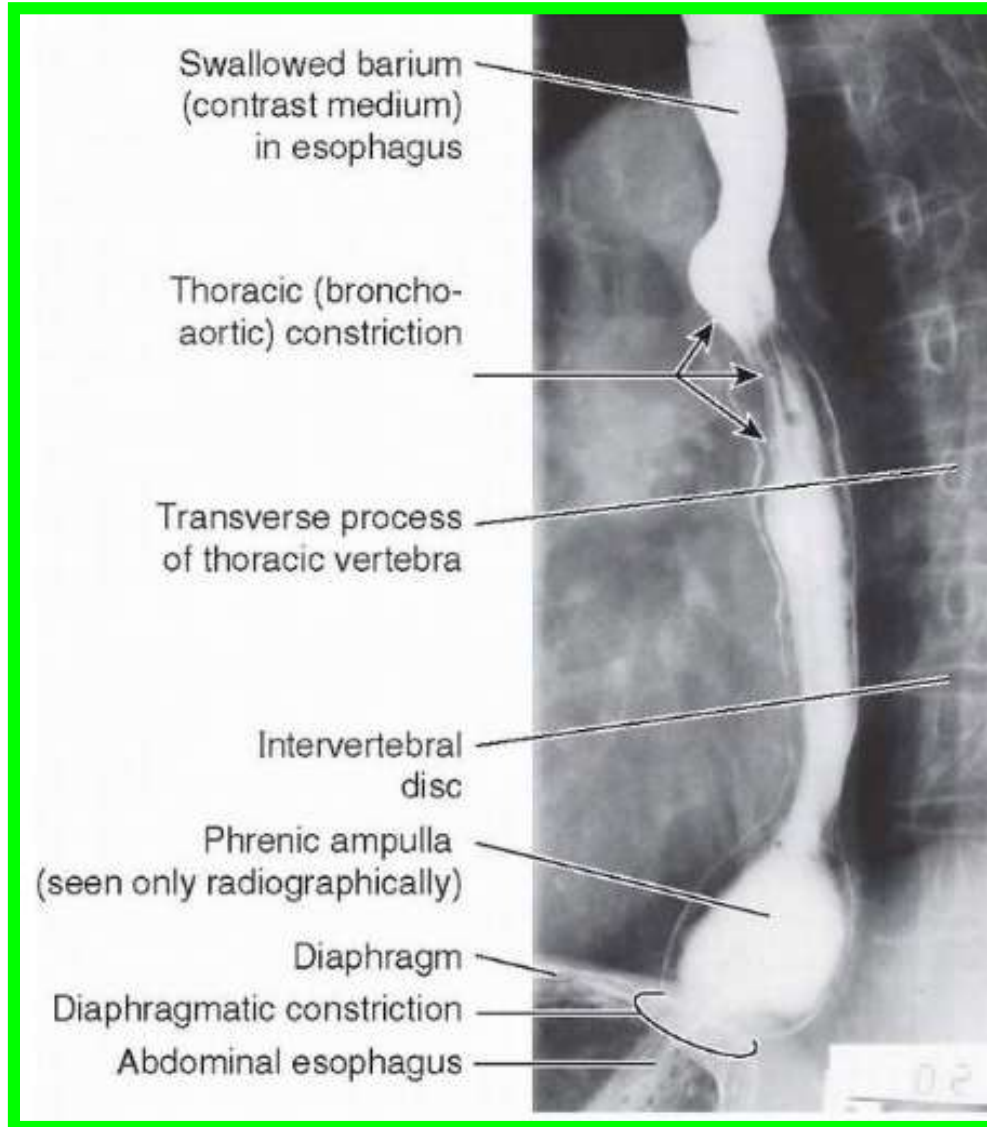
The Esophagus



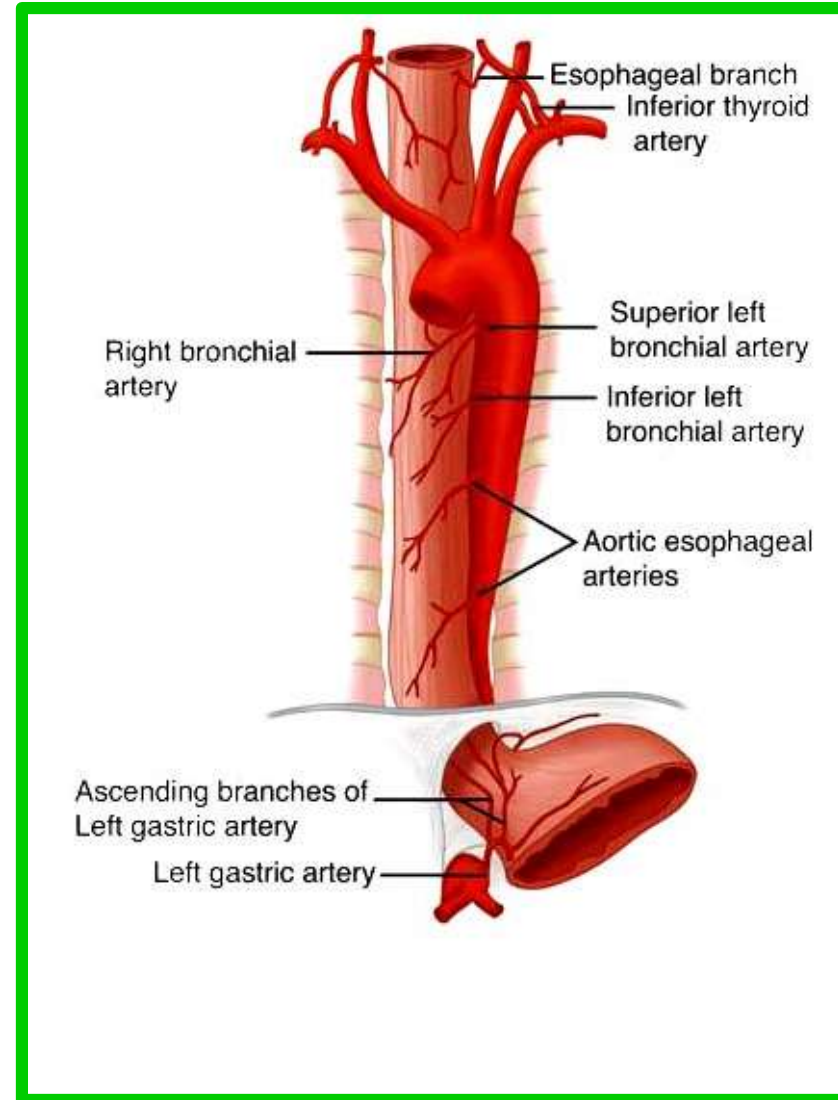
Dr. Aiman Qais Maathidy



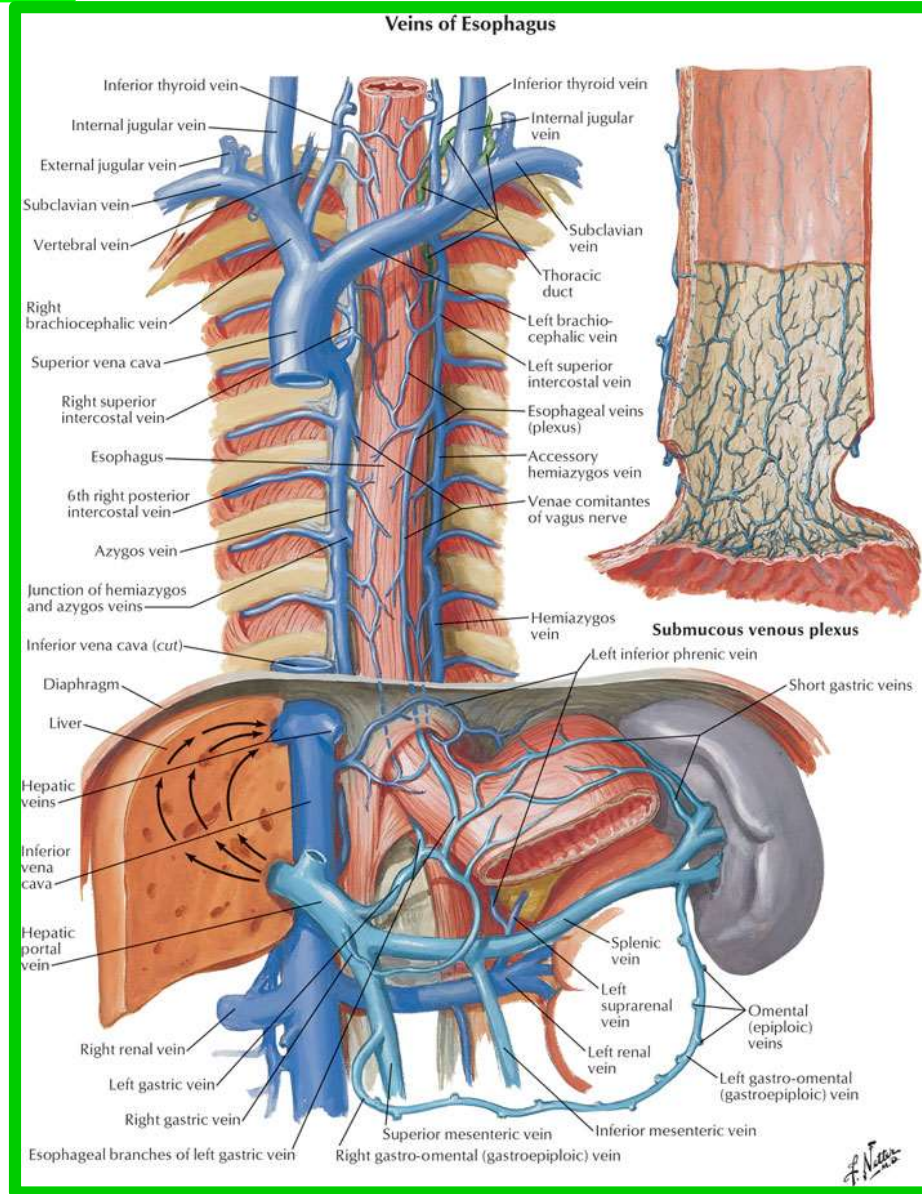
The Esophagus



The Esophagus

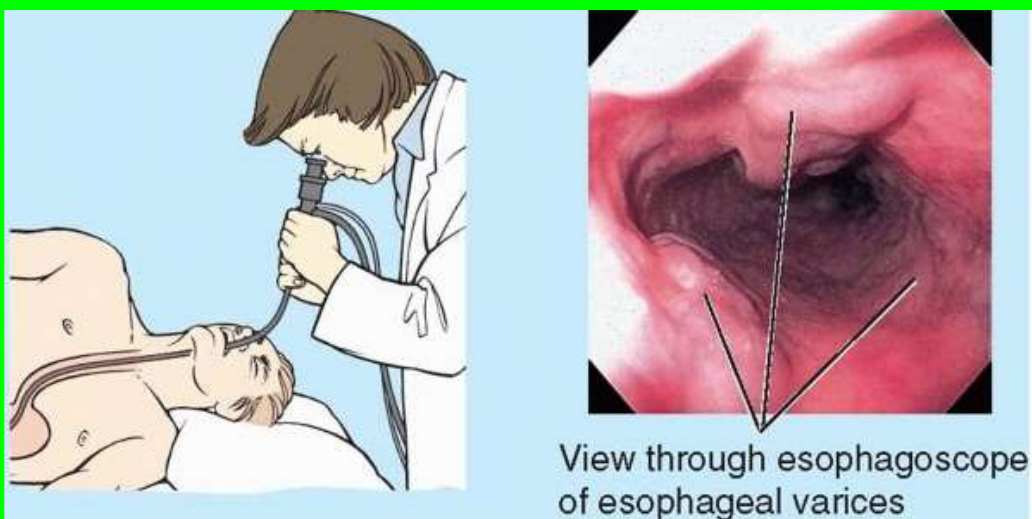


The Esophagus



Because the submucosal veins of the inferior esophagus drain to both **the portal and systemic venous systems**, they constitute a **portosystemic anastomosis**. In portal hypertension (**an abnormally increased blood pressure in the portal venous system**), blood is unable to pass through the liver via the hepatic portal vein, causing a reversal of flow in the esophageal tributary., **forming esophageal varices**

These distended collateral channels may rupture and cause severe hemorrhage that is life-threatening and difficult to control surgically. **Esophageal varices** commonly develop in persons who have developed **alcoholic cirrhosis (fibrous scarring) of the liver**

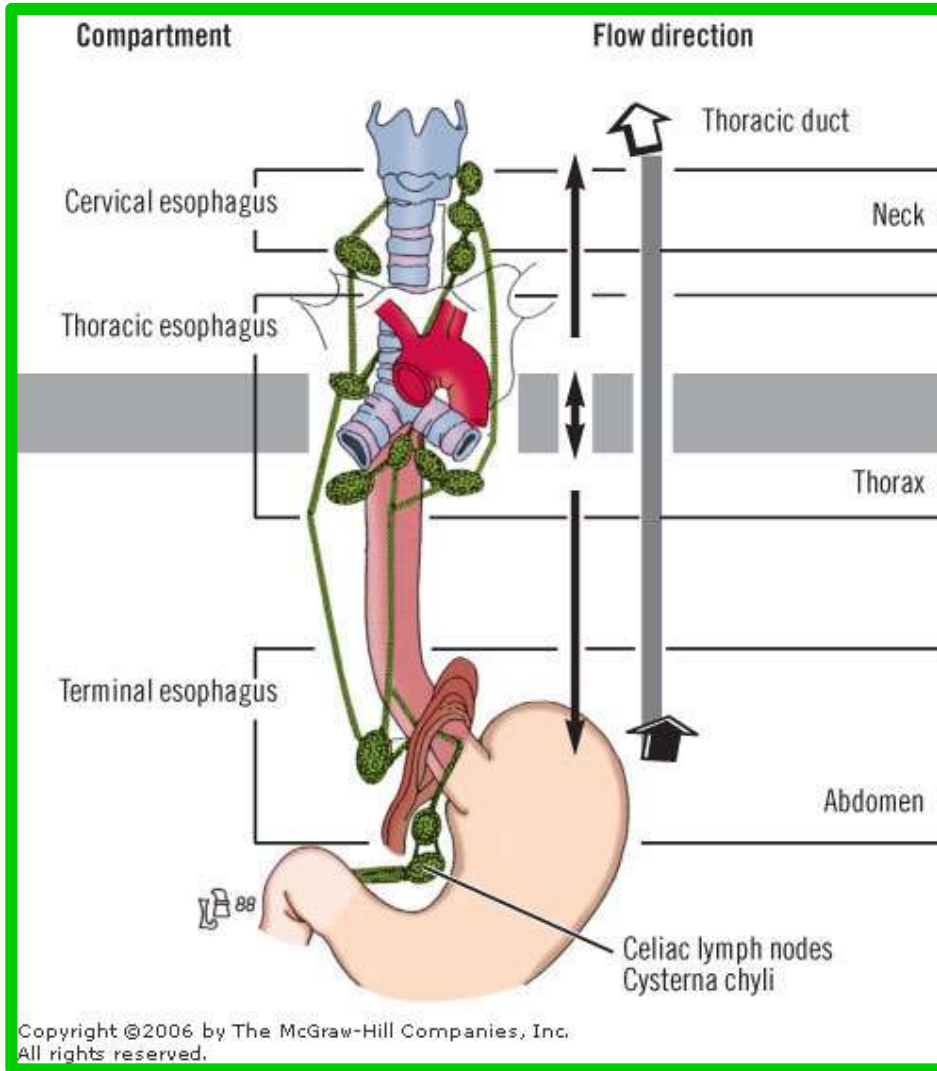


View through esophagoscope of esophageal varices

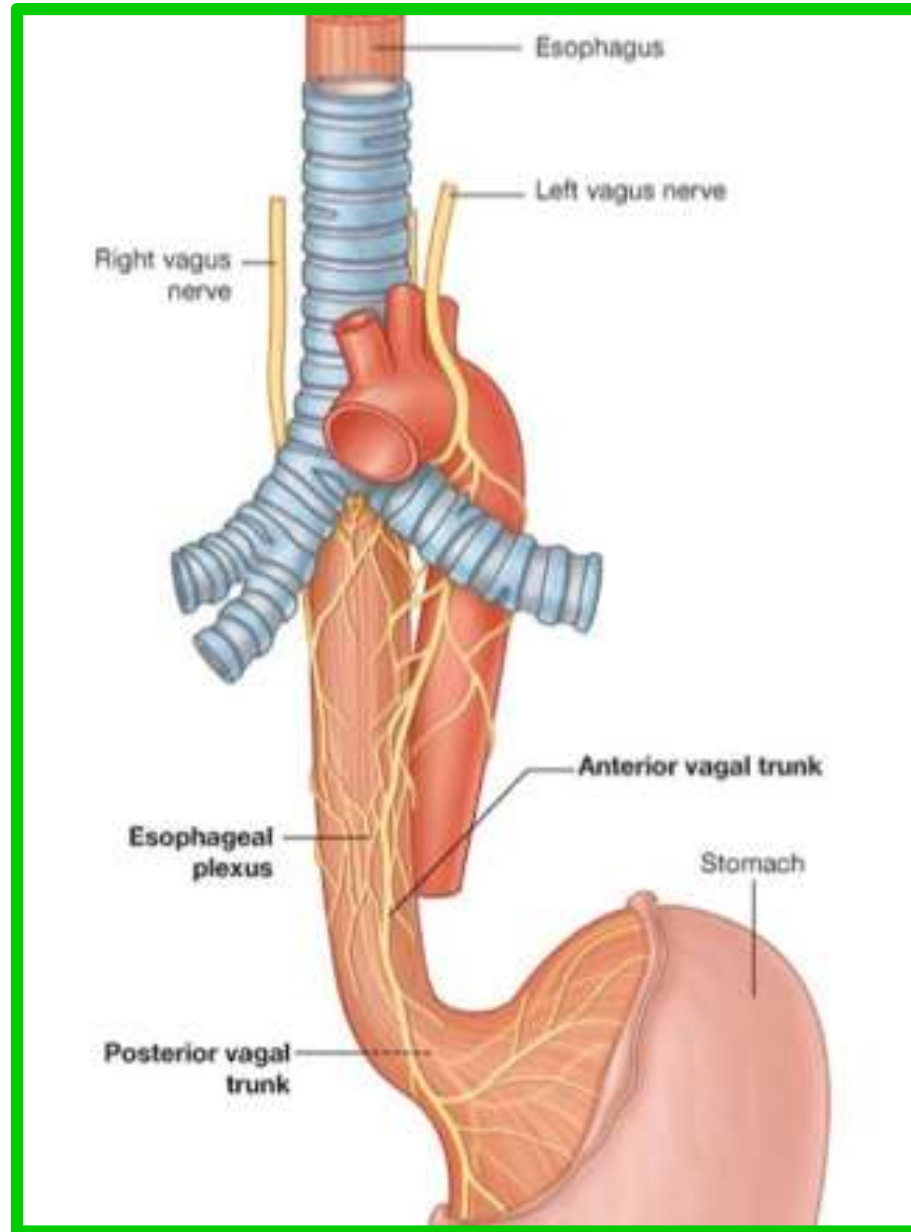
Esophageal Varices

Dr. Aiman Qais Maathidy
Tuesday 5 April 2022

The Esophagus

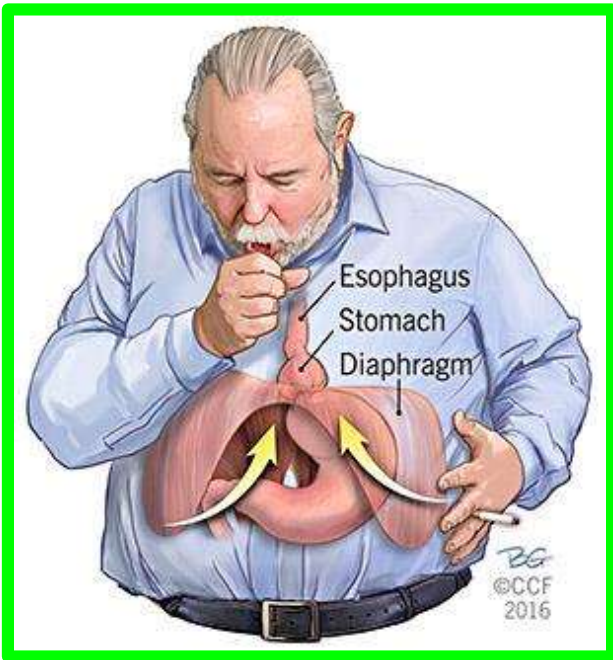


The Esophagus

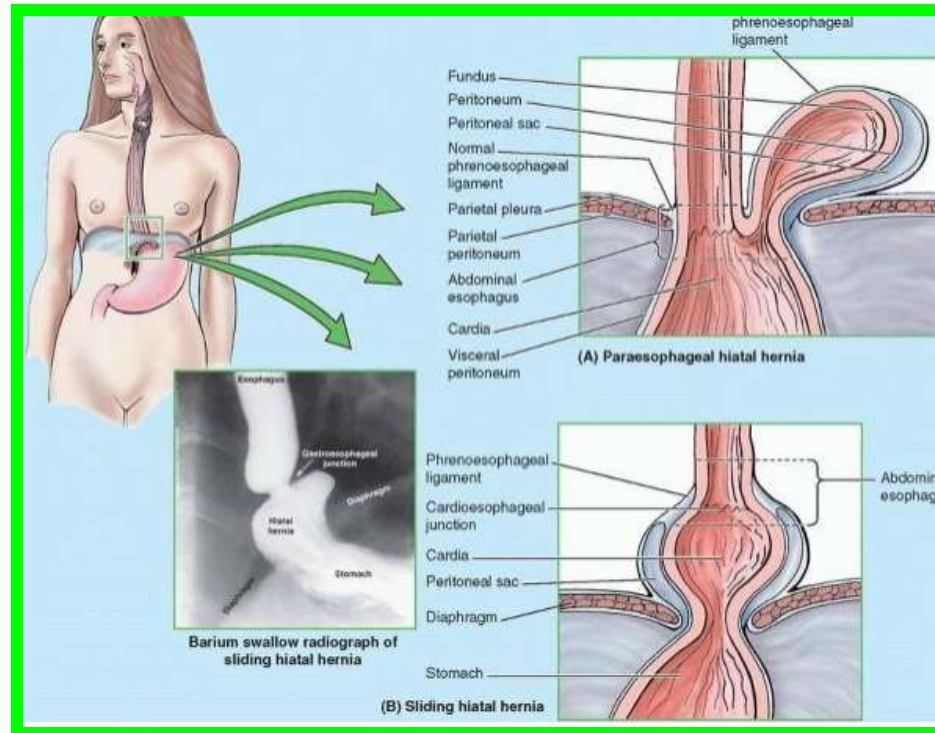


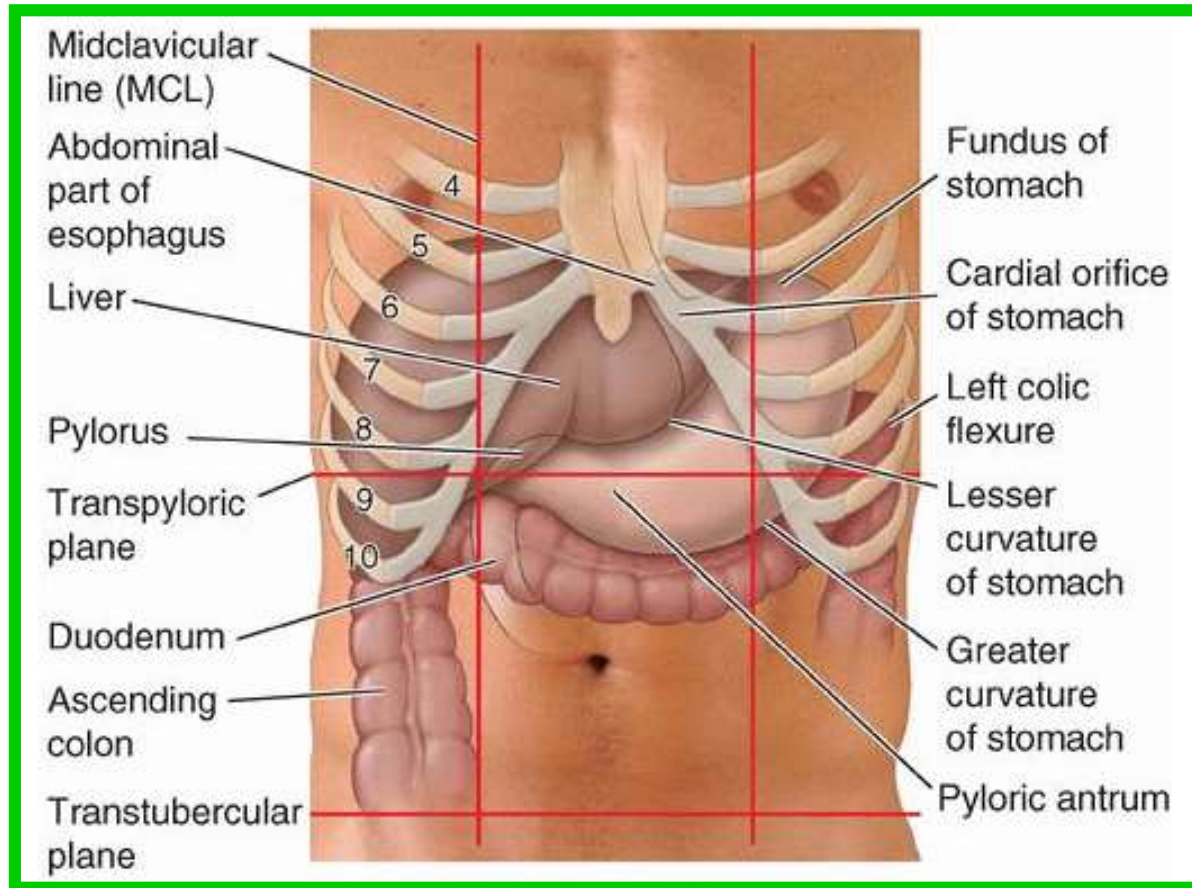
A hiatal (hiatus) hernia is a protrusion of part of the stomach into the mediastinum through the esophageal hiatus of the diaphragm. The hernias occur most often in people after middle age, possibly because of **weakening of the muscular part of the diaphragm** and **widening of the esophageal hiatus**.

the two main types are: **paraesophageal hiatal hernia** and **sliding hiatal hernia**

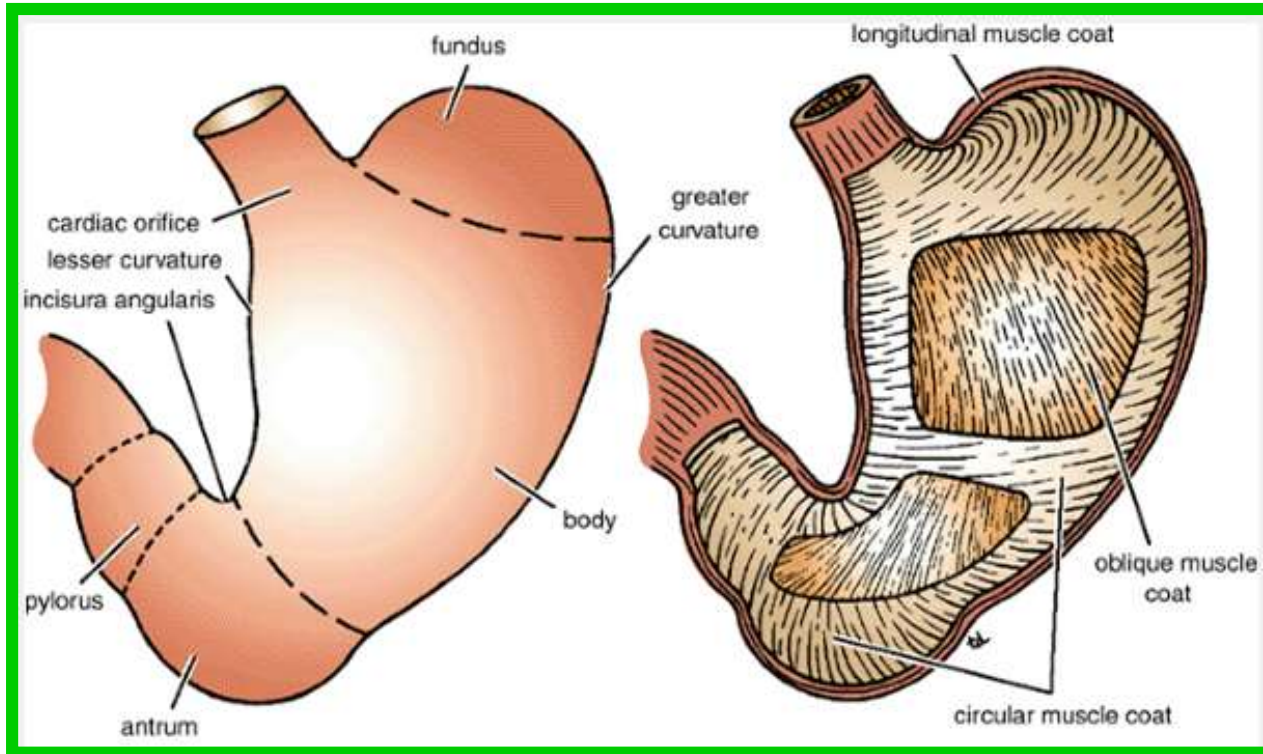


Dr. Aiman Qais Maathidy
Tuesday 5 April 2022

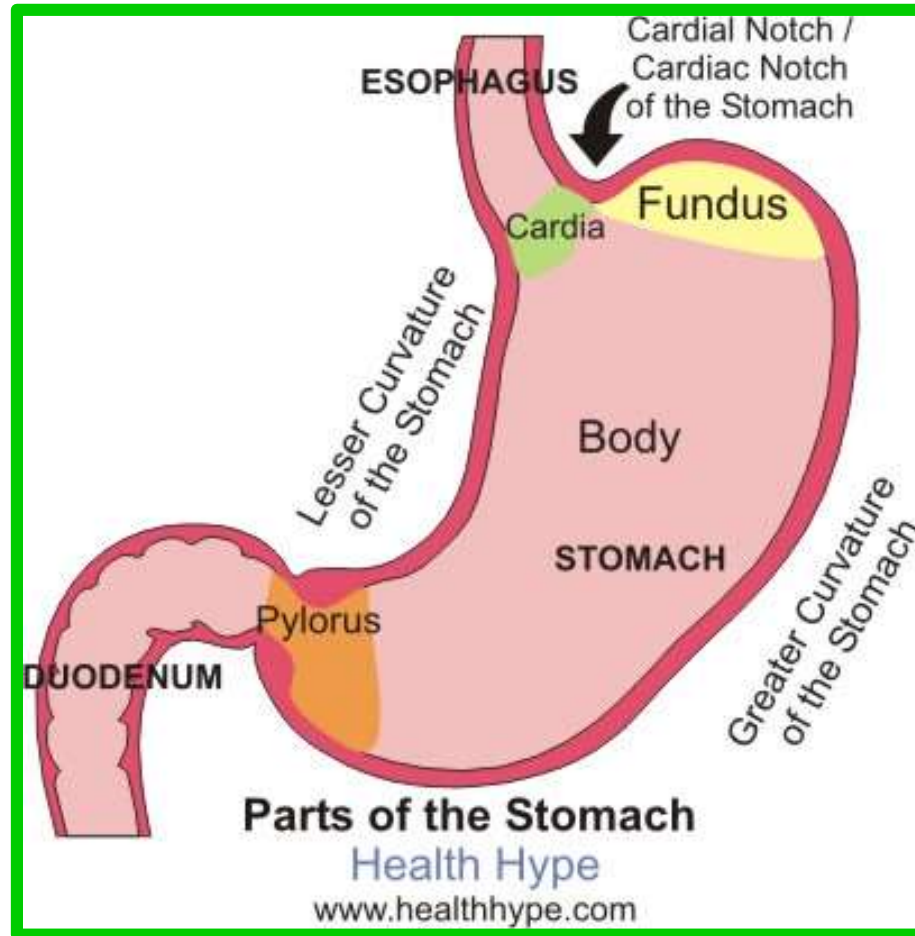




Stomach



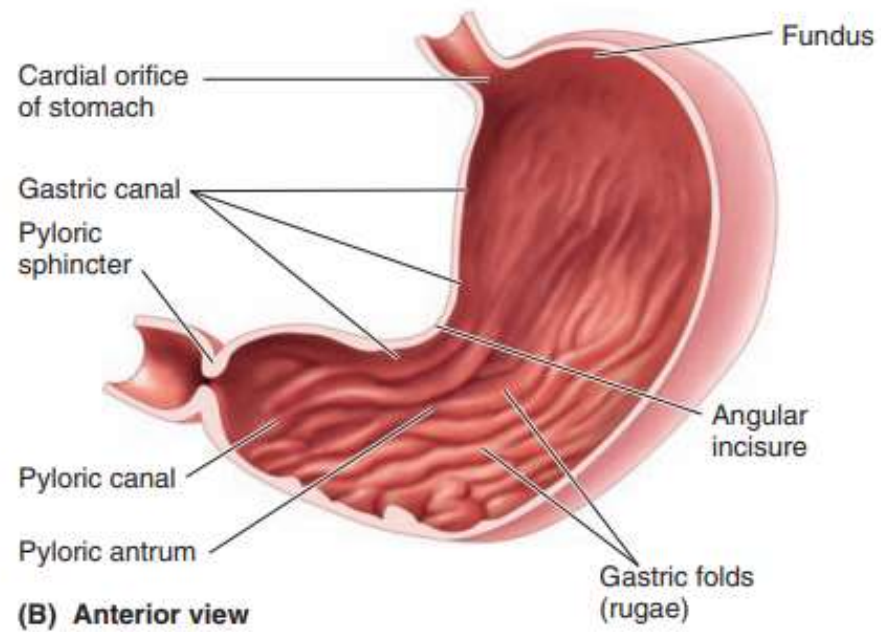
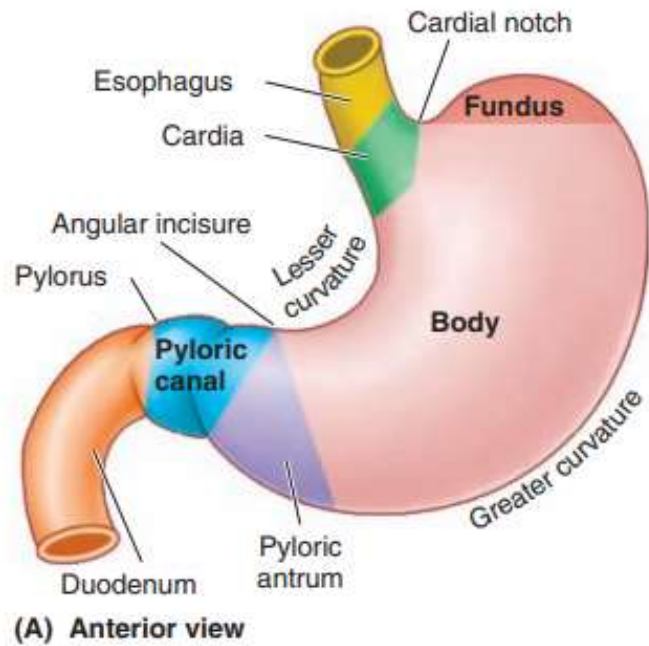
Stomach



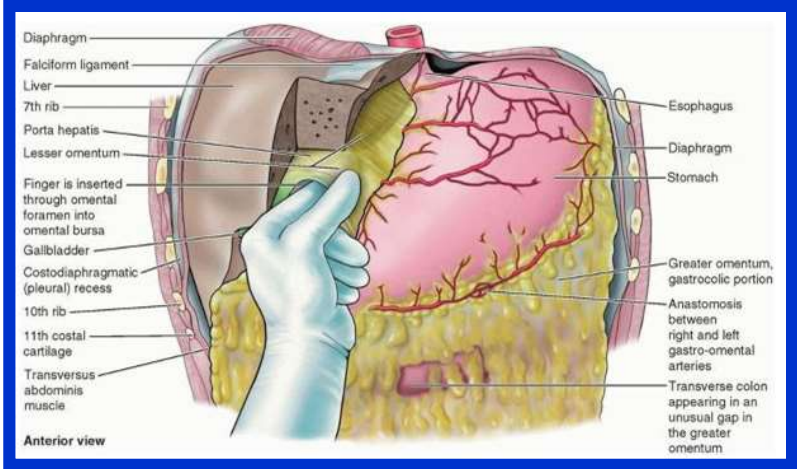
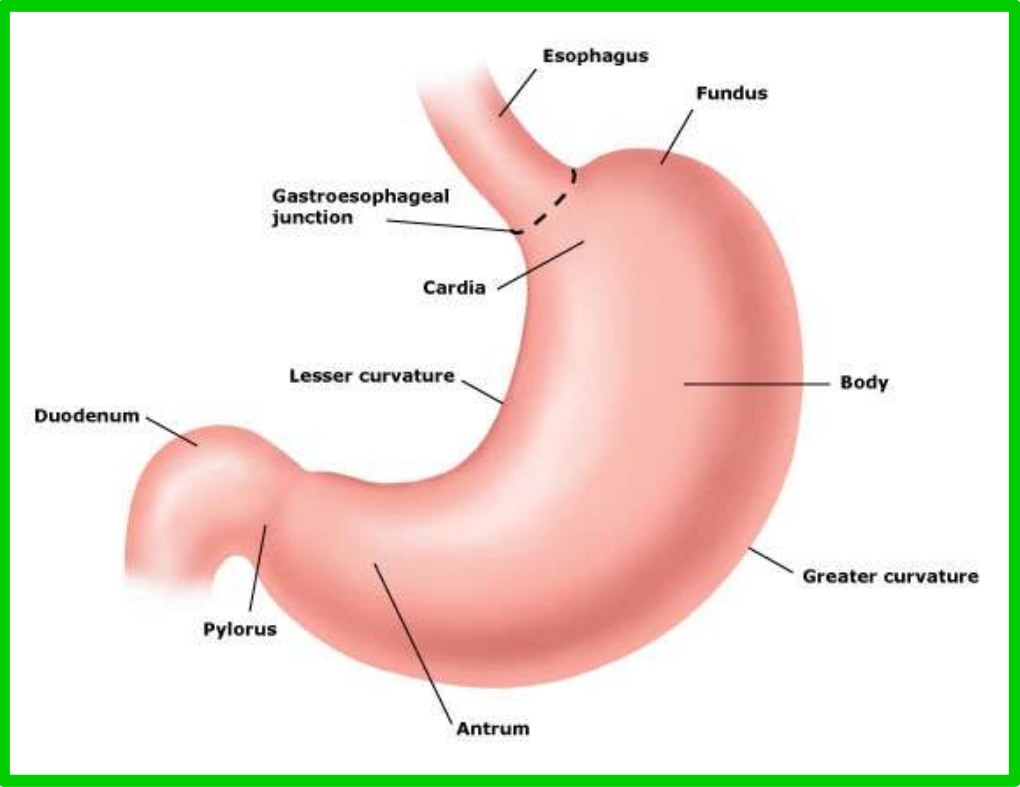
Stomach

70

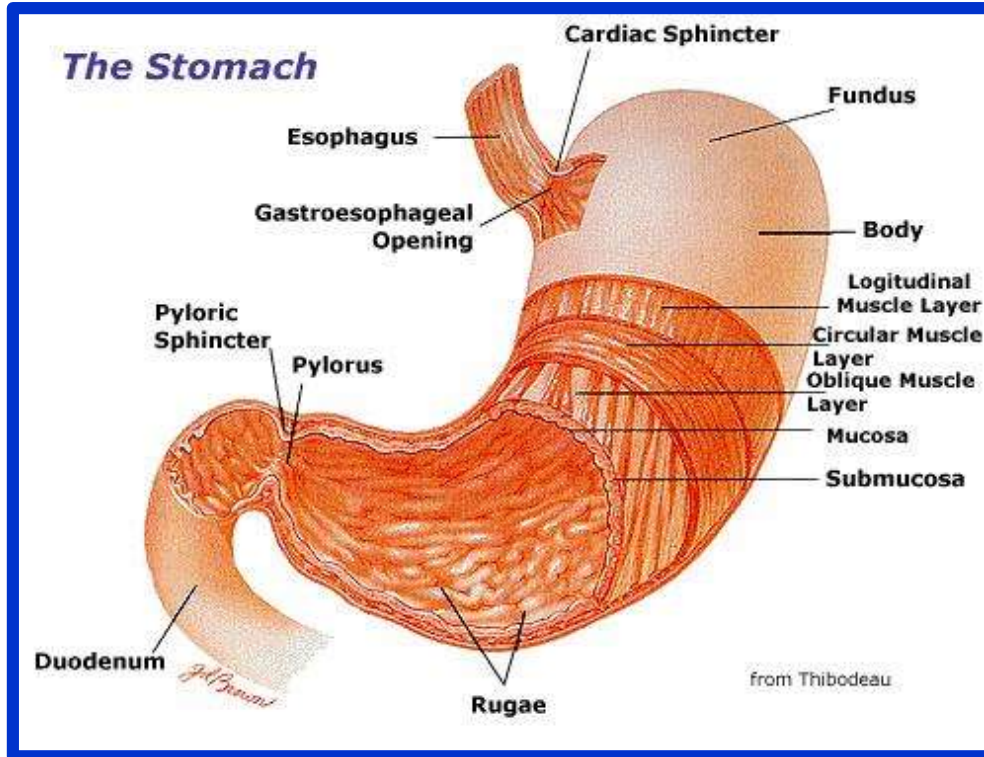
Dr. Aiman Qais Maathidy
Tuesday 5 April 2022



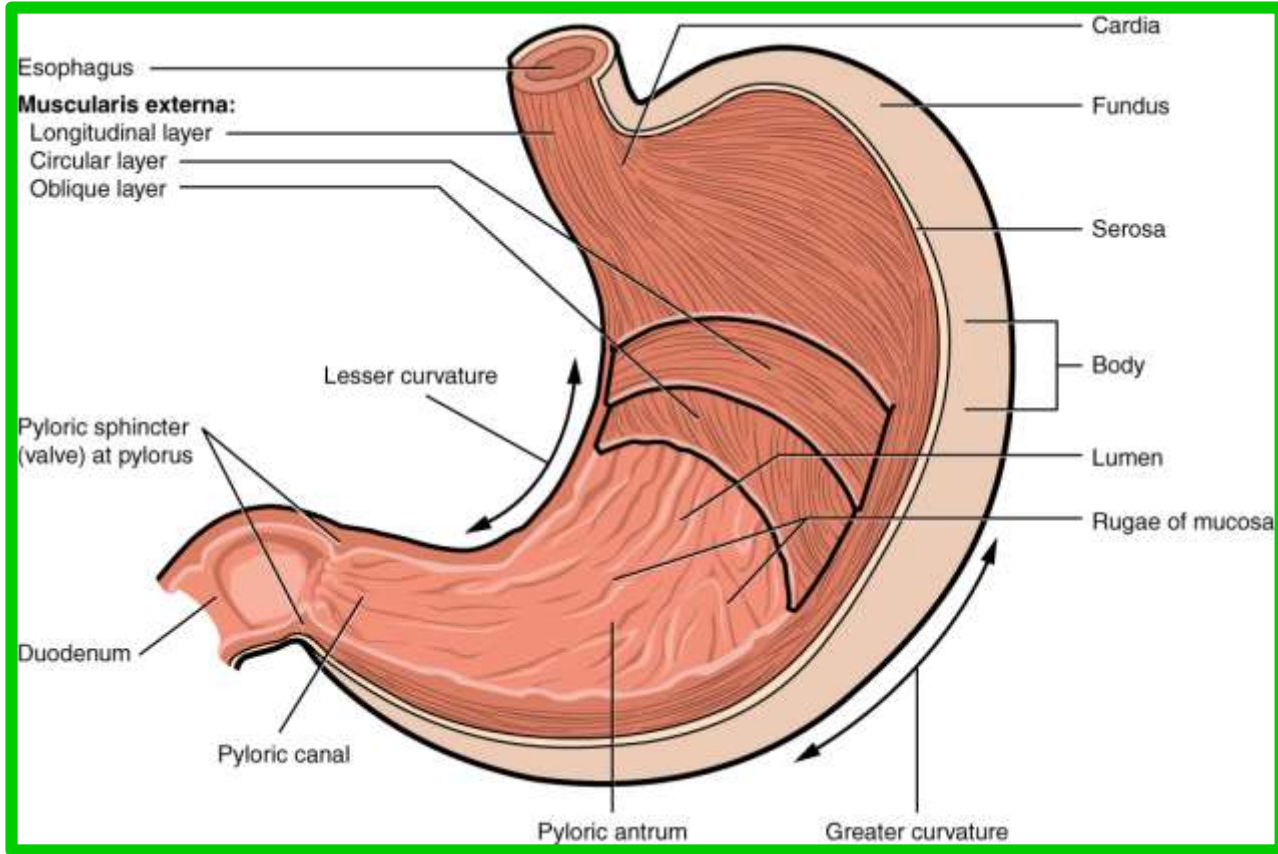
Stomach



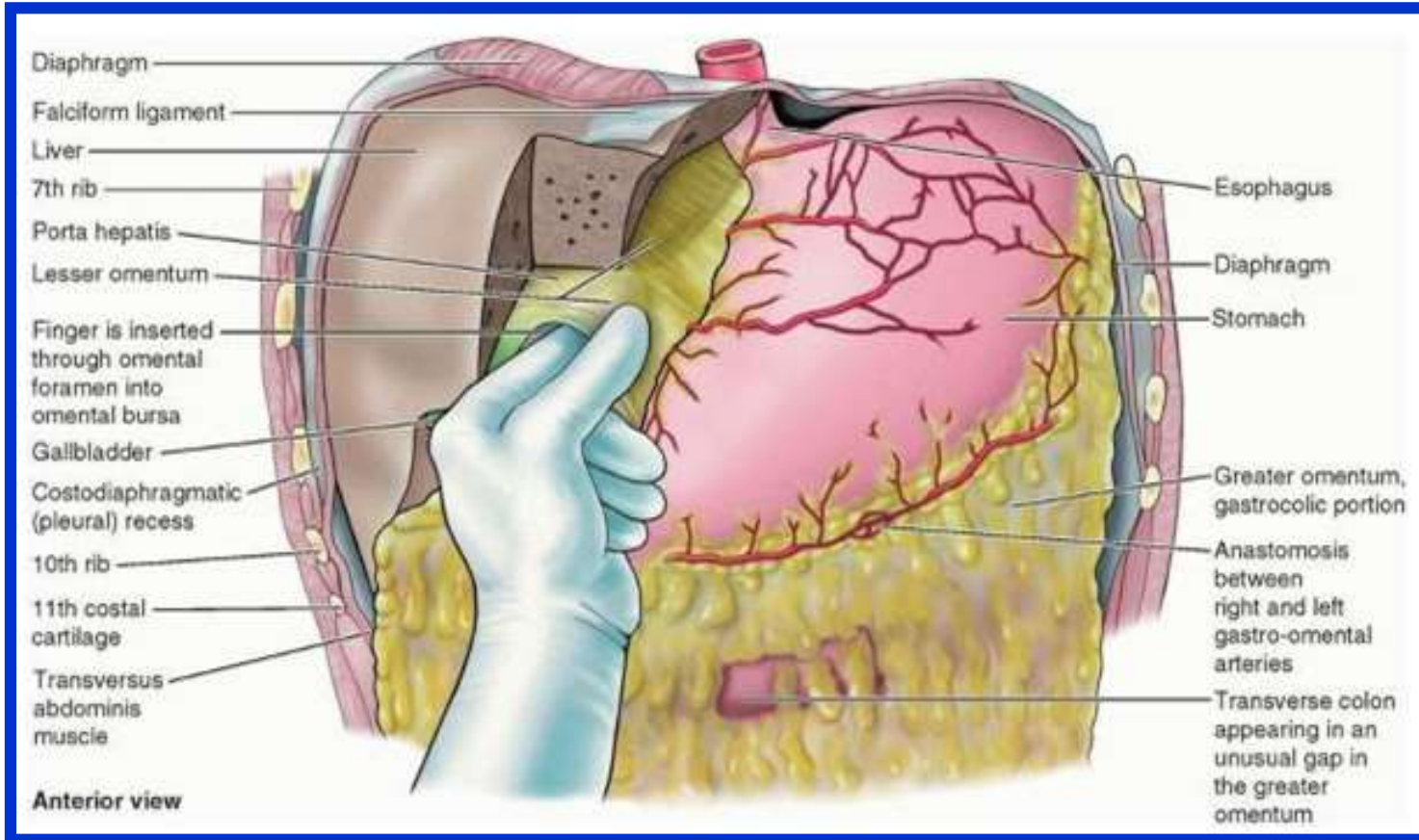
Stomach



Stomach

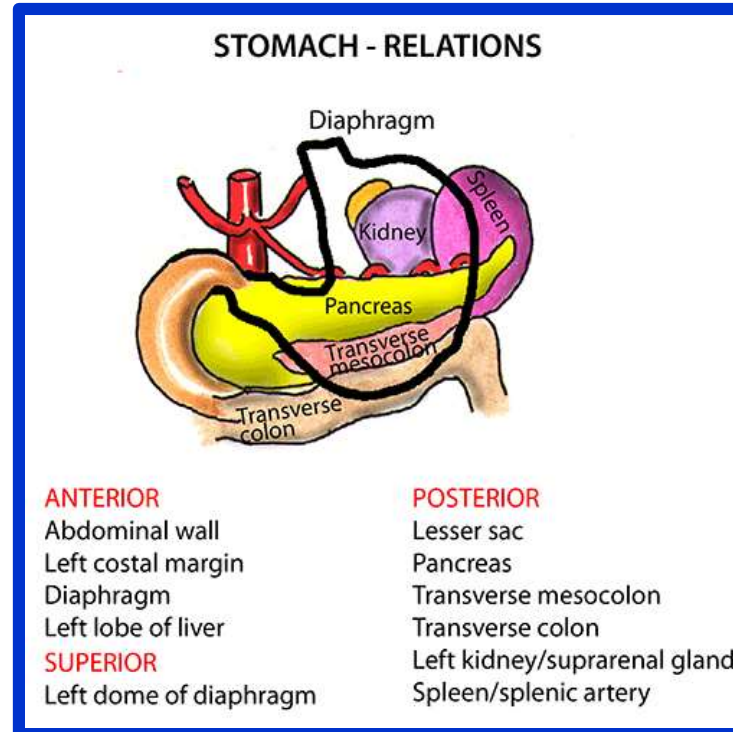
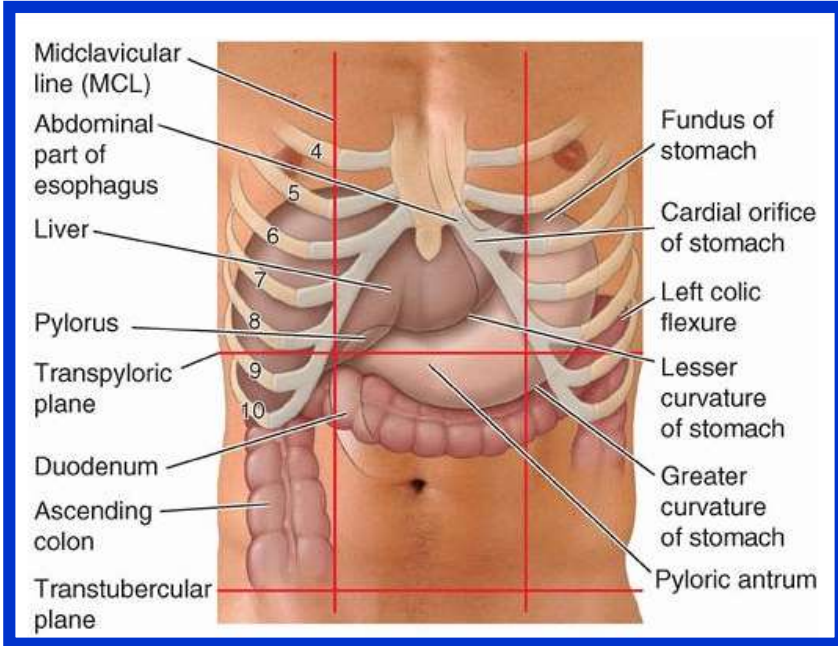


Stomach



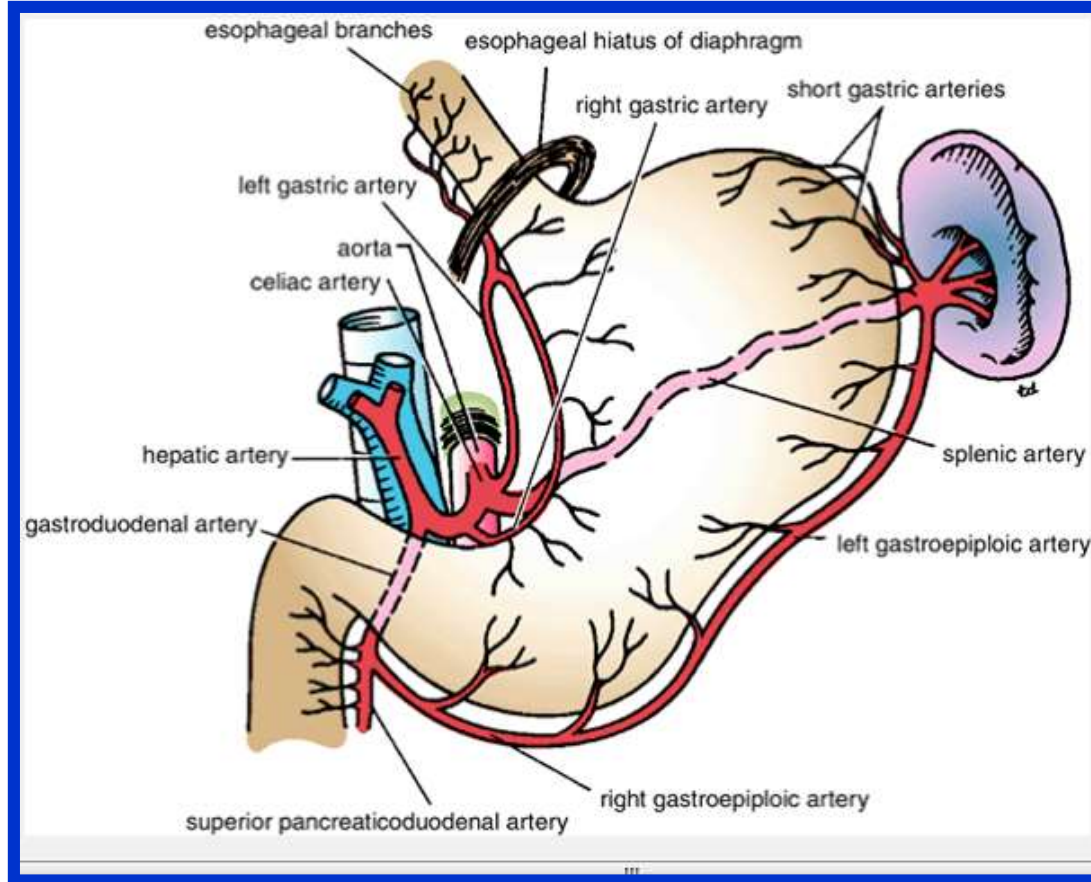
Stomach

Relations

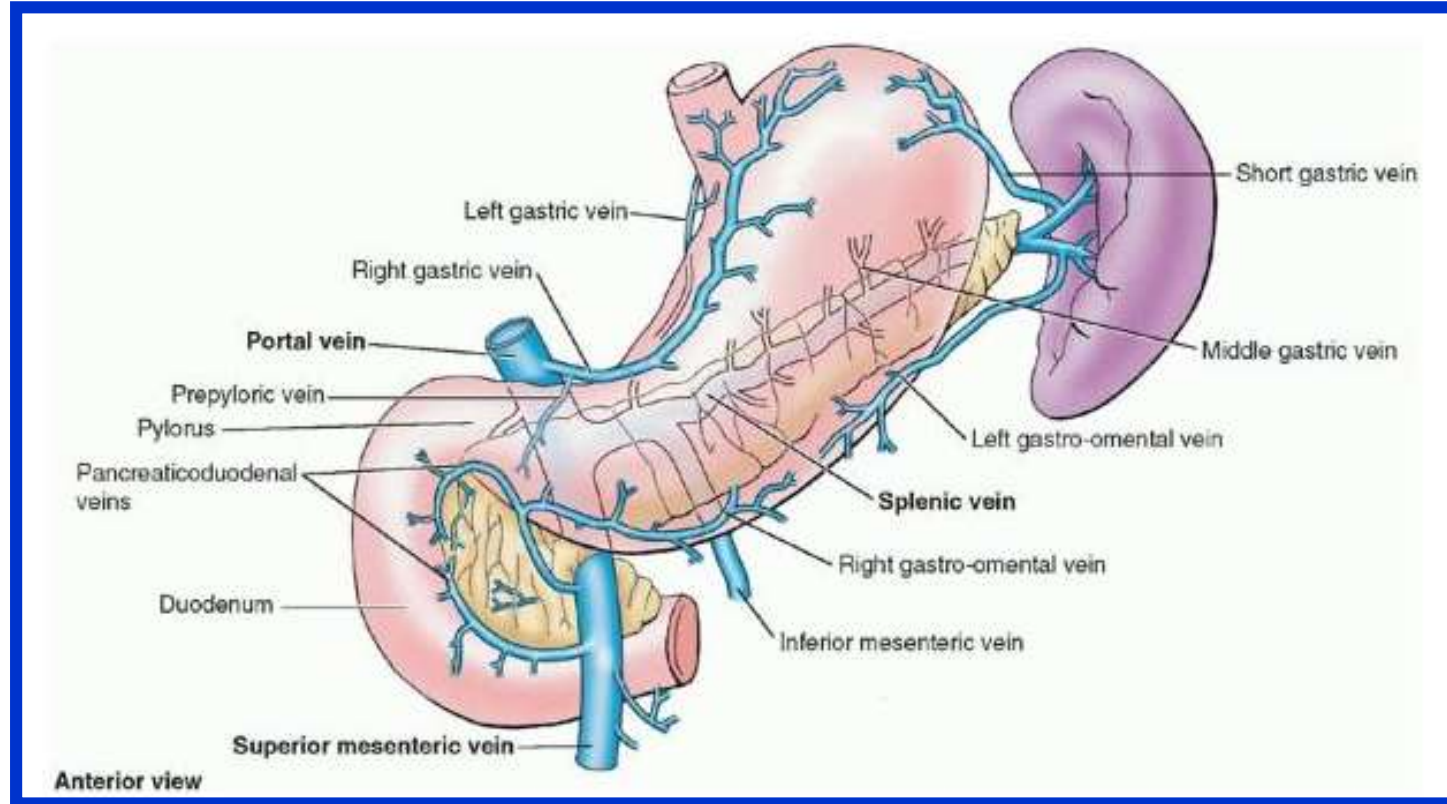


Stomach

Blood Supply

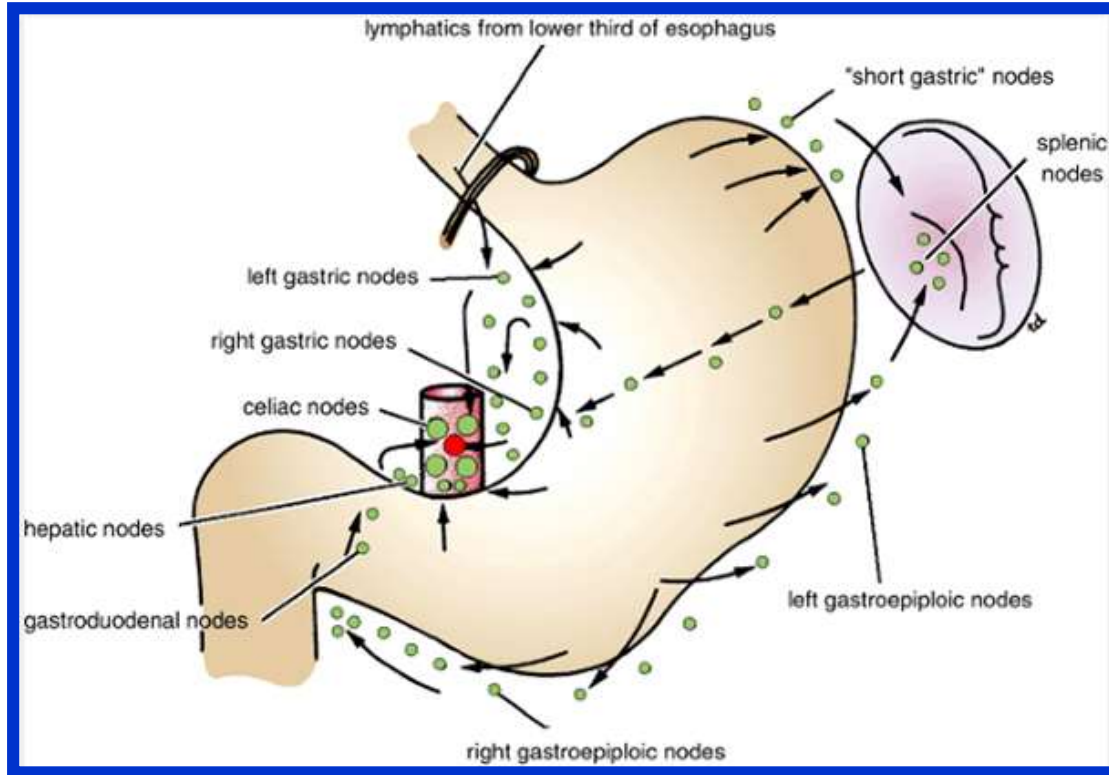


Veins



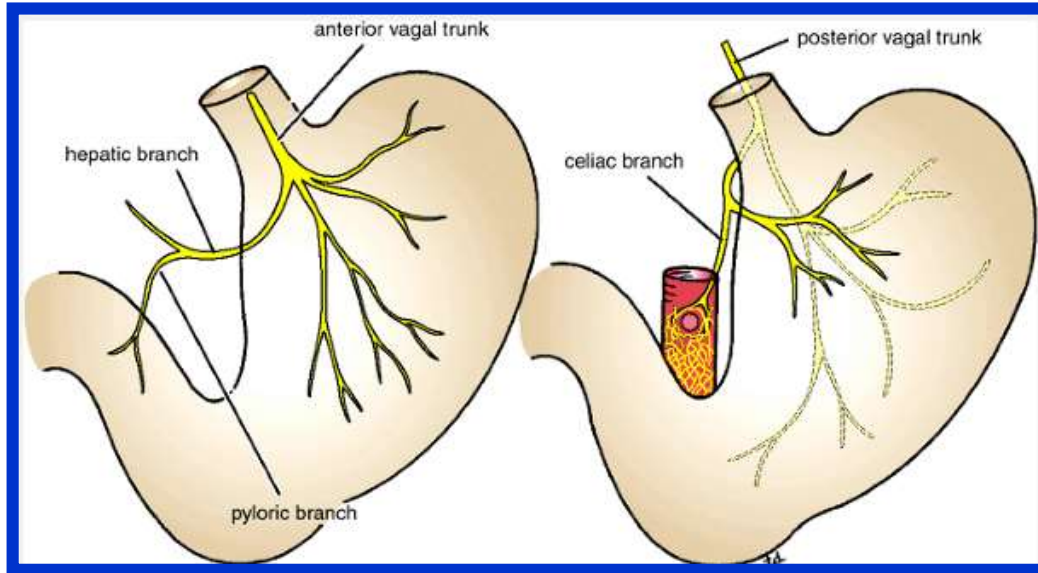
Stomach

Lymph Drainage



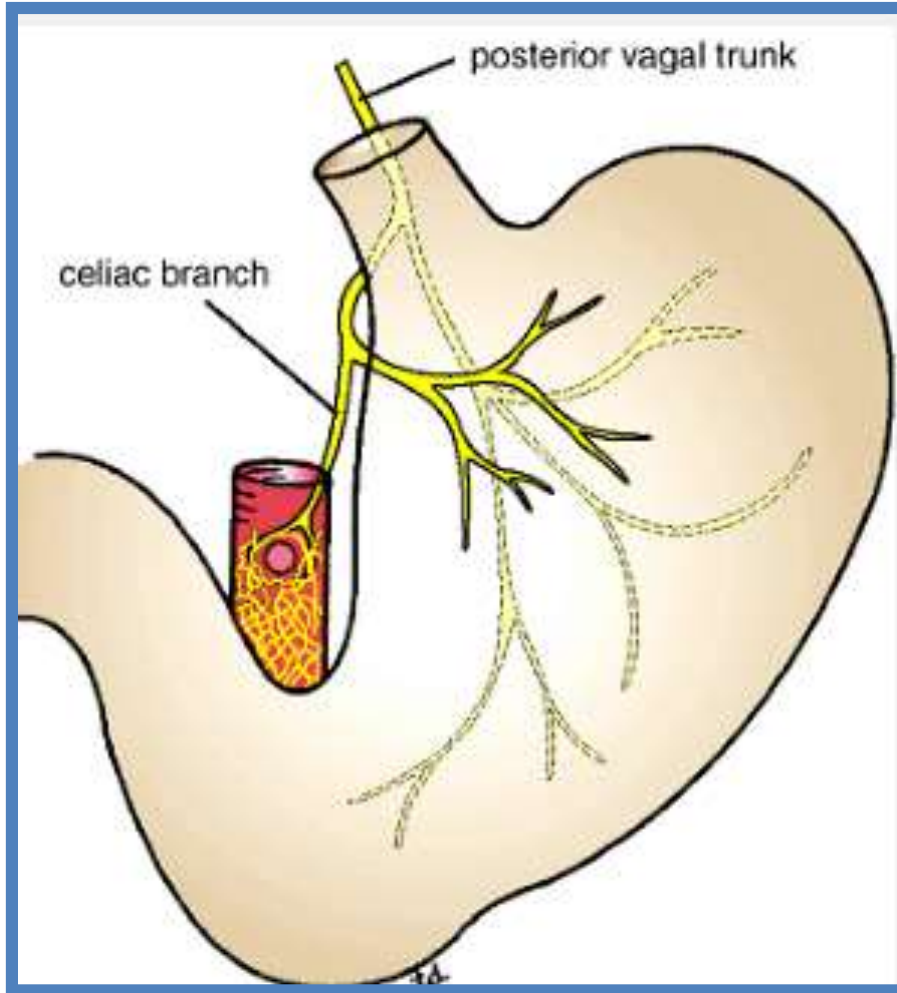
Stomach

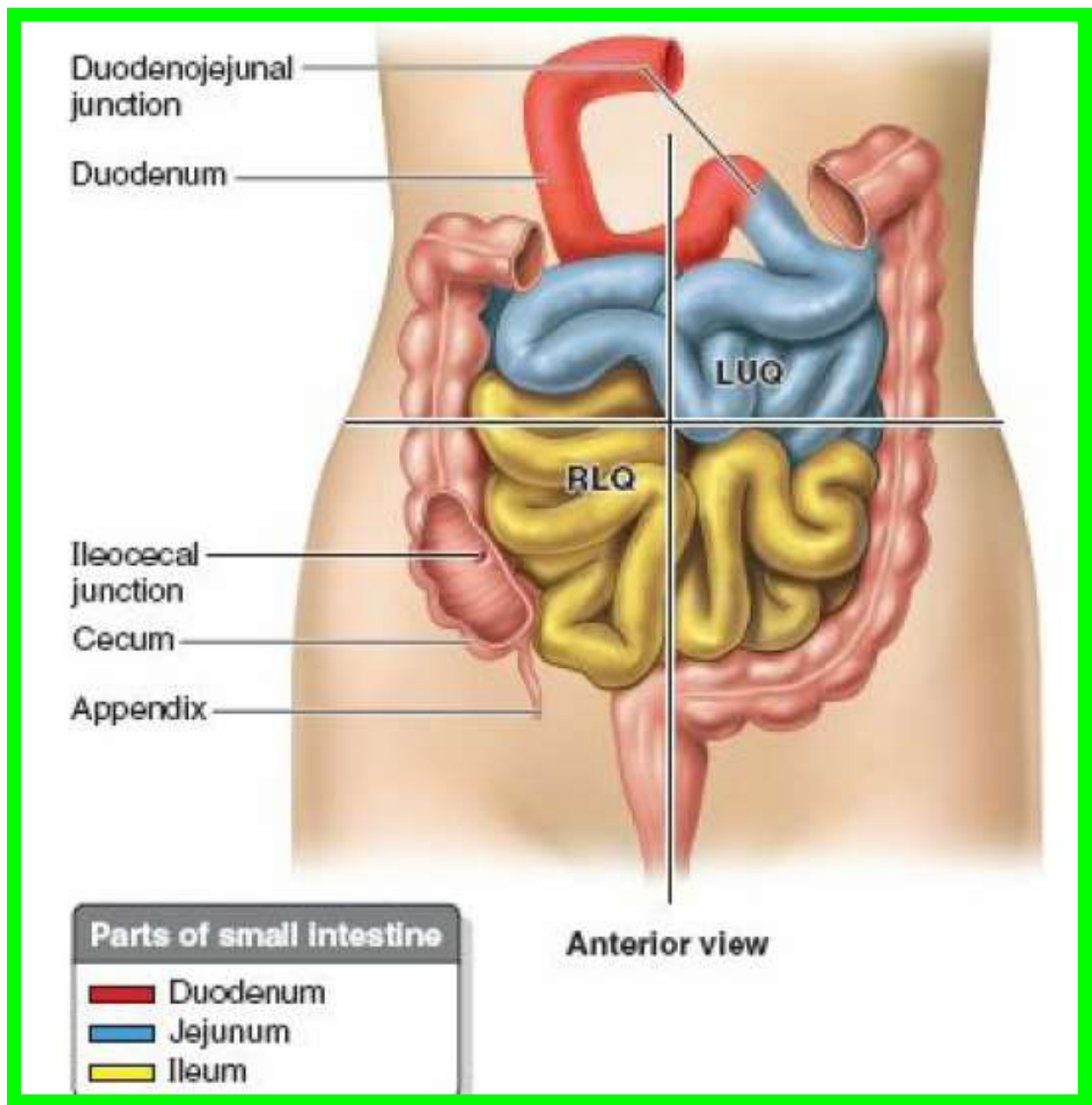
Nerve Supply



Stomach

Nerve Supply





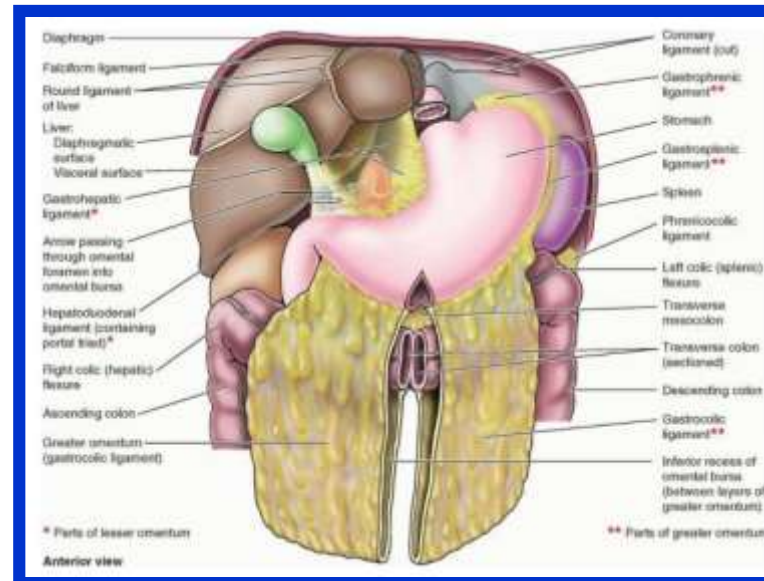
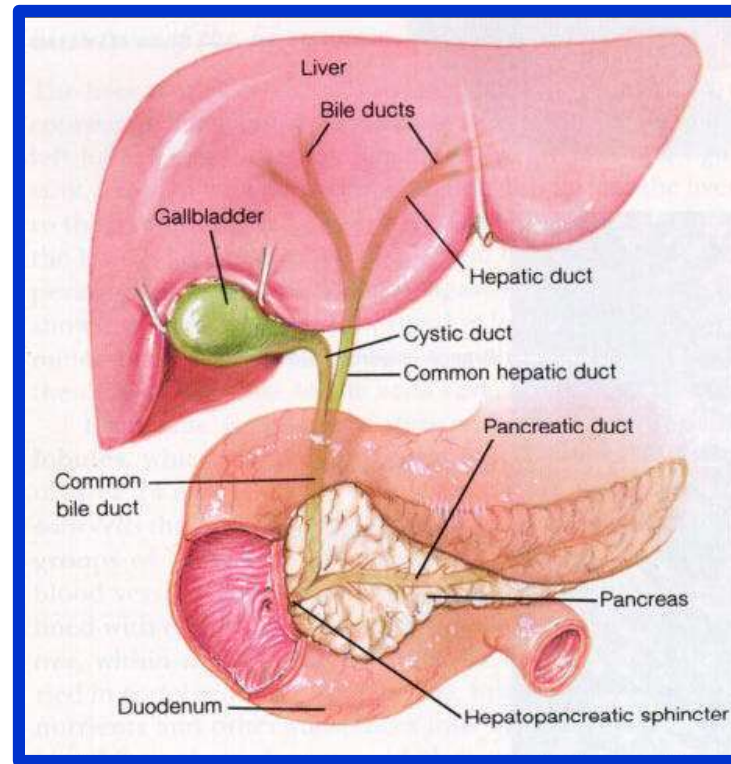
Small Intestine

Dr Aiman Qais AL Maathidy
Wednesday 6 April 2022

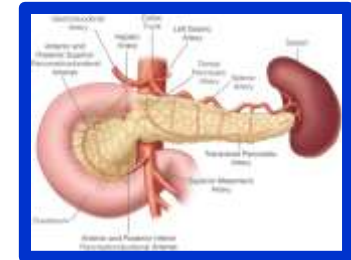
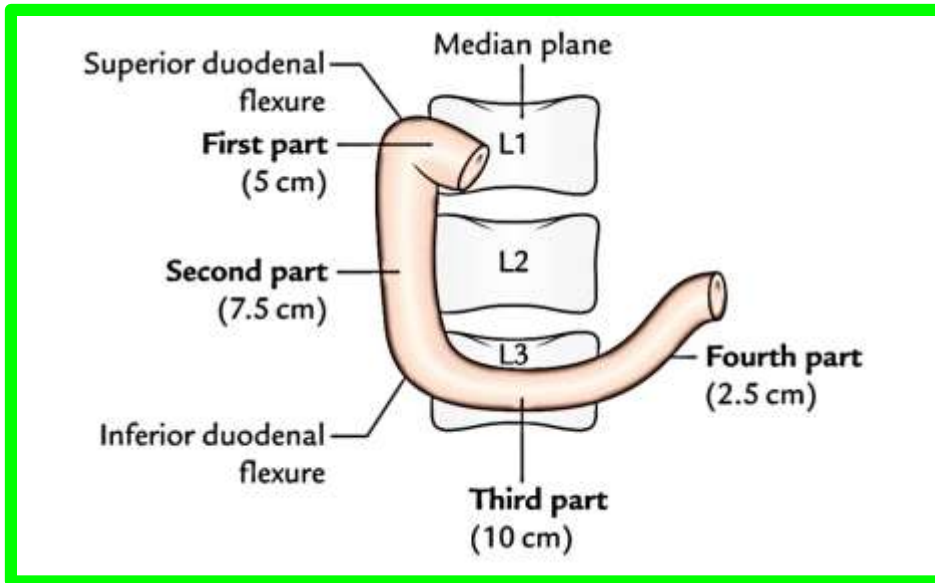
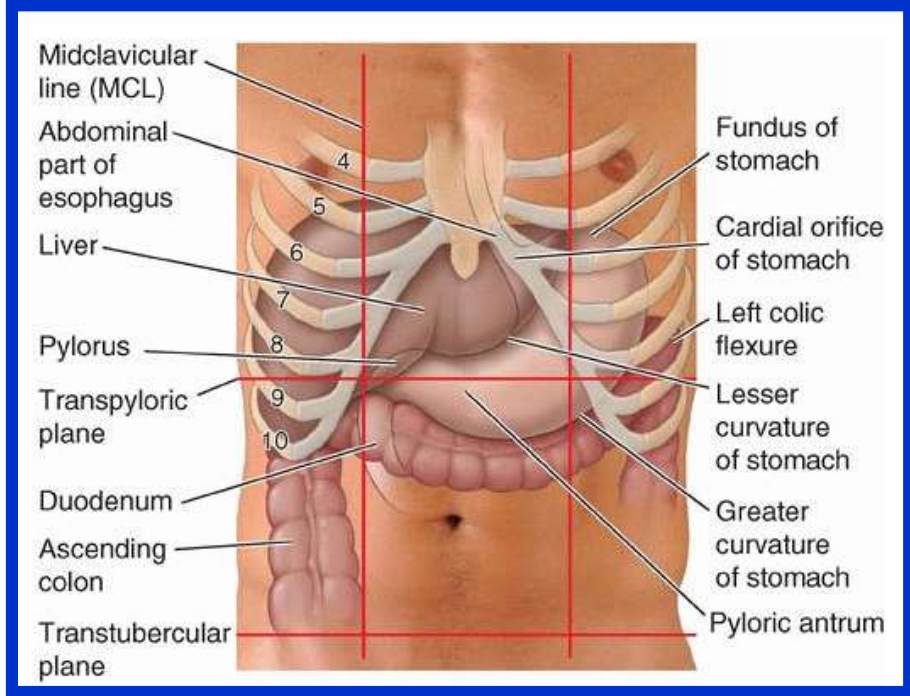
Duodenum

- ❖ The duodenum is a **C-shaped tube**, about **10 in. (25 cm)** long, which joins the stomach to the jejunum.
- ❖ It receives the openings of **the bile** and **pancreatic ducts**. The duodenum curves around the head of the pancreas

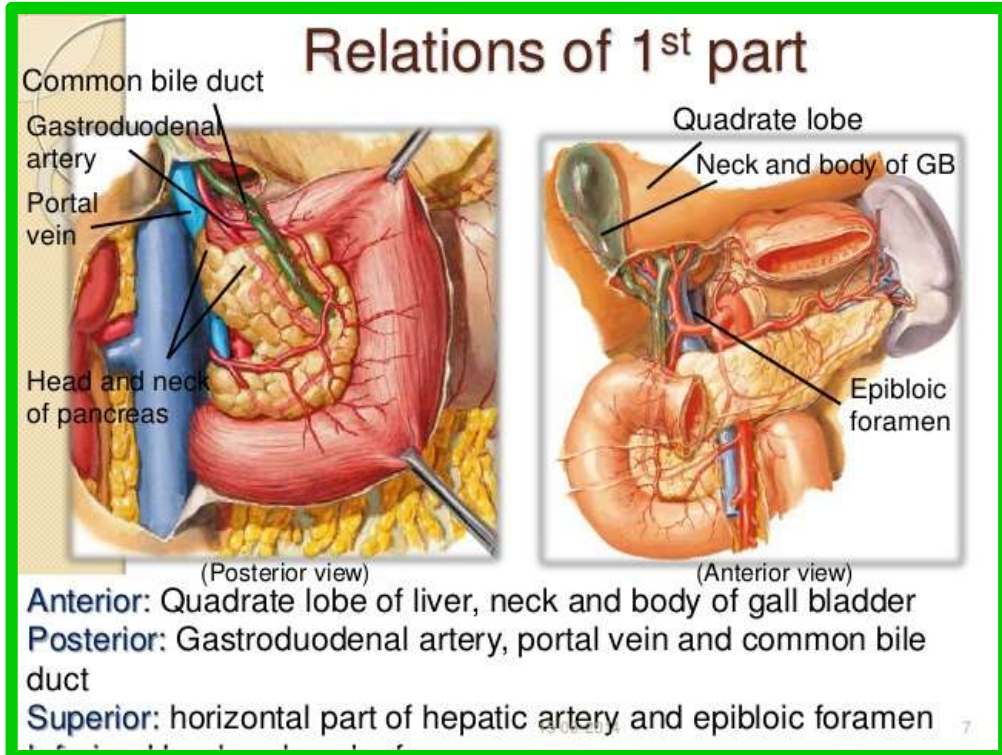
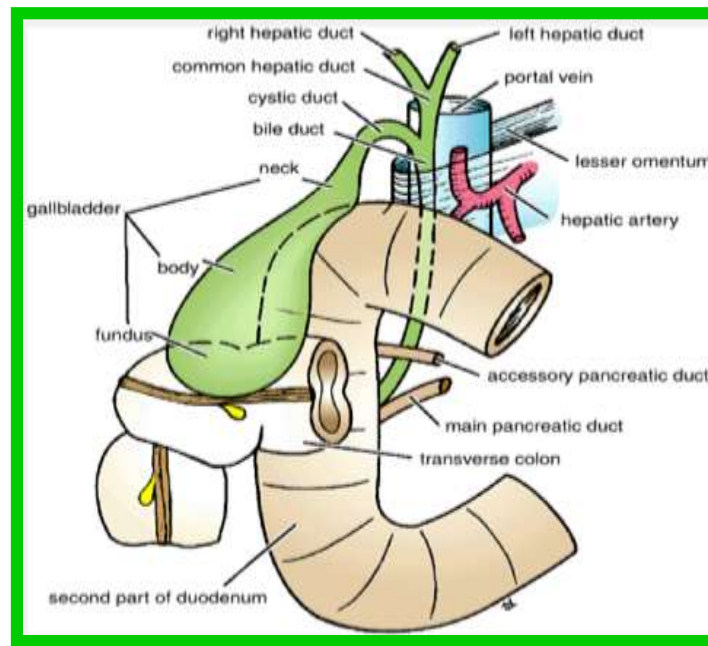
The first inch (2.5 cm) of the duodenum resembles the stomach in that it is covered on its anterior and posterior surfaces with peritoneum and has **the lesser omentum** attached to its upper border and **the greater omentum** attached to its lower border



Duodenum

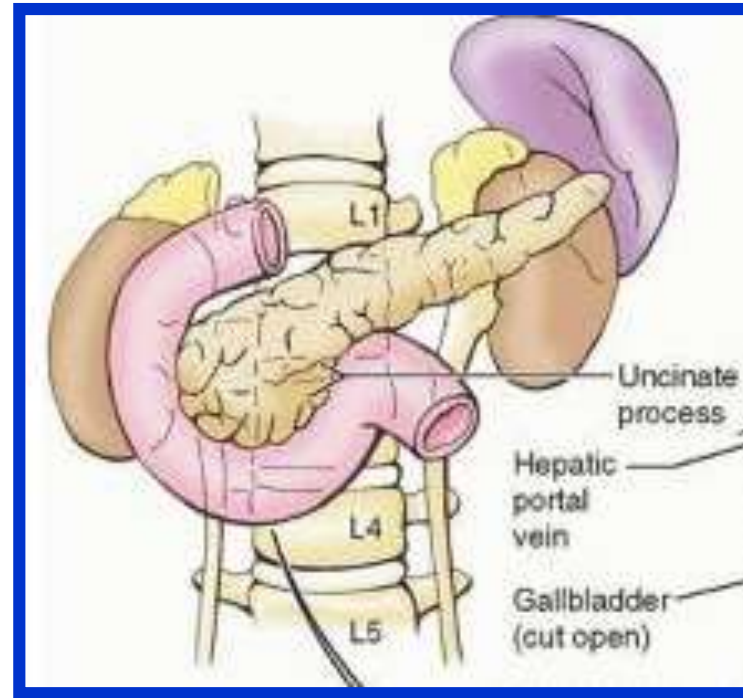
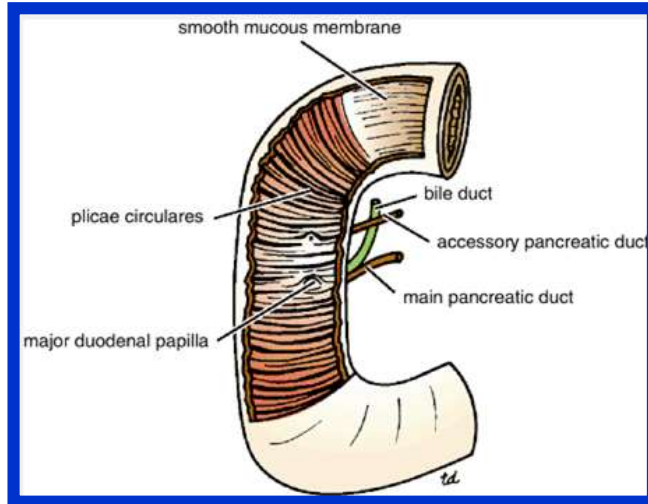


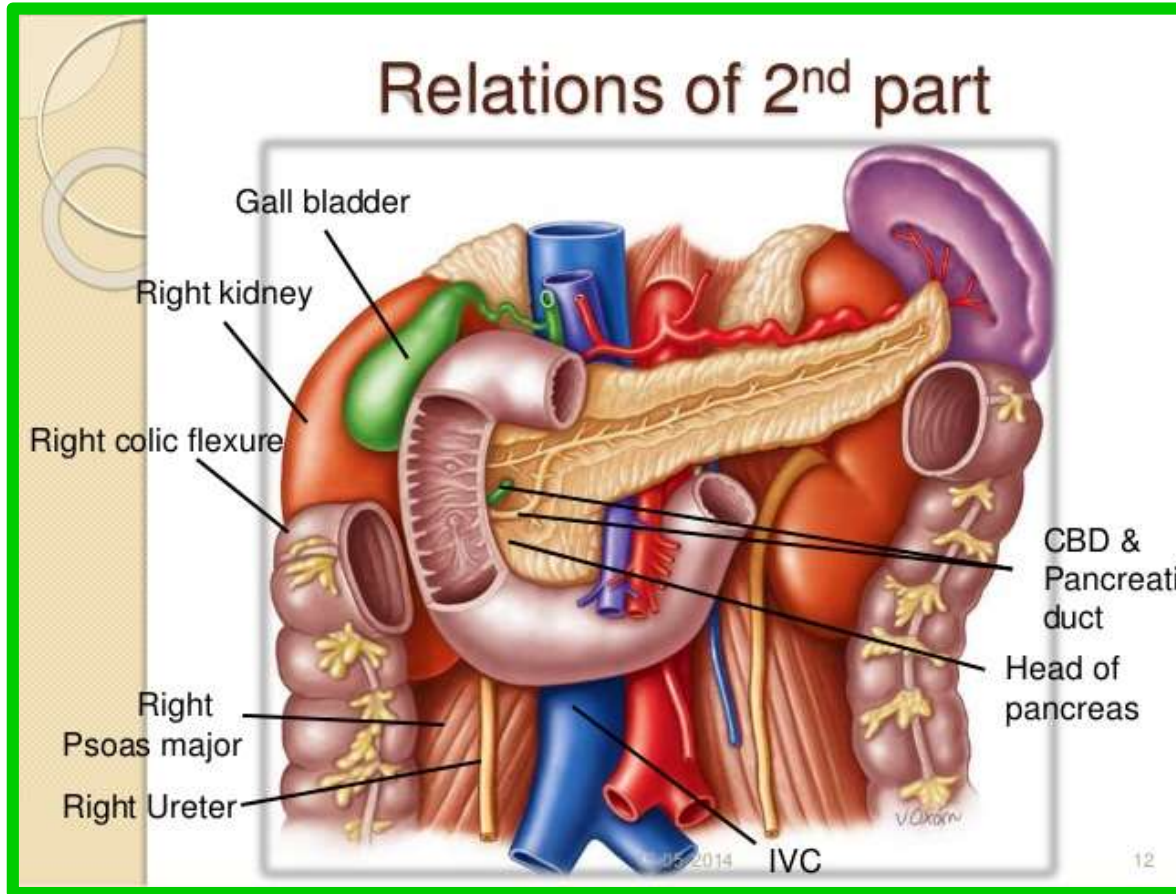
Duodenum



Duodenum

Dr Aiman Qais AL Maathidy
Wednesday 6 April 2022

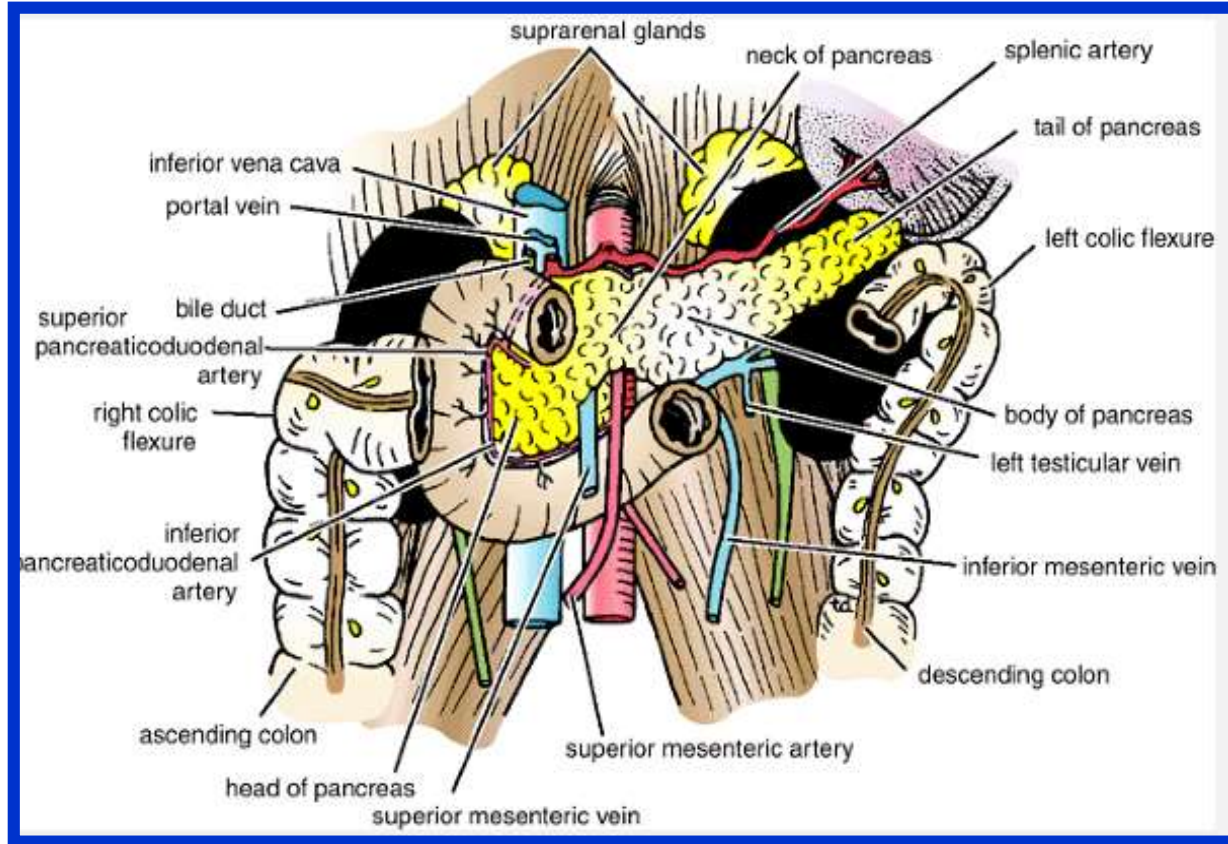




Duodenum

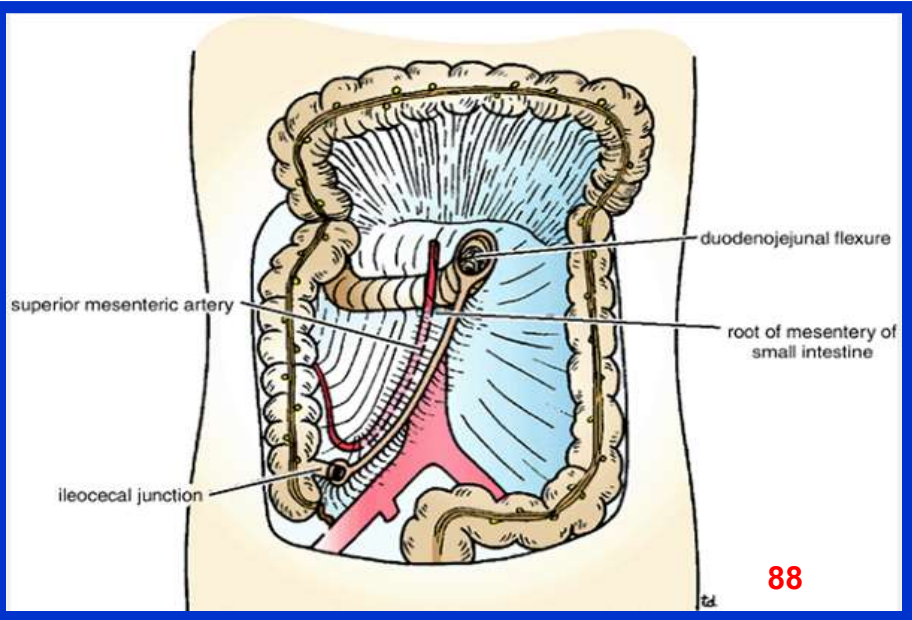
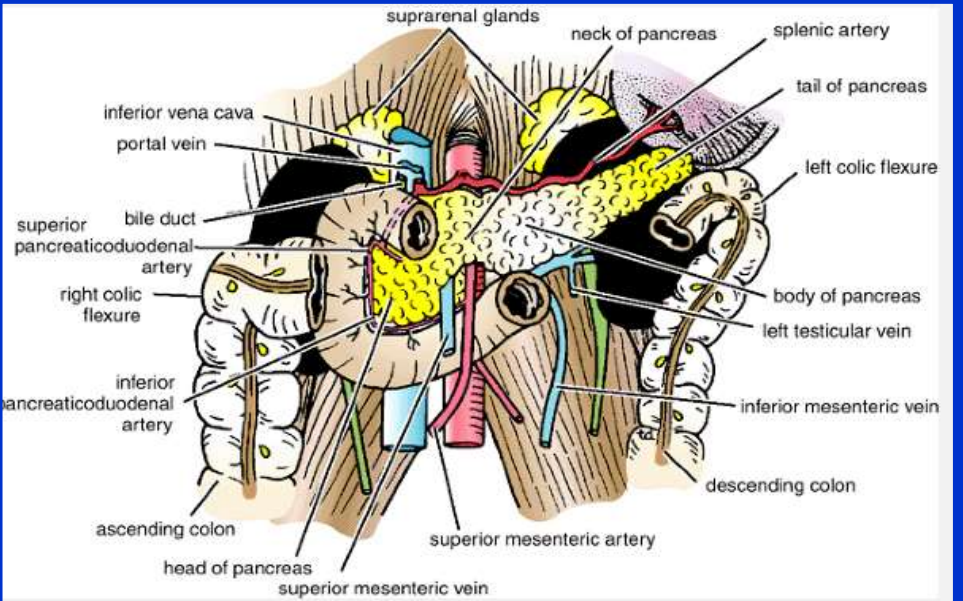
Dr Aiman Qais AL Maathidy

Wednesday 6 April 2022



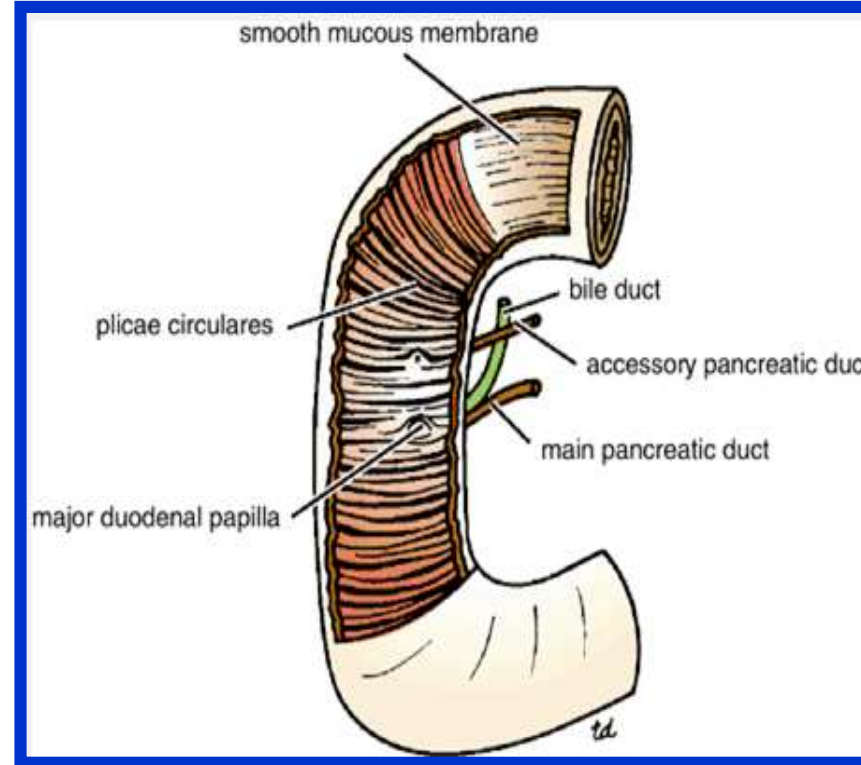
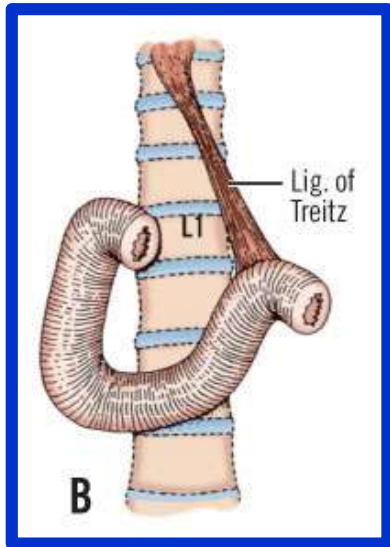
Duodenum

Dr Aiman Qais AL Maathidy
Wednesday 6 April 2022

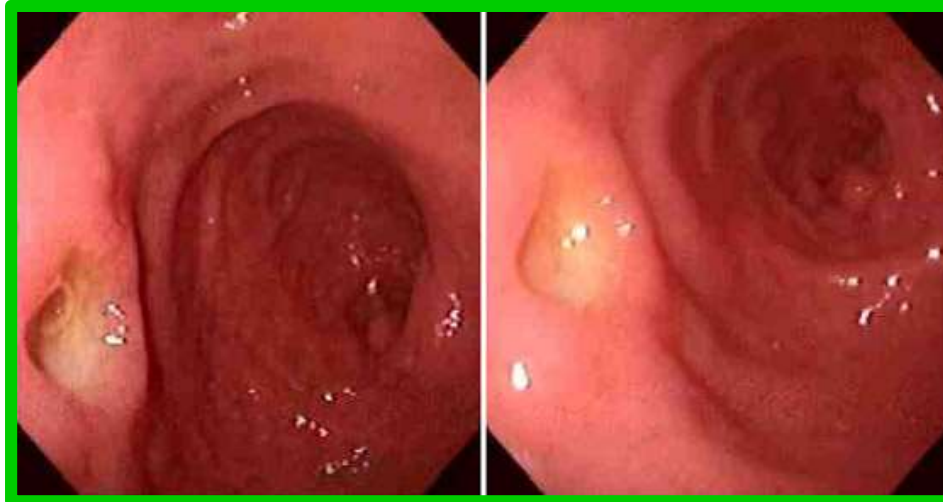
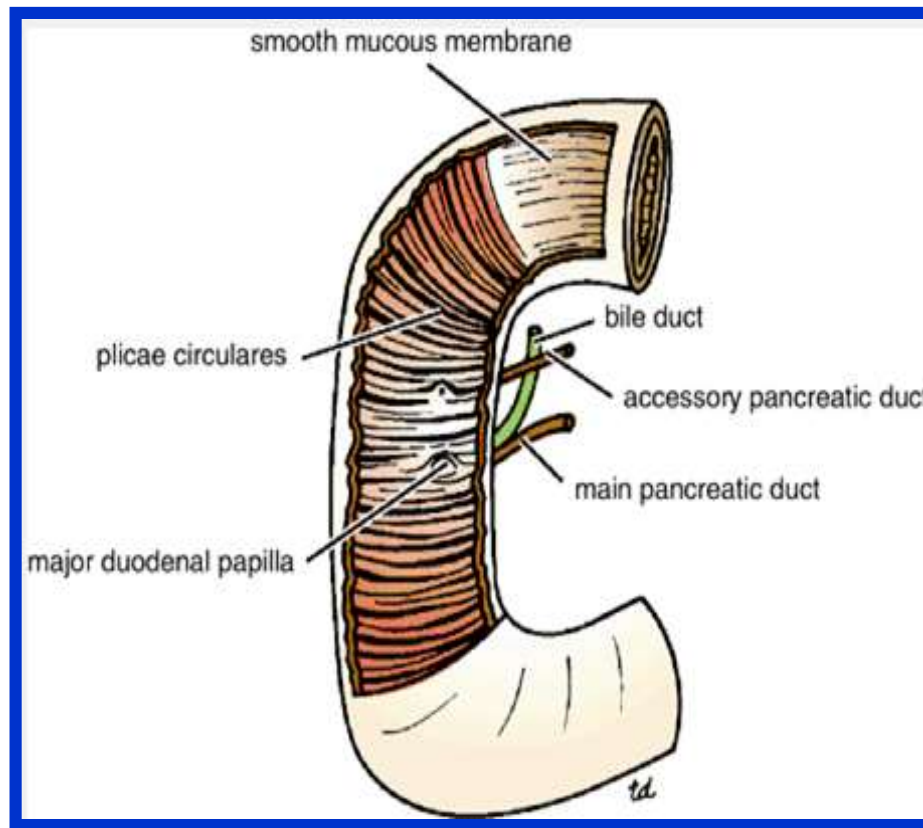


Duodenum

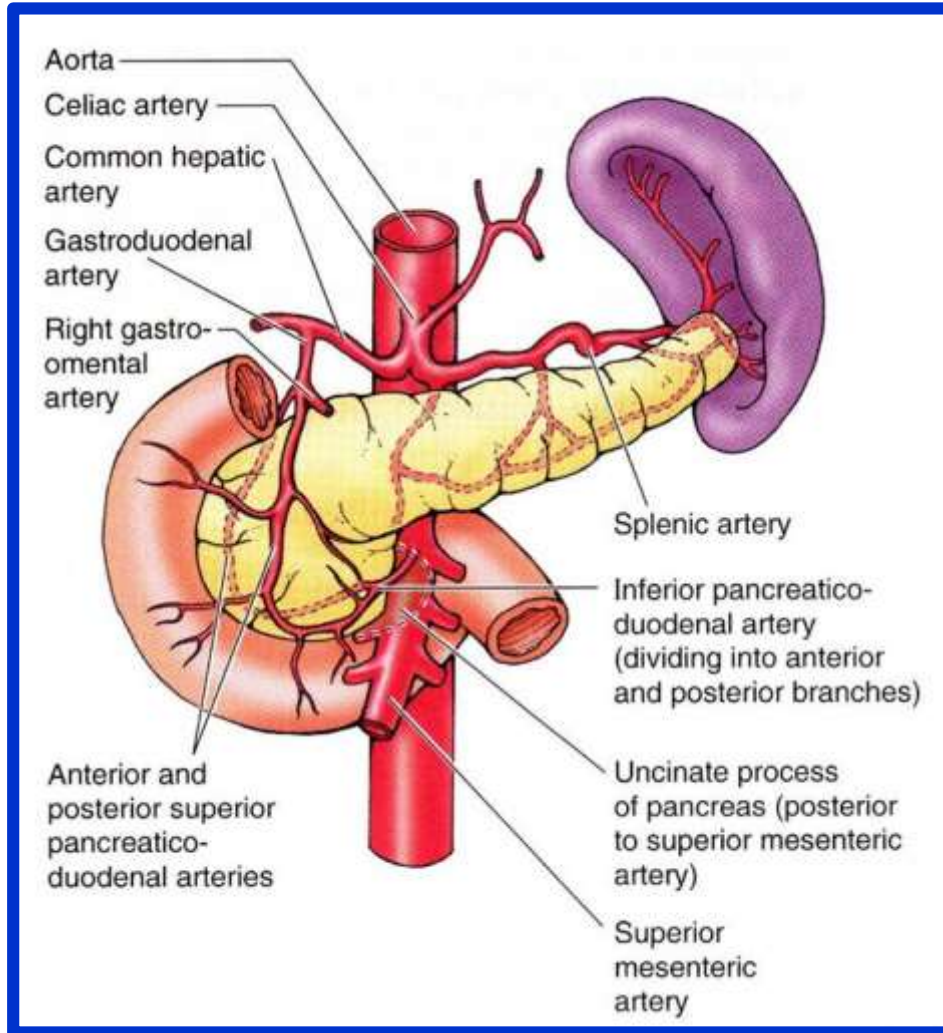
Dr Aiman Qais AL Maathidy



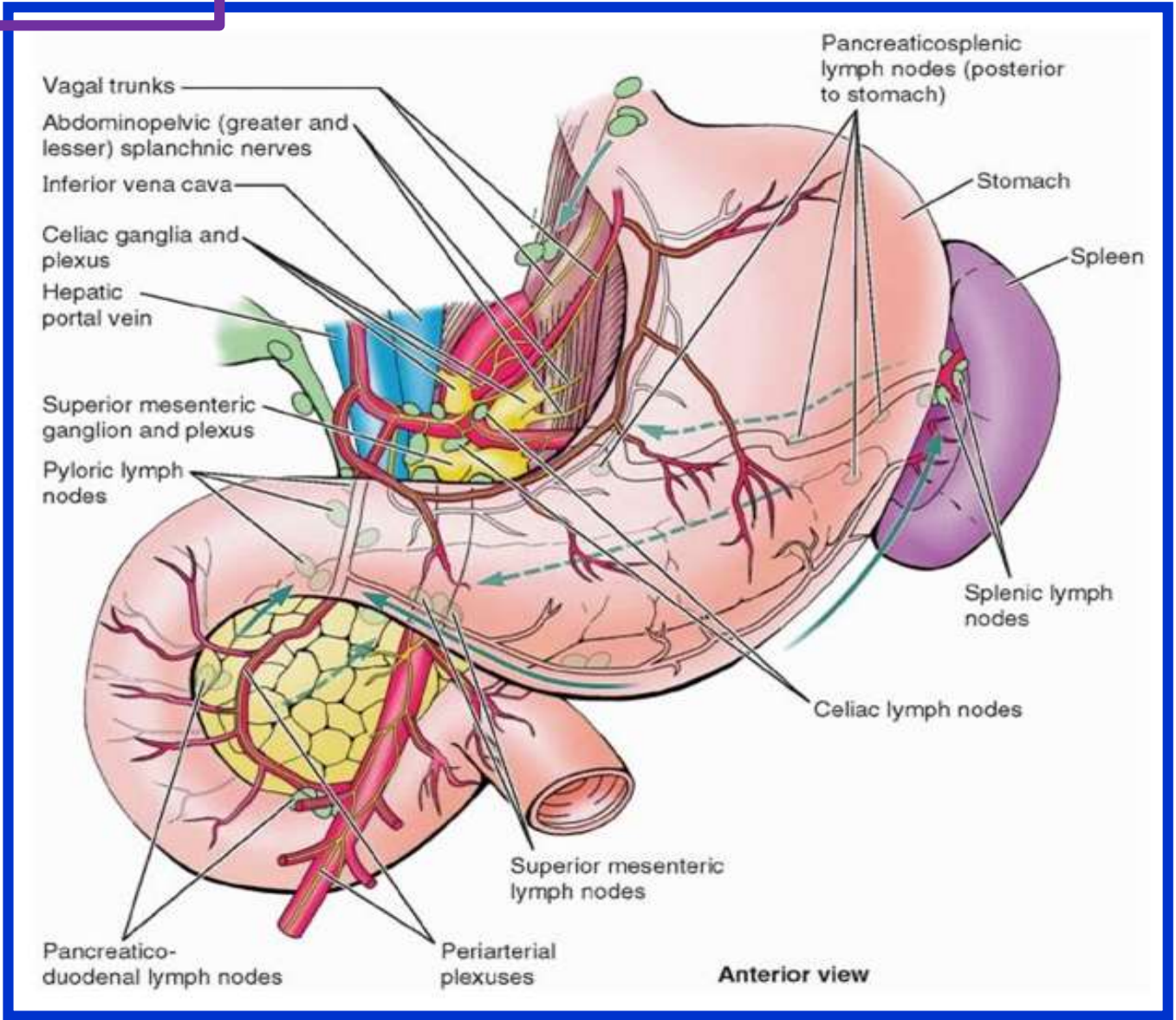
Duodenum



Duodenum

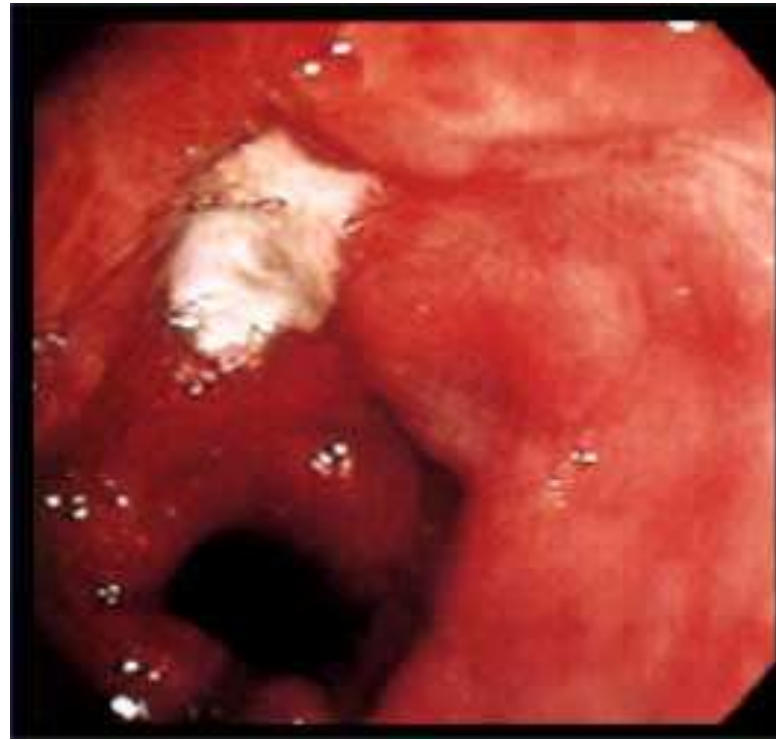


Duodenum



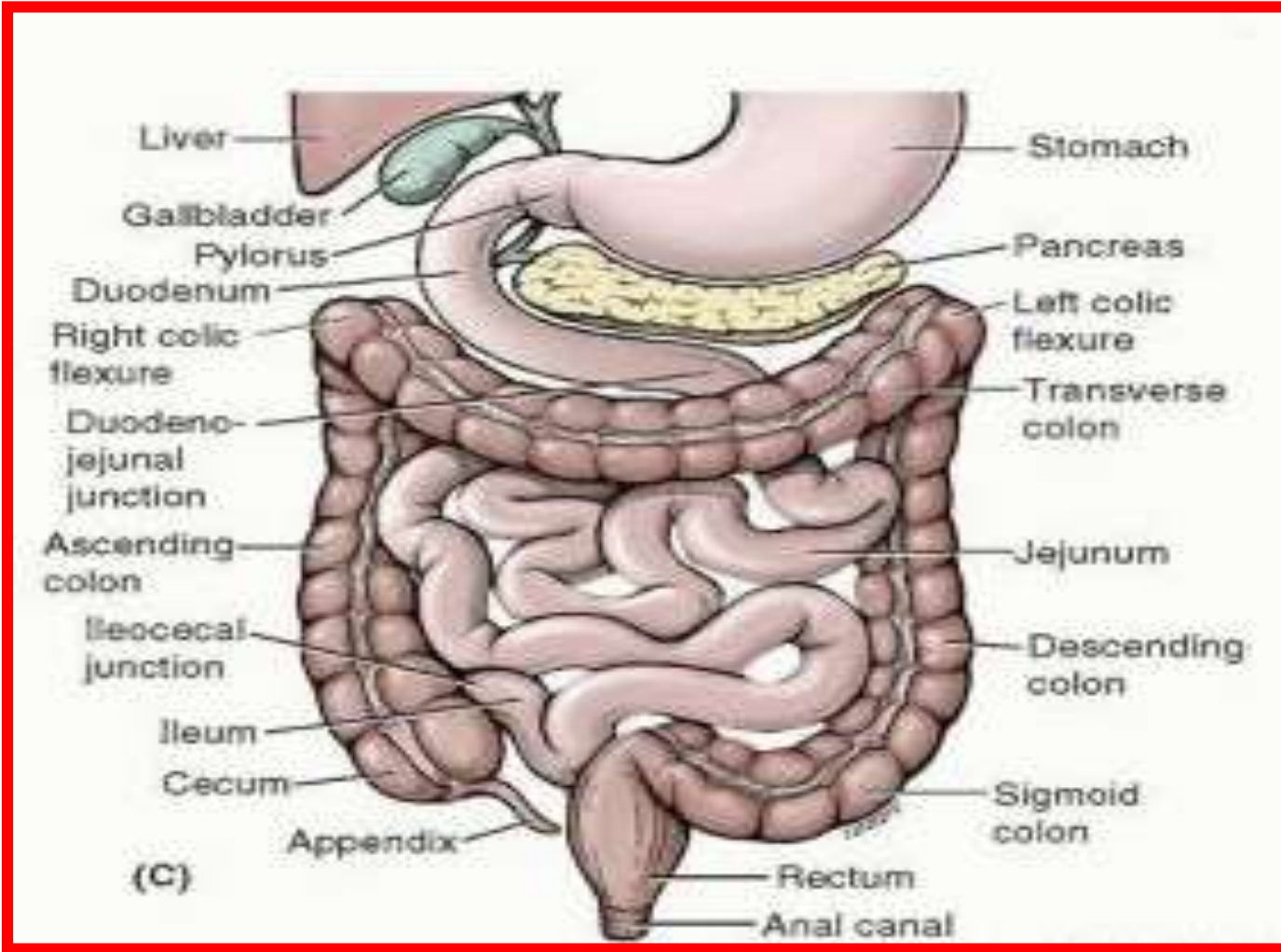
Duodenal ulcers (peptic ulcers) are inflammatory erosions of the duodenal mucosa. Most (65%) duodenal ulcers occur in the posterior wall of the superior part of the duodenum within 3 cm of the pylorus.

Occasionally, an ulcer perforates the duodenal wall, permitting the contents to enter the peritoneal cavity and causing peritonitis.

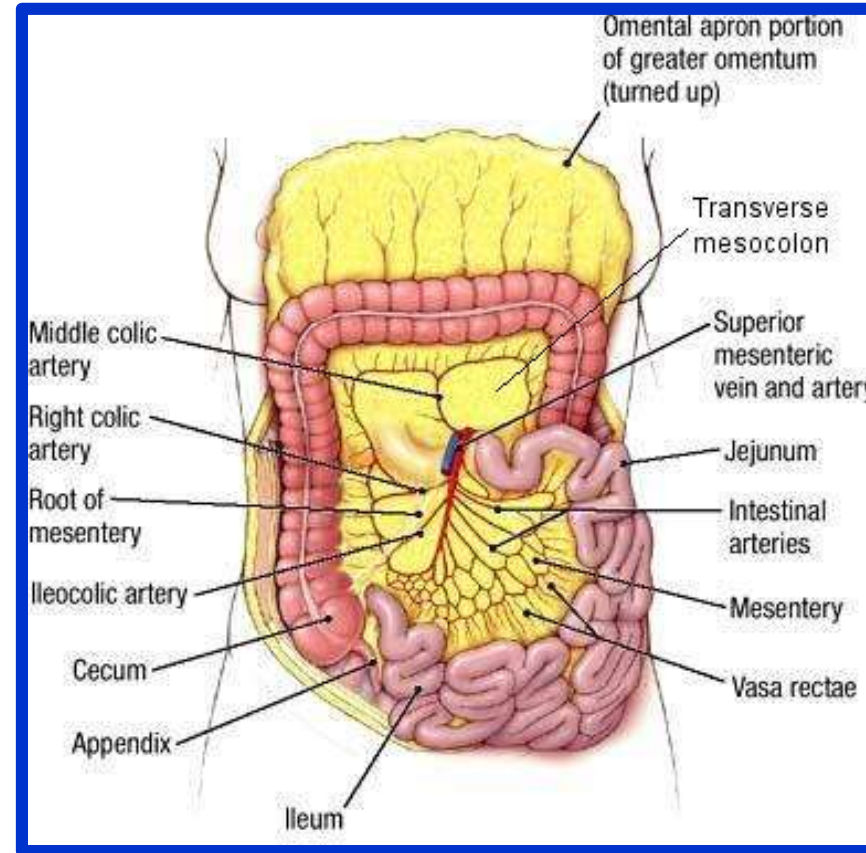
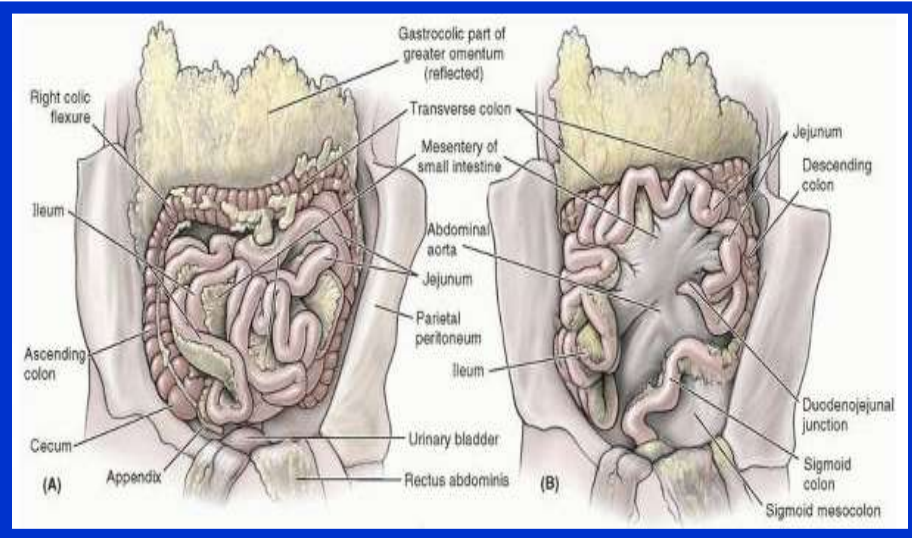


Although **bleeding from duodenal ulcers** commonly occurs, erosion of **the gastroduodenal artery** (a posterior relation of the superior part of the duodenum) by a duodenal ulcer results in severe hemorrhage into the peritoneal cavity and subsequent peritonitis

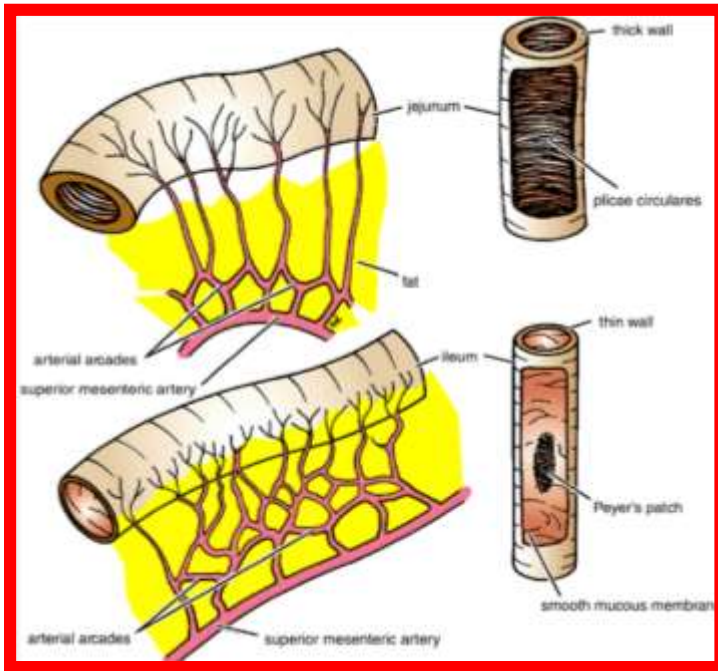
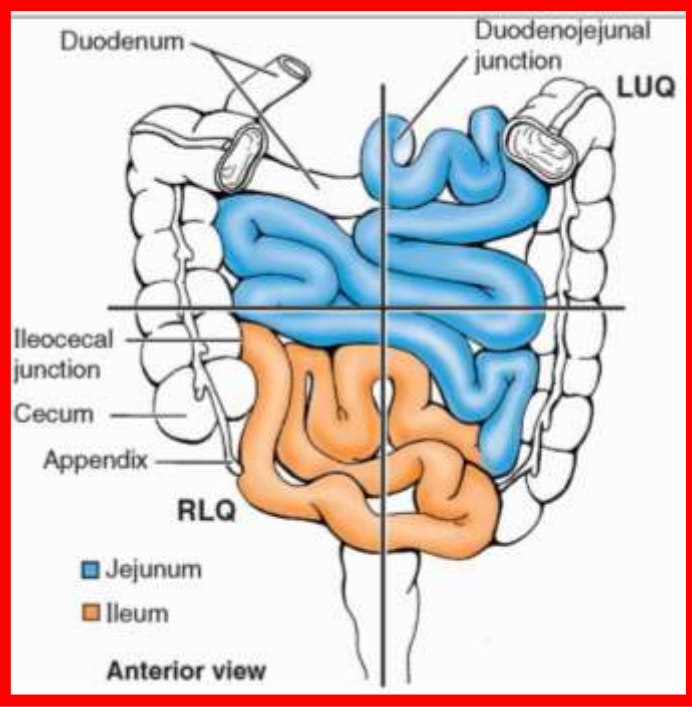
Jejunum and Ileum



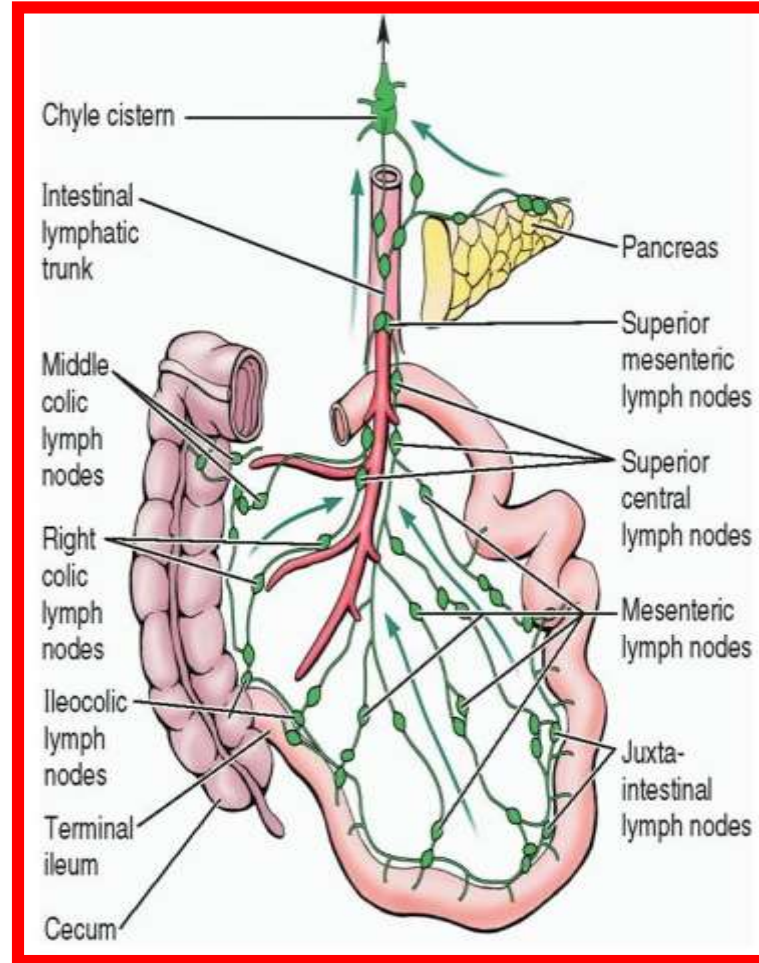
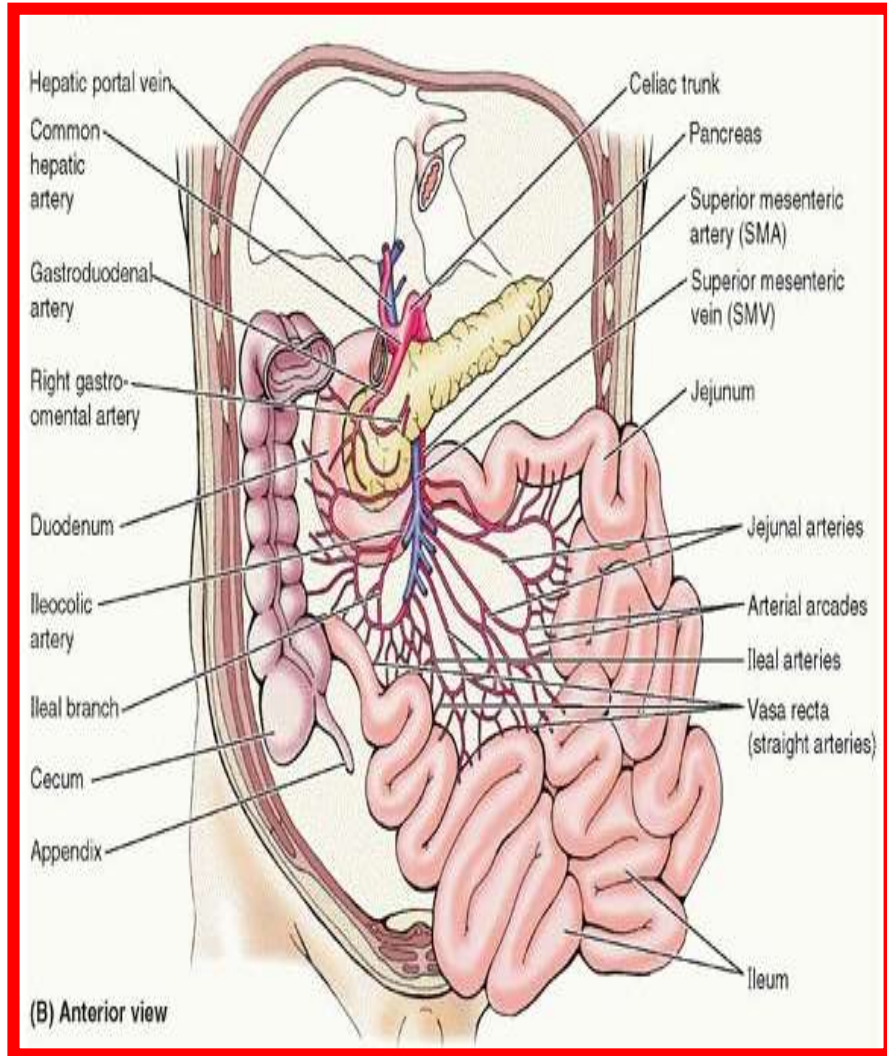
Jejunum and Ileum



Jejunum and Ileum

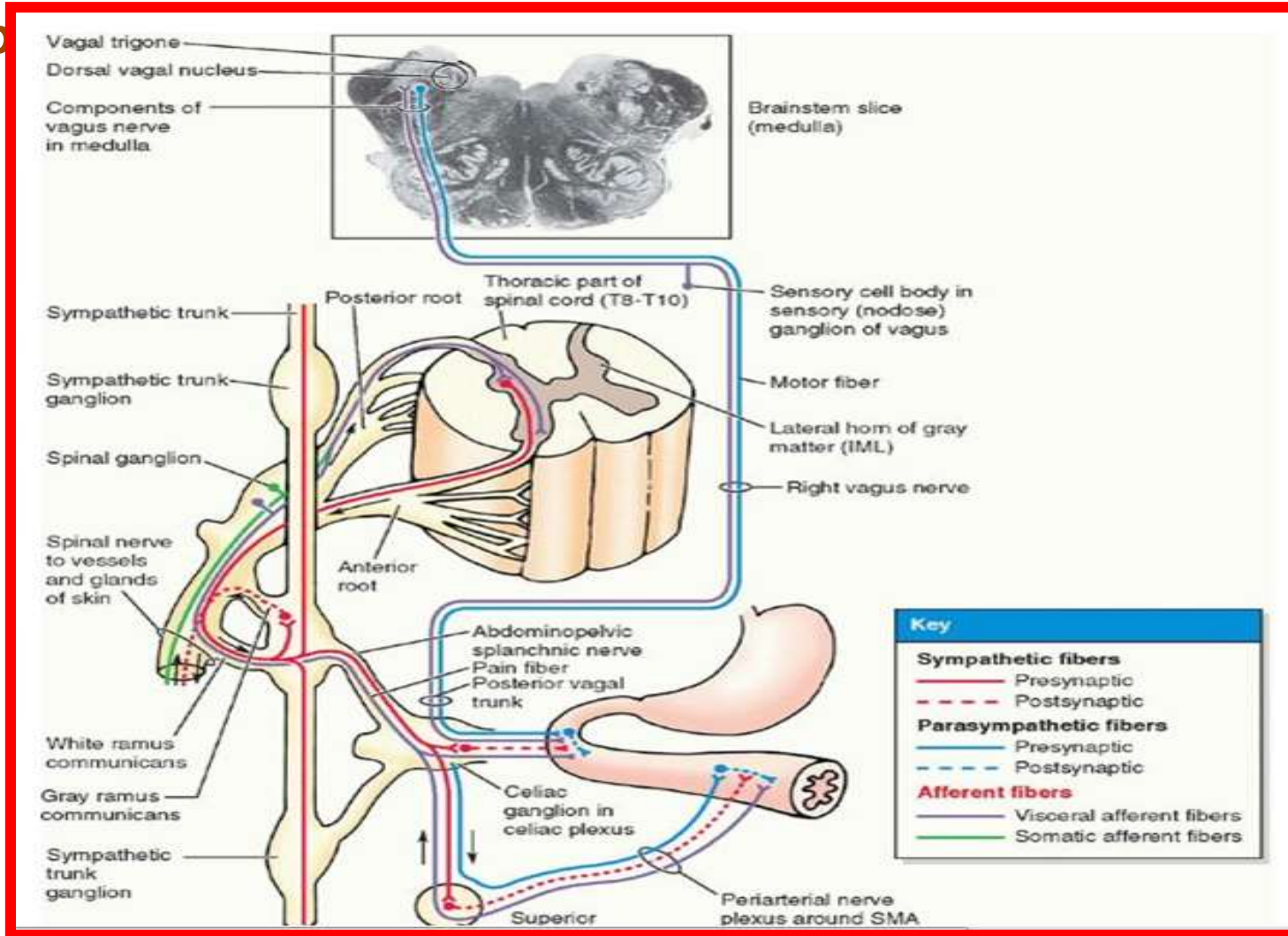


Jejunum and Ileum

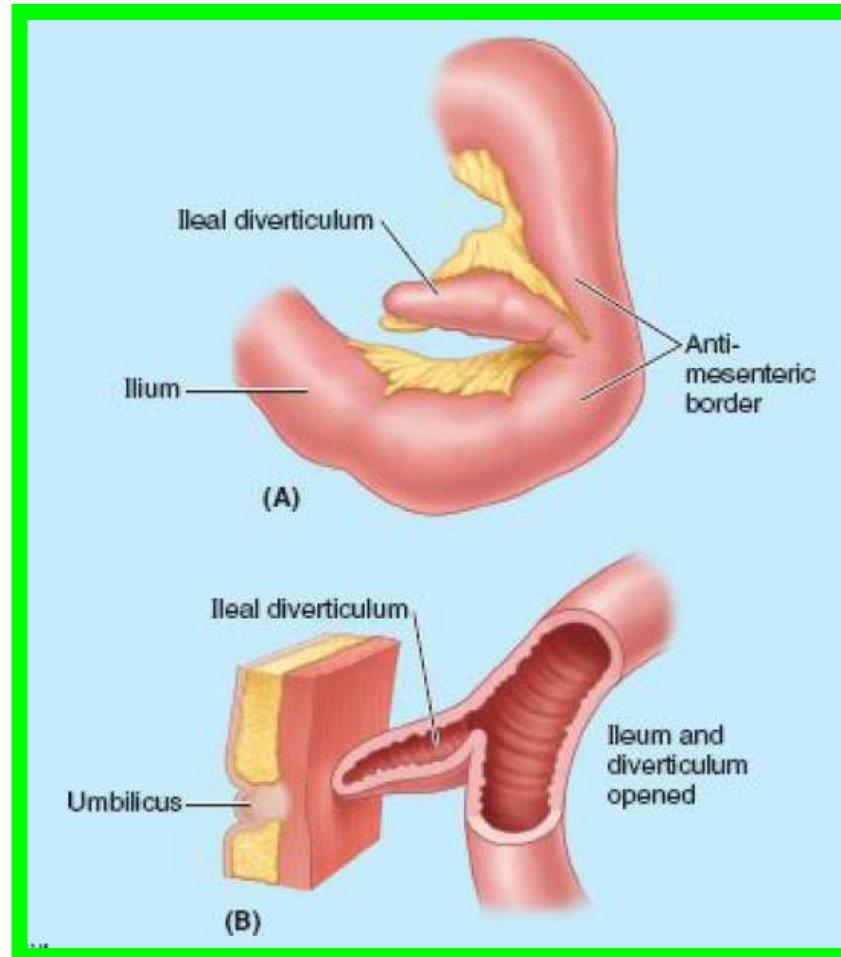


Jejunum and Ileum

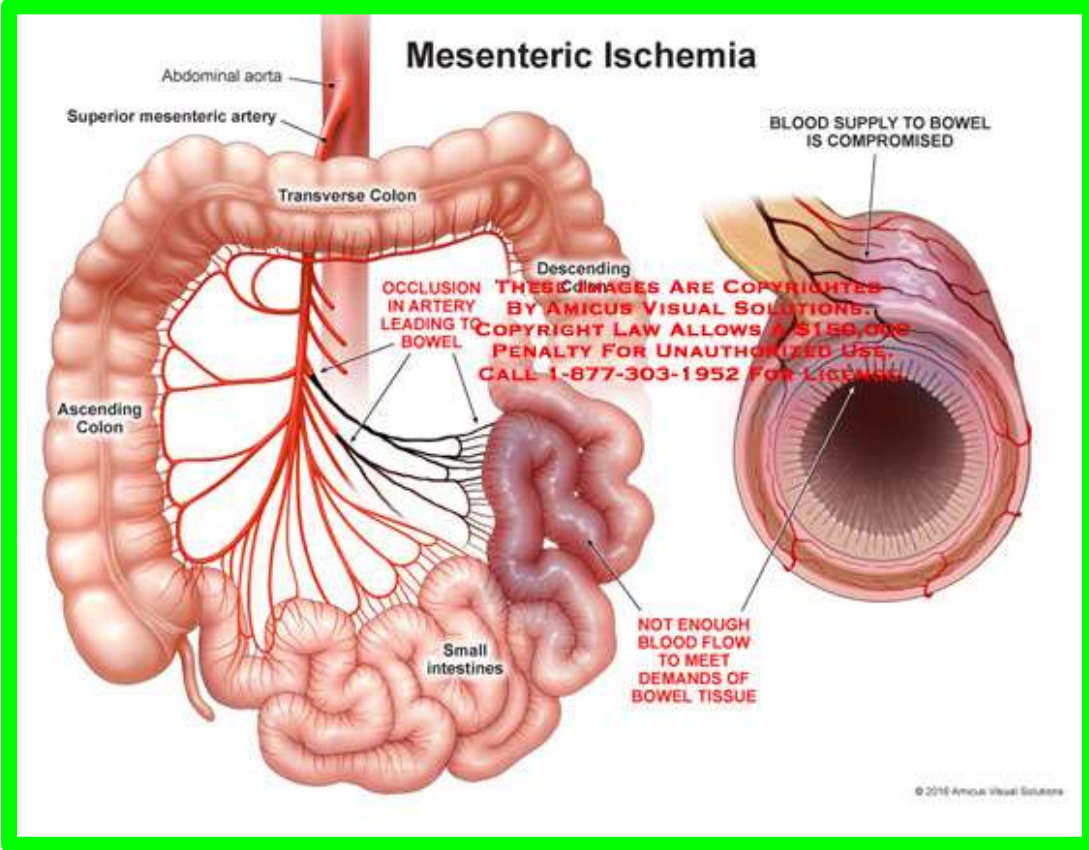
Nerve Supp



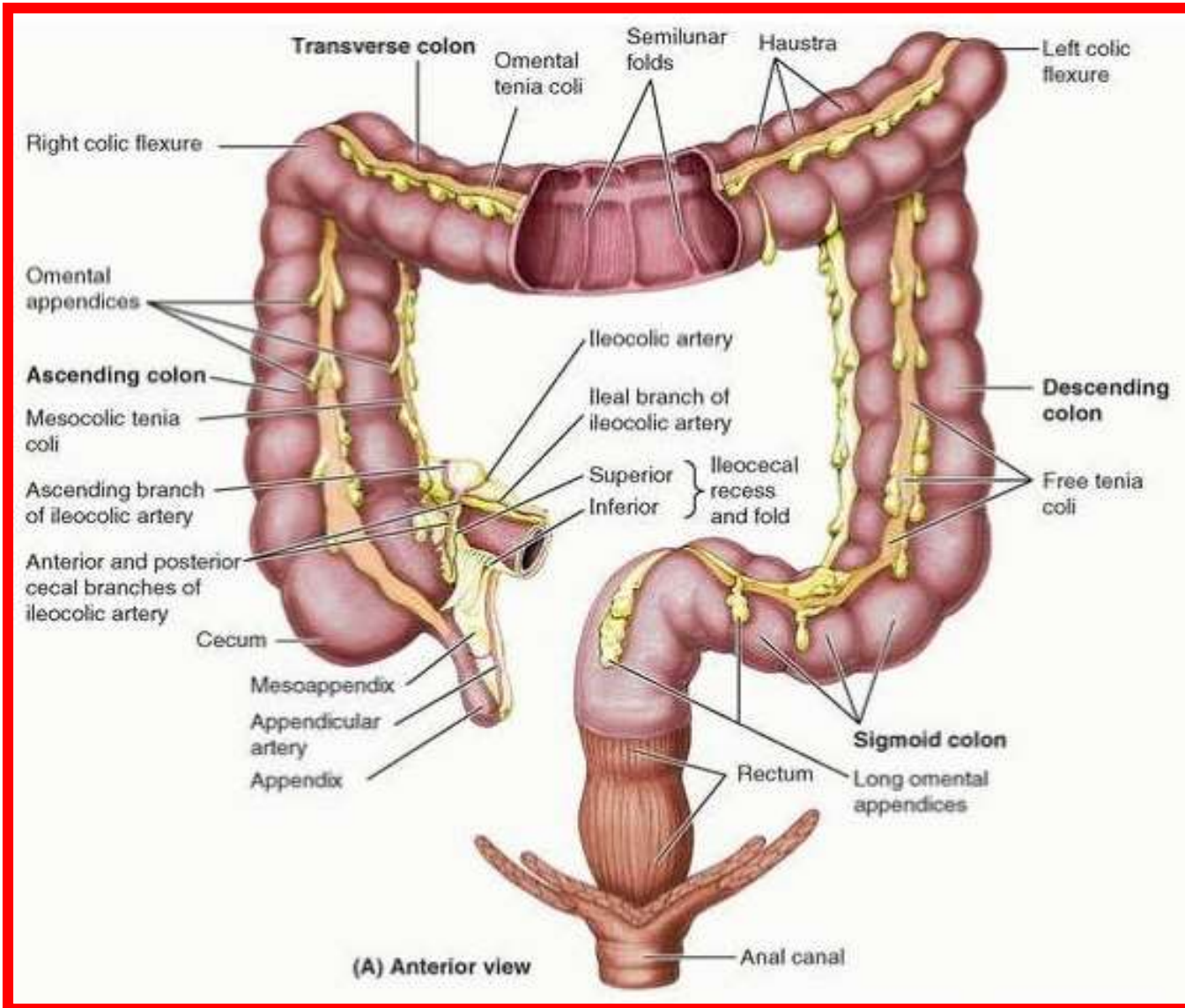
Ileal Diverticulum



Ischemia of Intestine

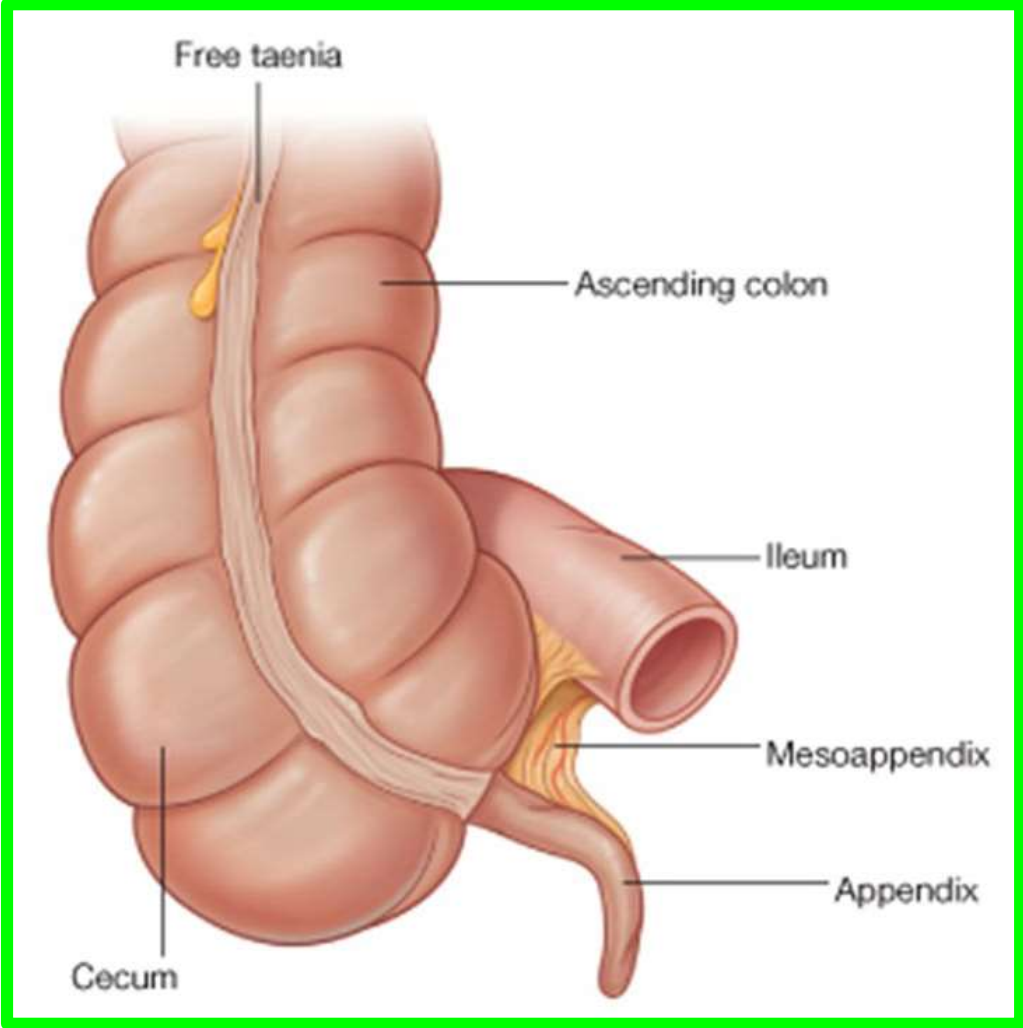


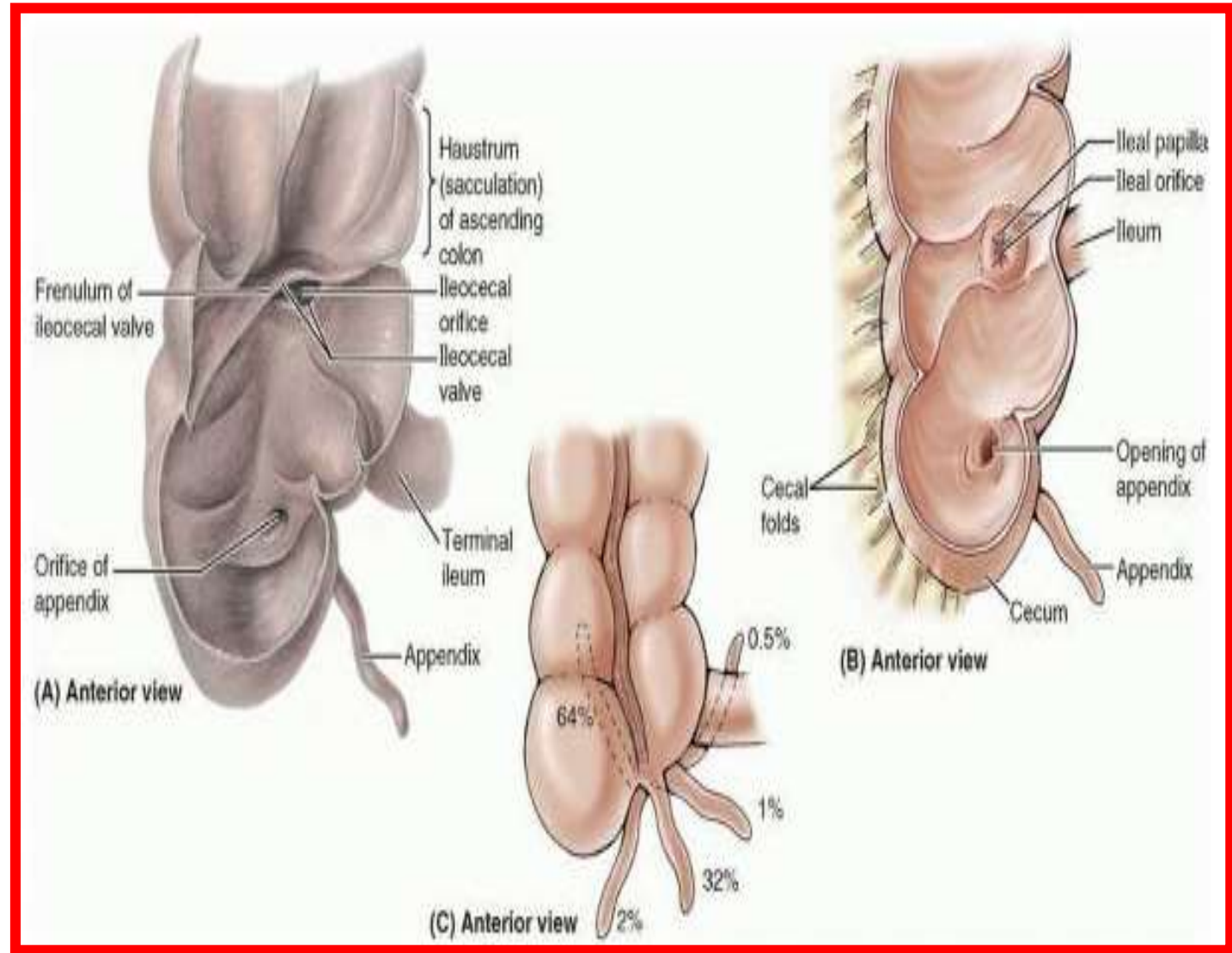
Large Intestine



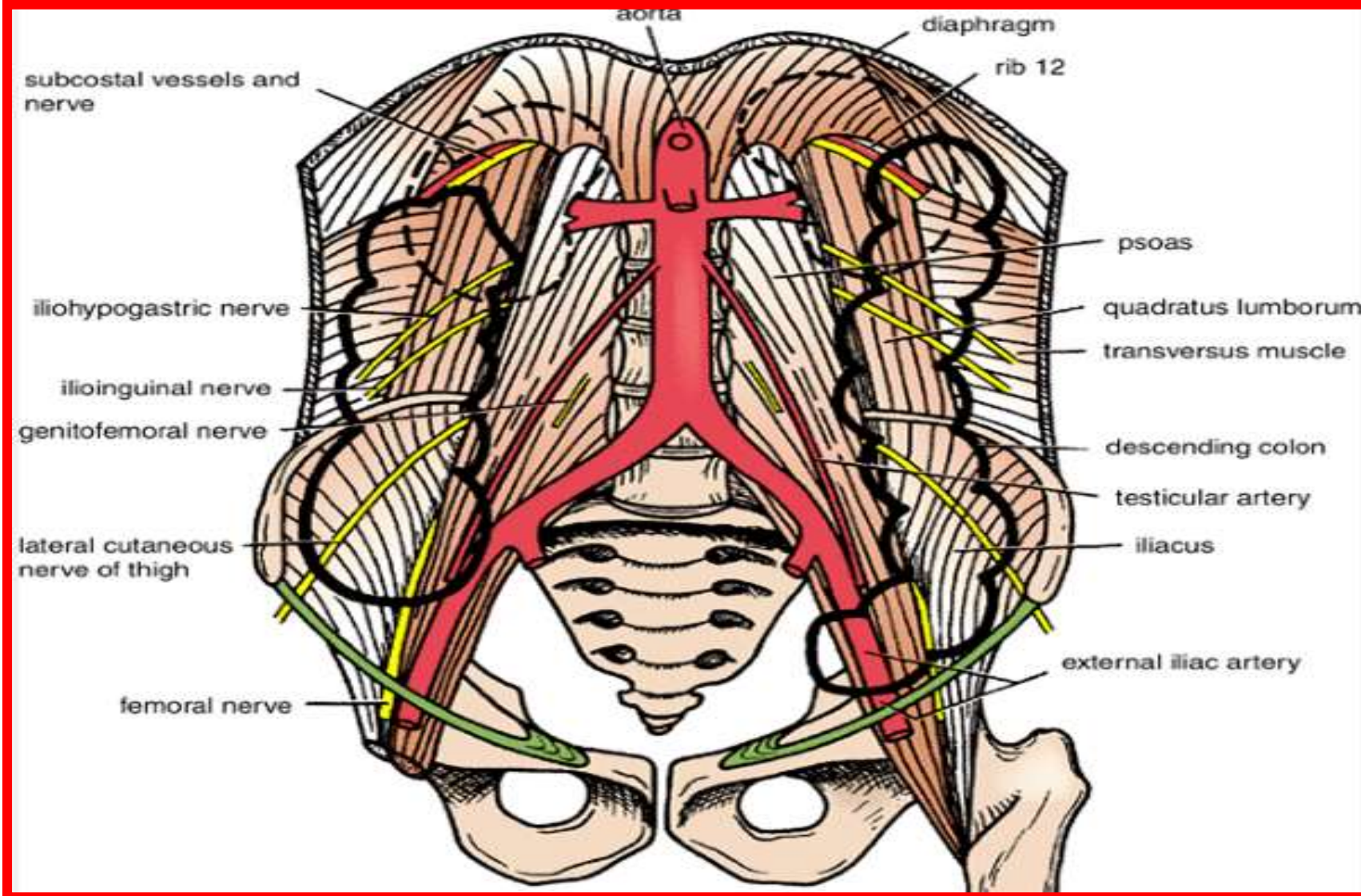
Large Intestine

Cecum



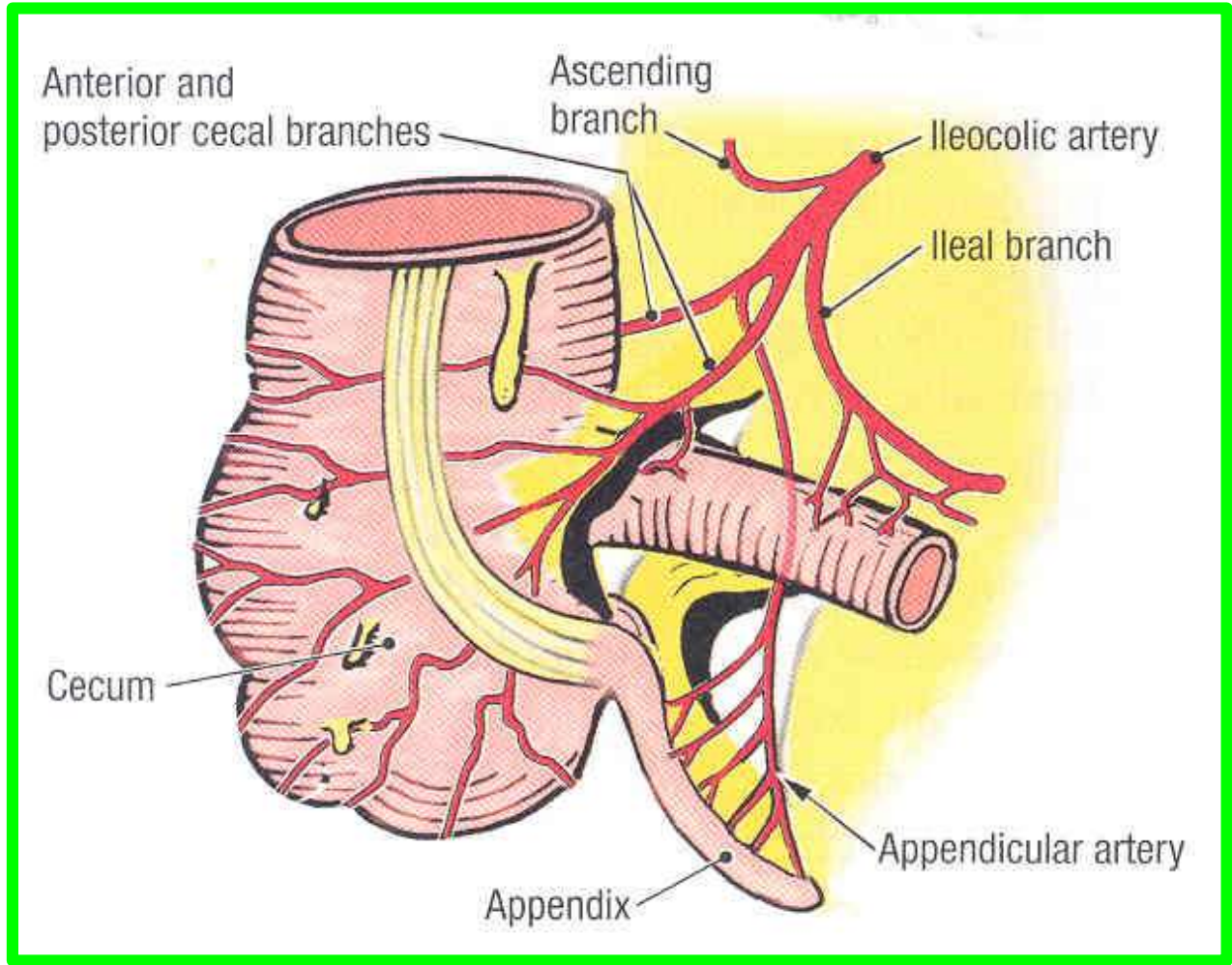


Cecum

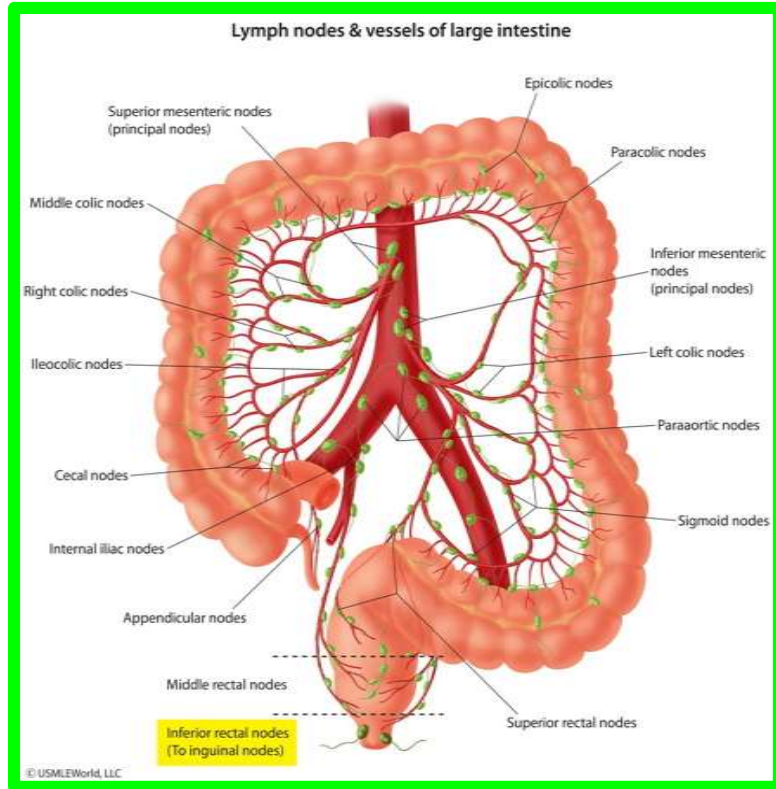
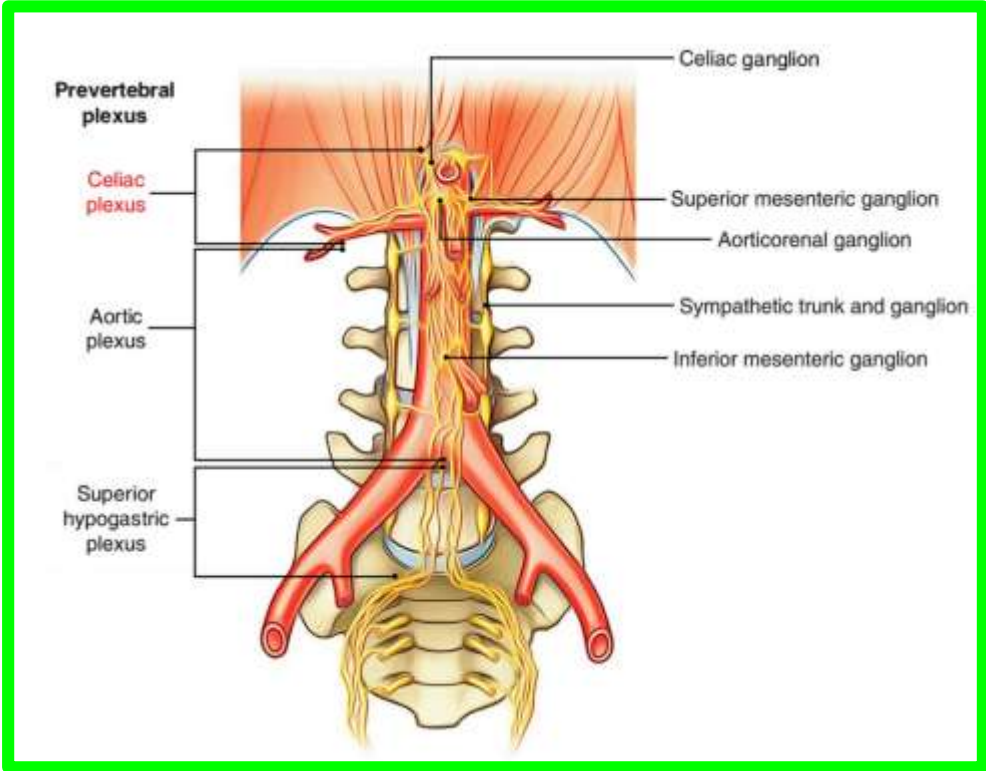


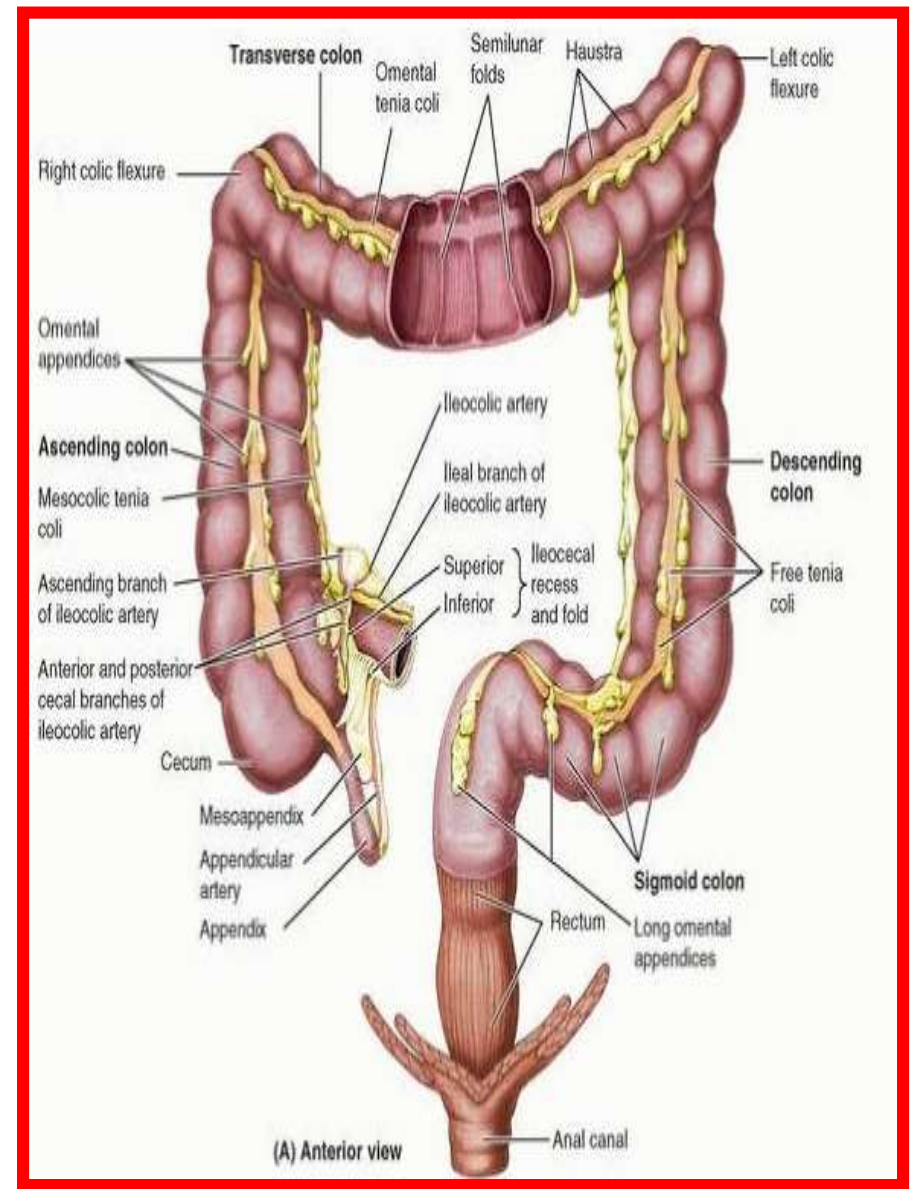
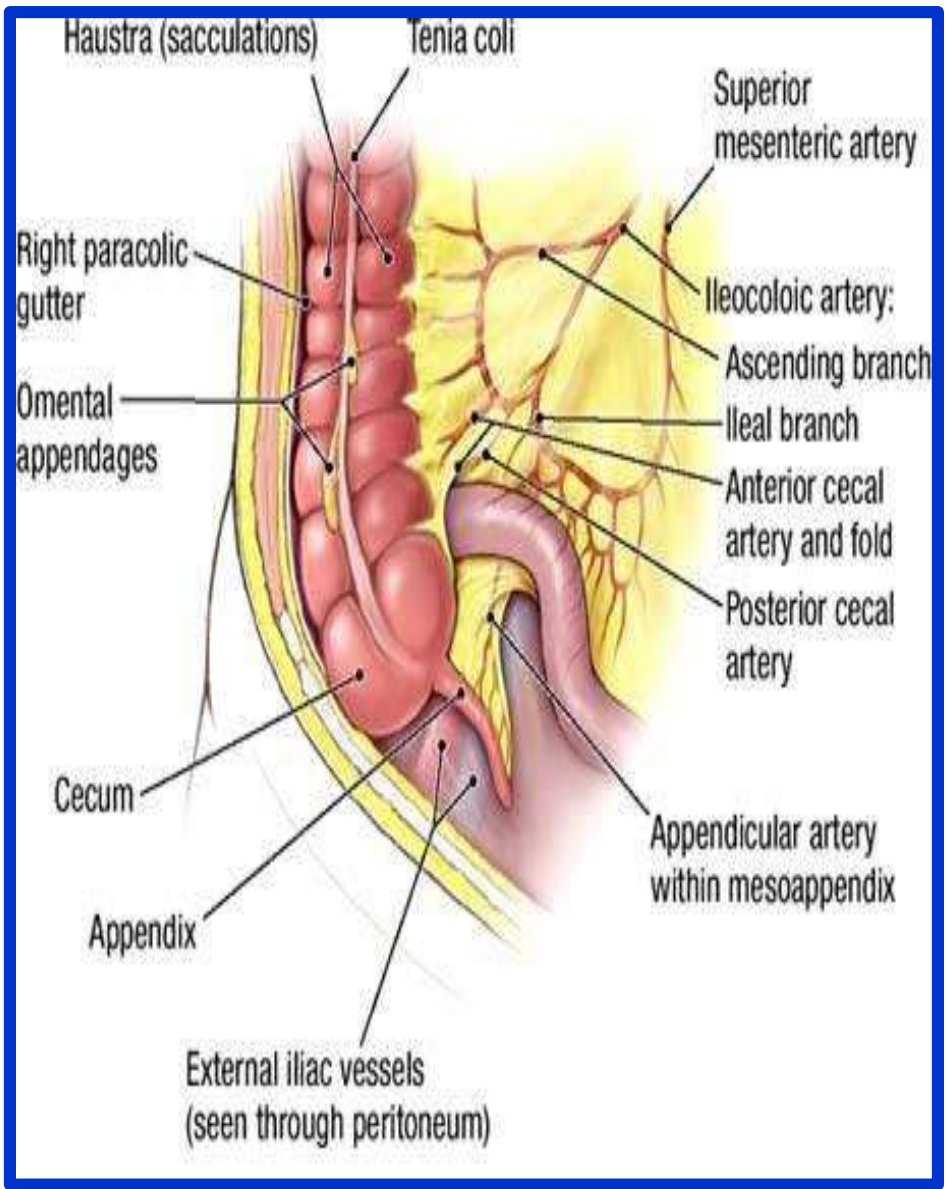
Large Intestine

Cecum

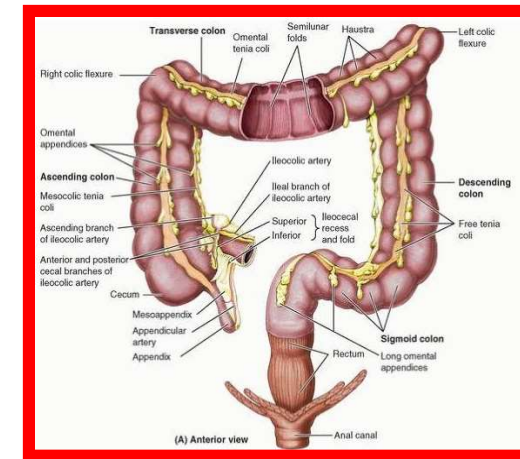
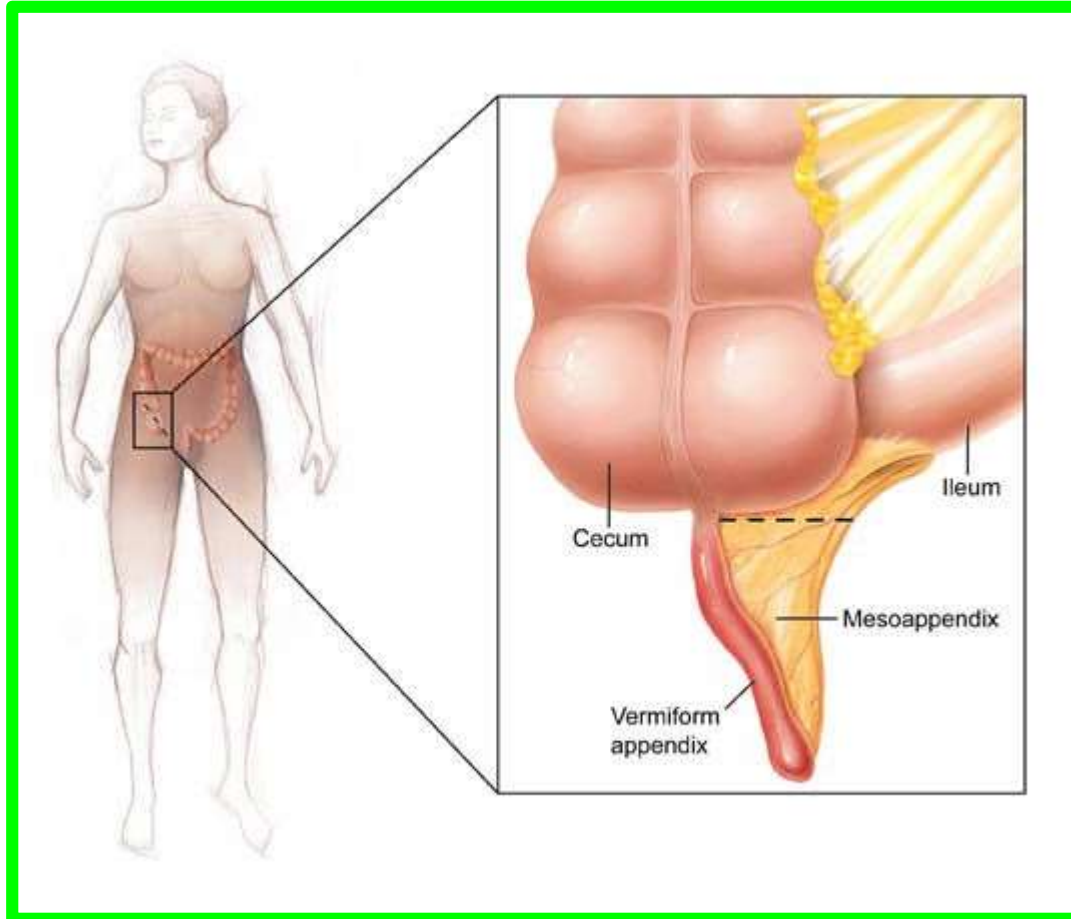


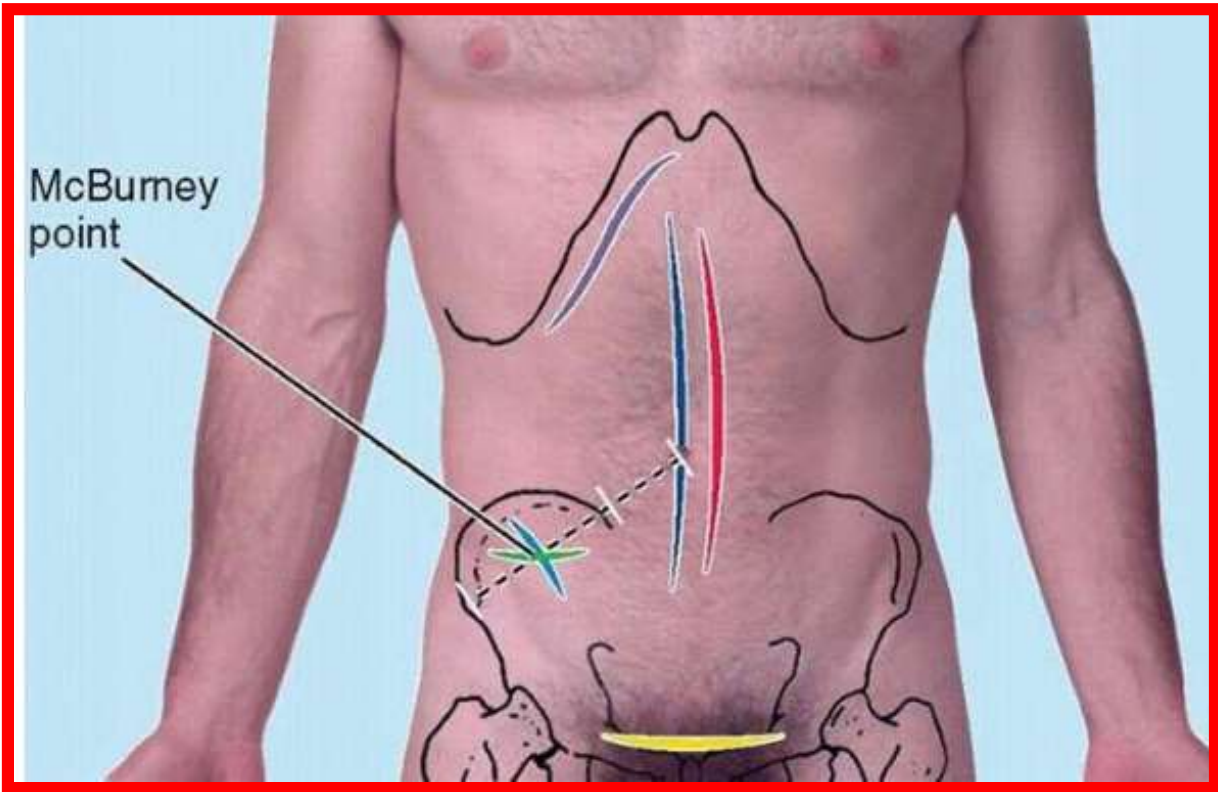
Cecum



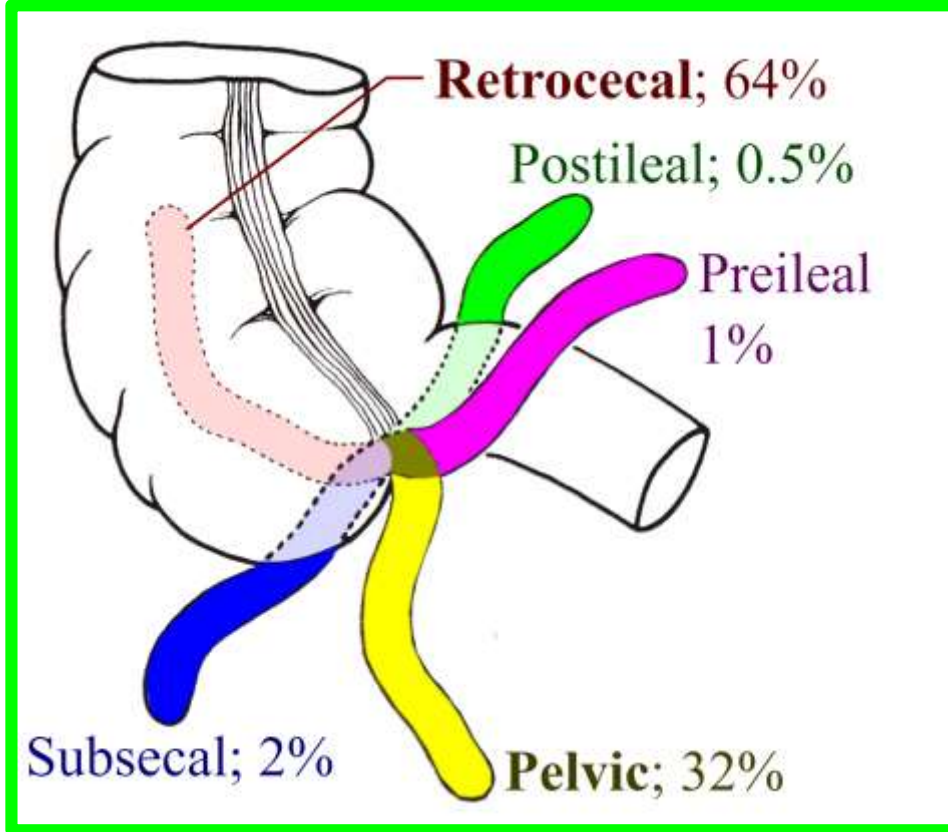


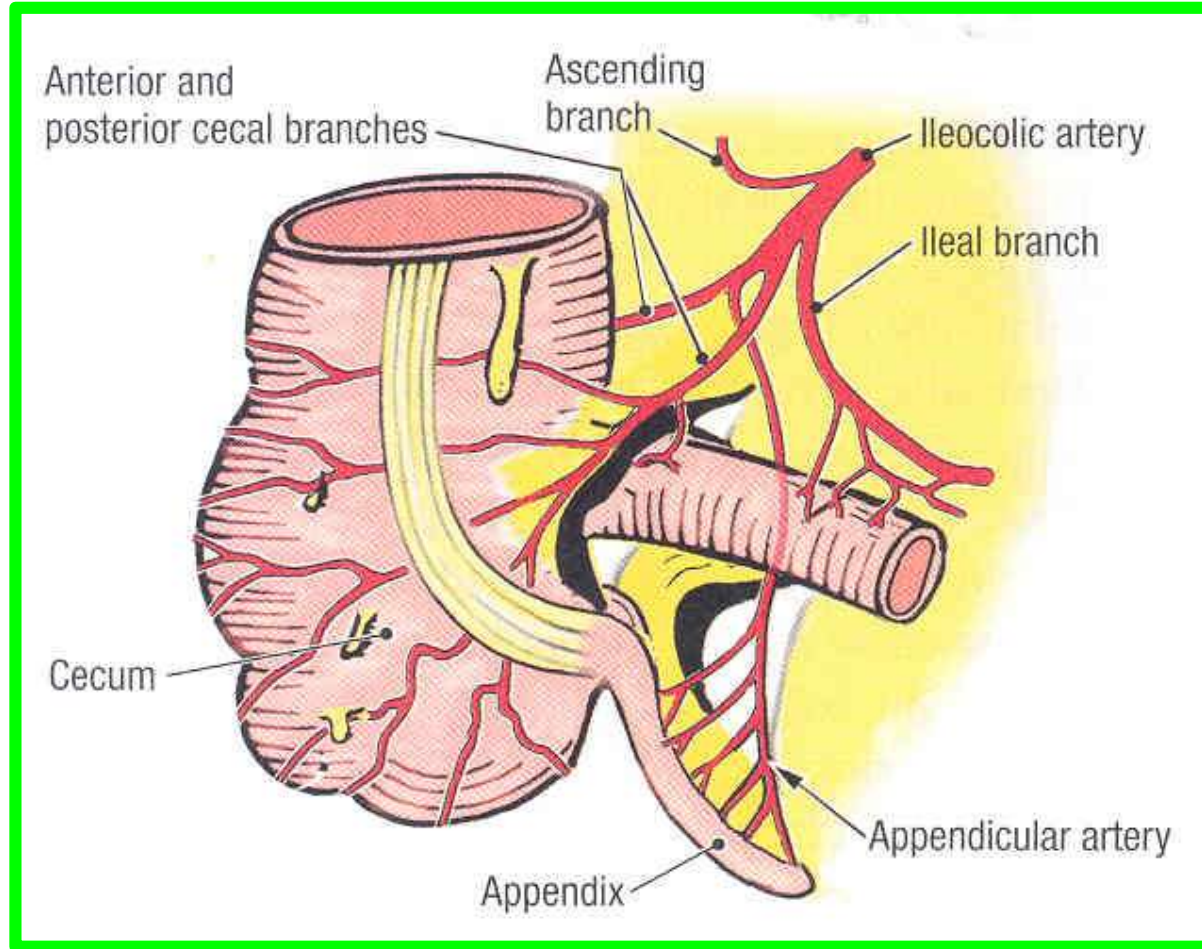
Appendix





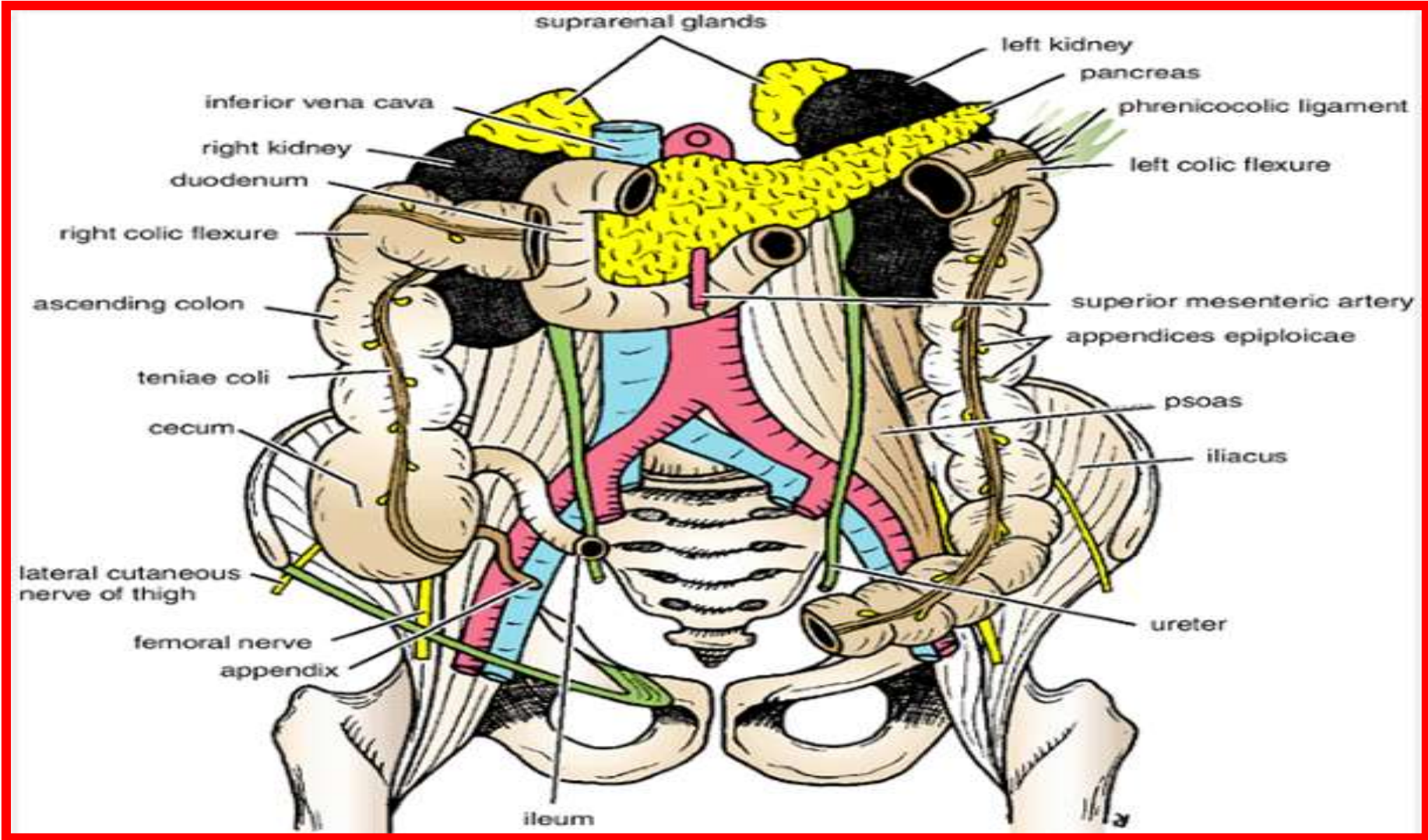
Common Positions of the Tip of the Appendix





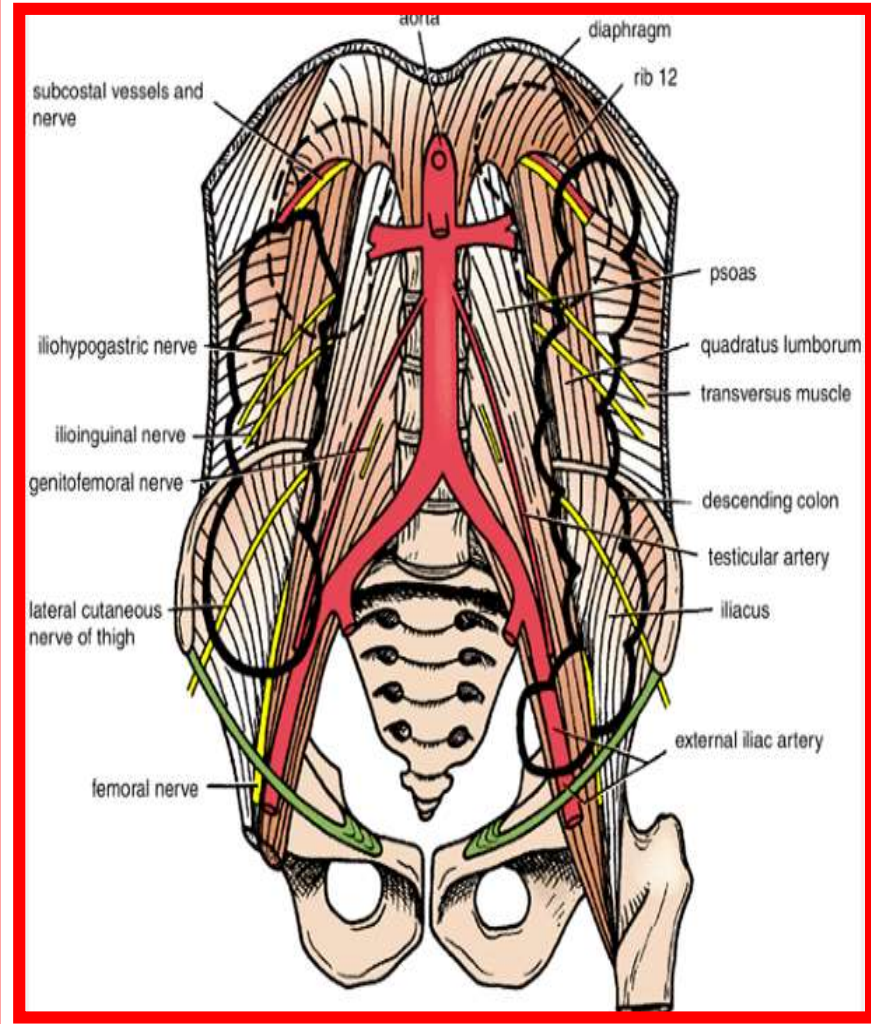
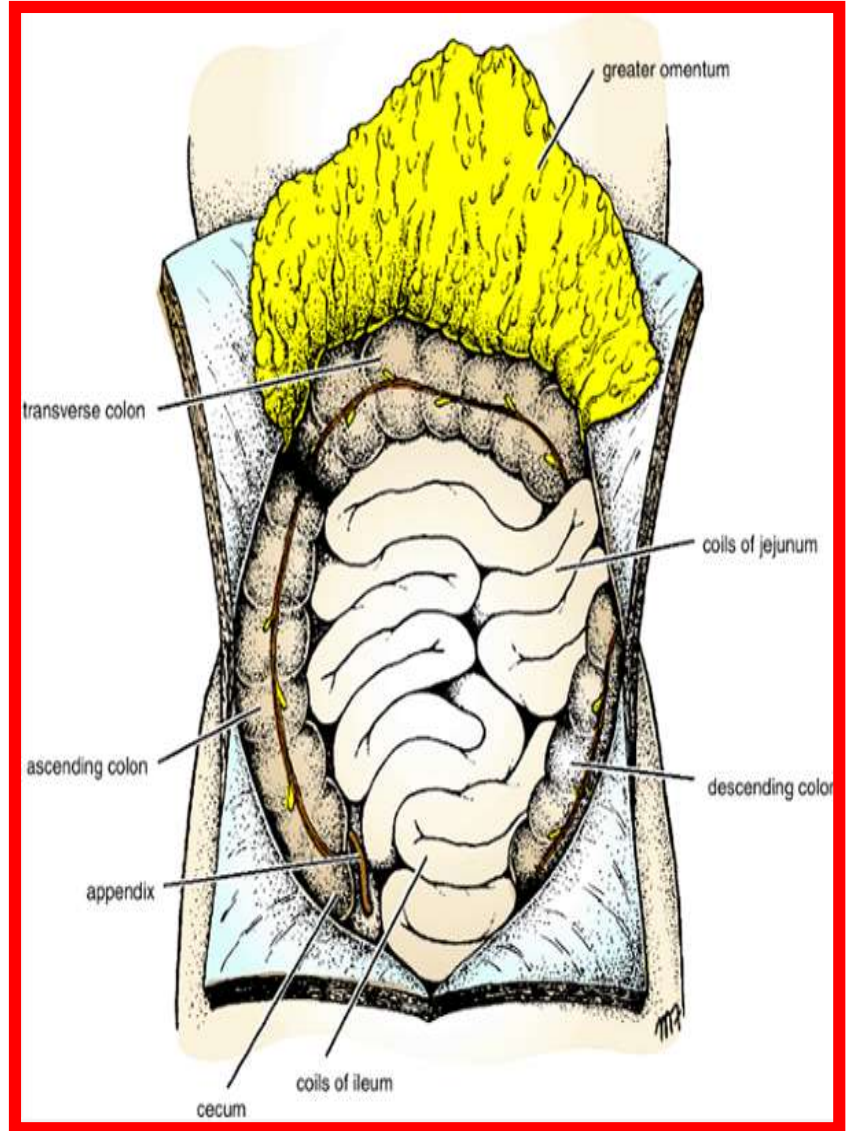
Ascending Colon

Large Intestine



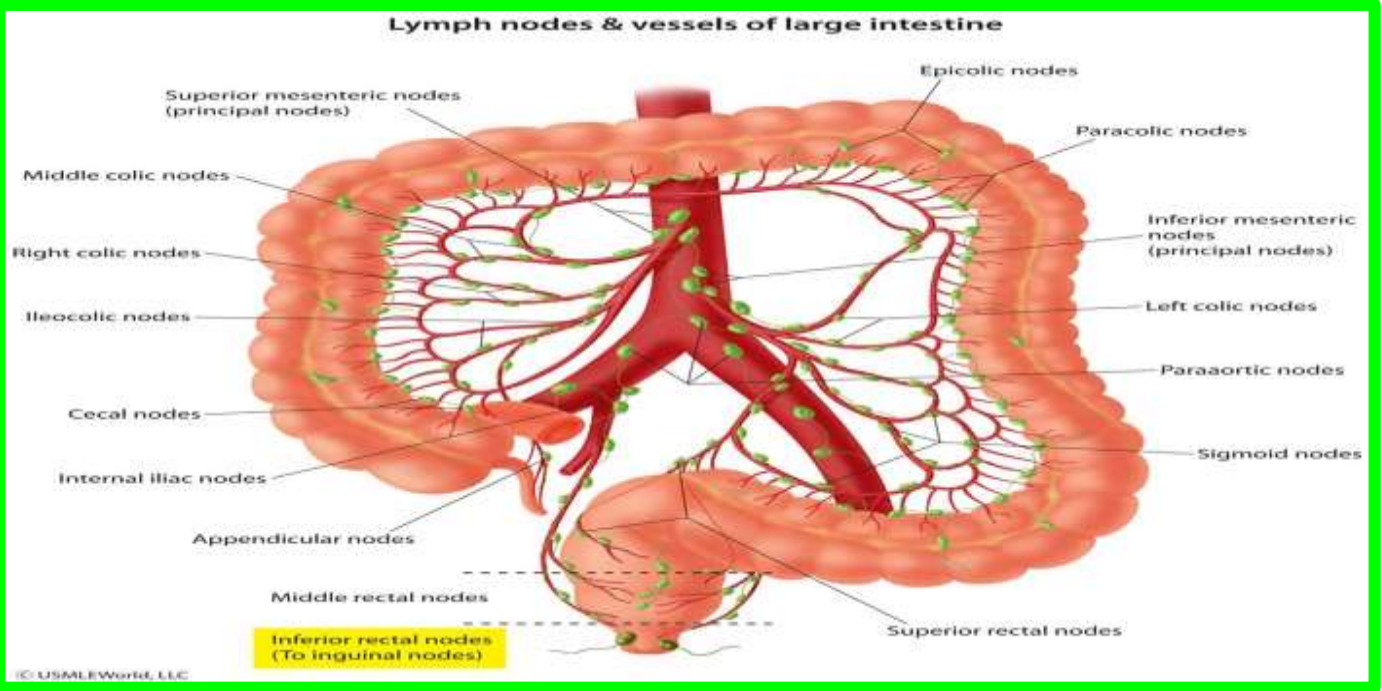
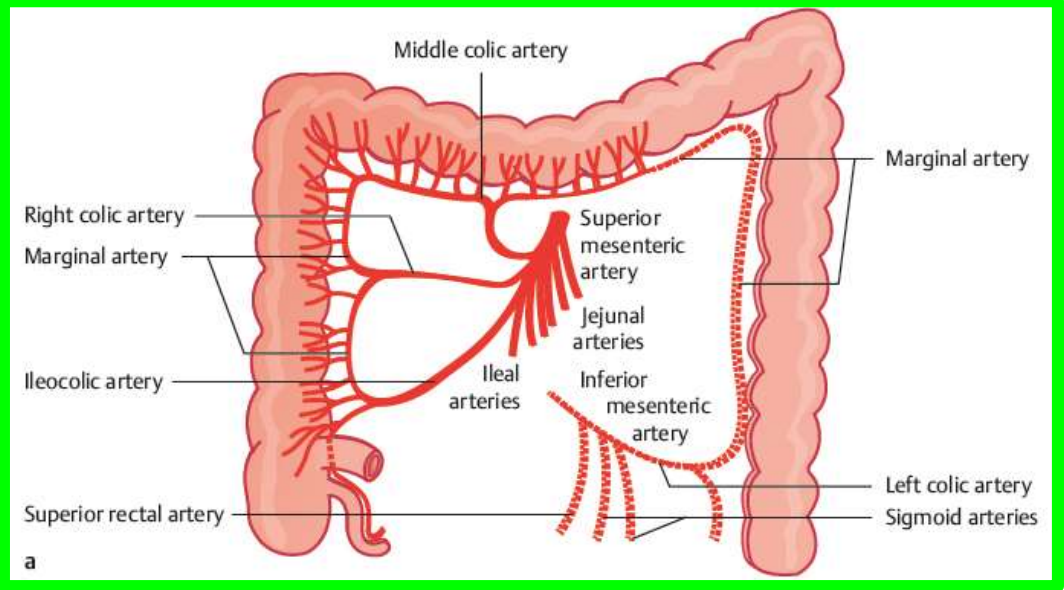
Ascending Colon

Large Intestine

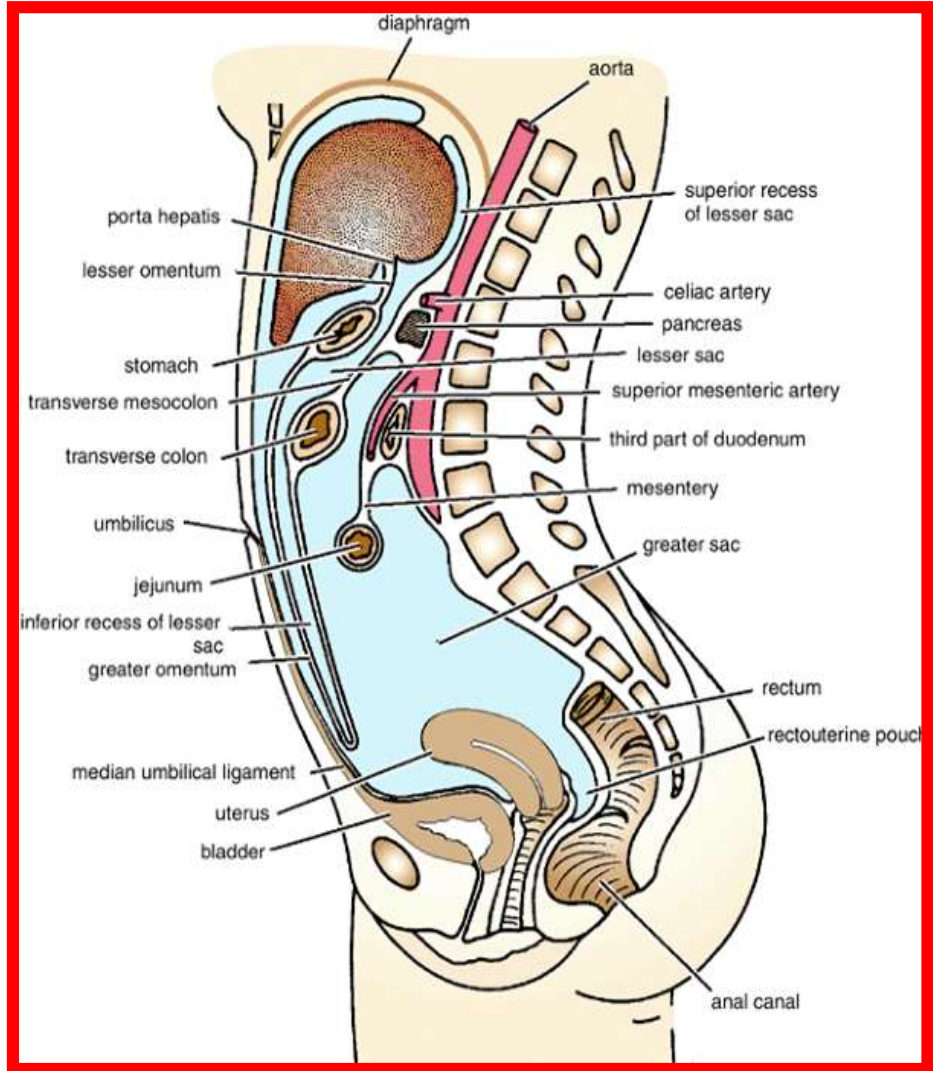
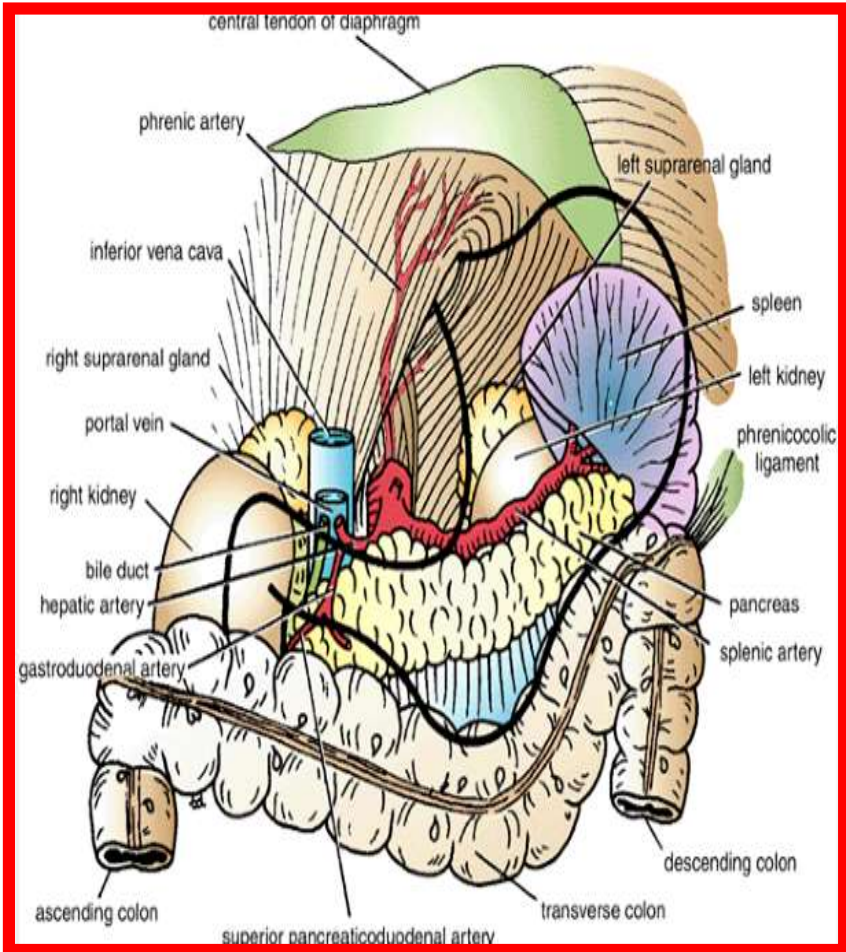


Ascending Colon

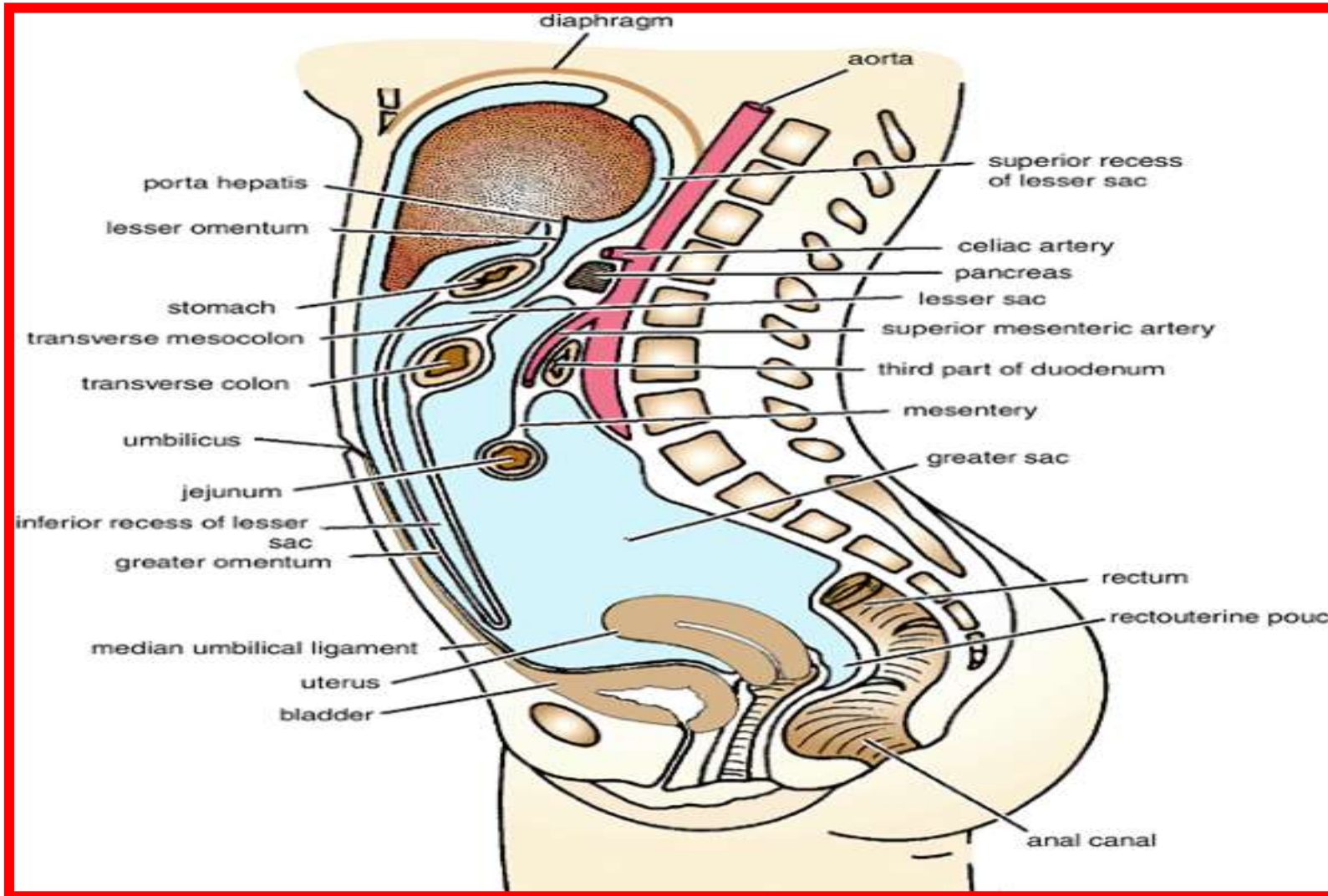
Dr Aiman Q AL Maathidy
Sunday 10 April 2022



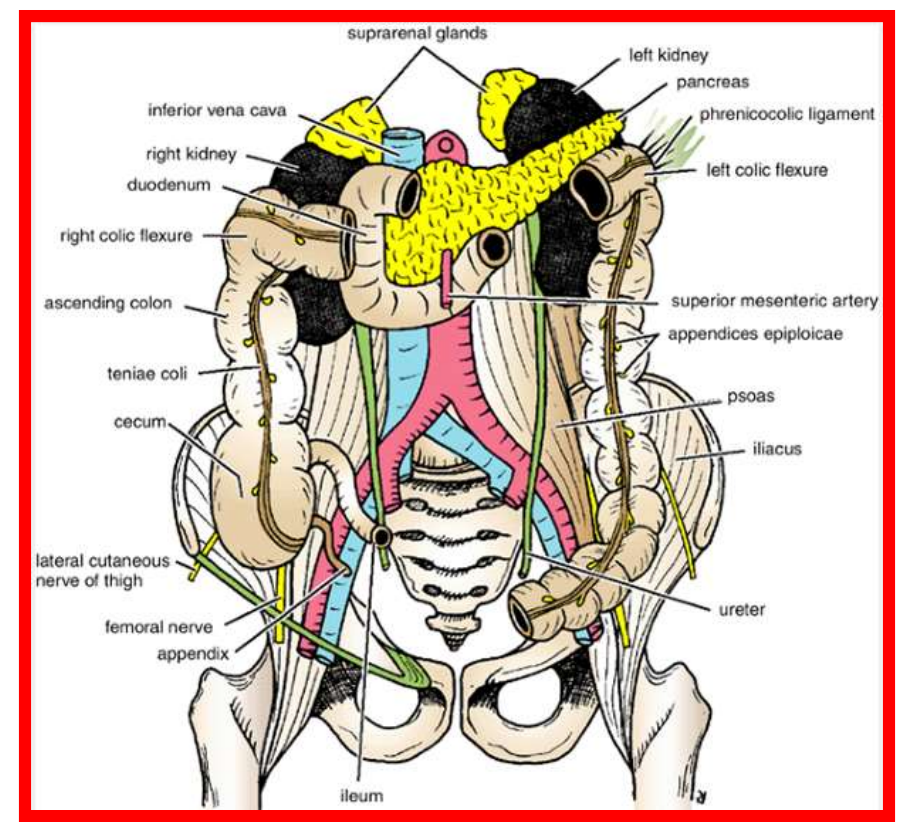
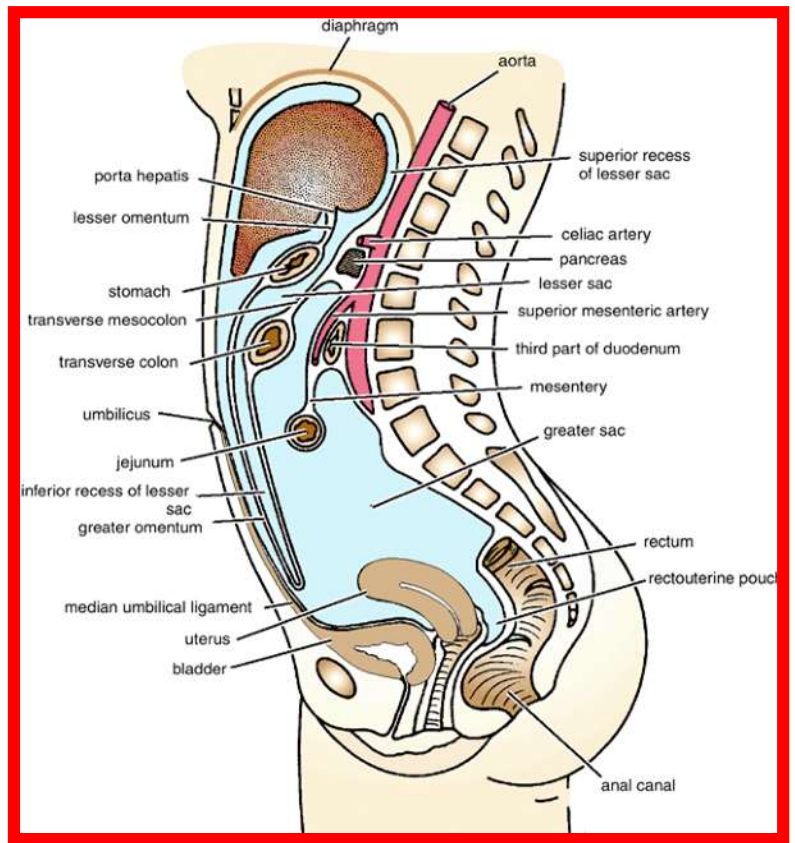
Transverse Colon



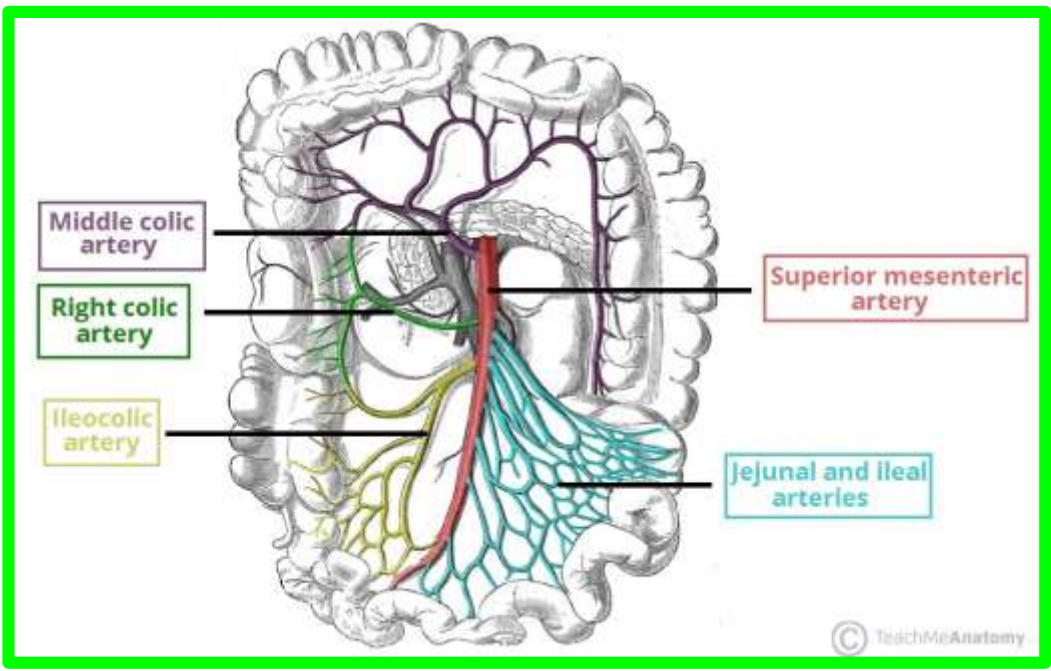
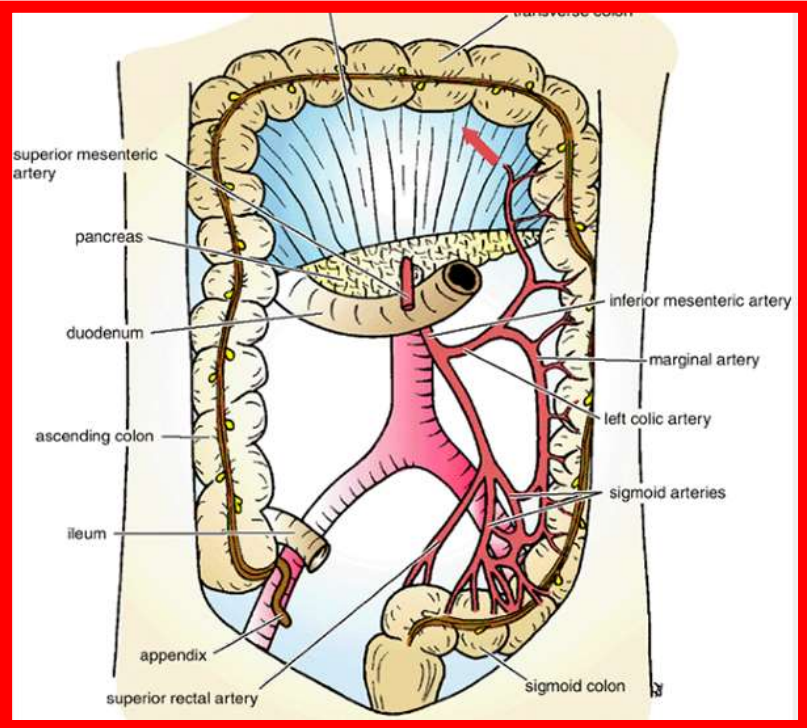
Transverse Colon

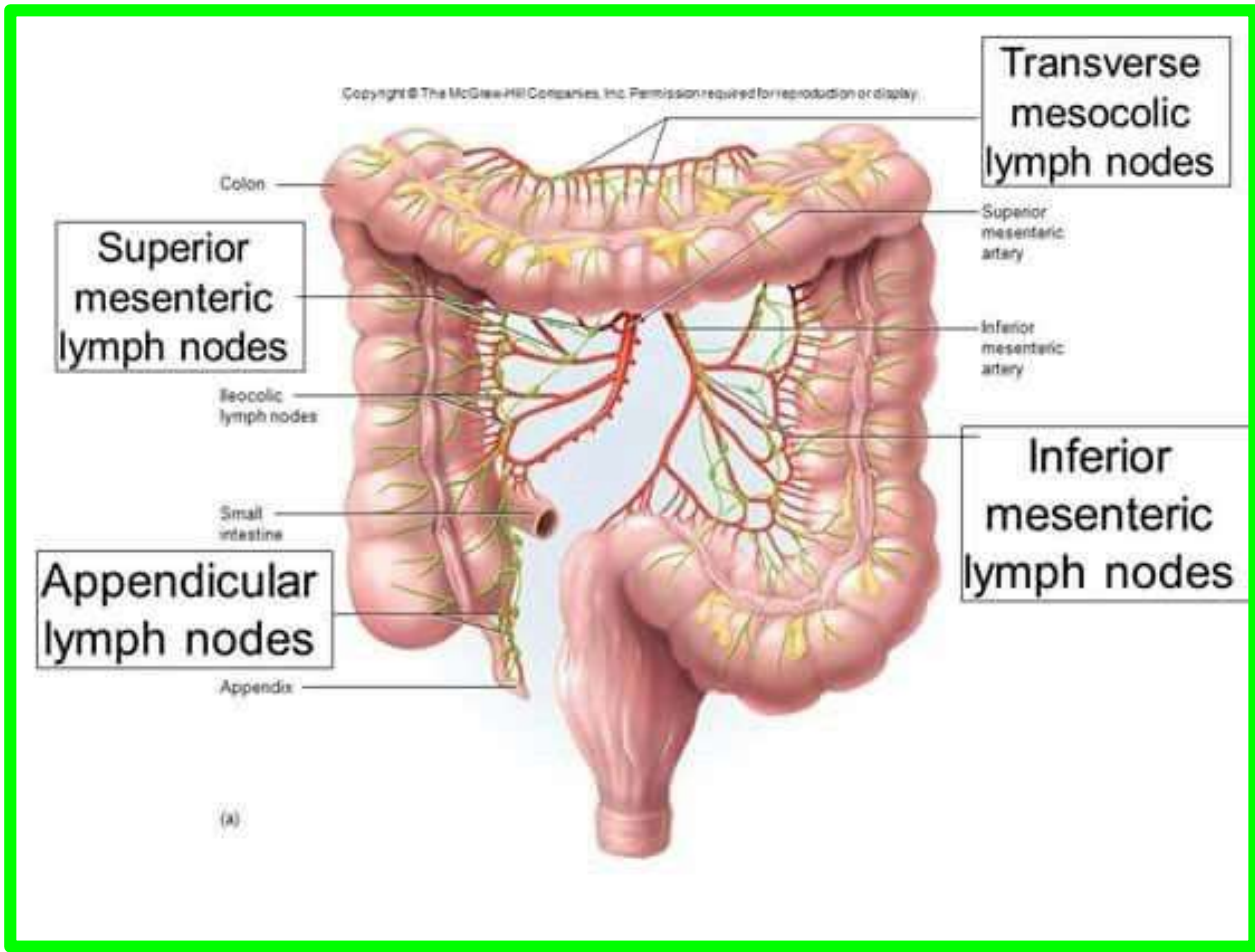


Transverse Colon

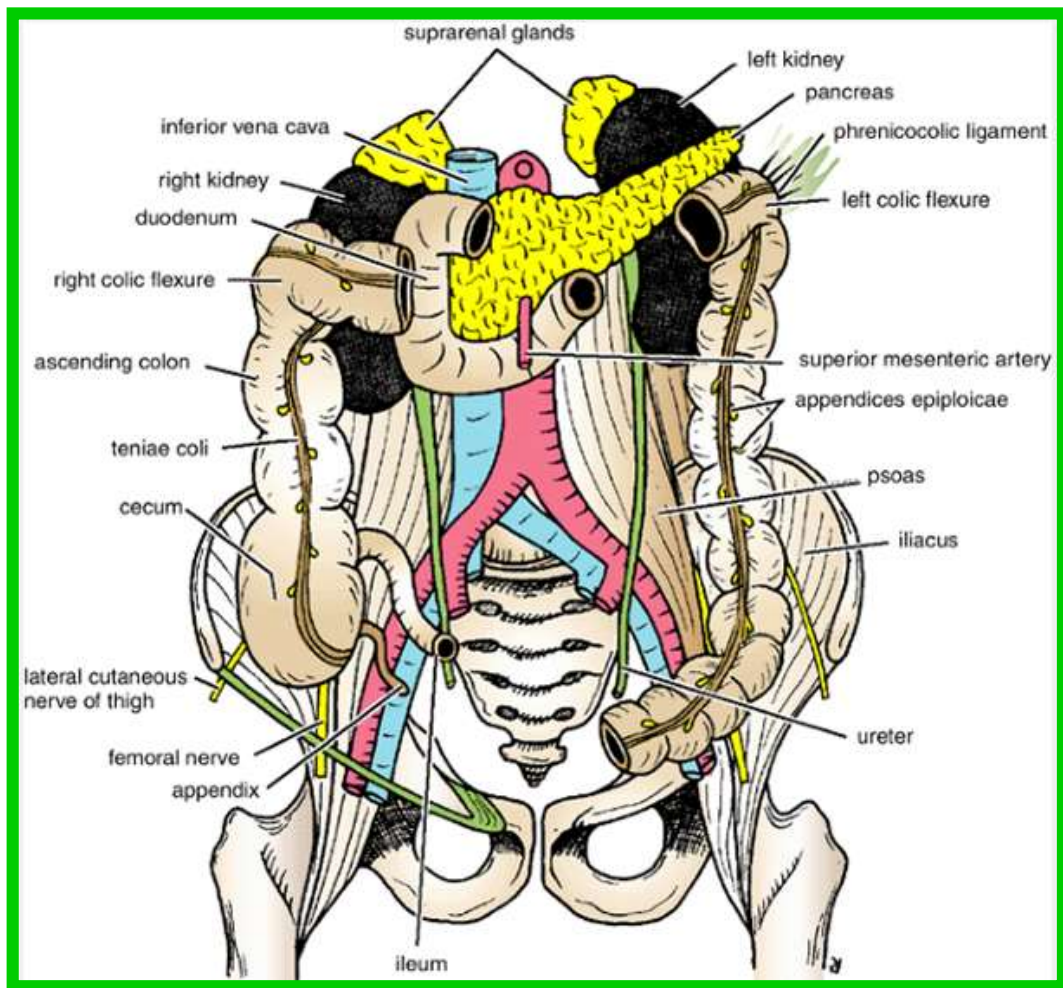


Transverse Colon

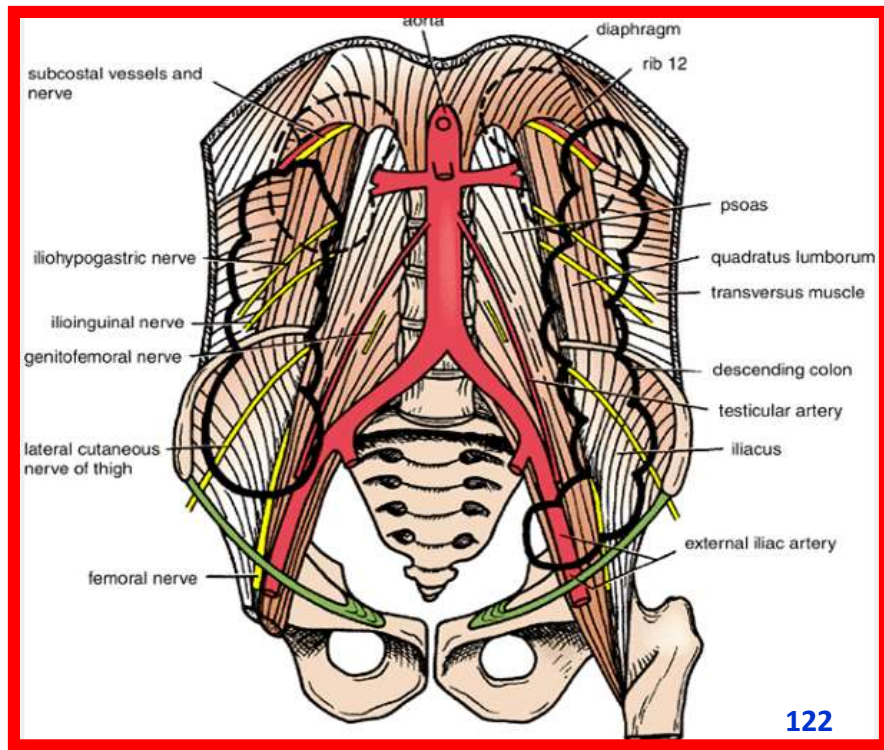
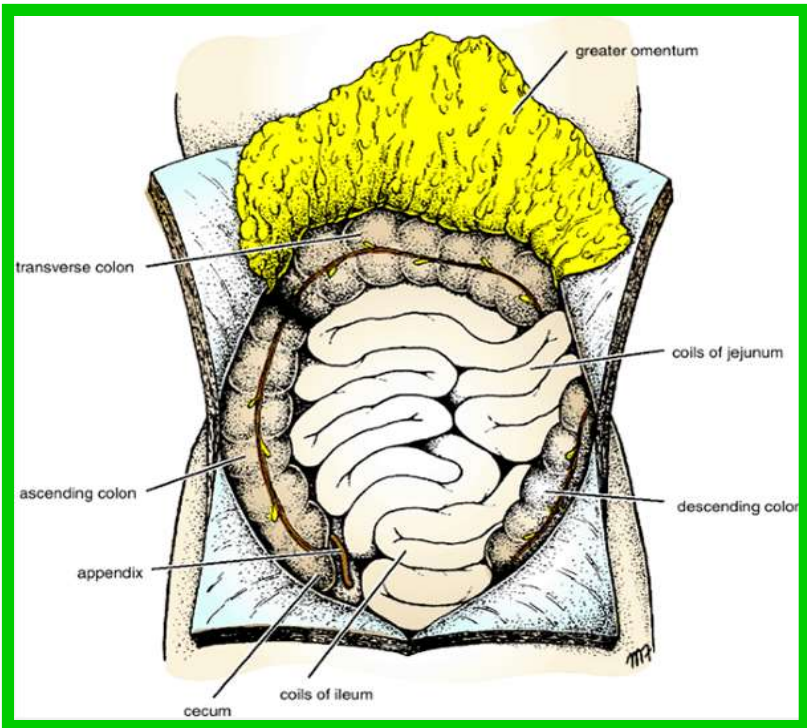




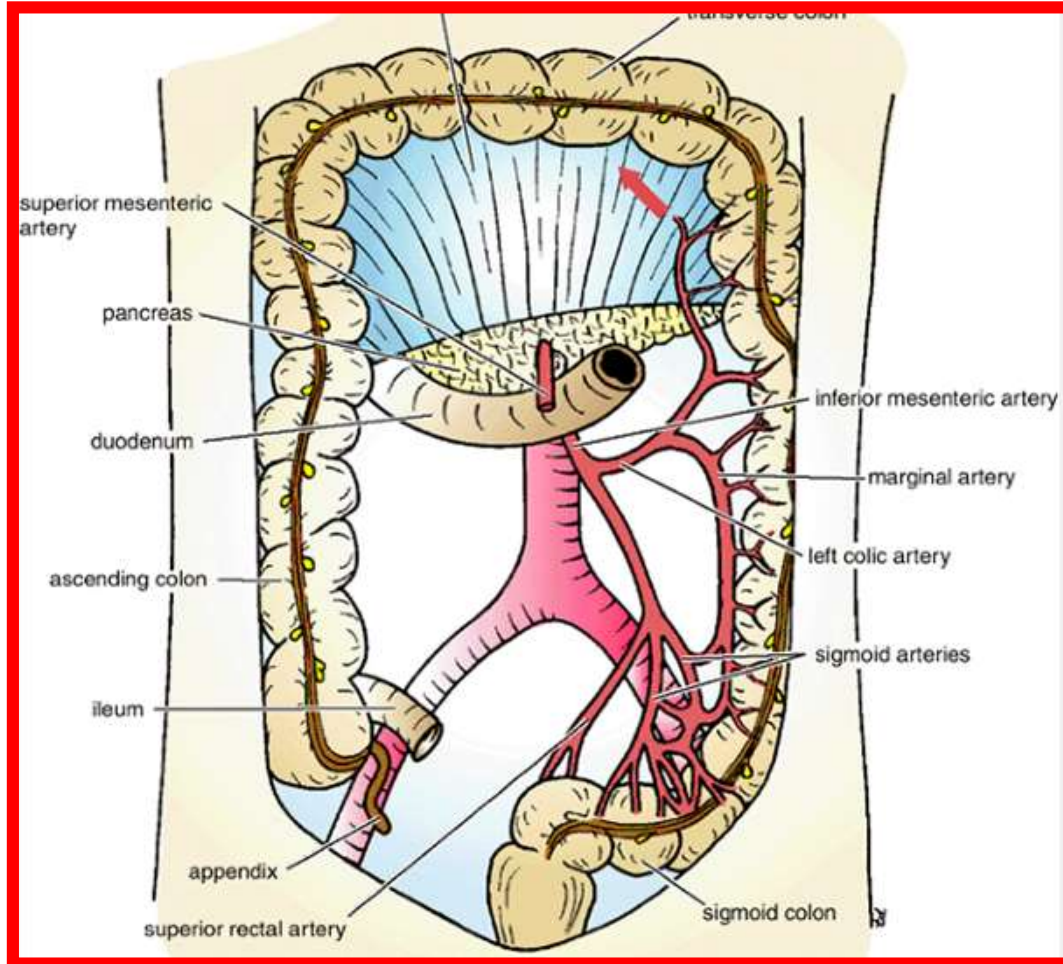
Descending Colon



Descending Colon



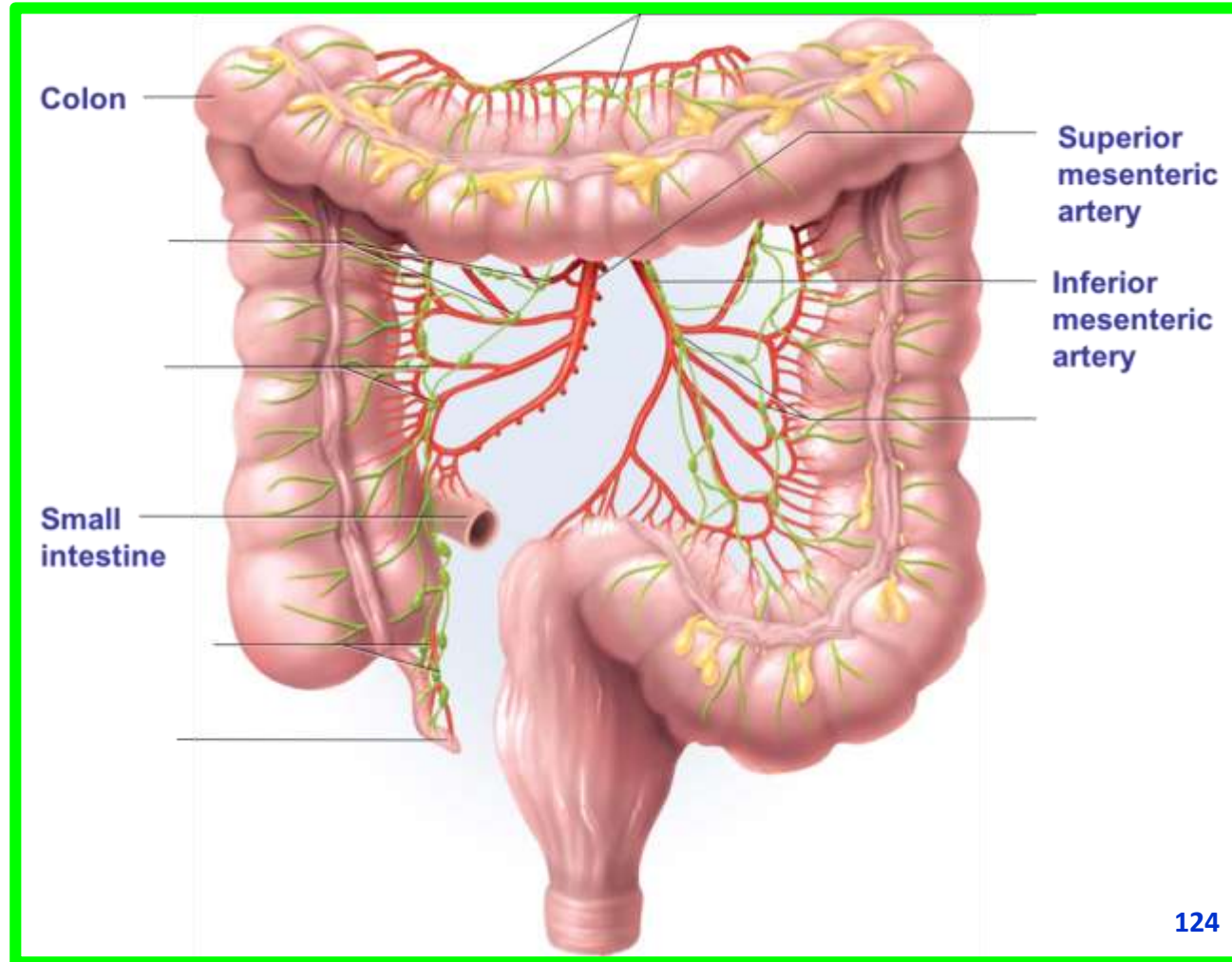
Descending Colon



Descending Colon

Lymph Drainage

Lymph drains into the colic lymph nodes and the **inferior mesenteric nodes** around the origin of the **inferior mesenteric artery**.

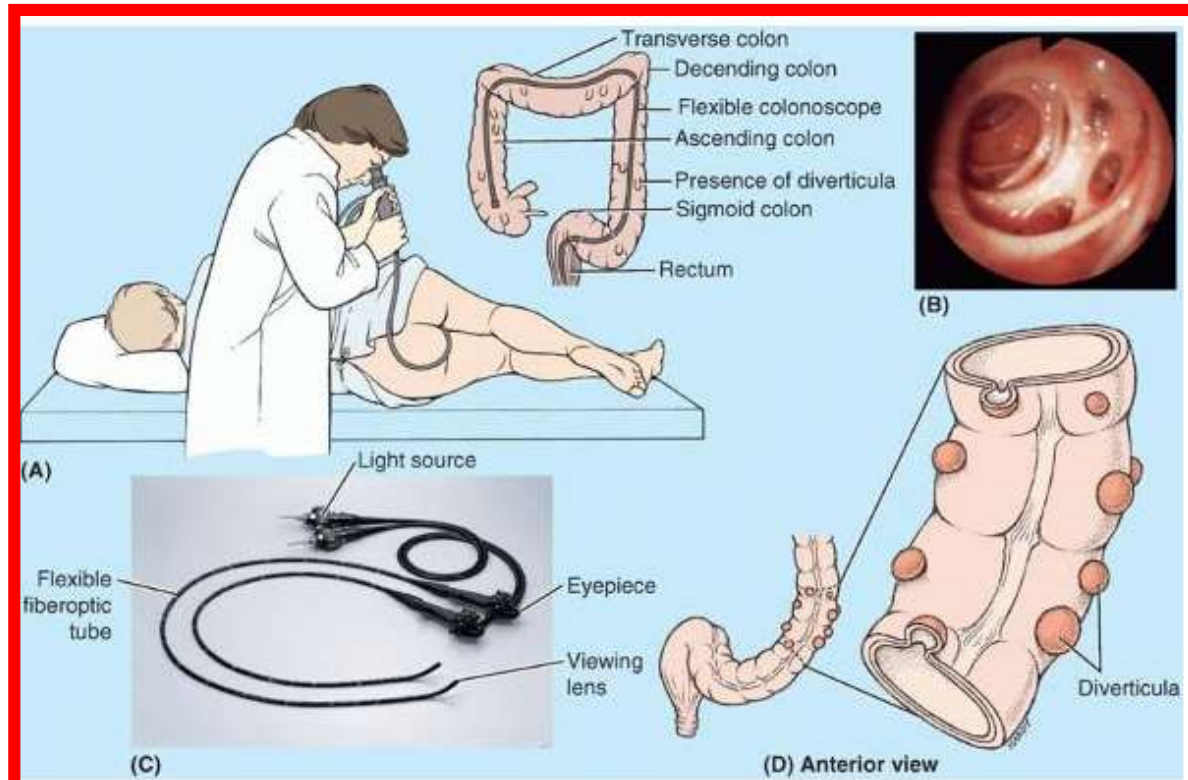


Examination of large intestine

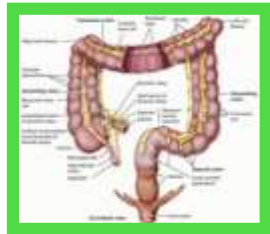
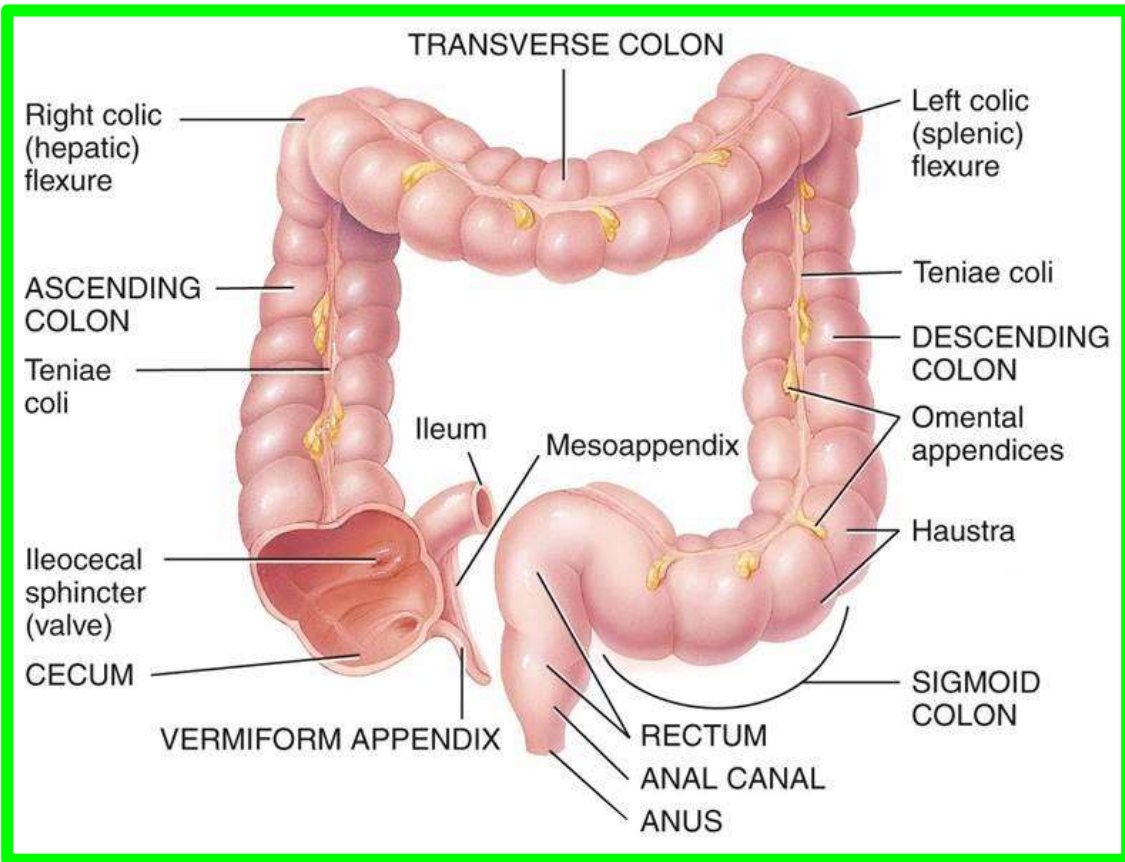
Dr Aiman Q AL Maathidy

Sunday 10 April 2022

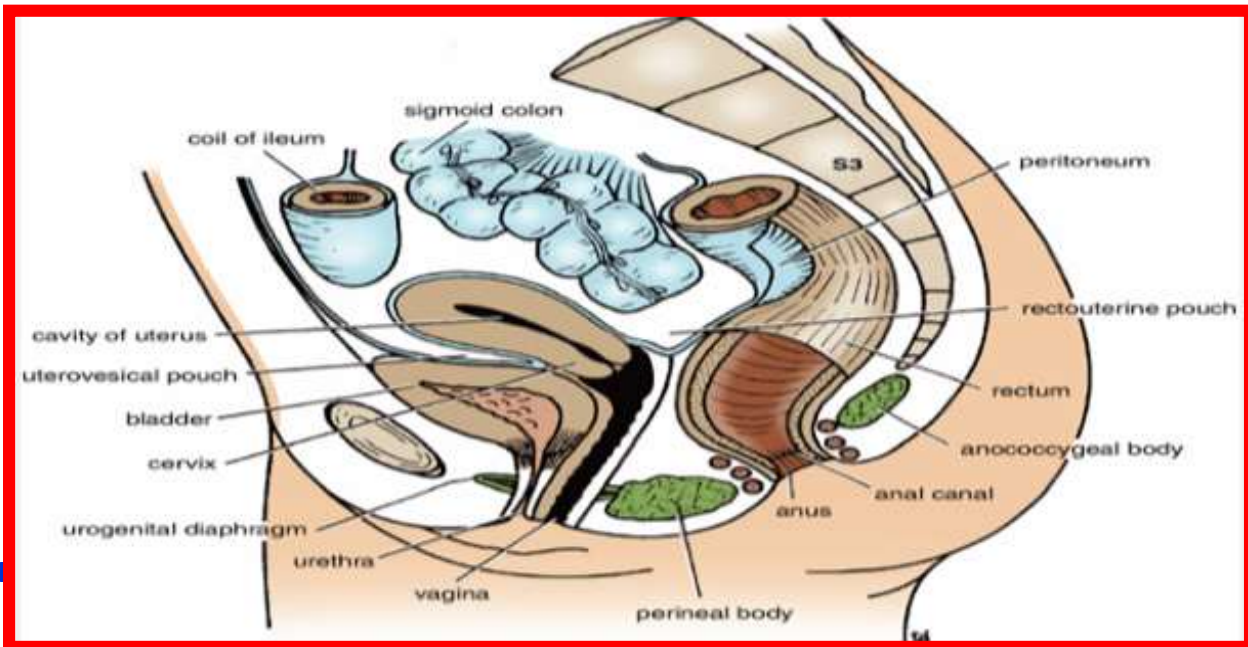
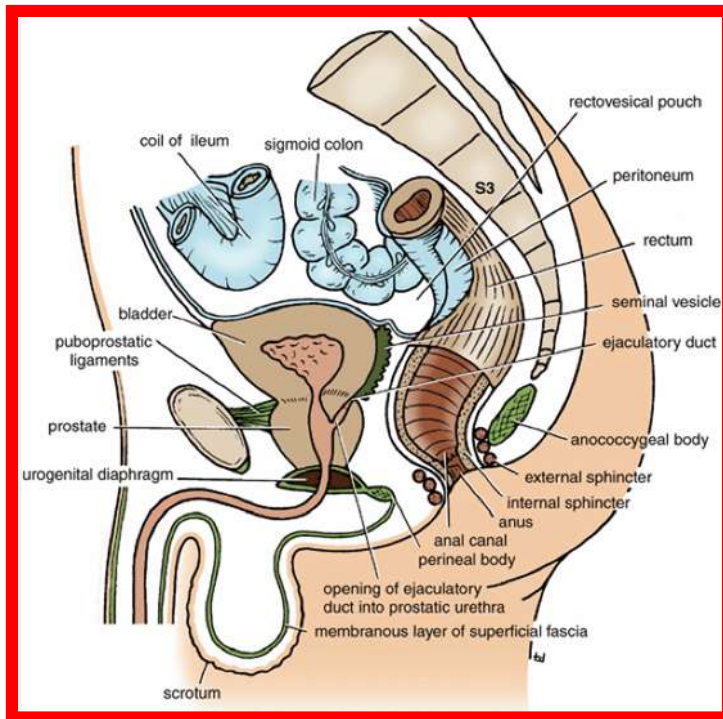
The interior of the colon can be observed and photographed in a procedure called colonoscopy or coloscopy, using a long, flexible fiberoptic endoscope (**colonoscope**) inserted into the colon through the anus and rectum. Small instruments can be passed through the colonoscope and used to facilitate minor operative procedures, such as biopsies or removal of polyps.



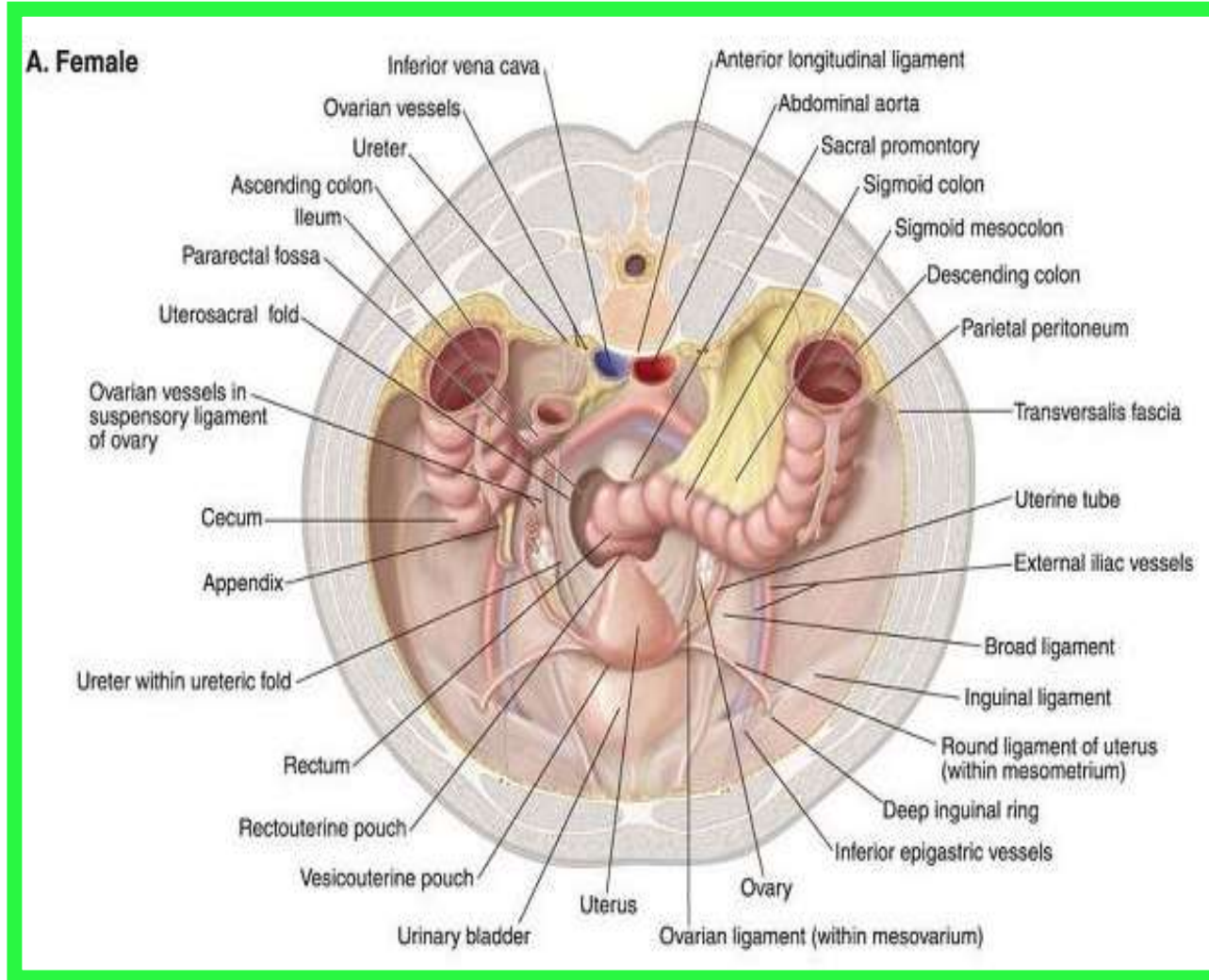
Sigmoid Colon



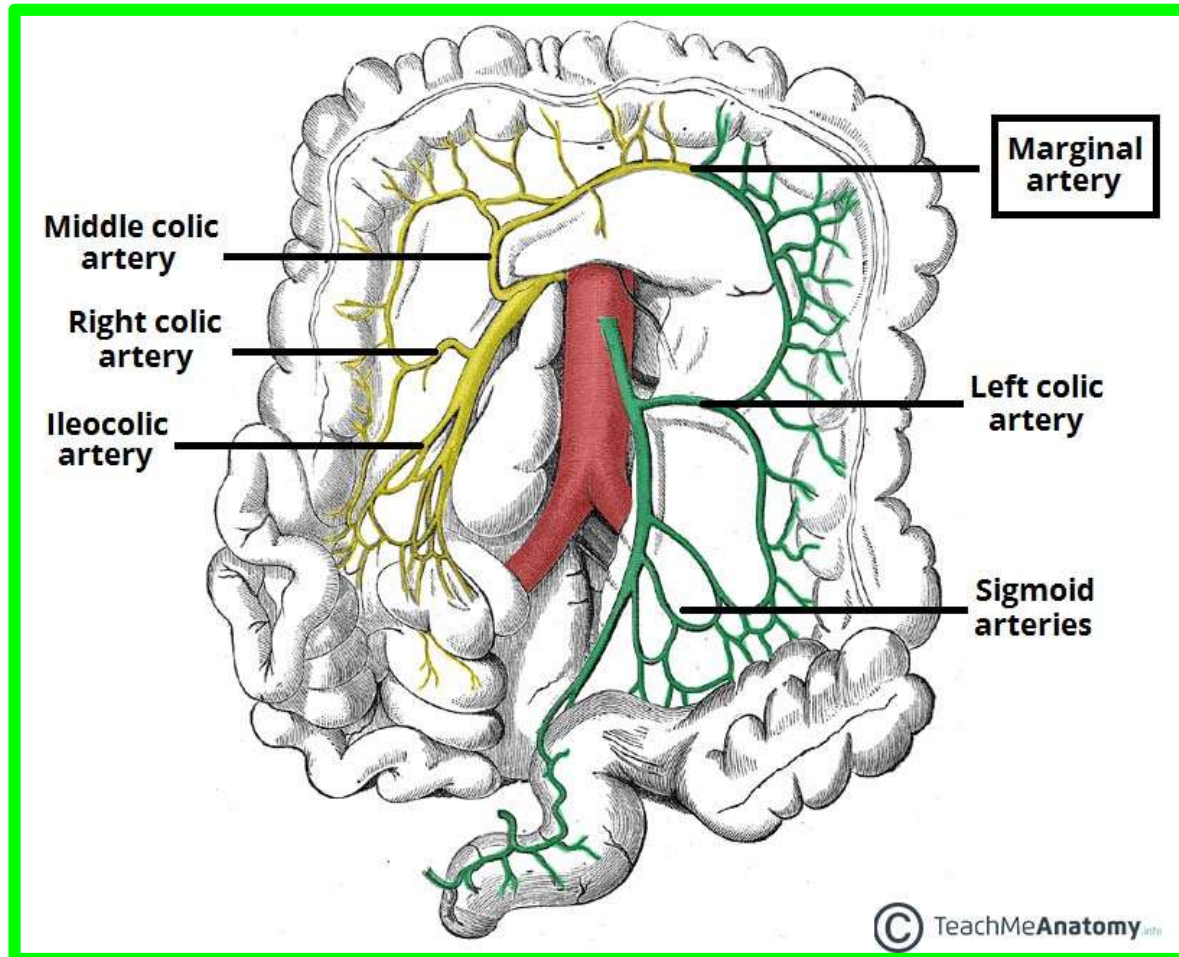
Sigmoid Colon



Sigmoid Colon

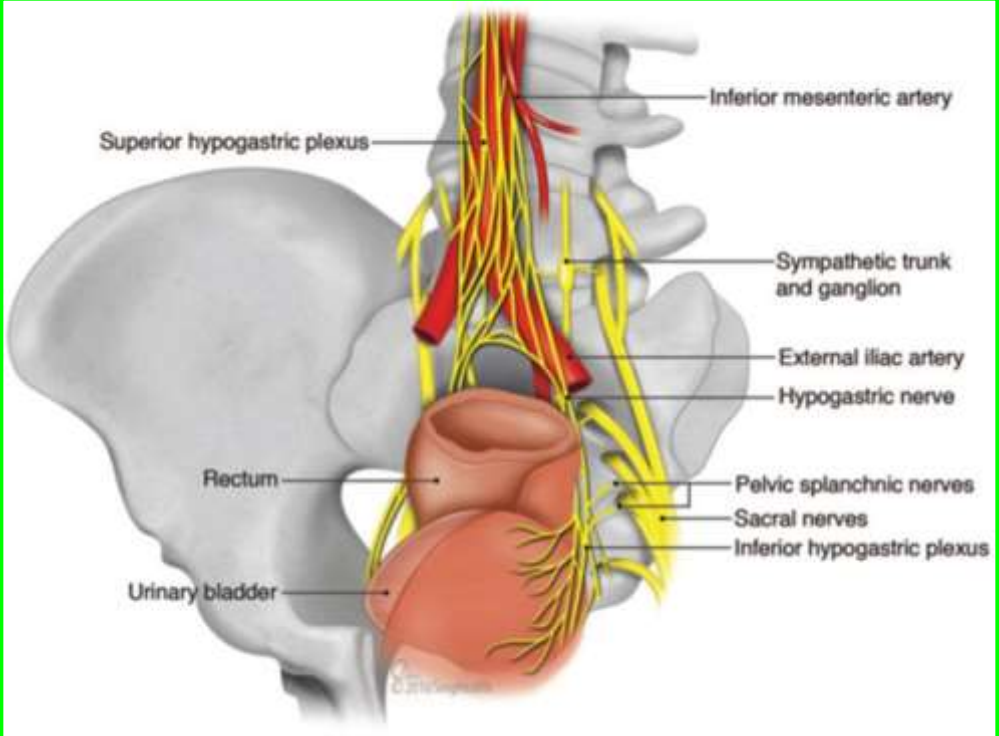
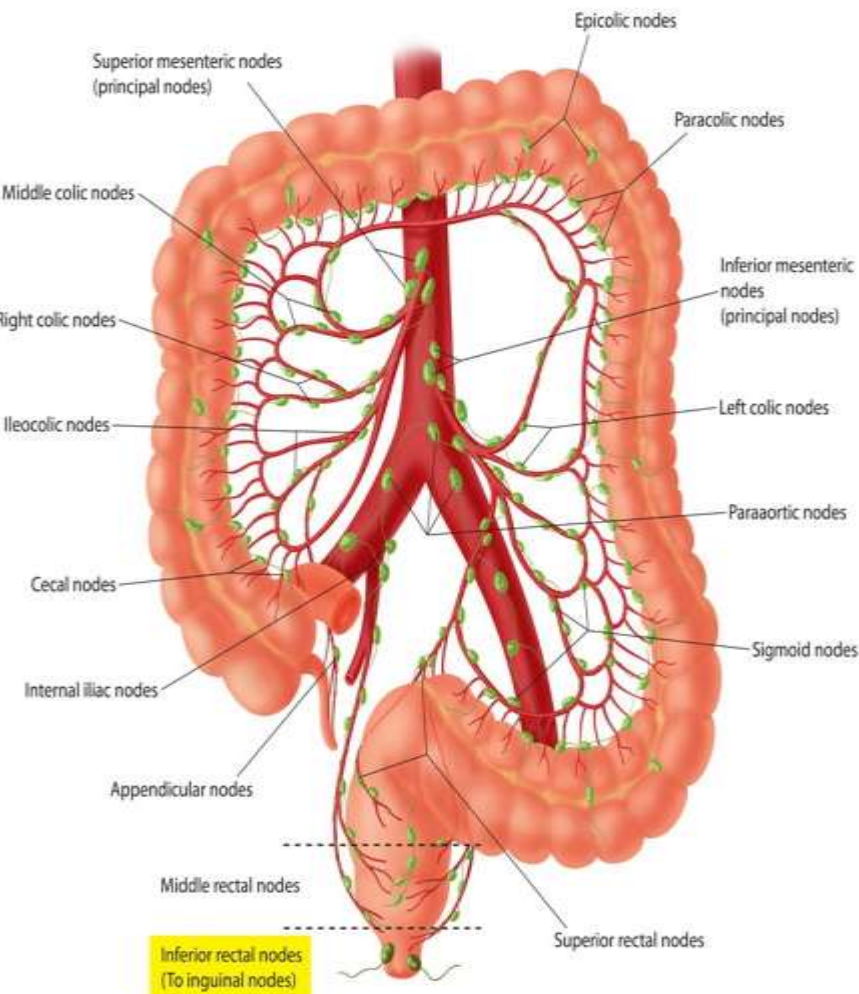


Sigmoid Colon



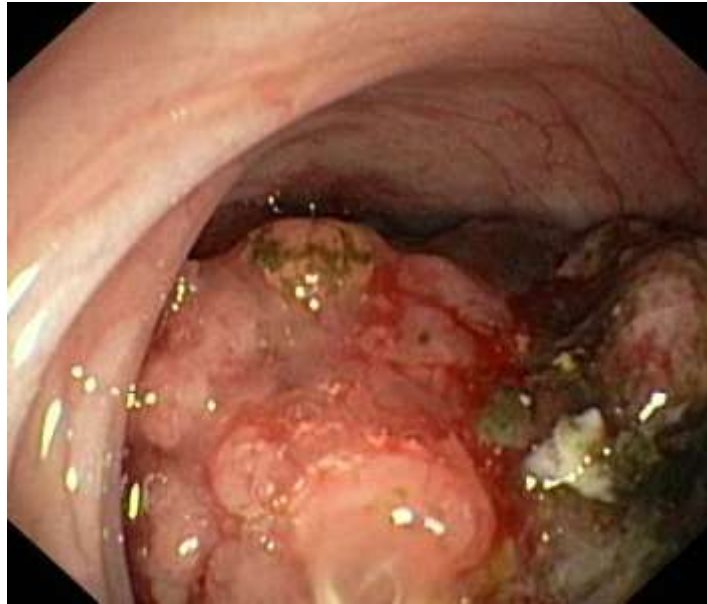
Sigmoid Colon

Lymph nodes & vessels of large intestine

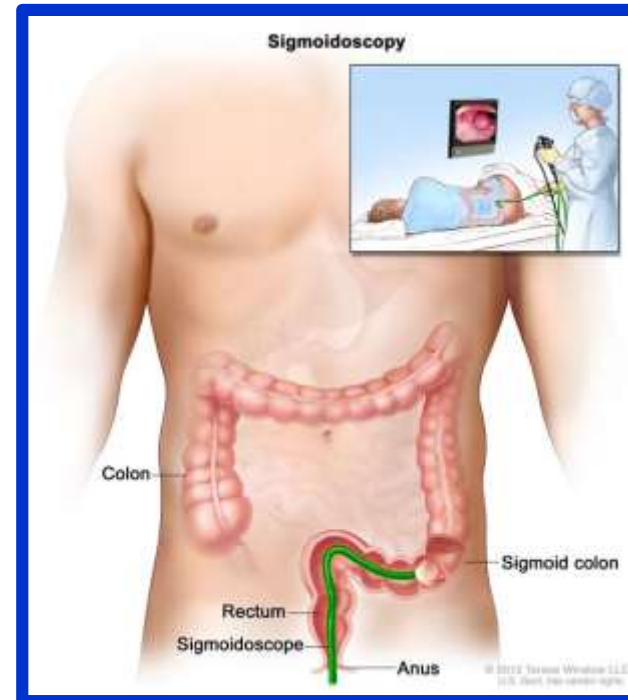
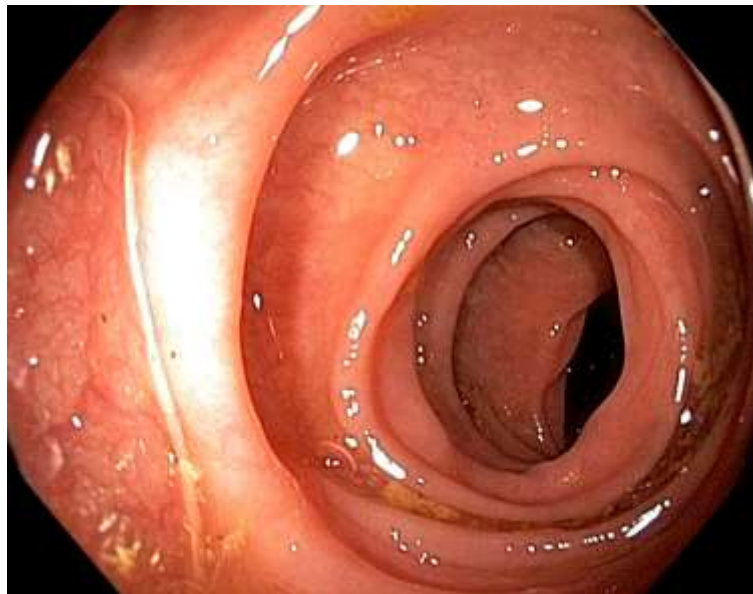


Sigmoid Colon

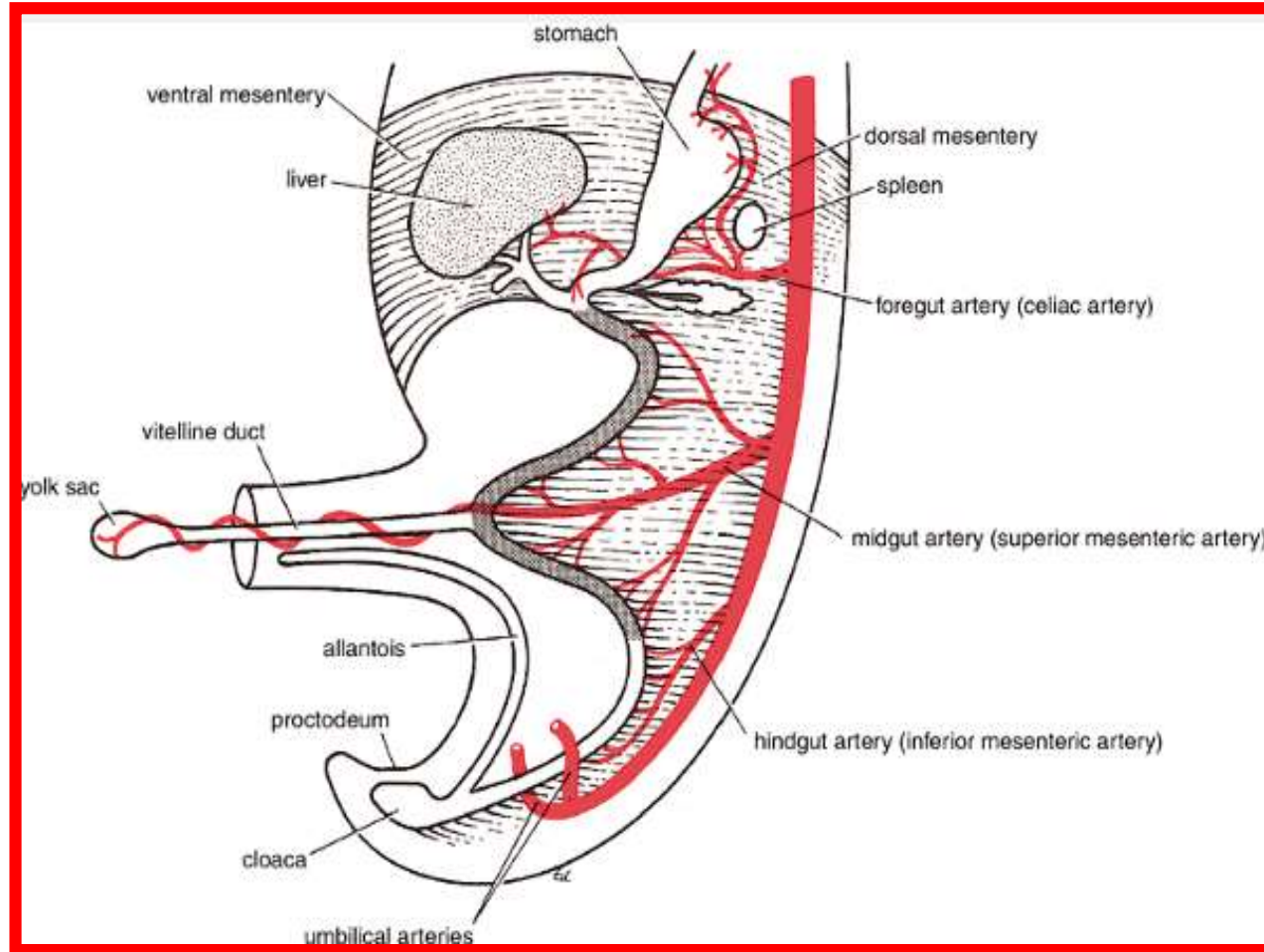
Dr Aiman Q AL Maathidy
Sunday 10 April 2022
131



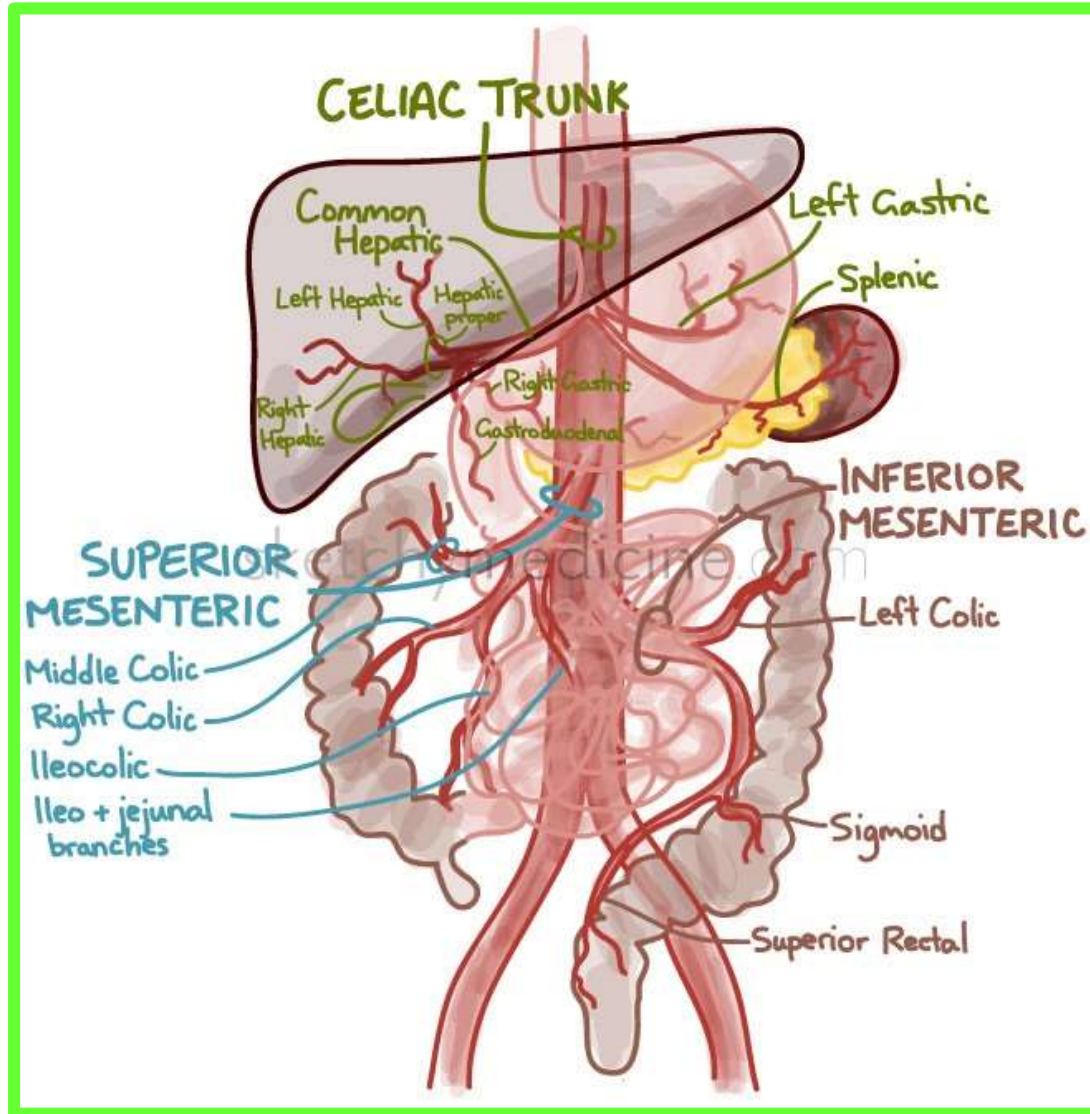
Most tumors of the large intestine occur in the sigmoid colon and rectum; they often appear near **the rectosigmoid junction**. The interior of the sigmoid colon is observed with a **sigmoidoscope**, a shorter endoscope, in a procedure called **sigmoidoscopy**.



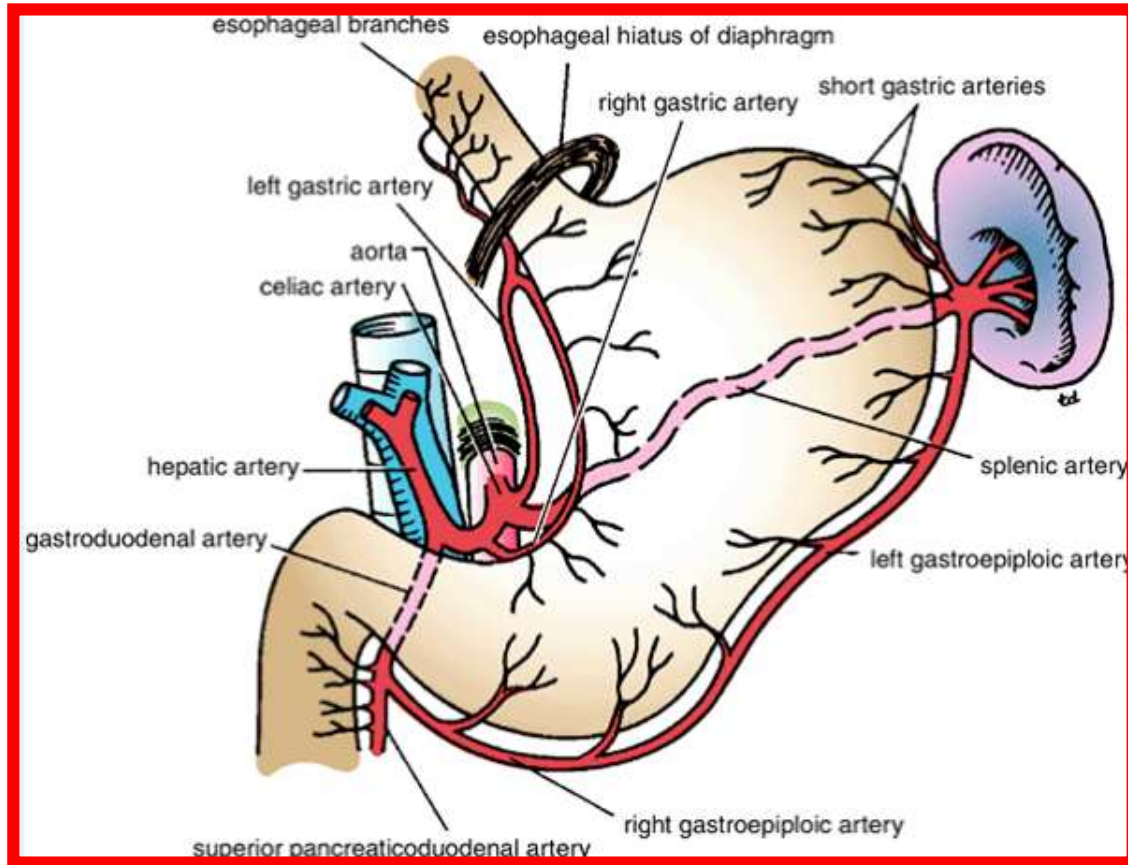
Blood Supply of the Gastrointestinal Tract



Blood Supply of the Gastrointestinal Tract



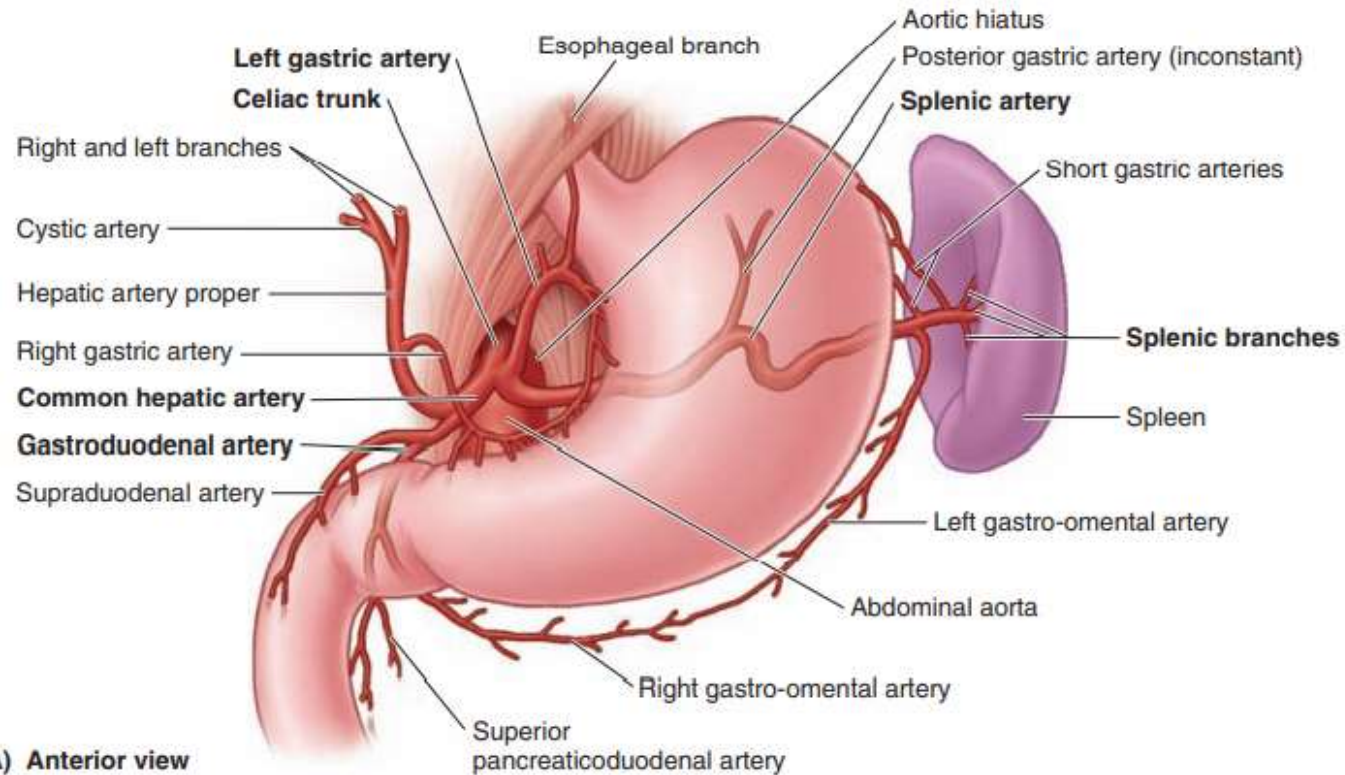
Blood Supply of the Gastrointestinal Tract



Celiac Artery

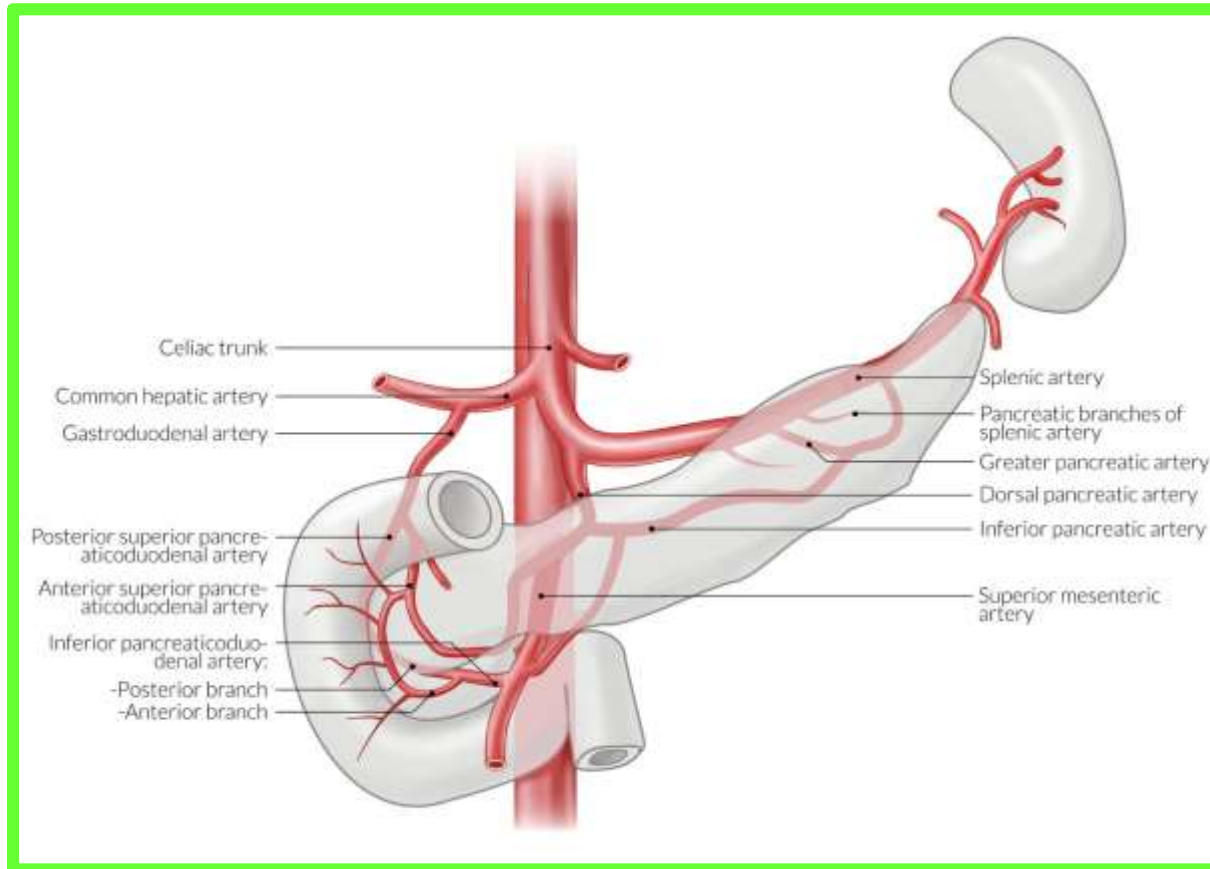
Dr Aiman Al-Maathidy

Thursday 14 April 2022

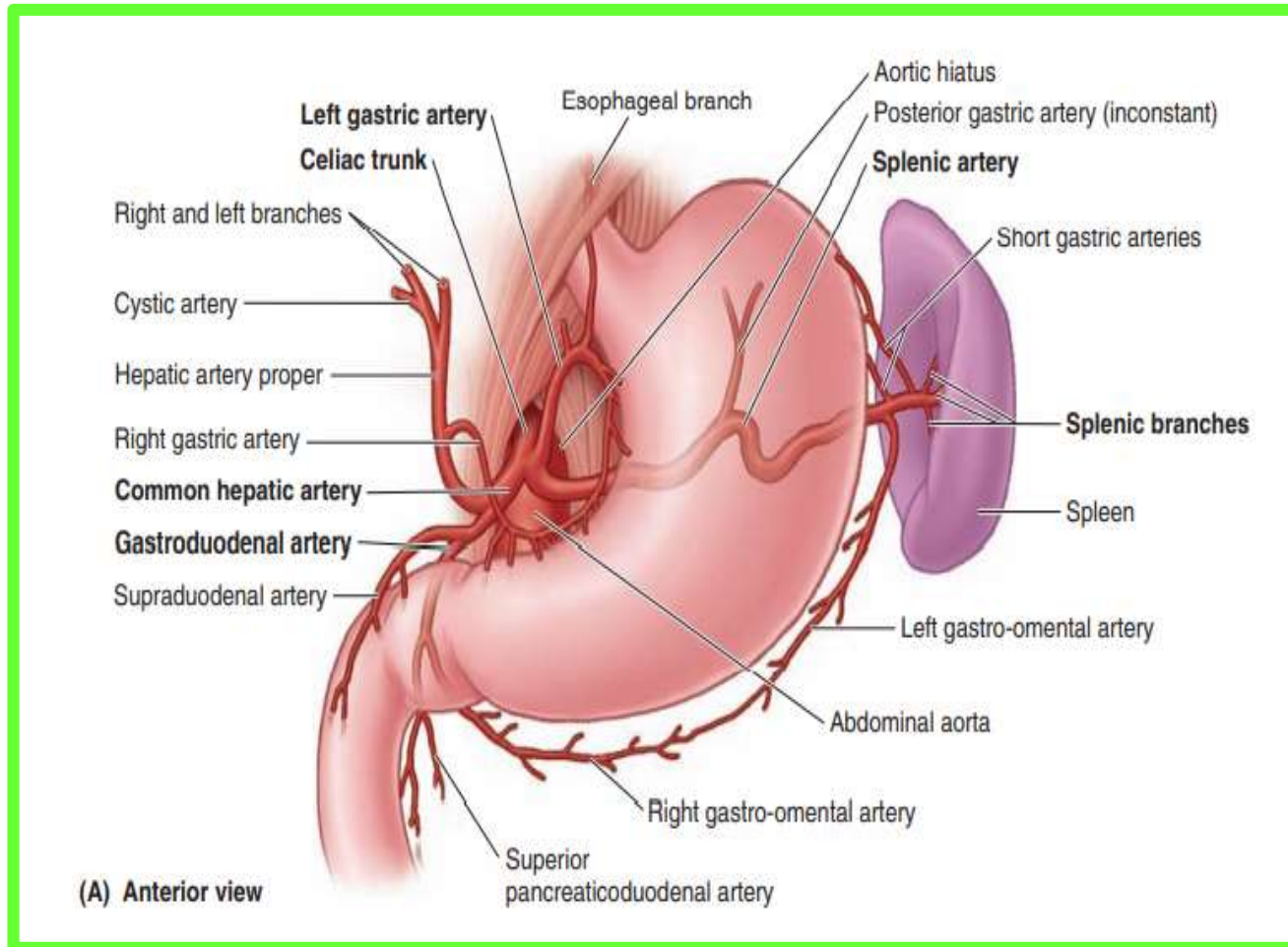


Celiac Artery

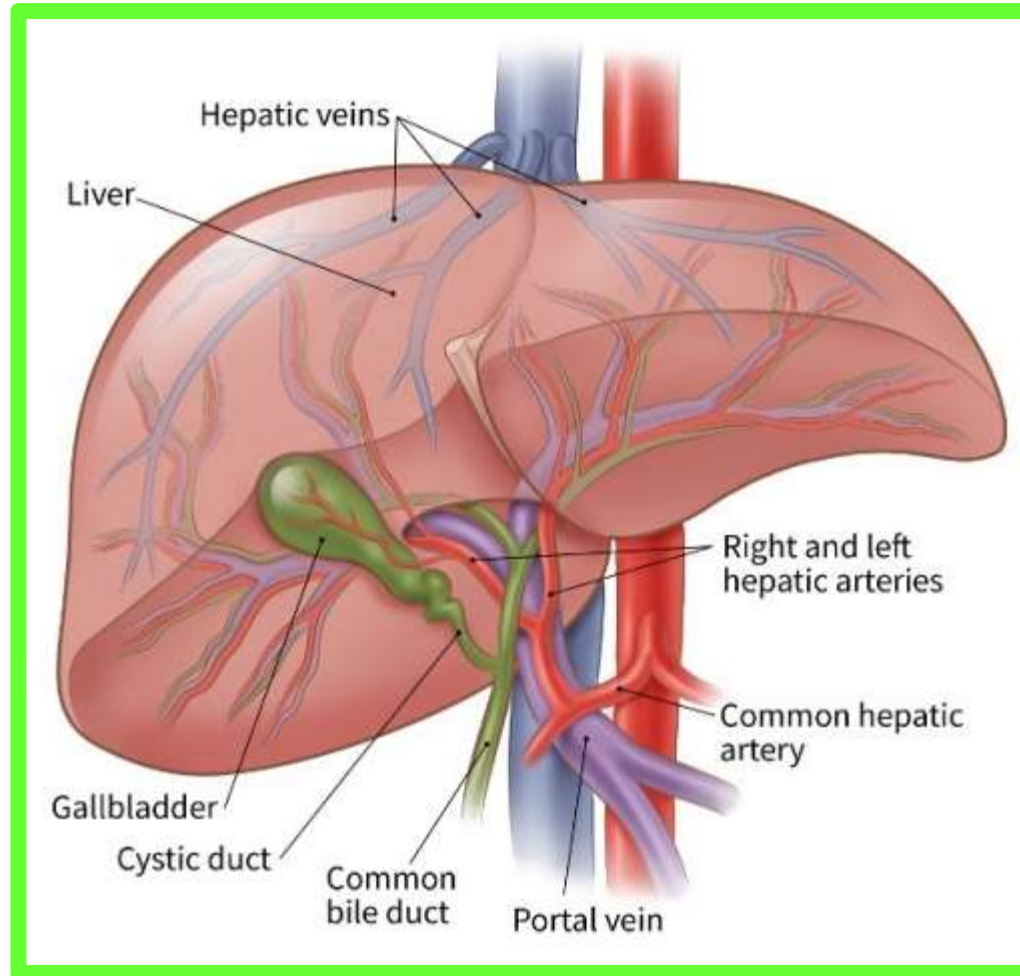
Dr Aiman Al-Maathidy
Thursday 14 April 2022



Celiac Artery



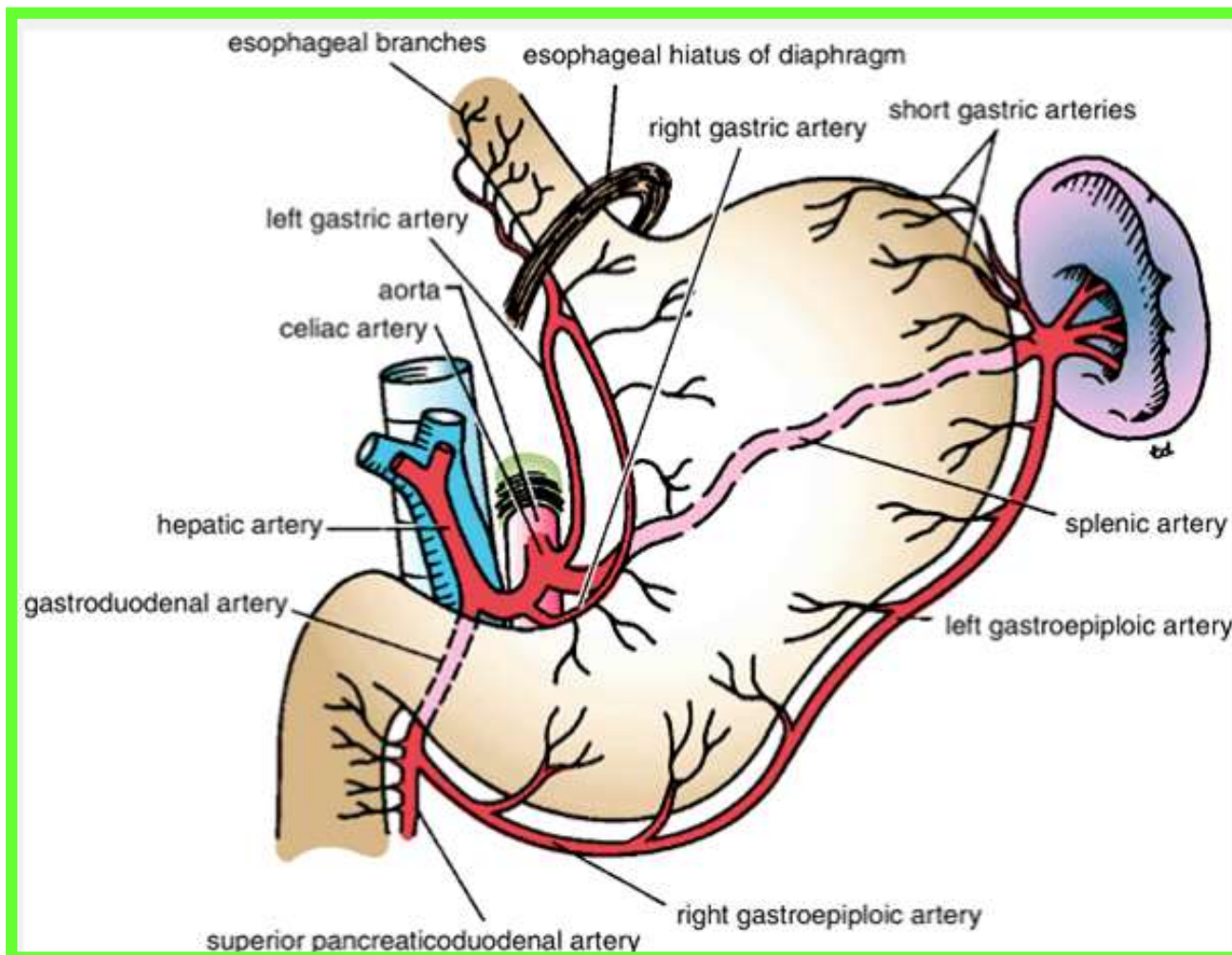
□ Celiac Artery



Celiac Artery

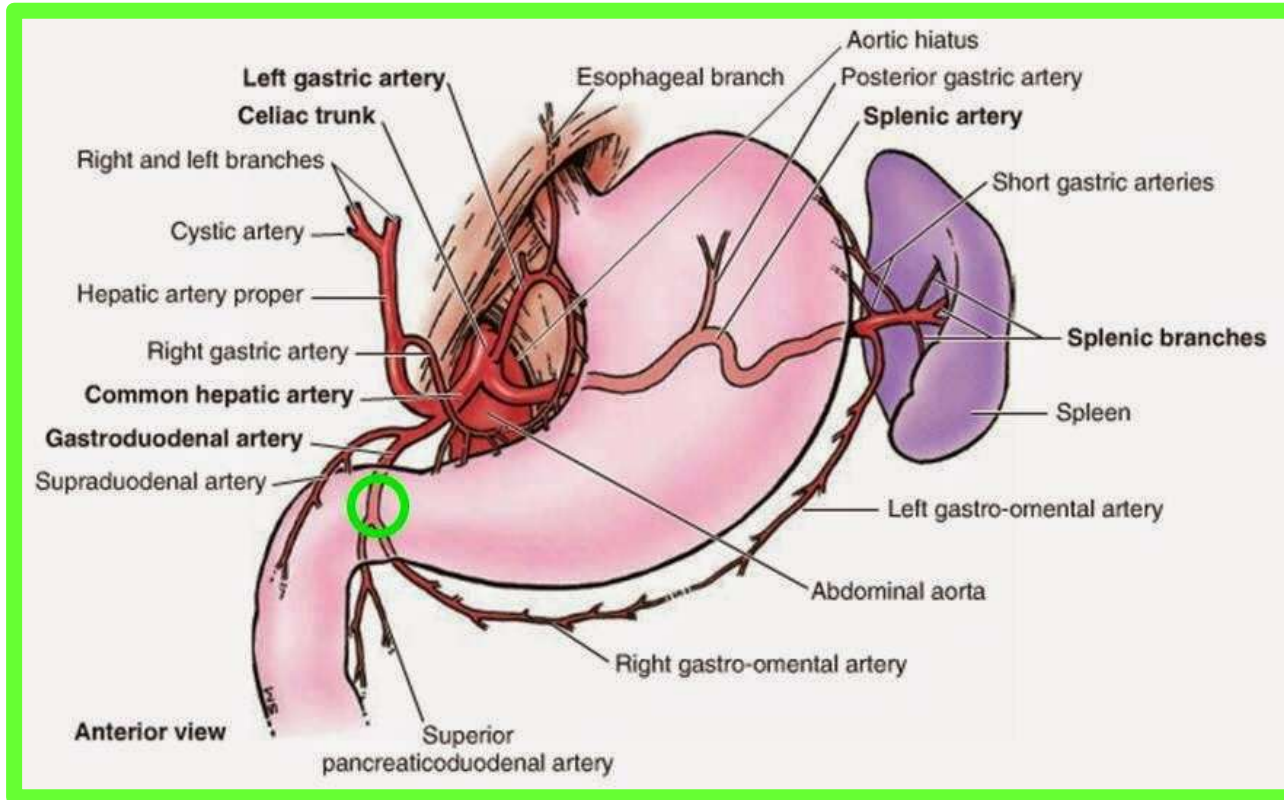
Branches of Hepatic Artery

Dr Aiman Al-Maathidy



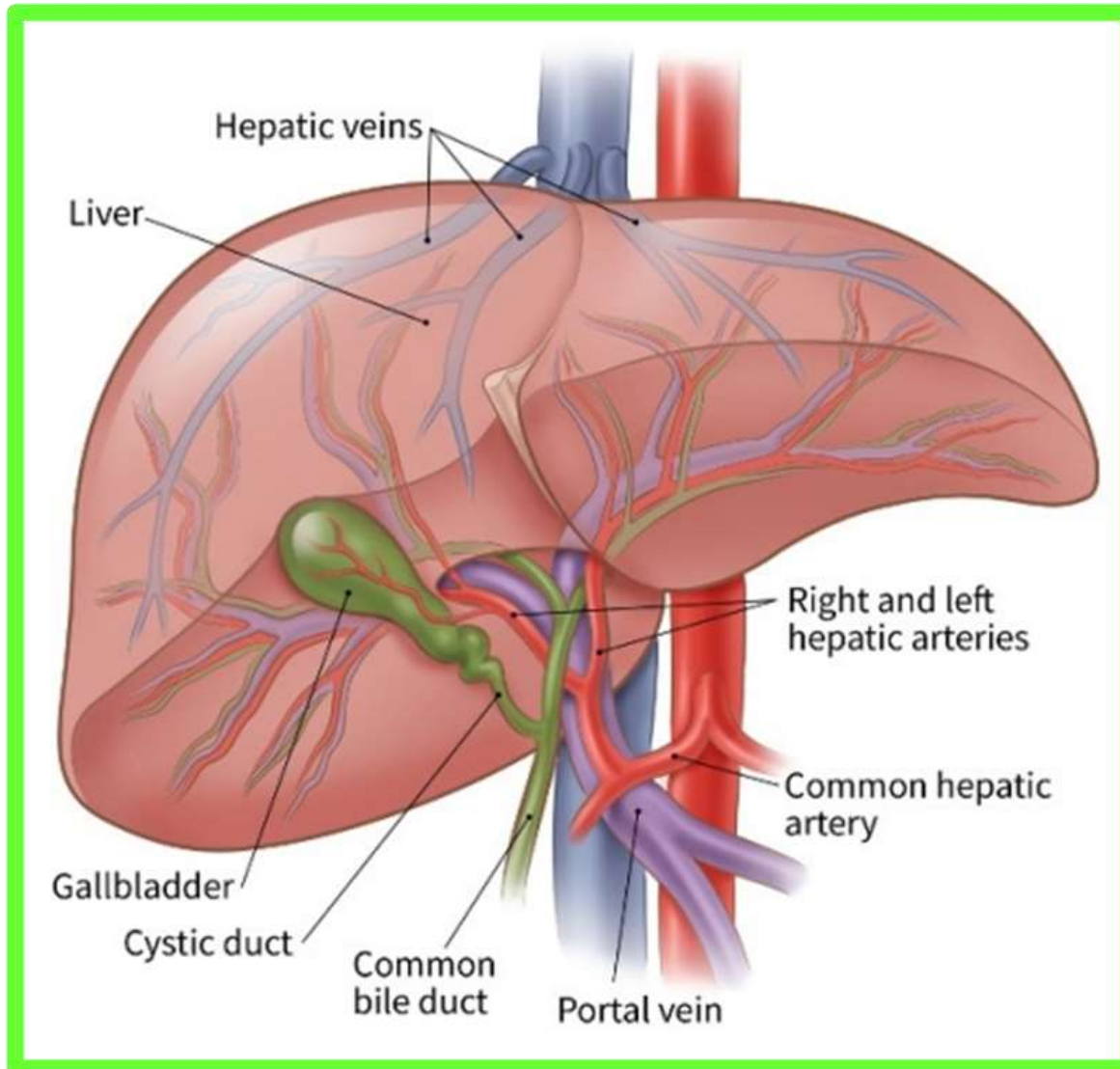
Celiac Artery

Branches of Hepatic Artery



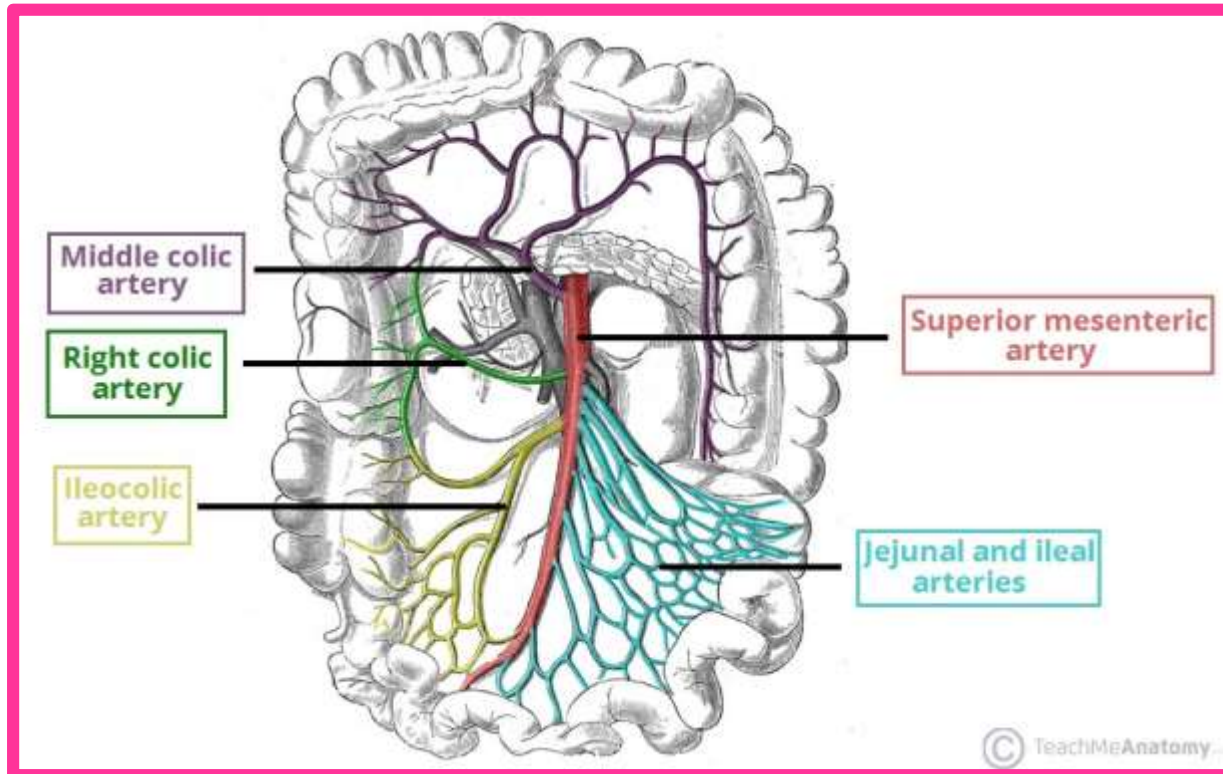
Celiac Artery

Branches of Hepatic Artery

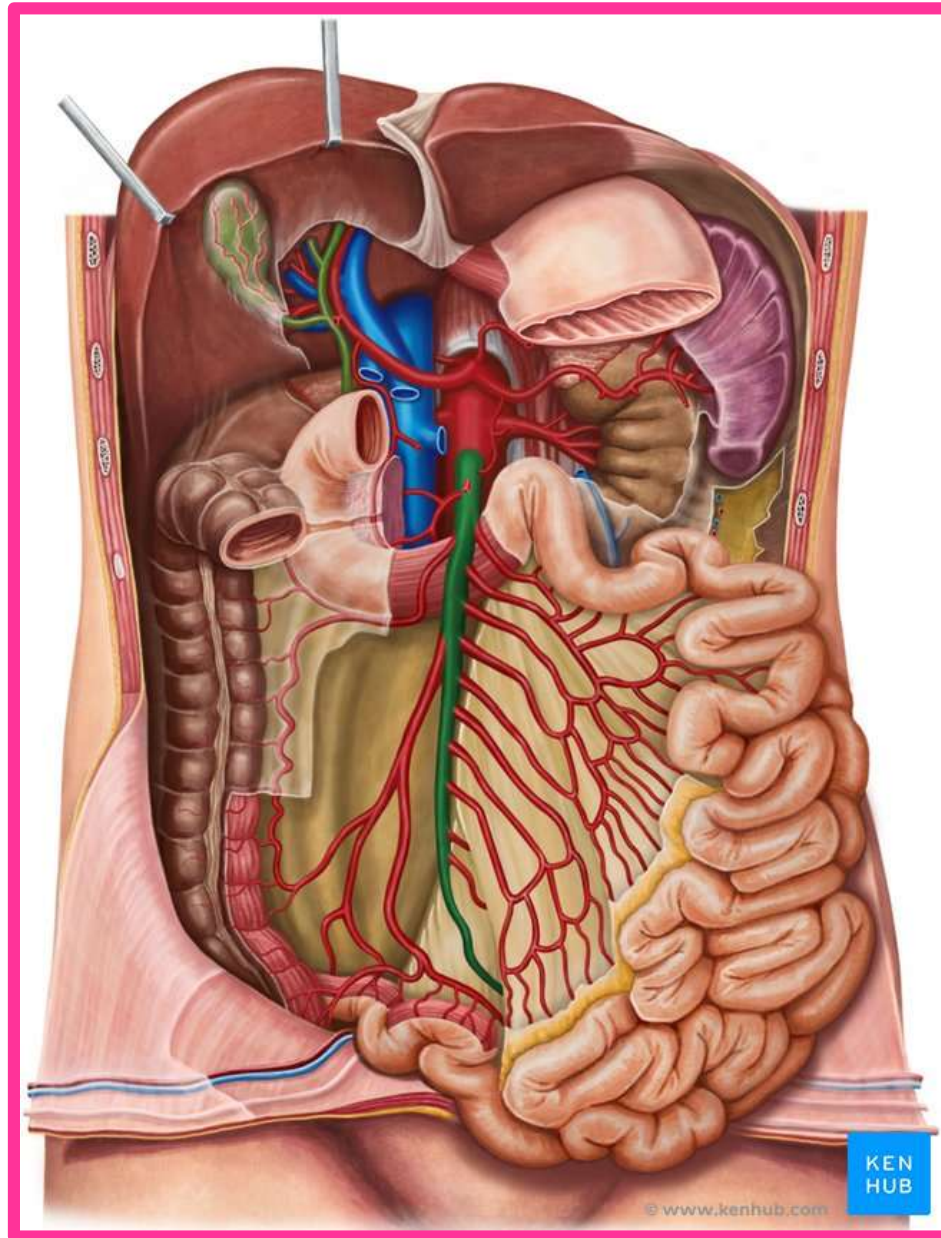


Blood Supply of the Gastrointestinal Tract

Superior Mesenteric Artery



Superior Mesenteric Artery

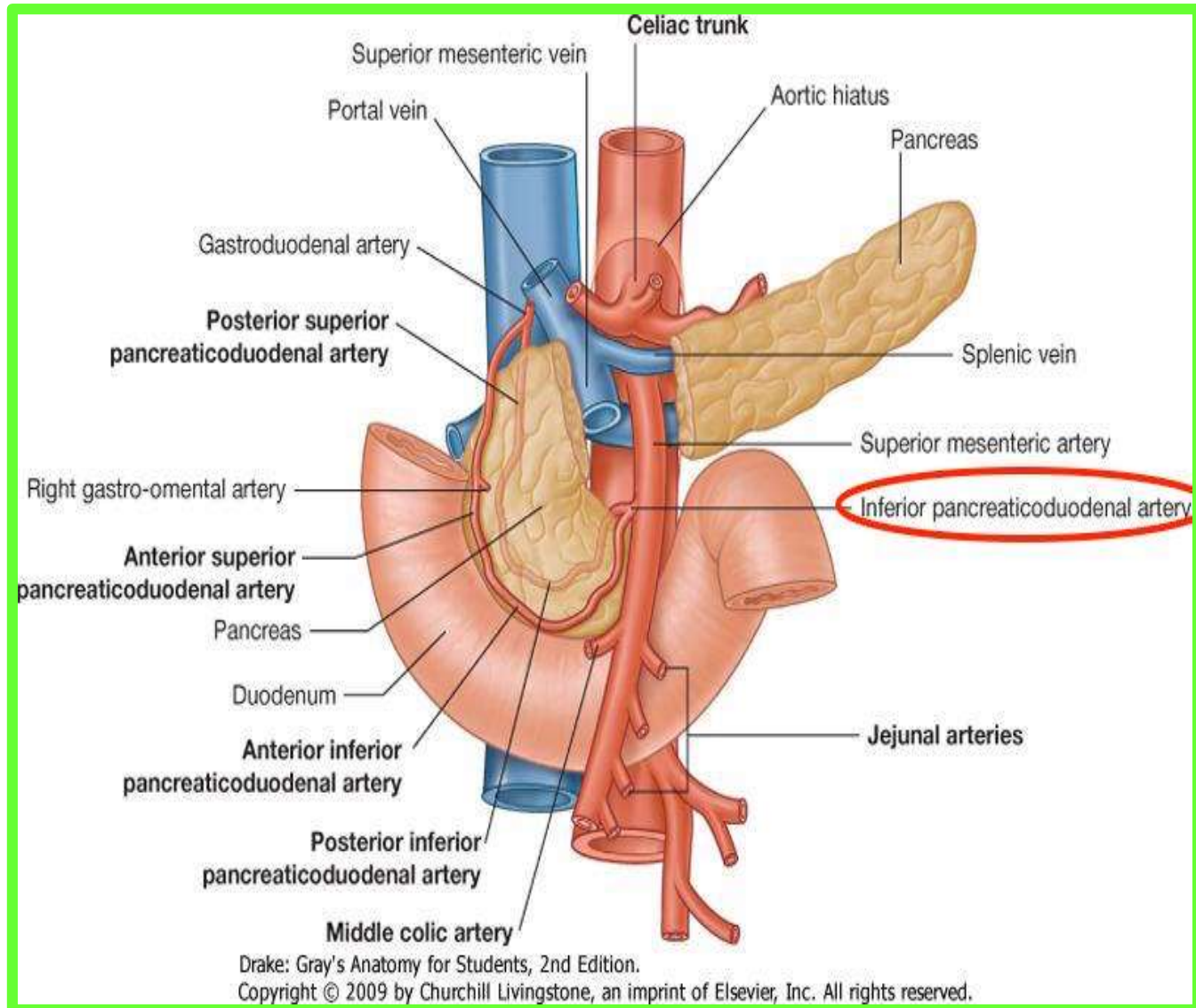


Dr Aiman Al-Maathidy
Thursday 14 April 2022

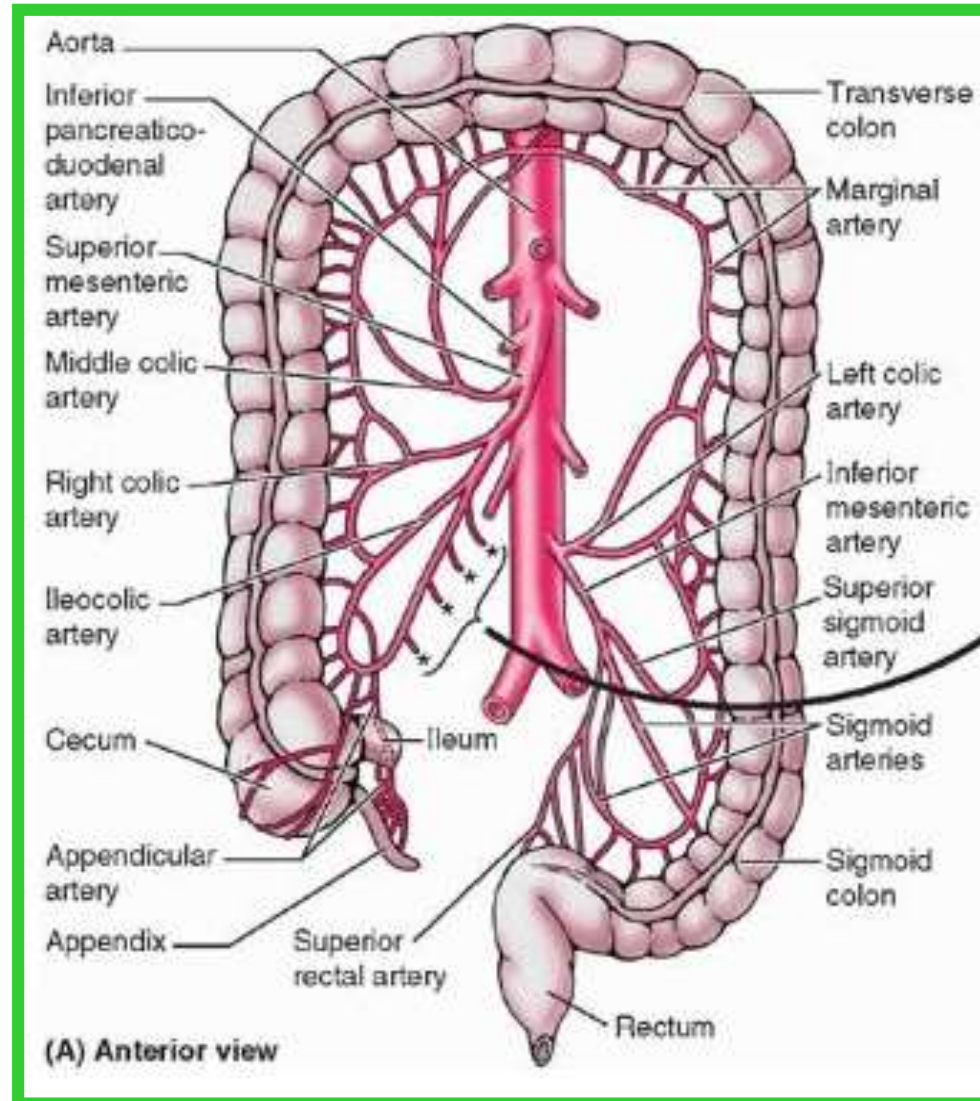
KEN
HUB

© www.kenhub.com

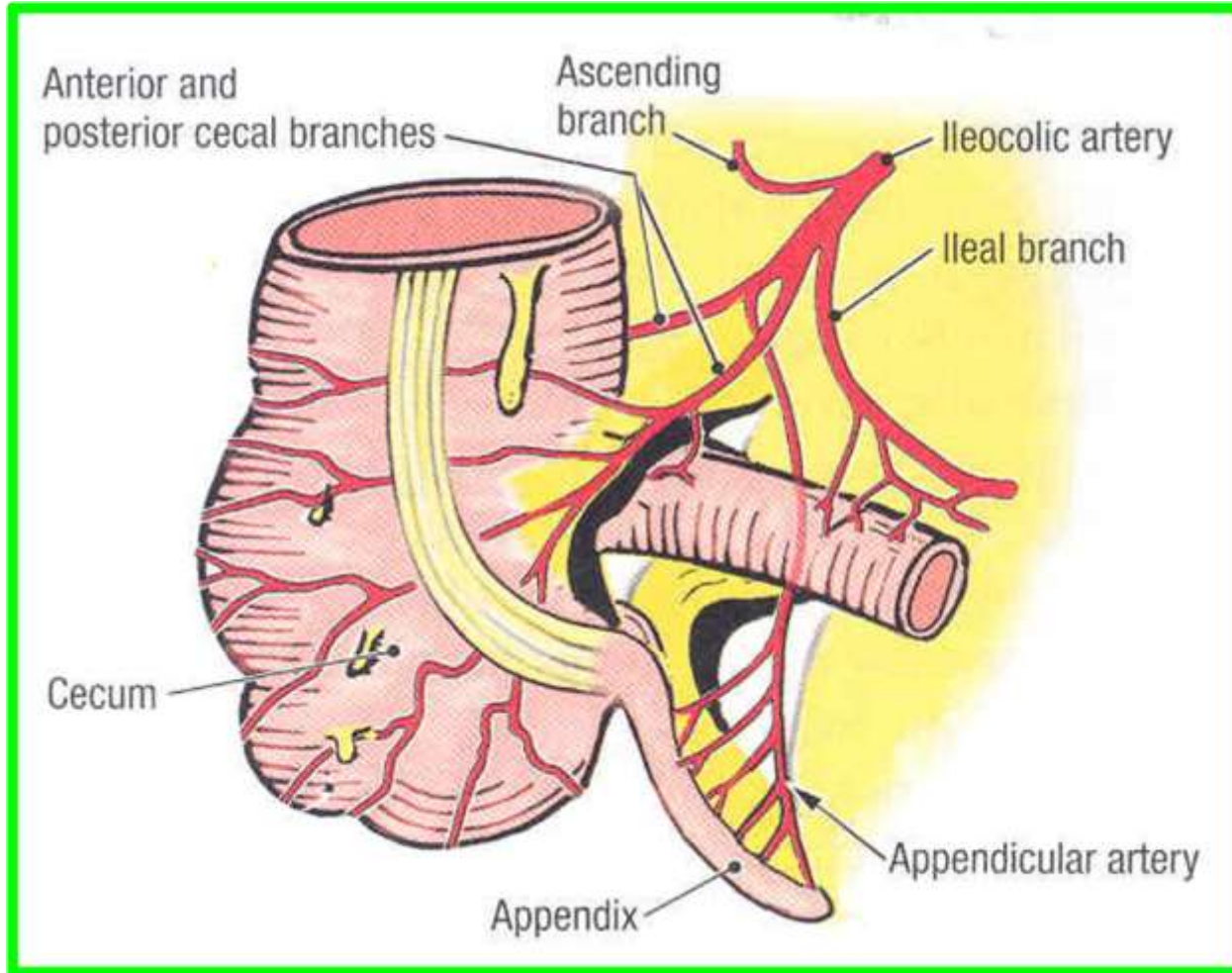
Superior Mesenteric Artery Branches



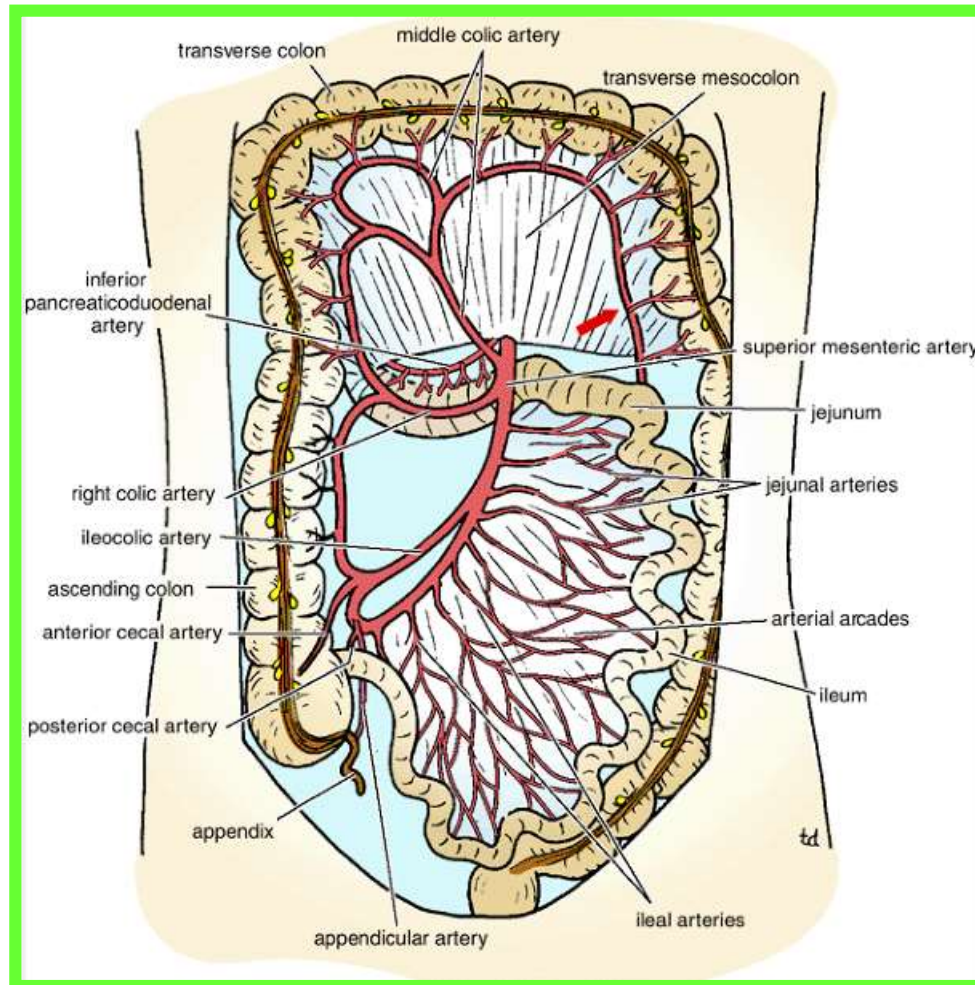
Superior Mesenteric Artery



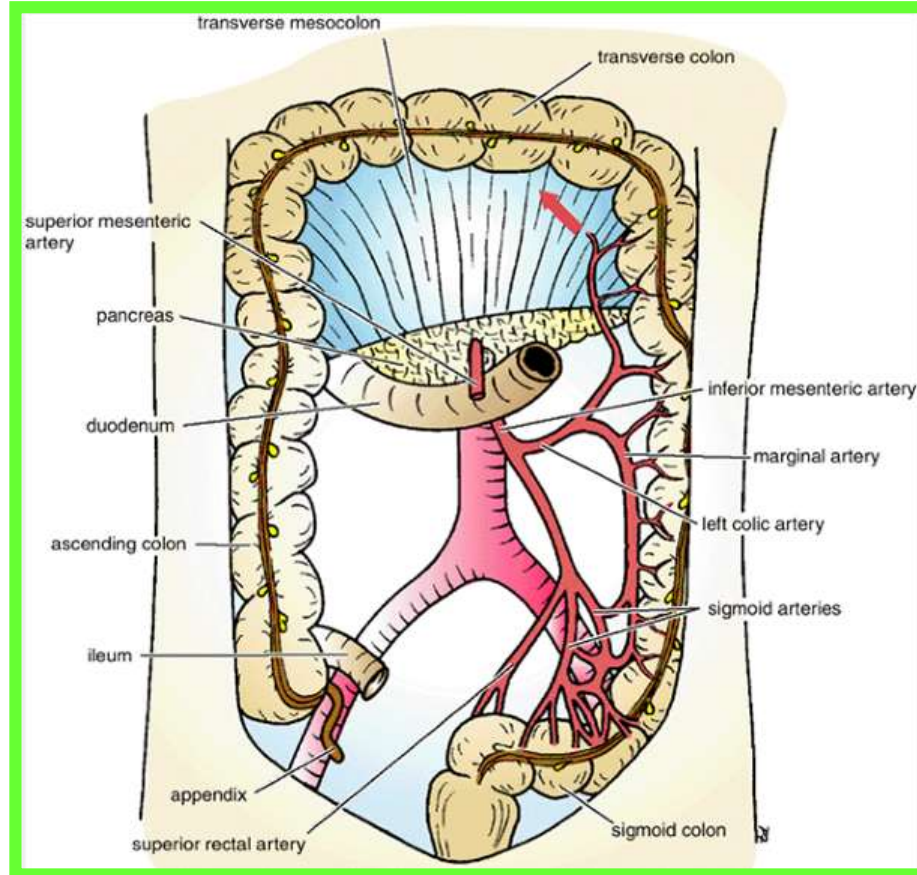
Superior Mesenteric Artery



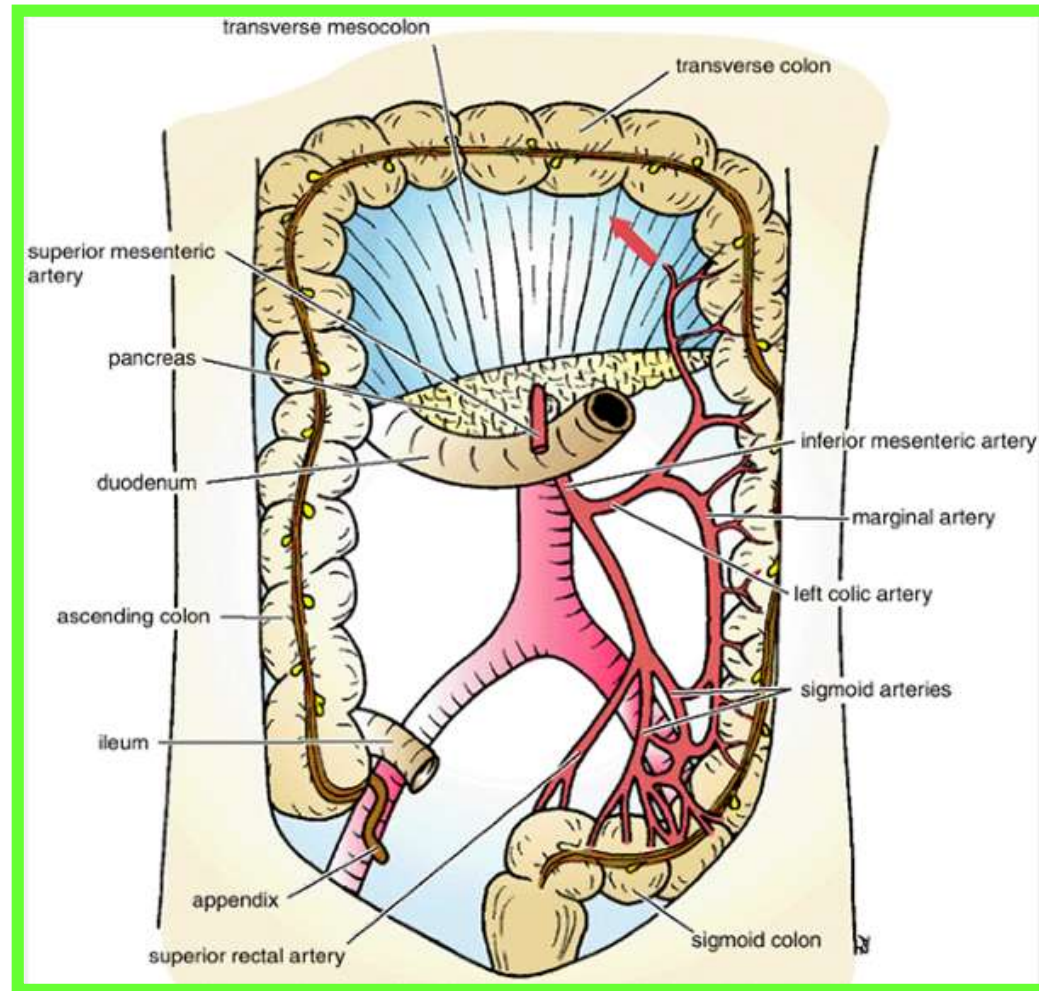
Superior Mesenteric Artery



Inferior Mesenteric Artery

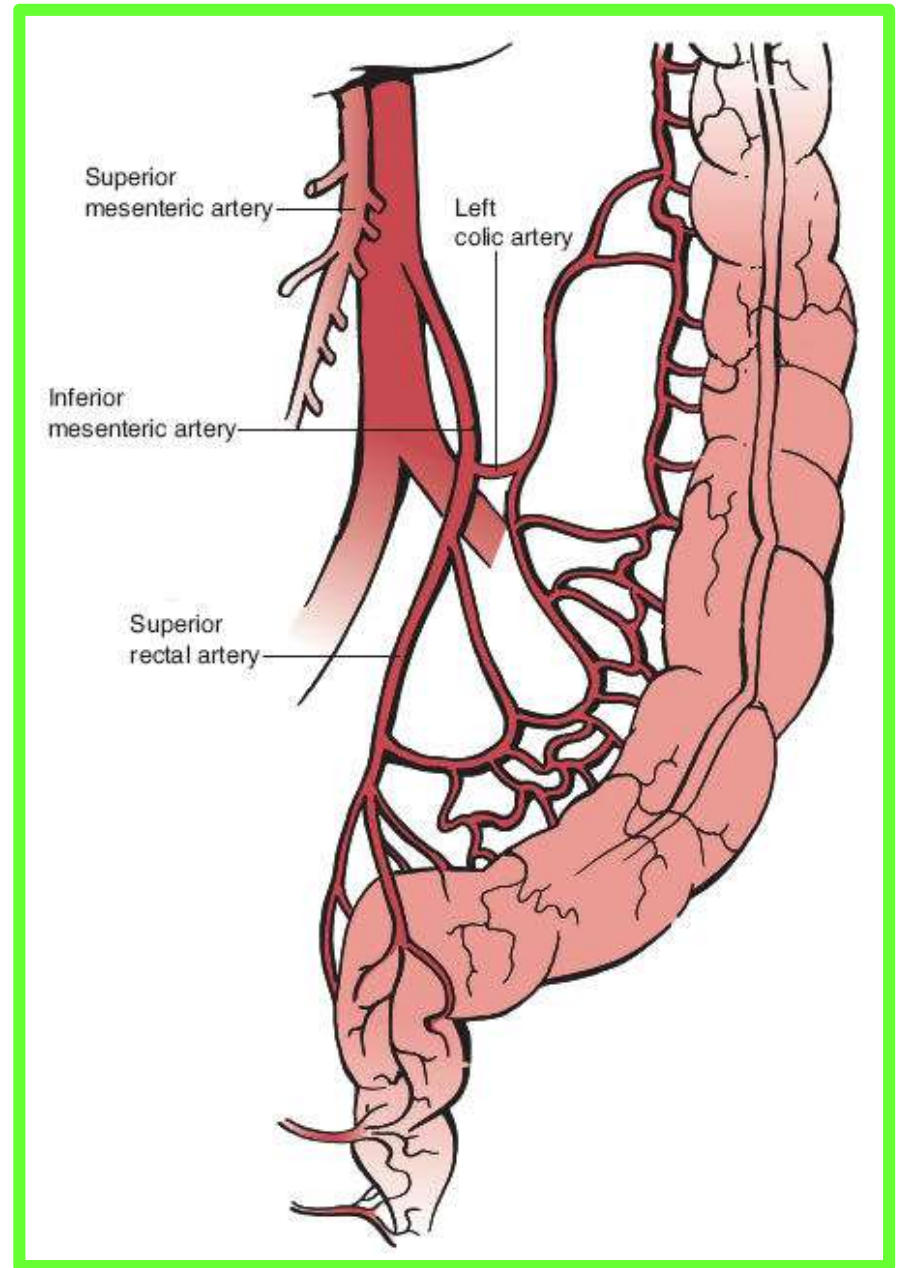


Inferior Mesenteric Artery

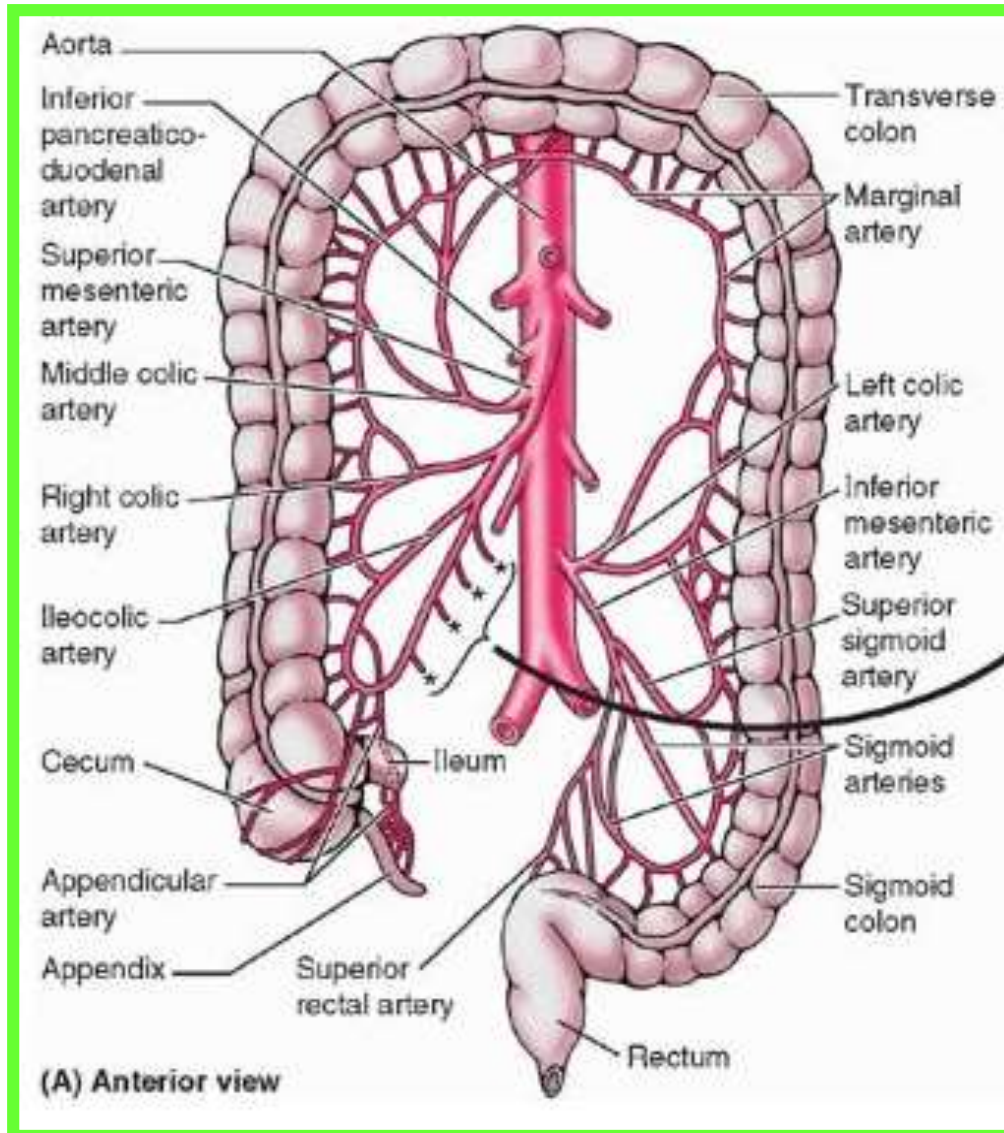


Inferior Mesenteric Artery

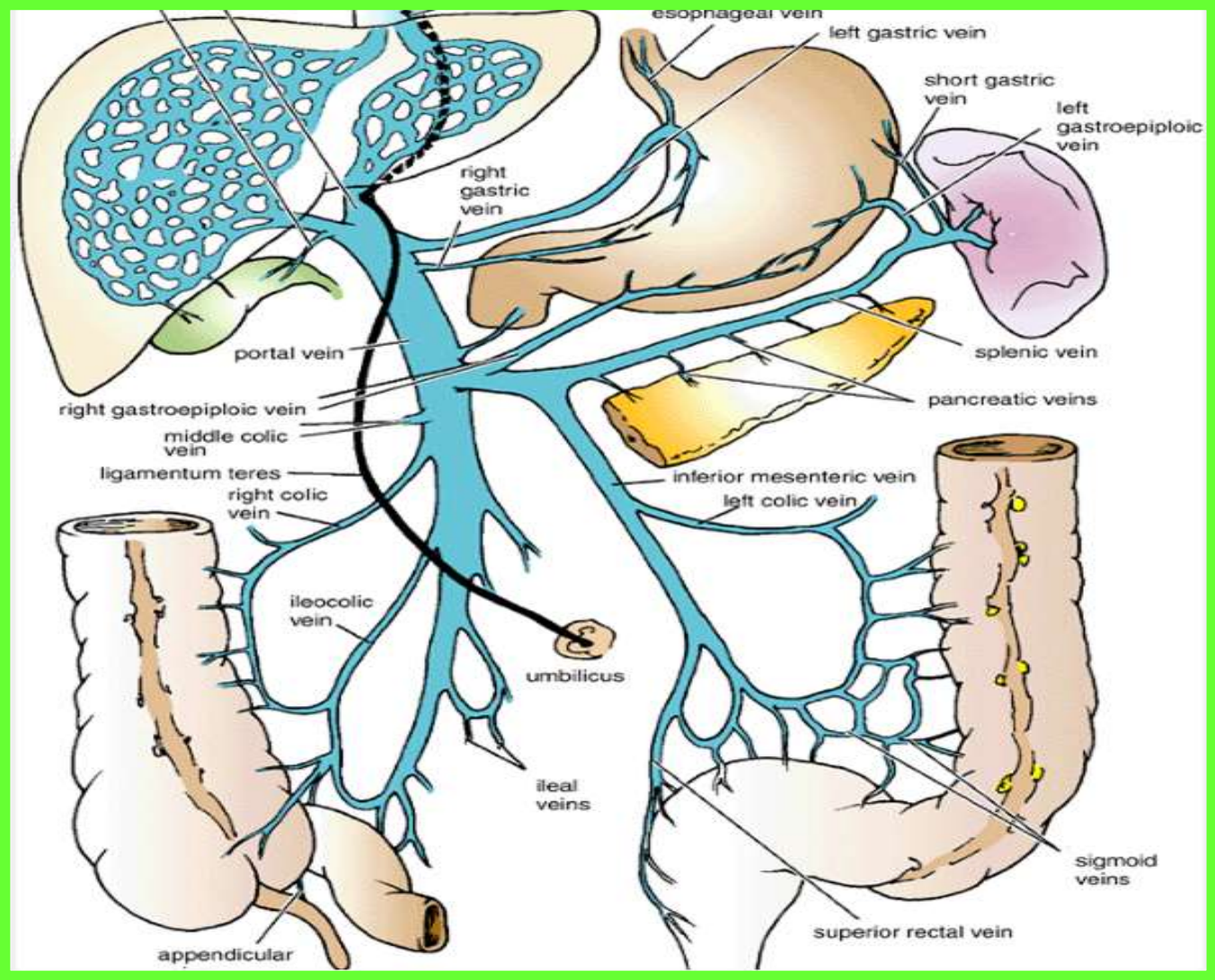
Branches



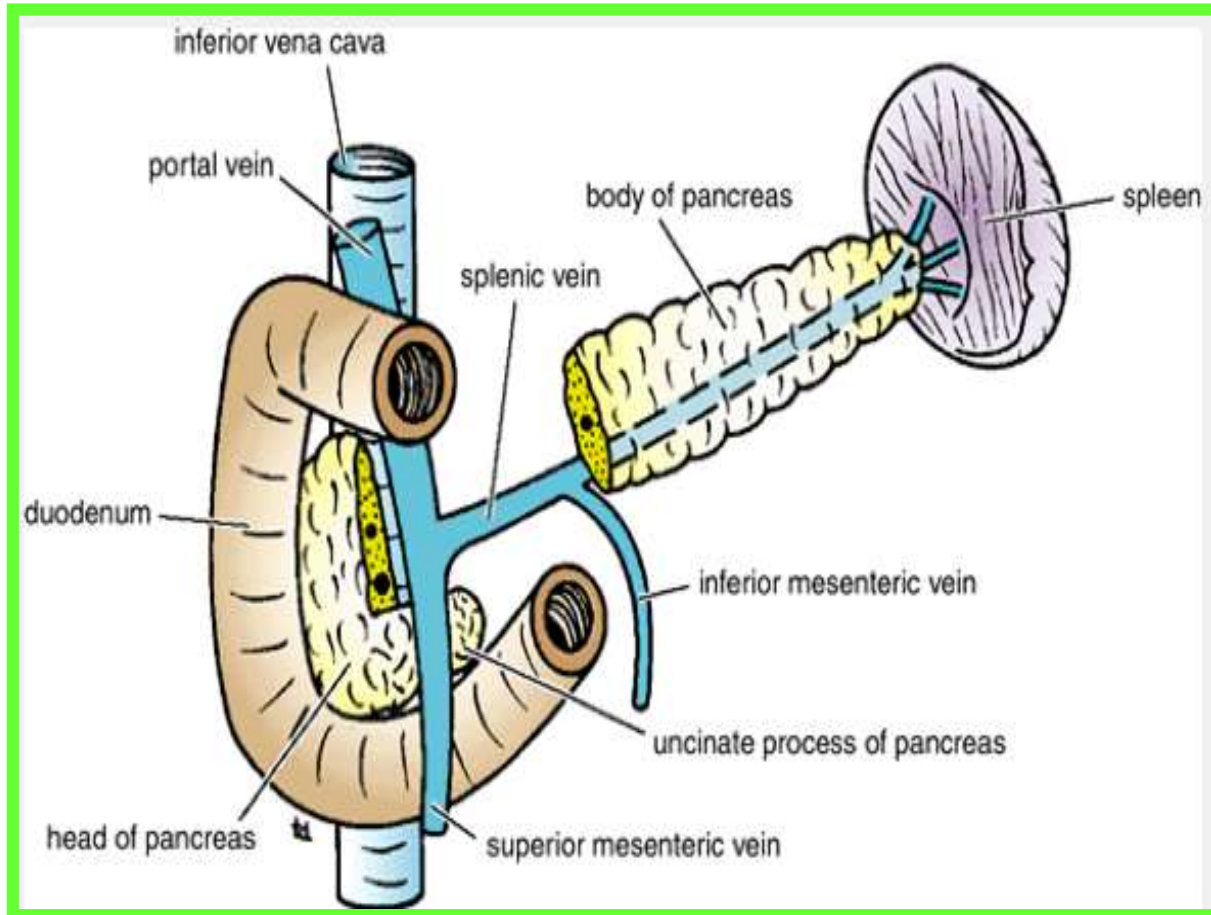
Marginal Artery



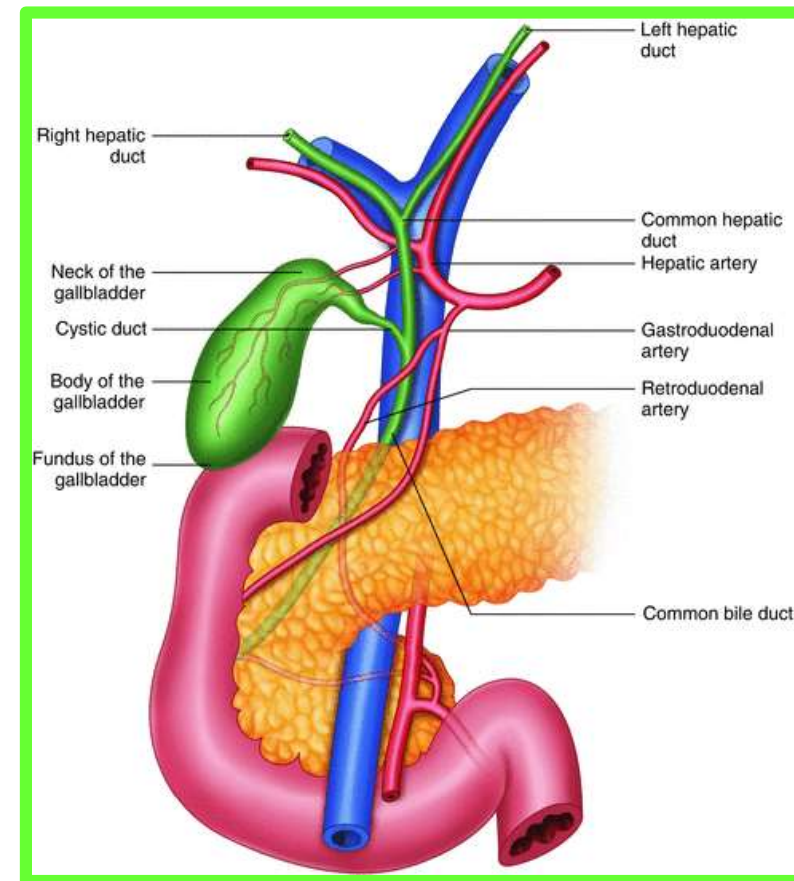
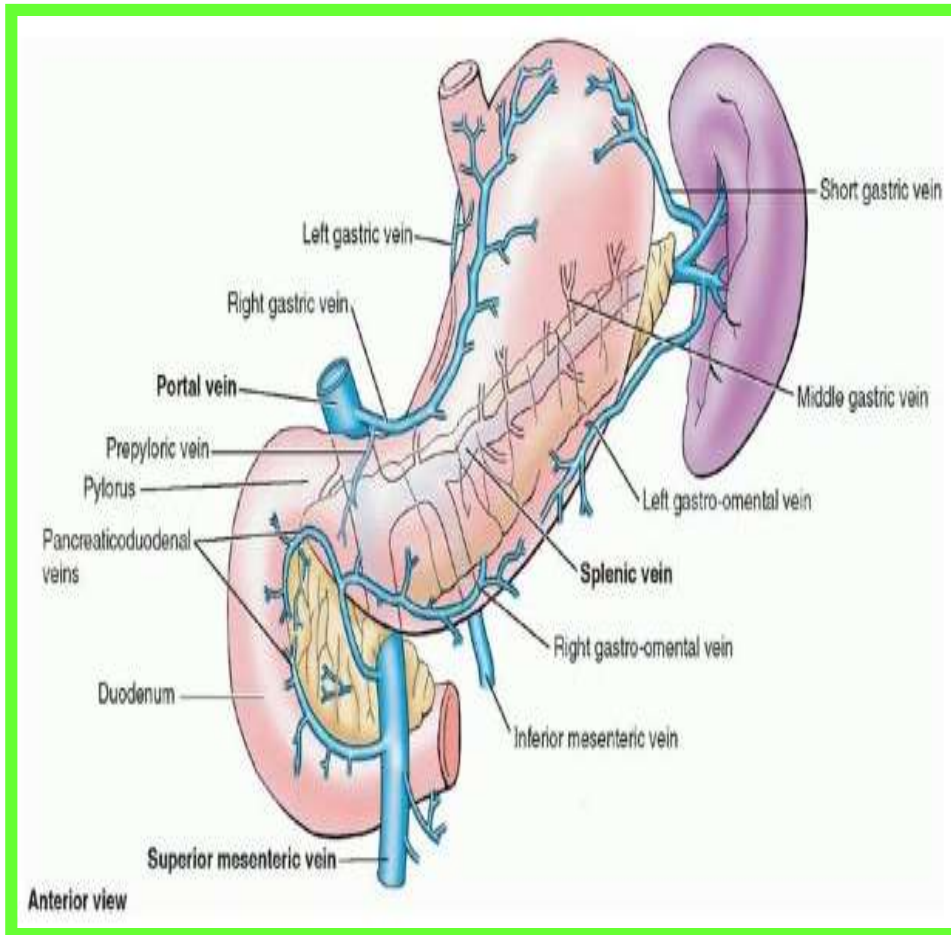
Portal Vein (Hepatic Portal Vein)



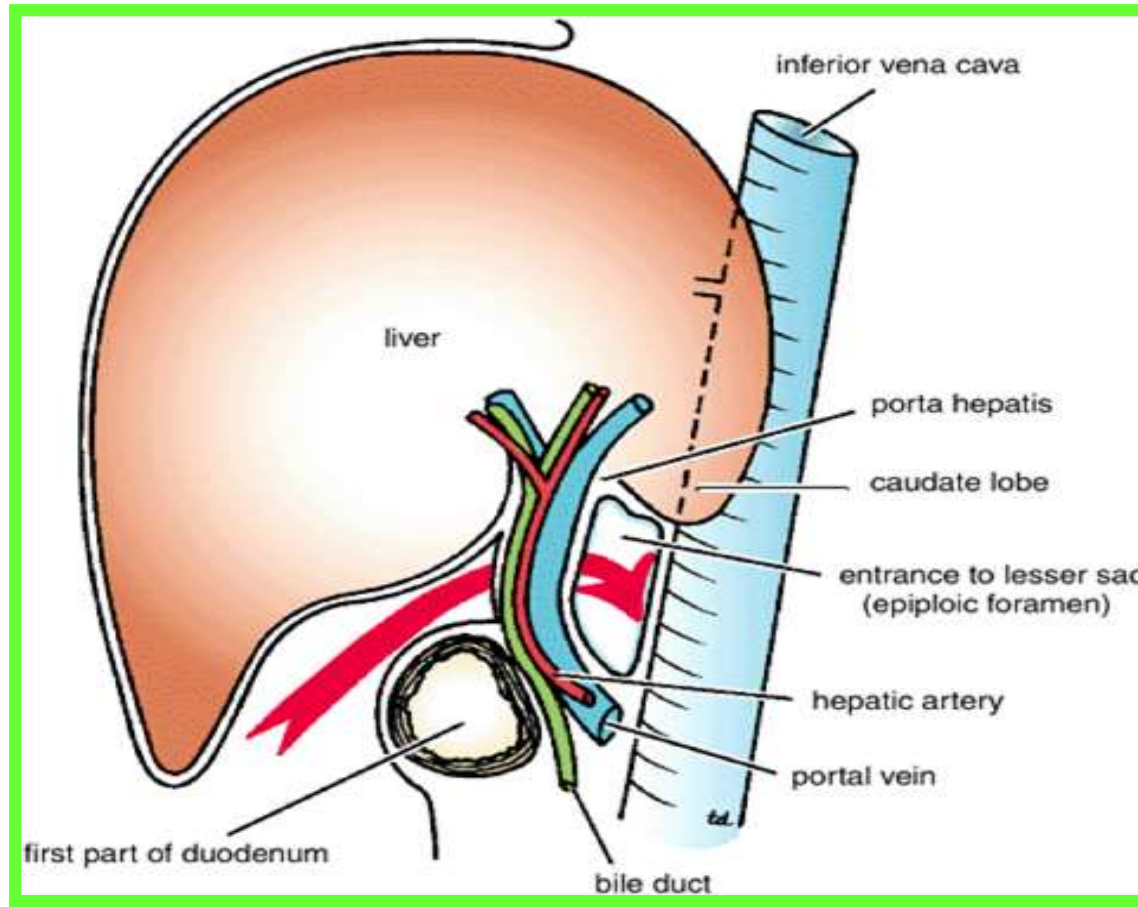
Portal Vein (Hepatic Portal Vein)



Portal Vein (Hepatic Portal Vein)

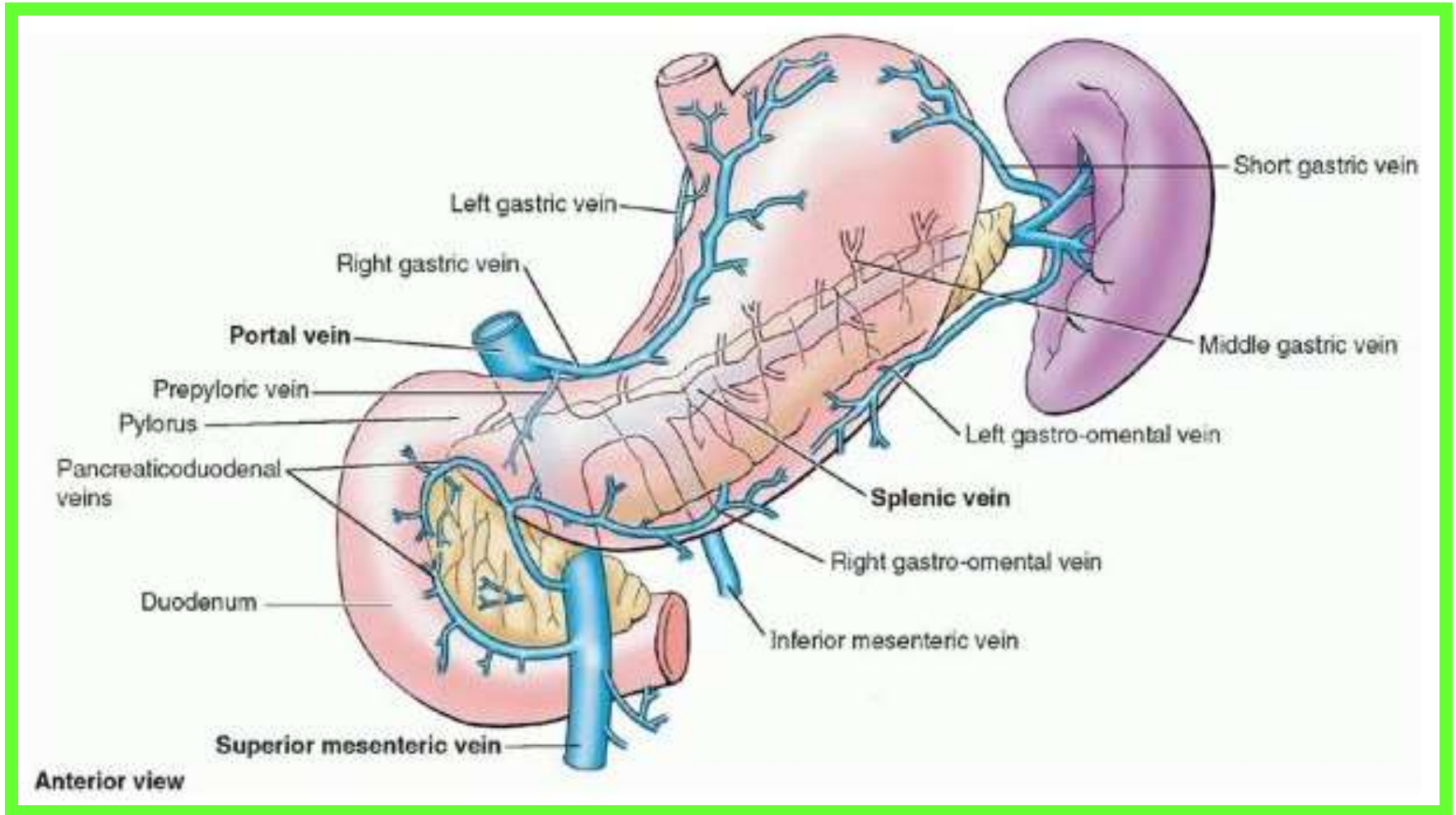


Portal Vein (Hepatic Portal Vein)



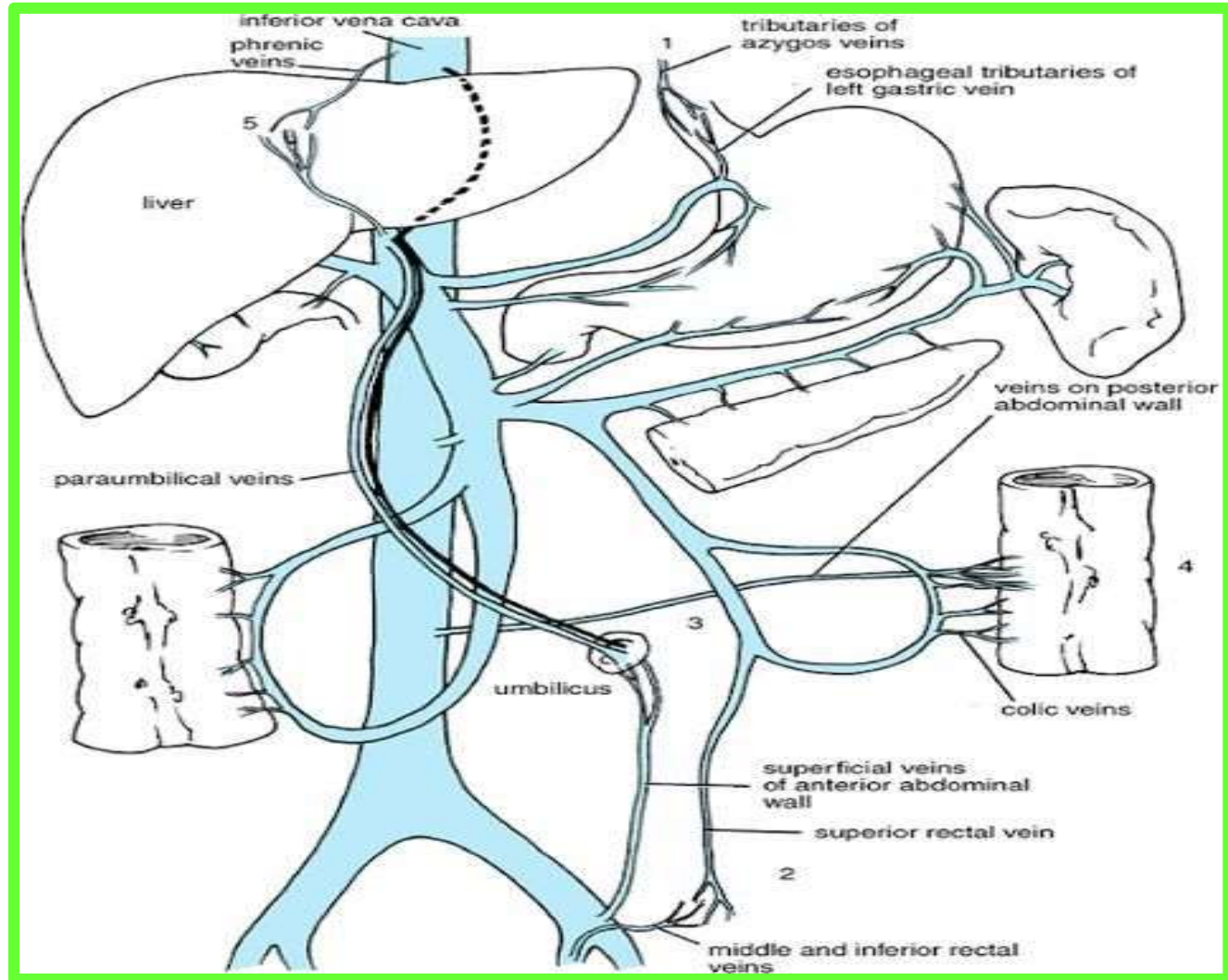
Portal Vein (Hepatic Portal Vein)

Tributaries of the Portal Vein

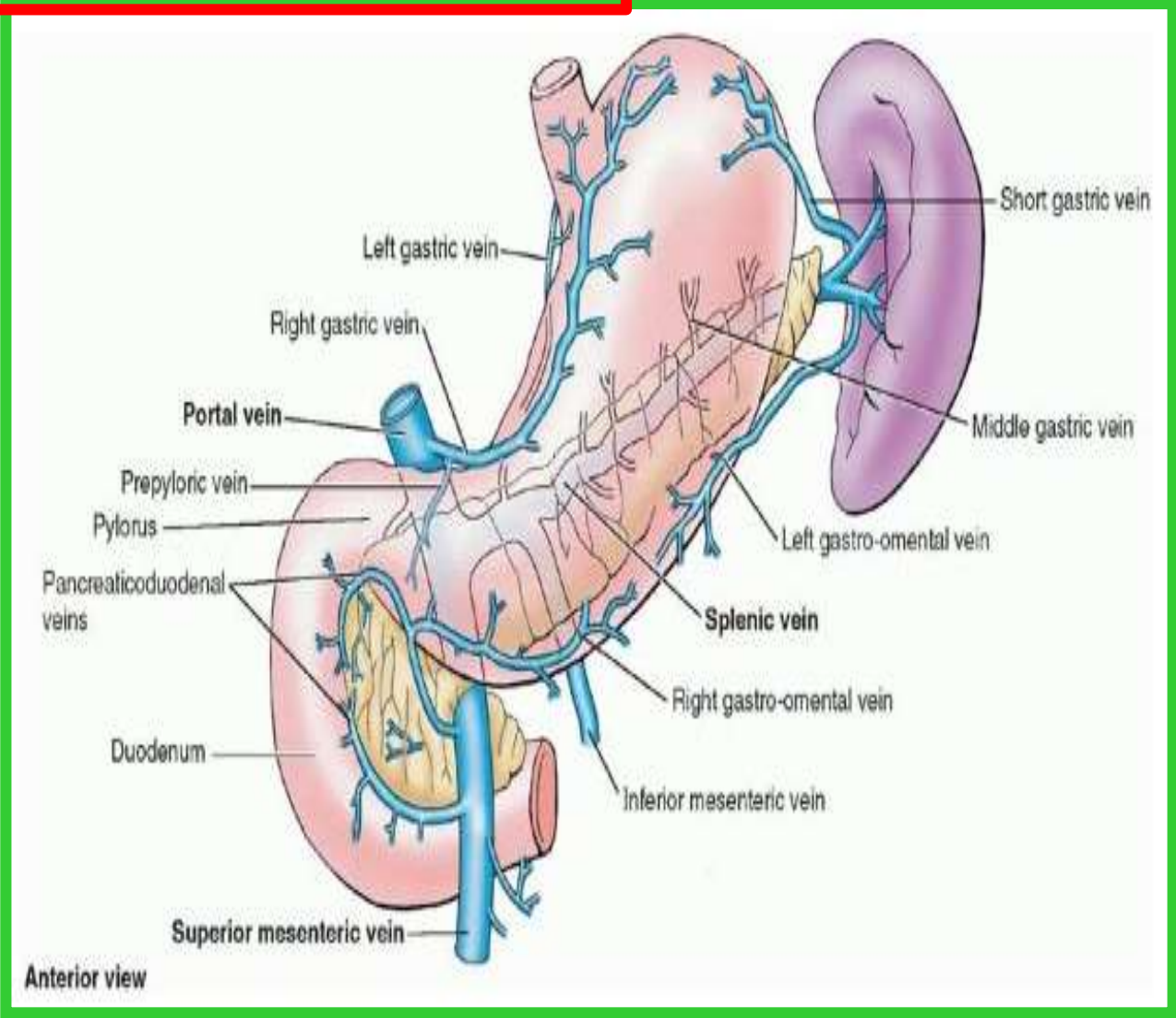


Portal Vein (Hepatic Portal Vein)

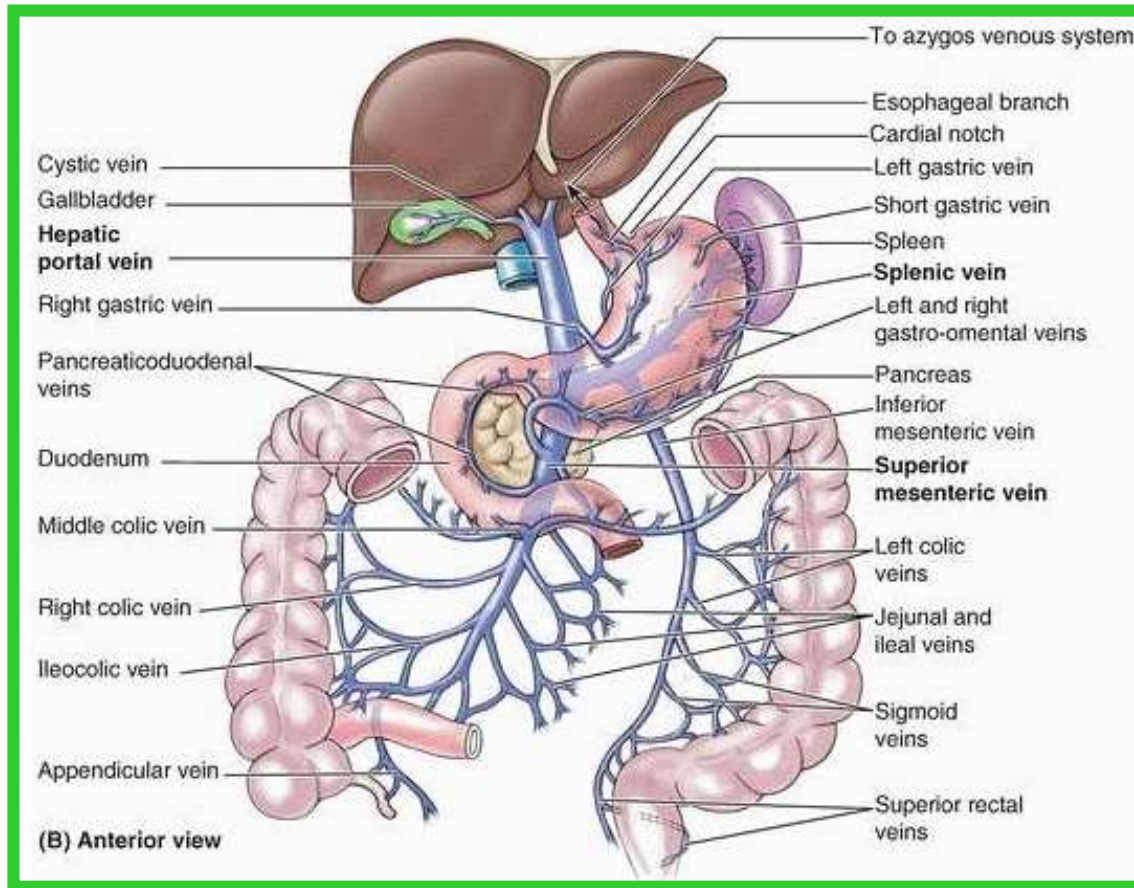
Thursday 14 April 2022
Dr Aiman Al-Maathidy



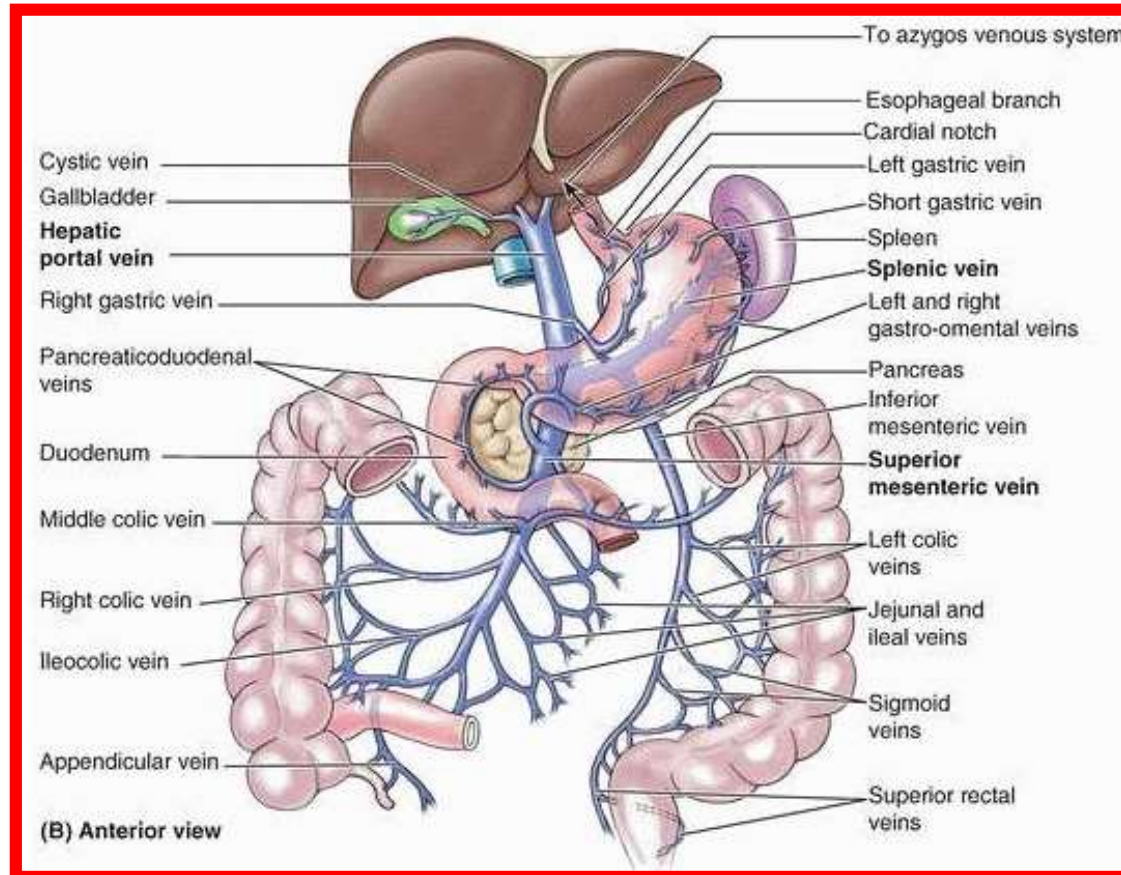
Tributaries of the Portal Vein



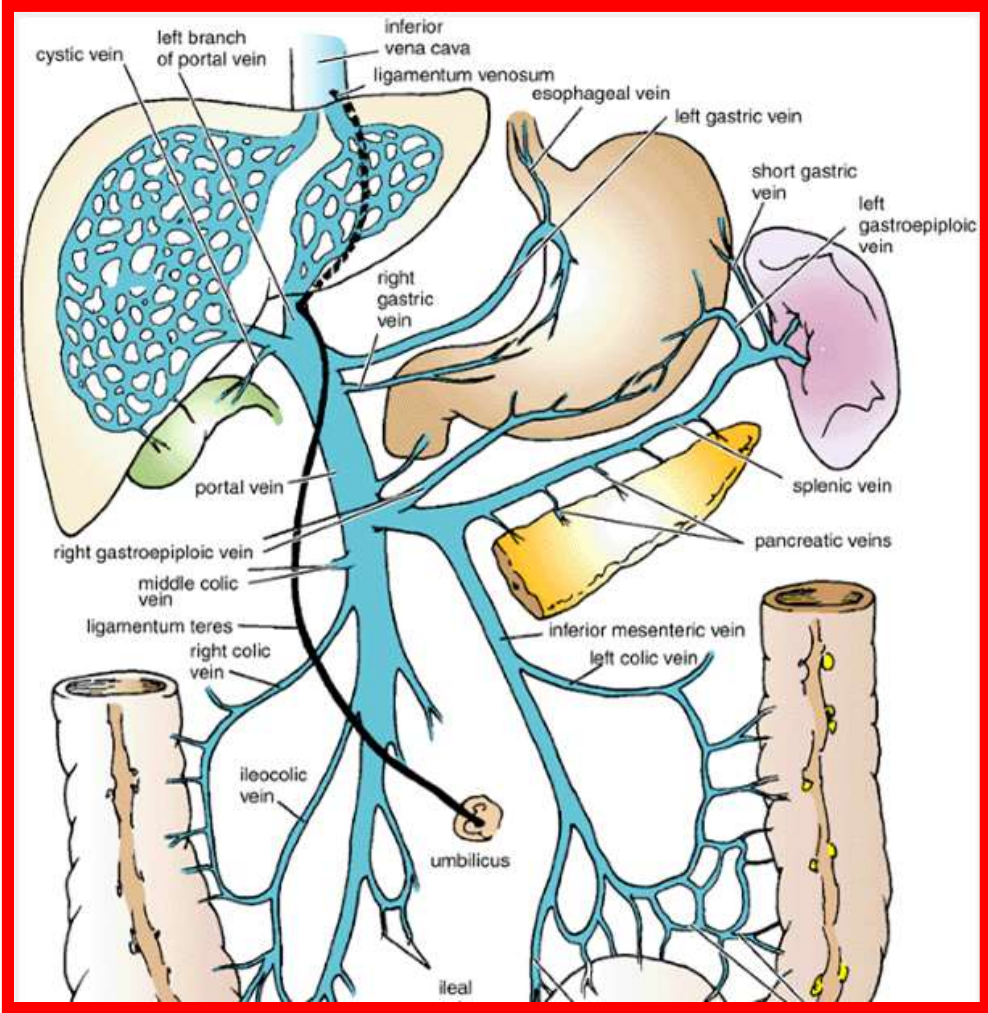
Tributaries of the Portal Vein



Tributaries of the Portal Vein

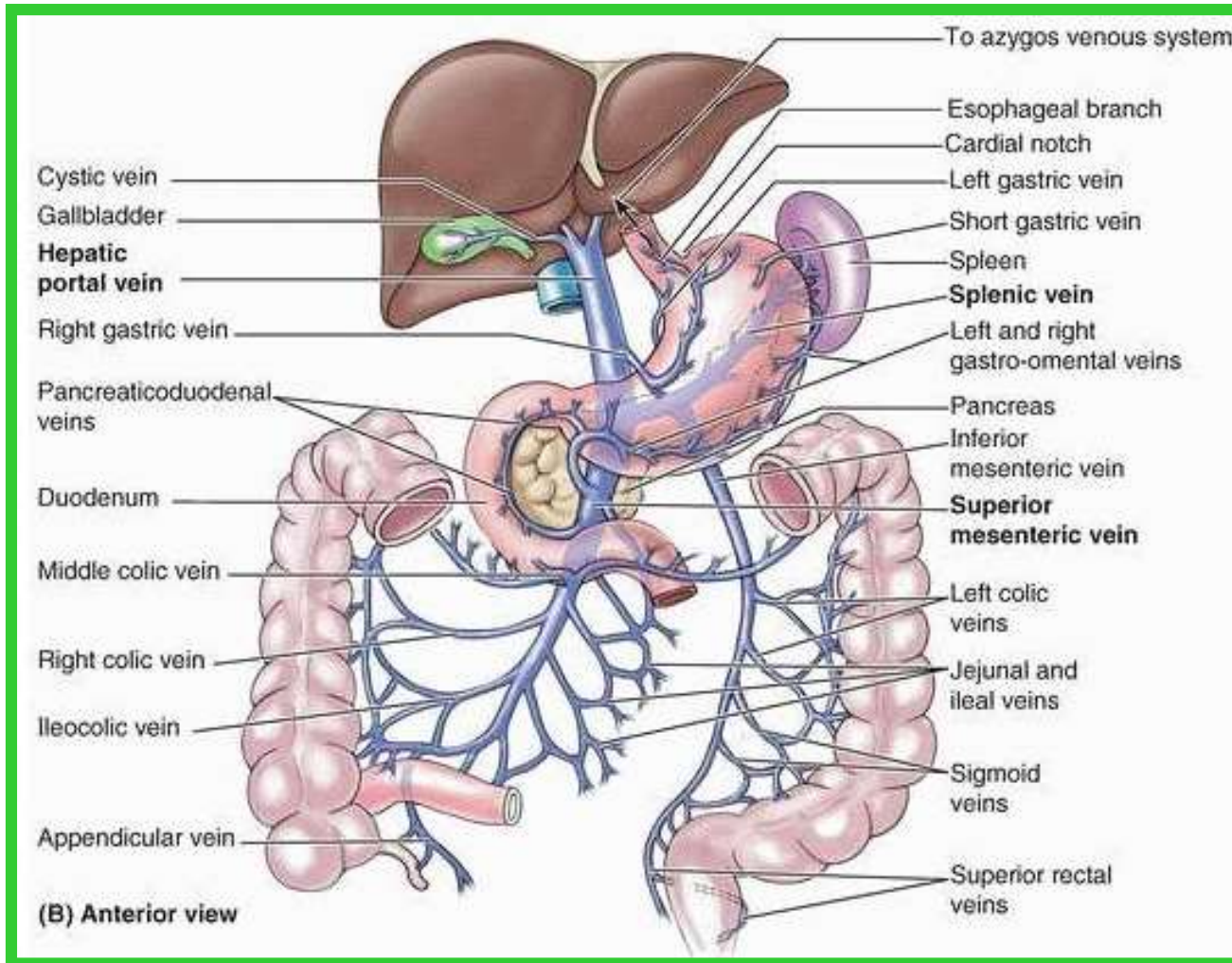


Tributaries of the Portal Vein

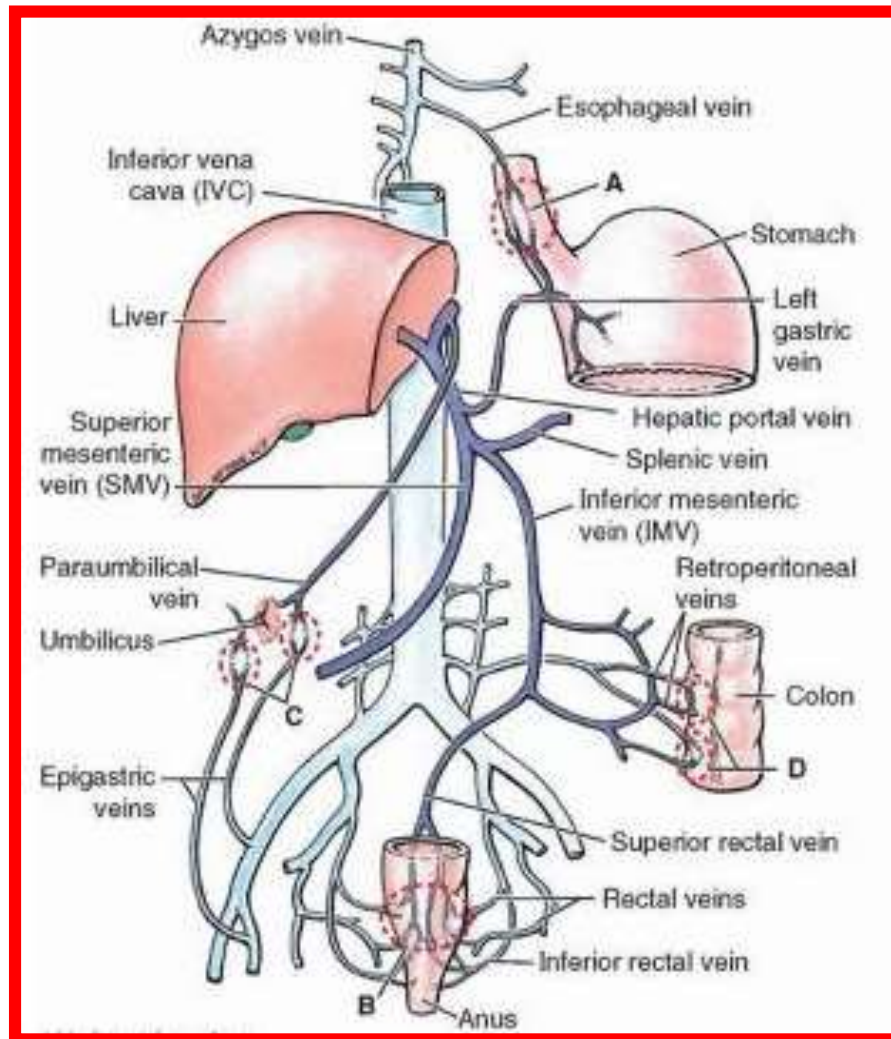


Tributaries of the Portal Vein

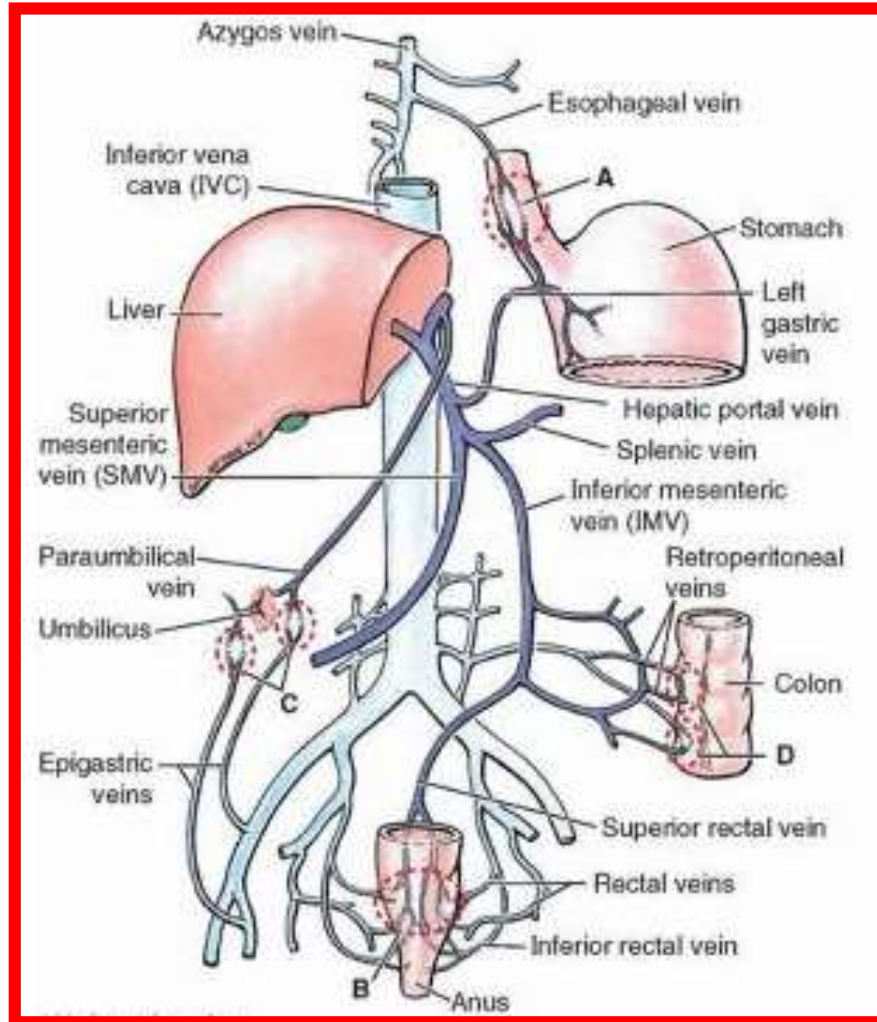
Cystic veins: These veins either drain the gallbladder directly into the liver or join the portal vein



HEPATIC PORTAL VEIN AND PORTAL-SYSTEMIC ANASTOMOSES

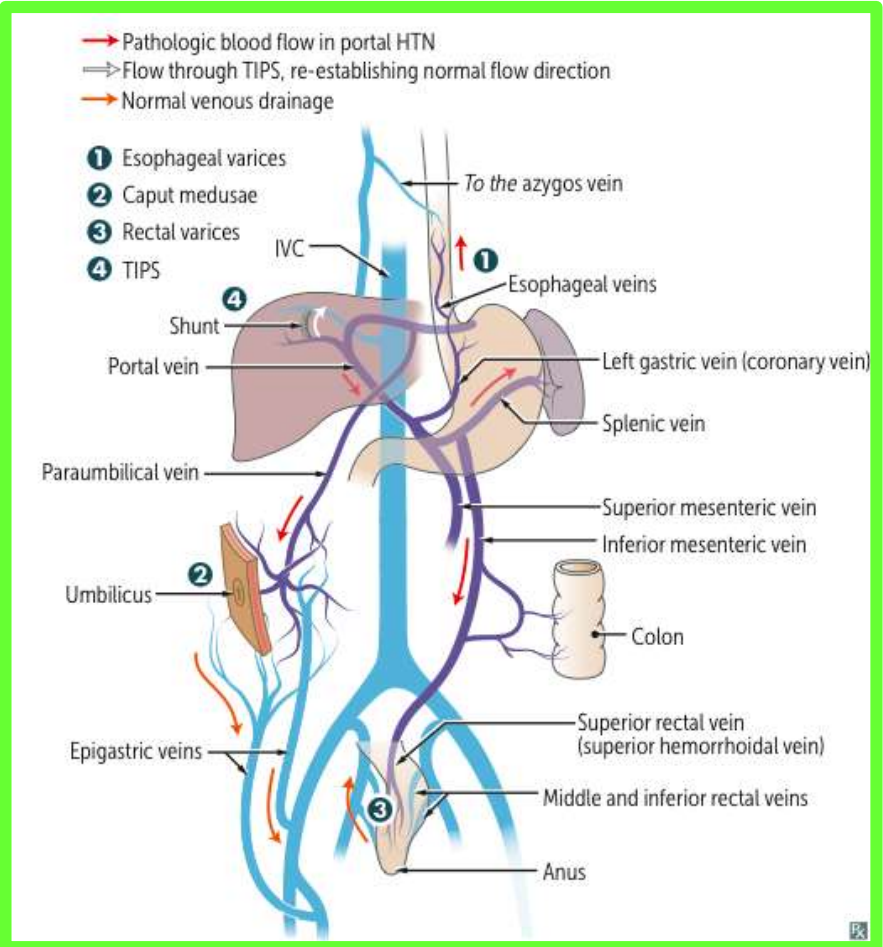
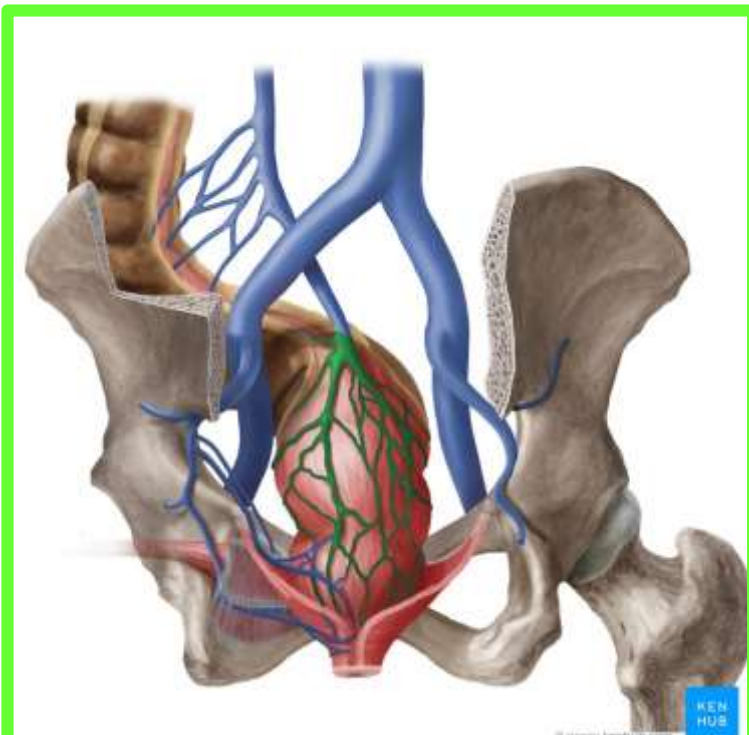


HEPATIC PORTAL VEIN AND PORTAL-SYSTEMIC ANASTOMOSES



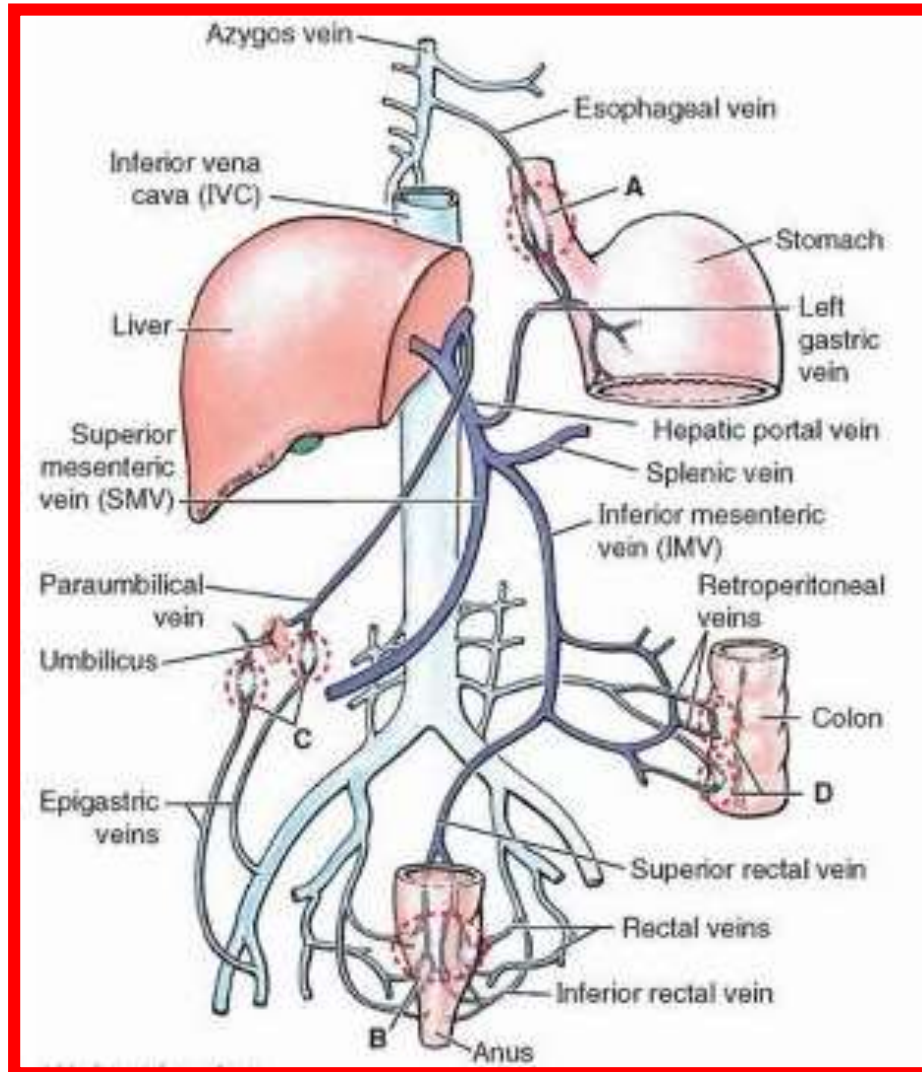
HEPATIC PORTAL VEIN AND PORTAL-SYSTEMIC ANASTOMOSES

Dr Aiman Al-Maathidy
Thursday 18 July 2019
34

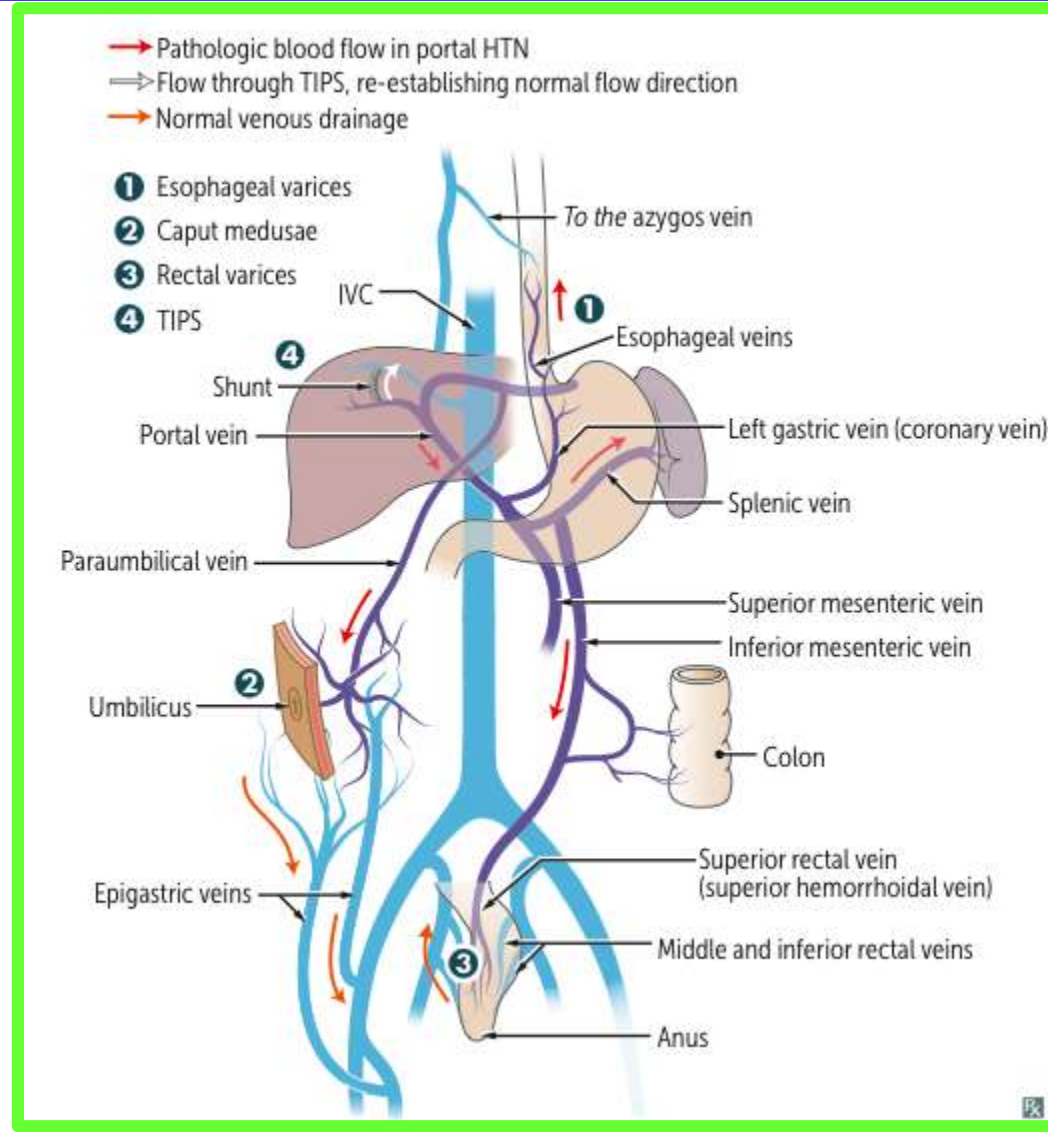


HEPATIC PORTAL VEIN AND PORTAL-SYSTEMIC ANASTOMOSES

Dr Aiman Al-Maathidy
Thursday 14 April 2022



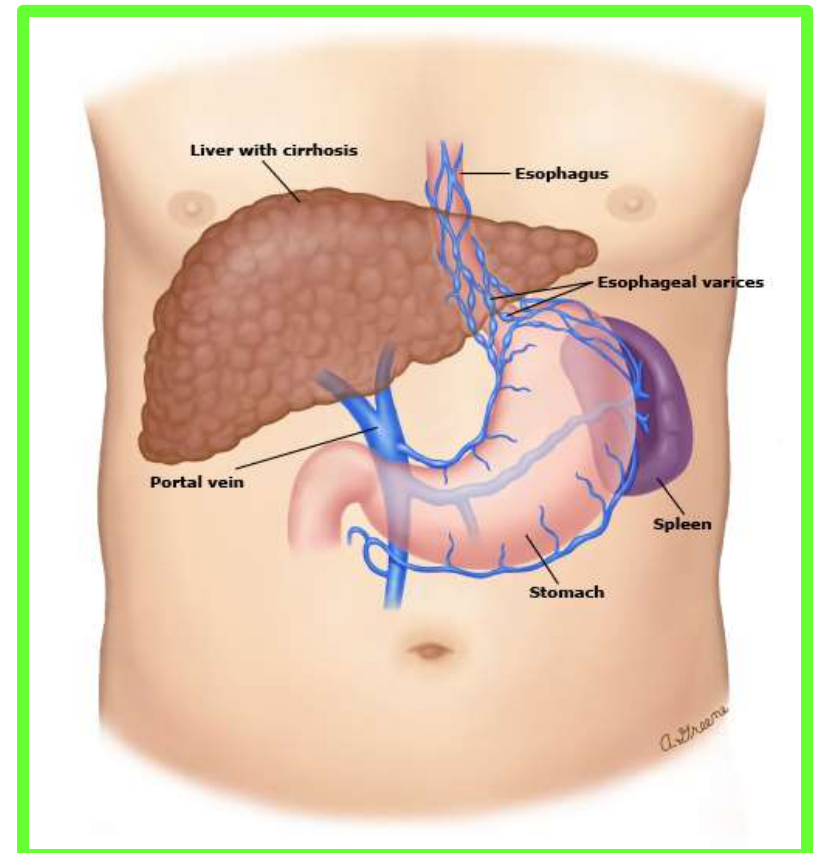
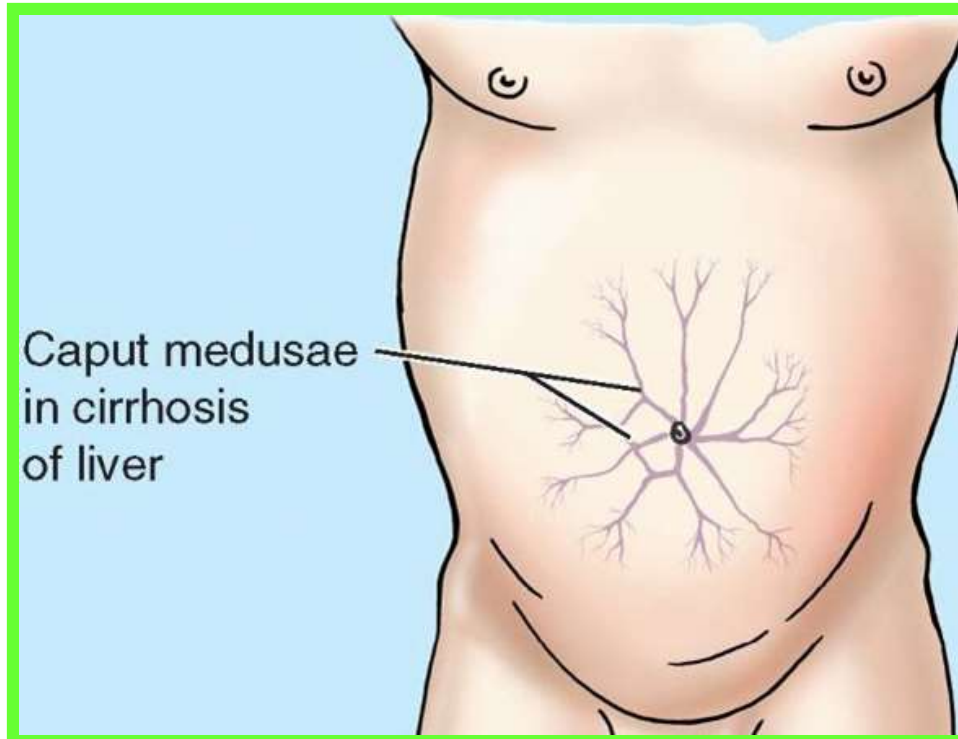
HEPATIC PORTAL VEIN AND PORTAL-SYSTEMIC ANASTOMOSES



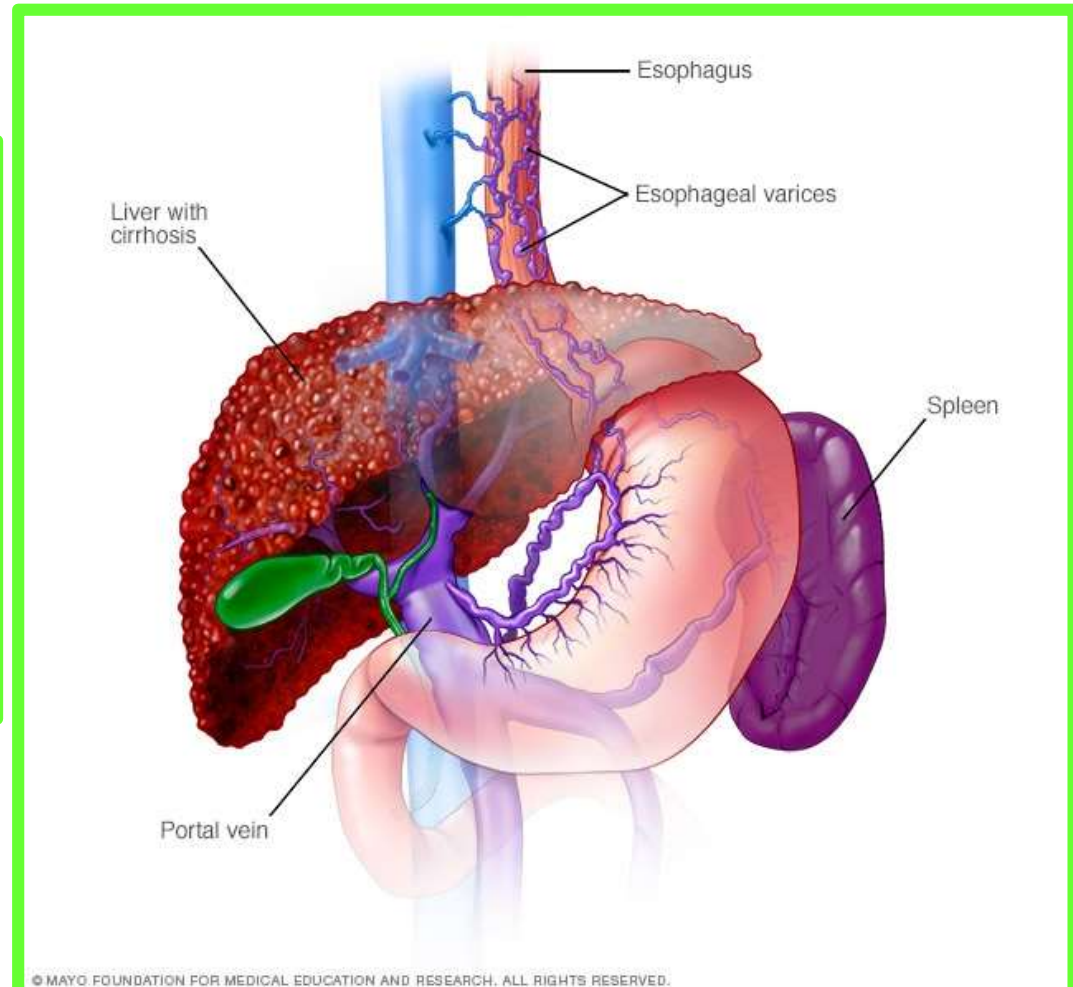
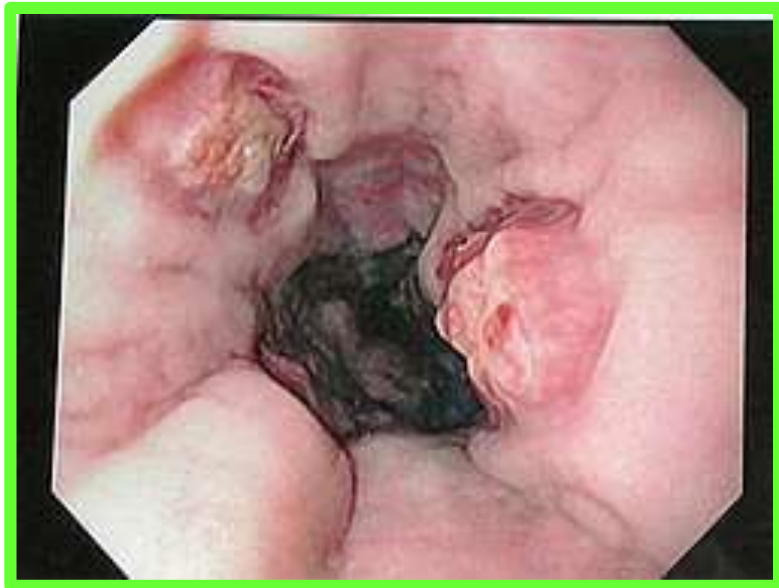Portal Hypertension

Dr Aiman Al-Maathidy
Thursday 14 April 2022

When **scarring and fibrosis from cirrhosis of the liver obstruct the hepatic portal vein**, pressure rises in the hepatic portal vein and its tributaries, producing **portal hypertension**. At the sites of **anastomoses between portal and systemic veins**, portal hypertension produces **enlarged varicose veins** and blood flow from the portal to the systemic system of veins



Portal Hypertension



Dr Aiman Al-Maathidy
Thursday 14 April 2022
38

Portal Hypertension

