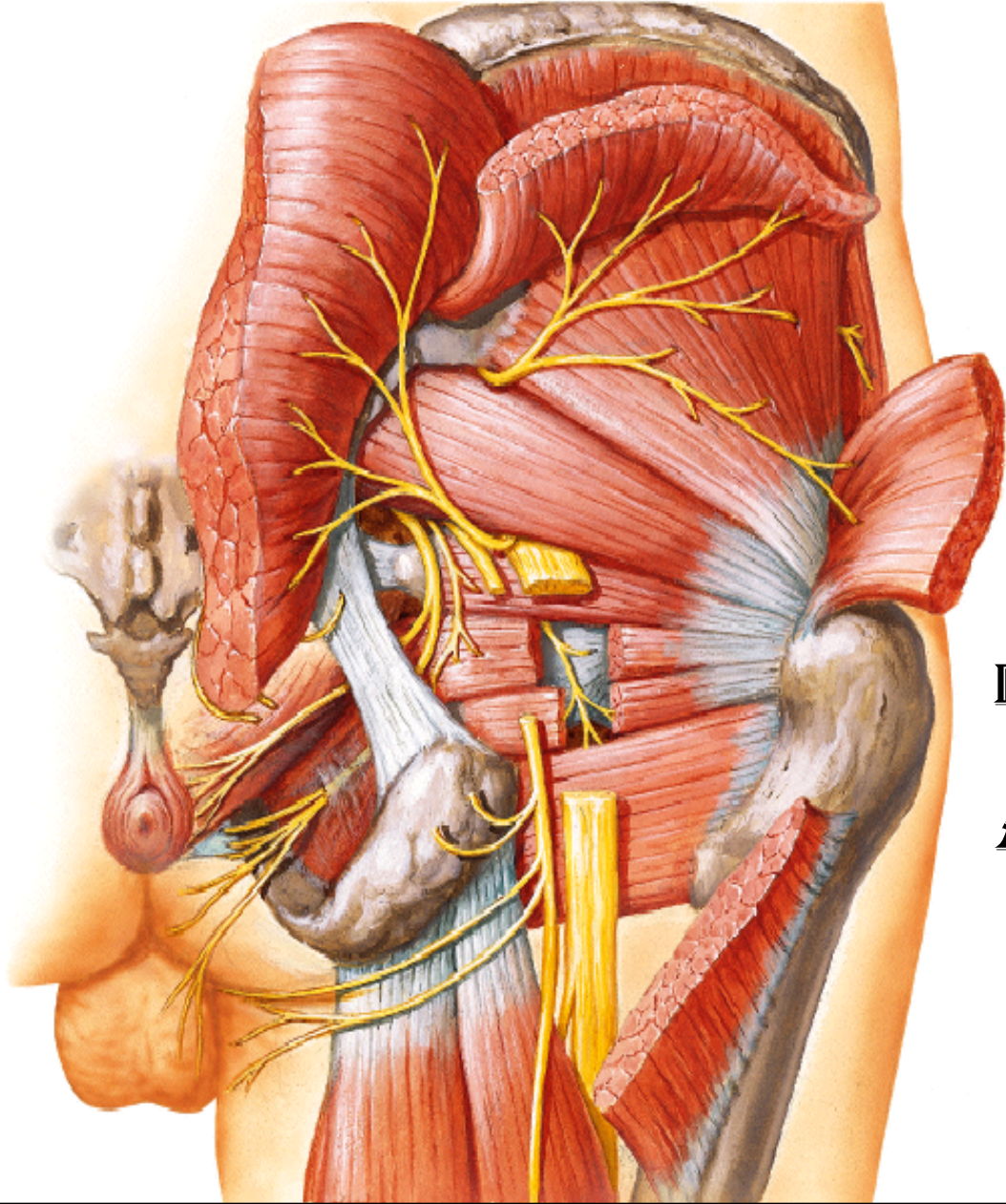


GLUTEAL REGION



BY

DR ABULMAATY MOHAMED
ASSISTANT PROFESSOR
ANATOMY & EMBRYOLOGY
MUTAH UNIVERSITY

LIGAMENTS

sacrospinous lig. :

From tip of ischial spine.

To margin of last sacral &
1st coccygeal vertebrae

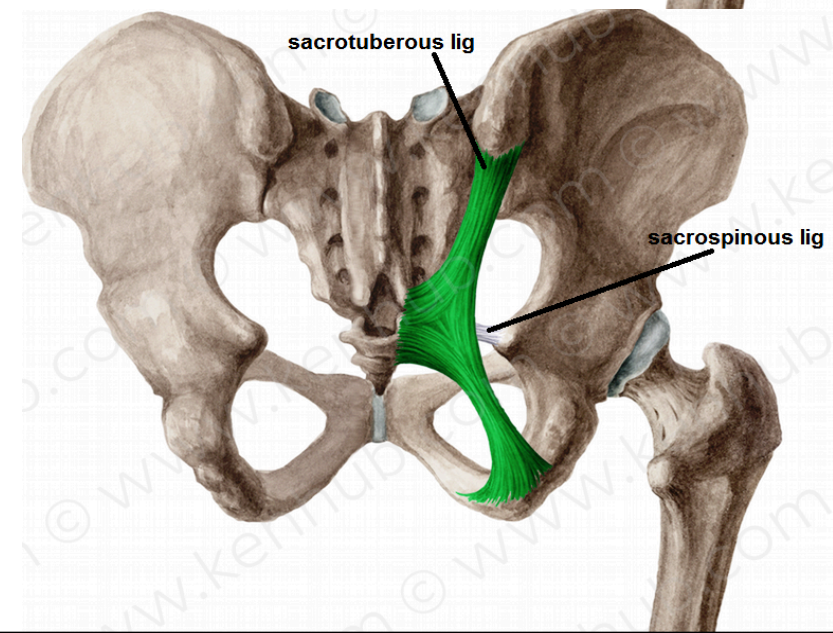
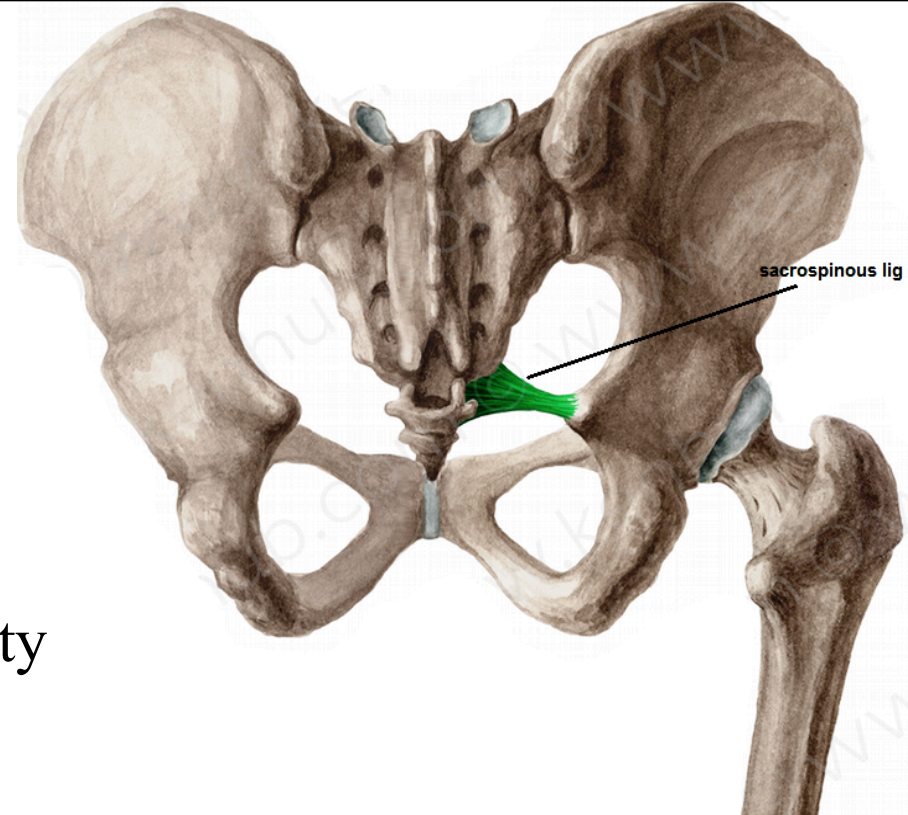
sacrospinous lig. :

From medial border of ischial tuberosity

To back of sacrum & coccyx

Functions

-transform sciatic notches into foramina



MUSCLES

DEEP MUSCLES

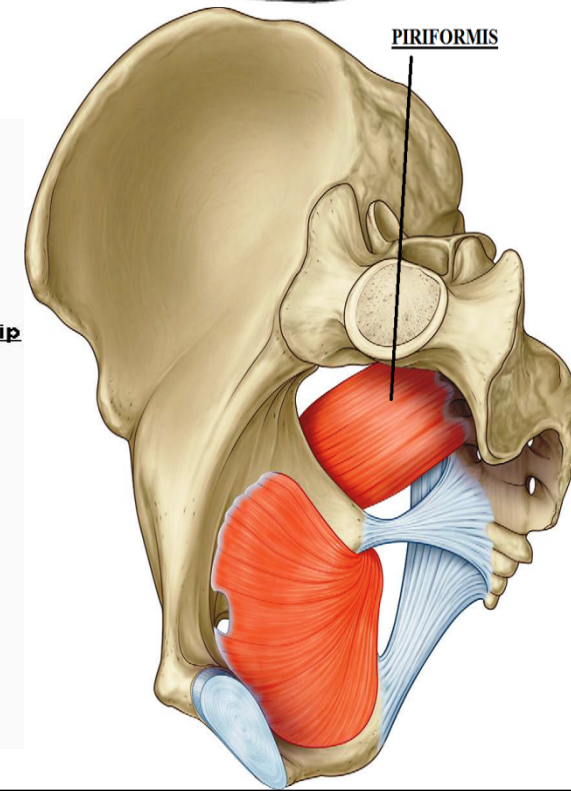
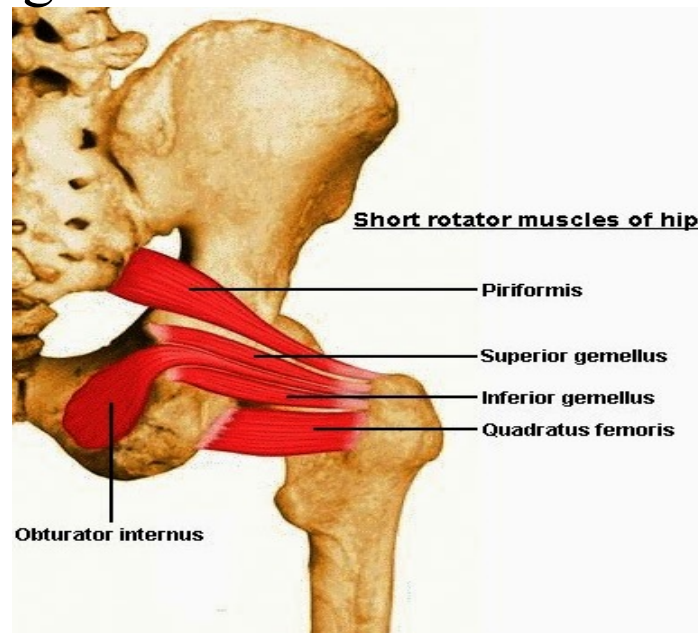
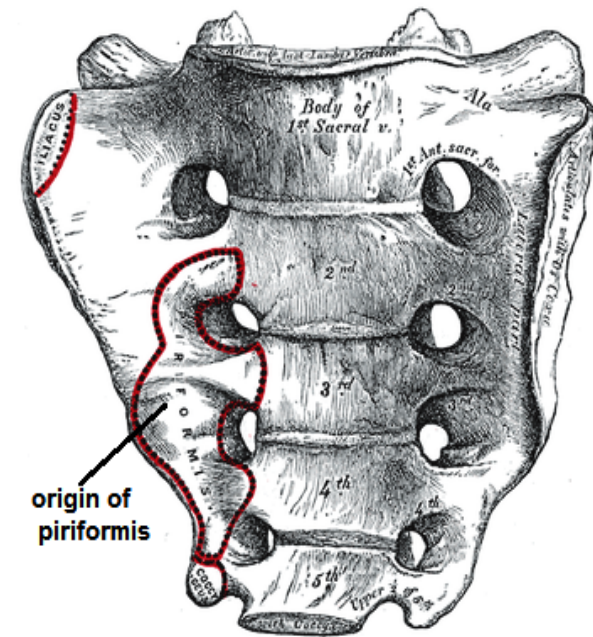
piriformis

O.:- anterior surface of middle 3 sacral vertebrae

I.:- pass through greater sciatic foramen to upper border of greater trochanter

N.S.:- sacral plexus (S1, 2 nerves)

A.:- lateral rotation of thigh



MUSCLES

DEEP MUSCLES

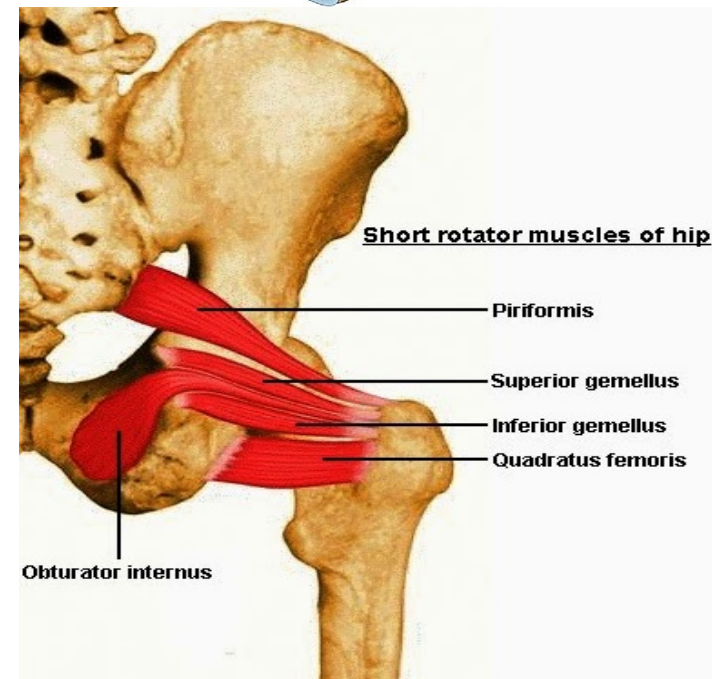
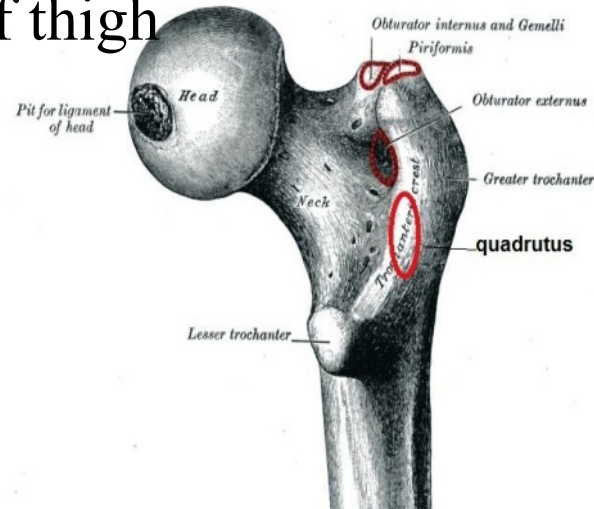
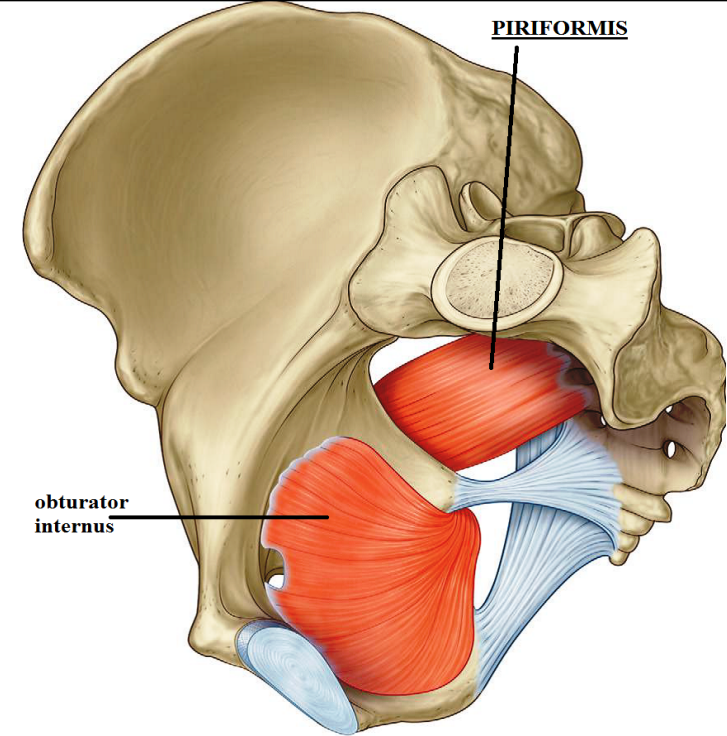
obturator internus

O.:- inner surface of obturator membrane & the surrounding bone

I.:- pass through lesser sciatic foramen to insert in greater trochanter above trochanteric fossa

N.S.:- sacral plexus, n. to obturator internus

A.:- lateral rotation of thigh



MUSCLES

DEEP MUSCLES

superior gemellus

O.:- upper border of lesser sciatic notch

I.:- upper border of tendon of obturator internus
then to medial surface of greater trochanter

N.S.:-n. to obturator internus

A.:- lateral rotation of thigh

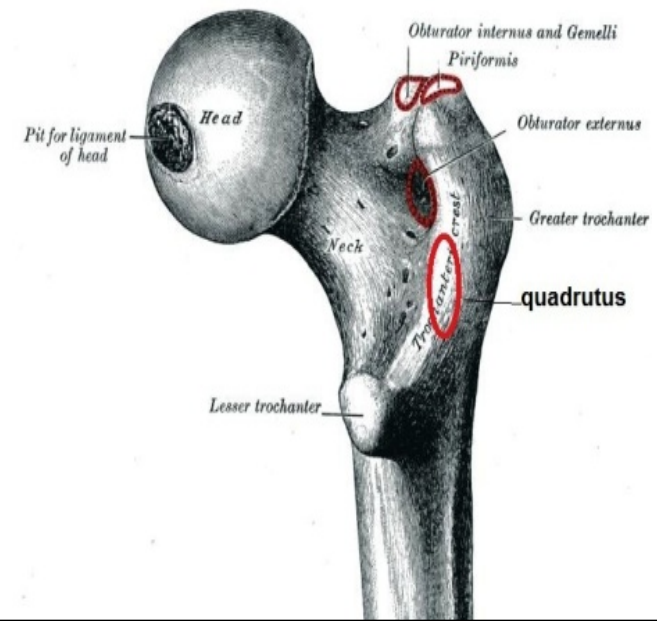
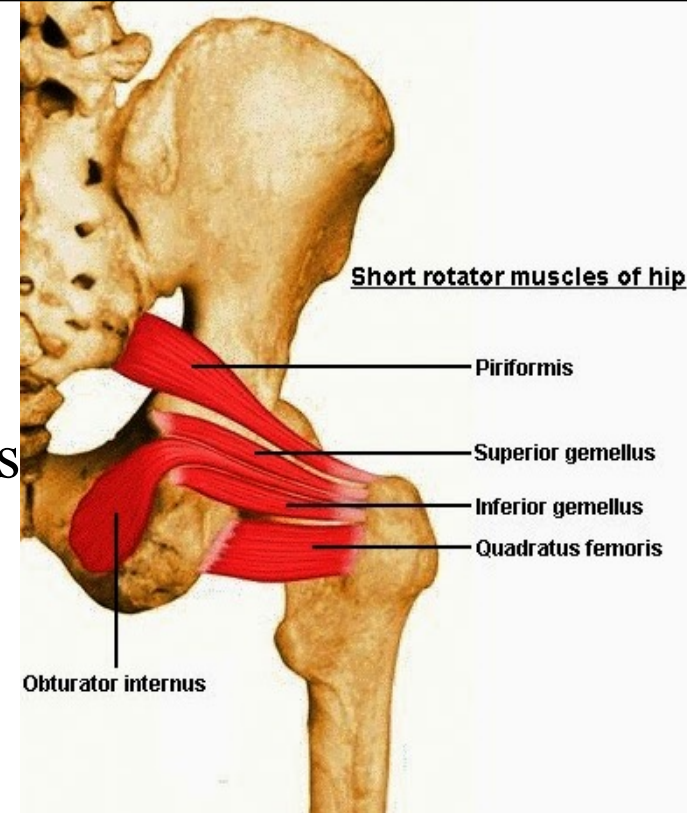
inferior gemellus

O.:- lower border of lesser sciatic notch

I.:- lower border of tendon of obturator internus
then to medial surface of greater trochanter

N.S.:-n. to quadratus femoris

A.:- lateral rotation of thigh



MUSCLES

DEEP MUSCLES

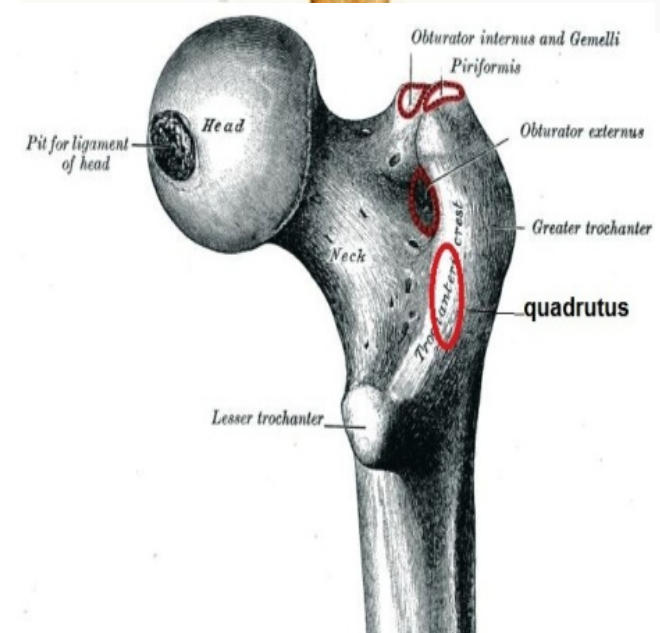
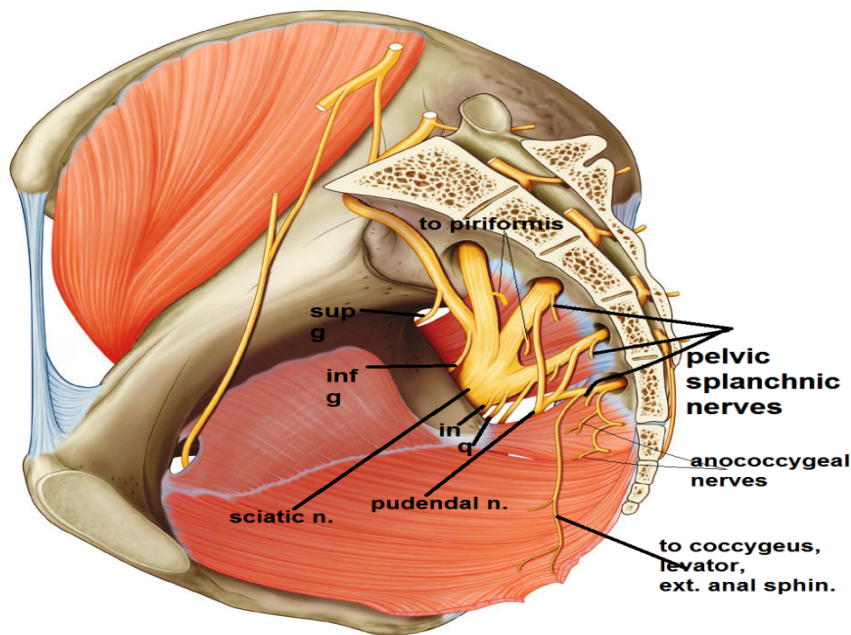
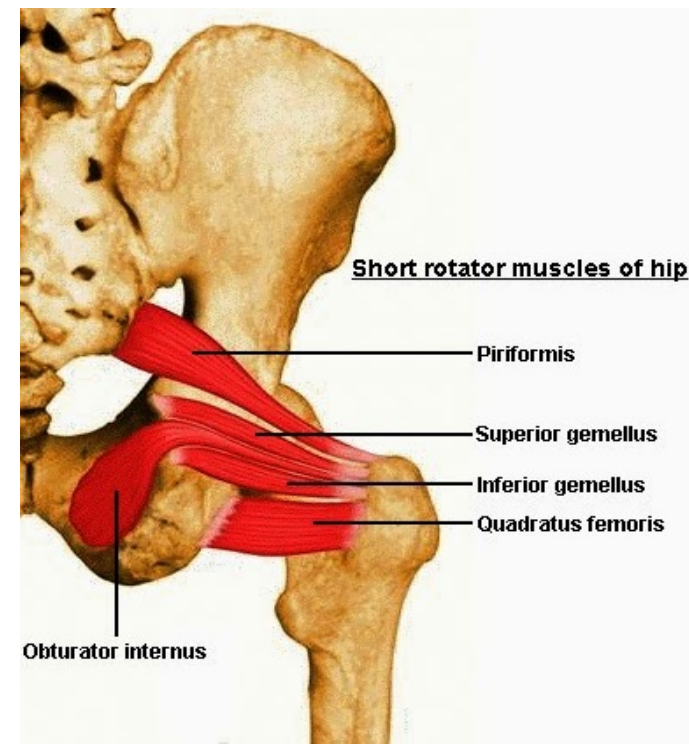
quadratus femoris

O.:- Lateral border of ischial tuberosity

I.:- quadrate tubercle

N.S.:- sacral plexus, n. to quadratus femoris

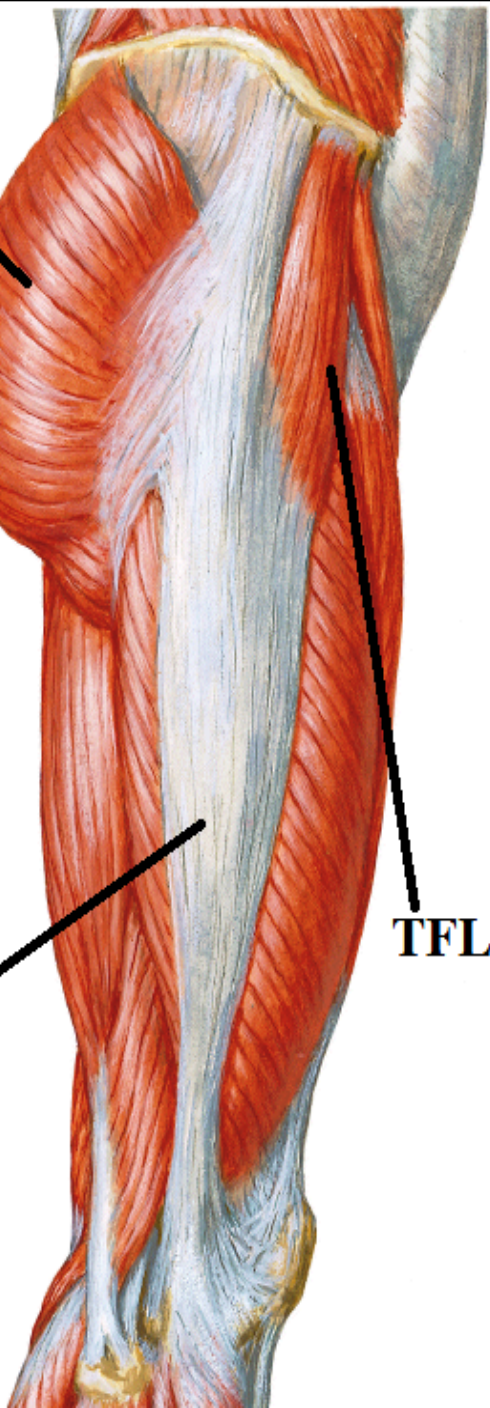
A.:- lateral rotation of thigh



G Mx

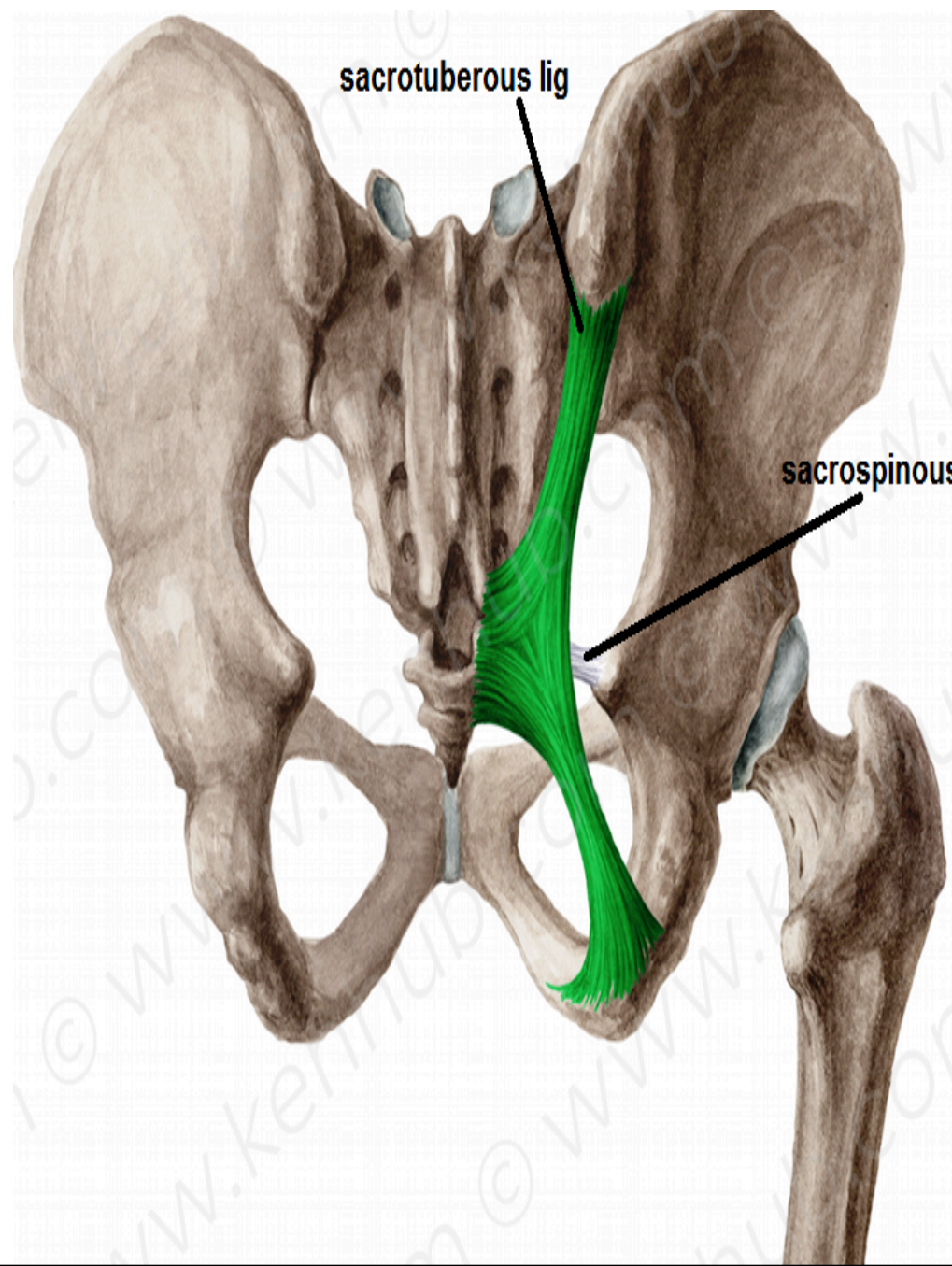
ITT

TFL



sacrospinous lig

sacrospinous lig



MUSCLES

SUPERFICIAL MUSCLES

Gluteus minimus:

O.: outer surface of ilium()ant.& inferior gluteal lines

I. : front of greater trochanter.

gluteus medius :

O. : outer surface of ilium (). post. & ant. gluteal lines

I. :lateral aspect of greater trochanter.

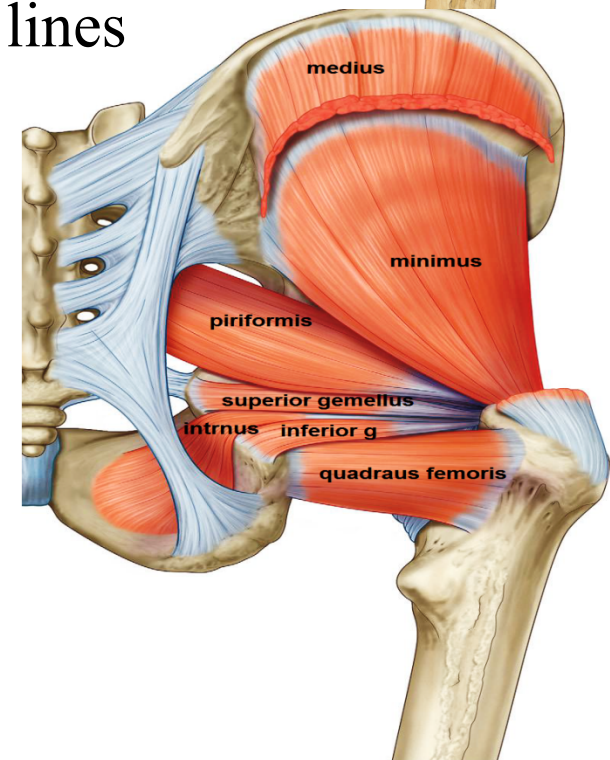
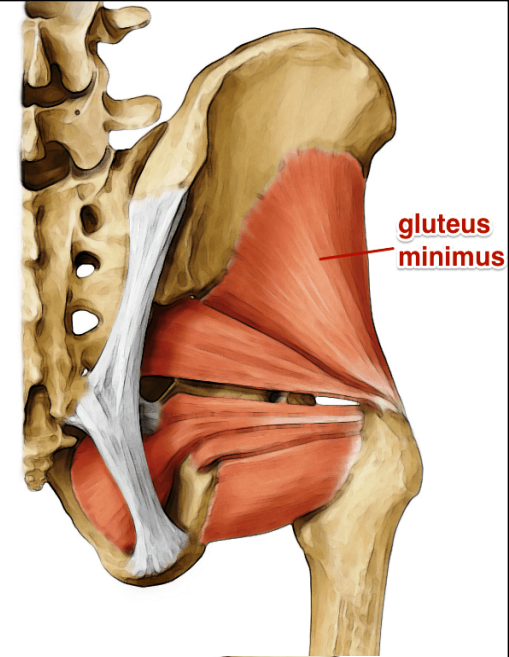
N.S : both supplied by superior gluteal n.

ACTION :

1- abduction of thigh

2- Medial rotation of thigh by the ant. fibers

3-prevent tilting of pelvis towards unsupported side on standing on one limb so paralysis of these muscles on both sides causes waddling gait



MUSCLES

SUPERFICIAL MUSCLES

gluteus maximus:

O. : outer surface of ilium behind post. gluteal line

Back of sacrum & coccyx &
sacrospinous lig.

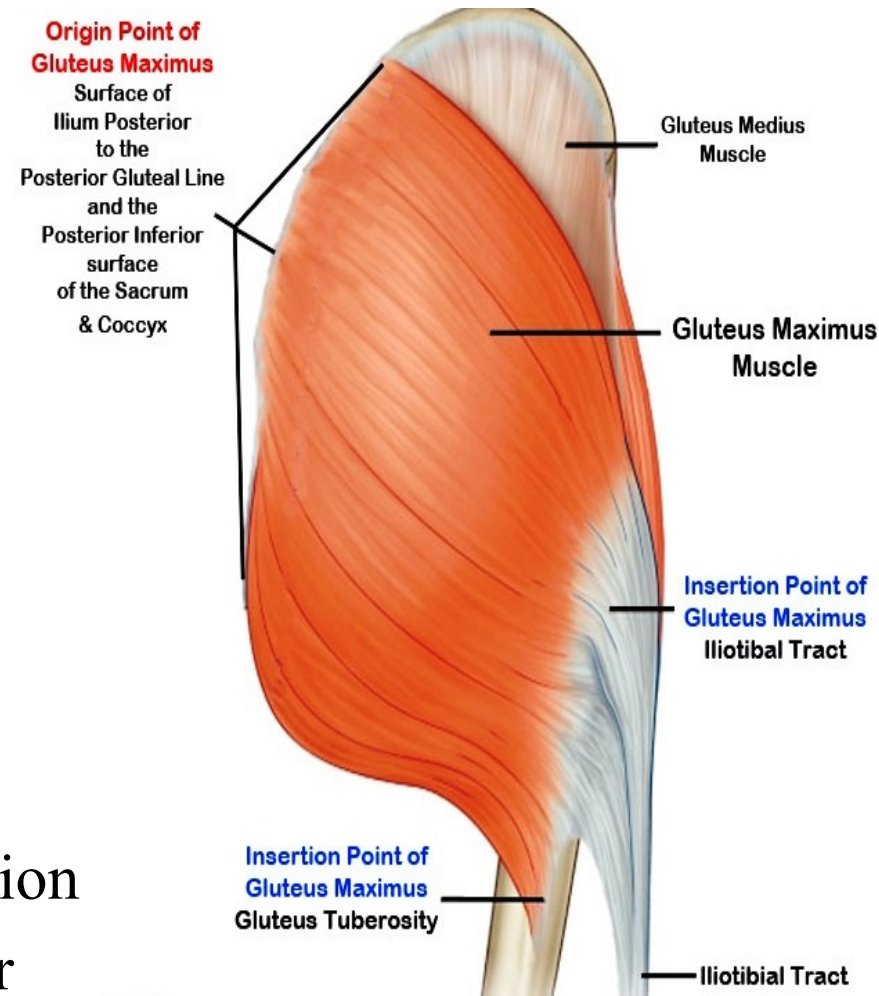
I. : superficial 3 / 4 insert in
post. border of iliotibial tract
deep 1 / 4 insert in
gluteal tuberosity

N.S. : inferior gluteal n.

A. :

1-main extensor of hip joint

2- tense iliotibial tract in standing position
to keep bone of L.L above each other



MUSCLES

SUPERFICIAL MUSCLES

tensor fascia lata :

O.: ant. 5cm of outer lip of iliac crest

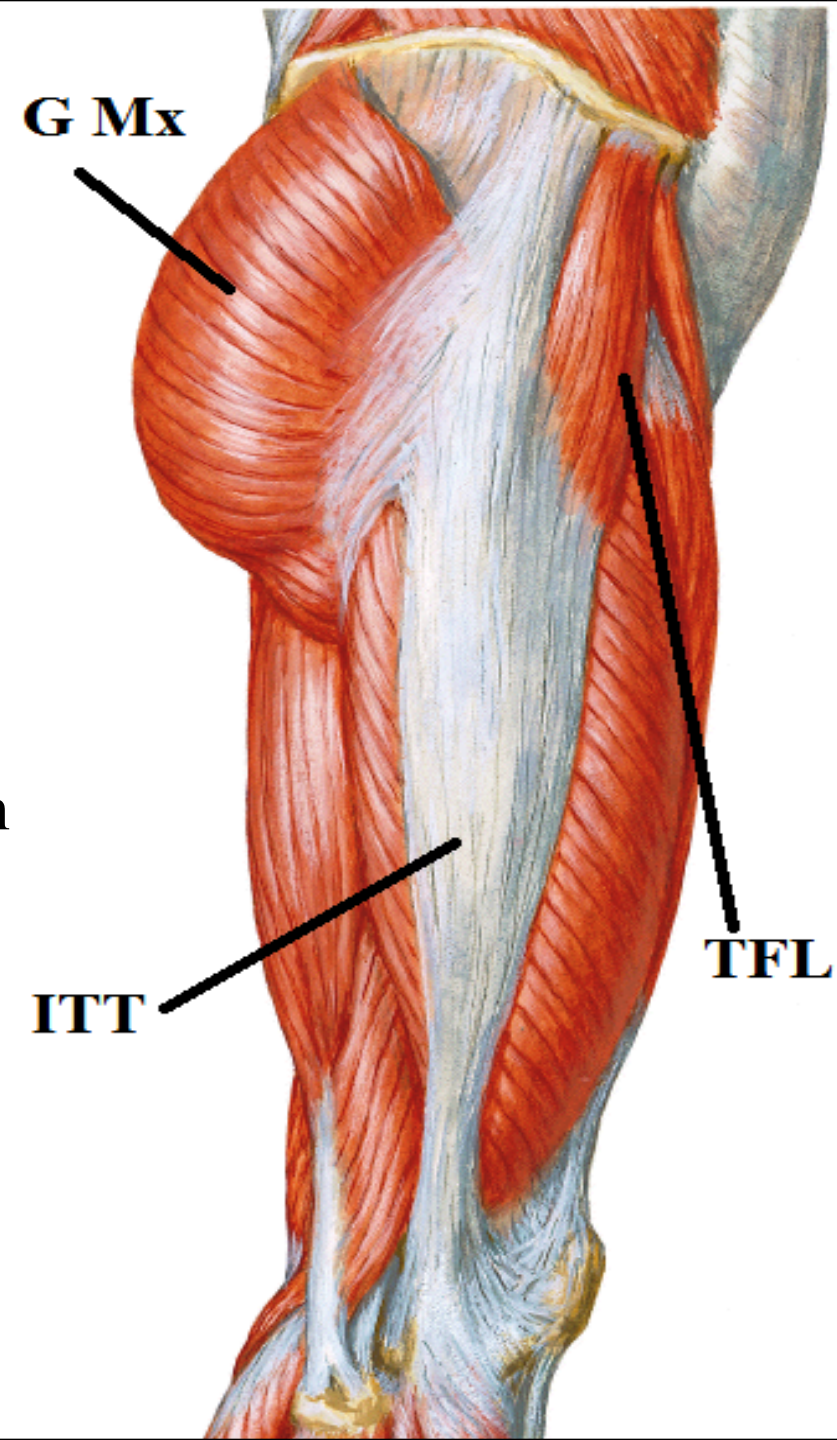
I.: ant. border of iliotibial tract

N.S.: superior gluteal n.

A.:

1-abduction of thigh

2-tense iliotibial tract in standing position
to keep bone of L.L above each other



FORAMINA

greater sciatic foramen :

piriformis

structures above piriformis

superior gluteal n &

superior gluteal vessels

structures below piriformis

inferior gluteal n.&

inferior gluteal vessels

sciatic n.

post. cut. n. of thigh.

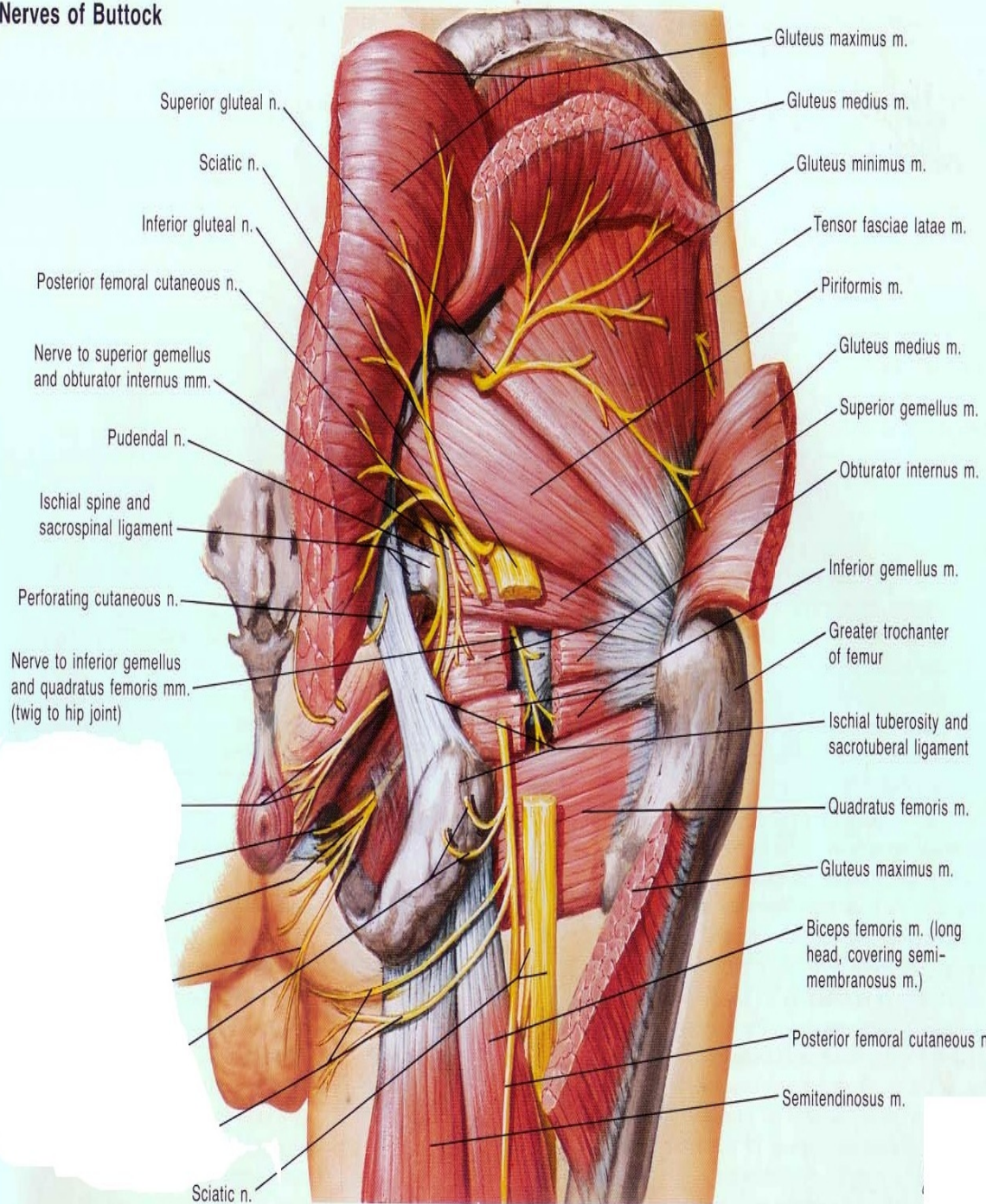
n. to quadratus femoris

n. to obturator internus

int. pudendal vessels

Pudendal n.

Nerves of Buttock

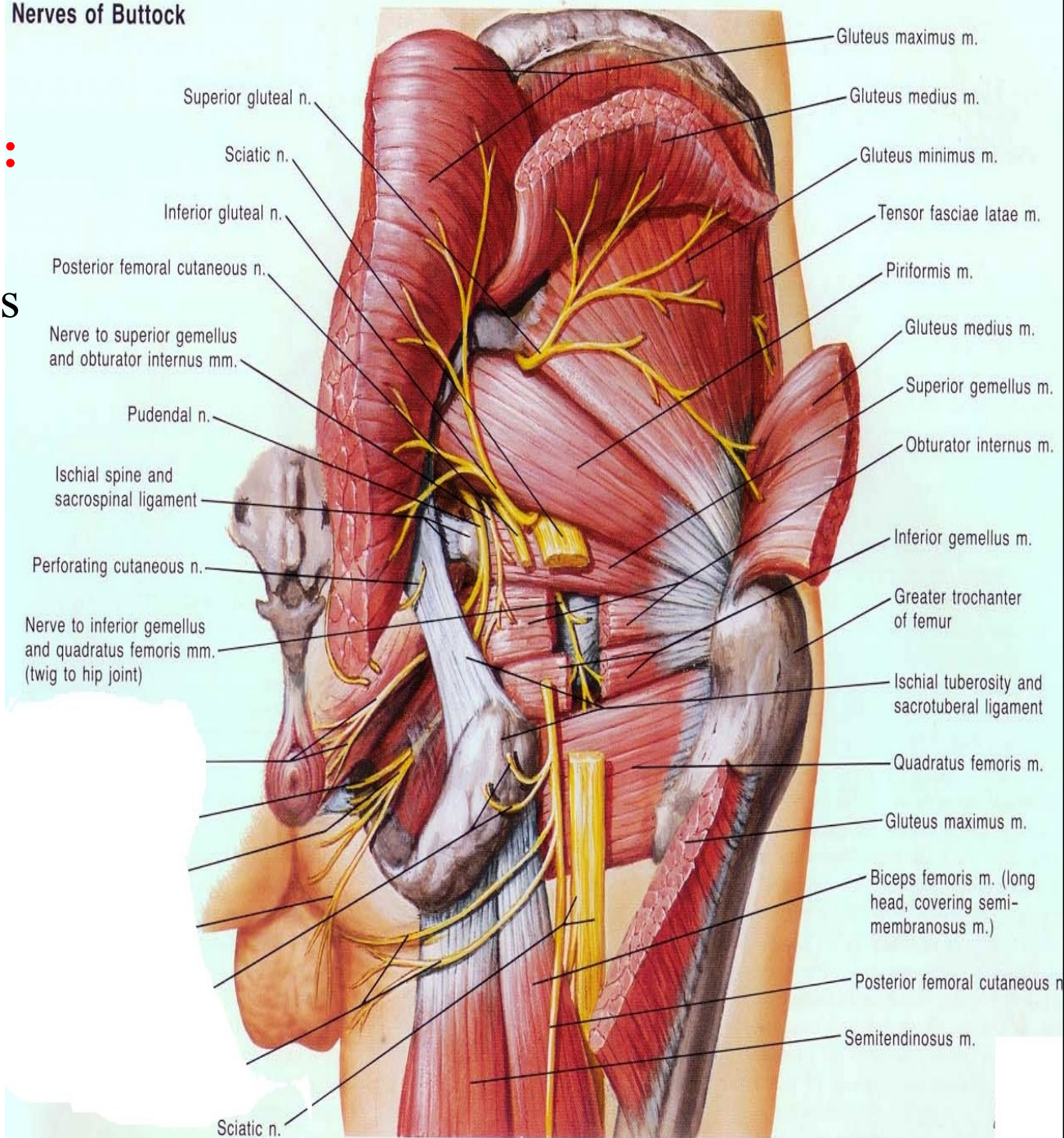


FORAMINA

lesser sciatic foramen :

- obturator internus
- n. to obturator internus
- int. pudendal vessels
- pudendal n.

Nerves of Buttock



NERVES OF GLUTEAL REGION :

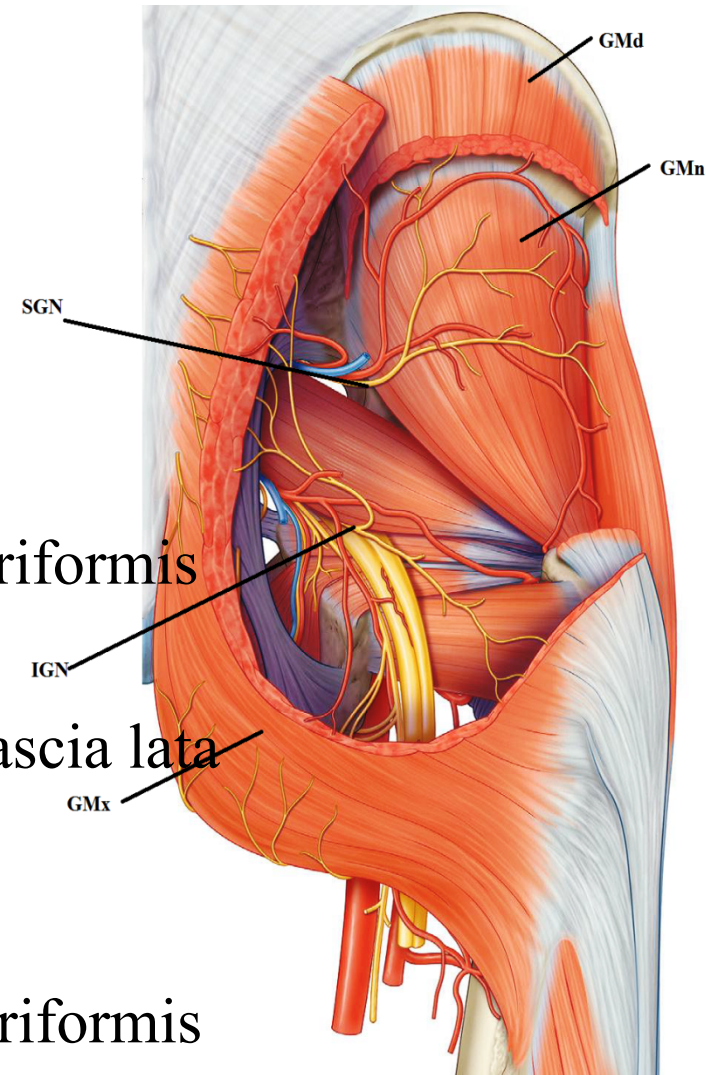
- superior gluteal n. -inferior gluteal n.
- sciatic n -post. cut. n. of thigh
- to Quadratus femoris -n. to obturator internus
- pudendal n.

superior gluteal n.

- arise inside pelvis from sacral plexus
- pass through greater sciatic foramen above piriformis
- pass () gluteus medius & minimus
- supply gluteus medius& minimus & tensor fascia lata

inferior gluteal n. :

- arise inside pelvis from sacral plexus
- pass through greater sciatic foramen below piriformis
- supply gluteus maximus



THANQ