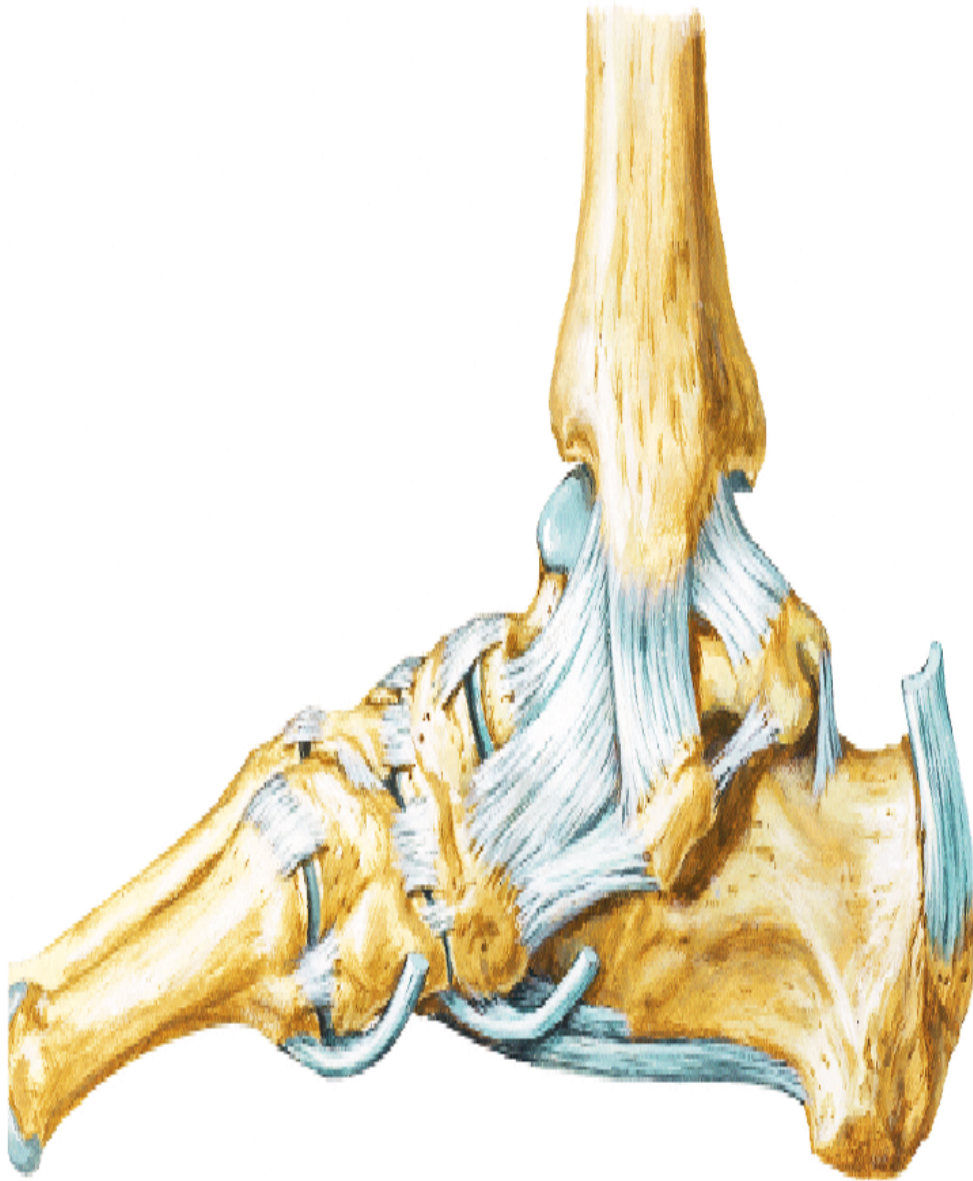

ANKLE JOINT & JOINTS OF FOOT



BY

DR ABULMAATY MOHAMED
ASSISTANT PROFESSOR
ANATOMY & EMBRYOLOGY
MUTAH UNIVERSITY

ANKLE JOINT

Type: synovial

variety: hinge

Articular parts:

Above:

Inferior surface of lower end of tibia,

Inner surface of medial malleolus,

Inner surface of lateral malleolus

Below: talus

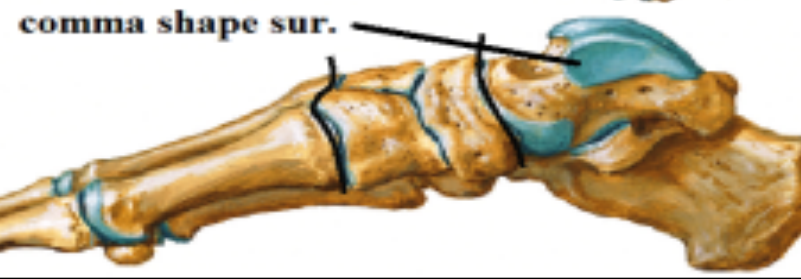
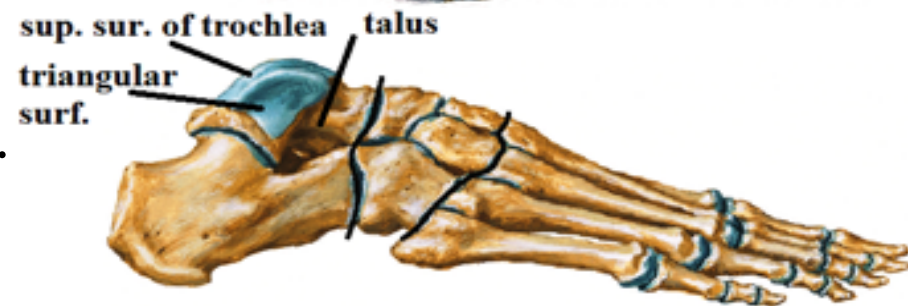
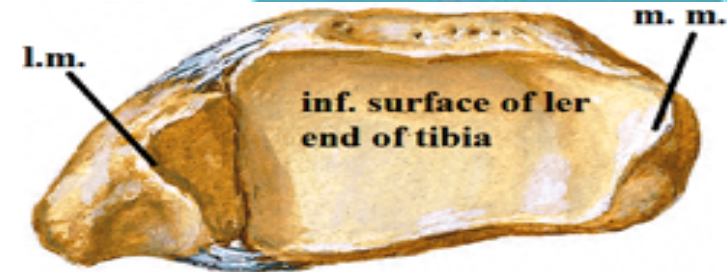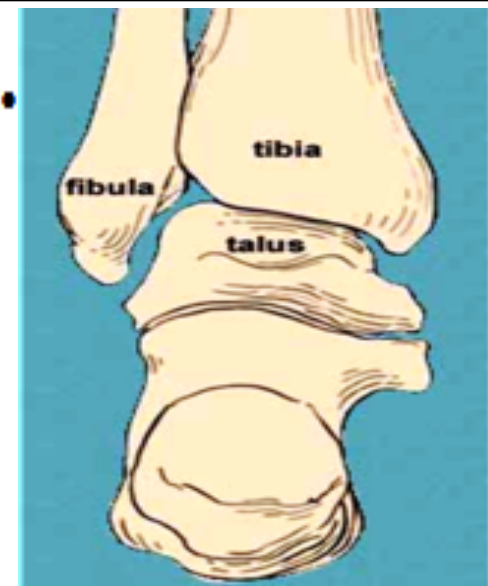
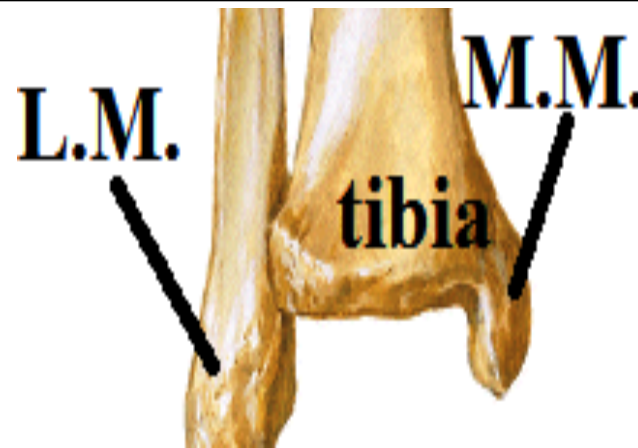Superior surface of trochlea of talus

Comma shaped surface for med. Mall.

Triangular surface for lat. Mall.

Capsule: attach to margins of articular surface. Thin in front, back thick on sides

Synovial membrane: line the capsule



ANKLE JOINT

Ligaments:

1-medial collateral (deltoid) lig.

-One of the strongest ligaments in the body

-Triangular in shape

-Attachment

Apex : medial malleolus

Base:

tuberosity of navicular bones

Plantar calcaneo navicular (spring) ligament

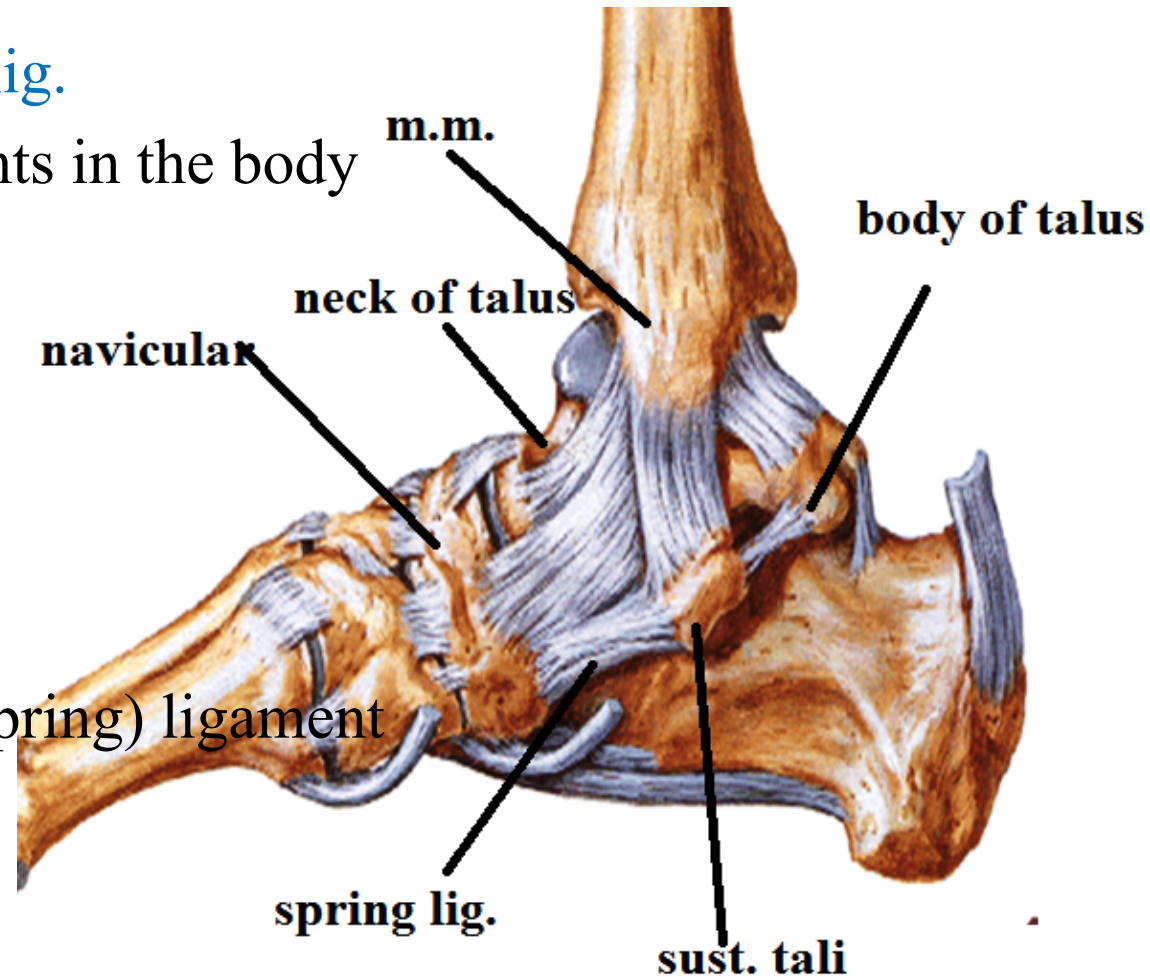
neck of talus

Sustantaculum tali

Body of talus

-Function 1- prevent over eversion of foot

2- maintain the medial long. Arch of foot



ANKLE JOINT

Ligaments:

2-lateral collateral lig.

-weaker

- 3 bands

calcaneo – fibular lig :

From : tip of lateral malleolus

To : lateral surface of calcaneus

ant. talofibular lig :

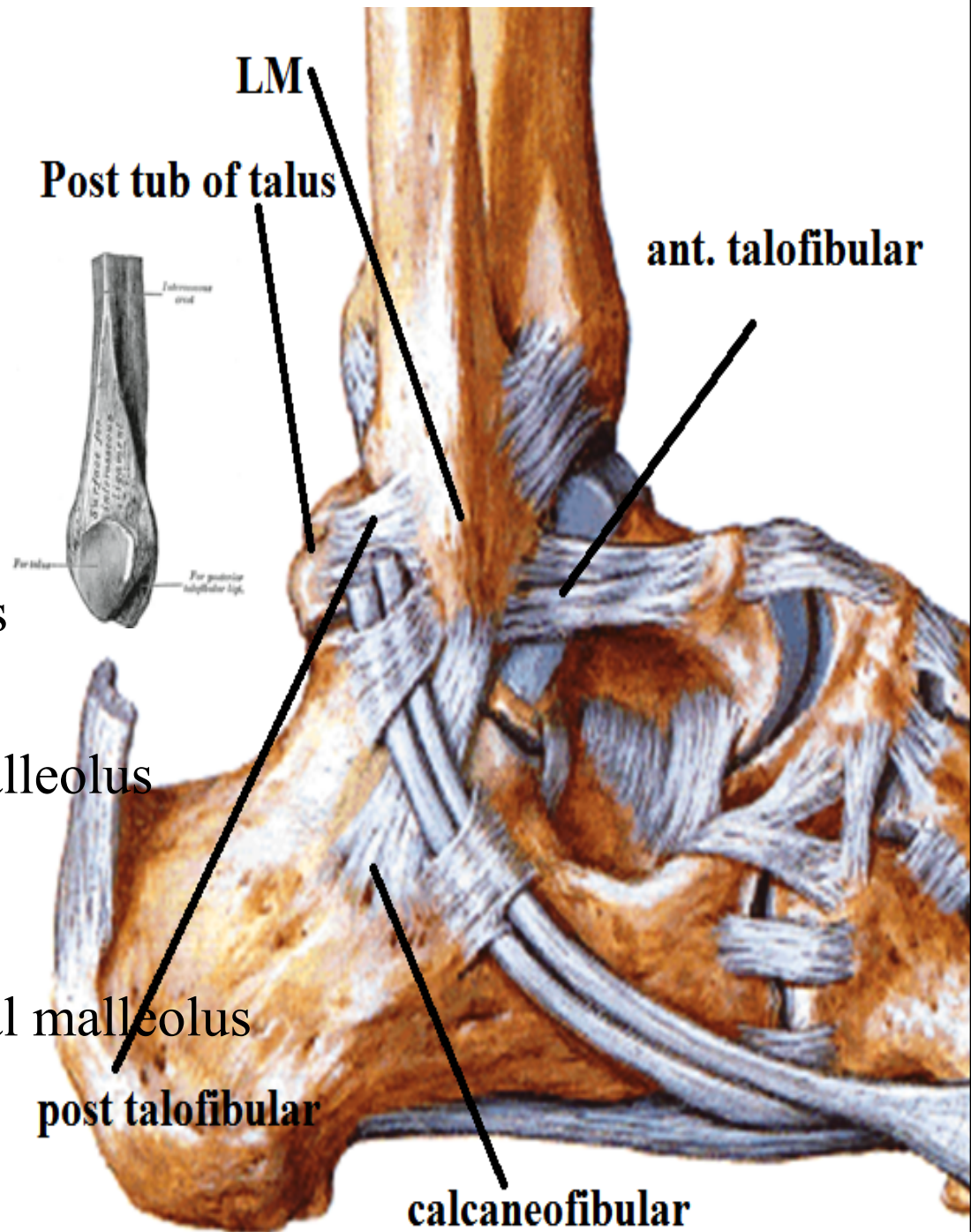
From : ant. border of lateral malleolus

To : neck of talus

post. talofibular lig :

From : malleolar fossa of lateral malleolus

To : posterior tubercle of talus



ANKLE JOINT

Relations:

Anteriorly

Structures deep to the extensor retinacula

1-**Tom**: Tibialis ant.

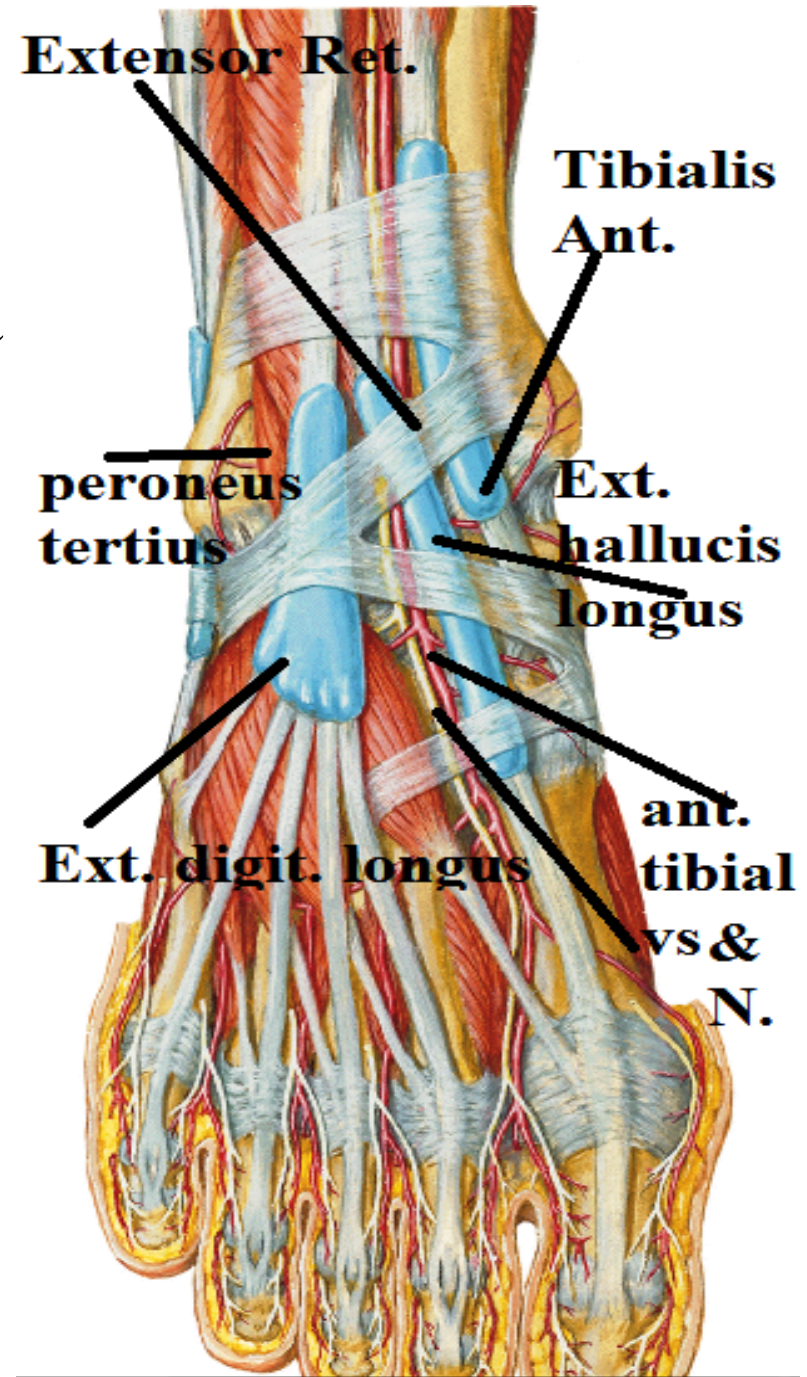
2-**Has**: ext. hallucis longus

3-**Very**: ant. tibial vessels

4-**Nice**: ant. tibial n.

5-**Dog**: ext. digitorum longus

6-**& Pigs**: peroneus tertius



ANKLE JOINT

Relations:

posteromedially

Structures deep to the flexor retinaculum

- 1-Tom: Tibialis post.
- 2-Does: flexor digitorum longus
- 3-Very: post. tibial vessels
- 4-Nice: post. tibial n.
- 5-hats: flexor hallucis longus

Posterolaterally

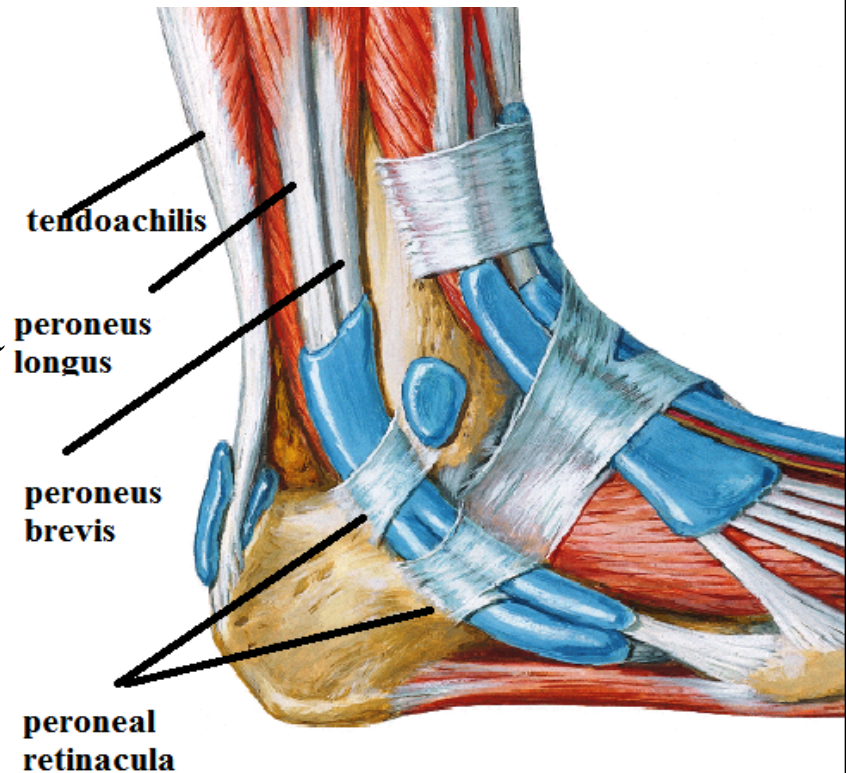
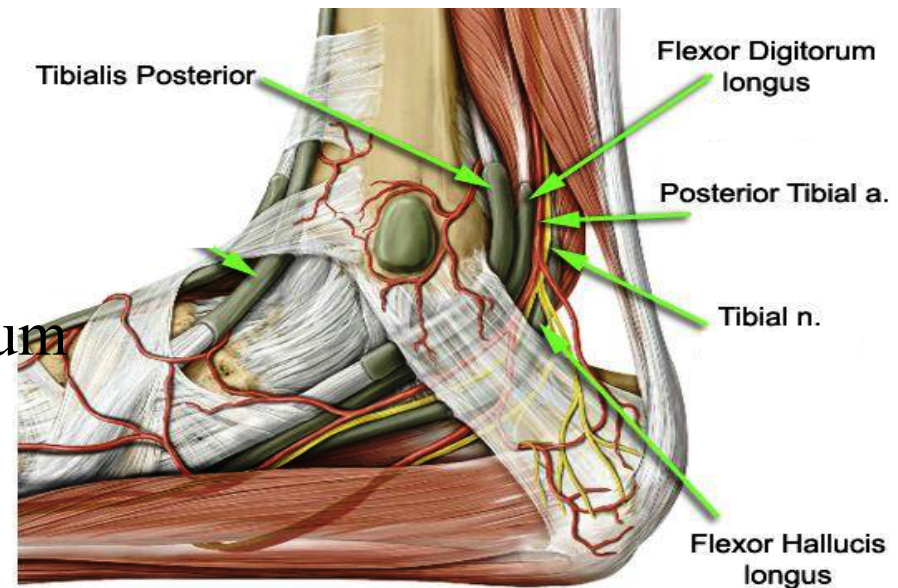
Structures deep to the peroneal retinacula

Tendons of peroneus longus & brevis

posterior

Tendoachilis

N.S. Ant. & post. Tibial nerves



ANKLE JOINT

Movements:

only dorsiflexion & plantar flexion

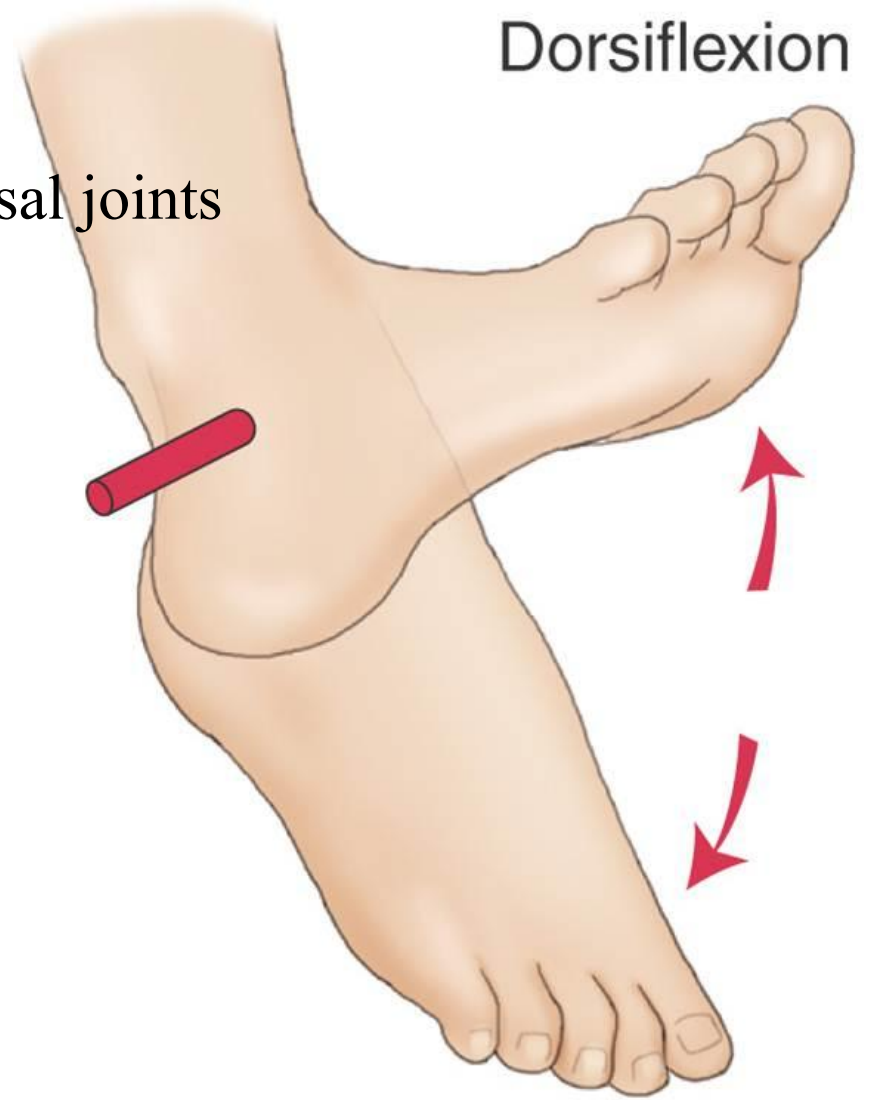
But Eversion & inversion occur at tarsal joints

Dorsiflexion (extension): by

- 1-tibialis ant
- 2-extensor hallucis longus
- 3-extensor digi longus
- 4-peroneus tertius

Plantar flexion (flexion) : by

- 1-gasterocnemius
- 2-soleus
- 3-plantaris
- 4-tibialis post.
- 5-flexor hall. Longus
- 6-flexor digi longus



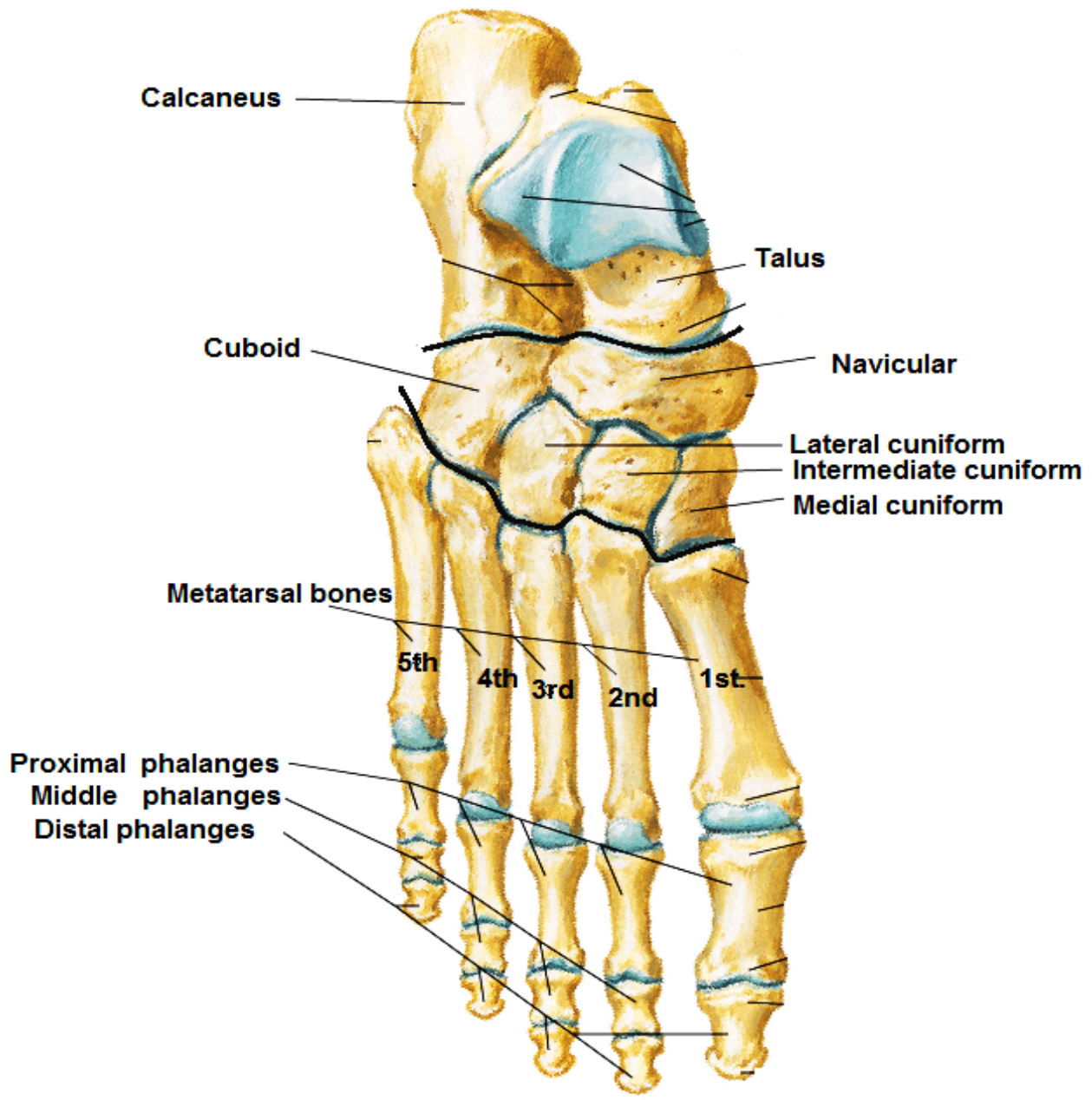
Dorsiflexion

Plantarflexion

JOINTS OF FOOT

Bones of Foot

Dorsal View



JOINTS OF FOOT

1- SUBTALAR JOINT

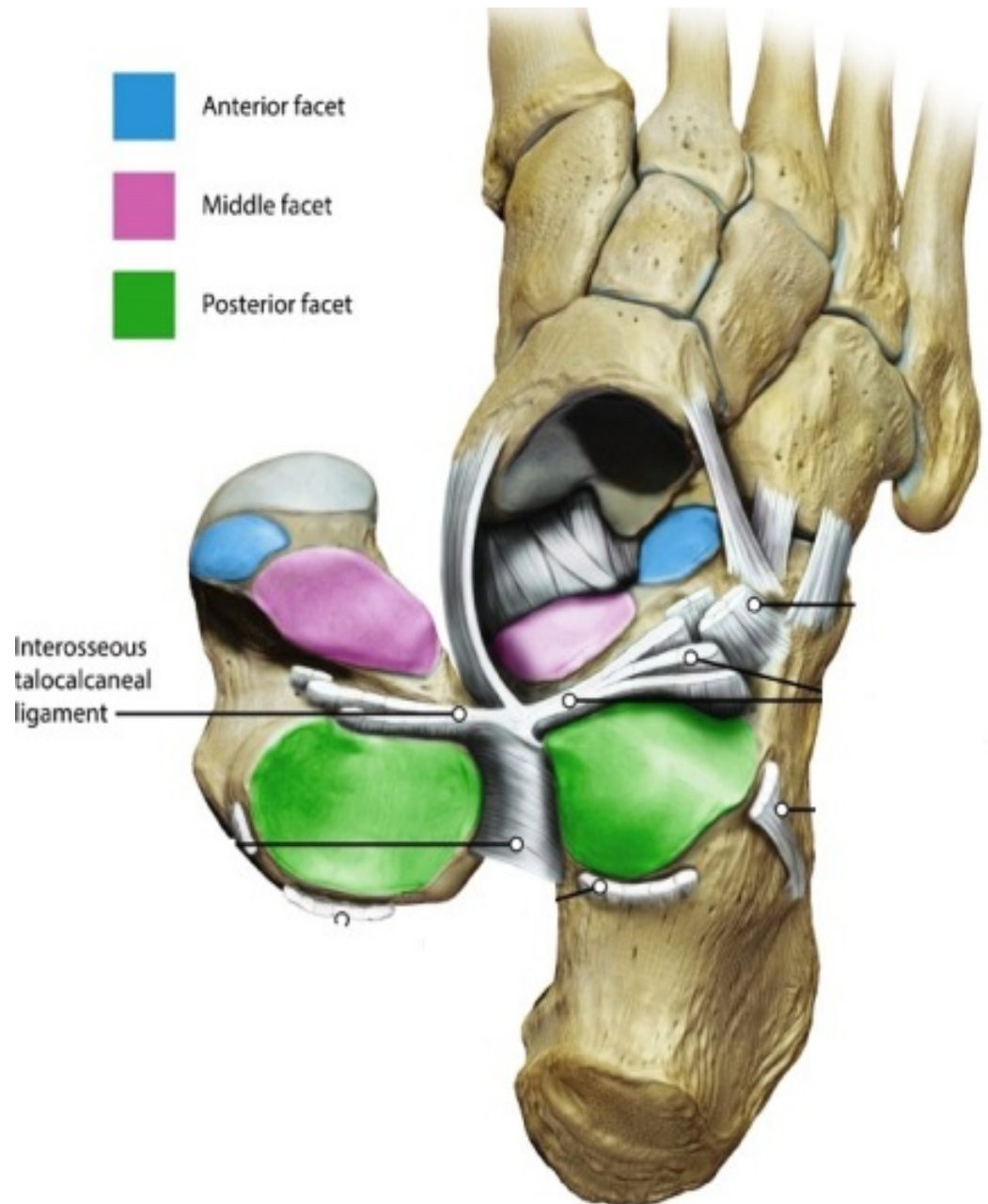
Type: synovial

variety: plane

Articular parts:

lower surface of body of talus

upper surface of calcaneus



JOINTS OF FOOT

2- TALOCALCANEONAVICULAR JOINT

Type: synovial

variety: Ball & socket

Articular parts:

a- **Ball:-** is formed by the head of the talus.

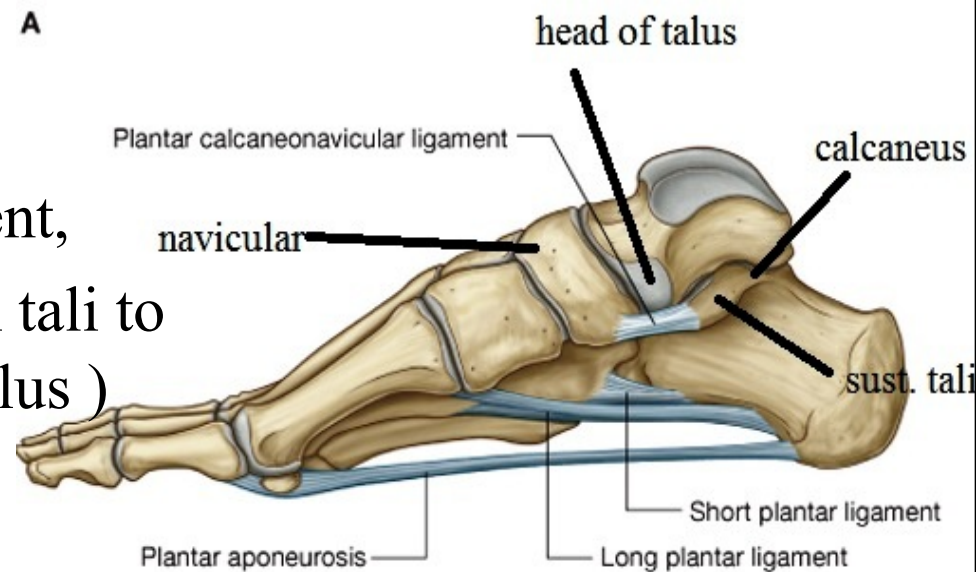
b- **Socket:-** is formed by

- navicular bone,

- upper surface of the spring ligament,
(which extends from sustentaculum tali to
navicular bone it support head of talus)

- sustentaculum tali,

- superior surface of the calcaneus



JOINTS OF FOOT

Movements

1- Inversion

-medial rotation of the foot so the sole looks inwards

- It is done by

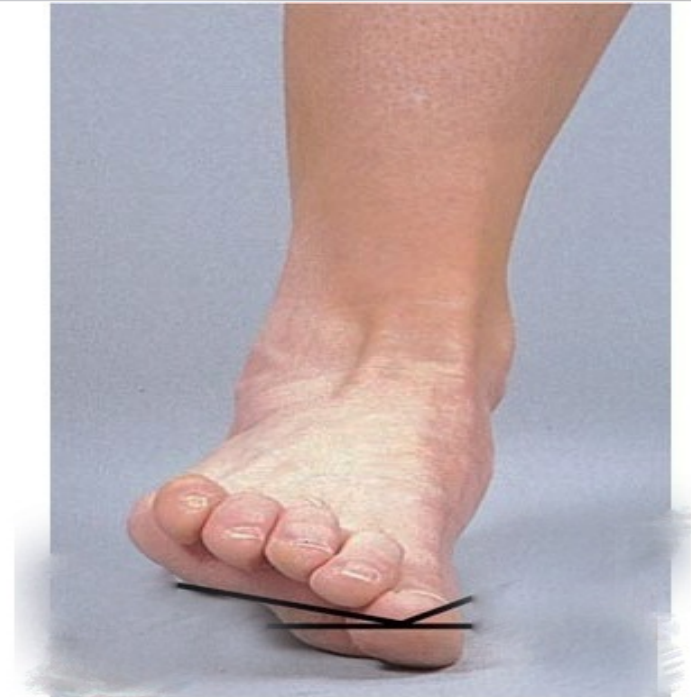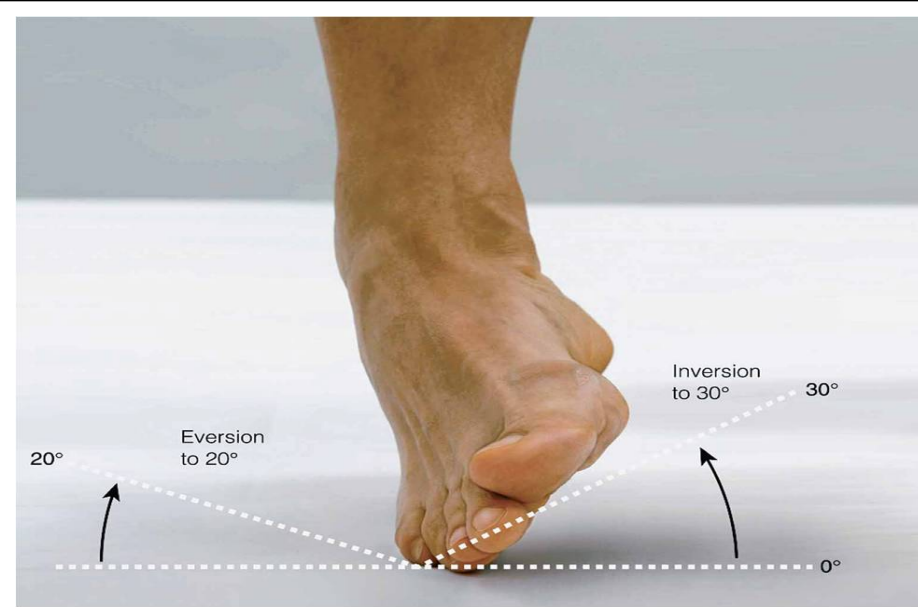
- Tibialis anterior
- Tibialis posterior.

2- Everson:

-Lateral rotation of the foot so the sole looks outwards

-It is done by

- Peroneus longus.
- Peroneus brevis.
- Peroneus tertius.



eversion

TIBIOFIBULAR JOINTS

TIBIOFIBULAR JOINTS

1- superior tibiofibular

Type: synovial **variety:** plane

Articular parts:

Head of fibula

Fibular facet on lateral condyle of tibia

Movements:- sliding

2- middle tibiofibular

the interosseous membrane()tibia & fibula

3- inferior tibiofibular

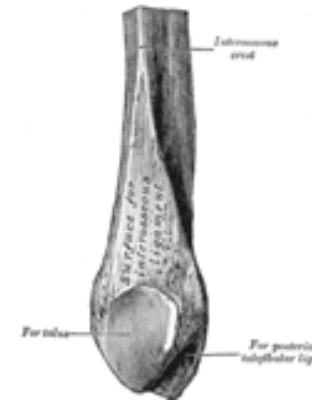
Type: fibrous

Articular parts:

Rough area on medial side of lower part of fibula

Fibular notch on lower end of tibia

Movements:- no



THANQ