

DEEP FASCIA OF THE SOLE

fibrous flexor sheath :

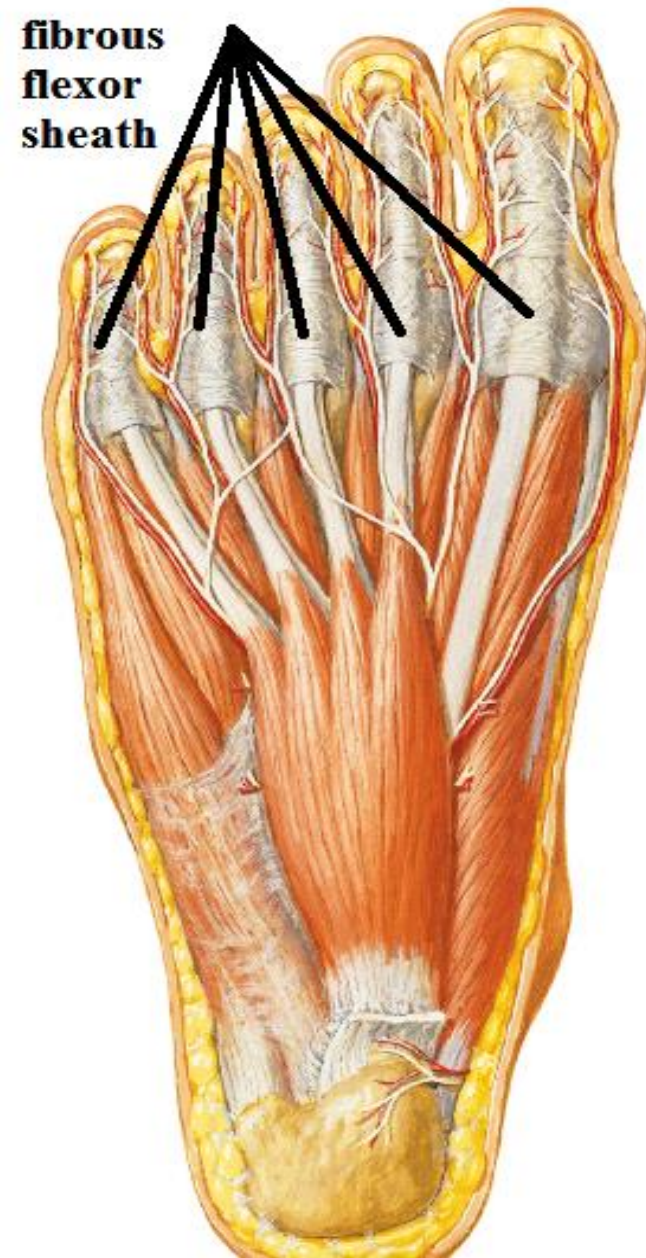Def. : thick deep fascia in planter aspect of toes

contents :

of big toe: flexor hallucis longus

of other toes: flexor digitorum longus & brevis

functions: hold tendons to bone preventing their bowing during flexion



DEEP FASCIA OF THE SOLE

Plantar aponeurosis :

Def.: thick deep fascia in central part of the sole

Attachment: Δ with

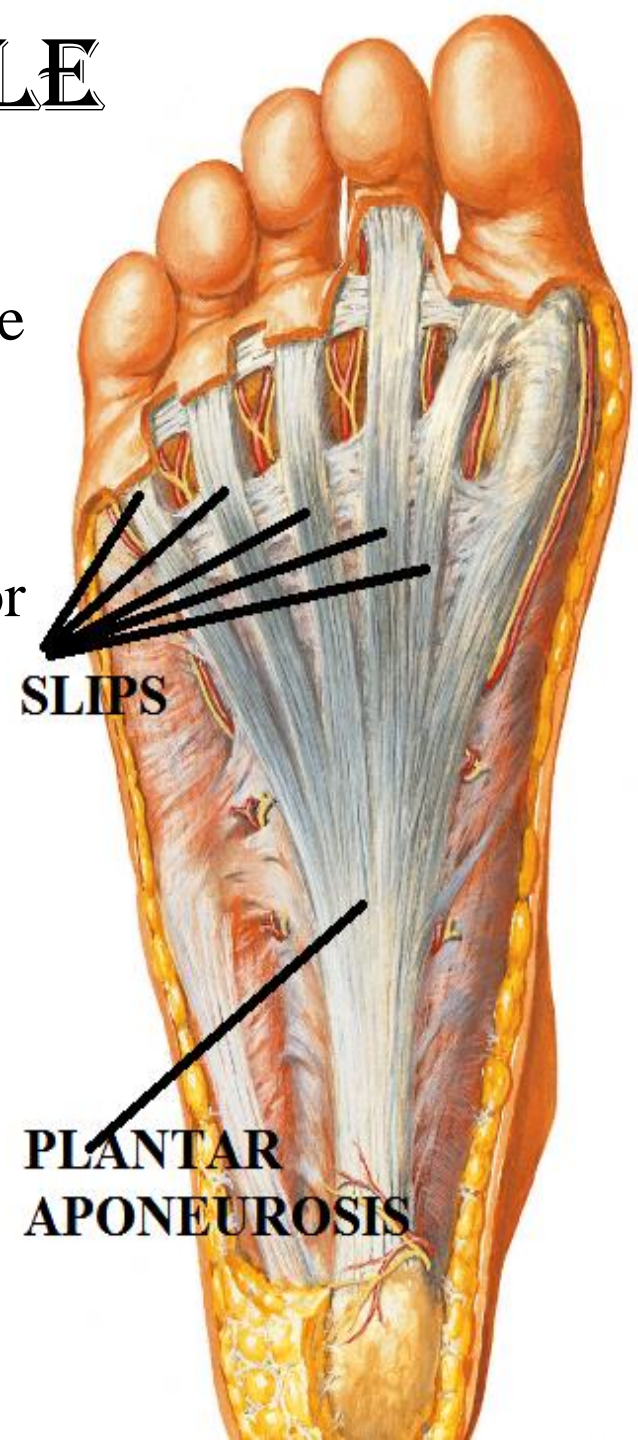
Apex: attach to tubercle of calcaneus

Base: give 5 slips that attach to fibrous flexor sheath of the toes.

-These slips give passage to the planter digital nerves & vessels and lumbrical muscles.

-the slips are interconnected by superficial transverse metatarsal lig.

Function: protect deep structures



MUSCLES OF THE SOLE

1st layer: 3 muscles:

Abductor hallucis:

forms the medial margin of the foot

Abduct the big toe

Abductor digiti minimi:

forms the lateral margin of the foot

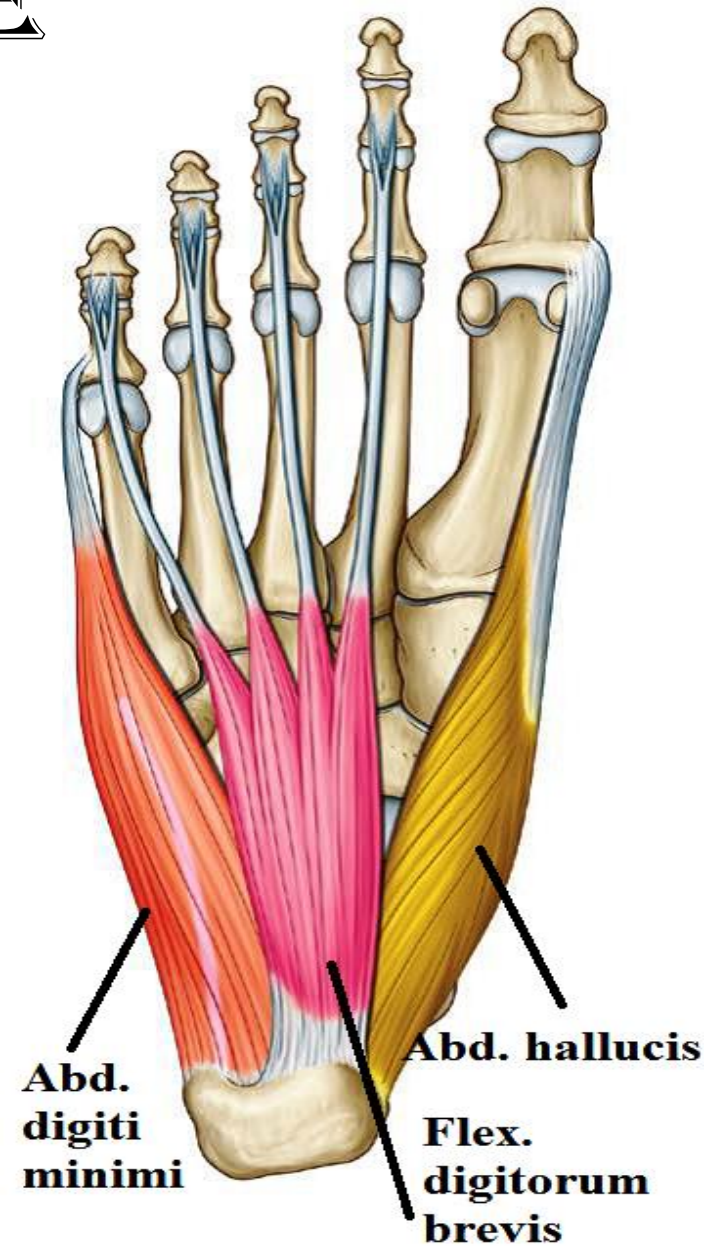
Abduct the little toe

Flexor digitorum brevis:

in the middle of foot ,

just above plantar aponeurosis

Flex the lateral 4 toes



MUSCLES OF THE SOLE

2nd layer: 2 tendons & 2 muscles

1-tendon of flexor hallucis longus

2-tendon of flexor digitorum longus:

Cross superficial to flexor hallucis longus.

Its lateral side receive the insertion of flexor digitorum accessorius

at middle of sole , it gives 4 tendons that give origin to lumbricals then pass () the

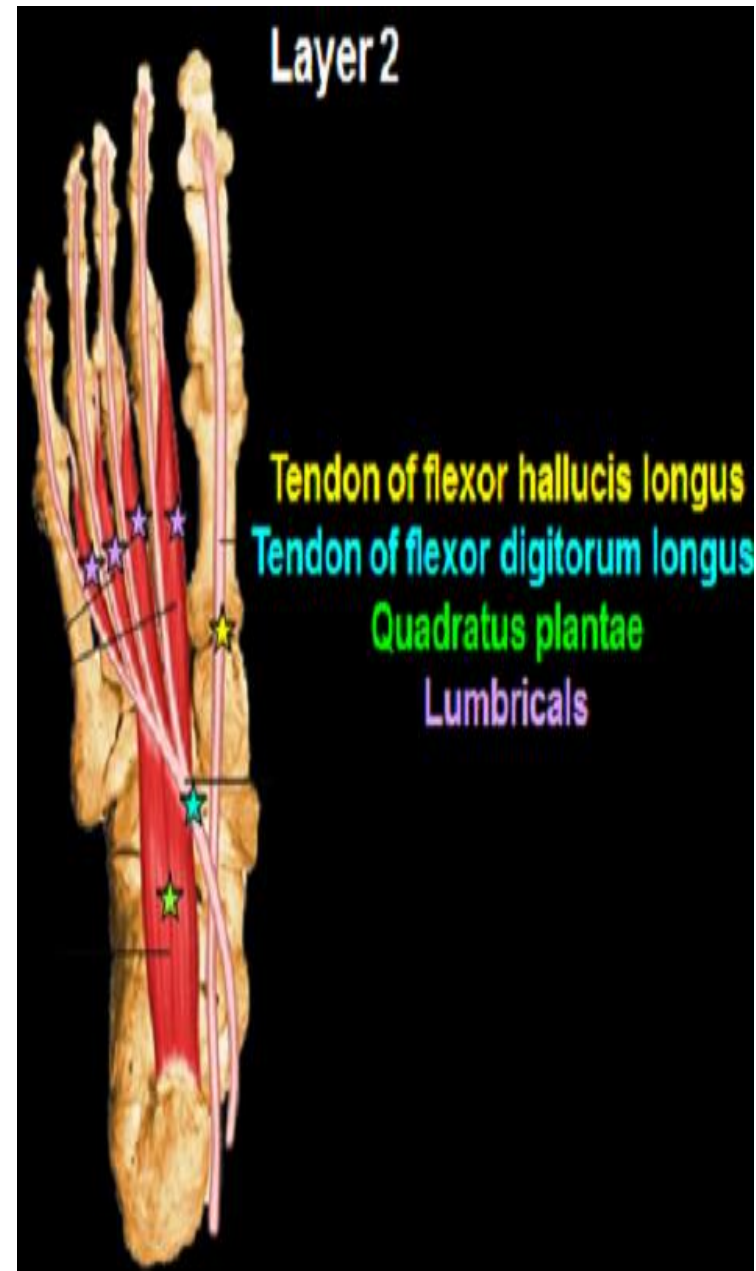slips of tendons of flexor digit. brevis to insert in plantar surface of bases of distal phalanges

3-flexor digitorum accessorius

It straighten the oblique line of pull of the tendon of flexor digitorum longus

4-lumbrical muscles

Flex the M/P joint& extend the I /p joint of the lateral 4 toes



MUSCLES OF THE SOLE

3rd layer: 3 muscles

1-flexor hallucis brevis

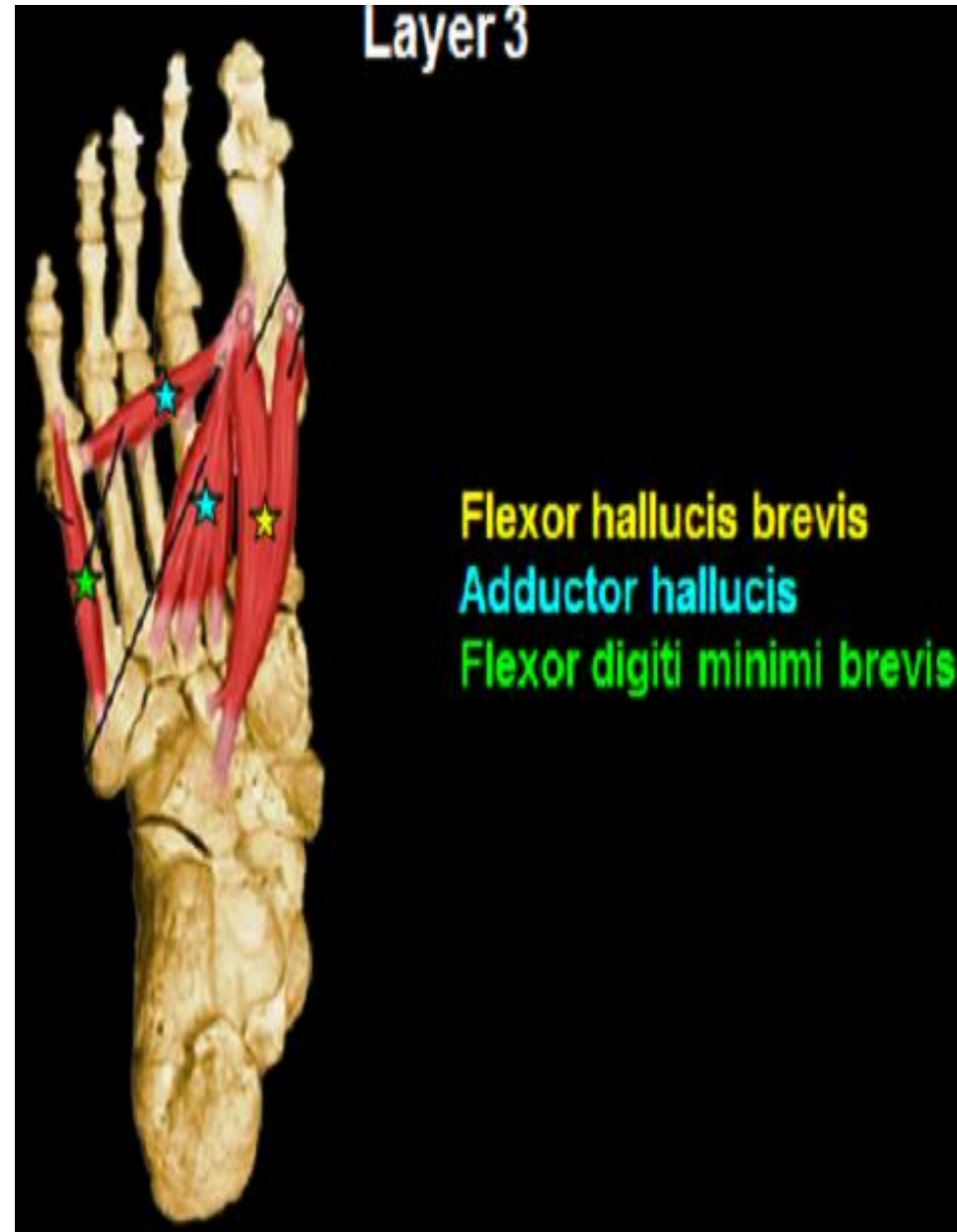Flex the M/P joint of the big toe

2-adductor hallucis

Adduct the big toes

3-flexor digiti minimi brevis:

Flex the M/P joint of the little toe



MUSCLES OF THE SOLE

4th layer: 2 tendons & 2 muscles

1- Peroneus longus:

2- Tibialis post. :

3- planer interossei :

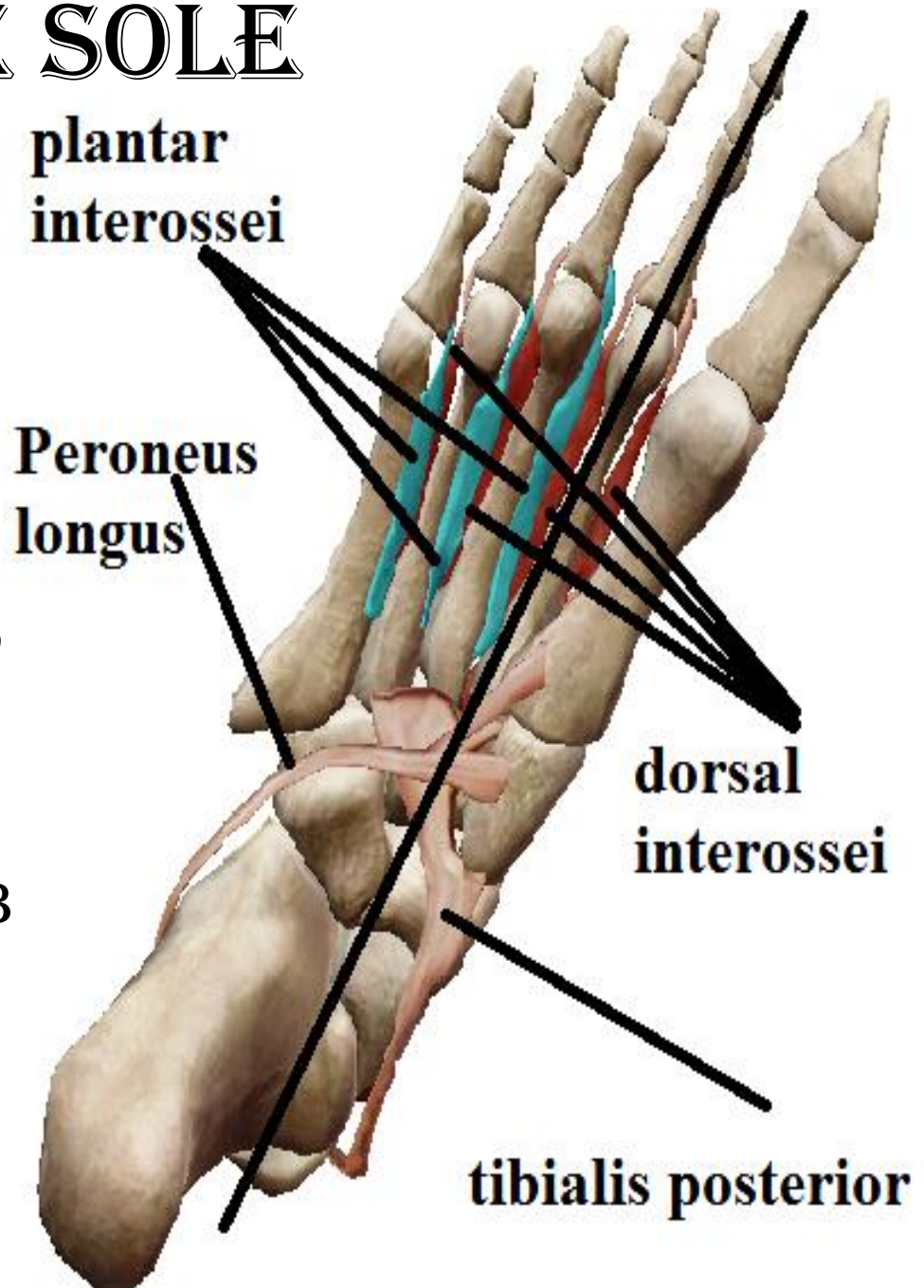
Adduct the toes 3-5

toward the axis of the 2nd toe PAD

4- dorsal interossei :

Abduct the toes 2-4

toward the axis of the 2nd toe DAB



NERVES OF THE SOLE

MEDIAL PLANTAR NERVE

O.: - a terminal br. of post. tibial nerve.

-deep to flexor retinaculum

C & r: (runs with the artery on its medial side)

- pass deep to abductor hallucis

-then () abductor hallucis & flexor digi. Brevis

branches:

Cutaneous:

Medial 2 /3 of sole

plantar surface of medial 3 1/2 toes

N.B: medial plantar n.

has similar distribution as median n. in hand

Muscular

1-(1st layer) abductor hallucis & flexor digitorum brevis

2-(2nd layer) 1st lumbrical

3-(3rd layer) flexor hallucis brevis

flexor hallucis
brevis

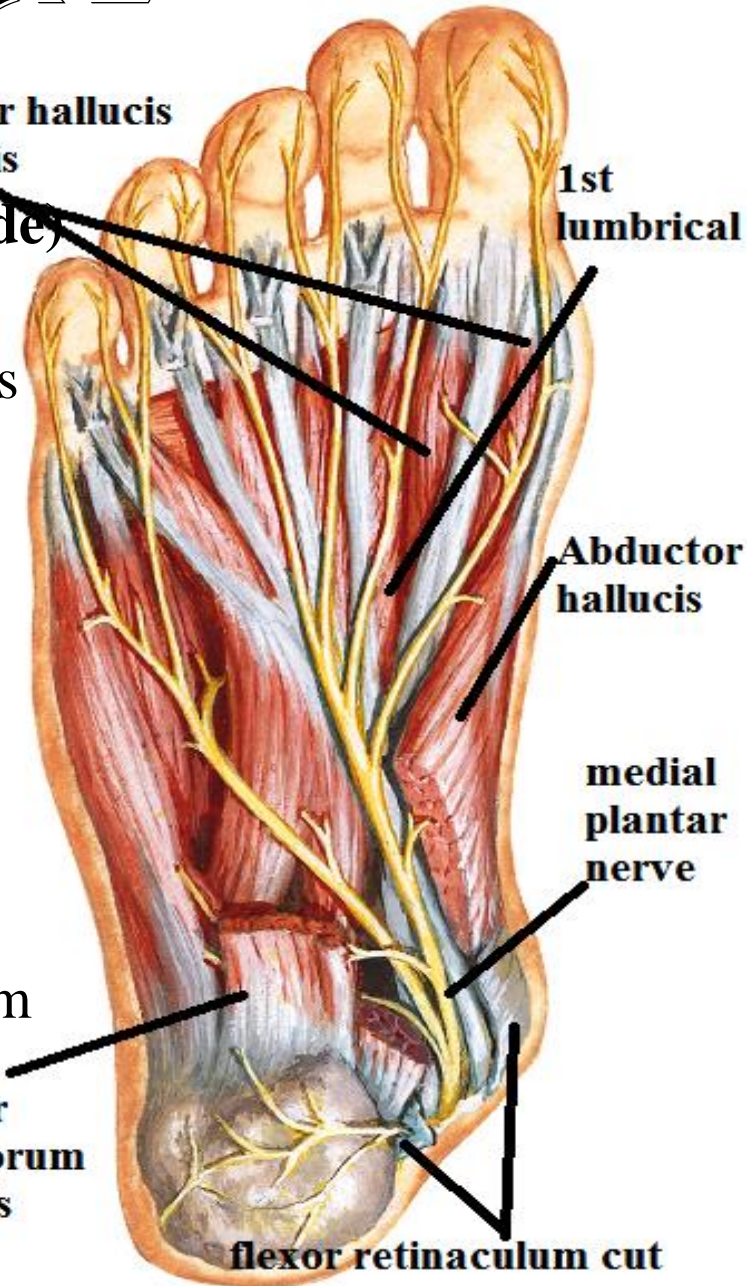
1st
lumbrical

Abductor
hallucis

medial
plantar
nerve

flexor
digitorum
brevis

flexor retinaculum cut



LATERAL PLANTAR NERVE

O.:

- a terminal branch of post. tibial nerve
- deep to flexor retinaculum

C & r: (runs with the artery on its lateral side)

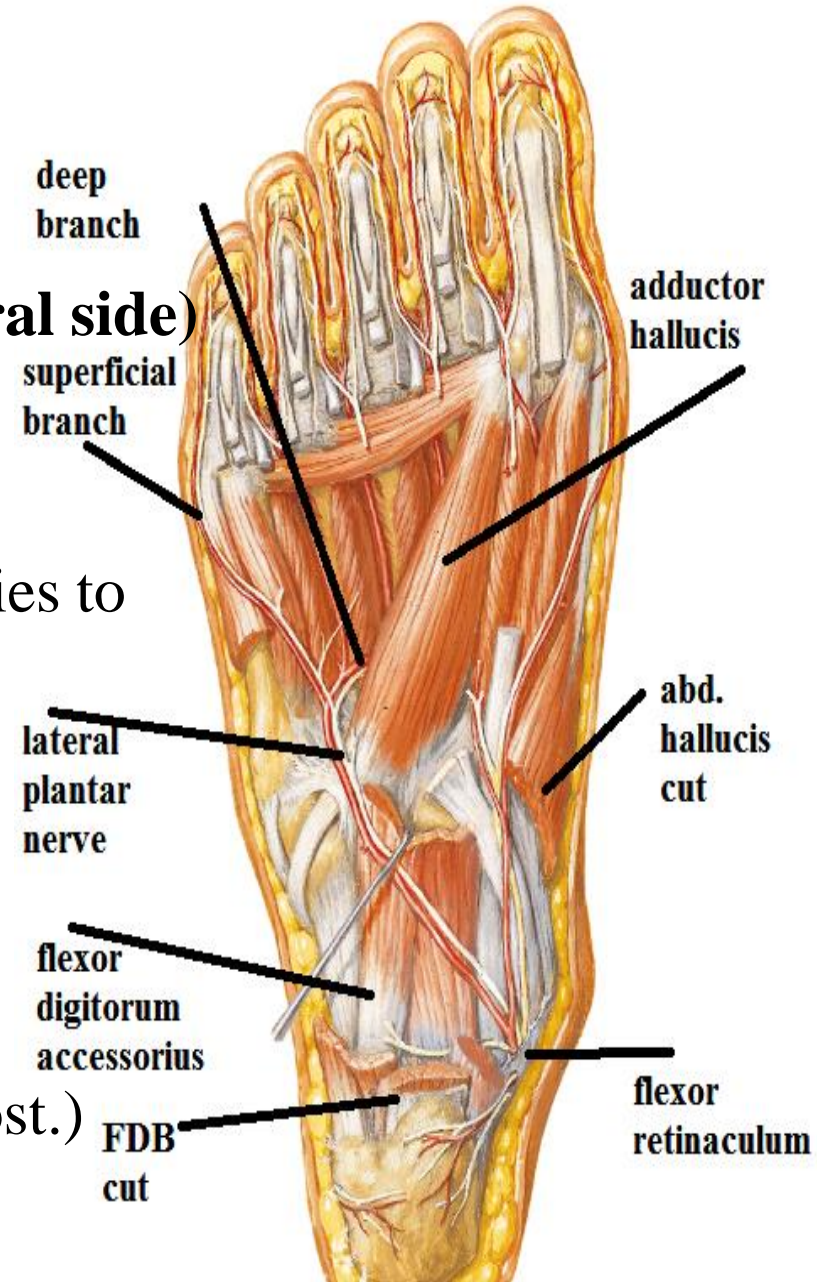
- Pass deep to abductor hallucis.
- then deep to flexor digitorum brevis

i.e. () FDB & flexor digitorum accessories to base of 5th metatarsal where it divide into superficial & deep brs

- the deep br. runs medially

between the 3rd layer (adductor hallucis) and the 4th layer

(tendons of peroneus longus & tibialis post.)



LATERAL PLANTAR NERVE

branches :

اجمالا هيدى باقى الجلد و باقى العضلات

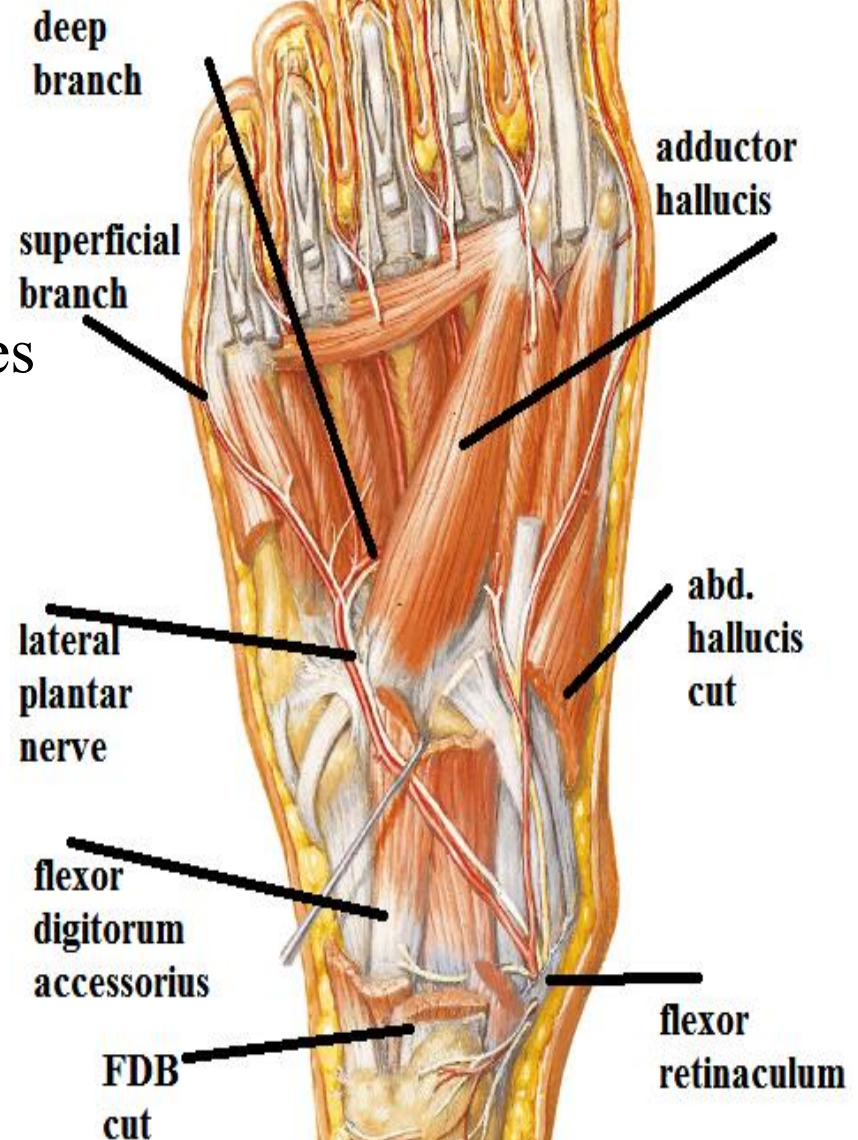
Cutaneous:

Skin of lateral 1 /3 of sole

skin of plantar surface of lateral 1 ½ toes

Muscular

- abductor digiti minimi
- Flexor digitorum accessories
- lateral 3 lumbricals
- flexor digiti minimi brevis
- adductor hallucis
- all interossei



CUTANEOUS
INNERVATION OF
THE FOOT

CUTANEOUS INNERVATION OF SOLE

1- lateral 1 /3 from lateral plantar nerve

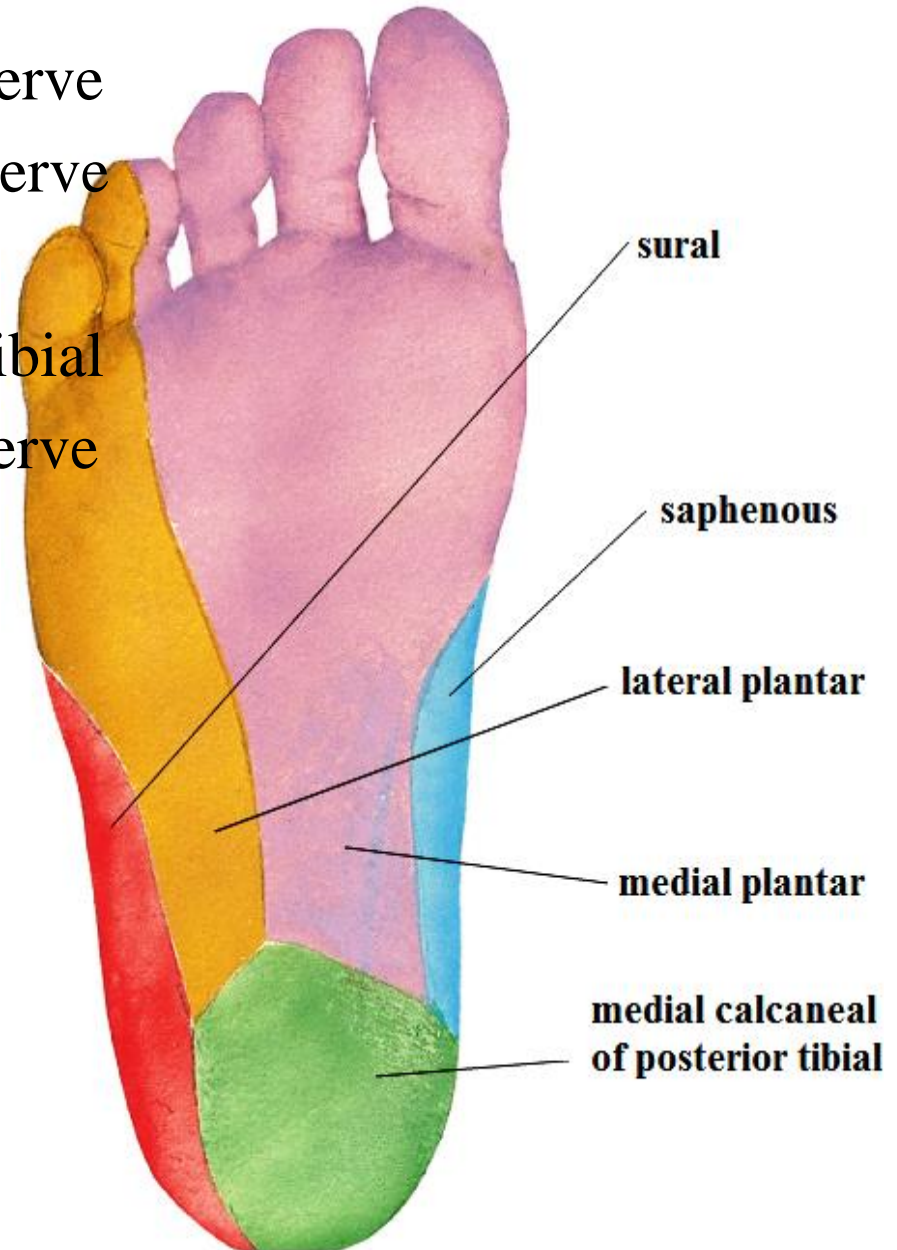
2- medial 2 /3 from medial plantar nerve

3- medial side of heel

from medial calcaneal of posterior tibial

4- medial border from saphenous nerve

5- lateral border from sural nerve



CUTANEOUS INNERVATION OF DORSUM

all the dorsum of foot and toes is supplied by

Superficial peroneal nerve except

1-medial side of dorsum

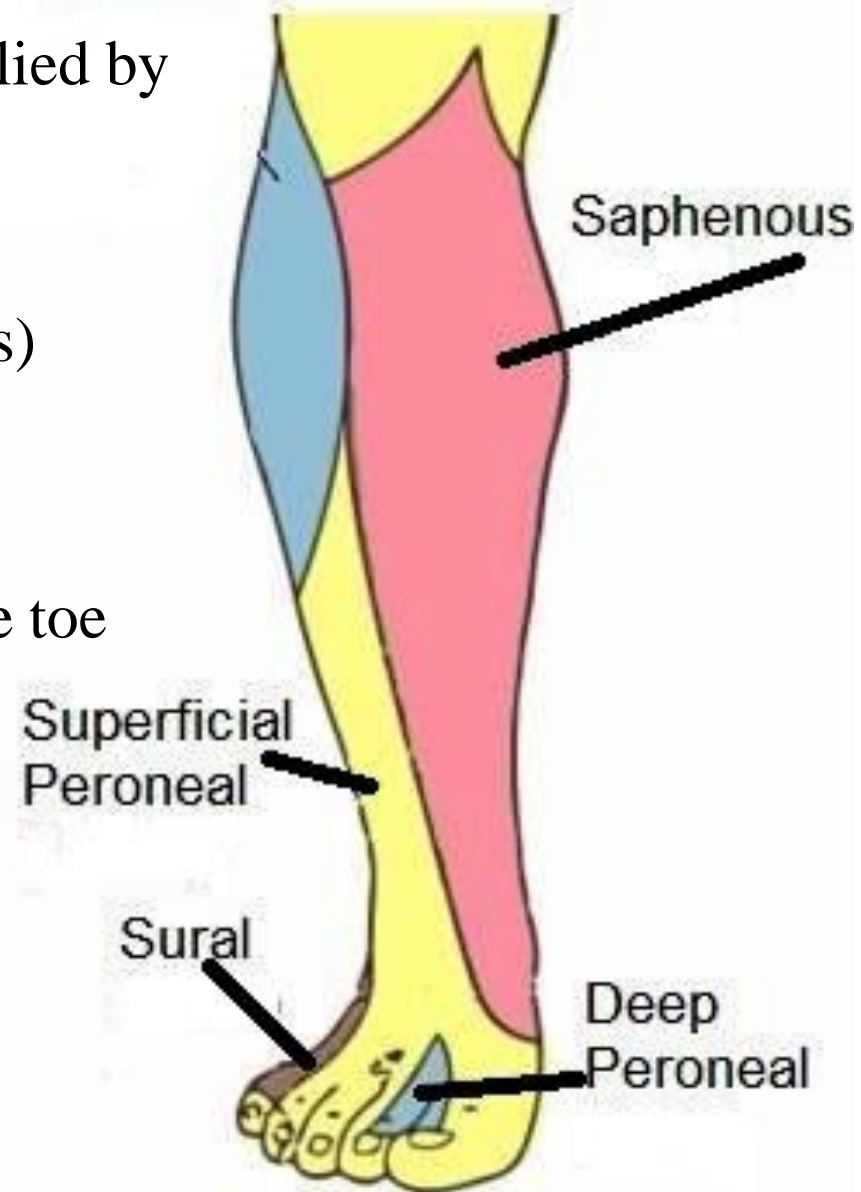
till head of 1st metatarsal (by saphenous)

2-adjacent side of 1st & 2nd toes

(by deep peroneal)

3-lateral side of dorsum of foot & little toe

(by sural)



THANQ